

Loma Linda University

## TheScholarsRepository@LLU: Digital Archive of Research, Scholarship & Creative Works

---

Loma Linda University Electronic Theses, Dissertations & Projects

---

6-2000

### Anti-Inflammatory Agents and the Modulation of Replacement Root Resorption

Geoffrey Toshio Okada

Follow this and additional works at: <https://scholarsrepository.llu.edu/etd>



Part of the [Endodontics and Endodontology Commons](#)

---

#### Recommended Citation

Okada, Geoffrey Toshio, "Anti-Inflammatory Agents and the Modulation of Replacement Root Resorption" (2000). *Loma Linda University Electronic Theses, Dissertations & Projects*. 1594.  
<https://scholarsrepository.llu.edu/etd/1594>

This Thesis is brought to you for free and open access by TheScholarsRepository@LLU: Digital Archive of Research, Scholarship & Creative Works. It has been accepted for inclusion in Loma Linda University Electronic Theses, Dissertations & Projects by an authorized administrator of TheScholarsRepository@LLU: Digital Archive of Research, Scholarship & Creative Works. For more information, please contact [scholarsrepository@llu.edu](mailto:scholarsrepository@llu.edu).

UNIVERSITY LIBRARY  
LOMA LINDA, CALIFORNIA

LOMA LINDA UNIVERSITY

Graduate School

---

Anti-Inflammatory Agents and the  
Modulation of Replacement Root Resorption

by

Geoffrey Toshio Okada


---

A Thesis submitted in partial satisfaction of  
the requirements for the degree of  
Master of Science in Endodontics

---


June, 2000

Each person whose signature appears below certifies that this thesis in their opinion is adequate, in scope and quality, as a thesis for the degree Master of Science.




Mahmoud Torabinejad, Professor of Endodontics

,Chairperson



Leif K. Bakland, Professor of Endodontics



Kenneth R. Wright, Assistant Professor of Anatomy

## ACKNOWLEDGMENTS

I would like to express my appreciation to the individuals who helped me complete this study. I am grateful to Loma Linda University Animal Care Facility for providing the facilities. I wish to thank John M. Chrisler and Charles J. Kean for their advice and the use of their facilities, and I wish to thank the other members of my guidance committee, Leif K. Bakland, Mahmoud Torabinejad, and Kenneth R. Wright for their advice and comments. I am grateful to John M. Hough for providing histologic instruction and Jay S. Kim for providing statistical assistance and advice. I am also grateful to August Tang, Chomquan Tongbayai, Keith T. Komatsu, and Silvia C. M. Cecchini for their technical assistance and support.

This research was partially funded by a grant from the Foundation of the American Association of Endodontists.

## TABLE OF CONTENTS

Approval Page.....	ii
Acknowledgments.....	iii
Table of Contents.....	iv
List of Figures.....	v
List of Tables.....	vi
Abstract.....	vii
I. Introduction.....	1
A. Review of the Literature.....	4
B. Clastic Cells.....	8
C. Inflammation.....	11
D. Anti-Inflammatory Drugs.....	12
E. Animal Models.....	14
F. Medicaments.....	16
II. Materials and Methods.....	20
A. Statistical Analysis.....	22
III. Results.....	28
IV. Discussion.....	35
V. Conclusion.....	40
VI. References.....	41

## LIST OF FIGURES

Figure	Page
1. Clastic cell in resorptive defect on root surface.....	10
2. Arachidonic acid pathway of metabolism.....	13
3. Cross section of root with a normal periodontal ligament.....	23
4. Cross section of root from the control group .....	24
5. Cross section of root from the fluoride group.....	25
6. Cross section of root from the Ketorolac tromethamine group.....	26
7. Cross section of root from the Dexamethasone sodium phosphate group.....	27

## LIST OF TABLES

Table	Page
1. Treatment groups.....	20
2. Analysis between treatment groups for artifact samples using normal approximation to binomial distribution.....	30
3. Analysis using normal approximation to binomial distribution between treatment groups for unchanged samples.....	31
4. Analysis using normal approximation to binomial distribution between treatment groups for resorbed samples.....	32
5. Analysis using normal approximation to binomial distribution between treatment groups for ankylosed samples.....	33
6. Number of recording sites / Number of sites in treatment group for experimental groups and individual examiners.....	34
7. $\kappa$ -statistics of reproducibility between two examiners.....	35

## ABSTRACT OF THE THESIS

### Anti-Inflammatory Agents and the Modulation of Replacement Root Resorption

by

Geoffrey Toshio Okada

Master of Science, Graduate Program in Endodontics

Loma Linda University, June, 2000

Dr. Mahmoud Torabinejad, Chairperson

Replacement resorption (RR) occurs following severe injury to the periodontal ligament (PDL). It has been suggested that inflammatory reactions precede RR. The purpose of this study was to examine and compare histologically the effect of topical application of two anti-inflammatory medications and stannous fluoride (SF) on the development of RR. Thirty-four roots of beagle dog mandibular 2<sup>nd</sup>, 3<sup>rd</sup>, and 4<sup>th</sup> premolars received root canal therapy. They were then extracted and left to bench dry for one hour. Following removal of their PDLs, they were soaked for five minutes in either 10 µg/ml ketorolac (n=10), 16 µg/ml of dexamethasone (n=11), or 1% stannous fluoride (n=10), the latter, which has been shown to inhibit RR. The remaining three roots were rinsed in saline and served as controls. After treating the surfaces of the roots, they were replanted and rigidly splinted for two months. The dogs were sacrificed and their jaws were decalcified. Transverse sections (5µm) were stained and root surfaces were classified according to Andreasen's criteria of: 1) unchanged, 2) resorbed, or 3) ankylosed. Contingency Table Analysis showed significant differences ( $p < 0.003$ ) between the experimental and the control groups, and in many of the pairwise comparisons ( $p < 0.015$ ). Topical application of anti-inflammatory agents such as ketorolac or



dexamethasone show an inhibitory effect on replacement root resorption compared to controls. In addition, ketorolac is more effective than dexamethasone in delaying replacement root resorption. However, stannous fluoride appears to be the more effective medicament than ketorolac or dexamethasone. Consequently, ketorolac or dexamethasone may be useful in combination with fluoride in the treatment of replacement root resorption.

## INTRODUCTION

Three types of external root resorption result from traumatic injuries: surface, inflammatory, and replacement resorption (Andreasen 1985, Bakland 1992, Tronstad 1988). Surface resorption is associated with traumatic injuries that cause minor damage to the cementum, cementoblasts or periodontal ligament (PDL) and is usually observed only histologically. It may be either transient or progressive in nature. The transient type of resorption results in complete repair of the PDL by deposition of new cementum with insertion of Sharpey's fibers. Small areas of the root surface show superficial resorption lacunae repaired by new cementum. In the progressive type, the surface resorption proceeds to involve dentin. Due to their small size, surface resorptions are usually not revealed on radiographs. However, with ideal angulation of the central beam, it is sometimes possible to recognize small excavations of the root surface surrounded by a periodontal space of normal width.

Inflammatory resorption is associated with pulpal deterioration due to traumatic injury and progresses from surface resorption described above. Factors affecting development of inflammatory resorption are, according to Andreasen (1985):

- 1) injury to the PDL (from luxation movement, by removal of PDL from surface, or extended drying of root surface),
- 2) initiation of surface resorption exposing dentinal tubules,
- 3) communication of tubules with necrotic, infected pulp tissue or an inflammatory zone harboring bacteria, and
- 4) patency of dentinal tubules (age related – larger diameter, more rapid resorption).

Histologically, it is characterized by bowl-shaped areas of resorption of cementum and dentin associated with inflammatory changes in the adjacent periodontal tissue. The inflammatory reaction in the periodontium forms granulation tissue with numerous lymphocytes, plasma cells, and polymorphonuclear leukocytes (PMNs). Adjacent to these areas, the root surface undergoes resorption with numerous Howship's lacunae and multinucleated cells. Radiographically, inflammatory resorption is characterized by root resorption with adjacent bone resorption. The first radiographic sign of root resorption can be seen as early as two weeks after trauma and is usually first observed in the apical third of the root (Andreasen 1966).

Replacement resorption occurs following extensive damage to cementum and PDL. Tooth structure is replaced with bone, resulting in bone and dentin fusing together in ankylosis of the tooth. It can, for instance, be demonstrated histologically as early as two weeks after replantation. Osteoclasts remove dentin before cementoblasts can cover the exposed dentin with cementum. The etiology of replacement resorption appears to be related to the absence of vital cementum covering the root surface and the presence of necrotic PDL cells and tissue. In teeth where damage has occurred to the PDL and cementum with resultant ankylosis, either transient or permanent ankylosis will occur. During the process of replacement resorption, damaged PDL is replaced with cells from adjacent bone marrow. These cells have osteogenic potential, producing bone, which replaces dental tissues, resulting in ankylosis of the tooth. The transient form is related to minor areas of damage upon the root surface. In these cases, ankylosis is initially formed and then resorbed by adjacent normal areas of the PDL. Permanent ankylosis is a progressive form, which occurs when extensive areas of PDL are removed from the root,

or excessive drying has occurred prior to replantation [i.e. extra-oral for extended time periods resulting in a dried PDL (Gilles et al., 1994)]. The progressive nature of replacement root resorption is a major concern in the treatment of traumatically injured teeth, and for transplanted and intentionally replanted teeth. Resorption can be observed histologically as early as two weeks after the procedure. Radiographically, it is characterized by disappearance of the normal periodontal space and continuous replacement of root substance with bone. Replacement resorption has a significant preference for certain locations on the root surface: It is more common in the apical half of the root compared to the cervical half (Andreasen 1980b).

It appears that resorption is more likely to occur after extensive trauma, including surgical trauma, when teeth are extracted for the purpose of intentional replantation. The PDL is forced against the alveolar process, damaging the cementoblasts. Resorption takes place on the root surface directly beneath the areas of cementoblastic damage.

It has been suggested that inflammatory reactions precede replacement resorption (Trope et al., 1997). The hypothesis of this study is that the topical use of anti-inflammatory medications will reduce the amount of replacement resorption.

The purpose of this study was to compare histologically the effect of topical applications of: 1) a non-steroidal anti-inflammatory drug (NSAID), 2) a corticosteroid, or 3) stannous fluoride on the development of replacement root resorption of intentionally extracted and replanted teeth in beagle dogs after an 8 week period.

## Review of the literature

Tronstad (1988) and Bakland (1992) discuss replacement resorption or dento-alveolar ankylosis as characterized by cementum and dentin being replaced with bone that fuses with dentin. It is a serious condition because the teeth become part of the alveolar bone remodeling process and are progressively resorbed. It occurs most frequently as a result of complications following luxation injuries, especially avulsions in which the PDL dries and loses its vitality. In the transient type, less than 20% of the root surface becomes ankylosed and cannot be reliably detected clinically. In such cases, reversal may occur, resulting in re-establishment of a PDL connection between tooth and bone. In the progressive type, tooth structure is gradually resorbed and replaced permanently with bone. The cells responsible for replacement resorption are the osteoclasts. Histologically, there is a direct fusion between dentin and bone. Lack of mobility and a high-pitched metallic sound when percussed are often the first indications of ankylosis involving more than 20% of the root surface.

Currently, there is no treatment for replacement resorption. It may be possible to slow the resorptive process by treating the root surface with a fluoride solution prior to replantation of teeth in which the PDL and cementum are not viable any longer. Without vital surface cells, ankylosed teeth are incorporated in the alveolar bone and become part of the normal remodeling process of the bone, gradually being resorbed and replaced by bone. However, replacement resorption should not automatically be viewed as a failure, since a replanted tooth may last for many years. Complete bony replacement of the root may occur, but it should not be regarded as a disease process. It occurs as a natural mistake because the cells involved in the remodeling of bone are not able to distinguish

between cementum, dentin, or bone. The speed with which the tooth is replaced by bone varies, and is dependent on extra-oral time, hormonal regulation, age, and metabolic rate of the patient.

According to Andreasen (1985), ankylosis is a fusion of the alveolar bone with the root surface and can be demonstrated histologically as early as 2 weeks after replantation. The pathogenesis of replacement resorption is manifested in two ways: either permanent (progressive) or transient replacement resorption. The progressive form is always elicited when the entire PDL is removed before replantation and there is gradual resorption of the entire root. Transient replacement resorption is possibly related to minor areas of damage on the root surface. In these cases, the ankylosis is initially formed and later replaced with adjacent normal areas of the PDL. The etiology of replacement resorption appears to be related to the absence of a vital PDL covering the root surface. A vital PDL apparently possesses an anti-invasion factor that resists the invasion of bone cells. Osteoclasts, acting as phagocytic cells, actively participate in the healing process to repair traumatized teeth and bone.

The amount and rate of resorption is related to the time the tooth has been out of the mouth. Hammarstrom et al. (1989) extracted and replanted 72 maxillary and mandibular teeth on 18 monkeys. The maxillary teeth had root canal treatment and were allowed to dry for 1 hour before replantation. However, the mandibular teeth had no root canal treatment and were allowed to dry for 15 minutes before replantation. Antibiotics were given to half the monkeys in each group for two weeks. The animals were sacrificed from 2 days to 40 weeks after replantation. Histological and histometric analyses revealed that teeth with short extra-oral time, with or without root canal

treatment or antibiotics had 60-70% normal periodontium at 40 weeks with minor ankylosis. Teeth left to dry for 1 hour had 60-80% resorption and ankylosis with 50-70% loss in root length.

The exact mechanism behind this replacement resorption is essentially unknown but is suggested to be a hormonally regulated process initiated by endosteal osteoblasts (Hammarstrom et al., 1989). When a permanent dentoalveolar ankylosis is established, the cementoblasts and the periodontal membrane are lost and the dental root is covered by osteoblasts and osteoclasts in continuity with the endosteal cells outlining the marrow spaces of the alveolar bone. The osteoblasts may mediate root resorption following parathyroid hormone stimulation. The vitality of the periodontal membrane is critical for long-term good prognosis for a replanted tooth. It is important to have a very short extra-oral period or a suitable storage medium for the avulsed tooth during the extra-oral period.

The rate of root resorption appears to be related with the patient's age. Andersson et al. (1989) studied the case records and radiographs of 29 patients between the ages of 8 and 39 years. Thirty-nine teeth had been avulsed and subsequently replanted after being stored dry extra-orally for 60 minutes or longer. Twenty-six patients had been prescribed antibiotics for 7 to 10 days. Pulp were extirpated from 1 to 56 days after replantation (average 20 days). Calcium hydroxide was used as a temporary root canal material in 22 teeth. The observation time ranged from 1-142 months (average 58 months). The rate of root resorption was found to be related to the age of the patient at the time of trauma, while the time of pulp extirpation had no significant influence. Teeth replanted in young

patients resorbed, ankylosed, and then resorbed in 3-7 years, whereas in older patients, under similar conditions, the teeth survived for a longer time.

Among the factors associated with root resorption, the length of extra-oral time appears to be the most important. Gunday et al. (1995) studied 9 canine teeth by scanning electron microscopy 90 days after replantation. After extraction, teeth were stored in saline solution for 5 minutes, replanted with pulps intact or stored in saline for 30 or 120 minutes, obturated with calcium hydroxide sealer and replanted. Flexible splinting was applied for 1 week. Root resorption was observed on various regions of all teeth in the experimental groups. The worst resorption was observed in the cases without root canal fillings and stored for 5 minutes in saline. However, resorption was found to be much more extensive in those teeth stored extra-orally for 120 minutes than for 30 minutes. No ankylosis was observed.

In a review article by Andreasen et al. (1992), replacement resorption is related to the severity of injury to the PDL or damage to the PDL as a result of extra-oral drying of avulsed and replanted teeth. The etiology of replacement resorption is related to the absence of a vital PDL. When the site of injury is extensive, the competition between PDL and bone healing favors bone healing, thereby creating ankylosis. When minor injuries to the PDL occur, temporary ankylosis is reported with subsequent reversal.

The initial appearance of ankylosis has been found to occur in two varieties, with or without initial resorption of the root. The presence of bacteria on the root surface and a non-vital PDL or a defect in the cementum cover of the root may activate an osteoclast attack prior to bone apposition. Once ankylosis is established it becomes an integral part



of the continuous bone remodeling system as well as the osteoclast/calcium homeostasis system; it may also be a part of growth-related bone remodeling, which is age dependent.

### Clastic cells

It is hypothesized that the clastic cells are attracted only to or can attach only to mineralized tissue. Therefore, if mineralized tissue is not present, the osteoclast will not be attracted. Conversely, either removal or mineralization of the organic matrix of bone or the root covering will make it possible for the phagocytic cells to recognize the mineral component. Consequently, an injury that results in removal of the precementum or pre dentin, or any process that results in mineralization of the organic matrix, predisposes the root to resorption. Damaged PDL areas and parts of the root surface are removed by a resorptive process, leading to the resorption of cementum and dentin. If the resorption cavity penetrates the intermediate layer of cementum and comes in contact with dentinal tubules communicating with infected necrotic pulp tissue or an infected leukocyte zone, then inflammatory resorption will occur as a result of the diffusion of bacterial toxins and cytokines from the pulp chamber to the root surface.

According to Hammarstrom et al. (1985), the osteoclast is the main cell involved in the resorption of both bone and other hard tissues including dentin, but other cells, such as the macrophage and the monocyte, have been reported to have bone-resorbing capacity. Currently, it is accepted that osteoclasts originate from bone marrow precursor cells from the macrophage-monocyte cell line, the granulocyte-monocyte colony forming unit. Slight morphologic differences have been described between bone resorbing osteoclasts and the odontoclasts, which are responsible for root resorption (Ten Cate et

al., 1986). Considering these differences, it might be appropriate to define the resorbing cells according to the tissue being resorbed. Osteoclasts may become activated by bacterial toxins and cytokines (interleukins, IL-1, IL-3; tumor necrosing factors, TNF- $\alpha$ , TNF- $\beta$ ; colony stimulating factor, CSF; prostaglandins, PGs; and leukemia-inhibitory factor, LIF), which are released from inflammatory cells (Andreasen et al., 1994; Hammarstrom et al., 1985, 1992). (Figure 1)

In 1988, Lindskog et al. used 8 monkeys to study odontoclast colonization of a dentin surface. Thirty-two second permanent maxillary and mandibular incisors were extracted and experimental cavities prepared on the root surfaces. The pulps of the teeth were immediately infected with bacterial plaque from adjacent teeth and the teeth replanted. The teeth were extracted between 20 hours to 4 weeks and prepared for scanning electron microscopy.

Odontoclasts were observed to undergo a series of specific morphological plasma membrane changes during spreading on a dentin surface and development into actively resorbing cells. The cells appear to explore the dentin surface to find an area suitable for resorption. The cells then increase in size and a progressive disappearance of the peripheral fringe occurs. Adaptation to the surface is characterized by active resorption of the dentin surface evidenced by the presence of resorption lacunae. Bacterial inflammation, which is a well-known stimulant of bone and dentin resorption, appears to increase the activity of the odontoclasts.

It is widely accepted that odontoclasts responsible for resorption of dental hard tissue resemble the osteoclast, since both clastic cells have the same ultrastructural and functional characteristics. These osteoclast-like cells have the capacity to absorb distinct

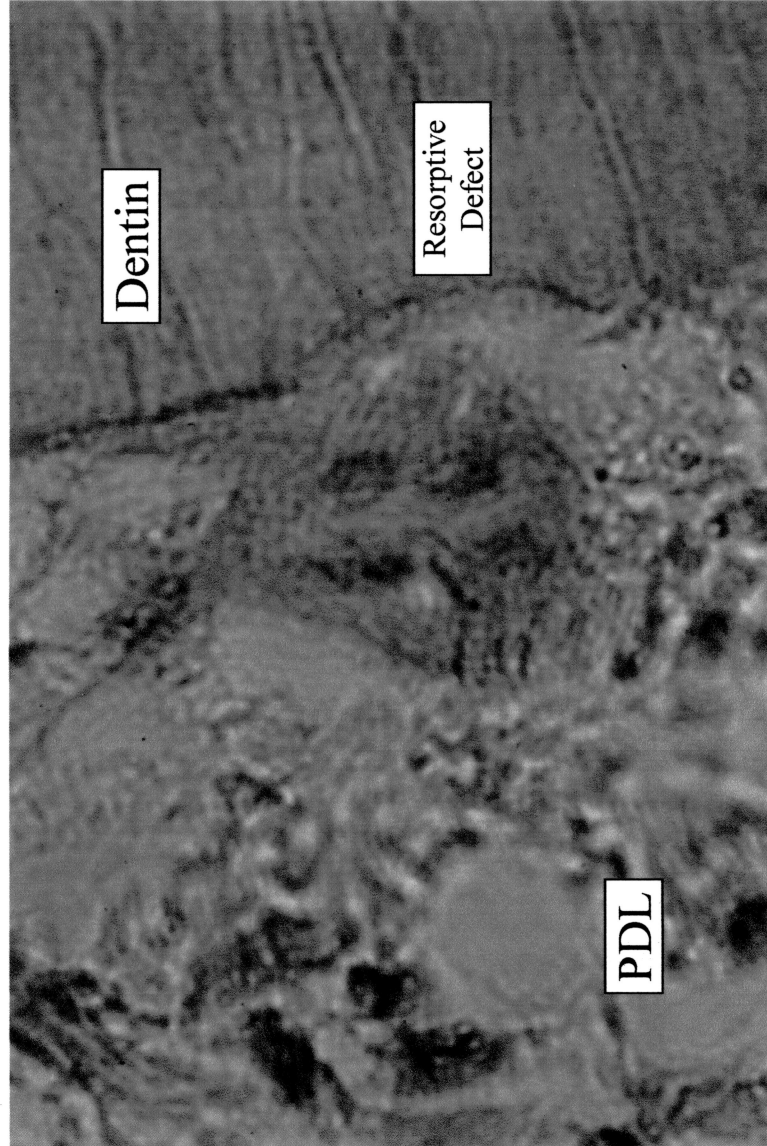


Figure 1. Clastic cell in resorptive defect on root surface (x 400 magnification).

mineralized tissues (bone, cementum, or dentin) at the same time. Scanning electron microscopy revealed that when resorption is restricted to the cementum layer, mononuclear cells instead of osteoclast-like cells are seen (Wesselink et al., 1986).

Sahara et al. (1996), using tartrate resistant acid phosphatase (TRAP) activity for a histochemical marker for odontoclast differentiation, identified mononuclear precursor cells and observed their morphological as well as functional differentiation into mature multinucleate odontoclasts. It was demonstrated that: 1) odontoclasts differentiate from TRAP-positive mononuclear cells, which presumably originate from hematopoietic stem cells, 2) membrane specialization of odontoclasts occurs with development of a clear zone and ruffled border (the most important morphological and functional differentiation of clastic cells), 3) multinucleation of odontoclasts takes place only after attachment to the resorption surface, 4) mature multinucleate odontoclasts can resorb predentin as well as dentin in the same way osteoclasts resorb bone, and 5) at the end of resorption, odontoclasts gradually lose their ruffled borders and become detached from the resorbed surface.

### Inflammation

Torabinejad and Kettering (1985) have reported that the interaction of T cells and antigens can cause lymphocyte proliferation and the release of lymphokines. These biologically active materials can affect the behavior of macrophages, PMNs, and lymphocytes. In addition, lymphocytes present with an osteoclast-activating factor. Macrophages along with monocytes can cause bone resorption by release of inflammatory mediators, such as prostaglandins (PGs). Torabinejad et al. (1985) further

reported that production of PGs is the key element for bone destruction. Mechanical injury to the periapical tissues is likely to initiate the release of non-specific mediators of inflammation.

Trowbridge (1997) described how neutrophils and macrophages produce PGs and leukotrienes (LTs) during the inflammatory process. The precursor molecule, arachidonic acid, is produced by the action of phospholipase A<sub>2</sub> on cell membrane phospholipids. The activation of neutrophil lysosomal phospholipase during inflammation is thought to be a major mechanism in initiating the formation of arachidonic acid. Once formed, arachidonic acid metabolism proceeds along one of two different pathways: the cyclooxygenase (COX) or the lipoxygenase pathway.

#### Anti-inflammatory drugs

Mediators generated by COX (also known as PGH synthase) include PGs and thromboxane (Tx). Two isoforms of the membrane protein COX have been identified. COX-1 is expressed in most tissues and is responsible for the physiological production of PGs. COX-2, which is induced by cytokines, mitogens and endotoxins in inflammatory cells, is responsible for the elevated production of PGs during inflammation (Kurumbail et al., 1996). NSAIDs, such as aspirin and indomethacin, inhibit both COX-1 and COX-2 and thus suppress PG synthesis. Corticosteroids, such as dexamethasone, inhibit phospholipase A<sub>2</sub> and suppress the production of arachidonic acid and subsequent metabolism via the COX and lipoxygenase pathways (Figure 2). It has also been found that corticosteroids inhibit specifically the expression of COX-2 (Seibert et al., 1997).

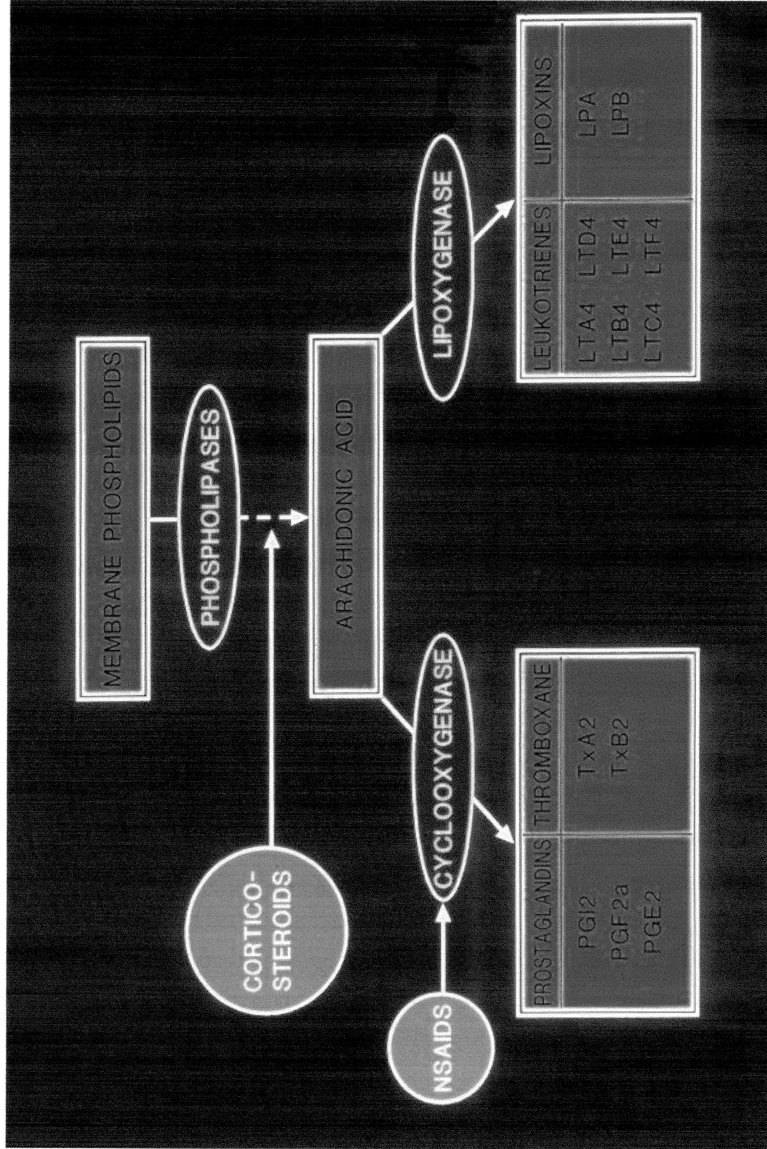


Figure 2. Arachidonic Acid Pathway of Metabolism  
 Corticosteroids inhibit the action of phospholipase on arachidonic acid production.  
 NSAIDs inhibit cyclooxygenase and suppress PG and Tx synthesis.

## Animal models

Studies on replantation have been performed on teeth in several animal models. Mirzabagi used 40 rabbits in autograft and allograft tooth transplantation studies in 1978. The rabbits were non-inbred, genetically heterogeneous but known to be well characterized for serologically significant genes. All animals were of known antigenic configuration for the major histocompatibility locus (RL-A). Three groups of animals were pre-immunized by means of skin allografts before tooth transplantation, and two groups were not pre-immunized. Tooth transplantation was performed one week after complete rejection of skin grafts. The lower right incisors were transferred back to their own socket and the lower left incisors were transplanted to the left side of another rabbit. Specimens were prepared after 4, 6, 8, and 10 weeks. Varying degrees of alveolar bone resorption were observed in all transplants. Bone resorption in autografts could be due to the inflammatory reaction from the surgical procedure, to occlusal trauma, or to the septic environment of the oral cavity. Immunogenetic differences may be an additional factor in allografts.

From these results it was postulated that degeneration of the periodontal ligament and a diminished vascular supply to the area can inhibit root resorption or ankylosis and obviously result in no reattachment. Autografts exhibited a greater degree of reattachment of periodontal ligament than did allografts. Ankylosis was more prominent in allografts than in autografts. Allograft rejection may cause degeneration of the root forming structures as well as degeneration of periodontal ligaments and surrounding alveolar bone.

As Andreasen (1981) demonstrated in monkeys, active inflammatory resorption is connected with necrotic pulp tissue or a leukocyte zone in the pulp communicating with the resorption site. Sixteen maxillary central incisors were extracted and replanted after storage in saline solution for 18 minutes. Six teeth were replanted without endodontic treatment and 10 teeth with endodontic treatment. In addition, 93 maxillary central incisors or mandibular lateral incisors were prepared for histobacteriologic study. Specimens were collected after 2 and 8 weeks. It appeared that teeth without bacteria in the necrotic pulp tissue had significantly fewer leukocyte zones and inflammatory resorption cavities than teeth with bacteria in the necrotic tissue. In every case, the pulp tissue subjacent to the dentinal tubules that led to an inflammatory resorption area contained bacteria. Furthermore, the presence of bacteria in the dentinal tubules, their penetration, and the area involved were significantly related to the presence of inflammatory resorption of the root. Histologic evidence seemed to support the protective action of the intermediate layer of cementum located under the regular cementum layer.

The cementum layers that cover the roots of the teeth are thought to be essential elements in the resistance of the root to resorption. On the most external aspect of the cementum is a layer of cementoblasts covering a zone of non-mineralized cementoid. This cementoid layer is predominantly organic in nature, as is the predentin layer internally, and both are thought to be key in resisting resorption. Animal experiments support the theory that it is the outermost layers of the cementum that prevent resorption.

Wesselink et al. (1986) applied liquid nitrogen to the exposed jaws of 24 female mice. Five applications of 10-second duration were performed in the region of the first



and second mandibular molars. Specimens obtained from 15 minutes to 32 days following cold application were prepared for light and electron microscopy.

Ankylosis and root resorption were induced in a fairly reproducible manner without accompanying infection of the periodontal tissues and without causing fractures of the alveolar bone. Disruption of all cellular elements in the treated portion of the periodontal ligament was noted after cold application. A thin layer of mineralized material appeared along the root surface a few days following cold application. Subsequent phagocytosis of this material may have initiated root resorption. One or two weeks following cold application, root resorption started and layers of bone were deposited along the alveolar wall which sometimes occupied the entire width of the periradicular space, thereby resulting in ankylosis. The authors concluded that severe damage inflicted upon the periodontal ligament is usually followed by root resorption and ankylosis.

### Medicaments

In teeth with prolonged extra-alveolar periods, root surfaces have been treated with numerous substances to inhibit root resorption. Shulman et al. (1973), extracted bilateral lateral incisors in rhesus monkeys, extirpated the pulps, immersed the teeth in 2% phosphate-acidulated sodium fluoride (pH 5.5) for 20 minutes and rinsed before replantation. In this model, it was postulated that release of fluoride from the replant into the adjacent alveolar bone tended to inhibit bone resorption and produce a net increase in bone formation, and thereby enhance ankylosis.

Citric acid was used by Klinge et al. (1984) on replanted maxillary anterior teeth

of beagle dogs. They reported that the frequency of ankylosis after replantation of teeth that have been air-dried for 45 minutes, could be reduced by removing non-vital periodontal ligament remnants from the root surface, exposing dentin matrix collagen by treatment with citric acid, and preventing direct contact between the alveolus and the root surface during the healing period. Conversely, Zervas et al. (1991) in a similar study using citric acid, showed that surface demineralization of teeth prior to replantation led to poor healing.

Bjorvatn et al. (1989), in a study using beagles, found that application of SnF<sub>2</sub> to the root surface prior to replantation effectively reduces resorptive processes during the first post-operative weeks. By subsequently treating the root surface with tetracycline, the adverse effect of SnF<sub>2</sub> on periodontal connective tissue repair may be reduced. In a later study, Selvig et al. (1990) found that the frequency of adverse healing reactions after delayed replantation of teeth from which non-vital soft tissue remnants have been removed can be reduced by demineralizing the root surface and preventing mechanical trauma to the root surface during the 21 day post-operative period. Root surface treatment with SnF<sub>2</sub>, followed by tetracycline resulted in complete absence of inflammatory resorption and ankylosis.

Hypochloric acid was used by Nordenram et al. (1973) on extracted incisors of Java monkeys. Results revealed the inflammatory reaction, as well as the occurrence of active resorption processes were far more pronounced in the experimental teeth than in the control teeth. Superficial demineralization of the root surface with HCl prior to replantation did not improve the healing nor prolong the survival time.

Reeve et al. (1964) fixed canine incisors in 40% formalin for 15 minutes before replantation. The resorptive process was found to be minimal until 12 weeks following replantation. After 12 weeks, resorption was rapid with complete destruction of the root occurring within 6 months after replantation. No difference was noted in the resorptive pattern of the formalin and non-formalin fixed teeth.

A comparison study using 95% alcohol, 10% formalin, or 60 °C hot water (Butcher et al. 1955) on extracted incisors of rhesus monkeys, showed that root resorption was greatest in teeth treated with formalin and least with alcohol immersion. Ankylosis was more frequently encountered in teeth immersed in formalin and alcohol. However, areas of reattachment of the PDL to the tooth were found to occur in replanted teeth, which were immersed in 10% formalin, 95% alcohol, or hot water (60 °C).

Robinson et al. (1976) used the mandibular first molars of hamsters to compare the effects of immersion in either 0.1% disodium ethane-1-hydroxy-1,1 diphosphate; 2% sodium fluoride; 1% pyrophosphate; or physiological saline before replantation. No significant difference in the amount of root resorption was observed in teeth immersed in any of the solutions. Damage occurred from both mechanical stress and chemical change resulting from the inflammatory processes that are not experienced in the bone in *in vitro* experiments.

Indomethacin was administered systemically by Walsh et al. (1987) in dogs pre-extraction and throughout the course of the study in doses of either 1 mg/kg or 5 mg/kg. Root resorption (active resorption) was approximately the same between the low dose animals and the controls. Replacement resorption (resorption cavity filled in with osteoid bone) was greater in the low dose animals than the controls. Ankylosis (root surface and

surrounding bone were fused) was greater in the high dose animals than the controls, and this ankylosis was not associated with resorption. It was postulated that inhibition of the inflammatory response allowed osteoblastic activity to predominate.

Nevins et al. (1980) extracted maxillary and mandibular incisors of cynomolgous monkeys, removed the PDL, extirpated the pulps, and immersed the teeth in hyaluronidase for 30 minutes prior to replantation. The enzyme treated teeth showed alveolar bone in close adaptation to unresorbed cementum in five of eight teeth. It was hypothesized that when potentially antigenic components of cementum matrix (unsaturated disaccharides of hyaluronic acid and chondroitin sulfate) are enzymatically removed subsequent to root surface decalcification, replantation would be more successful. Any remaining antigenic sites would be further inactivated by cross-linking agents (glutaraldehyde). However, calcium phosphate (hydroxyapatite) must first be removed from cementum for enzymatic hydrolysis of ground substance to be effective.

Sae-Lim et al. (1998) compared systemic versus topical application of dexamethasone on the periodontal healing of replanted dogs' teeth. Incisors and premolars were endodontically treated, extracted and stored in ViaSpan for 48 hours, rinsed and replanted. Systemic dexamethasone was administered to three beagle dogs for a period of 5 days and the effects were allowed to clear for 4 weeks. Additional teeth were then treated as previously described with or without local administration of dexamethasone. Significant differences were found for complete healing and inflammatory root resorption, but not for replacement resorption. Topical use enhanced periodontal healing and reduced resorptive complications.

## MATERIALS AND METHODS

This study was conducted on 36 roots of teeth of three two-year-old beagle dogs. The teeth treated were the mandibular 2nd, 3rd and 4th premolars. The animals were anesthetized with an intravenous injection of Thiopental sodium (Ohmeda Pharmaceutical Products Division, Liberty Corner, NJ) at a dose of 10 mg/kg body weight followed by inhalation anesthesia using 1% Halothane or 3% Isoflurane and 1-2 liters/minute of oxygen. Lidocaine HCl 2% with 1:100,000 epinephrine was used for local infiltration anesthesia.

Using aseptic techniques, the mandibular premolars were opened and pulp tissue removed with nickel-titanium, .04-taper, rotary files (Tulsa Dental). All root canals (thirty-six) were cleaned and shaped with K-type files, and irrigated with 5.25% sodium hypochlorite following which they were irrigated with physiologic saline, dried with paper points, obturated with gutta percha and Roth's sealer, using a warm vertical condensation technique, sectioned through the furcation, and extracted. Roots were randomly divided into: Group 1) 3 roots - no treatment (positive control), Group 2) 11 roots - 1% stannous fluoride, Group 3) 11 roots - Toradol® (ketorolac tromethamine) 10 µg/ml, and Group 4) 11 roots - Decadron® (dexamethasone sodium phosphate), 16 µg/ml (Table 1).

Group	n	Treatment
I	3	None (positive control)
II	11	Stannous fluoride 1%
III	11	Ketorolac tromethamine 10 µg/ml (Toradol ®)
IV	11	Dexamethasone sodium phosphate 16 µg/ml (Decadron ®)

Table 1. Treatment groups

After air-drying for 1 hour, soft tissues were mechanically removed with curettes from the root surfaces, and the roots were immersed for 5 minutes in the test solutions, followed by a rinse with sterile saline and then replanted. The root canal accesses were sealed with a composite restorative material and the teeth were rigidly splinted for eight weeks. Meperidine hydrochloride injection, USP (10 mg/kg body weight) was used every six hours, for one day, to control post-operative pain. The animals received a soft diet for 3 days and water ad lib. Oral hygiene was inspected daily to prevent gingival inflammation by food debris.

Animals from both the experimental and control groups were sacrificed after 8 weeks from the time of replantation with an overdose of sodium pentobarbital (Nembutal™, Abbott Laboratories, North Chicago, IL) (500 mg) and perfused with a saline solution followed by 10% neutral buffered formalin. The jaws containing the teeth were harvested, radiographed, and fixed in 10% neutral buffered formalin. The mandibles were dissected from their soft tissue and sectioned so that only the experimental area remained. These specimens were decalcified, embedded in paraffin and butylmethacrylate, and serially sectioned, from marked blocks, from cemento-enamel junction to the root apex in 5 µm thickness at 500 µm intervals, perpendicular to the long axes of the teeth. Specimens were mounted on glass slides coated with poly-L-lysine, fixed with celloidin adhesive, air dried, and stained with hematoxylin, eosin, and Orange G (stains collagen) for light microscopic observation.

For histometric evaluation, each section was evaluated independently by two examiners. Every section was examined from the level where the root was completely surrounded by bone cervically, to the apex of the root. Sections coronal to the alveolar

bone were excluded because of possible extraction trauma. The root surfaces were evaluated according to Andreasen (1975, 1980), using 8 points of registration in each section. The registration points were created by projecting the cross-section of the root on a screen supplied with a star-shaped grid with 8 radii (Figures 3-7). At the intersections of the radii and the root surface, the appearance of the root surface was classified and recorded according to the following defined criteria: 1) *Artifact*. Normal structures, resorptive defects or bone are not distinguishable on the root surface due to processing artifacts. 2) *Unchanged*. Normal structured periodontal ligaments and an intact cementum layer. 3) *Resorbed*. Resorption cavities are present on the root surface adjacent to bone deposition upon the root surface. 4) *Ankylosed*. Alveolar bone is in close approximation to the root surface. The root surface may or may not have been resorbed before bone deposition.

### Statistical analysis

Data collection was on an ordinal measurement scale and categorically recorded as 0 = artifact, 1 = unchanged, 2 = resorbed, and 3 = ankylosed. Responses obtained were not continuous and did not follow a normal distribution. Therefore, a Kruskal-Wallis Contingency Table Analysis (Conover, 1980) was used to compare the periodontal condition based on the three morphologic classifications for the four treatment groups.

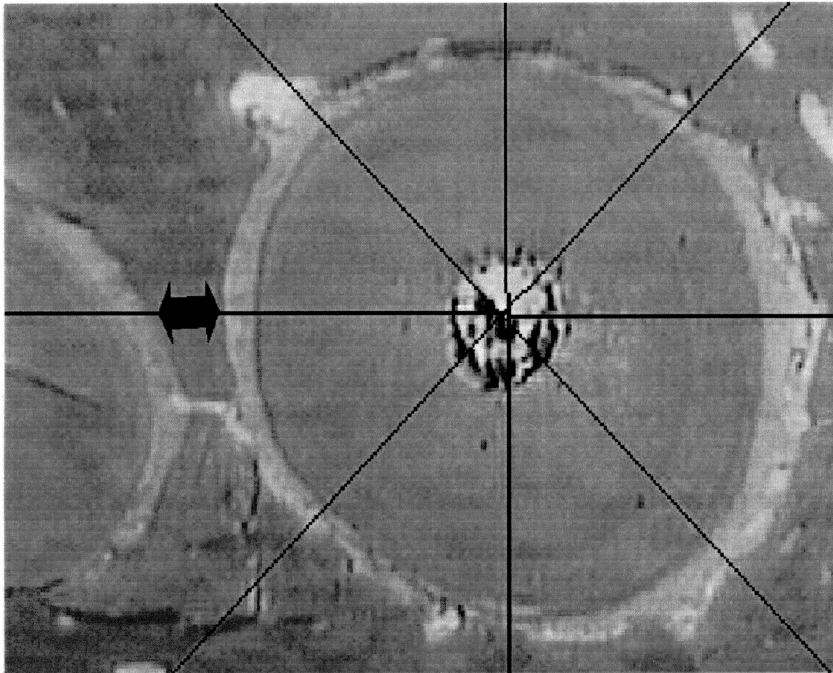


Figure 3. Normal Periodontal Ligament  
(Black arrow = Unchanged)



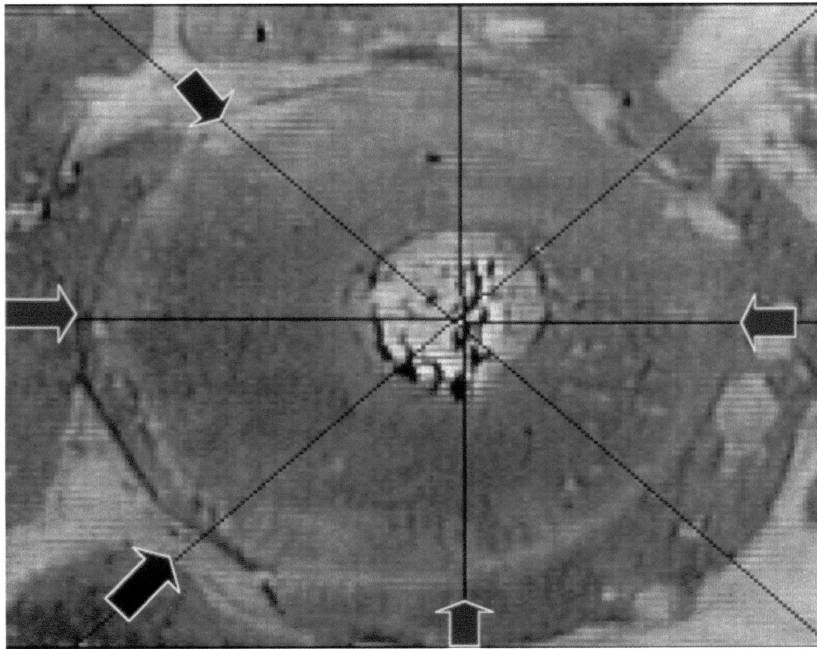


Figure 4. Control  
(Black arrow = Unchanged; Green arrow = Ankylosis; Red arrow = Resorbed)

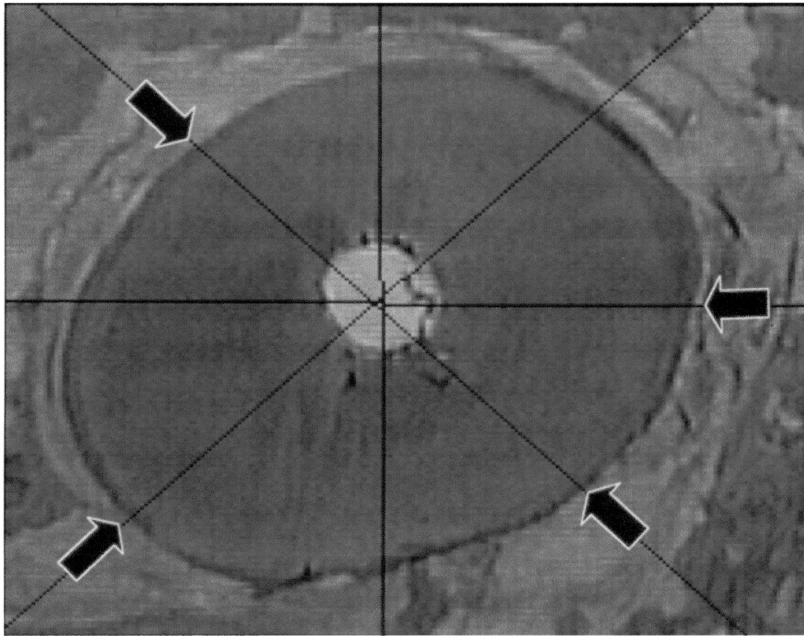


Figure 5. Fluoride  
(Black arrow = Unchanged)

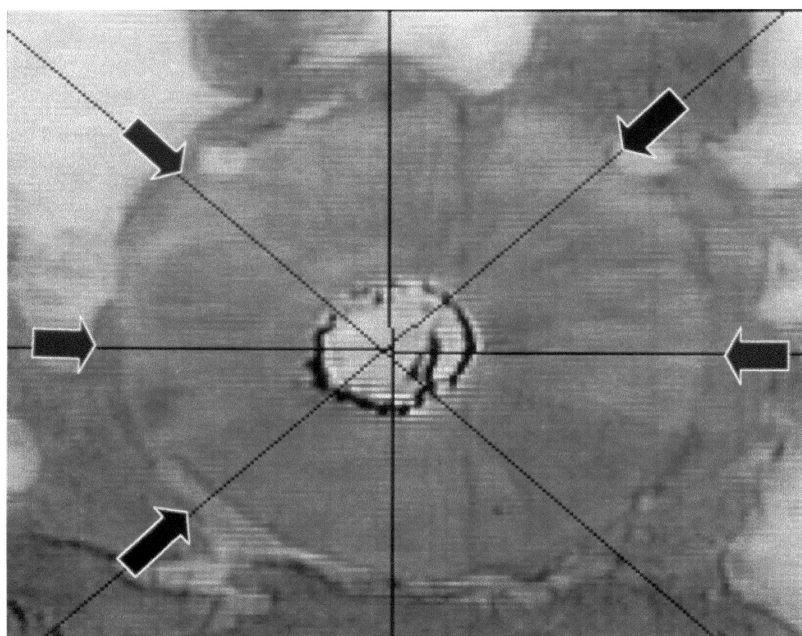


Figure 6. Ketorolac tromethamine  
(Black arrow = Unchanged; Green arrow = Ankylosed; Red arrow = Resorbed)

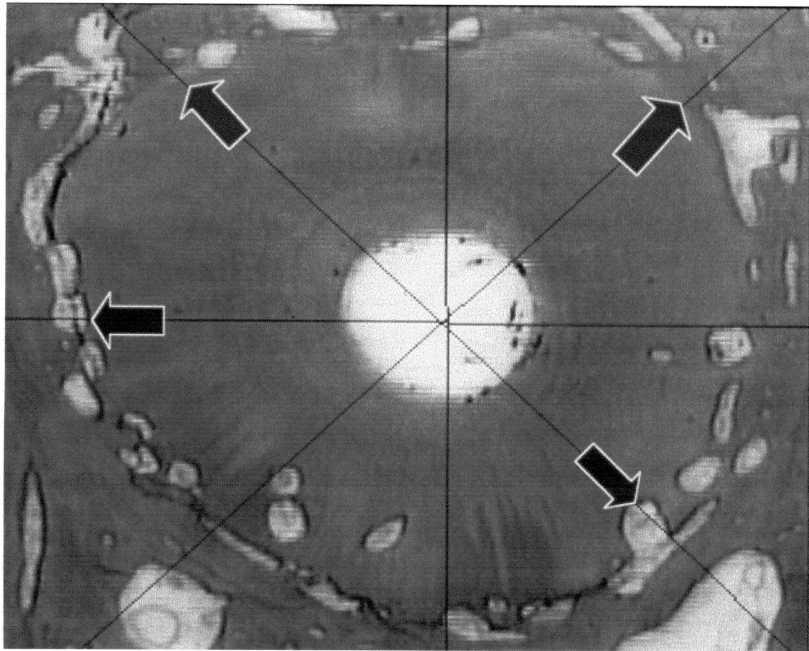


Figure 7. Dexamethasone sodium phosphate  
(Green arrow = Ankylosed; Red arrow = Resorbed)

## RESULTS

Two roots were lost at the time of extraction but none were lost after the replantation. Crown fracture to the osseous crest on the two samples occurred with placement of extraction forces. Therefore, these roots were unsuitable for atraumatic extraction and were left in their sockets. Forces exerted on the teeth during extraction are different than those in clinical replantation in both quantity and duration. It can then be extrapolated that forces from traumatic injury are also very much different (Barbakow et al., 1981).

The exposed radicular openings were filled with self-curing composite and left for the duration of the experiment. These roots were histologically processed to demonstrate a periodontal membrane not subjected to experimental conditions and served as negative controls (Figure 3).

Significant differences among the treatment groups were detected with the p-value  $< 0.0001$ . A non-parametric multiple comparison process based on ranks showed that differences in periodontal healing were also detected between each treatment group with results of: 1) fluoride, dexamethasone, or ketorolac significantly greater than controls ( $p < 0.0001$ ), 2) ketorolac or dexamethasone significantly greater than fluoride ( $p < 0.0001$ ), and 3) dexamethasone significantly greater than ketorolac ( $p < 0.003$ ). Pairwise comparison of treatment outcomes was also significant with p values less than 0.015 (Figures 4-7).

Second examiner readings showed similar differences with 1) fluoride significantly greater than controls ( $p < 0.0001$ ), and 2) ketorolac or dexamethasone significantly greater than fluoride ( $p < 0.0001$ ).

A normal approximation to binomial distribution was used to determine the differences between individual treatment groups for each morphologic classification. The test was performed at a significance level at  $\alpha = 0.05$ .

Significant sample differences were obtained with: 1) The artifact group, ketorolac was significantly less than controls ( $p < 0.0001$ ) (Table 2); 2) For the unchanged group, fluoride was significantly greater than ketorolac, dexamethasone, or controls ( $p < 0.0001$ ); and ketorolac was significantly greater than dexamethasone ( $p = 0.0150$ ) (Table 3). 3) In the resorbed group, fluoride was significantly less than ketorolac, dexamethasone, or controls ( $p < 0.0001$ ); and ketorolac was significantly greater than controls ( $p = 0.0376$ ) (Table 4). 4) In the ankylosed group, fluoride was significantly less than ketorolac, dexamethasone, or controls ( $p < 0.0001$ ); ketorolac was significantly less than dexamethasone ( $p = 0.0062$ ) or control ( $p = 0.0020$ ) (Table 5).

The reproducibility of readings (Table 6) between the two examiners was measured using a  $\kappa$ -statistic analysis. The kappa statistic in dental measurement, as a means to evaluate reliability, adjusts for the degree of agreement expected purely by chance (Fleiss and Chilton, 1983). A weighted  $\kappa$ -statistic value was used where  $0 \leq \kappa < 0.40$  = poor reproducibility;  $0.40 \leq \kappa < 0.75$  = good reproducibility;  $0.75 \leq \kappa$  = excellent reproducibility. The results show good reproducibility of results between examiners in all treatment groups (Table 7).

ARTIFACT SAMPLES

	Fluoride	Ketorolac	Dexamethasone	Control (+)
Fluoride	*	p = 0.2240 nsd	p = 0.0768 nsd	p = 0.1260 nsd
Ketorolac	*	*	p = 0.1458 nsd	p < 0.0001 K < C
Dexamethasone	*	*	*	p = 0.4502 nsd
Control (+)	*	*	*	*

Table 2. Analysis between treatment groups for artifact samples using normal approximation to binomial distribution.  
(nsd = no significant difference)

UNCHANGED SAMPLES

	Fluoride	Ketorolac	Dexamethasone	Control (+)
Fluoride	*	$p < 0.0001$ F > K	$p < 0.0001$ F > D	$p < 0.0001$ F > C
Ketorolac	*	*	$p = 0.0150$ K > D	$p = 0.0836$ nsd
Dexamethasone	*	*	*	$p = 0.9878$ nsd
Control (+)	*	*	*	*

Table 3. Analysis using normal approximation to binomial distribution between treatment groups for unchanged samples.  
(nsd = no significant difference)



RESORBED SAMPLES

	Fluoride	Ketorolac	Dexamethasone	Control (+)
Fluoride	*	p < 0.0001 F < K	p < 0.0001 F < D	p < 0.0001 F < C
Ketorolac	*	*	p = 0.7045 nsd	p = 0.0376 K > C
Dexamethasone	*	*	*	p = 0.0548 nsd
Control (+)	*	*	*	*

Table 4. Analysis using normal approximation to binomial distribution between treatment groups for resorbed samples.  
(nsd = no significant difference)

ANKYLOSED SAMPLES

	Fluoride	Ketorolac	Dexamethasone	Control (+)
Fluoride	*	p < 0.0001	p < 0.0001	p < 0.0001
Ketorolac	*	*	p = 0.0062	p = 0.0020
Dexamethasone	*	*	*	p = 0.1528 nsd
Control (+)	*	*	*	*

Table 5. Analysis using normal approximation to binomial distribution between treatment groups for ankylosed samples.  
nsd = no significant difference)

	Unchanged		Resorbed		Ankylosed	
	Examiner 1	Examiner 2	Examiner 1	Examiner 2	Examiner 1	Examiner 2
Control (-)	98/104 (94%)	82/104 (79%)	1/104 (0.9%)	1/104 (0.9%)	0/104 (0%)	21/104 (20%)
Control (+)	76/288 (26%)	124/288 (43%)	55/288 (19%)	27/288 (9%)	148/288 (51%)	130/288 (45%)
Stannous fluoride	534/696 (77%)	547/696 (78%)	54/696 (8%)	24/696 (3%)	97/696 (14%)	117/696 (17%)
Ketorolac tromethamine	298/752 (40%)	312/752 (41%)	193/752 (26%)	105/752 (14%)	241/752 (32%)	327/752 (43%)
Dexamethasone sodium phosphate	253/832 (30%)	324/832 (39%)	241/832 (29%)	80/832 (10%)	308/832 (37%)	414/832 (50%)

Table 6. Number of recording sites / Number of sites in treatment group for experimental groups and individual examiners.

Treatment Group	$\kappa$ -value	Reproducibility
Control (+) - no treatment	0.524	good
Stannous fluoride 1%	0.640	good
Dexamethasone sodium 16 $\mu\text{g/ml}$	0.478	good
Ketorolac tromethamine 10 $\mu\text{g/ml}$	0.591	good
All treatments combined	0.591	good

Table 7.  $\kappa$ -statistics of reproducibility between two examiners.

In summary, the results indicate that resorption increases according to treatment groups in the following order: control (-) < fluoride < ketorolac < dexamethasone < control (+).

## DISCUSSION

The history of replacement root resorption has focused on limiting the extra-oral time of an avulsed tooth. More recent studies (Hiltz et al., 1991; Trope et al., 1992; Harkacz et al., 1997; Olson et al., 1997; Rozenfarb et al., 1997) are concerned with finding a suitable storage/transport media to maintain PDL cell viability. However, cost of and accessibility to, these products have been major obstacles. To be useful, these media would have to be readily available to the general public. Patients may not realize the importance of extra-oral time or an appropriate storage media. Therefore, a non-vital PDL may be the more common occurrence rather than a tooth transported in a suitable media. Efforts may then have to be focused on inhibiting replacement resorption and ankylosis.

The methods used in this study, favored induction of replacement root resorption. Extended extra-oral time (Løe & Waerhaug 1961; Anderson et al., 1968; Kaqueler & Massler 1969; Groper & Bernick 1970; Hamner et al., 1970; Andreasen 1981b), PDL removal prior to replantation (Løe & Waerhaug 1961, Hamner et al., 1970; Andreasen 1981c, Andreasen & Kristerson 1980), and rigid splinting (Andreasen 1975) have all been shown to potentiate ankylosis.

Non-steroidal anti-inflammatory medicaments are known to inhibit PGE production and further exert immunomodulatory effects by stimulating the production of leukotrienes. NSAIDs in vitro have been found to inhibit cyclooxygenase, shunt the arachidonic acid precursors into the 5-lipoxygenase pathway, and result in an increased production of LTs. It has recently been shown that some lipoxygenase products, especially, LTB<sub>4</sub>, are potent stimuli of suppressor cell generation (Goodwin 1985).

Glucocorticoids have been widely accepted in reducing inflammation by the reduction and inhibition of macrophage activation. In turn, IL-1, TNF-β, IL-6 and production of prostaglandins are affected. The mechanism of action has been hypothesized to be the inhibition of transcription processes leading to macrophage activation. Local administration of dexamethasone has been shown to reduce osteoclastic bone resorption. Reduction of the number of osteoclasts by direct receptor mediated and specific cytotoxicity has been postulated, as well as the enhancement of calcitonin receptors on these cells, which make them more responsive to the existing systemic concentration of the hormone whose main function is to reduce bone resorptive activity.

Stannous fluoride has a different and complex reaction pattern when exposed to dental tissues. Aqueous solutions of SnF<sub>2</sub> are acidic and cause demineralization of

cementum and dentin, which enhances the uptake of fluoride in the hard tissues.

Stannous fluoride inhibits bacterial plaque formation on enamel caused by an interference with adhesion through the combined effect of tin and fluoride ions. The combined effect of these ions appears to be responsible for the lack of root resorption. Although treatment with SnF<sub>2</sub> prevents root resorption, it delays resolution of inflammatory reactions (Bjorvatn et al., 1989). Topical application of either acidulated sodium fluoride or neutral sodium fluoride solution for two minutes before replantation, did not significantly reduce the amounts of surface and replacement resorption (Barbakow et al., 1981).

Other possible mechanisms for inhibition of replant root resorption are: 1) Fluoride is incorporated directly into the mineral lattice work of cementum, which is generally accepted as the most significant effect of topical fluorides (the conversion of hydroxyapatite to fluorapatite results in an increase in crystallite size, which renders the cementum more able to resist dissolution). 2) Fluoride loosely bound to the organic constituents of cementum is readily released and may inhibit odontoclastic cell activity, probably by interfering with 'clast' cell enzymes. 3) Fluoride may enhance the remineralization of apatite. 4) Acid phosphate fluoride by way of an impurity in the orthophosphate, probably polyphosphate, modifies the crystal growth of surface calcium fluoride, and more closely packed calcium fluoride crystals thereby inhibit the decalcification process. 5) Fluoride treatment appears to enhance post-replant and post-transplant ankylosis. Because of root resorption at sites not ankylosed ('inflammatory' resorption), enhanced ankylosis may play a role in prolonging tooth replant and allograft survival (Shulman et al., 1973). This enhanced ankylosis can be thought of as enhanced osseointegration of the tooth, analogous to an implant. However, an implant is not

ankylosed because there is no resorption of the implant. It has been suggested that the enhanced ankylosis resulting from fluoride treatment of replanted teeth is due to an inhibition of bone resorption that results in a net increase in bone formation (Mellberg et al., 1974).

A recent *in vivo* study (Trope et al., 1997) maintains that periodontal healing after tooth extraction affects the amount of replacement resorption. And despite root canal treatment after replantation, inflammatory resorption still persists. Apparently as socket age increases, the incidence of complete healing decreases significantly and there is a significant increase in the incidence of replacement resorption. Therefore, an inflammatory component may be contributory to the replacement root resorption process.

It is widely accepted that clastic cells participate in the resorptive process. It has been postulated that the number of clastic cells are responsible for the amount of resorption. Whereas, another theory is that the state of activity of the clastic cell, not the number of cells, is responsible for the resorption. An attempt to detect and quantify the presence of clastic cells was made using a TRAP stain specific for clastic cells. Unfortunately, the stain was not detected, by light microscopy, in any of the preliminary sections. Lack of staining was most probably due to the long fixation period. However, during histologic preparation, the specimens became separated from the slide. Further processing used glass slides coated with poly-L-lysine, and sections were coated with celloidin adhesive, and additionally air-dried before staining. These additional steps may have prevented the uptake of stain into the cell.

An additional reason for the lack of clastic cells is that resorption takes place in the acute inflammatory phase and 8 weeks may be too long a period for active resorption

to continue. The fact that large resorptive defects and replacement resorption has occurred is an indication that healing (bone deposition) may occur at an earlier time.



## CONCLUSION

The results of this study prove the hypothesis that topical application of anti-inflammatory agents, such as ketorolac or dexamethasone, show an inhibitory effect on replacement root resorption compared to controls. In addition, ketorolac is more effective than dexamethasone in delaying replacement root resorption. However, stannous fluoride appears to be the more effective medicament than ketorolac or dexamethasone. Consequently, ketorolac or dexamethasone may be useful in combination with fluoride in the treatment of replacement root resorption. Further studies are needed to determine the effectiveness of combined chemotherapy. Moreover, topical versus systemic application of various NSAIDs should also be investigated.

## REFERENCES

1. Anderson AW, Sharav Y, and Massler M. Periodontal reattachment after tooth replantation. *Periodontics* 1968;6(4):161-167.
2. Andersson L, Bodin L, and Sorensen S. Progression of root resorption following replantation of human teeth after extended extra-oral storage. *Endod Dent Traumatol* 1989;5:38-47.
3. Andreasen JO and Hjorting-Hansen E. Replantation of teeth. Radiographic and clinical study of 110 human teeth replanted after accidental loss. *Acta Odontol Scand* 1966;24:263-286.
4. Andreasen JO and Kristerson L. The effect of limited drying or removal of the periodontal ligament on periodontal healing after replantation of mature permanent incisors in monkeys. *Acta Odontol Scand* 1980;38:385-397.
5. Andreasen JO and Andreasen FM. *Textbook and Color Atlas of Traumatic Injuries to the Teeth*. Third Edition. Mosby Year-Book, Inc., St. Louis 1994. pp.127-130.
6. Andreasen JO, Borum MK, Jakobsen HL, Andreasen FM. Replantation of 400 avulsed permanent incisors. 4. Factors related to periodontal ligament healing. *Endod Dent Traumatol* 1995;11:76-89
7. Andreasen JO. The effect of splinting upon periodontal healing after replantation of permanent incisors in monkeys. *Acta Odontol Scand* 1975;33:313-323.
8. Andreasen JO. A time-related study of periodontal healing and root resorption activity after replantation of mature permanent incisors in monkeys. *Swed Dent J* 1980a;4:101-110.
9. Andreasen JO. Analysis of pathogenesis and topography of replacement root resorption (ankylosis) after replantation of mature permanent incisors in monkeys. *Swed Dent J* 1980b;4:231-240.
10. Andreasen JO. Relationship between surface and inflammatory resorption and changes in the pulp after replantation of permanent incisors in monkeys. *J Endod* 1981a;7(7):294-301.
11. Andreasen JO. Effect of extra-alveolar period and storage media upon periodontal and pulpal healing after replantation of mature permanent incisors in monkeys. *Int J Oral Surg* 1981b;10(1):43-53.
12. Andreasen JO. Periodontal healing after replantation and autotransplantation of incisors in monkeys. *Int J Oral Surg* 1981c;10(1):54-61.

13. Andreasen JO. External root resorption: its implication in dental traumatology, paedodontics, periodontics, orthodontics and endodontics. *Int Endod J* 1985;18:109-118.
14. Andreasen JO and Andreasen FM. Root resorption following traumatic dental injuries. *Proc Finn Dent Soc* 1992;88(1-2):95-114.
15. Bakland LK. Root Resorption. *Dent Clin N Am* 1992;36:491-507.
16. Barbakow FH, Cleaton-Jones PE, Austin JC, Vieira E. Healing of replanted teeth following topical treatment with fluoride solutions and systemic admission of thyrocalcitonin: a histometric analysis. *J Endod* 1981;7(7):302-308.
17. Bjorvatn K, Selvig KA, and Klinge B. Effect of tetracycline and SnF on root resorption in replanted incisors in dogs. *Scand J Dent Res* 1989;97:477-482.
18. Butcher EO and Vidair RV. Periodontal fiber reattachment in replanted incisors of the monkey. *J Dent Res* 1955;34:569-76.
19. Conover WJ. *Practical Non-Parametric Statistics*. Second Edition. Wiley & Sons. 1980.
20. Fleiss JL and Chilton NW. The measurement of interexaminer agreement and periodontal disease. *J Periodont Res* 1983;18:601.
21. Gilles JA, Carnes DL, and Windeler AS. Development of an in vitro culture system for the study of osteoclast activity and function. *J Endod* 1994;20(7):327-331.
22. Goodwin JS. Immunologic effects of nonsteroidal anti-inflammatory agents. *Med Clin North Am* 1985;69(4):793-804.
23. Groper JN and Bernick S. Histological study of the periodontium following replantation of teeth in the dog. *J Dent Child* 1970;37(1):25-35.
24. Gunday M, Sazak H, and Turkmen C. A scanning electron microscopic study of external root resorption in replanted dog teeth. *J Endod* 1995;21(5):269-271.
25. Hammarstrom L and Lindskog S. General morphological aspects of resorption of teeth and alveolar bone. *Int Endod J* 1985;18:93-108.
26. Hammarstrom L, Pierce A, Blomlof L, Feiglin B and Lindskog S. Tooth avulsion and replantation - A review. *Endod Dent Traumatol* 1986;2:1-8.
27. Hammarstrom L, Blomlof L, and Lindskog S. Dynamics of dentoalveolar ankylosis and associated root resorption. *Endod Dent Traumatol* 1989;5:163-175.

28. Hammarstrom L and Lindskog S. Factors regulating and modifying dental root resorption. *Proc Finn Dent Soc* 1992;88 Suppl 1:115-123.
29. Hamner JE, Reed OM, and Stanley HR. Reimplantation of teeth in the baboon. *J Am Dent Assoc* 1970;81(3):662-670.
30. Harkacz OM, Carnes DL, and Walker WA. Determination of periodontal ligament cell viability in the oral rehydration fluid Gatorade and milks of varying fat content. *J Endod* 1997;23(11):687-690.
31. Hiltz J and Trope M. Vitality of human lip fibroblasts in milk, Hank's balanced salt solution and ViaSpan storage media. *Endod Dent Traumatol* 1991;7:69-72.
32. Kaqueler JC and Massler M. Healing following tooth replantation. *J Dent Child* 1969;36(5):303-314.
33. Klinge B, Nilveus R, and Selvig KA. The effect of citric acid on repair after delayed tooth replantation in dogs. *Acta Odontol Scand* 1984;42:351-359.
34. Krasner P and Rankow HJ. New philosophy for the treatment of avulsed teeth. *Oral Surg Oral Med Oral Pathol Oral Radiol Endod* 1995;79(5):616-623.
35. Kurumbail RG, Stevens AM, Gierse JK, McDonald JJ, Stegeman RA, Pak JY, Gildehaus D, Miyahiro JM, Penning TD, Seibert K, Isakson PC, and Stallings WC. Structural basis for selective inhibition of cyclooxygenase-2 by anti-inflammatory agents. *Nature* 1996 Dec 19-26;384(6610):644-648.
36. Lindskog S, Blomlof L, and Hammarstrom L. Dentin resorption in replanted monkey incisors. Morphology of dentinoclast spreading in vivo. *J Clin Periodontol* 1988;15:365-370.
37. Loe H and Waerhaug J. Experimental replantation of teeth in dogs and monkeys. *Arch Oral Biol* 1961;3:176-184.
38. Mellberg JR, Shulman L. Treatment of human teeth with fluoride for replantation and allotransplantation. *J Dent Res* 1974;53(4):844-846.
39. Mirzabagi MH. Histologic study of tooth transplantation in the rabbit. *Oral Surg* 1978;46(5):618-627.
40. Nevins AJ, LaPorta RF, Borden BG, and Lorenzo P. Replantation of enzymatically treated teeth in monkeys. Part I. *Oral Surg* 1980;50(3):277-281.
41. Nordenram A, Bang G, and Anneroth G. A histologic study of replanted teeth with superficially demineralised root surfaces in Java monkeys. *Scand J Dent Res* 1973;81:294-302.

42. Olson BD, Mailhot JM, Anderson RW, Schuster GS, and Weller RN. Comparison of various transport media on human periodontal ligament cell viability. *J Endod* 1997;23(11):676-679.
43. Reeve CM, Sather AH, and Parker JA. Resorption pattern of formalin-fixed teeth in dogs. *J Dent Res* 1964;43:825.
44. Robinson PJ and Shapiro IM. Effect of diphosphates on root resorption. *J Dent Res* 1976;55:166.
45. Rozenfarb N, Kupietzky A, and Shey Z. Milk and egg albumen are superior to human saliva in preserving human skin fibroblasts. *Pediatr Dent* 1997; 19(5):347-348.
46. Sae-Lim V, Metzger Z, and Trope M. Local dexamethasone improves periodontal healing of replanted dogs' teeth. *Endod Dent Traumatol* 1998;14:232-236.
47. Sahara N, Toyoki A, Ashizawa Y, Deguchi T and Suzuki K. Cytodifferentiation of the odontoclast prior to the shedding of human deciduous teeth: an unstructural and cytochemical study. *Anat Rec* 1996;244:33-49.
48. Seibert K, Zhang Y, Leahy K, Hauser S, Masferrer J, and Isakson P. Distribution of COX-1 and COX-2 in normal and inflamed tissues. *Adv Exp Med Biol* 1997;400A:167-170.
49. Selvig KA, Bjorvatn K, and Claffey N. Effect of stannous fluoride and tetracycline on repair after delayed replantation of root-planed teeth in dogs. *Acta Odontol Scand* 1990;48:107-112.
50. Shulman LB, Gedalia I, and Feingold RM. Fluoride concentration in the root surfaces and alveolar bone of fluoride-immersed monkey incisors three weeks after replantation. *J Dent Res* 1973;52:1314-1316.
51. Ten Cate AR and Anderson RD. An ultrastructural study of tooth resorption in the kitten. *J Dent Res* 1986;65(8):1087-1093.
52. Torabinejad M and Kettering JD. Identification and relative concentrations of B and T lymphocytes in human chronic periapical lesions. *J Endod* 1985a;11(3):122-125.
53. Torabinejad M, Eby WC and Naidorf IJ. Inflammatory and immunological aspects of the pathogenesis of human periapical lesions. *J Endod* 1985b;11(11):479-488.
54. Tronstad L. Root resorption - etiology, terminology and clinical manifestations. *Endod Dent Traumatol* 1988;4:241-252.
55. Trope M. Clinical management of the avulsed tooth. *Dent Clin North Am* 1995;39(1):93-112.

UNIVERSITY LIBRARY  
LOMA LINDA, CALIFORNIA

56. Trope M and Friedman S. Periodontal healing of replanted dog teeth stored in ViaSpan, milk, and Hank's balanced salt solution. *Endod Dent Traumatol* 1992;8:183-188.
57. Trope M, Hupp JG, and Mesaros SV. The role of the socket in the periodontal healing of replanted dog's teeth stored in ViaSpan for extended periods. *Endod Dent Traumatol* 1997;13:171-175.
58. Trowbridge HO and Emling RC. *Inflammation: A Review of the Process*. Fifth Edition. Quintessence Publishing Co, Inc. Chicago. 1997.
59. Walsh JS, Fey MR, and Omnell LM. The effects of indomethacin on resorption and ankylosis in replanted teeth. *ASDC J Dent Child* 1987;54(4):261-266.
60. Wesselink PR, Beertsen W, and Everts V. Resorption of the mouse incisor after the application of cold to the periodontal attachment apparatus. *Calcif Tissue Int* 1986;39:11-21.
61. Zervas P, Lambrianidis T, and Karabouta-Vulgaropoulou I. The effect of citric acid treatment on periodontal healing after replantation of permanent teeth. *Int Endod J* 1991;24:317-325.