

## *Psychiatric Disorders Induced by Twiddler's Syndrome May Pose Treatment Challenges in Clinical Practice*

Mohamed Tashani, MD<sup>1</sup>, Laura Given, MD<sup>2</sup>, Jason Mader, DO<sup>1</sup>

### ABSTRACT

Twiddler's syndrome is a rare condition caused by the coiling of the leads, leading to a malfunction in the pacemaker or automated implantable cardioverter-defibrillator (AICD). Bayliss first described it in 1968 as a rare but potentially fatal complication of pacemaker treatment.<sup>1</sup> Inappropriate shocks due to malfunctioning of the AICD can be devastating, traumatic, or fatal to the patient.

Traumatic and inappropriate shocks can cause patients to develop stress or anxiety disorders associated with their AICD. Treatment for anxiety or acute stress disorder with medications can be difficult due to a patient's underlying proarrhythmic conditions.

We are presenting a case report regarding a malfunctioning AICD that caused the patient to develop an acute stress disorder with worsening of her underlying anxiety disorder and the challenges posed by treating her.

*Author affiliations are listed at the end of this article.*

*Correspondence to:*  
Mohamed Tashani, MD  
Marshall University  
Joan C. Edwards  
School of Medicine  
[dr.tashani.mohamed@gmail.com](mailto:dr.tashani.mohamed@gmail.com)

### KEYWORDS

Twiddler's Syndrome, SSRIs, Psychiatric Disorder, AICD Malfunctioning

### INTRODUCTION

Twiddler's syndrome has an estimated frequency of 0.07%.<sup>2</sup> It usually occurs in the first year of implantation but can occur later.<sup>3</sup> Unintentional or deliberate manipulation of the generator within the skin pocket of the patient will result in the coiling of generator leads.<sup>3</sup> It is dangerous in patients with a defibrillator because of the loss of adequate sensing of the lead and capturing of the rhythm and possible false treatment of malignant ventricular arrhythmias.<sup>3</sup>

Risk factors include obesity or elderly patients because of the loose subcutaneous tissue allowing the pulse generator to rotate in its pocket. Other risk factors include female gender, weight loss, exaggerated upper limb movements, device manipulation, or a large pocket size relative to the defibrillator.<sup>4</sup>

Patients with Twiddler's syndrome should be

admitted to a telemetry bed for monitoring prior to surgical intervention.<sup>5</sup> Creating a small surgical pocket and suturing the device to the fascia can help prevent manipulation of the pulse generator and lead displacement.<sup>6</sup> Patient education and counseling against further manipulation are important for long-term management.<sup>3</sup>

We present a case report regarding a malfunctioning AICD that caused the patient to develop an acute stress disorder with worsening of her underlying anxiety disorder and the challenges posed by treating her.

### CASE REPORT

A 68-year-old female with a newly diagnosed, rate-controlled atrial fibrillation (AF) and non-ischemic cardiomyopathy with an ejection fraction of 25-30% had an AICD and dual chamber pacemaker



placed one month prior to presentation due to ventricular tachycardia. Apixaban had been held due to a hematoma at the pacemaker/defibrillator implantation site.

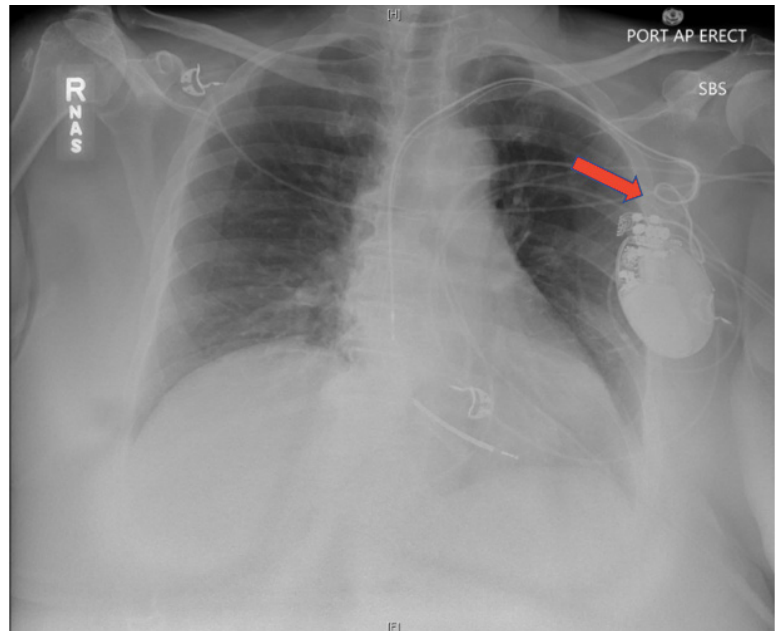
She presented to the emergency room with stroke-like symptoms. The computed tomography angiography (CTA) revealed a left frontal ischemic stroke from a middle cerebral artery (MCA) branch occlusion. Neurology decided to administer a systemic tissue plasminogen activator (tPA) that improved her neurological status. The patient denied any symptoms related to her AF at that time. On admission, the electrocardiogram (EKG) showed rate-controlled AF. However, interrogation of the AICD revealed her to be in AF with a rapid ventricular rate (RVR), ranging from 100 to 160 beats per minute (bpm) around 50% of the time since the implantation of the device. Neurology cleared the patient to be restarted on apixaban.

During her hospital stay, she developed symptomatic AF with RVR. The electrophysiologist adjusted her rate-control medication. A cardioversion was scheduled but not performed because the patient received two inappropriate shocks for AF with RVR with a rate of 244 bpm and then converted to sinus rhythm. Her heart rate remained in normal sinus rhythm on metoprolol and amiodarone.

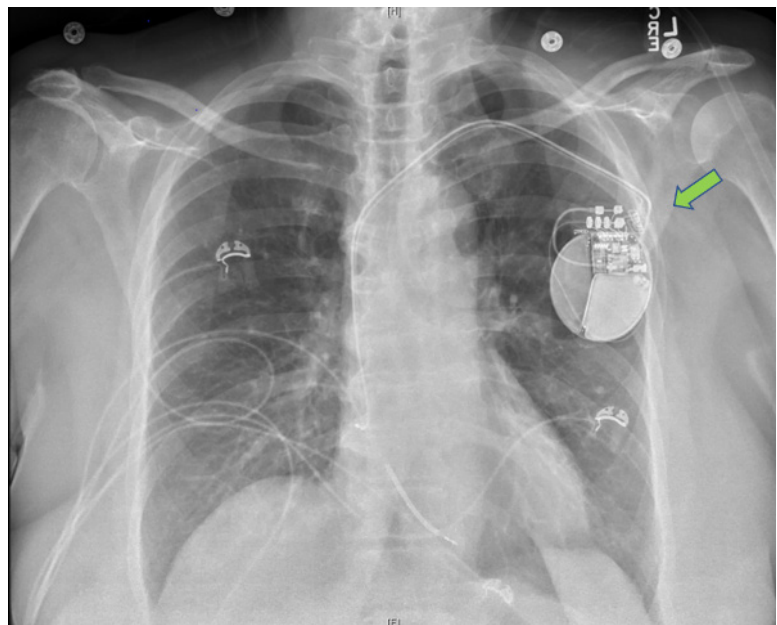
Previously, she had failed dofetilide due to polymorphic ventricular tachycardia and Torsade de Pointes (TdP) while taking a selective serotonin reuptake inhibitor (SSRI). Those medications were stopped at that time.

Repeat interrogation of the AICD showed right atrium (RA) lead malfunction, requiring revision. A chest X-ray showed the leads wrapped around the generator in the pocket multiple times (Figure 1). She was diagnosed with Twiddler's syndrome based on the clinical symptoms and imaging. She was then scheduled for lead revision and AICD reprogramming.

Apixaban was held while the RA and right ventricle (RV) leads were revised. A repeat chest x-ray showed successful revision of the leads (Figure 2). However, the patient reverted to AF with RVR, which was difficult to control. Amiodarone was discontinued due to adverse effects, and digoxin was initiated with plans for atrioventricular nodal (AVN) ablation.



**FIGURE 1:** AP Chest radiography indicating coiling leads around AICD/Pacer (red arrow)



**FIGURE 2:** AP Chest radiography indicating leads revision (green arrow)



After inappropriate AICD shocks followed by revision of the leads, she started to develop symptoms of emotional distress, tearfulness, and insomnia. The patient did report a history of anxiety. She was afraid to move out of the bed because she did not want to experience inappropriate shocks again. This fear worsened when she noticed her heart rate increase on the monitor with minimal exertion. Mental health was consulted to evaluate the patient. She was started on sertraline, which has a lesser risk for QT prolongation.

After failing the rate-control medications and considering her history of prolonged QT intervals from antiarrhythmic medications, she underwent AVN radiofrequency ablation instead of AF ablation since she had a recent pacemaker pocket revision. This led her to have rate-controlled AF with a ventricular-paced rhythm. Her QT interval remained stable on the sertraline. The patient was discharged to inpatient rehabilitation on metoprolol and digoxin for her rate-controlled AF and sertraline for her acute stress and anxiety disorder.

## DISCUSSION

Dofetilide is a class III antiarrhythmic agent approved to maintain and achieve sinus rhythm in patients with symptomatic AF and severe left ventricular dysfunction. Dofetilide should be initiated in the hospital under continuous telemetry with serial EKGs and regular serum electrolyte monitoring. In clinical trials, the risk of QT prolongation and ventricular tachycardia (VT) occurred in < 3% of patients.<sup>7</sup> However, concomitant QT prolongation medications are common in practice. In our case, the patient was started on dofetilide with pre-existing use of sertraline. The corrected QT interval (QTc) before initiation of dofetilide was 492 milliseconds (ms), and after initiation, the QTc was 539 ms when she developed VT and TdP. This led to the discontinuation of both medications. She later developed another episode of VT induced by a bradyarrhythmia; therefore, a decision was made for AICD implantation.

In a retrospective cohort study, 114 patients involved in studying dofetilide revealed that 28% of patients used concomitant QT-prolonging medications. The

most common medications included trazodone, venlafaxine, and paroxetine. Dofetilide was discontinued in 31% of those taking concomitant QT-prolonging drugs versus 15% of patients who were not taking concomitant QT-prolonging drugs ( $P = 0.04$ ). Reported discontinuation of dofetilide with sertraline was 8% of patients and 25% of patients with trazodone. Concomitant usage of other QT-prolonging drugs increased the risk of adverse events by almost two-fold.<sup>7</sup>

As a result of the inappropriate shock from the AICD secondary to Twiddler's syndrome, our patient developed acute stress disorder with some symptoms of depression. She was more prone to developing a new psychiatric disorder with her previous history of generalized anxiety disorder (GAD), a new diagnosis of stroke, and her recent discontinuation of sertraline. Due to her symptoms of anxiety and fear from receiving the inappropriate shocks, new-onset insomnia, and tearful episodes, sertraline was resumed. Dofetilide was considered the highest contributing factor to her prolonged QT previously. During her stay, her QTc interval remained stable.

The SADHART (Sertraline Antidepressant Heart-Attack Randomized Trial) studied the effect of sertraline on the QT interval of patients who had an acute MI or who were hospitalized with unstable angina within 30 days of enrollment. There was no statistically significant difference in QTc from baseline after 16 weeks of treatment. Studies show potentially clinically significant QT prolongation only when sertraline is taken concomitantly with other QT-prolonging medications. According to post-marketing data, the risk of sertraline on QT prolongation is rare.<sup>8</sup>

The patient did meet the Diagnostic and Statistical Manual of Mental Disorders (DSM-V) criteria for acute stress disorder. The abbreviated criteria of the DSM-V for acute stress disorder defines it as exposure to actual or threatened death with the presence of nine or more defined symptoms from five categories. The categories include intrusion, negative mood, dissociation, avoidance, or arousal that starts or worsens after the traumatic event. First-line treatment for acute stress disorder is trauma-focused cognitive behavioral therapy (CBT). However, with



her underlying co-morbid psychiatric disorders such as GAD and a new stroke diagnosis, resuming the SSRI was decided to be more beneficial. In the FOCUS (Effects Of Fluoxetine On Functional Outcomes After Acute Stroke) trial, patients treated with an SSRI after a stroke did not show a significant improvement in their stroke-related disability, but the rate of new-onset depression was less.<sup>9</sup>

## CONCLUSION

Twiddler's syndrome is treated surgically, but acute stress disorder from inappropriate shocks requires close attention to medical therapy, which can be challenging. The risk of QT interval prolongation is common with antiarrhythmic medication and increases with the concomitant use of SSRIs. A risk score by obtaining clinical risk factors to identify patients with the highest risk of QTc interval prolongation can be useful in guiding monitoring and treatment decisions.<sup>10</sup> The threshold should be low for close monitoring of the patient when placed on an SSRI in patients with proarrhythmic conditions. Treating psychiatric disorders is a key element in improving patient outcomes by reducing patient stress and increasing patient adherence to treatment.

## AUTHOR AFFILIATIONS

1. Marshall University Joan C. Edwards School of Medicine, Huntington, West Virginia
2. Cabell Huntington Hospital, Huntington, West Virginia

## REFERENCES

1. Bayliss CE, Beanlands DS, Baird RJ. The pacemaker-twiddler's syndrome: a new complication of implantable transvenous pacemakers. *Canadian Medical Association journal* 1968;99:371-3.
2. Fahraeus T. Early pacemaker twiddler syndrome. *Europace* 2003;5:279-81.
3. Gurkirat S, Hemant K, Zahidullah K, Narender Omprakash B. Pacemaker Twiddler Syndrome - A Rare but Serious Cause of Pacemaker Malfunction. *International Journal of Clinical Cardiology* 2018;5.
4. Jabri A, Laiq Z, Nabeel Y. Twiddler's Syndrome: An Unusual Cause of Repeated Shocks by Implantable Cardioverter-Defibrillator in an Asymptomatic Patient. *Heart Views* 2019;20:118-21.
5. Lesnick JA, Cooper BL, Doshi PB. Twiddler's Syndrome. *Clin Pract Cases Emerg Med* 2019;3:299-300.
6. Nicholson WJ, Tuohy KA, Tilkemeier P. Twiddler's Syndrome. *New England Journal of Medicine* 2003;348:1726-7.
7. Anand V, Vakil K, Tholakanahalli V, Li JM, McFalls E, Adabag S. Discontinuation of Dofetilide From QT Prolongation and Ventricular Tachycardia in the Real World. *JACC Clin Electrophysiol* 2016;2:777-81.
8. Funk KA, Bostwick JR. A comparison of the risk of QT prolongation among SSRIs. *The Annals of pharmacotherapy* 2013;47:1330-41.
9. Tisdale JE, Jaynes HA, Kingery JR, Mourad NA, Trujillo TN, Overholser BR, Kovacs RJ. Development and validation of a risk score to predict QT interval prolongation in hospitalized patients. *Circulation: Cardiovascular Quality and Outcomes*. 2013 Jul;6(4):479-87.

