

UNIVERSIDADE DE SÃO PAULO
HOSPITAL DE REABILITAÇÃO DE ANOMALIAS CRANIOFACIAIS

ISABELA DE CASTRO SARTORI

**Comparison of the dental arches of children with oral clefts
operated by different primary surgeries at first months and
5 years of life**

**Comparação dos arcos dentários de crianças com fenda
orofacial operadas por diferentes cirurgias primárias nos
primeiros meses de vida e aos 5 anos**

BAURU
2021

UNIVERSIDADE DE SÃO PAULO
HOSPITAL DE REABILITAÇÃO DE ANOMALIAS CRANIOFACIAIS

ISABELA DE CASTRO SARTORI

Comparison of the dental arches of children with oral clefts operated by different primary surgeries at first months and 5 years of life

Comparação dos arcos dentários de crianças com fenda orofacial operadas por diferentes cirurgias primárias nos primeiros meses de vida e aos 5 anos

Dissertação constituída por artigo apresentada ao Hospital de Reabilitação de Anomalias Craniofaciais da Universidade de São Paulo, para obtenção do título de Mestre em Ciências da Reabilitação na área de concentração Fissuras Orofaciais e Anomalias Relacionadas.

Orientadora: Profa. Dra. Thais Marchini de Oliveira Valarelli

Versão corrigida

BAURU
2021

Sartori, Isabela de Castro

Comparison of the dental arches of children with oral clefts operated by different primary surgeries at first months and 5 years of life / Isabela de Castro Sartori. -- Bauru, 2021.

43 p. : il. ; 31 cm.

Dissertação (mestrado) -- Hospital de Reabilitação de Anomalias Craniofaciais, Universidade de São Paulo, 2021.

Orientadora: Profa. Dra. Thais Marchini de Oliveira Valarelli

Autorizo, exclusivamente para fins acadêmicos e científicos, a reprodução total ou parcial desta dissertação, por processos fotocopiadores e outros meios eletrônicos.

Isabela de Castro Sartori

Data:

Comitê de Ética do HRAC-USP
CAAE: 40003220.6.0000.5441
Data: 05/04/2021

ERRATA

FOLHA DE APROVAÇÃO

DEDICATÓRIA

Dedico este trabalho à **minha família**, em especial à minha **mãe**, que por tantas vezes teve seus joelhos dobrados em oração para que esse sonho se tornasse realidade. Mulher de fé, de força e sabedoria. Dedico também ao meu **pai** (*in memoriam*) que sempre me impulsionou a estudar e ser melhor a cada dia.

AGRADECIMENTOS

Primeiramente a **Deus**,
minha rocha, minha fortaleza, meu escudo, sempre no controle de tudo. A Ele toda a honra e toda a glória.

Aos meus **irmãos**,
pelo apoio, incentivo, conselhos, pelos momentos de alegria que me proporcionaram alegrando meu coração.

Aos meus **cunhados**,
por sempre me guiar, olhando sempre para frente, e nunca para trás.

Aos meus **sogros**,
que sempre oraram e me guiaram para o caminho correto a ser seguido.

Ao meu **marido**,
quantos ensinamentos, paciência, compreensão, conselhos, me fazendo sempre ser uma pessoa melhor e me ajudando a lidar com as dificuldades.

À minha amiga **Amanda**,
sem você me dando forças e segurando em minhas mãos, tudo seria muito mais difícil. Com você a jornada foi mais leve e divertida.

À minha orientadora **Profa. Dra. Thais Marchini de Oliveira Valarelli**,
pela doçura, por nos ensinar o caminho que devemos seguir, pela generosidade, paciência, pela confiança e principalmente pela oportunidade que me foi dada.

Ao meu professor **Fabricio Pinelli Valarelli**,
por me incentivar a realizar o mestrado, pelas inúmeras oportunidades, por todo o conhecimento transmitido, por ser o grande responsável pela profissional que sou hoje.

À **Eloá e Paulinha**,
por toda ajuda nesse percurso, por me escutar, pela paciência, pelos conselhos.

À **Ana Regina**,
pela paciência, pelo apoio, carinho, parceria, ajuda. Sempre tão solícita e atenciosa.

A todos os **funcionários** e **professores** do HRAC,
que fazem com que o hospital seja exemplo em tratamentos de alta qualidade.

À **banca examinadora** pela dedicação, disponibilidade e por tantas sugestões importantes para a melhora do meu trabalho.

ABSTRACT

Comparison of the dental arches of children with oral clefts operated by different primary surgeries at first months and 5 years of life

This study aimed to evaluate and compare the development of the dental arches of children with unilateral cleft lip and palate before and after the primary surgeries performed with different techniques at the first months and five years of life. The sample comprised 56 dental casts divided into the following groups: Group 1 (G1) – cheiloplasty (Millard technique) at 3 months and one-step palatoplasty (Von Langenback technique) at 12 months; and Group 2 (G2) – cheiloplasty (Millard technique) and two-step palatoplasty: hard palate closure (Hans Pichler technique) at 3 months and soft palate closure (Sommerlad technique) at 12 months. The dental casts were digitized through 3D scanner and evaluated at 3 months of life – pre-surgical (T1) and 5 years – post-surgical (T2). The following linear measurements were analyzed: intercanine (C–C'), intertuberosity (T–T'), and intermolar distances (M–M'); anterior dental arch length (I–CC'), anterior intersegment (I–C'), and total arch (I–TT'). The dental arch area was also measured. Paired t test and Wilcoxon test compared the intragroup analyses, while independent t test and Mann-Whitney test the intergroup analyses ($p < 0.05$). In G1, the intragroup comparison showed statistically significant smaller I–CC' and I–C' means at T2 ($p = 0.001$ and $p < 0.001$, respectively), while T–T', I–TT', and area comparisons were significantly greater between times ($p < 0.001$, $p = 0.002$, and $p < 0.001$, respectively). In G2, the intragroup comparison exhibited statistically significant smaller C–C' and I–C' means at T2 ($p = 0.004$, for both), while T–T', I–TT' and area comparisons were significantly greater between times ($p < 0.001$, $p = 0.004$, and $p < 0.001$, respectively). At T2, the intergroup analysis revealed that G1 had a statistically significant smaller I–CC' mean ($p = 0.014$). The analysis of the intergroup differences ($\Delta = T2 - T1$) showed that G1 had a statistically smaller I–CC' mean ($p = 0.043$). In conclusion, two-step palatoplasty showed a more favorable prognosis for the maxillary growth than one-step palatoplasty in children with oral clefts.

Keywords: Cleft lip. Cleft palate. Dental molds. Three-dimensional image.



RESUMO

O propósito deste estudo foi avaliar e comparar o desenvolvimento dos arcos dentários de crianças com fissura unilateral de lábio e palato antes e após diferentes cirurgias primárias com diferentes técnicas cirúrgicas nos primeiros meses de vida e aos 5 anos. A amostra foi composta por 56 modelos dentários divididos nos seguintes grupos: Grupo 1 (G1) – fechamento do lábio (técnica de Millard) aos 3 meses e palatoplastia em 1 estágio (técnica de Von Langenback) aos 12 meses. Grupo 2 (G2) – fechamento do lábio (técnica de Millard) e palatoplastia em 2 estágios: fechamento do palato duro (técnica de Hans Pichler) aos 3 meses e do palato mole (técnica de Sommerlad) aos 12 meses. Os modelos dentários foram digitalizados por meio de um scanner 3D e avaliados aos 3 meses de vida, Tempo 1 (T1) - pré-cirúrgica e Tempo 2 (T2) – pós-cirúrgica: aos 5 anos. Foram analisadas as seguintes medidas lineares: distâncias intercaninos (C–C'), intertuberosidades (T–T') e intermolar (M–M'), comprimento anterior do arco dentário (I–CC'), intersegmento anterior (I–C'), total do arco (I–TT') e intersegmento anterior (I–C'). A área dos arcos dentários também foi analisada. O Testes T pareado e Wilcoxon foram aplicados nas análises intragrupos, enquanto Teste T independente e Mann-Whitney nas comparações intergrupos ($p < 0,05$). No G1 houve diferença estatisticamente significativa em I–CC' e I–C' com menores médias em T2 ($p = 0,001$ e $p < 0,001$, respectivamente), enquanto T–T', I–TT' e área cresceram significativamente entre os tempos analisados ($p < 0,001$, $p = 0,002$ e $p < 0,001$, nesta ordem). No G2 houve diferença estatisticamente significativa das medidas C–C' e I–C' apresentando redução em T2 ($p = 0,004$, em ambas), entretanto T–T', I–TT' e área cresceram significativamente ($p < 0,001$, $p = 0,004$ e $p < 0,001$, respectivamente). Na análise intergrupo, em T2 houve diferença estatisticamente significativa na distância I–CC', em que G1 apresentou a menor média ($p = 0,014$). A análise das diferenças intergrupo ($\Delta = T2 - T1$) mostrou diferença estatisticamente significativa na medida I–CC' em que G1 mostrou menor média em relação a G2 ($p = 0,043$). Este estudo concluiu que a cirurgia do palato em duas etapas mostrou prognóstico mais favorável em relação ao crescimento maxilar quando comparada com a cirurgia do palato em uma etapa na reabilitação de pacientes com fissura labiopalatinas.

Palavras-chave: Fenda labial. Fenda palatina. Modelos dentários. Imagem tridimensional.

SUMMARY

1	INTRODUCTION	11
2	OBJECTIVE	16
3	ARTICLE	20
3.1	COMPARISON OF THE DENTAL ARCHES OF CHILDREN WITH ORAL CLEFTS OPERATED BY DIFFERENT PRIMARY SURGERIES AT FIRST MONTHS AND 5 YEARS OF LIFE	21
4	GENERAL CONCLUSIONS	35
	REFERENCES	39
	APPENDIX	44

1 INTRODUCTION

1 INTRODUCTION

Cleft lip and palate (CLP) is the malformation most common diagnosed in the craniofacial region of the humans. CLP etiology is facial development abnormalities during embryogenesis and is associated to severe development anomalies of the hard and soft tissues. CLP is characterized by the incomplete or complete cleft lip, with or without palate involvement. The maxillary growth disturbance is typical in individuals with cleft lip and palate probably because the lack of maxillary growth caused by the healing of the lip and/or palate repair. The literature reports a general global CLP incidence of 1.43 at 1000 live births (HOFFMANNNOVA *et al.*, 2018; HAQUE *et al.*, 2020).

Children with CLP require multidisciplinary treatment mostly because problems with dental anomalies, esthetics, hearing and speech impairment, and mainly, psychosocial behavior. Worldwide, thousands of CLP surgical repairs are performed annually through different techniques. However, the literature lacks studies on the comparison of the outcomes of these different repair techniques. Each rehabilitation center treats CLP with different surgical approaches (AMBROSIO *et al.*, 2020; HAQUE *et al.*, 2020).

In this context, cheiloplasty (lip surgical repair) is frequently performed in either newborns during the first week of life or in babies between 3 and 6 months of life, while palatoplasty (palate surgical repair) is performed between 12 and 18 months of age (AMBROSIO *et al.*, 2018; HOFFMANNNOVA *et al.*, 2018). The repair goal is to restore the normal morphology and the function, with the minimum of disturbance of the maxillary growth potential (MORIOKA *et al.*, 2018). Studies have affirmed that the maxillary arch dimension of individuals with unilateral CLP is significantly smaller than that of the individual without oral clefts (HAQUE *et al.*, 2020). Thus, the primary plastic surgeries rehabilitate the esthetics and function, but they caused a deleterious side-effect on the maxillary growth due to the healings from the lip/palate repair (HOFFMANNNOVA *et al.*, 2018). This results in a concave face, Class II malocclusion, lack of midface growth, and orthodontics anomalies such as crowding, rotation, and tooth mispositioning (HAQUE *et al.*, 2020).

In children with unilateral CLP, cheiloplasty can be repaired by Millard technique (incisions that allowed the flat rotation and advancement) and one-step

palatoplasty (hard and soft palate) by Von Langenbeck technique (mucoperiosteal flaps through lateral relaxing incisions) (AMBROSIO *et al.*, 2020). Besides Von Langenbeck technique, palate closure can be achieved by several other surgical techniques such as: Hans Pichler technique (anterior palate closure alone at 3 months) and Sommerlad technique (posterior palate closure alone at 12 months).

The initial analysis of the palate growth enables to verify the maxillary morphology, determine more clearly the amount of palatal tissue, and examine how each CLP type behaves after the surgical procedures (GENERALI *et al.*, 2017; SAKODA *et al.*, 2017; BEDNAR *et al.*, 2018). This can suggest the best surgical technique and the surgical time most suitable for correcting each CLP type, thus changing the rehabilitation protocols (AMBROSIO *et al.*, 2018).

Three-dimensional (3D) anthropometric analyses have been used to evaluate the maxillofacial development in individuals with craniofacial anomalies at important phases of the rehabilitation protocol, such as before and after the primary surgeries. This knowledge of 3D morphometry of the dental arches would help in the rehabilitation and would provide new criteria for further studies and rehabilitation protocols (AMBROSIO *et al.*, 2020). By using 3D images, long-term comparisons of several surgical techniques and interventions can be obtained at different time intervals; the cleft severity can be verified by measurements to provide proper surgical planning; and dental development can be predicted (DE MENEZES *et al.*, 2016; MORIOKA *et al.*, 2018; BOTTICELLI *et al.*, 2019). The advantage of performing the evaluation of primary surgeries outcomes in 5-year-old children is to analyze the dental arch dimensions and maxilla-mandible relation before the mixed dentition and to provide other treatments such as secondary alveolar bone graft and orthodontics (RANDO *et al.*, 2018).

2 OBJECTIVE

2 OBJECTIVE

This study aimed to evaluate and compare the development of the dental arches of children with unilateral cleft lip and palate before and after the primary surgeries performed with different techniques at the first months and five years of life.

3 ARTICLE

3 ARTICLE

3.1 COMPARISON OF THE DENTAL ARCHES OF CHILDREN WITH ORAL CLEFTS OPERATED WITH DIFFERENT PRIMARY SURGERIES AT FIRST MONTHS AND 5 YEARS OF LIFE

Autores:

Eloá Cristina Passucci Ambrosio

Doutora, Departamento de Odontopediatria, Ortodontia e Saúde Pública, Faculdade de Odontologia de Bauru - Universidade de São Paulo, Bauru, São Paulo, Brasil.

Isabela de Castro Sartori

Aluna do Mestrado, Hospital de Reabilitação de Anomalias Craniofaciais, Universidade de São Paulo, Bauru, SP, Brasil.

Paula Karine Jorge

Doutoranda, Departamento de Odontopediatria, Ortodontia e Saúde Pública, Faculdade de Odontologia de Bauru - Universidade de São Paulo, Bauru, São Paulo, Brasil.

Cleide Felício Carvalho Carrara

Doutora, Dentista Profissional de Odontopediatria, Hospital de Reabilitação de Anomalias Craniofaciais, Universidade de São Paulo, Bauru, SP, Brasil.

Fabício Pinelli Valarelli

Doutor, Professor Auxiliar, Departamento de Ortodontia, Universidade Ingá, Maringá, Paraná, Brasil.

Maria Aparecida Andrade Moreira Machado

Doutora, Professora Titular do Departamento de Odontopediatria, Ortodontia e Saúde Pública, Faculdade de Odontologia de Bauru - Universidade de São Paulo, Bauru, São Paulo, Brasil.

Thais Marchini Oliveira

Doutora, Professora Associada, Departamento de Odontopediatria, Ortodontia e Saúde Pública, Faculdade de Odontologia de Bauru - Universidade de São Paulo, Bauru, São Paulo, Brasil.

Abstract

This study aimed to evaluate and compare the development of the dental arches of children with unilateral cleft lip and palate before and after the primary surgeries performed with different techniques at the first months and five years of life. The sample comprised 56 dental casts divided into the following groups: Group 1 (G1) – cheiloplasty (Millard technique) at 3 months and one-step palatoplasty (Von Langenback technique) at 12 months; and Group 2 (G2) – cheiloplasty (Millard technique) and two-step palatoplasty: hard palate closure (Hans Pichler technique) at 3 months and soft palate closure (Sommerlad technique) at 12 months. The dental casts were digitized through 3D scanner and evaluated at 3 months of life – pre-surgical (T1) and 5 years – post-surgical (T2). The following linear measurements were analyzed: intercanine (C–C'), intertuberosity (T–T'), and intermolar distances (M–M'); anterior dental arch length (I–CC'), anterior intersegment (I–C'), and total arch (I–TT'). The dental arch area was also measured. Paired t test and Wilcoxon test compared the intragroup analyses, while independent t test and Mann-Whitney test the intergroup analyses ($p < 0.05$). In G1, the intragroup comparison showed statistically significant smaller I–CC' and I–C' means at T2 ($p = 0.001$ and $p < 0.001$, respectively), while T–T', I–TT', and area comparisons were significantly greater between times ($p < 0.001$, $p = 0.002$, and $p < 0.001$, respectively). In G2, the intragroup comparison exhibited statistically significant smaller C–C' and I–C' means at T2 ($p = 0.004$, for both), while T–T', I–TT' and area comparisons were significantly greater between times ($p < 0.001$, $p = 0.004$, and $p < 0.001$, respectively). At T2, the intergroup analysis revealed that G1 had a statistically significant smaller I–CC' mean ($p = 0.014$). The analysis of the intergroup differences ($\Delta = T2 - T1$) showed that G1 had a statistically smaller I–CC' mean ($p = 0.043$). In conclusion, two-step palatoplasty showed a more favorable prognosis for the maxillary growth than one-step palatoplasty in children with oral clefts.

Keywords: Cleft lip. Cleft palate. Dental Molds. Three-dimensional image.

Introduction

Cleft lip and palate (CLP) is the malformation most common diagnosed in the craniofacial region of the humans. CLP etiology is facial development abnormalities

during embryogenesis and is associated to severe development anomalies of the hard and soft tissues. The maxillary growth disturbance is typical in individuals with cleft lip and palate probably because the lack of maxillary growth caused by the healing of the lip and/or palate repair (HOFFMANNOVA *et al.*, 2018; HAQUE *et al.*, 2020). Children with CLP require multidisciplinary treatment mostly because problems with dental anomalies, esthetics, hearing and speech impairment, and mainly, psychosocial behavior. Worldwide, thousands of CLP surgical repairs are performed annually through different techniques. However, the literature lacks studies on the comparison of the outcomes of these different repair techniques. Each rehabilitation center treats CLP with different surgical approaches (HAQUE *et al.*, 2020).

In this context, cheiloplasty (lip surgical repair) is frequently performed in either newborns during the first week of life or in babies between 3 and 6 months of life, while palatoplasty (palate surgical repair) is performed between 12 and 18 months of age (HOFFMANNOVA *et al.*, 2018). The repair goal is to restore the normal morphology and the function, with the minimum of disturbance of the maxillary growth potential (MORIOKA *et al.*, 2018). Studies have affirmed that the maxillary arch dimension of individuals with unilateral CLP is significantly smaller than that of the individual without oral clefts (HAQUE *et al.*, 2020). Thus, the primary plastic surgeries rehabilitate the esthetics and function, but they caused a deleterious side-effect on the maxillary growth due to the healings from the lip/palate repair (HOFFMANNOVA *et al.*, 2018). This results in a concave face, Class III malocclusion, lack of midface growth, and orthodontics anomalies such as crowding, rotation, and tooth mispositioning (HAQUE *et al.*, 2020). In children with unilateral CLP, cheiloplasty can be repaired by Millard technique (incisions that allowed the flat rotation and advancement) and one-step palatoplasty (hard and soft palate) by Von Langenbeck technique (mucoperiosteal flaps through lateral relaxing incisions) (AMBROSIO *et al.*, 2020). Besides Von Langenbeck technique, palate closure can be achieved by several other surgical techniques such as: Hans Pichler technique (anterior palate closure alone at 3 months) and Sommerlad technique (posterior palate closure alone at 12 months).

By using tridimensional (3D) images, long-term comparisons of several surgical techniques and interventions can be obtained at different time intervals; the cleft severity can be verified by measurements to provide proper surgical planning;

and dental development can be predicted (DE MENEZES *et al.*, 2016; MORIOKA *et al.*, 2018; BOTTICELLI *et al.*, 2019). The advantage of performing the evaluation of primary surgeries outcomes in 5-year-old children is to analyze the dental arch dimensions and maxilla-mandible relation before the mixed dentition and to plan other treatments such as secondary alveolar bone graft and orthodontics (RANDO *et al.*, 2018). This study aimed to evaluate and compare the development of the dental arches of children with unilateral cleft lip and palate before and after the primary surgeries performed with different techniques at the first months and five years of life.

Material and Methods

This study was approved by the Institutional Review Board under protocol CAAE: 40003220.6.0000.5441.

The inclusion criteria comprised children with unilateral CLP, regularly enrolled in the institution, operated by the same plastic surgeon, who started the rehabilitation treatment without previous surgery, and returned at 5 years-old to the institution. Exclusion criteria were the presence of associated malformation or syndrome and children with incomplete records.

Sample size calculation used the study of Carrara *et al.* (2016), considering a standard deviation of 2.32 mm for the total dental arch length at pre-surgical stage, with significance level of 5%, power test of 80%, and minimum difference to be clinically detected of 2.7 mm. The minimum sample size of each group was of 14 children.

The sample was divided into two groups according to the surgical technique: Group 1 (G1) – cheiloplasty (Millard technique) at 3 months and one-step palatoplasty (Von Langenback technique) at 12 months; and Group 2 (G2) – cheiloplasty (Millard technique) and two-step palatoplasty: hard palate closure (Hans Pichler technique) at 3 months and soft palate closure (Sommerlad technique) at 12 months.

The children had the impressions taken at 3 months of life (pre-surgical) – T1 and at 5 years-old (post-surgical) – T2. The dental casts were digitized through 3D Scanner (Scanner R700TM Scanner; 3Shape AS, Copenhagen, Denmark) and analyzed by two examiners by stereophotogrammetry software (Mirror imaging

software, Canfield Scientific, Inc., Fairfield, NJ, USA) (JORGE *et al.*, 2016; AMBROSIO *et al.*, 2018).

The following linear measurements were analyzed: *intercanine distance* (C–C') – transversal line between the eruption points and/or cusps of the maxillary primary canine in the greater (C) and smaller bone segment (C'); *anterior dental arch length* (I–CC') – straight line of the interincisive point (I) perpendicularly to the C–C' distance; *anterior intersegment length* (I–C') – straight line from the point I to the eruption point and/or cusp of the maxillary primary canine in the smaller bone segment (C'); *intertuberosity distance* (T–T') – transversal line from the end of the alveolar ridge of the greater (T) to the smaller (T') bone segments; *pre-surgical sagittal length* (I–TT') – straight line from the point (I) perpendicularly to the distance T–T' (MAULINA *et al.*, 2007; JORGE *et al.*, 2016; AMBROSIO *et al.*, 2018; MELLO *et al.*, 2019). All linear measurements were analyzed in millimeters (mm) (Figures 1A and 2A).

The dental arch area was analyzed in squared millimeters (mm²). At T1, the area was marked by using the alveolar ridge crest contouring each palatal bone segment adjacent to the cleft, with posterior limit of the distance T–T'. At this time period, both segments were summed to enable the comparisons. At T2, the area was marked by contouring the primary teeth with posterior limit of the distance T–T' (JORGE *et al.*, 2016; AMBROSIO *et al.*, 2018) (Figures 1B and 2B).

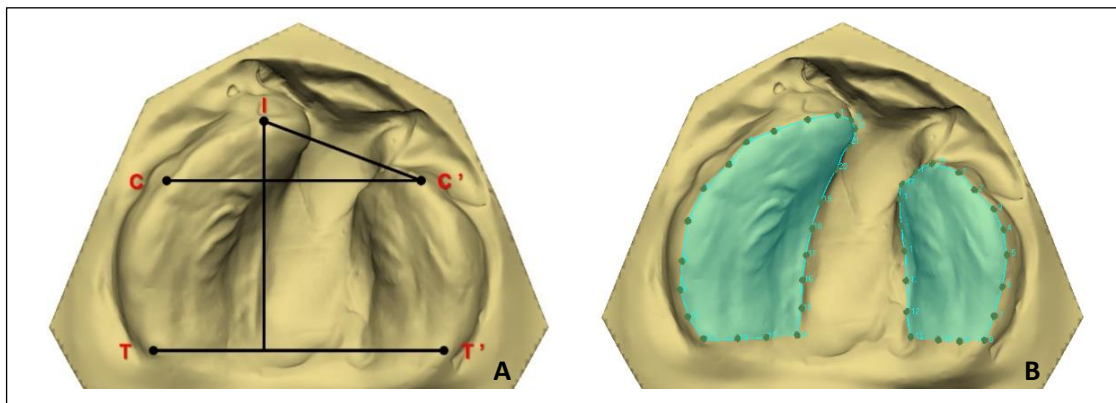


Figure 1 - Dental arch of T1

Source: Created by the author.

A= Anatomical points and linear measurements; **B=** Contour of the greater and smaller segments to calculate the area.

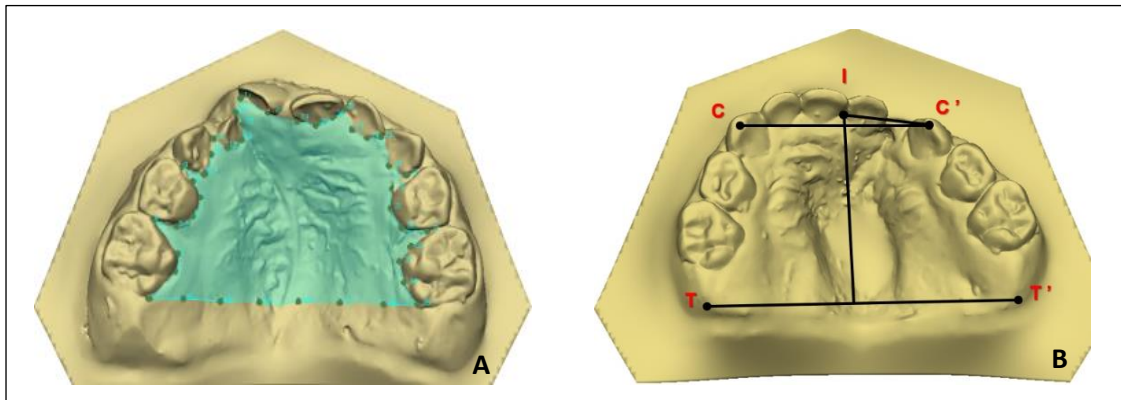


Figure 2 - Dental arch of T2

Source: Created by the author.

A= Anatomical points and linear measurements; **B=** Contour of the palate to calculate the area.

All statistically analyses were performed in GraphPad Prism software (Prism 5 for Windows - Version 5.0 – GraphPad software., Inc. San Diego, USA), with level of significance of 5%. Shapiro-Wilk test checked the normality. To evaluate the method reliability, 1/3 of the sample was measured twice with a 15-day interval (AMBROSIO *et al.*, 2018). For analysis of intra-examiner reproducibility and inter-examiner, the paired Interclass Correlation Coefficient (ICC) was used. Paired t test and Wilcoxon test analyzed the intragroup comparisons, while independent t test and Mann-Whitney test analyzed the intergroup comparisons. In the parametric analyses, data was presented as means and standard deviation (SD) and non-parametric analyses as median and interquartile amplitude (IA).

Results

Sample characterization

Fourteen children composed each group, totalizing 56 analyzed dental models. The mean ages were 0.33 (\pm 0.08) years at T1 and 6.51 (\pm 0.86) years at T2.

Analyses of intraexaminer and interexaminer reliability

No statistically significant differences occurred in the analyses of the intraexaminer (Wilcoxon test, $p=0.100$ and Dahlberg's formula = 0.287) and interexaminer reliability (Mann-Whitney test, $p=0.962$).

Intragroup analysis

In G1, the intragroup comparison showed statistically significant smaller I-CC' and I-C' means at T2 ($p=0.001$ and $p<0.001$, respectively) (Table 1). T-T', I-TT', and area comparisons were significantly greater between times ($p<0.001$, $p=0.002$, and $p<0.001$, respectively) (Table 1).

Table 1 - Analyses of the linear measurements (mm) and area (mm²) of Group 1 (Paired t test and Wilcoxon test)

Variables	Time 1		Time 2		<i>p</i>
	Mean (Median)	SD (IA)	Mean (Median)	SD (IA)	
C - C'	(29.61)	(5.73)	(25.64)	(4.15)	0.104†
I - CC'	6.83	0.91	4.31	2.14	0.001*
I - C'	19.38	3.13	12.22	2.11	<0.001*
T - T'	(37.56)	(4.72)	(46.36)	(5.41)	<0.001†*
I - TT'	25.07	1.47	29.2	3.88	0.002*
Area	(837.66)	(161.68)	(1274.89)	(206.15)	<0.001†*

Source: Created by the author.

†Wilcoxon test.

*Statistically significant difference.

In G2, the intragroup comparison exhibited statistically significant smaller C-C' and I-C' means at T2 ($p=0.004$) while T-T', I-TT' and area comparisons were significantly greater between times ($p<0.001$, $p=0.004$, and $p<0.001$, respectively) (Table 2).

Table 2 - Analyses of the linear measurements (mm) and area (mm²) of Group 2 (Paired t test and Wilcoxon test)

Variables	Time 1		Time 2		<i>p</i>
	Mean (Median)	SD (IA)	Mean (Median)	SD (IA)	
C - C'	27.9	2.95	25.55	2.75	0.004*
I - CC'	6.76	1.32	6.07	1.30	0.252
I - C'	(18.2)	(3.99)	(13.22)	(1.02)	0.004†*
T - T'	36.07	2.14	43.33	3.67	<0.001*

I – TT'	25.4	3.17	29.26	3.73	0.004*
Area	860.12	148.1	1156.98	158.37	<0.001*

Source: Created by the author.

†Wilcoxon test.

*Statistically significant difference.

Intergroup analyses

At T2, the intergroup analysis revealed that G1 had a statistically significant smaller I–CC' mean than that of G2 ($p=0.014$) (Table 3).

Table 3 - Intergroup analysis (G1 vs. G2) of the linear measurements (mm) and area (mm²) (Independent t test and Mann-Whitney test)

Variables	<i>p</i>	
	Time 1	Time 2
C – C'	0.800‡	0.495
I – CC'	0.870	0.014*
I – C'	0.287	0.323‡
T – T'	0.730‡	0.057
I – TT'	0.727	0.966
Area	0.906	0.147‡

Source: Created by the author.

‡Mann-Whitney.

*Statistically significant difference.

The analysis of the intergroup differences ($\Delta = T2 - T1$) showed that G1 had a statistically smaller I–CC' mean than that of G2 ($p=0.043$) (Table 4).

Table 4 - Analyses of the intergroup differences ($\Delta = T2 - T1$) of the linear measurements (mm) and area (mm²) – Independent t test

Variables	Group 1		Group 1		<i>p</i>
	Mean	Mean	Mean	Mean	
C – C'	-1.92	4.01	-2.34	2.59	0.741
I – CC'	-2.51	2.41	-0.68	2.14	0.043*
I – C'	-7.16	4.04	-4.59	4.61	0.130
T – T'	10.39	3.45	7.26	4.66	0.053
I – TT'	4.13	4.05	3.86	4.24	0.866
Area	421.64	261.33	296.86	207.13	0.173

Source: Created by the author.

*Statistically significant difference.

Discussion

The dental arches of children with cleft lip and palate was evaluated at the first months of life and at 5 years of age because the literature lacks studies on evaluating the maxillary growth before the onset of the permanent dentition. And before any other orthodontic intervention for palate expansion. In children with maxillary growth deficiency, orthodontic treatment for opening the palate suture can be performed from 6 years of age onwards. But if this study were carried out after the orthodontic intervention, it would generate changes in the measures, leading to a obliquity in the results and allowing for a lack of reliability. Most of the longitudinal studies evaluated the maxillary changes 12-24 months after the lip and palate repair surgeries (CERÓN-ZAPATA *et al.*, 2016; DE MENEZES *et al.*, 2016; HOFFMANNOVA *et al.*, 2016; JORGE *et al.*, 2016). Other studies did measure the dental arch area of children with clefts, but they did not follow the maxillary growth until 5 years of age (LO *et al.*, 2003; DARVANN *et al.*, 2007; RUSSELL; LONG; ROMBERG, 2015; DE MENEZES *et al.*, 2016; JORGE *et al.*, 2016; GENERALI *et al.*, 2017). This present study revealed that children submitted to two-step palate repair had better growth than those submitted to one-step palatoplasty. One-step palatoplasty (G1) showed more reduction in the anterior arch length after lip and full palate repair. This was similar to the results of the study of Haque *et al.* (2020) who affirmed that in children with unilateral CLP the maxillary constriction is the main disadvantage of the standard palatoplasty procedure. Two-step palatoplasty (G2) exhibited smaller reduction in both the anterior arch length and anterior transversal arch length.

In both groups, cheiloplasty at 3 months of age had a restrictive effect on both anterior arch length (I-CC') and anterior transversal arch length (I-C') and in the posterior part of the arch, it remained stable (I-TT' e T-T'). This result was similar to those reported by Haque *et al.* (2020) who performed different surgical techniques that inhibited the maxillary growth, especially on the anterior segment (GIRINON *et al.*, 2019). Other studies on linear measurements revealed that the maxillary anterior area of individuals with unilateral CLP underwent transversal restriction after cheiloplasty by means of the decreasing of the intercanine distance, but showing and increasing of the intertuberosity distance; after palatoplasty, these distances were maintained stable (MAZAHERI *et al.*, 1971; ROUSSEAU *et al.*, 2013; JORGE *et al.*, 2016; SAKODA *et al.*, 2017).

At 5-year-old post-surgical evaluation, G1 had a more restrictive effect on the anterior arch length than G2, corroborating the results of the studies of Haque e Mohammad (2015) and Girinon *et al.* (2019), where individuals submitted to two-step palatoplasty showed better maxillary growth, that is, one-step palatoplasty was less favorable than two-step palatoplasty. Different results showed similar maxillary deficiency in individuals submitted to lip repair compared to those submitted to lip and palate repair (LI *et al.*, 2006).

The study of Yu *et al.* (2020) measured the total dental arch area of individuals with unilateral CLP before palatoplasty (at 12 months) to verify whether the cleft amplitude could be considered an aggravating factor on the maxillary growth and performed cephalometric analyses of these individuals at 9 years of age. Moreover, Bednar *et al.* (2018) measured the total dental arch area in children with unilateral CLP and without clefts at the first months of life. These different methodologies and different measurements make the comparisons difficult.

It is difficult to obtain dental casts of newborns because of the affliction and agitation of the baby during the impression procedure (BRUGGINK *et al.*, 2019). Despite of these limitations, the impression procedure of newborns is the gold standard for the documentation of children with CLP. In the future, intraoral scanning could replace the impressions, but the current scanning device tips are still too big to be used inside the babies' mouth. In this study, the used software showed good reproducibility to determine the maxillary growth.

This present study enabled a better understanding of the effect of lip and palate surgical repair on the craniofacial growth and development. Notwithstanding, further studies are necessary aiming at decreasing the iatrogenic effects of the surgeries, favoring the rehabilitation, and improving the quality of life of this children. This would provide objective estimates of the maxillary growth and the outcomes could be used as control data for studies evaluating the growth and treatment of individuals with cleft lip and palate compared with those without clefts.

Conclusion

Based on the results, this study concluded that two-step palatoplasty showed a more favorable prognosis for the maxillary growth than one-step palatoplasty in children with oral clefts, with restriction in the anterior part of the arch.

References

- AMBROSIO, E. C. P. *et al.* Longitudinal morphometric analysis of dental arch of children with cleft lip and palate: 3D stereophotogrammetry study. **Oral Surg Oral Med Oral Pathol Oral Radiol**, New York, v. 126, n. 6, p. 463-468, 2018.
- AMBROSIO, E. C. P. *et al.* Prospective cohort 3d study of dental arches in children with bilateral orofacial cleft: assessment of volume and superimposition. **Int J Paediatr Dent**, Oxford, 2020. No prelo.
- BEDNAR, K. A. *et al.* Palatal and alveolar tissue deficiency in infants with complete unilateral cleft lip and palate. **Cleft Palate Craniofac J**, Pittsburgh, v. 55, n. 1, p. 64-69, 2018.
- BOTTICELLI, S. *et al.* Novel 3-D Analysis for the assessment of cleft dimensions on Digital models of infants with unilateral cleft lip and palate. **Cleft Palate Craniofac J**, Pittsburgh, v. 56, n. 1, p. 127-133, 2019.
- BRUGGINK, R. *et al.* Three dimensional maxillary growth modeling in newborns. **Clin Oral Investig**, Berlin, v. 23, n. 10, p. 3705-3712, 2019.
- CERÓN-ZAPATA, A. M. *et al.* 3D evaluation of maxillary arches in unilateral cleft lip and palate patients treated with nasopalveolar moulding vs. Hotz's plate. **J Oral Rehabil**, v. 43, n. 2, p. 111-118, 2016.
- DARVANN, T. A. *et al.* Palatal surface area of maxillary plaster casts--a comparison between two-dimensional and three-dimensional measurements. **Cleft Palate Craniofac J**, Pittsburgh, v. 44, n. 4, p. 381-390, 2007.
- DE MENEZES, M. *et al.* Evaluation of a three-dimensional stereophotogrammetric method to identify and measure the palatal surface area in children with unilateral cleft lip and palate. **Cleft Palate Craniofac J**, Pittsburgh, p. 53, n. 1, p. 16-21, 2016.
- GENERALI, C. *et al.* Three-dimensional evaluation of the maxillary arch and palate in unilateral cleft lip and palate subjects using digital dental casts. **Eur J Orthod**, Oxford, v. 39, n. 6, p. 641-645, 2017.
- GIRINON, F. *et al.* Maxillary shape after primary cleft closure and before alveolar bone graft in two different management protocols: a comparative morphometric study. **J Stomatol Oral Maxillofac Surg**, Issy les Moulineaux, v. 120, n. 5, p. 406-409, 2019.

HAQUE, S. *et al.* Effects of Multiple factors on treatment outcome in the three-dimensional maxillary arch morphometry of children with unilateral cleft lip and palate. **J Craniofac Surg**, Hagerstown, v. 31, n. 6, p. e534-e538, 2020.

HAQUE, S.; MOHAMMAD, K. A. Spectrum of palatoplasty has detrimental effect on maxillary growth: myth or fact?. **Bangladesh Journal of Medical Science**, Dhaka, 15; v. 14, n. 1, p. 109-110, 2015.

HOFFMANNOVA, E. *et al.* Palatal growth in complete unilateral cleft lip and palate patients following neonatal cheiloplasty: Classic and geometric morphometric assessment. **Int J Pediatr Otorhinolaryngol**, Limerick, v. 90, p. 71-76, 2016.

HOFFMANNOVA, E. *et al.* Three-dimensional development of the upper dental arch in unilateral cleft lip and palate patients after early neonatal cheiloplasty. **Int J Pediatr Otorhinolaryngol**, Limerick, v. 109, p. 1-6, 2018.

JORGE, P. K. *et al.* Comparison of two treatment protocols in children with unilateral complete cleft lip and palate: Tridimensional evaluation of the maxillary dental arch. **J Craniomaxillofac Surg**, Edinburgh, v. 44, n. 9, p. 1117-1122, 2016.

LI, Y. *et al.* Effects of lip repair on maxillary growth and facial soft tissue development in patients with a complete unilateral cleft of lip, alveolus and palate. **J Craniomaxillofac Surg**, Edinburgh, v. 34, n. 6, p. 355-361, 2006.

LO, L. J. *et al.* Palatal surface area measurement: comparisons among different cleft types. **Ann Plast Surg**, Boston, v. 50, n. 1, p. 18-23, discussion 23-24, 2003.

MAULINA, I. *et al.* The influence of early orthodontic treatment on the growth of craniofacial complex in deciduous occlusion of unilateral cleft lip and palate patients. **Stomatologija**, Kaunas, v. 9, n. 3, p. 91-96, 2007.

MAZAHERI, M. *et al.* Changes in arch form and dimensions of cleft patients. **Am J Orthod**, St. Louis, v. 60, n. 1, p. 19-32, 1971.

MELLO, B. Z. F. *et al.* Analysis of dental arch in children with oral cleft before and after the primary surgeries. **J Craniofac Surg**, Hagerstown, v. 30, n. 8, p. 2456-2458, 2019.

MORIOKA, D. *et al.* Longitudinal follow-up of individuals with cleft lip using three-dimensional stereophotogrammetry. **J Craniofac Surg**, Hagerstown, v. 29, n. 5, p. 1261-1265, 2018.

RANDO, G. M. *et al.* Anthropometric analysis of the dental arches of five-year-old children with cleft lip and palate. **J Craniofac Surg**, Hagerstown, v. 29, n. 6, p. 1657-1660, 2018.

ROUSSEAU, P. *et al.* Effect of lip closure on early maxillary growth in patients with cleft lip and palate. **JAMA Facial Plast Surg**, Chicago, v. 15, n. 5, p. 369-373, 2013.

RUSSELL, L. M.; LONG, R. E. JR., ROMBERG, E. The effect of cleft size in infants with unilateral cleft lip and palate on mixed dentition dental arch relationship. **Cleft Palate Craniofac J**, Pittsburgh, v. 52, n. 5, p. 605-613, 2015.

SAKODA, K. L. *et al.* 3D analysis of effects of primary surgeries in cleft lip/palate children during the first two years of life. **Braz Oral Res**, São Paulo, v. 31, p. e46, 2017.

YU, Q. *et al.* A novel splicing mutation of ARHGAP29 is associated with nonsyndromic cleft lip with or without cleft palate. **J Matern Fetal Neonatal Med**, London, 2020. No prelo.

4 GENERAL CONCLUSIONS

4 GENERAL CONCLUSIONS

This present study enabled a better understanding of the effect of lip and palate surgical repair on the craniofacial growth and development. Notwithstanding, further studies are necessary aiming at decreasing the iatrogenic effects of the surgeries, favoring the rehabilitation, and improving the quality of life of these children. Based on the results, this study concluded that two-step palatoplasty showed a more favorable prognosis for the maxillary growth than one-step palatoplasty in children with oral clefts.

REFERENCES

REFERENCES

- AMBROSIO, E. C. P. *et al.* Longitudinal morphometric analysis of dental arch of children with cleft lip and palate: 3D stereophotogrammetry study. **Oral Surg Oral Med Oral Pathol Oral Radiol**, New York, v. 126, n. 6, p. 463-468, 2018.
- AMBROSIO, E. C. P. *et al.* Prospective cohort 3d study of dental arches in children with bilateral orofacial cleft: assessment of volume and superimposition. **Int J Paediatr Dent**, Oxford, 2020. No prelo
- BEDNAR, K. A. *et al.* Palatal and alveolar tissue deficiency in infants with complete unilateral cleft lip and palate. **Cleft Palate Craniofac J**, Pittsburgh, v. 55, n. 1, p. 64-69, 2018.
- BOTTICELLI, S. *et al.* Novel 3-D Analysis for the assessment of cleft dimensions on Digital models of infants with unilateral cleft lip and palate. **Cleft Palate Craniofac J**, Pittsburgh, v. 56, n. 1, p. 127-133, 2019.
- DE MENEZES, M. *et al.* Evaluation of a three-dimensional stereophotogrammetric method to identify and measure the palatal surface area in children with unilateral cleft lip and palate. **Cleft Palate Craniofac J**, Pittsburgh, p. 53, n. 1, p. 16-21, 2016.
- GENERALI, C. *et al.* Three-dimensional evaluation of the maxillary arch and palate in unilateral cleft lip and palate subjects using digital dental casts. **Eur J Orthod**, Oxford, v. 39, n. 6, p. 641-645, 2017.
- HAQUE, S. *et al.* Effects of Multiple factors on treatment outcome in the three-dimensional maxillary arch morphometry of children with unilateral cleft lip and palate. **J Craniofac Surg**, Hagerstown, v. 31, n. 6, p. e534-e538, 2020.
- HOFFMANNOVA, E. *et al.* Three-dimensional development of the upper dental arch in unilateral cleft lip and palate patients after early neonatal cheiloplasty. **Int J Pediatr Otorhinolaryngol**, Limerick, v. 109, p. 1-6, 2018.
- MORIOKA, D. *et al.* Longitudinal follow-up of individuals with cleft lip using three-dimensional stereophotogrammetry. **J Craniofac Surg**, Hagerstown, v. 29, n. 5, p. 1261-1265, 2018.
- RANDO, G. M. *et al.* Anthropometric analysis of the dental arches of five-year-old children with cleft lip and palate. **J Craniofac Surg**, Hagerstown, v. 29, n. 6, p. 1657-1660, 2018.
- SAKODA, K. L. *et al.* 3D analysis of effects of primary surgeries in cleft lip/palate children during the first two years of life. **Braz Oral Res**, São Paulo, v. 31, p. e46, 2017.

APPENDIX

APPENDIX A

DECLARATION OF EXCLUSIVE USE OF THE ARTICLE IN DISSERTATION

We hereby declare that we are aware of the article *Comparison of the dental arches of children with oral clefts at first months and 5 years of life* will be included in (Dissertation/Thesis) of the student (Isabela de Castro Sartori) was not used and may not be used in other works of Graduate Programs at the Bauru School of Dentistry, University of São Paulo.

Bauru, July 2, 2021.

Eloá Cristina Passucci Ambrosio
Author


Signature

Isabela de Castro Sartori
Author


Signature

Paula Karine Jorge
Author


Signature

Cleide Felício de Carvalho Carrara
Author


Signature

Fabricio Pinelli Valarelli
Author


Signature

Maria Aparecida Andrade Moreira Machado
Author


Signature

Thais Marchini de Oliveira
Author


Signature