

UNIVERSIDADE DE SÃO PAULO  
FACULDADE DE ODONTOLOGIA DE BAURU

MARILIA SAYAKO YATABE IOSHIDA

**Three-dimensional assessment of maxillary protraction with  
miniplates in patients with cleft lip and palate**

**Avaliação tridimensional da protração ortopédica da maxila com  
miniplacas em pacientes com fissura labiopalatina**

BAURU

2016



MARILIA SAYAKO YATABE IOSHIDA

**Three-dimensional assessment of maxillary protraction with  
miniplates in patients with cleft lip and palate**

**Avaliação tridimensional da protração ortopédica da maxila com  
miniplacas em pacientes com fissura labiopalatina**

Tese constituída por artigos apresentados à Faculdade de Odontologia de Bauru da Universidade de São Paulo para obtenção do título de Doutor em Ciências no Programa de Ciências Odontológicas Aplicadas, na área de concentração Ortodontia.

Orientadora: Prof<sup>ª</sup>. Dr<sup>ª</sup>. Daniela Gamba Garib  
Carreira

**Versão Corrigida**

BAURU  
2016

Y27t Yatabe-Ioshida, Marília Sayako  
Three-dimensional assessment of maxillary protraction  
with miniplates in patients with cleft lip and palate / Marília  
Sayako Yatabe-Ioshida. – Bauru, 2016.  
81 p. : il. ; 31cm.

Tese (Doutorado) – Faculdade de Odontologia de  
Bauru. Universidade de São Paulo

Orientador: Prof.<sup>a</sup> Dr.<sup>a</sup> Daniela Gamba Garib  
Carreira

**Nota:** A versão original desta tese encontra-se disponível no Serviço de Biblioteca e Documentação da Faculdade de Odontologia de Bauru – FOB/USP.

Autorizo, exclusivamente para fins acadêmicos e científicos, a  
reprodução total ou parcial desta dissertação/tese, por  
processos fotocopiadores e outros meios eletrônicos.

Assinatura:

Data:

Comitê de Ética HRAC-USP  
Protocolo nº: 819.693  
Data: 30/09/2014

## FOLHA DE APROVAÇÃO



---

---

# Dedico este trabalho...

... aos meus pais, **Kimiko e Sérgio**,  
pela dedicação incondicional por toda minha vida...

... ao **Marcos**,  
por compartilhar nossas vidas e nossos sonhos...

... e especialmente à **Kaori**,  
por ser uma pessoa tão cheia de vida, alegria e amor. E pela paciência  
e compreensão nos momentos da minha ausência.

---

---





---

---

# Agradeço a Deus...

...pela dádiva da vida e por me permitir compartilhar com pessoas incríveis!

...por me presentear com uma pequena-grande família!! Obrigada por confiarem e abraçarem juntos o meu sonho! Graças a dedicação e abdicção de vocês este sonho se tornou realidade.

---

---



---

---

# Agradeço especialmente...

Às minhas famílias Sato, Tsujimoto e Yatabe, que apesar da distância, se fazem sempre presentes! Na alegria e na tristeza, na saúde e na doença! Essa família é, realmente, muito unida!

À família do meu esposo (Caio, Fabiana, Flavia, Ju, Julia, Marisa, Nilton, Marcel e Tadashi) pelos sorrisos sempre estampados quando nos encontramos. Obrigada pelo apoio e carinho de sempre!

Aos amigos de décadas (Carina, Diana, Leticia, Rapha, Thaisinha, Cintia, Silvia, Sabrina, Vivian, Rafa, Luluzinhas de Bauru). Apesar da distância, o carinho e alegria de estar com vocês continua. As memórias que carrego comigo me dão a alegria e o suporte de continuar mesmo nas batalhas mais difíceis. Com certeza não faltarão oportunidades para nos reencontrar! Saudades sempre!

*“A vida me ensinou a dizer adeus às pessoas que amo*

*sem tirá-las do meu coração”*

*Charles Chaplin*

Ao Dr. **Renato Faco**. Depois de passar a residência inteira fugindo de você, quem diria que fôssemos ser parceiros de pesquisa de Doutorado!! Foi um prazer trabalhar ao seu lado! Minha admiração pela competência profissional, pelo seu entusiasmo em ser pai, e principalmente pela sua calma!

---

---



---

---

# Agradeço especialmente...

## à Profa. Daniela Garib

Ao longo de 9 anos de convivência, você me ensinou Ortodontia, instigou a minha paixão pela pesquisa, me estendeu a mão e me guiou ao longo de toda a jornada. Obrigada por confiar em mim uma pesquisa brilhante, e me apoiar na realização de um sonho. Com certeza agregaram e influenciaram a profissional que almejo ser. Mas acima disso, você ainda se preocupou em me lembrar que toda vida deve ter seu equilíbrio entre trabalho, diversão e família.

À família Garib Carreira: Laurinha, Helena, Dani e Alemão, que nos receberam de braços abertos, e que demonstram um carinho tão grande pela nossa família. Que o tempo fortaleça os laços de amizade.

---

---



---

---

# Special Thanks to...

## "The Best Lab Ever and J2's"

Not only co-workers, but friends, confidants, and, why not, "family"!

**Lucia Cevidanes**, que excedeu às expectativas de orientadora e se tornou uma querida amiga. Obrigada não só pelos conselhos e orientações, mas pela confiança e oportunidade de compartilhar tantas experiências, inclusive a de como ser uma boa mãe! TT and Nani are great kids!

**Antônio Carlos e Elaine Ruelas**, pelo carinho, convivência e amizade. Aprender Ortodontia e Física foi uma simples consequência de trabalhar com uma pessoa tão especial!

**Liliane e Marcelo Gomes**, casal baiano mais querido! Ficam guardadas ótimas lembranças dos momentos divertidos no lab, dos almoços, desabafos e longas noites de trabalho! Thank God Wendy's!

**Cristiano Tonello**, querido amigo e parceiro de conversas quando o computador já não dava mais conta de nos entreter! Obrigada pelo convívio e pelo carinho.

**Bernardo, Barbra, Ana Clara e Nina**. Que linda família! Obrigada por nos receber de braços abertos e pelo carinho para com a minha família. Bernardo, obrigada pelos brainstorms às 08:00AM ou PM e pelos mais diversos conselhos!

**Lucie and Julia**, my dearest french girls! You two are very talented girls, and it was my great honor to have worked with you, and beyond that, shared the greatest days of work: Nutella's day!!

**Bea, Tung, François, JB and Laura**: brilliant minds that I had the honor to work with! I have learned a lot more than I have thought I would, and I can't thank you enough for that! I'll be always praying for all your projects!!

---

---





---

---

# Special Thanks to...

Hugo and Hilde De Clerck,

An inovated tool for Orthodontics was born from your passion and fearless engagement to Orthodontics. A promising orthopedic treatment to help young patients find a new perspective in life.

I can't thank you enough for trusting me the present and future years of this research. I'm very grateful and honored to be part of this amazing group of brilliant minds!

---

---



---

---

# Agradeço...

AOS PROFESSORES DE ORTODONTIA DA FACULDADE DE  
ODONTOLOGIA DE BAURU

**Prof. Dr. Arnaldo Pinzan**

**Prof. Dr. José Fernando Castanha Henriques**

**Prof. Marcos Roberto de Freitas**

**Prof. Dr. Renato Rodrigues de Almeida**

Pelos ensinamentos transmitidos, gentileza e cordialidade sempre presentes. Admiro a paixão pela Ortodontia que demonstram, mas acima de tudo, o carinho e zelo que demonstram pelas suas famílias.

ESPECIALMENTE AO PROF. DR. GUILHERME JANSON

*"O saber a gente aprende com os mestres e os livros.*

*A sabedoria, se aprende é com a vida..."*

*Cora Coralina*

Por tantas vezes, e de inúmeras formas, você não foi só o mestre que ensinou, mas também a pessoa que me instiga a buscar ser sempre melhor. É também a pessoa que mostra que a vida nem sempre será um mar de rosas...

---

---



---

---

# Agradeço...

Às amigadas que o Berçário Leite & Amor uniu. **Dudu, Rafinha, Fran & Rafa, Bebeth, Carina & Khalil, Gui, Léo, Bella & Kiyoshi, Marina, Dani & Heitor, Pedro, Ana & Gustavo.** O carinho que os une é puro, verdadeiro, sólido e lindo! E eu agradeço por compartilharmos momentos de alegrias e orgulho dos nossos pequenos, dúvidas e experiências em relação ao crescimento e desenvolvimento deles.

Aos colegas de Pós Graduação da FOB e do HRAC pela convivência respeitosa e amigável. Agradeço especialmente às amigas **Carol Menezes, Cintia Junqueira, Larissa Bressane, Louise Calil, Lucas Mendes, Patrícia Bittencourt, Suelen Costa.** Agradeço pelos conselhos, conhecimentos e momentos de tristeza e felicidade compartilhados. Resumindo, agradeço pela preciosa **amizade** de cada um.

Aos residentes, funcionários do agendamento, Radiologia, Setor Odontológico, documentação, recepção e docentes do Centrinho, especialmente à **Thais Silva, Sabrina, Claudia, Denise e Solange,** por não medirem esforços para me ajudar sempre.

Aos funcionários da Disciplina de Ortodontia da FOB-USP pelo respeito e prontidão com que sempre me receberam. **Wagner,** pela disponibilidade sempre que precisei. **Sérgio,** por compartilhar seus conhecimentos e técnicas ortodônticas. **Vera,** obrigada pela solicitude e amizade de sempre. **Cléo,** agradeço imensamente pelo carinho com que sempre me acolheu, pelas conversas e por alegrar meus dias nublados... **Bonné,** pelo bom humor e perseverança demonstrados sempre! Obrigada pela paciência até o último segundo, e por fazer possível o que eu acreditava ser impossível!

Aos pacientes da pesquisa e seus familiares. Por acreditarem no nosso trabalho e esforço. Pela colaboração e por ajudarem a tornar realidade a conclusão deste projeto. A vocês, meus sinceros agradecimentos.

À Faculdade de Odontologia de Bauru – Universidade de São Paulo, na pessoa da Diretora Profa. Dra. Maria Aparecida de Andrade Moreira Machado e do Vice-Diretor Prof. Dr. Carlos Ferreira dos Santos.

À FAPESP, pela concessão das bolsas de estudos.

À todos que contribuíram e contribuem para a realização desta pesquisa.

---

---



---

---

## ABSTRACT

### **Three-dimensional assessment of maxillary protraction with miniplates in patients with cleft lip and palate**

The aim of this study was to assess maxillary, mandibular and glenoid fossa changes after bone anchored maxillary protraction (BAMP) therapy in patients with unilateral complete cleft lip and palate (UCLP). Methods: The experimental group comprised 24 patients with UCLP and maxillary sagittal deficiency with a mean initial age of 11.8 years. Cone-beam computed tomography (CBCT) exams of 24 patients with UCLP taken before (T1) and 18 months (T2) after beginning BAMP therapy were selected from the files of the Hospital of Rehabilitation of Craniofacial Anomalies. CBCTs were superimposed at the cranial base. Three-dimensional displacements of landmarks placed in surface models were quantified and visualized in color-coded maps and semi-transparency superimpositions. Kolmogorov-smirnov test was used to calculate distribution of normality. Paired *t* test was used to compare cleft and non-cleft sides ( $p < 0.05$ ). Results: A point and non-cleft central incisor displaced toward anterior (1.66mm), inferior (1.21mm) and to the cleft side. Orbitale, Infraorbitale foramen and maxillary first permanent molar displaced similarly toward anterior, inferior and medial direction. The zygoma displaced similarly toward anterior and inferior, however the cleft side showed a significantly greater lateral displacement compared to the non-cleft side. The superior concavity of the glenoid fossa showed symmetrical displacement toward anterior, lateral and superior, while the anterior and posterior eminences showed symmetrical displacements toward anterior, lateral and inferior. The mandible showed an overall symmetrical inferior and posterior displacement except for the medial pole of the condyle, which showed a significantly greater lateral displacement on the cleft side. Conclusions: Maxilla showed an anterior and inferior displacement. The glenoid fossa and the overall mandible symmetrically displaced downward and backward. The zygoma of the cleft side was the only maxillary landmark to show significantly greater lateral displacement than the non-cleft side, as well as the medial pole of the condyle on the cleft side.

**Keywords:** Cleft lip, Cleft palate, Orthodontic Anchorage Procedure, Angle Class III

---

---





---

---

## RESUMO

O objetivo deste trabalho foi avaliar as alterações da maxila, mandíbula e fossa glenóide após o tratamento com protração maxilar ancorada em osso (BAMP) em pacientes com fissura unilateral completa de lábio e palato (UCLP). Métodos: o grupo experimental foi composto por 24 pacientes com UCLP e deficiência sagital de maxila com idade inicial de 11,8 anos. Foram selecionados exames de tomografia computadorizada de feixe cônico (CBCT) de 24 pacientes com fissura UCLP realizadas antes e após 18 meses de terapia com BAMP pertencentes ao Hospital de Reabilitação de Anomalias Craniofaciais. Os exames de CBCT foram sobrepostos pela base do crânio. Deslocamentos tridimensionais foram mensurados por meio de pontos colocados em modelos de superfície, bem como foram visualizados em mapas coloridos e sobreposições de semi-transparência. A distribuição de normalidade foi calculada por meio do teste de Kolmogorov-Smirnov. A comparação entre os lados com e sem fissura foi realizada por meio do teste *t* pareado ( $p < 0.05$ ). Resultados: O ponto A e o incisivo central superior do lado sem fissura deslocaram para anterior (1.66mm), inferior (1.21mm) e para o lado da fissura. Os pontos Orbitário, Forame Infra-orbitário e os primeiros molares permanentes superiores se deslocaram simetricamente para anterior, inferior e medial. O ponto Zigomático deslocou simetricamente para anterior e inferior, porém o lado da fissura apresentou um deslocamento significativamente maior para lateral comparado ao lado sem fissura. A concavidade superior da fossa glenóide apresentou um deslocamento simétrico para anterior, lateral e superior. As eminências anterior e posterior da fossa glenóide apresentaram um deslocamento simétrico para anterior, lateral e inferior. No geral, não houve diferença estatisticamente significante entre os lados com e sem fissura para o deslocamento inferior e posterior da mandíbula. O polo medial do côndilo foi o único ponto em que o lado da fissura apresentou um deslocamento significativamente maior para lateral quando comparado ao lado sem fissura. Conclusões: A maxila mostrou um deslocamento simétrico para anterior e inferior. A fossa glenóide e a mandíbula mostraram um deslocamento simétrico para inferior e para trás. Entretanto, os pontos zigomático e polo medial apresentaram um deslocamento lateral significativamente maior no lado da fissura.

**Palavras-chave:** Fissura de lábio. Fissura de palato. Procedimento de ancoragem ortodôntica. Classe III de Angle.

---

---



---

---

## TABLE OF CONTENT

|            |   |           |
|------------|---|-----------|
| <b>1</b>   | <b>INTRODUCTION .....</b>   | <b>13</b> |
| <b>2</b>   | <b>ARTICLES.....</b>  | <b>19</b> |
| <b>2.1</b> | <b>ARTICLE 1: BAMP therapy in unilateral complete cleft lip and palate:<br/>a 3D assessment of the maxillary effects.....</b> | <b>21</b> |
| <b>2.2</b> | <b>ARTICLE 2: Mandibular and glenoid fossa changes after BAMP<br/>therapy in UCLP: 3D assessment.....</b>                     | <b>40</b> |
| <b>3</b>   | <b>DISCUSSION.....</b>  | <b>63</b> |
| <b>4</b>   | <b>CONCLUSION.....</b>  | <b>67</b> |
|            | <b>REFERENCES .....</b>   | <b>71</b> |
|            | <b>ANNEX .....</b>  | <b>77</b> |

---

---



# **1 INTRODUCTION**

---

---



## 1 INTRODUCTION

The face of an individual with unilateral complete cleft lip and palate (UCLP) is often characterized by a short and retrusive maxilla, a vertical elongation of the anterior face, and a retrusive mandible.(1) There is also a reduction in the posterior face height and a slight increase in cranial base angulation and interocular distance.(1) In non-operated patients with UCLP the maxillary growth is similar. The length of the maxilla seems to be shorter, but the sagittal growth may not be compromised, the vertical direction of maxillary growth seems to be similar to non-cleft patients, and the width of the maxilla would be increased, if it weren't for the muscle's function that seems to collapse the segments during growth.(2)

After primary surgeries, the maxillary growth is believed to be altered. Some authors suggest that even though there might be an intrinsic maxillary retrusion,(3-6) the primary surgeries influence its growth and displacement.(7-11) When compared the changes after lip repair versus lip and palate repair, it is known that the morphology and position of the mandible, and growth direction of the maxilla and mandible are similar, but there was a significant retrusion of the basal bones and the anterior dentoalveolar region of the maxilla in patients who had only lip repair.(12) There is a hypothesis that the major disturbance in craniofacial growth of patients with UCLP is attributable to palatal surgery.(8, 13, 14) It is suggested that the scar tissue adjacent to the vomero-premaxillary suture affects the basal maxilla. The role of this suture is still unknown, but the interference of this suture can alter the anteroposterior (A-P) maxillary position.(15)

Patients with UCLP operated show a different growth pattern, with smaller linear measurements when compared to non-cleft patients: a more obtuse cranial base angle, the length of the maxilla is smaller, SNA is significantly smaller and tends to decrease overtime, maxillary anterior height (N-ENA) is smaller, maxillary incisors were more lingually inclined, mandible retropositioned, shorter rami, more obtuse gonial angle, more obtuse SN•mandibular plane, smaller SNB, and greater lower and total anterior facial height.(16-19) These characteristics are more marked in patients with cleft lip and palate or cleft palate.(19) The comparison among different types of

---

---

cleft (lip, lip and palate or palate) did not show significant differences for mandibular growth and morphology, in other words, the primary plastic surgeries do not influence the mandible in patients with clefts.(20)

The small mandibular changes are believed to be related to muscle's function. Frequent airway infections and nasal septum deviation lead to mouth breathing and a habitual open mouth position. These characteristics, associated to an atresic maxilla result in a collapse of the tongue. This different mandibular position can induce a bone remodeling in the Gonion region to avoid the muscular stretch.(21)

Long-term studies showed that compared to non-cleft patients, the lip surgery influence growth: patients with UCLP show a smaller maxillary protrusion at alveolar level; lingual inclination of the maxillary incisors; smaller overjet; greater inclination of the palatal plane; greater overbite; similar maxillary length; similar mandibular size, shape and position; similar AP jaw relation; similar position of upper incisors apex; similar position of mandibular incisors.(15) Meanwhile, the palate surgery show different influences: smaller maxillary length at basal and alveolar level; smaller maxillary protrusion at basal and alveolar level; worst AP jaw relation at the basal and alveolar level; smaller overjet.(22)

The maxillary deficiency in patients with UCLP often leads to a posterior crossbite, a collapse of the segments of the maxilla and different magnitude of Class III malocclusions. The orthodontic treatment starts with a rapid maxillary expansion to correct the transversal discrepancy. To mild sagittal discrepancies, the most common approach is the face mask. It is a consensus in the literature that this therapy results in a forward movement of the maxilla (increase ANB angle and Wits), counterclockwise (CCW) rotation of the palatal and occlusal plane, a proclination of the maxillary incisors, a downward and backward rotation of the mandible, increase of the lower facial height, extrusion of mandibular incisors.(23-28) In moderate to severe cases, the most common option is the comprehensive orthodontic treatment combined to the orthognathic surgery.

Recently, a new method to treat Class III malocclusion has shown promising results in patients without clefts: the Bone anchored maxillary protraction (BAMP). Two miniplates are placed in the infrazygomatic region of the maxilla, and two

---

---



miniplates are placed between mandibular permanent lateral incisor and canine. After 1 month, intermaxillary elastics with 150g of force are placed in each side. The forces increase monthly until it reaches 250g per side in the third month.(29, 30) Cephalometric results showed a marked anterior displacement of the maxilla, a marked improvement of the Wits appraisal, a small increase of the mandibular length, posterior displacement of the mandible, a closure of the gonial angle, an improvement of overbite and overjet, and a remodeling of the glenoid fossa at the anterior eminence, and a bone resorption at the posterior wall.(29-31) The color-coded maps showed the individual variability in the response to the therapy.(32)

With the success of this new therapy, a doubt of the effects on patients with cleft arises. The hypothesis is that the BAMP therapy would show significant effects in patients with UCLP. The benefits for these patients would be significant, by improving the maxillo-mandibular discrepancy, the soft tissue profile, and additionally, the orthognathic surgery could be avoided. Therefore, the purpose of this study was to assess the changes in the maxilla, mandible and glenoid fossa after BAMP therapy in patients with unilateral complete cleft lip and palate.



**2 ARTICLES**

---

---



## 2 ARTICLES

The article(s) presented in this Thesis were written according to the American Journal of Orthodontics and Dentofacial Orthopedics instructions and guidelines for article submission

- ARTICLE 1 – BAMP therapy in unilateral complete cleft lip and palate: a 3D assessment of the maxillary effects
- ARTICLE 2 – Mandibular and glenoid fossa changes after BAMP therapy in patients with UCLP: 3D assessment

### 2.1 Article 1

#### **BAMP therapy in unilateral complete cleft lip and palate: a 3D assessment of the maxillary effects**

##### **Abstract**

**Introduction:** The aim of this study was to three-dimensionally assess the treatment outcomes of bone anchored maxillary protraction (BAMP) in patients with unilateral cleft lip and palate (UCLP). **Methods:** The experimental group (CG) comprised 24 patients with UCLP and maxillary sagittal deficiency with a mean initial age of 11.8 years. The comparison group (NCG) was composed by 24 non-cleft Class III patients with a mean initial age of 11.7 years. Cone-beam computed tomography (CBCT) were performed before and after BAMP therapy in both groups and superimposed at the cranial base. Three-dimensional displacements of maxillary landmarks were quantified and visualized with color-coded maps and semi-transparent superimpositions. *T* test corrected for multiple testing (Holm-Bonferroni method) and paired *t* test were used to compare the cleft and non-cleft groups, and cleft side

---

versus non-cleft sides, respectively ( $p < 0.05$ ). **Results:** Maxillary protraction showed an anterior (1.66mm) and inferior displacement (1.21mm) of the A point in the experimental group with no differences compared to the NCG group. Maxillary first molars of the cleft group showed significantly greater medial displacement than the non-cleft group. The only variable that showed significant difference between cleft and non-cleft sides was the zygoma that showed a greater lateral displacement at the cleft side. **Conclusion:** BAMP caused a marked amount of maxillary protraction in patients with UCLP with discrete differences between the cleft and non-cleft sides. Maxillary displacements in UCLP were similar compared with those observed in non-cleft individuals.

**Keywords:** Cleft lip, Cleft palate, Orthodontic Anchorage Procedure, Angle Class III

## Introduction

In patients with complete cleft lip and palate, maxillary growth is often compromised by the restrictive forces from the lip and palate repair.<sup>1</sup> In unoperated patients with unilateral complete cleft lip and palate (UCLP) the maxilla is intrinsically retruded.<sup>2</sup> Such maxillary retrusion is often more severe in operated patients, where the maxillary antero-posterior position decreases in average 5.4 degrees from 5 to 18 years.<sup>3</sup> As a result, patients with cleft lip and palate often show a concave facial pattern associated to a Class III malocclusion. The Goslon Yardstick is a 'reliable, robust and simple mean' to assess dental arch relationship for patients with unilateral cleft lip and palate.<sup>4</sup> Ranging from 1-5, Scores 1 and 2 represent respectively excellent and good dental arch relationships and require simple or no orthodontic treatment; score 3 describes a fair dental relationship and requires a little more complex orthodontic treatment, such as maxillary expansion and protraction to compensate the sagittal and transversal discrepancies; and scores 4 and 5 show very poor dental arch relationship, and often need orthognathic surgery correction.<sup>1</sup> An intercenter study showed that between 6 and 12 years of age, approximately 35% of the patients are classified as Goslon 3, 30% as Goslon 4 and only 6% as Goslon 5.<sup>4</sup>

For decades, the most common therapy for maxillary deficiency in patients with complete cleft lip and palate with mild discrepancy consisted of rapid maxillary

---

expansion with a tooth-borne appliance connected to a face mask to attempt to pull the maxilla forward. Over the last decade, new treatment protocols have been proposed aiming to control dental compensations and increase the amount of skeletal maxillary protraction with face mask.<sup>5</sup> Bone anchorage has also been used to substitute conventional dental anchorage for maxillary protraction with face mask in patients with clefts.<sup>6</sup>

Recent studies have shown marked skeletal changes after bone anchored maxillary protraction (BAMP) in Class III patients without CLP.<sup>7</sup> Therefore, the purpose of this study was to three-dimensionally assess maxillary changes with BAMP therapy in patients with unilateral complete cleft lip and palate. The null hypothesis is that no differences are observed for maxillary outcomes in patients with UCLP and non-cleft individuals.

## **Material and Methods**

Institutional research ethics committee was obtained by the University \_\_\_\_\_. The sample size calculation was based on preliminary statistics including the first 10 patients of the experimental group. For a standard deviation of 1.49mm and a minimal intergroup difference of 1.5mm to be detected, a sample of 17 patients was required to provide statistical power of 80% with an alpha of 0.05.

The Cleft Group (CG) consisted of 24 patients with unilateral complete cleft lip and palate and maxillary sagittal deficiency, treated consecutively at the Hospital \_\_\_\_\_, University \_\_\_\_\_. The CG was prospectively treated and the inclusion criteria were ages between 10 and 13 years old; clinical presence of the mandibular permanent canines; patients who underwent secondary alveolar bone graft for at least 3 months; Goslon Index varying from 3-5. The exclusion criteria were: patients with syndromes and bad oral hygiene before placing the miniplates. The comparison Non-Cleft Group (NCG) consisted of secondary data analysis<sup>8</sup> of 25 Class III non-cleft patients, treated consecutively in a private practice. The samples are described in Table I. Bone anchored maxillary protraction following the same protocol<sup>7</sup> was performed in both groups. CBCT exams were obtained before (T1) and after treatment (T2) with an interval of 18 and 12 months for CG and NCG, respectively. In the Cleft Group, two patients were lost during the follow-up because of treatment

---

interruption; one patient was excluded due to maxillary miniplate instability and recurrent bad oral hygiene; and one patient was excluded due to movement artifacts during the CBCT exam. The study sample consisted then of 20 patients in the CG group. One patient was excluded from NCG group for missing CBCT data.

Three-dimensional surface models were created from the DICOM files in 6 steps:

1. *Create a volumetric label map:* using ITK-SNAP 2.4.0,<sup>9</sup> an open-source software ([www.itksnap.org](http://www.itksnap.org)), the cranial base and maxilla were segmented for T1 and T2 scans.
  2. *Create a virtual 3D surface model:* using 3D Slicer 4.4 ([www.slicer.org](http://www.slicer.org)), another open-source software, the virtual 3D surface models were created from the T1 and T2 volumetric label maps.
  3. *Head Orientation:* Slicer Software displays a 3D coordinate system that was kept fixed to be used as reference to consistently orient the 3D models of all patients. Using axial, coronal and sagittal views of the 3D models, the T1 model was moved to match the midsagittal plane (defined by glabella, crista galli and basion) vertically and coincident to the sagittal plane of the 3D coordinate system. The Frankfurt horizontal plane was oriented to match the axial plane. And the horizontal infra-orbitale (most inferior point of the left and right orbita) line was oriented to be coincident to the coronal plane.<sup>10</sup>
  4. *3D cranial base superimposition:* the 3D superimposition registered in the cranial base was performed in two steps: a) using 3D Slicer 4.4, the T2 scan was manually approximated to the T1 oriented scan. b) using the anterior cranial fossa label map as a best fit reference, a fully automated voxel-based registration was performed in 3D Slicer 4.4.<sup>11</sup> The matrix generated from the registration of T2 over T1 was applied to the T2 scan, volumetric label map and 3D surface model also in 3D Slicer 4.4.
  5. *Landmarks identification:* Landmarks were placed at T1 and T2 surface models using the Q3DC tool in the 3D Slicer 4.4 software as shown in Table II and Figure 1.
  6. *Quantitative measurements:* 3D linear distances and the amount of directional changes in each plane of the 3D space (x,y,z, respectively mediolateral, antero-posterior and superior-inferior axes) were measured
-



between corresponding coordinates of landmarks placed in the T1 and registered T2 surface models. Anterior, inferior and lateral displacements were considered positive values; and posterior, superior and medial displacements were considered as negative values.

Color-coded surface distance maps and semi-transparent superimpositions were used to visually demonstrate the overall maxillary changes in CG group.

### **Statistical analyses**

Intraclass correlation coefficient (ICC) with a confidence level of 95% was performed in 10 patients randomly selected from both group to assess the reproducibility of the X, Y and Z coordinates of the landmarks placed in T1 and T2.

The statistical analysis was performed with SPSS Statistical Software Package (Version 21.0; SPSS, Chicago, IL). All variables showed normal distribution using Kolmogorov-Smirnov test. Intergroup comparisons were performed with independent t tests corrected for multiple testing (Holm-Bonferroni method). The comparison between cleft (CS) and non-cleft sides (NCS) was performed using dependent t tests. The level of significance was set at 0.05.

### **Results**

A very good intra-examiner agreement was observed. The ICC result for each variable is displaced in Table III.

The mean values, standard deviation and the statistical comparisons between the CG and NCG can be found in Tables IV and V. Significant difference was found between the CG and NCG groups only for the U6: CG showed a medial displacement, while the NCG group showed a lateral displacement. (Table IV)

Regarding the symmetry of the maxillary displacement within the Cleft Group, the only difference found was the medial-lateral and superior-inferior displacements of the Zygomatic points (Table V). Figure 2 illustrates the slight asymmetry in maxillary anterior displacement in CG group.

---

Closest-point color-coded surface distance maps and semi-transparent superimpositions of CG group are shown in Figures 3 and 4.

## **Discussion**

Maxillary protraction therapy in patients with cleft lip and palate has been an important topic of discussion because it is minimally invasive procedure designed to decrease skeletal discrepancies in these patients. Many studies have reported the short-term maxillary growth response to facemask therapy using 2D lateral cephalometric measurements.<sup>12</sup> However, 2D lateral images can only show the changes in an antero-posterior or superior-inferior direction, as a 2D projection of a 3D structure: they cannot evaluate transverse changes or detect subtle differences between the greater and lesser segments of a cleft. With a three-dimensional tool in this study, it is possible to visualize and measure 3D linear distances and the directional changes in their X, Y, Z components, and compare the symmetry between sides. Landmark-based measurements have been validated as an accurate and reliable method in 3D studies.<sup>13</sup>

This is the first study to assess three-dimensional outcomes of bone anchored maxillary protraction using only intermaxillary elastics in patients with oral clefts. This study included a comparison group of consecutively treated non-cleft Class III malocclusion patients, treated with the same protocol. The effects of the maxillary protraction with BAMP therapy in non-cleft patients have been previously described in the literature.<sup>7</sup>

The U6 displaced medially in the CG, while it had displaced laterally in the NCG. (Table IV) Two factors might be associated to this medial displacement: the palatal defect still remains, and/or relapse of the maxillary expansion prior to alveolar bone graft in CG. The mean 3D displacement of the U6 showed similar displacements, which are also comparable with previous 2D studies.<sup>12</sup>

Midsagittal changes (A and U1) were in general similar between CG and NCG. (Table III) Even though not statistically significant, the upper incisors in the CG tended to adapt to the new bone formed in the alveolar graft area: the cleft-side incisor that was counter-angulated prior to the graft assumed a more vertical position during treatment, and the teeth tended to drift slightly towards the grafted area. In

---

addition, the amount of U1 anterior displacement in this study was within the range observed in the literature on maxillary orthopedic protraction.<sup>5</sup>

The overall treatment results were similar when the cleft side was compared to the non-cleft side at Orb, IOF and U6 landmarks in the 3D and every directional displacement, which was expected since a successful bone graft surgery was performed prior to the protraction therapy. (Table V) The lateral displacement of the Zyg on the CS showed a significant greater lateral displacement when compared to the NCS, which could be related to the fragility of the cleft segment. Even though the bone graft surgery was performed at the alveolar region, the defect originated from the cleft might have affected, in smaller proportions, other bone structures, and therefore the cleft segment was more exposed to the lateral force of growth associated to the elastics.<sup>14</sup> (Table V)

Even though few significant differences were found, a high level of individual variation was observed for maxillary outcomes in patients with UCLP, as can be seen in the closest point color-coded maps (Figure 4) and semi-transparent superimpositions of CG group shown in Figure 3. These results corroborate previous studies of maxillary protraction.<sup>5,15</sup> The main limitation of this study was the absence of a non-treated control group with UCLP, which was not feasible for ethical reasons. Considering that maxilla protrusion decreases over growth in patients with UCLP,<sup>3</sup> maxillary protraction might have been underestimated in this study.

Future studies should verify the long-term stability of growth changes. Additionally, the influence of growth pattern, type of cleft and skeletal maturation on BAMP outcomes should be tested.

## **Conclusion**

The BAMP therapy produced a marked and symmetrical protraction of maxillary upper and lower regions similarly to patients without oral clefts. This therapy may improve facial esthetic and increase self-esteem during adolescence, favoring a compensatory comprehensive orthodontic treatment.

The authors would like to thank Drs. Leonardo Gregorio, Liliane Gomes and Bernardo Souki for their assistance in patient care and data analysis; and FAPESP

---

(São Paulo Research Foundation / nº 2013/17596-3, 2013/19880-0 and 2014/11206-1) for the financial support.

## References

1. Mars M, Houston WJ. A preliminary study of facial growth and morphology in unoperated male unilateral cleft lip and palate subjects over 13 years of age. *Cleft Palate J* 1990;27(1):7-10.
  2. Graber TM. A Cephalometric Analysis of the Developmental Pattern and Facial Morphology in Cleft Palate\*. *The Angle Orthodontist* 1949;19(2):91-100.
  3. Semb G. A study of facial growth in patients with unilateral cleft lip and palate treated by the Oslo CLP Team. *Cleft Palate Craniofac J* 1991;28(1):1-21; discussion 46-8.
  4. Hathaway R, Daskalogiannakis J, Mercado A, et al. The Americleft study: an inter-center study of treatment outcomes for patients with unilateral cleft lip and palate part 2. Dental arch relationships. *Cleft Palate Craniofac J* 2011;48(3):244-51.
  5. Liou EJ, Tsai WC. A new protocol for maxillary protraction in cleft patients: repetitive weekly protocol of alternate rapid maxillary expansions and constrictions. *Cleft Palate Craniofac J* 2005;42(2):121-7.
  6. Baek SH, Kim KW, Choi JY. New treatment modality for maxillary hypoplasia in cleft patients. Protraction facemask with miniplate anchorage. *Angle Orthod* 2010;80(4):783-91.
  7. De Clerck HJ, Cornelis MA, Cevidanes LH, Heymann GC, Tulloch CJ. Orthopedic traction of the maxilla with miniplates: a new perspective for treatment of midface deficiency. *J Oral Maxillofac Surg* 2009;67(10):2123-9.
  8. Nguyen T, Cevidanes L, Cornelis MA, et al. Three-dimensional assessment of maxillary changes associated with bone anchored maxillary protraction. *Am J Orthod Dentofacial Orthop* 2011;140(6):790-8.
  9. Yushkevich PA, Piven J, Hazlett HC, et al. User-guided 3D active contour segmentation of anatomical structures: significantly improved efficiency and reliability. *Neuroimage* 2006;31(3):1116-28.
- 
-

10. Ruellas AC, Tonello C, Gomes L, et al. Common 3D Coordinate System for Assessments of Directional Changes. *American Journal of Orthodontics Dentofacial Orthopedics* 2016(ahead of print).
  11. Cevidanes LH, Styner MA, Proffit WR. Image analysis and superimposition of 3-dimensional cone-beam computed tomography models. *Am J Orthod Dentofacial Orthop* 2006;129(5):611-8.
  12. da Luz Vieira G, de Menezes LM, de Lima EMS, Rizzatto S. Dentoskeletal effects of maxillary protraction in cleft patients with repetitive weekly protocol of alternate rapid maxillary expansions and constrictions. *The Cleft Palate-Craniofacial Journal* 2009;46(4):391-98.
  13. Fourie Z, Damstra J, Gerrits PO, Ren Y. Accuracy and repeatability of anthropometric facial measurements using cone beam computed tomography. *Cleft Palate Craniofac J* 2011;48(5):623-30.
  14. Ewings EL, Carstens MH. Neuroembryology and functional anatomy of craniofacial clefts. *Indian J Plast Surg* 2009;42 Suppl:S19-34.
  15. De Clerck H, Cevidanes L, Baccetti T. Dentofacial effects of bone-anchored maxillary protraction: a controlled study of consecutively treated Class III patients. *Am J Orthod Dentofacial Orthop* 2010;138(5):577-81.
- 
-

## Figure Legends

Figure 1 - Landmarks placed in the 3D surface model: 1) the A point (A), 2) center of the central incisor on the non-cleft side, or the right central incisor of the NCg (U1), 3 and 4) right and left Infra-Orbital point (Or), 5 and 6) right and left infra-orbital foramen (IOF), 7 and 8) right and left inferior point of the zygomatic bone (Zyg), 9 and 10) mesial buccal cuspid of the first permanent molar on the right and left side (U6).

Figure 2 - Semi-transparency superimposition of the T1 (red) and T2 (white) 3D surface models in an superior view, cropped at the level of the ANS. From left to right, corresponds to the most discrete to the best outcome.

Figure 3 - Semi-transparency superimposition of the T1 (red) and T2 (white) 3D surface models in a lateral view.

Figure 4 -Colormap images of the anterior-posterior changes (Y-component) between T1 and T2 in an anterior view for both samples. In shades of red, the anterior displacement, in shades of green, no displacements, and in shades of blue, posterior displacement (range of -5mm to +5mm).

---

---

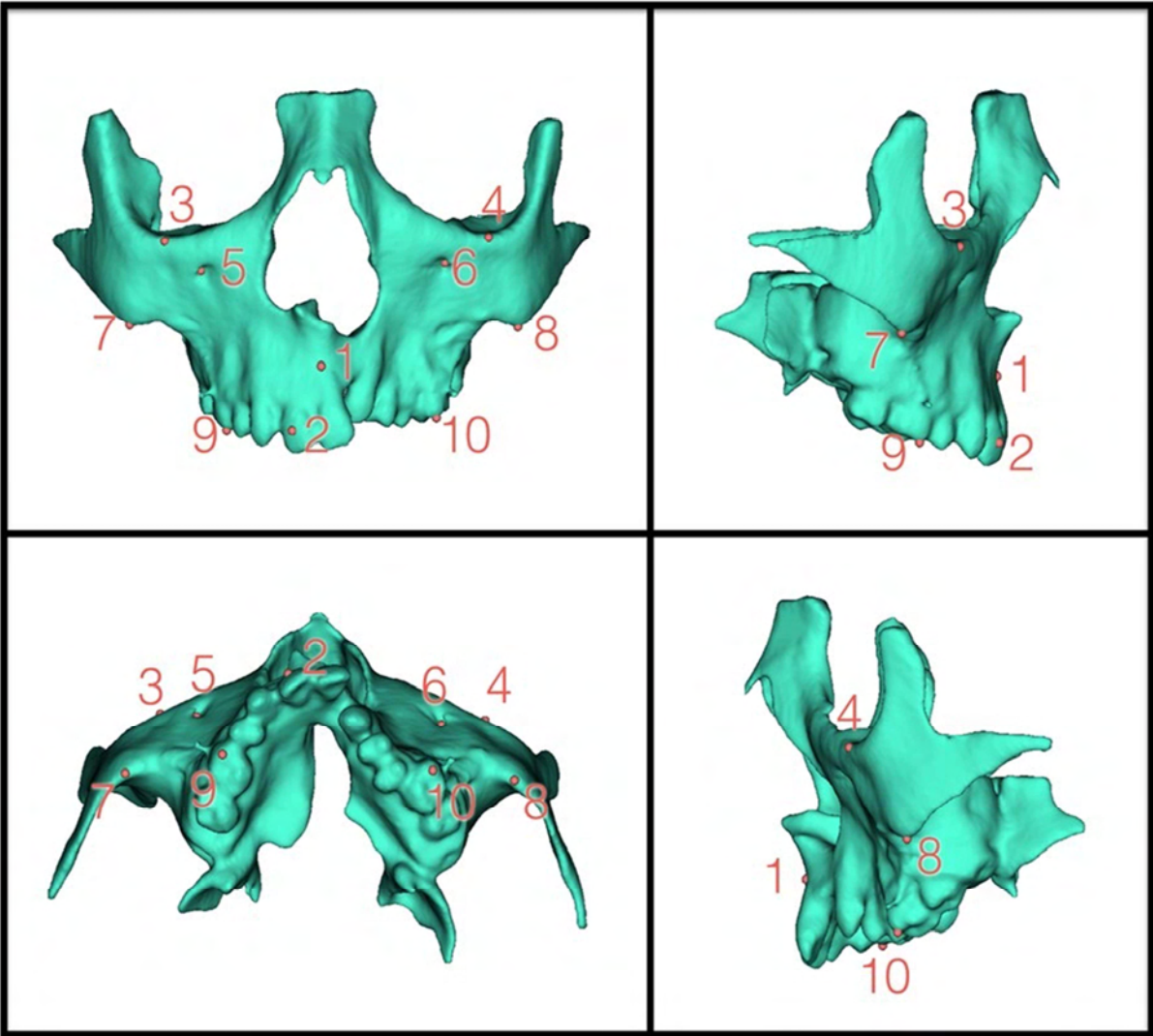


Figure 1




Figure 2



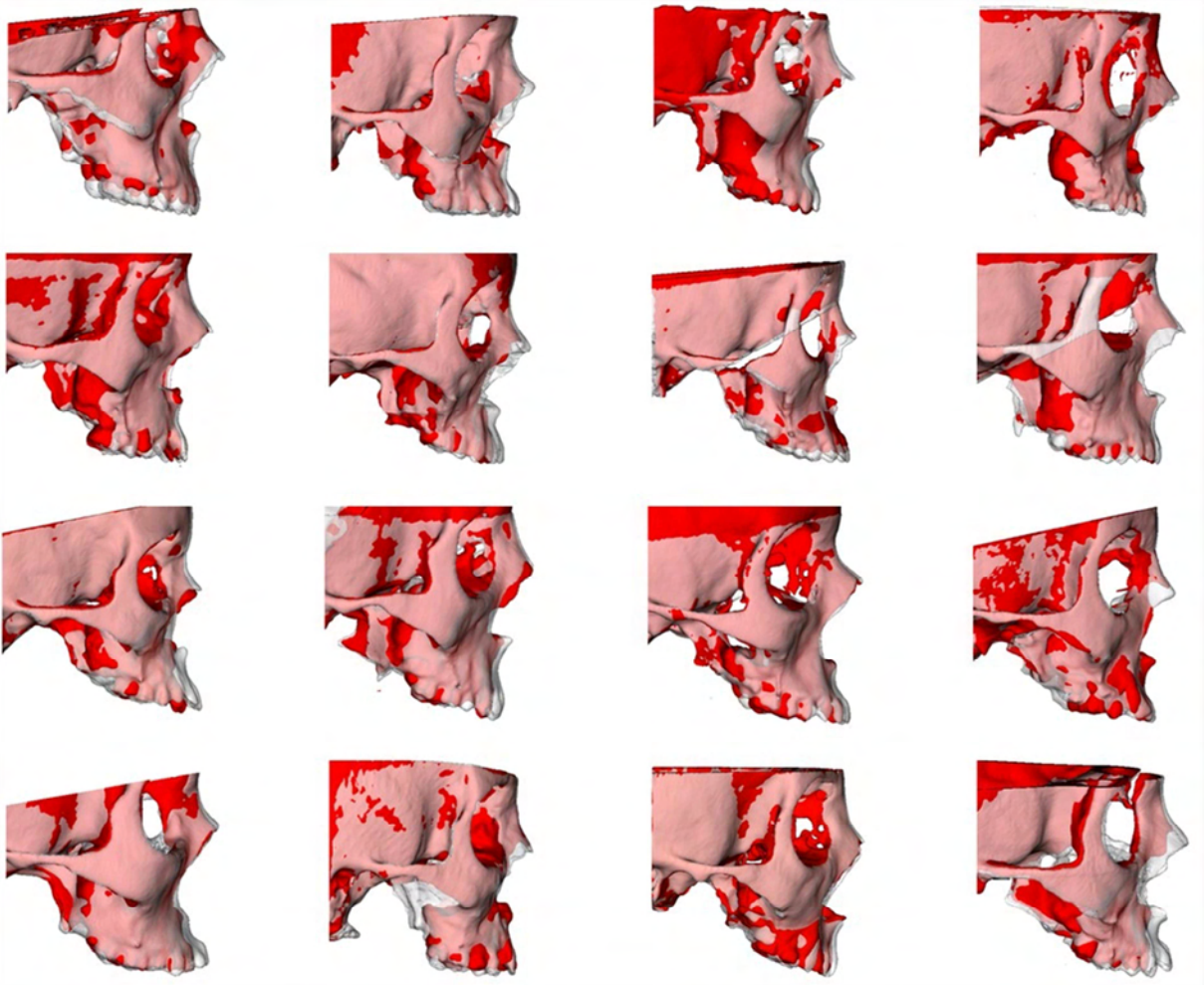


Figure 3

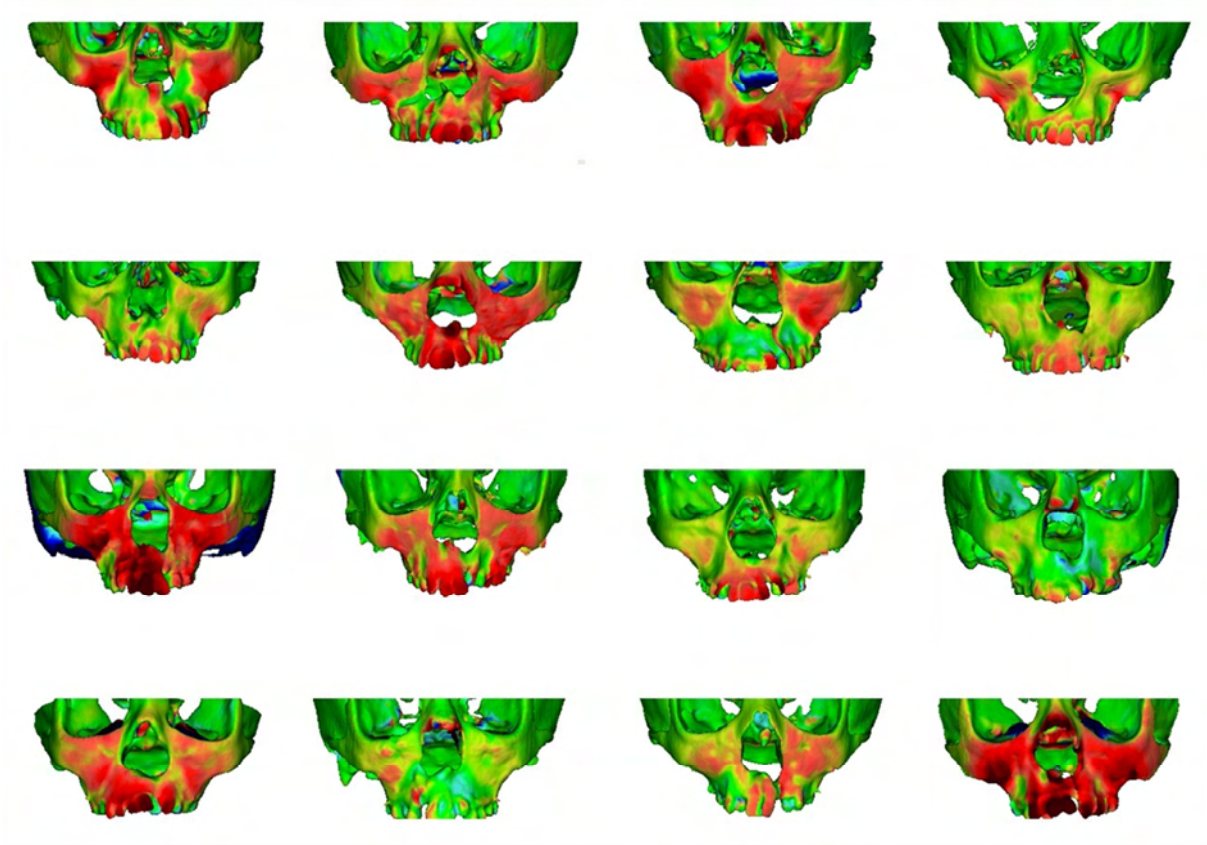


Figure 4

Table 1 - Intraexaminer results from ICC test.

|              | X    | Y    | Z    | 3D   |
|--------------|------|------|------|------|
| <b>U1</b>    | 0.97 | 1.00 | 0.77 | 0.95 |
| <b>A</b>     | 0.80 | 0.96 | 0.98 | 0.94 |
| <b>Or.R</b>  | 0.99 | 0.87 | 0.79 | 0.82 |
| <b>Or.L</b>  | 0.86 | 0.82 | 0.91 | 0.83 |
| <b>IOF R</b> | 0.87 | 0.92 | 0.83 | 0.95 |
| <b>IOF L</b> | 0.90 | 0.85 | 0.93 | 0.89 |
| <b>Zyg.R</b> | 0.76 | 0.87 | 0.94 | 0.84 |
| <b>Zyg.L</b> | 0.78 | 0.83 | 0.96 | 0.89 |
| <b>U6R</b>   | 0.92 | 0.89 | 0.96 | 0.97 |
| <b>U6L</b>   | 0.91 | 0.94 | 0.86 | 0.92 |

Table 2 - Sample description.

|                              | n   | sex                  | mean age at T1 CBCT exam     | Wits appraisal (mean (SD)) |
|------------------------------|---|----------------------|------------------------------|----------------------------|
| <b>Cleft Group (CG)</b>      | 24 (6 with cleft in the Right and 18 with cleft in the Left side) | 17 boys and 7 girls  | 11.8 years ( $\pm$ 9months)  | -7.13 (3.13)               |
| <b>Non-Cleft Group (NCG)</b> | 24  | 10 boys and 15 girls | 11.9 years ( $\pm$ 14months) | -4.8 (2.8)                 |

---

---

Table 3 - Description of the landmarks identification.

|   |  |
|---|--|
| <b>Central Incisor (U1)</b>                 | landmark placed at the center of the clinical crown of the non cleft side maxillary central incisor (CG group) or the right central incisor (NCG group).                                       |
| <b>A Point (A)</b>                          | landmark placed at the most posterior point of the concavity of the anterior region of the maxilla, as in the cephalometric analysis. The landmark should be seen in both left and right view. |
| <b>Orbitale (Or)</b>                        | landmarks placed at the most inferior point of the left and right orbita.  |
| <b>Infraorbitale Foramen (IOF)</b>          | landmarks placed at the entrance of the right and left infraorbital foramen.   |
| <b>Zygomatic</b>                            | landmarks placed in the most inferior portion of the inferior border of the right and left zygomatic bones.  |
| <b>Maxillary First Permanent Molar (U6)</b> | landmarks placed at the buccal-mesial occlusal cusp of the right and left first permanent molar.   |

Table 4 - Descriptive and statistical analyses of the comparison between CG x NCG.

| Landmarks             | Medial-lateral plane (X) |              | Anteroposterior plane (Y) |             | Superior-inferior plane (Z) |             | Total linear displacement |             |
|-----------------------|--------------------------|--------------|---------------------------|-------------|-----------------------------|-------------|---------------------------|-------------|
|                       | CG Group                 | NCG Group    | CG Group                  | NCG Group   | CG Group                    | NCG Group   | CG Group                  | NCG Group   |
|                       | Mean (SD)                | Mean (SD)    | Mean (SD)                 | Mean (SD)   | Mean (SD)                   | Mean (SD)   | Mean (SD)                 | Mean (SD)   |
| Central Incisors      | -0.48 (1.50)             | -0.28 (1.10) | 2.98 (2.11)               | 3.50 (2.18) | 0.84 (1.52)                 | 1.76 (1.32) | 3.89 (1.85)               | 4.50 (1.62) |
|                       | <b>p=0.627</b>           |              | <b>p=0.437</b>            |             | <b>p=0.043</b>              |             | <b>p=0.266</b>            |             |
| A point               | -0.36 (1.07)             | -0.32 (1.19) | 1.66 (1.54)               | 2.37 (1.83) | 1.21 (1.64)                 | 0.63 (1.43) | 2.61 (1.89)               | 3.20 (1.59) |
|                       | <b>p=0.906</b>           |              | <b>p=0.173</b>            |             | <b>p=0.220</b>              |             | <b>p=0.283</b>            |             |
| Orbitale              | 0.45 (0.54)              | 0.38 (0.58)  | 1.30 (0.67)               | 1.36 (0.98) | 0.56 (0.67)                 | 0.34 (0.81) | 1.77 (0.83)               | 1.83 (0.96) |
|                       | <b>p=0.670</b>           |              | <b>p=0.817</b>            |             | <b>p=0.338</b>              |             | <b>p=0.806</b>            |             |
| Infraorbitale Foramen | 0.17 (0.72)              | -0.20 (0.75) | 1.70 (1.20)               | 1.44 (1.24) | 0.69 (0.91)                 | 0.58 (1.03) | 2.47 (0.99)               | 2.24 (1.10) |
|                       | <b>p=0.085</b>           |              | <b>p=0.408</b>            |             | <b>p=0.809</b>              |             | <b>p=0.436</b>            |             |
| Zygomatic             | 0.41 (0.79)              | 0.55 (0.81)  | 1.63 (0.93)               | 1.77 (1.21) | 1.38 (1.24)                 | 1.27 (1.05) | 2.61 (1.06)               | 2.76 (0.95) |
|                       | <b>p=0.573</b>           |              | <b>p=0.661</b>            |             | <b>p=0.761</b>              |             | <b>p=0.639</b>            |             |
| 1st molar             | -0.76 (0.83)             | 0.10 (0.76)  | 3.21 (1.63)               | 3.27 (1.71) | 2.08 (1.41)                 | 2.26 (1.09) | 4.31 (1.65)               | 4.41 (1.38) |
|                       | <b>p=0.001*</b>          |              | <b>p=0.904</b>            |             | <b>p=0.628</b>              |             | <b>p=0.840</b>            |             |

\*Statistically significant

Table 5 - Descriptive and statistical analyses of the comparison between Cs x NCs.

|                              | Medial-lateral plane (X) |               | Anteroposterior plane (Y) |               | Superior-inferior plane (Z) |               | Total linear displacement |               |
|------------------------------|--------------------------|---------------|---------------------------|---------------|-----------------------------|---------------|---------------------------|---------------|
|                              | Cleft Side               | NonCleft Side | Cleft Side                | NonCleft Side | Cleft Side                  | NonCleft Side | Cleft Side                | NonCleft Side |
|                              | Mean (SD)                | Mean (SD)     | Mean (SD)                 | Mean (SD)     | Mean (SD)                   | Mean (SD)     | Mean (SD)                 | Mean (SD)     |
| <b>Orbitale</b>              | 0.64 (1.01)              | 0.27 (0.34)   | 1.24 (0.73)               | 1.36 (0.77)   | 0.47 (0.72)                 | 0.65 (0.78)   | 1.84 (0.89)               | 1.70 (0.86)   |
|                              | <b>p=0.13</b>            |               | <b>p=0.46</b>             |               | <b>p=0.24</b>               |               | <b>p=0.29</b>             |               |
| <b>Infraorbitale Foramen</b> | 0.04 (1.00)              | 0.30 (1.03)   | 1.68 (1.52)               | 1.73 (1.12)   | 0.53 (0.87)                 | 0.86 (1.25)   | 2.38 (1.17)               | 2.56 (0.98)   |
|                              | <b>p=0.23</b>            |               | <b>p=0.91</b>             |               | <b>p=0.52</b>               |               | <b>p=0.9</b>              |               |
| <b>Zygomatic</b>             | 0.69 (1.03)              | 0.13 (0.76)   | 1.54 (0.84)               | 1.72 (1.19)   | 1.11 (1.05)                 | 1.59 (1.47)   | 2.46 (0.90)               | 2.76 (1.39)   |
|                              | <b>p=0.01*</b>           |               | <b>p=0.38</b>             |               | <b>p=0.05</b>               |               | <b>p=0.19</b>             |               |
| <b>1st molar</b>             | -0.45 (1.12)             | -1.08 (1.28)  | 3.14 (1.49)               | 3.28 (1.90)   | 1.94 (1.39)                 | 2.21 (1.68)   | 4.09 (1.54)               | 4.54 (2.00)   |
|                              | <b>p=0.12</b>            |               | <b>p=0.56</b>             |               | <b>p=0.33</b>               |               | <b>p=0.16</b>             |               |

## 2.2 Article 2

### **Mandibular and glenoid fossa changes after BAMP therapy in patients with UCLP: 3D assessment**

#### **Abstract**

**Introduction:** The aim of this study was to assess the mandibular displacement and glenoid fossa remodeling after BAMP therapy in patients with unilateral complete cleft lip and palate (UCLP). **Methods:** The experimental group (EG) comprised 24 patients with UCLP and moderate to severe maxillary deficiency with a mean initial age of 11.8 years. The comparison group (CG) comprised 24 non-cleft Class III patients with a mean initial age of 11.7 years. Both groups were treated with BAMP therapy during 18 and 12 months, respectively. Cone-beam computed tomography (CBCT) were performed before and after treatment and superimposed at the anterior cranial base. Three-dimensional linear displacements of mandibular and glenoid fossa landmarks were quantified. Mandibular rotations on the three spatial planes were also calculated. *T* test corrected for multiple testing (Holm-Bonferroni method) and paired *t* test were used to compare, respectively, the cleft and non-cleft groups and cleft versus non-cleft sides ( $p < 0.05$ ). **Results:** The glenoid fossa displaced toward posterior and lateral in both groups. However, the overall articular fossa changes in the experimental group were significantly smaller when compared with the non-cleft group. The condylar displacement was similar in both groups following a posterior and lateral direction. The gonial angle displaced similarly toward posterior, lateral and inferior direction in both groups. The only intergroup difference for rotation was in the anterior view, where the intercondilar line rotated in the opposite directions. Most changes of the glenoid fossa and mandible were similar between the cleft and the non-cleft sides. **Conclusion:** Glenoid fossa and mandibular changes after BAMP therapy was similar in patients with UCLP compared to non-cleft patients. The exception was the posterior remodeling of the glenoid fossa that was slightly smaller in patients with cleft lip and palate.

**Keywords:** Cleft lip, Cleft palate, Orthodontic Anchorage Procedure, Angle Class III

---



## Introduction

Craniofacial growth is severely compromised in patients with unilateral complete cleft lip and palate (UCLP).<sup>1</sup> Lip and palate primary surgeries contributes for a deficient maxillary growth and a Class III skeletal pattern in UCLP.<sup>1</sup> The maxilla is often positioned more upward and posteriorly in patients with UCLP compared to patients with incomplete or without cleft. Additionally, patients with UCLP have vertical maxillary deficiency.<sup>2</sup>

The mandibular growth is less affected than the maxilla in the presence of UCLP. Individuals with UCLP demonstrate a slightly smaller and retruded mandible.<sup>3</sup> On the other hand, the mandibular growth is commonly hyperdivergent in UCLP with smaller rami height, more obtuse gonial angles and an increased lower anterior facial height.<sup>2</sup> These mandibular morphology are seen in non-operated and operated patients with UCLP and therefore are not influenced by the primary plastic surgeries.<sup>4</sup> Some authors suggest that vertical mandibular pattern observed in patients with cleft lip and palate might be related to the position of the tongue.<sup>5</sup> Whenever the maxilla is constricted, as well as the maxillary incisors are lingually tipped, the tongue cannot rest at the palatal vault. As a result, it rests between the maxillary and mandibular teeth, increasing the freeway space, and allowing an overclosure of the mandible.<sup>5</sup> Another hypothesis states that the frequent mouth breathing and deviated septum may influence the mandibular growth in UCLP, mainly at the gonion region.<sup>6</sup>

The effects of the facemask therapy are similar in patients with and without UCLP. The main facial changes that occur with facemask therapy include, besides the maxillary anterior displacement, a backward rotation of the mandible with an increase of the lower anterior facial height.<sup>7</sup> Considering that patients with UCLP usually show a vertical growth pattern, the clockwise rotation of the mandible during facemask therapy is an unfavorable effect. Recently a new orthopedic therapy for Class III malocclusion has been described in the literature.<sup>8</sup> Treatment with Bone Anchored Maxillary Protraction (BAMP) has now allowed greater amounts maxillary advancement coupled with better control of the mandibular plane rotation. BAMP therapy produced a closure of the gonial angle and a slight restriction of the anterior displacement of the mandible in non-cleft individuals. Compared to facemask, BAMP therapy produced a smaller increase of the lower anterior facial height.<sup>9</sup>

---

Few studies have previously reported that remodeling of the glenoid fossa occurs mandibular orthopedic treatment: a magnetic resonance study after Herbst appliance,<sup>10</sup> and a histologic study in rhesus monkeys treated with chincup therapy.<sup>11</sup> The only previous study after maxillary traction in humans showed a posterior remodeling of the anterior and posterior eminences of the glenoid fossa.<sup>12</sup> However, the glenoid fossa and mandibular outcomes after BAMP therapy in patients with UCLP has not been evaluated. Therefore, the aim of this study is to evaluate mandibular displacement and glenoid fossa remodeling after maxillary protraction anchored in miniplates in patients with UCLP. The hypothesis is that no difference is observed between patients with and without CLP.

## **Material and Methods**

This study was approved by Ethical Committee of the University\_\_\_\_ (n° 819.693). The sample size was calculated using preliminary statistics including the first 10 patients of the experimental group. For a standard deviation of 1.49mm and a minimal intergroup difference of 1.5mm to be detected, a sample of 17 was required to provide statistical power of 80% with an alfa of 0.05.

The Cleft Group (CG) consisted of 24 patients with unilateral complete cleft lip and palate and maxillary sagittal deficiency, treated consecutively at the Hospital \_\_\_\_\_, University \_\_\_\_\_. The CG was prospectively treated and the inclusion criteria were ages between 10 and 13 years old; clinical presence of the mandibular permanent canines; patients who underwent secondary alveolar bone graft for at least 3 months; Goslon Index varying from 3 to 5. The exclusion criteria were: patients with syndromes and inadequate oral hygiene. The comparison Non-Cleft Group (NCG) consisted of secondary data analysis<sup>13</sup> of 25 Class III non-cleft patients, treated consecutively in a private practice. The samples are described in Table I. Bone anchored maxillary protraction following the same protocol<sup>8</sup> was performed in both groups. CBCT exams were obtained before (T1) and after treatment (T2) with an interval of 18 and 12 months for CG and NCG, respectively. In the Cleft Group, two patients were lost during the follow-up because of treatment interruption; one patient was excluded due to maxillary miniplate instability and recurrent bad oral hygiene, one patient was excluded due to movement artifacts during the CBCT exam, one patient was excluded because the glenoid fossa and the

---

---

condyles were cut out from the exam. The final Cleft group consisted of 19 patients for glenoid fossa evaluation. Mandibular displacement was performed in 12 out of the 19 patients with cleft because 7 CBCT exams (T1 or T2) were performed with the mouth open. One patient was excluded from NCG group for missing CBCT data and the final Non-cleft group consisted of 24 patients.

In order to measure linear and angular 3D displacements, the following steps were taken:

1. *Create a volumetric label map:* using ITK-SNAP 2.4.0,<sup>14</sup> an open-source software ([www.itksnap.org](http://www.itksnap.org)), the cranial base and maxilla were segmented for T1 and T2 scans.
  2. *Create a virtual 3D surface model:* using 3D Slicer 4.4 ([www.slicer.org](http://www.slicer.org)), another open-source software, the virtual 3D surface models were created from the T1 and T2 volumetric label maps.
  3. *Head Orientation:* Slicer Software displays a 3D coordinate system that was kept fixed to be used as reference to consistently orient the 3D models of all patients. Using axial, coronal and sagittal views of the 3D models, the T1 model was moved to match the midsagittal plane (defined by glabella, crista galli and basion) vertically and coincident to the sagittal plane of the 3D coordinate system. The Frankfurt horizontal plane was oriented to match the axial plane. And the horizontal infra-orbitale (most inferior point of the left and right orbita) line was oriented to be coincident to the coronal plane.<sup>15</sup>
  4. *3D cranial base superimposition:* the 3D superimposition registered in the cranial base was performed in two steps: a) using 3D Slicer 4.4, the T2 scan was manually approximated to the T1 oriented scan. b) using the anterior cranial fossa label map as a best fit reference, a fully automated voxel-based registration was performed in 3D Slicer 4.4.<sup>16</sup> The matrix generated from the registration of T2 over T1 was applied to the T2 scan, volumetric label map and 3D surface model also in 3D Slicer 4.4.
  5. *Landmarks identification:* (a) Anatomic points were defined at T1 and T2 volumetric models using the greyscale image as reference using ITK-SNAP 2.4.0,<sup>14</sup> (b) The volumetric point models were transformed into surface models using Slicer 4.4. (c) Landmarks were placed at T1 and T2
-

surface point models using the Q3DC tool in the 3D Slicer 4.4 software as displayed in Table 2 and Figure 1.

6. *Quantitative measurements:* using the Q3DC tool in 3D Slicer 4.4 Software, 3D linear distances and the amount of directional changes in each plane of the 3D space (x,y,z, respectively medio-lateral, antero-posterior and superior-inferior axes) were measured between corresponding coordinates of landmarks placed in the T1 and registered T2 surface models. Anterior, inferior and lateral displacements were considered positive values; and posterior, superior and medial displacements were considered as negative values. The angular measurements shown in Table 2 and Figure 2 were calculated between T2 and T1. The mandibular rotations were measured in a superior view (Yaw), anterior view (Roll) and sagittal view (Pitch). In the anterior, and right side views, clockwise (CW) rotation is considered as a positive value and counterclockwise (CCW) rotation is considered as a negative value. In a superior view, rotation to the right is considered as a positive value and to the left is considered as a negative value. Color-coded surface distance maps and semi-transparent superimpositions were used to visually demonstrate the overall mandibular and glenoid fossa changes in CG group. (Figures 3 to 5)

### **Statistical analyses**

Intraclass correlation coefficient with a confidence level of 95% was performed to assess the reproducibility of the linear and angular measurements between T1 and T2.

All variables showed a normal distribution. The statistical analysis was performed with SPSS Statistical Software Package (Version 21.0; SPSS, Chicago, IL). The comparison between the Cleft Group (CG) and Non-cleft Group (NCG) considering the mean value between right and left sides was performed using independent t test corrected for multiple testing (Holm-Bonferroni method). The comparison between the cleft (Cs) and non-cleft (NCs) sides in CG group was performed using paired t test. The level of significance was 0.05.

---

## Results

The ICCs showed very good intraexaminer agreement varying from 0.79 to 1.00.

### Fossa remodeling

The glenoid fossa displacement was posterior, lateral and superior in both sides of the cleft group, while the fossa displacement in the non-cleft group was posterior, lateral and inferior. (Table 3) No intergroup statistical difference was found in the three spatial planes (x, y and z). However, the total linear displacement of fossa landmarks showed a significantly smaller magnitude in the cleft group. (Table 3)

Right and left glenoid fossa symmetrically remodeled in the cleft group. (Table 4 and Figure 4).

### Mandibular Displacement

No statistical differences were found for the condyle and ramus displacement between CG and NCG groups.

When comparing the cleft and non-cleft sides, no differences were found for anteroposterior or supero-inferior displacements of all mandibular landmarks. The exception was the medial pole of the condyle (MC) which showed a significant larger lateral displacement at the cleft side compared to the opposite side. (Table 4)

### Mandibular rotation

The only significant difference between the CG and NC groups was found for the inter-condylar line in the anterior view. While it showed a slight CCW roll in the CG group, it showed a CW roll in the NCG group (Table 5).

The semitransparency superimposition and the color-coded surface distance maps of the glenoid fossa and mandibles are shown in Figures 3 to 5.

## Discussion

This is the first study to assess and highlight the mandibular and fossa changes that occur with maxillary protraction therapy in patients with complete unilateral cleft lip and palate. The methodology applied in this study enabled the

---

three-dimensional assessment of mandibular displacements and rotation after the BAMP therapy, including assessments of symmetry of the mandibular changes. This study also included a comparison group of non-cleft Class III malocclusion patients treated with the same protocol. Previous studies with BAMP therapy in patients without oral cleft showed a backward and downward displacement of the mandible, a closure of the gonial angle, and a backward displacement of the glenoid fossa.<sup>17</sup>

#### LINEAR CHANGES

The glenoid fossa in the CG group displaced posteriorly, laterally and superiorly, and showed significantly smaller 3D amount of remodeling than NCG group (Table 3). However, when the 3D components of the direction of changes were tested, no significant differences among groups were found (Table 3). The glenoid fossa displacement seems to be associated to the mandibular displacement, since the condyle showed a similar pattern of displacement. These results are in accordance to a previous study using BAMP therapy in non-cleft patients, which found a posterior remodeling of glenoid fossa anterior (1.30-1.47mm) and posterior eminences (1.30-1.39mm).<sup>12</sup>

The condyle was displaced posteriorly, laterally and superiorly in the cleft group, while displaced posteriorly, laterally and inferiorly in the non-cleft group. (Table 3) The difference in the vertical direction was not statistically significant. The displacement found in this study corroborates the posterior displacement of the condyle previously found with the BAMP therapy in non-cleft patients.<sup>12</sup> The Gonial landmark also showed a posterior, lateral and inferior displacement in both groups, suggesting that the whole rami displaced backwards, also as previously described in the literature.<sup>12</sup>

Despite the mandibular growth, the backward and downward displacement of the mandible contributed to the orthopedic correction of the Class III malocclusion, by masking the mandibular corpus elongation, and therefore favoring an improvement in the facial convexity and the overjet correction after the treatment.

When comparing the cleft and non-cleft sides, only the lateral displacement of the medial pole of the cleft side condyle was significantly greater than the non-cleft side. Even though the lateral pole did not show statistical significant difference, it also showed a greater lateral displacement in the cleft side. It states that the condyle in the cleft side displaced more laterally than the non-cleft side. This asymmetry

---

might be the result of slight difference in the elastic direction between the cleft and non-cleft sides. The miniplate was usually placed more anteriorly in the lesser segment determining a more vertical elastic vector at this side. Other hypothesis is that the cleft side condyle displaces laterally as a counterpart of a greater zygomatic lateral movement at the cleft side after BAMP therapy. This correlation is in accordance to previous findings that showed the mandible follows the deviations of the maxillary asymmetry in patients with CLP.<sup>18</sup>

#### ANGULAR CHANGES

In an anterior view, the inter-condylar line showed a significant difference between groups, with CCW rotation in the CG group and CW rotation in the NCG group. This difference was not clinically relevant. (Table 5) These asymmetrical displacements of the mandible are in accordance to previous findings in the literature that showed an asymmetrical growth of the mandible following the asymmetric maxilla, indicating a parallel growth in patients with UCLP.<sup>18</sup>

In the lateral view, the Co-Me line showed a similar CW rotation between CG and NCG groups, corroborating previous findings.<sup>19</sup> The Occlusal Line showed a similar counterclockwise rotation for both groups.<sup>20</sup> Considering that most of the patients with UCLP show a vertical pattern of growth with a reduced height of the rami, more obtuse gonial angle and increased lower anterior facial height,<sup>2</sup> the small amount of clockwise rotation of the mandible favors the esthetic treatment outcome (Table 5).

The limitation of this study is the different ethnical background of the cleft and non-cleft groups. However, the treatment outcomes were very similar regardless of the different ethnical origins of the samples.

The symmetrical condylar and ramus displacements, with no significant shape changes of the mandible, suggest that the forces applied in the miniplates do not compromise the condyle shape neither the TMJ. The symmetrical glenoid fossa remodeling may suggest better stability of the mandibular displacement. However, future studies should verify the mandibular remodeling pattern with regional superimposition and the long-term stability of the mandibular changes.

---

## **Conclusions**

BAMP therapy produced similar glenoid fossa changes to the 3D components of the direction of changes: posterior, lateral and inferior-superior, however the amount of the 3D fossa displacement was significantly smaller in patients with cleft. Overall mandibular displacements and rotations were similar in patients with and without UCLP. Despite the presence of a unilateral cleft, most of the mandibular changes were symmetrical.

The authors would like to acknowledge FAPESP (São Paulo Research Foundation / nº 2013/17596-3, 2013/19880-0 and 2014/11206-1) for the financial support.



---

---

**REFERENCES**

1. Semb G. A study of facial growth in patients with unilateral cleft lip and palate treated by the Oslo CLP Team. *Cleft Palate Craniofac J* 1991;28(1):1-21; discussion 46-8.
  2. Graber TM. A Cephalometric Analysis of the Developmental Pattern and Facial Morphology in Cleft Palate\*. *The Angle Orthodontist* 1949;19(2):91-100.
  3. Aduss H. Craniofacial growth in complete unilateral cleft lip and palate. *Angle Orthod* 1971;41(3):202-13.
  4. Silva Jr OG, Corrêa Normando AD, Capelozza Jr L. Mandibular morphology and spatial position in patients with clefts: intrinsic or iatrogenic? *The Cleft palate-craniofacial journal* 1992;29(4):369-75.
  5. Ross RB, Johnston MC. The effect of early orthodontic treatment on facial growth in cleft lip and palate. *Cleft Palate J* 1967;4:157-64.
  6. Ross RB. The clinical implications of facial growth in cleft lip and palate. *Cleft Palate J* 1970;7:37-47.
  7. Baccetti T, Franchi L, McNamara JA, Jr. Treatment and posttreatment craniofacial changes after rapid maxillary expansion and facemask therapy. *Am J Orthod Dentofacial Orthop* 2000;118(4):404-13.
  8. De Clerck HJ, Cornelis MA, Cevidanes LH, Heymann GC, Tulloch CJ. Orthopedic traction of the maxilla with miniplates: a new perspective for treatment of midface deficiency. *J Oral Maxillofac Surg* 2009;67(10):2123-9.
  9. Cevidanes L, Baccetti T, Franchi L, McNamara JA, Jr., De Clerck H. Comparison of two protocols for maxillary protraction: bone anchors versus face mask with rapid maxillary expansion. *Angle Orthod* 2010;80(5):799-806.
  10. Ruf S, Pancherz H. Temporomandibular joint remodeling in adolescents and young adults during Herbst treatment: A prospective longitudinal magnetic resonance imaging and cephalometric radiographic investigation. *Am J Orthod Dentofacial Orthop* 1999;115(6):607-18.
  11. Janzen EK, Blucher JA. The cephalometric, anatomic, and histologic changes in *Macaca mulatta* after application of a continuous-acting retraction force on the mandible. *Am J Orthod* 1965;51(11):823-55.
  12. De Clerck H, Nguyen T, de Paula LK, Cevidanes L. Three-dimensional assessment of mandibular and glenoid fossa changes after bone-anchored
- 
-

- Class III intermaxillary traction. *Am J Orthod Dentofacial Orthop* 2012;142(1):25-31.
13. Nguyen T, Cevidanes L, Cornelis MA, et al. Three-dimensional assessment of maxillary changes associated with bone anchored maxillary protraction. *Am J Orthod Dentofacial Orthop* 2011;140(6):790-8.
  14. Yushkevich PA, Piven J, Hazlett HC, et al. User-guided 3D active contour segmentation of anatomical structures: significantly improved efficiency and reliability. *Neuroimage* 2006;31(3):1116-28.
  15. Ruellas AC, Tonello C, Gomes L, et al. Common 3D Coordinate System for Assessments of Directional Changes. *American Journal of Orthodontics Dentofacial Orthopedics* 2016(ahead of print).
  16. Cevidanes LH, Styner MA, Proffit WR. Image analysis and superimposition of 3-dimensional cone-beam computed tomography models. *Am J Orthod Dentofacial Orthop* 2006;129(5):611-8.
  17. Baccetti T, McGill JS, Franchi L, McNamara JA, Jr., Tollaro I. Skeletal effects of early treatment of Class III malocclusion with maxillary expansion and face-mask therapy. *Am J Orthod Dentofacial Orthop* 1998;113(3):333-43.
  18. Laspos CP, Kyrkanides S, Tallents RH, Moss ME, Subtelny JD. Mandibular and maxillary asymmetry in individuals with unilateral cleft lip and palate. *Cleft Palate Craniofac J* 1997;34(3):232-9.
  19. Tindlund RS, Rygh P. Maxillary protraction: different effects on facial morphology in unilateral and bilateral cleft lip and palate patients. *The Cleft palate-craniofacial journal* 1993;30(2):208-21.
  20. Baek SH, Kim KW, Choi JY. New treatment modality for maxillary hypoplasia in cleft patients. Protraction facemask with miniplate anchorage. *Angle Orthod* 2010;80(4):783-91.
- 
-

## Figure Legends

Figure 1 - Landmarks placed in the 3D surface model: 1 and 2) Condyle-Superior (SC); 3 and 5) Condyle-Lateral (CL); 4 and 6) Condyle-Medial (MC); 7) Menton (Me); 8) B Point (B); 9 and 10) Incisal of the mandibular central incisors (L1); 11 and 12) mesio-buccal cusp of the first permanent molar (L6); 13 and 14) Gonion (Go).

Figure 2 - Yaw, Roll and Pitch measurements. Black line corresponds to T1 and red line corresponds to T2. 1) Inter-Condylar Line - Yaw; 2) Intermolar Line - Yaw; 3) Inter-Condylar Line - Roll; 4) Intermolar Line - Roll; 5) Co-Me Line - Pitch; 6) Occlusal Plane - Pitch.

Figure 3 - Closest point colormap of the mandible from an anterior view of all patients from the CG group. Ranges from -5mm to +5mm. In blue the posterior, superior and/or medial displacement, and in red the anterior, inferior and/or lateral displacement.

Figure 4 - Closest point colormap of the glenoid fossa from the inferior view of the CG group. Ranges from -5mm to +5mm. In blue the posterior, superior and/or medial displacement, and in red the anterior, inferior and/or lateral displacement.

Figure 5 - Lateral visualization of the semi-transparent superimposition of T1 (green) and T2 (white) mandibles of the CG group.

---

---

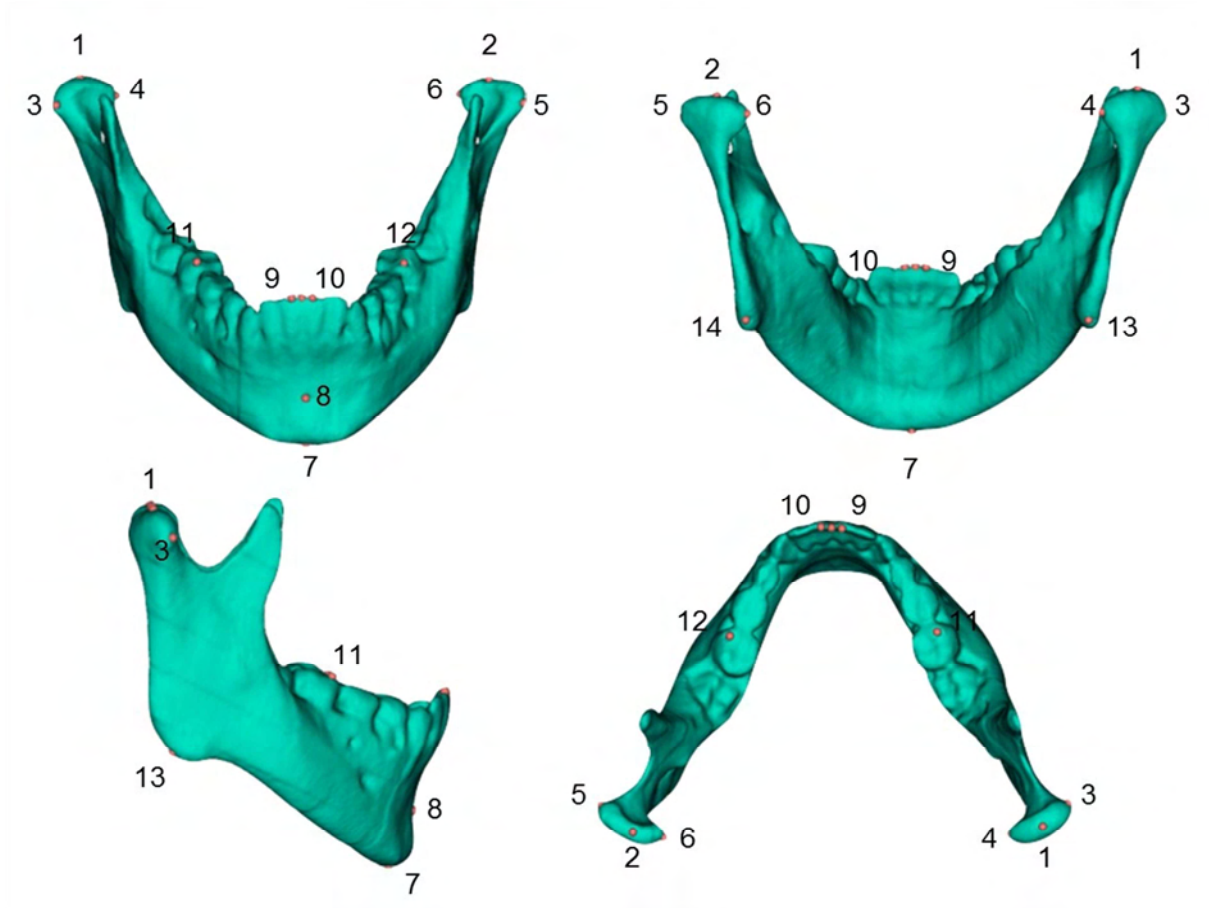


Figure 1

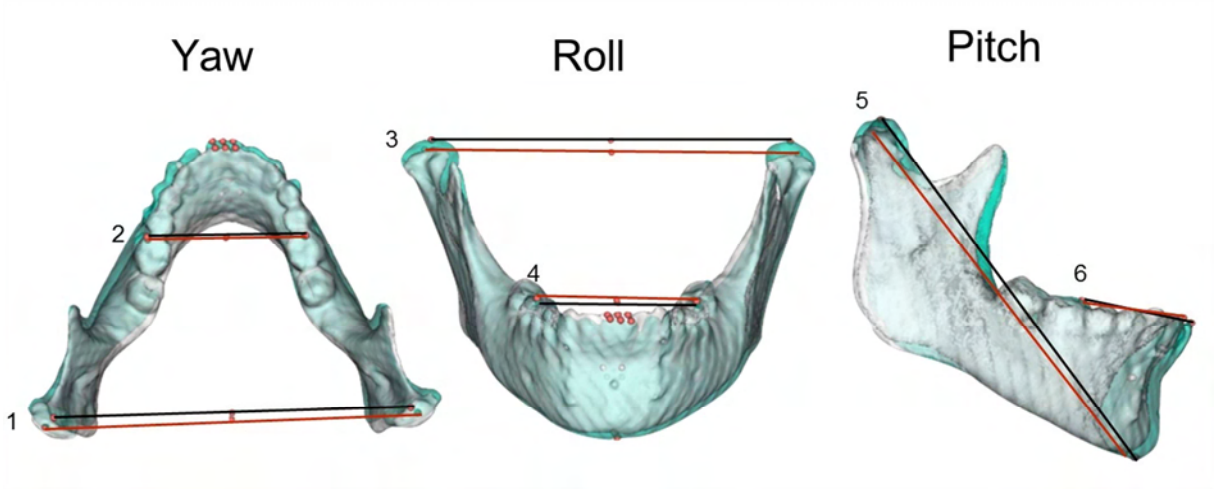


Figure 2

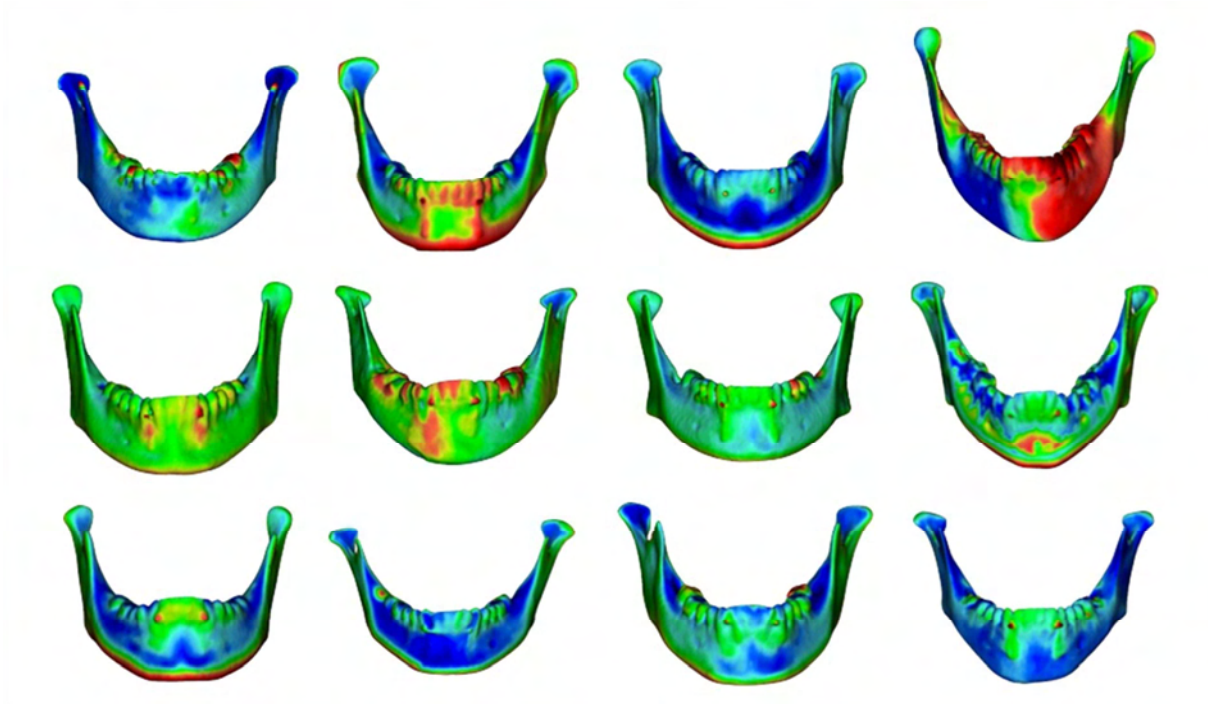


Figure 3

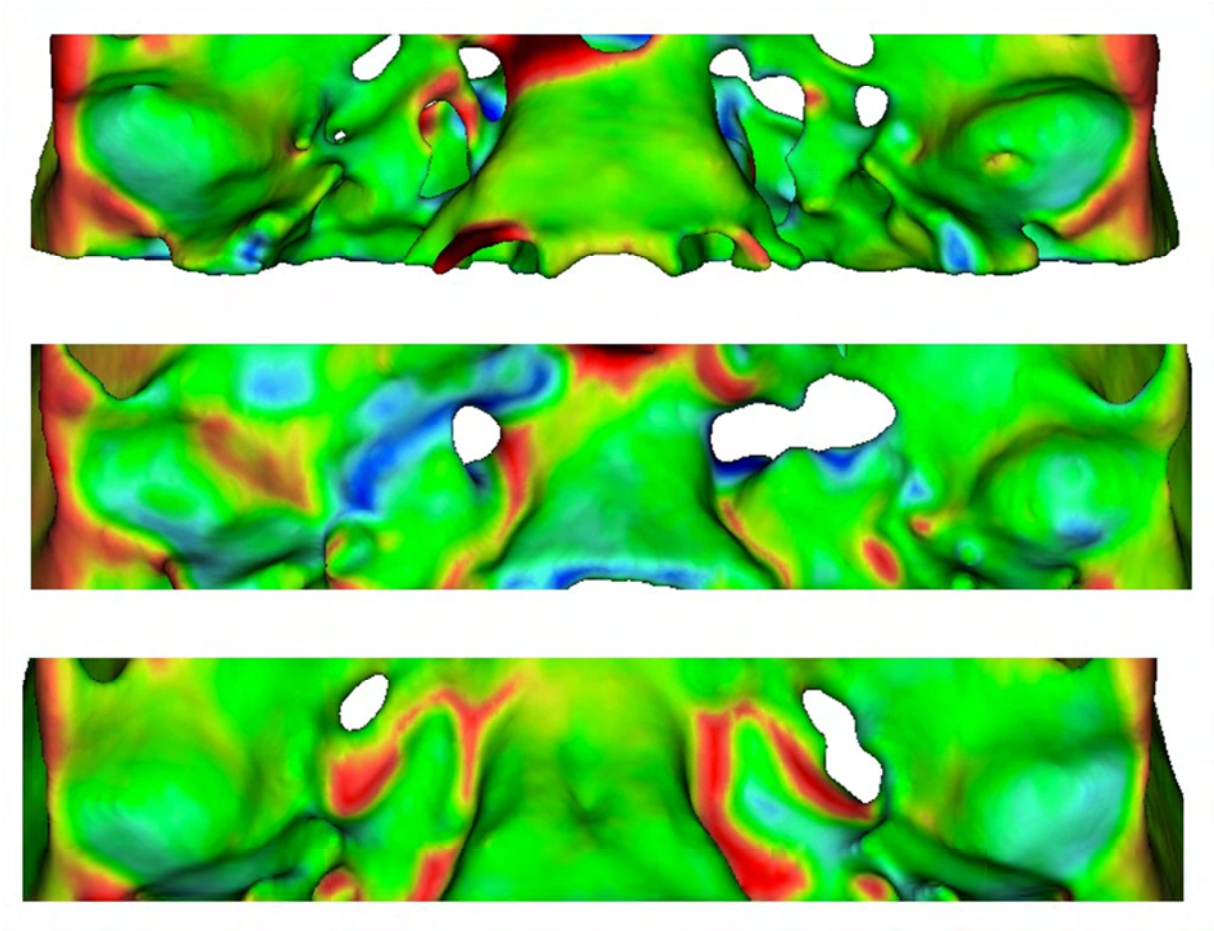


Figure 4




Figure 5



Table 1 - Sample description.

|                              | n   | sex                  | mean age at T1 CBCT exam     | Wits appraisal (mean (SD)) |
|------------------------------|---|----------------------|------------------------------|----------------------------|
| <b>Cleft Group (CG)</b>      | 24 (6 with cleft in the Right and 18 with cleft in the Left side) | 17 boys and 7 girls  | 11.8 years ( $\pm$ 9months)  | -7.13 (3.13)               |
| <b>Non-Cleft Group (NCG)</b> | 24  | 10 boys and 15 girls | 11.9 years ( $\pm$ 14months) | -4.8 (2.8)                 |

Table 2 - Description of the landmarks and lines identification.

|   |  |
|---|--|
| <b>Glenoid Fossa - Superior (FS)</b>                    | The most superior and central point of the superior curvature of the fossa   |
| <b>Glenoid Fossa - Anterior (FA)</b>                    | defined by the middle point between the most inferior point of the anterior eminence of the glenoid fossa and FS         |
| <b>Glenoid Fossa - Posterior</b>                        | defined by the middle point between the most inferior point of the posterior eminence of the glenoid fossa and FS        |
| <b>Condyle - Superior (CS)</b>                          | the most superior and central point of the condyle   |
| <b>Condyle - Lateral (CL)</b>                           | the most extreme point of the lateral pole of the condyle  |
| <b>Condyle - Medial (CM)</b>                            | the most extreme point of the medial pole of the condyle   |
| <b>Menton (Me)</b>                                      | the most inferior point of the chin  |
| <b>B Point (B)</b>                                      | the most posterior point of the anterior curvature of the sinfisis   |
| <b>Incisal of the mandibular central incisor (I-L1)</b> | the central point of the incisor of each of the mandibular central incisor   |
| <b>Apex of the mandibular central incisor (A-L1)</b>    | the apex of the root of each of the mandibular central incisor   |
| <b>Mandibular first permanent molar (L6)</b>            | the bucco-mesial cusp of the mandibular first permanent molar  |
| <b>Gonion (Go)</b>                                      | the projection of a virtual bissetrix of a line adjacent to the mandibular base and the posterior border of the mandible |
| <b>Inter-Condylar Line</b>                              | A line connecting right and left CS  |
| <b>Intermolar Line</b>                                  | A line connecting right and left L6  |
| <b>Occlusal Line</b>                                    | A line connecting the middle point of right and left L6 with the middle point of right and left I-L1                     |
| <b>Co - Me</b>  | A line connecting the middle point of right and left CS with the Me point  |

Table 3 - Descriptive and statistical analyses of the comparison of linear measurements (T2-T1) between CG x NCG.

|                             | AP              |                 |              | RL              |                |              | SI              |                |              | 3D             |                |               |
|-----------------------------|-----------------|-----------------|--------------|-----------------|----------------|--------------|-----------------|----------------|--------------|----------------|----------------|---------------|
|                             | Cg              | NCg             | p            | Cg              | NCg            | p            | Cg              | NCg            | p            | Cg             | NCg            | p             |
| <b>Superior Fossa</b>       | -0.49<br>(0.75) | -0.76<br>(0.94) | <b>0.333</b> | 0.59<br>(0.59)  | 0.53<br>(0.94) | <b>0.799</b> | -0.06<br>(0.28) | 0.09<br>(0.69) | <b>0.360</b> | 1.34<br>(0.42) | 1.95<br>(0.68) | <b>0.001*</b> |
| <b>Anterior Fossa</b>       | -0.24<br>(0.50) | -0.59<br>(0.99) | <b>0.155</b> | 0.68<br>(0.52)  | 0.65<br>(1.06) | <b>0.895</b> | 0.12<br>(0.21)  | 0.37<br>(0.70) | <b>0.115</b> | 1.18<br>(0.29) | 1.88<br>(0.71) | <b>0.000*</b> |
| <b>Posterior Fossa</b>      | -0.53<br>(0.61) | -0.81<br>(0.83) | <b>0.213</b> | 0.62<br>(0.54)  | 0.71<br>(1.04) | <b>0.733</b> | 0.12<br>(0.17)  | 0.34<br>(0.69) | <b>0.140</b> | 1.31<br>(0.43) | 1.95<br>(0.64) | <b>0.000*</b> |
| <b>Superior Condyle</b>     | -0.80<br>(0.69) | -1.00<br>(1.12) | <b>0.506</b> | 0.78<br>(0.88)  | 0.85<br>(0.58) | <b>0.797</b> | -0.22<br>(0.47) | 0.24<br>(1.07) | <b>0.086</b> | 1.68<br>(0.70) | 2.11<br>(0.88) | <b>0.118</b>  |
| <b>Lateral Condyle</b>      | -1.32<br>(0.79) | -0.93<br>(1.08) | <b>0.221</b> | 0.85<br>(0.57)  | 0.82<br>(0.74) | <b>0.911</b> | 0.19<br>(0.88)  | 0.55<br>(1.18) | <b>0.312</b> | 2.03<br>(0.79) | 2.26<br>(0.86) | <b>0.432</b>  |
| <b>Medial Condyle</b>       | -0.99<br>(0.64) | -1.17<br>(1.01) | <b>0.513</b> | 0.38<br>(0.42)  | 0.55<br>(0.49) | <b>0.275</b> | 0.13<br>(0.58)  | 0.52<br>(1.07) | <b>0.163</b> | 1.62<br>(0.72) | 2.07<br>(0.83) | <b>0.104</b>  |
| <b>Menton</b>               | -1.46<br>(2.78) | -0.12<br>(2.57) | <b>0.267</b> | -0.70<br>(1.44) | 0.16<br>(1.06) | <b>0.046</b> | 1.68<br>(3.07)  | 1.41<br>(2.70) | <b>0.802</b> | 4.22<br>(2.39) | 3.40<br>(2.25) | <b>0.382</b>  |
| <b>B Point</b>              | -1.20<br>(2.35) | -0.19<br>(2.35) | <b>0.270</b> | -0.77<br>(1.39) | 0.16<br>(1.03) | <b>0.038</b> | 1.91<br>(3.94)  | 1.16<br>(3.54) | <b>0.581</b> | 4.62<br>(2.41) | 3.83<br>(2.29) | <b>0.314</b>  |
| <b>Incisal L1</b>           | 0.04<br>(1.92)  | 0.25<br>(1.90)  | <b>0.756</b> | -0.64<br>(0.88) | 0.27<br>(1.01) | <b>0.013</b> | 2.09<br>(3.06)  | 0.61<br>(2.43) | <b>0.168</b> | 3.80<br>(1.87) | 2.86<br>(2.65) | <b>0.155</b>  |
| <b>Apical L1</b>            | -1.15<br>(2.17) | -0.17<br>(2.07) | <b>0.211</b> | -0.44<br>(1.03) | 0.27<br>(1.01) | <b>0.064</b> | -1.51<br>(2.71) | 0.48<br>(2.39) | <b>0.275</b> | 3.56<br>(1.94) | 3.05<br>(1.46) | <b>0.429</b>  |
| <b>Mesio-buccal cusp L6</b> | 0.22<br>(1.25)  | 0.78<br>(2.05)  | <b>0.316</b> | 0.07<br>(0.86)  | 0.12<br>(0.76) | <b>0.864</b> | 2.42<br>(2.26)  | 1.64<br>(1.77) | <b>0.307</b> | 3.43<br>(1.45) | 3.08<br>(1.62) | <b>0.522</b>  |
| <b>Gonion</b>               | -2.36<br>(2.70) | -2.03<br>(1.52) | <b>0.699</b> | 0.89<br>(0.76)  | 0.85<br>(0.49) | <b>0.859</b> | 1.34<br>(1.54)  | 1.70<br>(2.24) | <b>0.573</b> | 3.93<br>(2.11) | 3.74<br>(1.67) | <b>0.796</b>  |

\*Statistically significant

Table 4 - Descriptive and statistical analyses of the comparison of linear measurements (T2-T1) between Cs x NCs.

|                             | AP              |                 |              | RL              |                 |               | SI              |                 |              | 3D             |                |              |
|-----------------------------|-----------------|-----------------|--------------|-----------------|-----------------|---------------|-----------------|-----------------|--------------|----------------|----------------|--------------|
|                             | Cs              | NCs             | <i>p</i>     | Cs              | NCs             | <i>p</i>      | Cs              | NCs             | <i>p</i>     | Cs             | NCs            | <i>p</i>     |
| <b>Superior Fossa</b>       | -0.30<br>(1.03) | -0.68<br>(0.74) | <b>0.142</b> | 0.77<br>(0.96)  | 0.42<br>(0.77)  | <b>0.292</b>  | -0.11<br>(0.48) | -0.01<br>(0.34) | <b>0.550</b> | 1.55<br>(0.62) | 1.14<br>(0.75) | <b>0.156</b> |
| <b>Anterior Fossa</b>       | -0.35<br>(0.60) | -0.14<br>(0.70) | <b>0.332</b> | 0.94<br>(0.81)  | 0.43<br>(0.75)  | <b>0.433</b>  | 0.09<br>(0.32)  | 0.15<br>(0.31)  | <b>0.616</b> | 1.36<br>(0.47) | 1.00<br>(0.56) | <b>0.115</b> |
| <b>Posterior Fossa</b>      | -0.36<br>(0.72) | -0.69<br>(0.67) | <b>0.068</b> | 0.74<br>(1.04)  | 0.51<br>(0.77)  | <b>0.115</b>  | 0.08<br>(0.27)  | 0.16<br>(0.36)  | <b>0.565</b> | 1.43<br>(0.46) | 1.19<br>(0.68) | <b>0.236</b> |
| <b>Superior Condyle</b>     | -0.82<br>(0.92) | -0.77<br>(0.80) | <b>0.894</b> | 0.88<br>(0.83)  | 0.68<br>(1.37)  | <b>0.761</b>  | -0.28<br>(0.49) | -0.16<br>(0.65) | <b>0.527</b> | 1.66<br>(0.67) | 1.70<br>(0.99) | <b>0.894</b> |
| <b>Lateral Condyle</b>      | -1.35<br>(1.05) | -1.29<br>(0.82) | <b>0.840</b> | 1.11<br>(0.85)  | 0.59<br>(0.71)  | <b>0.053</b>  | 0.28<br>(1.16)  | 0.11<br>(0.82)  | <b>0.563</b> | 2.22<br>(1.01) | 1.85<br>(0.74) | <b>0.133</b> |
| <b>Medial Condyle</b>       | -0.95<br>(0.97) | -1.02<br>(0.69) | <b>0.825</b> | 0.51<br>(0.43)  | 0.25<br>(0.76)  | <b>0.027*</b> | 0.35<br>(1.28)  | -0.10<br>(0.92) | <b>0.430</b> | 1.72<br>(0.98) | 1.53<br>(0.76) | <b>0.525</b> |
| <b>Incisal L1</b>           | 0.16<br>(2.06)  | -0.08<br>(1.87) | <b>0.349</b> | -0.69<br>(0.93) | -0.59<br>(0.88) | <b>0.455</b>  | 2.16<br>(2.97)  | 1.97<br>(3.17)  | <b>0.260</b> | 3.83<br>(1.89) | 3.76<br>(1.87) | <b>0.637</b> |
| <b>Apical L1</b>            | -1.16<br>(2.14) | -1.14<br>(2.26) | <b>0.910</b> | -0.55<br>(1.13) | -0.32<br>(1.11) | <b>0.371</b>  | -1.56<br>(2.72) | 1.46<br>(2.77)  | <b>0.706</b> | 3.49<br>(2.14) | 3.64<br>(1.83) | <b>0.569</b> |
| <b>Mesio-buccal cusp L6</b> | 0.25<br>(1.28)  | 0.18<br>(1.39)  | <b>0.791</b> | 0.42<br>(1.19)  | -0.27<br>(1.19) | <b>0.174</b>  | 2.58<br>(2.43)  | 2.26<br>(2.16)  | <b>0.209</b> | 3.61<br>(1.44) | 3.25<br>(1.53) | <b>0.068</b> |
| <b>Gonial Angle T2-T1</b>   | -2.19<br>(2.97) | -2.53<br>(2.67) | <b>0.485</b> | 0.97<br>(0.70)  | 0.82<br>(1.27)  | <b>0.702</b>  | 1.32<br>(1.67)  | 1.35<br>(2.12)  | <b>0.962</b> | 3.76<br>(2.23) | 4.09<br>(2.12) | <b>0.325</b> |

\*Statistically significant

Table 5 - Descriptive and statistical analyses of the comparison of angular measurements (T2-T1) between CG and NCG.

|                        | YAW             |                 | ROLL            |                | PITCH           |                 |
|------------------------|-----------------|-----------------|-----------------|----------------|-----------------|-----------------|
|                        | CG              | NCG             | CG              | NCG            | CG              | NCG             |
| <b>Condylar Line</b>   | -0.16<br>(0.57) | 0.08 (0.67)     | -0.13<br>(0.35) | 0.21<br>(0.46) |                 |                 |
|                        | <b>p=0.274</b>  |                 | <b>p=0.021*</b> |                |                 |                 |
| <b>Intermolar Line</b> | -0.13<br>(0.88) | -0.21<br>(1.16) | 0.69 (0.88)     | 0.17<br>(0.93) |                 |                 |
|                        | <b>p=0.811</b>  |                 | <b>p=0.113</b>  |                |                 |                 |
| <b>Occlusal Line</b>   |                 |                 |                 |                | -1.10<br>(2.92) | -2.03<br>(2.31) |
|                        |                 |                 |                 |                | <b>p=0.351</b>  |                 |
| <b>Co - Me</b>         |                 |                 |                 |                | 0.90 (1.92)     | 0.08 (1.54)     |
|                        |                 |                 |                 |                | <b>p=0.212</b>  |                 |



## **3 DISCUSSION**

---

---





### **3 DISCUSSION**

Maxillary growth of patients with cleft lip and palate has been an important topic of discussion. The literature has stated that one of the main reasons of this deficiency is the primary plastic surgeries.(7-11, 33, 34) During growth, operated children with UCLP show almost no increase in the length of the maxilla while non-cleft patients showed significant amount of increment of the maxilla.(1) Therefore, the 2.61mm displacement of the A point of the maxilla found in this study is considered a positive outcome after maxillary protraction therapy.

The BAMP therapy showed symmetrical anterior and inferior displacement of the maxilla, and posterior and inferior displacement of the mandible and glenoid fossa. Even though, a high level of individual variability was observed in patients with UCLP. A comparison group of untreated patients with UCLP and/or non-cleft patients treated with BAMP would be necessary to better understand the changes occurred with this therapy in patients with clefts. In a short-term assessment, the maxillary protraction with BAMP improved the profile and corrected the Class III malocclusion, overjet and Wits appraisal. These changes favored the comprehensive orthodontic treatment of the patients, decreasing the total treatment time, the need of orthognathic surgery in most patients and consequently, the burden of care.

---

---



## **4 CONCLUSION**

---

---



## **4 CONCLUSION**

The BAMP therapy produced a marked and symmetrical protraction of maxillary upper and lower regions similarly to patients without oral clefts. Regarding the mandible, it produced similar glenoid fossa changes to the 3D components of the direction of changes: posterior, lateral and inferior-superior, but the amount of the 3D fossa displacement was significantly smaller in patients with cleft. Overall mandibular displacements and rotations were similar in patients with and without UCLP. Despite the presence of a unilateral cleft, most of the mandibular changes were symmetrical. This therapy improved the maxillary deficient profile and Class III malocclusion in patients with unilateral cleft lip and palate, favoring the compensatory orthodontic treatment and increasing self-esteem during adolescence.

---

---



# REFERENCES

---

---





## REFERENCES

1. Semb G. A study of facial growth in patients with unilateral cleft lip and palate treated by the Oslo CLP Team. *Cleft Palate Craniofac J.* 1991;28(1):1-21; discussion 46-8.
  2. Will LA. Growth and development in patients with untreated clefts. *The Cleft palate-craniofacial journal.* 2000;37(6):523-6.
  3. Bishara SE. The influence of palatoplasty and cleft length on facial development. *Cleft Palate J.* 1973;10:390-8.
  4. Dahl E. Craniofacial morphology in congenital clefts of the lip and palate. An x-ray cephalometric study of young adult males. *Acta Odontologica Scandinavica.* 1970;28:Suppl 57: 11+.
  5. Hagerty RF, Hill MJ. Facial growth and dentition in the unoperated cleft palate. *Journal of Dental Research.* 1963;42(1):412-21.
  6. Isiekwe M, Sowemimo G. Cephalometric findings in a normal Nigerian population sample and adult Nigerians with unrepaired clefts. *The Cleft palate journal.* 1984;21(4):323-8.
  7. Graber TM. A Cephalometric Analysis of the Developmental Pattern and Facial Morphology in Cleft Palate\*. *The Angle Orthodontist.* 1949;19(2):91-100.
  8. Mars M, Houston WJ. A preliminary study of facial growth and morphology in unoperated male unilateral cleft lip and palate subjects over 13 years of age. *Cleft Palate J.* 1990;27(1):7-10.
  9. Mestre J, Subtelny J. A comparative cephalometric analysis of untreated cleft palate adults and normal adults. *Cleft Palate Bull.* 1960;10(7).
  10. Ortiz-Monasterio F, Serrano A, Barrera G, Rodriguez-Hoffman H, Vinageras E. A study of untreated adult cleft palate patients. *Plast Reconstr Surg.* 1966;38(1):36-41.
-

11. Yoshida H, Nakamura A, Michi K-i, Go-Ming W, Kan L, Wei-Liu Q. Cephalometric analysis of maxillofacial morphology in unoperated cleft palate patients. *The Cleft palate-craniofacial journal*. 1992;29(5):419-24.
  12. Capelozza L, Normando ADC, daSilva OG. Isolated influences of lip and palate surgery on facial growth: Comparison of operated and unoperated male adults with UCLP. *Cleft Palate-Cran J*. 1996;33(1):51-6.
  13. Graber TM. The congenital cleft palate deformity. *J Am Dent Assoc*. 1954;48(4):375-95.
  14. Kuijpers-Jagtman AM, Long RE. The influence of surgery and orthopedic treatment on maxillofacial growth and maxillary arch development in patients treated for orofacial clefts. *The Cleft Palate-Craniofacial Journal*. 2000;37(6):527-.
  15. Liao YF, Mars M. Long-term effects of lip repair on dentofacial morphology in patients with unilateral cleft lip and palate. *Cleft Palate Craniofac J*. 2005;42(5):526-32.
  16. Aduss H. Craniofacial growth in complete unilateral cleft lip and palate. *Angle Orthod*. 1971;41(3):202-13.
  17. Dogan S, Oncag G, Akin Y. Craniofacial development in children with unilateral cleft lip and palate. *Br J Oral Maxillofac Surg*. 2006;44(1):28-33.
  18. Hayashi I, Sakuda M, Takimoto K, Miyazaki T. Craniofacial growth in complete unilateral cleft lip and palate: a roentgeno-cephalometric study. *Cleft Palate J*. 1976;13:215-37.
  19. Seo YJ, Park JW, Kim YH, Baek SH. Initial growth pattern of children with cleft before alveolar bone graft stage according to cleft type. *Angle Orthod*. 2011;81(6):1103-10.
  20. Silva Jr OG, Corrêa Normando AD, Capelozza Jr L. Mandibular morphology and spatial position in patients with clefts: intrinsic or iatrogenic? *The Cleft palate-craniofacial journal*. 1992;29(4):369-75.
  21. Ross RB. The clinical implications of facial growth in cleft lip and palate. *Cleft Palate J*. 1970;7:37-47.
- 
-

22. Liao YF, Mars M. Long-term effects of palate repair on craniofacial morphology in patients with unilateral cleft lip and palate. *Cleft Palate Craniofac J.* 2005;42(6):594-600.
  23. Borzabadi-Farahani A, Lane CJ, Yen SL. Late maxillary protraction in patients with unilateral cleft lip and palate: a retrospective study. *Cleft Palate Craniofac J.* 2014;51(1):e1-e10.
  24. Buschang PH, Porter C, Genecov E, Genecov D, Sayler KE. Face mask therapy of preadolescents with unilateral cleft lip and palate. *Angle Orthod.* 1994;64(2):145-50.
  25. Dogan S. The effects of face mask therapy in cleft lip and palate patients. *Ann Maxillofac Surg.* 2012;2(2):116-20.
  26. Susami T, Okayasu M, Inokuchi T, Ohkubo K, Uchino N, Uwatoko K, et al. Maxillary protraction in patients with cleft lip and palate in mixed dentition: cephalometric evaluation after completion of growth. *Cleft Palate Craniofac J.* 2014;51(5):514-24.
  27. Tindlund RS, Rygh P. Maxillary protraction: different effects on facial morphology in unilateral and bilateral cleft lip and palate patients. *The Cleft palate-craniofacial journal.* 1993;30(2):208-21.
  28. Vieira GdL, Menezes LM, Lima EMS, Rizzatto S. Dentoskeletal effects of maxillary protraction in cleft patients with repetitive weekly protocol of alternate rapid maxillary expansions and constrictions. *The Cleft Palate-Craniofacial Journal.* 2009;46(4):391-8.
  29. Cevidanes L, Baccetti T, Franchi L, McNamara JA, Jr., De Clerck H. Comparison of two protocols for maxillary protraction: bone anchors versus face mask with rapid maxillary expansion. *Angle Orthod.* 2010;80(5):799-806.
  30. De Clerck H, Cevidanes L, Baccetti T. Dentofacial effects of bone-anchored maxillary protraction: a controlled study of consecutively treated Class III patients. *Am J Orthod Dentofacial Orthop.* 2010;138(5):577-81.
  31. De Clerck H, Nguyen T, de Paula LK, Cevidanes L. Three-dimensional assessment of mandibular and glenoid fossa changes after bone-anchored Class III intermaxillary traction. *Am J Orthod Dentofacial Orthop.* 2012;142(1):25-31.
-

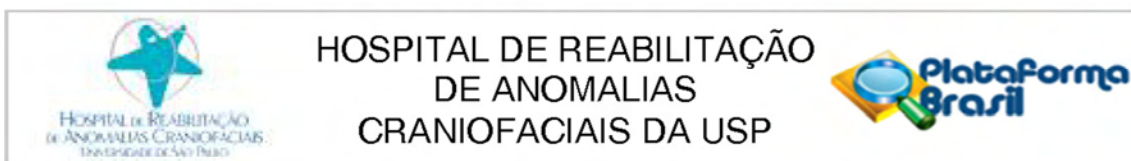
32. Nguyen T, Cevidanes L, Cornelis MA, Heymann G, de Paula LK, De Clerck H. Three-dimensional assessment of maxillary changes associated with bone anchored maxillary protraction. *Am J Orthod Dentofacial Orthop*. 2011;140(6):790-8.
33. Bishara SE, Jakobsen JR, Krause JC, Sosa-Martinez R. Cephalometric comparisons of individuals from India and Mexico with unoperated cleft lip and palate. *Cleft Palate J*. 1986;23(2):116-25.
34. Ortiz-Monasterio F, Rebeil AS, Valderrama M, Cruz R. Cephalometric measurements on adult patients with non-operated cleft palates. *Plast Reconstr Surg Transplant Bull*. 1959;24(1):53-61.

**ANNEX**

---

---





## PARECER CONSUBSTANCIADO DO CEP

### DADOS DO PROJETO DE PESQUISA

**Título da Pesquisa:** Avaliação tridimensional da protração ortopédica da maxila com miniplacas em pacientes com fissura labiopalatina

**Pesquisador:** Marília Sayako Yatabe

**Área Temática:**

**Versão:** 2

**CAAE:** 34407914.6.0000.5441

**Instituição Proponente:** Hospital de Reabilitação de Anomalias Craniofaciais da USP

**Patrocinador Principal:** Financiamento Próprio

### DADOS DO PARECER

**Número do Parecer:** 819.693

**Data da Relatoria:** 30/09/2014

#### Apresentação do Projeto:

É um estudo observacional de dados secundários. Serão avaliados exames de tomografia computadorizada de feixe cônico realizados antes e após a utilização de elásticos intermaxilares apoiados em miniplacas instaladas na maxila e na mandíbula. Esses exames serão comparados por meio de análises tridimensionais.

A amostra dessa pesquisa será composta por exames de TCFC pertencentes ao arquivo do HRAC-USP que vem sendo adquiridos durante a pesquisa "Avaliação da protração ortopédica da maxila com miniplacas em pacientes com fissura labiopalatina", tese de Doutorado do aluno Renato André de Souza Faco, aprovado pelo Comitê de Ética sob o protocolo número 52/2012.

#### Objetivo da Pesquisa:

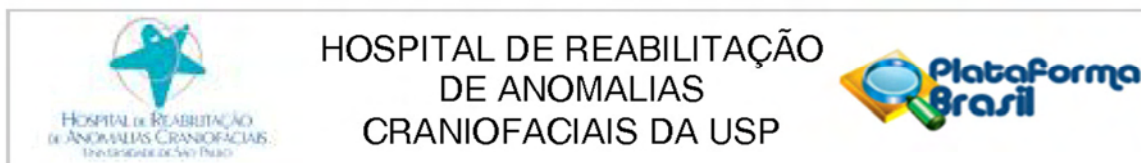
O presente trabalho tem por objetivo identificar os efeitos dentoalveolares da mecânica de protração maxilar ancorada em miniplacas em pacientes com fissuras labiopalatinas completas e unilaterais com deficiência maxilar moderada a severa. A hipótese nula é de que essa mecânica não ocasiona alterações na relação maxilomandibular no sentido anteroposterior.

#### Avaliação dos Riscos e Benefícios:

Os autores afirmaram que:

"Riscos: Não se aplica, pois serão utilizados dados secundários.

**Endereço:** SILVIO MARCHIONE 3-20  
**Bairro:** VILA NOVA CIDADE UNIVERSITARIA      **CEP:** 17.012-900  
**UF:** SP      **Município:** BAURU  
**Telefone:** (14)3235-8421      **Fax:** (14)3234-7818      **E-mail:** uep\_projeto@centrinho.usp.br



Continuação do Parecer: 819.693

Benefícios: Não se aplica, pois serão utilizados dados secundários."

**Comentários e Considerações sobre a Pesquisa:**

O projeto havia ficado com pendência devido à discrepâncias entre o projeto anexado e as informações da plataforma Brasil. Os autores esclareceram as pendências, ressaltando que se trata de projeto com imagens de arquivo (observacional retrospectivo), sendo assim removeram o TCLE.

**Considerações sobre os Termos de apresentação obrigatória:**

Carta de encaminhamento dos pesquisadores aos CEP;  
Formulário HRAC;  
Folha de Rosto Plataforma Brasil;  
Termo de Compromisso de Manuseio de Informações;  
Formulário de Permissão para uso de Registros para Fins Científicos;  
Termo de Compromisso de Tornar Públicos os Resultados da Pesquisa e Destinação de Materiais ou Dados Coletados;  
Análise Crítica dos Riscos e Benefícios;  
Critérios para Suspender ou Encerrar as Pesquisas;  
Termo de Compromisso do Pesquisador Responsável.

**Recomendações:**

Não se aplica.

**Conclusões ou Pendências e Lista de Inadequações:**

Como os pesquisadores esclareceram as pendências, sugiro aprovação.

**Situação do Parecer:**

Aprovado

**Necessita Apreciação da CONEP:**

Não

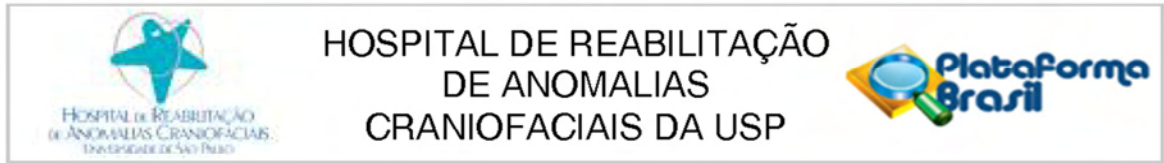
**Considerações Finais a critério do CEP:**

O pesquisador deve atentar que o projeto de pesquisa aprovado por este CEP refere-se ao protocolo submetido para avaliação. Portanto, conforme a Resolução CNS 466/12, o pesquisador é responsável por "desenvolver o projeto conforme delineado", se caso houver alterações nesse projeto, este CEP deverá ser comunicado em emenda via Plataforma Brasil, para nova avaliação.

Cabe ao pesquisador notificar via Plataforma Brasil o relatório final para avaliação, assim como os relatórios semestrais, os Termos de Consentimento Livre e Esclarecidos e/ou outros Termos

**Endereço:** SILVIO MARCHIONE 3-20  
**Bairro:** VILA NOVA CIDADE UNIVERSITARIA      **CEP:** 17.012-900  
**UF:** SP      **Município:** BAURU  
**Telefone:** (14)3235-8421      **Fax:** (14)3234-7818      **E-mail:** uep\_projeto@centrinho.usp.br





Continuação do Parecer: 819.693

obrigatórios, quando solicitados no parecer.

BAURU, 06 de Outubro de 2014

---

**Assinado por:**  
**Marcia Ribeiro Gomide**  
**(Coordenador)**

**Endereço:** SILVIO MARCHIONE 3-20  
**Bairro:** VILA NOVA CIDADE UNIVERSITARIA      **CEP:** 17.012-900  
**UF:** SP      **Município:** BAURU  
**Telefone:** (14)3235-8421      **Fax:** (14)3234-7818      **E-mail:** uep\_projeto@centrinho.usp.br