


SPECIAL REPORT

International League Against Epilepsy classification and definition of epilepsy syndromes with onset in childhood: Position paper by the ILAE Task Force on Nosology and Definitions

Nicola Specchio¹  | Elaine C. Wirrell²  | Ingrid E. Scheffer³  | Rima Nabhout⁴  |
 Kate Riney^{5,6}  | Pauline Samia⁷  | Marilisa Guerreiro⁸ | Sam Gwer⁹ |
 Sameer M. Zuberi¹⁰ | Jo M. Wilmschurst¹¹  | Elissa Yozawitz¹²  | Ronit Pressler¹³  |
 Edouard Hirsch¹⁴  | Sam Wiebe¹⁵  | Helen J. Cross¹⁶  | Emilio Perucca^{17,18}  |
 Solomon L. Moshé¹⁹  | Paolo Tinuper^{20,21} | Stéphane Auvin²² 

¹Rare and Complex Epilepsy Unit, Department of Neuroscience, Bambino Gesù Children's Hospital, Scientific Institute for Research and Health Care, Full Member of EpiCARE, Rome, Italy

²Divisions of Child and Adolescent Neurology and Epilepsy, Department of Neurology, Mayo Clinic, Rochester, Minnesota, USA

³Austin Health and Royal Children's Hospital, Florey Institute, Murdoch Children's Research Institute, University of Melbourne, Melbourne, Victoria, Australia

⁴Reference Center for Rare Epilepsies, Department of Pediatric Neurology, Necker-Sick Children Hospital, Public Hospital Network of Paris, member of EpiCARE, Imagine Institute, National Institute of Health and Medical Research, Mixed Unit of Research 1163, University of Paris, Paris, France

⁵Neurosciences Unit, Queensland Children's Hospital, South Brisbane, Queensland, Australia

⁶Faculty of Medicine, University of Queensland, South Brisbane, Queensland, Australia

⁷Department of Pediatrics and Child Health, Aga Khan University, Nairobi, Kenya

⁸Department of Neurology, University of Campinas, Campinas, Brazil

⁹School of Medicine, Kenyatta University, and Afya Research Africa, Nairobi, Kenya

¹⁰Paediatric Neurosciences Research Group, Royal Hospital for Children and Institute of Health & Wellbeing, member of EpiCARE, University of Glasgow, Glasgow, UK

¹¹Department of Paediatric Neurology, Red Cross War Memorial Children's Hospital, Neuroscience Institute, University of Cape Town, Cape Town, South Africa

¹²Isabelle Rapin Division of Child Neurology of the Saul R. Korey Department of Neurology, Montefiore Medical Center, Bronx, New York, USA

¹³Programme of Developmental Neurosciences, University College London National Institute for Health Research Biomedical Research Centre Great Ormond Street Institute of Child Health, Department of Clinical Neurophysiology, Great Ormond Street Hospital for Children, London, UK

¹⁴Neurology Epilepsy Units "Francis Rohmer", INSERM 1258, FMTS, Strasbourg University, Strasbourg, France

¹⁵Department of Clinical Neurosciences, University of Calgary, Calgary, Alberta, Canada

¹⁶Programme of Developmental Neurosciences, University College London National Institute for Health Research Biomedical Research Centre Great Ormond Street Institute of Child Health, Great Ormond Street Hospital for Children, and Young Epilepsy Lingfield, London, UK

¹⁷Department of Neuroscience, Monash University, Melbourne, Victoria, Australia

¹⁸Department of Medicine, Austin Health, University of Melbourne, Heidelberg, Victoria, Australia

¹⁹Isabelle Rapin Division of Child Neurology, Saul R. Korey Department of Neurology, and Departments of Neuroscience and Pediatrics, Albert Einstein College of Medicine and Montefiore Medical Center, Bronx, New York, USA

²⁰Department of Biomedical and Neuromotor Sciences, University of Bologna, Bologna, Italy

²¹Institute of Neurological Sciences, Scientific Institute for Research and Health Care, Bologna, Italy

²²Robert Debré Hospital, Public Hospital Network of Paris, NeuroDiderot, National Institute of Health and Medical Research, Department Médico-Universitaire Innovation Robert-Debré, Pediatric Neurology, University of Paris, Paris, France

This is an open access article under the terms of the [Creative Commons Attribution](https://creativecommons.org/licenses/by/4.0/) License, which permits use, distribution and reproduction in any medium, provided the original work is properly cited.

© 2022 The Authors. *Epilepsia* published by Wiley Periodicals LLC on behalf of International League Against Epilepsy.

Correspondence

Elaine C. Wirrell, Child and Adolescent Neurology, Mayo Clinic, 200 First St SW, Rochester, MN 55902, USA.
Email: wirrell.elaine@mayo.edu

Abstract

The 2017 International League Against Epilepsy classification has defined a three-tier system with epilepsy syndrome identification at the third level. Although a syndrome cannot be determined in all children with epilepsy, identification of a specific syndrome provides guidance on management and prognosis. In this paper, we describe the childhood onset epilepsy syndromes, most of which have both mandatory seizure type(s) and interictal electroencephalographic (EEG) features. Based on the 2017 Classification of Seizures and Epilepsies, some syndrome names have been updated using terms directly describing the seizure semiology. Epilepsy syndromes beginning in childhood have been divided into three categories: (1) self-limited focal epilepsies, comprising four syndromes: self-limited epilepsy with centrotemporal spikes, self-limited epilepsy with autonomic seizures, childhood occipital visual epilepsy, and photosensitive occipital lobe epilepsy; (2) generalized epilepsies, comprising three syndromes: childhood absence epilepsy, epilepsy with myoclonic absence, and epilepsy with eyelid myoclonia; and (3) developmental and/or epileptic encephalopathies, comprising five syndromes: epilepsy with myoclonic–atonic seizures, Lennox–Gastaut syndrome, developmental and/or epileptic encephalopathy with spike-and-wave activation in sleep, hemiconvulsion–hemiplegia–epilepsy syndrome, and febrile infection-related epilepsy syndrome. We define each, highlighting the mandatory seizure(s), EEG features, phenotypic variations, and findings from key investigations.

KEYWORDS

benign occipital epilepsy, childhood epilepsy with centrotemporal spikes, continuous spike-and-wave in sleep, eyelid myoclonia, febrile infection-related epilepsy syndrome, hemiconvulsion–hemiplegia–epilepsy syndrome, Landau–Kleffner syndrome, Lennox–Gastaut syndrome, myoclonic absences, myoclonic atonic, Panayiotopoulos syndrome

1 | INTRODUCTION

The goal of this paper is to describe epilepsy syndromes that begin in childhood (age 2–12 years). Additional syndromes that have a variable age at onset, including in childhood, are described in the paper on epilepsy syndromes with onset at a variable age.¹ The childhood onset syndromes can be broadly divided into three main groups: (1) self-limited focal epilepsies (SeLFES); (2) generalized epilepsy syndromes, which are thought to have a genetic basis; and (3) developmental and/or epileptic encephalopathies (DEEs), which often have both focal and generalized seizures, including Lennox–Gastaut syndrome (LGS), developmental epileptic encephalopathy with spike-and-wave activation in sleep (DEE-SWAS), and epileptic encephalopathy with spike-and-wave activation in sleep (EE-SWAS), or may have generalized seizures alone, such as epilepsy with myoclonic atonic seizures (EMaTS), or focal/multifocal seizures alone, such as hemiconvulsion–hemiplegia–epilepsy syndrome (HHE) and febrile infection-related epilepsy syndrome (FIRES).

Key Points

- The ILAE produced a classification of epileptic syndromes presenting in childhood
- Syndromes with onset in childhood are divided into three categories: self-limited focal epilepsies, generalized epilepsies, and developmental and/or epileptic encephalopathies
- Each syndrome has mandatory seizure types, EEG features, age at onset, and findings from key investigations
- Precise identification of an epileptic syndrome can provide useful information on prognosis and management

Childhood is also the typical age of onset of childhood absence epilepsy (CAE); this syndrome is covered in a separate paper on the idiopathic generalized epilepsy (IGE) syndromes.²

Recognition of these childhood syndromes requires careful analysis of seizure semiology, evolution over time, and the developmental course of the child, as well as electroencephalographic (EEG) features (background, interictal, and ictal patterns) and, in some cases, brain magnetic resonance imaging (MRI) and genetic studies. At times, childhood syndromes may have evolved from other epilepsy syndromes or types, such as infantile epileptic spasms syndrome, which may evolve to LGS, or self-limited epilepsy with centrotemporal spikes (SeLECTS; formerly known as benign rolandic epilepsy or benign epilepsy with centrotemporal spikes) or structural focal epilepsy evolving to EE-SWAS. In other syndromes, children with prior normal development present with a severe, acute encephalopathy followed by drug-resistant epilepsy, as typically seen in FIRES, or HHE. Moreover, for some SeLFEs, there may be overlap with the IGEs or even evolution to them, reflecting the patient's underlying susceptibility to epileptic seizures.^{3,4}

The exact proportion of children with epilepsy who meet criteria for a specific syndrome has not been well

studied prospectively; however, retrospective data suggest that an epilepsy syndrome is identified in at least one third of cases.^{5,6}

This paper will address the specific clinical and laboratory features of epilepsy syndromes that begin in childhood and provide rationale for any significant nomenclature or definitional changes. Table 1 summarizes the epilepsy syndromes, with updated nomenclature and acronyms used in this paper.

2 | METHODOLOGY

The methodology for syndrome definitions is described in "Methodology for Classification and Definition of Epilepsy Syndromes with List of Syndromes: Report of the ILAE Task Force on Nosology and Definitions."⁷ A working group consisting of Task Force members with expertise in pediatrics was convened. One member of the group was assigned to draft a template for each proposed syndrome, using data from a literature review through July 2019, the

TABLE 1 Childhood epilepsy syndromes

Self-limited focal epilepsies		Genetic generalized epilepsies		DEEs	
Epilepsy syndromes with focal seizures	Formerly known as	Epilepsy syndromes with generalized seizures	Formerly known as	DEEs	Formerly known as
SeLECTS	Childhood epilepsy with centrotemporal spikes, (benign) Rolandic epilepsy, (benign) epilepsy with centrotemporal spikes	CAE ^a	Pyknolepsy, petit mal	EMaTS	Doose syndrome
SeLEAS	Panayiotopoulos syndrome, early onset (benign) occipital epilepsy	EEM	Jeavons syndrome	LGS	No changes
COVE	Late onset (benign) occipital epilepsy or idiopathic childhood occipital epilepsy–Gastaut type	EMA	Bureau and Tassinari syndrome	DEE-SWAS EE-SWAS Landau–Kleffner syndrome (subtype of EE-SWAS)	Epileptic encephalopathy with continuous spike-and-wave in sleep, atypical (benign) partial epilepsy (pseudo-Lennox syndrome)
POLE	Idiopathic photosensitive occipital lobe epilepsy			FIRES HHE	AERRPS, DESC No changes

Note: This table includes identified syndromes of this age group and not all epilepsy types.

Abbreviations: AERRPS, acute encephalitis with refractory, repetitive partial seizures; CAE, childhood absence epilepsy; COVE, childhood occipital visual epilepsy; DEE, developmental and/or epileptic encephalopathy; DEE-SWAS, developmental epileptic encephalopathy with spike-and-wave activation in sleep; DESC, devastating epileptic encephalopathy in school-aged children; EEM, epilepsy with eyelid myoclonia; EE-SWAS, epileptic encephalopathy with spike-and-wave activation in sleep; EMA, epilepsy with myoclonic absence; FIRES, febrile infection-related epilepsy syndrome; HHE, hemiconvulsion–hemiplegia–epilepsy syndrome; LGS, Lennox–Gastaut syndrome; POLE, photosensitive occipital lobe epilepsy; SeLEAS, self-limited epilepsy with autonomic seizures; SeLECTS, self-limited epilepsy with centrotemporal spikes.

^aCAE is addressed in the paper on idiopathic generalized epilepsies.²

most recent edition of “Epileptic Syndromes of Infancy, Childhood and Adolescence,”⁸ and current criteria listed on www.epilepsydiagnosis.org, which was circulated to all members. Every draft was discussed at either an online or an in-person meeting of Task Force members and modified based on further input and clinical experience of Task Force members, together with additional literature searches.

For each syndrome, mandatory features (must be present for diagnosis) and exclusionary features (must be absent for diagnosis) were proposed, along with alerts (features that are absent in the vast majority of cases, but rarely can be seen). Alerts should lead to caution in diagnosing the syndrome and consideration of other conditions. A Delphi process was then undertaken, surveying all Task Force members, in addition to recognized external experts in pediatric epilepsy, from all International League Against Epilepsy (ILAE) regions (Europe, Oceania/Asia, North America, Latin America, Africa, and the Eastern Mediterranean region), to reach consensus.

For each syndrome, the core diagnostic criteria, along with a summary of other features, are provided. Based on the Delphi process, tables with the mandatory and exclusionary criteria and alerts for each syndrome are provided at the end of the article.

Proposed syndromes are subdivided into (1) SeLFEs of childhood, (2) genetic generalized epilepsies, and (3) developmental and/or epileptic encephalopathies of childhood.

3 | SELF-LIMITED FOCAL EPILEPSIES OF CHILDHOOD

Focal epilepsies with onset during childhood are often self-limited and usually of unknown cause.^{9,10} Many self-limited childhood focal epilepsies have a characteristic electroclinical presentation and fall within one of the SeLFE syndromes (Figure 1). These conditions have been referred to in the past as “benign” or “idiopathic.”

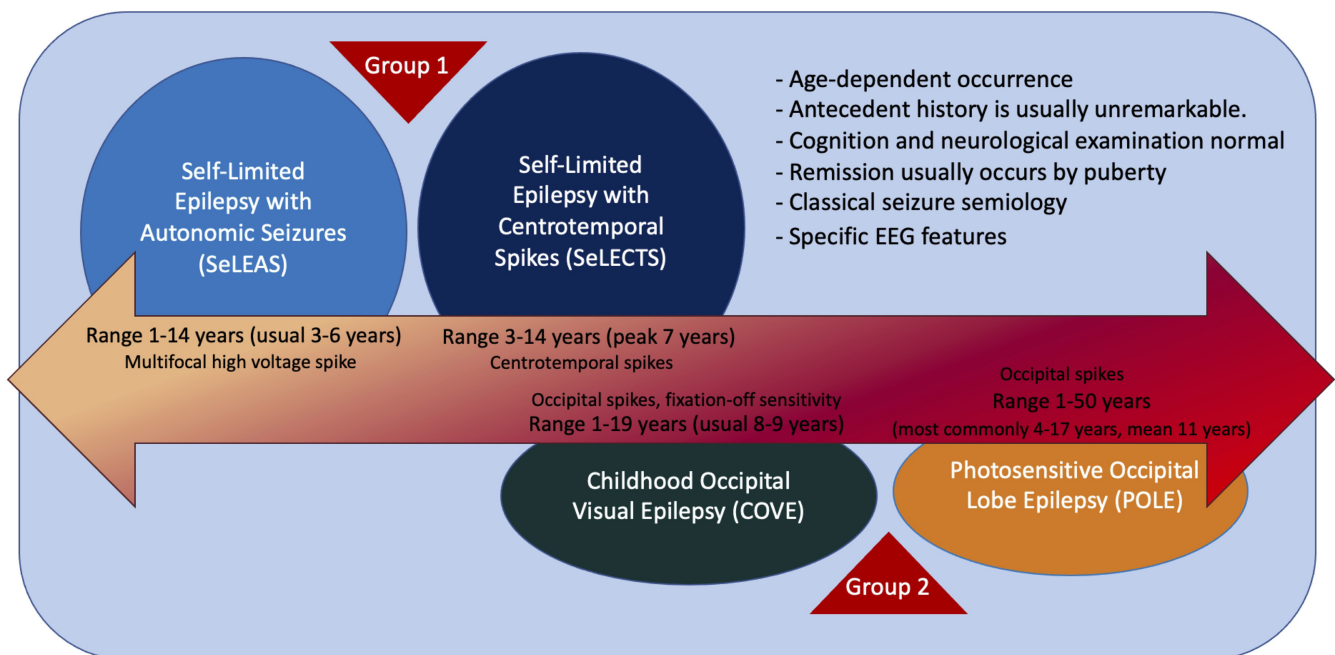


FIGURE 1 Self-limited focal epilepsies of childhood (SeLFE) syndromes are a group of conditions characterized by age-dependent occurrence in otherwise normal children. Cognition and neurological evaluation are typically normal. Remission occurs in almost all patients by puberty. Presumed genetic factors have an important role. Seizure semiology and electroencephalographic (EEG) features are specific for each of the syndromes included in this group. Within the SeLFEs, we recognize two levels of syndromes, based on the long-term prognosis. The first subgroup (Group 1) includes two syndromes: the former syndromes of childhood epilepsy with centrotemporal spikes or benign epilepsy of childhood with centrotemporal spikes or benign Rolandic epilepsy, now renamed as self-limited epilepsy with centrotemporal spikes; and of Panayiotopoulos syndrome or early onset benign occipital epilepsy, now renamed as self-limited epilepsy with autonomic seizures. The second subgroup (Group 2) includes two syndromes: the former syndromes of late onset benign occipital epilepsy or Gastaut syndrome or idiopathic childhood occipital epilepsy–Gastaut type, now renamed as childhood occipital visual epilepsy; and of idiopathic photosensitive occipital lobe epilepsy, now renamed as photosensitive occipital lobe epilepsy. In Group 1, remission is expected in all cases. In Group 2, remission is highly likely; however, a few patients may have persistence of seizures after adolescence. In the figure are represented the age at onset and EEG findings for each of the syndromes

The term “benign” is no longer recommended, as it fails to acknowledge the comorbidities present in some individuals. The term “idiopathic epilepsy” is now restricted to describing the four syndromes termed the idiopathic generalized epilepsies. Given the typical evolution of these conditions, with age-dependent onset and remission, it has been proposed to use the term “self-limited” when referring to such epilepsies.¹¹ The Nosology and Definitions Task Force of the ILAE proposes the term “self-limited focal epilepsies of childhood” to encompass this group of epilepsy syndromes.

Presumed genetic factors play an important etiological role, as supported by the higher incidence of a positive family history of epilepsy and age-dependent, focal EEG abnormalities. However, no specific genetic variants have been identified so far. Rarely, genetic variants may be associated with more severe phenotypes of these syndromes (i.e., *GRIN2A* in SeLECTS evolving to EE-SWAS).^{12–15}

The SeLFES account for up to 25% of all pediatric epilepsies.^{16,17} These syndromes share the following features:

1. Age-dependent occurrence, specific for each syndrome.
2. No significant structural lesion of the brain.
3. Birth, neonatal, and antecedent history is usually unremarkable.
4. Cognition and neurological examination are typically normal.
5. Remission usually occurs by puberty.
6. Pharmacoresponsiveness if treated.
7. Genetic predisposition for the EEG trait.
8. Classic seizure semiology for each syndrome. Seizures are focal motor or sensory with or without impaired awareness and may evolve to bilateral tonic-clonic seizures.
9. Specific EEG features: epileptiform abnormalities with distinctive morphology and location (depending on the epilepsy syndrome), often activated with sleep. The EEG has a normal background.

In most cases, children with SeLFES have features characteristic of one specific syndrome. However, some have a mixed picture, or may evolve from one syndrome to another over time.¹⁸ Furthermore, rare cases also show overlap with the IGEs.^{3,4}

Within the SeLFES, we recognize two levels of syndromes, based on the long-term prognosis.

The first subgroup includes two syndromes:

1. Self-limited epilepsy with centrotemporal spikes (SeLECTS; formerly called childhood epilepsy with centrotemporal spikes, benign epilepsy of childhood with centrotemporal spikes, or benign Rolandic epilepsy).

2. Self-limited epilepsy with autonomic seizures (SeLEAS; formerly called Panayiotopoulos syndrome or early onset benign occipital epilepsy).

The second subgroup includes two syndromes:

1. Childhood occipital visual epilepsy (COVE; formerly called late onset benign occipital epilepsy, Gastaut syndrome, or idiopathic childhood occipital epilepsy–Gastaut type; rare cases may begin around puberty/adolescence).
2. Photosensitive occipital lobe epilepsy (POLE; formerly called idiopathic photosensitive occipital lobe epilepsy).

In the first group, remission in both SeLECTS and SeLEAS is expected in all cases by adolescence, and if treatment is started it should not be continued beyond that age.

In COVE and POLE, the remission is highly likely; however, a few patients may experience a persistence of seizures after adolescence. Chronic treatment with anti-seizure medications (ASMs) is often prescribed. In most cases, ASMs can be successfully discontinued without seizure recurrence; however, rare cases may require a longer duration of ASM treatment.

All the above nomenclature changes were carefully evaluated by our working group. The main goal was to have a uniform classification and terminology for the self-limited childhood focal epilepsy syndromes. Our aim was to improve diagnosis and management of these epilepsy syndromes, for both counseling and treatment purposes.

3.1 | Self-limited epilepsy with centrotemporal spikes

SeLECTS is a self-limited epilepsy syndrome, formerly known as benign Rolandic epilepsy or benign epilepsy with centrotemporal spikes, which begins in children in their early school years (Table 2).¹⁹ Seizures are often brief, and typically involve focal clonic or tonic activity of the throat/tongue and one side of the lower face, which may then evolve to a focal to bilateral tonic-clonic seizure. This epilepsy syndrome occurs in children who are otherwise neurologically and cognitively normal, and imaging studies, if done, show no causal lesion. The EEG shows a normal background with high-amplitude centrotemporal sharp-and-slow-wave complexes, which are activated in drowsiness and sleep.²⁰ Seizures cease by puberty. The finding of a positive family history and focal EEG abnormalities in family members supports underlying genetic factors contributing to the etiology of SeLECTS.^{21,22}

TABLE 2 Self-limited epilepsy with centrottemporal spikes

	Mandatory	Alerts	Exclusionary
Seizures	Focal seizures with dysarthria, sialorrhea, dysphasia, and unilateral clonic or tonic-clonic movement of mouth in wakefulness or sleep and/or nocturnal focal to bilateral tonic-clonic seizures in sleep only If seizures occur during sleep, they are seen within 1 h of falling asleep or 1–2 h prior to awakening	Focal motor or generalized convulsive status epilepticus >30 min Usual seizure frequency more than daily Daytime seizures only	Generalized tonic-clonic seizures during wakefulness Atypical absences Seizures with gustatory hallucinations, fear, and autonomic features
EEG	High-amplitude, centrottemporal biphasic epileptiform abnormalities	Sustained focal slowing not limited to the postictal phase Persistently unilateral centrottemporal abnormalities on serial EEGs Lack of sleep activation of centrottemporal abnormalities	
Age at onset		>12 years	<3 years or >14 years
Development at onset		Moderate to profound intellectual disability	Neurocognitive regression with a continuous spike-and-wave pattern in sleep (suggests EE-SWAS)
Neurological exam		Hemiparesis or focal neurological findings, other than Todd paresis	
Imaging			Causal lesion on brain MRI
Course of illness	Remission by mid to late adolescence No developmental regression		Neurocognitive regression with a continuous spike-and-wave pattern in sleep suggests evolution to EE-SWAS
An MRI is not required for diagnosis but should be strongly considered in cases with alerts. An ictal EEG is not required for diagnosis.			
Syndrome without laboratory confirmation: In resource-limited regions, SeLECTs can be diagnosed without EEG and MRI in children without alerts who meet all other mandatory and exclusionary criteria.			

Note: Alert criteria are absent in the vast majority of cases, but rarely can be seen. Their presence should result in caution in diagnosing the syndrome and consideration of other conditions.

Abbreviations: EEG, electroencephalogram; EE-SWAS, epileptic encephalopathy with spike-and-wave activation in sleep; MRI, magnetic resonance imaging; SeLECTs, self-limited epilepsy with centrottemporal spikes.

3.1.1 | Epidemiology

SeLECTs is the most frequent SeLFE and accounts for approximately 6%–7% of all childhood epilepsies.^{5,23} Its incidence is approximately 6.1 per 100 000 children aged <16 years per year.^{24,25}

3.1.2 | Clinical context

The age at onset is usually between 4 and 10 years (range = 3–14 years) in 90% of patients, with a peak at approximately 7 years.²⁶ Both sexes are affected, with a slight male predominance (60%).^{25,27,28}

Antecedent, birth, and neonatal history is typically normal. A history of febrile seizures is seen in 5%–15%

of cases. Rarely, a history of SeLEAS may be present.²⁹ Development, cognition, neurological examination, and head size prior to seizure onset are typically normal. SeLECTs may be seen in children with a history of prior neurological injury or intellectual disability, but these features are considered coincidental and not causal. Prior to epilepsy onset, attention-deficit/hyperactivity disorder and specific cognitive function deficits, mainly related to language and executive function, may be seen.³⁰

3.1.3 | Course of illness

Seizures usually resolve by puberty but can occasionally continue until 18 years of age.³¹ While the epilepsy

is active, behavioral and neuropsychological deficits may rarely emerge or worsen, particularly in language and executive functioning.^{32,33} These deficits often improve or resolve with age.³⁴ The social outcome in adults is very good.³⁵ Seizures typically respond well to ASM. The prognosis for seizure remission is excellent even for those whose seizures are initially difficult to control.³⁶

3.1.4 | Seizures

Focal seizures with characteristic frontoparietal opercular features and/or nocturnal bilateral tonic-clonic seizures are mandatory for diagnosis. Seizures are brief, typically <2–3 min, usually few in number (most children have fewer than 10 lifetime seizures), and may occur sporadically, with frequent seizures seen over a few days or weeks and then several months passing before the next seizure.

Characteristic semiology of the focal seizures includes (1) somatosensory symptoms, with unilateral numbness or paresthesia of the tongue, lips, gums, and inner cheek²⁷; (ii) orofacial motor signs, specifically tonic or clonic contraction of one side of the face, mouth, and tongue, then involving one side of the face; (iii) speech arrest—children have difficulty or are unable to speak (dysarthria or anarthria) but can understand language; and (iv) sialorrhea, a characteristic ictal symptom—it is unclear whether this is due to increased salivation, swallowing disturbance, or both. In some cases, focal seizures in sleep evolve rapidly to tonic-clonic activity of the ipsilateral upper limb, to an ipsilateral hemiclonic seizure, or to a focal to bilateral tonic-clonic seizure. Todd paresis may occur postictally. In nocturnal seizures, the initial focal component may often not be witnessed.

Seizures occur during sleep in 80%–90% of patients and only while awake in <20% of children.³⁷ In seizures associated with SeLECTS, cognitive (e.g., gustatory hallucinations), emotional (e.g., fear), and autonomic features are not seen. Moreover, focal motor or focal to bilateral tonic-clonic status epilepticus, defined as seizure persisting for >30 min, is rare³⁷ and, if present, should lead to review of the diagnosis. The occurrence of atypical absence seizures, focal atonic seizures, and focal motor seizures with negative myoclonus with loss of balance and falls should suggest evolution to EE-SWAS, and evidence of cognitive impairment or regression should be sought.

Generalized tonic-clonic seizures, as distinct from focal to bilateral tonic-clonic seizures, during wakefulness are exclusionary, but may be difficult to differentiate clinically.

3.1.5 | Electroencephalogram

Background activity is typically normal, with the presence of normal sleep architecture. If sustained focal slowing without centrottemporal spikes or diffuse slowing is recorded, another epilepsy syndrome or a structural lesion should be considered, and brain imaging is recommended.

High-amplitude (>200 μ V, peak to trough),³⁸ centrottemporal sharp-and-slow-wave complexes that activate in drowsiness and sleep are mandatory for diagnosis. They are triphasic, high-voltage (100–300 μ V) sharp waves (initial low-amplitude positivity, then high-amplitude negativity followed again by low-amplitude positivity), with a transverse dipole (frontal positivity, temporoparietal negativity), often followed by a high-voltage slow wave.^{37,39} The abnormalities may be isolated or occur in trains of doublets and triplets, and focal, rhythmic, slow activity is occasionally observed in the same region as the spikes. The abnormalities may be unilateral or bilateral and independent (Figure 2A). There may be abnormalities seen outside the centrottemporal region (midline, parietal, frontal, occipital). If a continuous spike-and-wave pattern is present in sleep, the child should be evaluated for progressive language or cognitive impairment or regression. This EEG pattern should only lead to a diagnosis of EE-SWAS if developmental plateauing or regression is present.^{21,40}

A marked increase in the frequency of epileptiform activity in drowsiness and sleep is typical. The EEG pattern may also change such that sharp waves or spike-and-wave complexes have a broader field and become bilaterally synchronous (Figure 2B). In 10%–20% of children, centrottemporal sharp waves or spike-and-wave complexes may be activated by sensory stimulation of the fingers or toes.⁴¹

Seizures are typically infrequent; it is rare to obtain an ictal recording, and there are few published reports in the literature.⁴² Seizures may be accompanied by a brief decrease in amplitude of the background EEG, followed by diffuse sharp wave abnormalities of increasing amplitude, predominantly in one centrottemporal region,⁴² followed by high-amplitude slowing and then a return to the usual interictal EEG (Figure 2C). With focal to bilateral tonic-clonic seizures, ictal rhythms may become bilaterally synchronous (as opposed to generalized) sharp wave or spike-and-wave activity.^{43–45}

3.1.6 | Imaging

Neuroimaging is normal or may show nonspecific findings. If the electroclinical diagnosis of SeLECTS is made and there are no atypical features, neuroimaging is not required. If there are clinical, developmental, or EEG features or evolution inconsistent with this diagnosis,

neuroimaging should be considered. Nonspecific MRI findings, such as hippocampal asymmetry, white matter abnormalities, and enlargement of the lateral ventricles, should not exclude a diagnosis of SeLECTS.⁴⁶ Patients with focal epilepsy due to structural abnormalities such as focal cortical dysplasia, heterotopia, or low-grade brain tumors may mimic SeLECTS but usually show atypical features such as unilateral EEG abnormality or drug resistance.

3.1.7 | Genetics

Genetic factors play an important etiological role, as supported by the higher incidence of a positive family history for epilepsy or febrile seizures, and age-dependent, focal EEG abnormalities in the relatives of SeLECTS patients. Siblings may show the EEG trait of centrotemporal abnormalities in an age-dependent, autosomal dominant fashion without clinical seizures.²² However, the clinical epilepsy syndrome is likely complex in inheritance, as pedigrees with multiple individuals with SeLECTS are very rare.⁴² At this time, there are no identified pathogenic gene variants found in most children with SeLECTS. Heterozygous pathogenic variants in *GRIN2A* can be found in individuals with SeLECTS, who may show evolution to EE-SWAS, with associated language and cognitive impairment.^{13–15} Also, copy number variants have been detected in rare cases.⁴⁷ Other genetic etiologies such as fragile X syndrome (FraX) should be considered.

3.1.8 | Differential diagnosis

Other epilepsies:

- DEE-SWAS or EE-SWAS: Patients with DEE-SWAS may present with similar seizures but can be distinguished by cognitive and language regression. Children with SeLECTS may rarely evolve to this syndrome.
- Focal seizures due to structural brain abnormality.
- Other SeLFES: The morphology of the EEG abnormalities in the various SeLFES may overlap, and their

seizure localization may change with age. If patients present with prolonged focal nonmotor seizures with prominent autonomic features, especially ictal vomiting, SeLEAS should be considered.

- FraX should be excluded in males with intellectual impairment, as EEG changes in FraX may mimic those seen in SeLECTS.^{48,49} In FraX, seizures are most commonly focal impaired awareness seizures, and less likely focal motor without impaired awareness or focal to bilateral tonic-clonic seizures.

3.2 | Self-limited epilepsy with autonomic seizures

SeLEAS, formerly known as Panayiotopoulos syndrome or early onset benign occipital epilepsy, is characterized by the onset in early childhood of focal autonomic seizures that are often prolonged. EEG shows high-amplitude (>200 μ V, peak to trough)³⁸ focal spikes with variable localization that are typically activated by sleep. Seizures are infrequent in most patients, with 25% only having a single seizure. The epilepsy is self-limited, with remission typically within a few years from onset.⁵⁰ The mean duration of the disease is approximately 3 years (Table 3).⁵¹

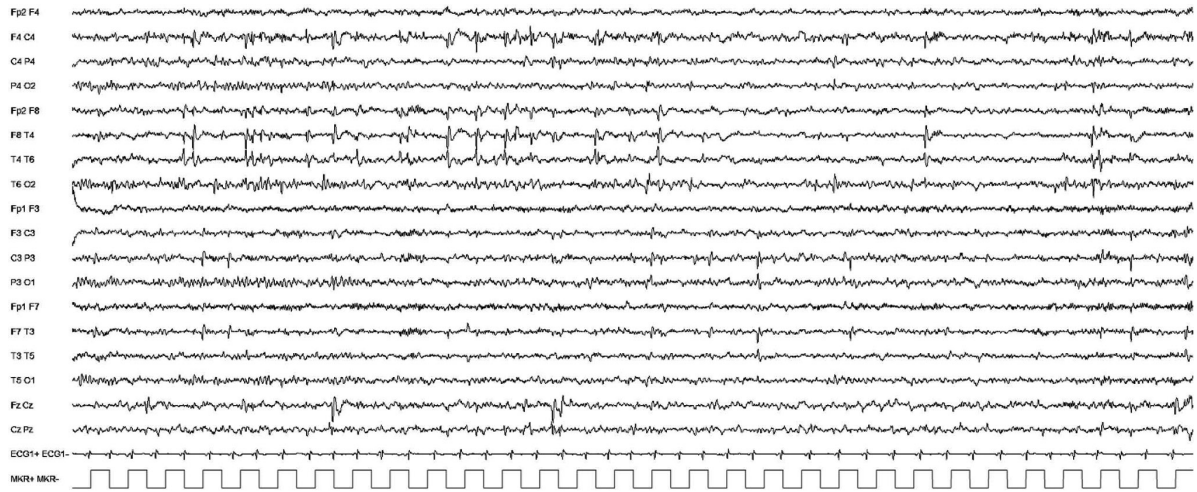3.2.1 | Epidemiology

The prevalence of SeLEAS depends on the age range studied. It accounts for 5% of childhood epilepsies between 1 and 14 years⁵¹ and 13% of childhood epilepsies between 3 and 6 years.⁵² SeLEAS is the most common cause of afebrile nonconvulsive status epilepticus in childhood.⁵³

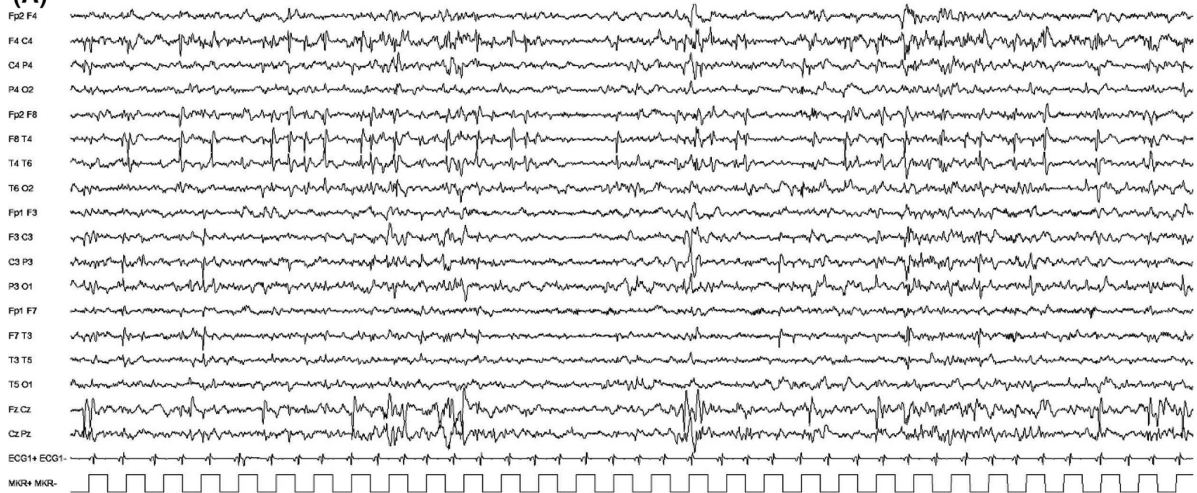
3.2.2 | Clinical context

The usual age at onset is between 3 and 6 years (70% of cases), and ranges from 1 to 14 years.⁵⁴ Both sexes are affected equally. Antecedent and birth history is normal. A history of febrile seizures is seen in 5%–17% of patients. Head size and neurological examination are normal. Development and cognition are normal.^{51,55,56}

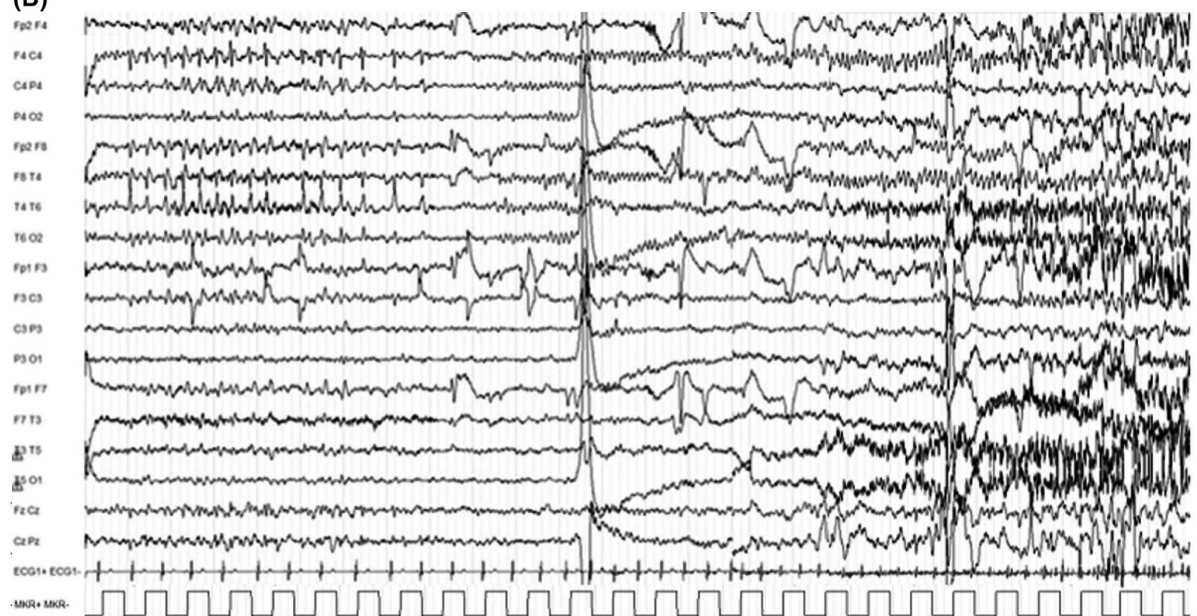
FIGURE 2 Self-limited epilepsy with centrotemporal spikes. Interictal and peri-ictal electroencephalographic (EEG) patterns seen in a 9-year-old child are shown. (A) Awake EEG showing high-amplitude, spike-and-wave abnormalities over C4 and T4 electrodes, in the right centrotemporal region. Abnormalities are isolated or occur in brief sequences. Synchronous or asynchronous stereotypic spikes are seen also over the left central region or over the anterior vertex. (B) Sleep EEG shows an increase in interictal epileptiform abnormalities and a higher amplitude. (C) Peri-ictal EEG. Repetitive spike-and-wave abnormalities are evident over right central and temporal regions. This activity suddenly disappears, and over the right central and temporal region there is low-voltage fast activity that increases in amplitude and decreases in frequency



(A)



(B)



(C)

100 μ v
1 sec

TABLE 3 Self-limited epilepsy with autonomic features

	Mandatory	Alerts	Exclusionary
Seizures	Focal autonomic seizures, with or without impaired awareness Autonomic symptoms often involve prominent retching and vomiting, but may also include malaise, pallor, flushing, abdominal pain, and pupillary or cardiorespiratory changes	Seizure frequency greater than monthly	
EEG	High-amplitude, focal or multifocal epileptiform abnormalities that increase in drowsiness and sleep	Sustained focal slowing not limited to the postictal phase Unilateral focal abnormalities in a consistent focal area across serial EEGs	
Age at onset		<3 years or >8 years	<1 year or >14 years
Development at onset		Moderate to profound intellectual disability	Neurocognitive regression with a continuous spike-and-wave pattern in sleep (suggests EE-SWAS)
Neurological exam		Hemiparesis or focal neurological findings, other than Todd paresis	
Imaging			Causal lesion on brain MRI
Course of illness	Remission by early to mid adolescence No developmental regression		Neurocognitive regression with a continuous spike-and-wave pattern in sleep suggests evolution to EE-SWAS
An MRI is not mandatory for diagnosis but should be done in the presence of any alerts. An ictal EEG is not required for diagnosis.			
Syndrome without laboratory confirmation: In resource-limited regions, at a minimum, an interictal EEG is required to confidently diagnose this syndrome.			

Note: Alert criteria are absent in the vast majority of cases, but rarely can be seen. Their presence should result in caution in diagnosing the syndrome and consideration of other conditions.

Abbreviations: EEG, electroencephalogram; EE-SWAS, epileptic encephalopathy with spike-and-wave activation in sleep; MRI, magnetic resonance imaging.

3.2.3 | Course of illness

Seizure frequency is typically low, with approximately 25% of children having a single seizure only, and the majority having fewer than five seizures in total.⁵⁷ Seizures typically remit within 1–2 years, with normal neurodevelopment, although approximately 20% of patients may evolve to other SeLFES, most commonly SeLECTS.⁵⁷ Rarely, SeLEAS may evolve to EE-SWAS.

3.2.4 | Seizures

Focal autonomic seizures, with or without impaired awareness, are mandatory for diagnosis. Autonomic features

at onset may vary, but most frequently include retching, pallor, flushing, nausea, malaise, or abdominal pain. Vomiting, the most common autonomic manifestation, occurs in approximately 75% of children and leads to misdiagnosis of acute gastroenteritis or migraine. Additional autonomic features include pupillary (e.g., mydriasis), temperature, and cardiorespiratory (breathing, pallor, cyanosis, and heart rate) changes. Syncope may rarely occur. Seizures frequently evolve with eye and/or head deviation, generalized hypotonia, and focal clonic (hemiclonic) or focal to bilateral tonic-clonic seizure activity. Awareness is usually preserved at seizure onset and may fluctuate in degree of impairment as the seizure progresses. More than 70% of seizures occur from sleep. Seizures are often prolonged and can last longer than 30 min.¹⁷

3.2.5 | Electroencephalogram

The background activity is normal. If persistent focal slowing is present, a structural brain abnormality should be sought as an alternative etiology. Diffuse slowing is not seen except in the postictal period.

Multifocal, high-voltage sharp waves or spike-and-wave complexes are typically seen, often over the posterior regions at disease onset. Abnormalities may show marked variability in terms of localization in sequential EEGs, and the predominance of abnormalities might move to either centrotemporal region or frontopolar region. Generalized abnormalities may also be seen.²⁹ EEG abnormalities are activated both by sleep deprivation and by sleep, when abnormalities often have a wider field and may be bilaterally synchronous (Figure S1A,B). Eye closure (elimination of central vision and fixation-off sensitivity) typically activates posterior abnormalities, but this finding is not pathognomonic of this syndrome.

If seizures are recorded, ictal onset varies, but most have posterior onset. The ictal pattern shows rhythmic slow activity intermixed with small spikes and/or fast activity (Figure S1C).⁵⁸

3.2.6 | Imaging

Neuroimaging, if performed, shows no causal lesion. MRI should be considered in cases with recurrent seizures or atypical presentations. Nonspecific MRI findings should not exclude a diagnosis of SeLEAS.

3.2.7 | Genetics

SeLEAS is probably genetically determined; however, no causative gene variants have been detected so far. There is a higher prevalence of febrile seizures in first-degree relatives and case reports of siblings with other SeLFES.^{18,51} There is no clear indication to perform genetic testing in most patients; however, rare cases with *SCN1A* pathogenic variants have been reported.⁵⁹⁻⁶¹

3.2.8 | Differential diagnosis

Other epilepsies:

- Focal seizures due to structural brain abnormalities. Temporal lobe epilepsy in early childhood and structural occipital epilepsies may present with ictal vomiting.
- SeLECTS should be diagnosed if seizures have prominent frontoparietal–opercular features.

- COVE is distinguished by prominent visual symptoms, as opposed to autonomic features.
- Familial focal epilepsy with variable foci. Different focal epilepsies occur in other family members, but SeLEAS is not usually seen.

Other conditions:

- Migraine-associated disorders such as benign paroxysmal vertigo.
- Syncope.
- Other medical disorders associated with intermittent vomiting.

3.3 | Childhood occipital visual epilepsy

COVE syndrome, formerly known as late onset benign occipital epilepsy, Gastaut syndrome, or idiopathic childhood occipital epilepsy–Gastaut type, begins in later childhood and is self-limited in the majority of patients. This syndrome occurs in developmentally normal children, with frequent, brief seizures during wakefulness, with visual phenomena without altered awareness, which are often followed by headaches with migrainous features. Seizures may be controlled, and remission of seizures often, but not invariably, occurs within 2–7 years from onset (Table 4).⁶²

3.3.1 | Epidemiology

COVE has a prevalence of 0.3% of children with newly diagnosed, afebrile seizures.²⁶

3.3.2 | Clinical context

Age at onset is typically at 8–9 years, with a range from 1 year to 19 years.⁶³ Both sexes are equally affected. Antecedent and birth history is normal. Patients have normal development and cognition, although mild cognitive impairment has been described. Head size and neurological examination are normal.⁶⁴

3.3.3 | Course of illness

Remission occurs in 50%–80% of patients by puberty with or without administration of ASM.^{65,66} Seizures are often responsive to ASM. Remission is more likely in the 90% of patients who only have focal seizures.⁶⁴ Occurrence of bilateral tonic–clonic seizures is associated with a lower rate of remission. Development usually remains normal.

TABLE 4 Childhood onset visual epilepsy

	Mandatory	Alerts	Exclusionary
Seizures	Focal sensory visual seizures with elementary visual phenomena (multicolored circles), with or without impaired awareness, and with or without motor signs (deviation of the eyes or turning of the head) Seizures arise predominantly or exclusively from wakefulness	Prolonged seizure lasting >15 min GTCS during wakefulness	Drop (tonic or atonic) seizures Atypical absences Progressive myoclonus
EEG	Occipital spikes or spikes-and-wave abnormalities (awake or sleep)	Sustained focal slowing not limited to the postictal phase	
Age at onset		<6 years >14 years	<1 year or >19 years
Development at onset		Intellectual disability	Neurocognitive regression
Neurological exam		Any significant neurological examination abnormality	Persistent visual field deficit
Imaging			Causal lesion on brain MRI Cerebral occipital lobe calcifications
Course of illness			Neurocognitive regression Development of myoclonic seizures, ataxia, spasticity

An MRI is required for diagnosis to exclude a causal lesion.

An ictal EEG is not required for diagnosis.

Syndrome without laboratory confirmation: In resource-limited regions, at a minimum, an interictal EEG and MRI are required to confidently diagnose this syndrome.

Note: Alert criteria are absent in the vast majority of cases, but rarely can be seen. Their presence should result in caution in diagnosing the syndrome and consideration of other conditions.

Abbreviations: EEG, electroencephalogram; GTCS, generalized tonic-clonic seizures; MRI, magnetic resonance imaging.

3.3.4 | Seizures

Focal sensory visual seizures during wakefulness are mandatory for diagnosis. They have abrupt onset, are brief (typically seconds, most lasting <3 min, rarely up to 20 min), and frequent without treatment. Typically, elementary visual phenomena occur, described as small multicolored circles seen in the peripheral vision, increasingly involving more of the visual field and moving horizontally across to the other side. This may be followed by deviation of the eyes or turning of the head (to the side ipsilateral to the hemisphere of seizure onset).⁶⁷

Other features consistent with occipital lobe onset may occur, including ictal blindness, complex visual hallucinations or illusions (such as palinopsia, micropsia, metamorphopsia), orbital pain, eyelid fluttering, or repeated eye closure.^{68,69} The seizure may spread outside the occipital lobe, resulting in hemiparesthesia, impaired awareness (14%), and hemiclonic (43%) or focal to bilateral tonic-clonic (13%) seizure.⁶³ Typical absence seizures may rarely occur in some patients after onset of the focal sensory seizures.⁷⁰

There may be ictal or postictal headache, nausea, or vomiting. Postictal headache with migrainelike features is common (in 50% of patients) and may be associated with nausea and vomiting.

3.3.5 | Electroencephalogram

The background activity is normal. Interictal occipital sharp waves or spike-and-wave complexes are typically seen but may only occur in sleep. Centrottemporal, frontal, or generalized abnormalities are also present in 20% of cases.⁷¹ Fixation-off sensitivity (facilitation of epileptiform abnormalities with elimination of central vision) is seen in 20%–90% of patients but is not pathognomonic of this syndrome.^{63,66,72} EEG abnormalities are enhanced by sleep deprivation and sleep (Figure S2A,B). COVE may rarely evolve to EE-SWAS; therefore, if cognitive regression occurs, a sleep EEG should be performed.

At ictal onset, there is a decrease in the usual background occipital spikes or spike-and-wave complexes with the sudden appearance of unilateral occipital fast rhythms

with spikes of low amplitude. There may be slower spike-and-wave abnormalities during oculoclonic seizures or ictal blindness (Figure S2C).^{68,69}

3.3.6 | Imaging

Neuroimaging is normal. Brain MRI is required to exclude a structural brain abnormality.⁷³

3.3.7 | Genetics

Genetic testing is not required, as there are no genes identified for this epilepsy syndrome. It is presumed that the etiology is genetic, and likely complex/polygenic in inheritance.¹⁸ A family history of febrile seizures or epilepsy occurs in up to one third of cases, and a family history of migraine is reported in 9%–16% of cases.^{63,66}

3.3.8 | Differential diagnosis

Other epilepsies:

- Focal seizures due to a structural brain abnormality.
- Celiac disease, epilepsy, and cerebral calcification syndrome is distinguished by occipital lobe calcification, best seen on brain computerized tomography scan.
- Mitochondrial encephalomyopathy, lactic acidosis, and strokelike episodes (MELAS).
- Lafora disease is distinguished by the presence of regression, prominent myoclonus, progressive ataxia, and spasticity.

Other conditions:

- Migraine with visual aura can be distinguished by the more gradual development and longer duration of the aura, and the character of the visual phenomena (linear, zig-zag, or fortification spectral phenomena as opposed to colored circles or light flashes that change in size or move horizontally).
- Posterior reversible encephalopathy syndrome presents with acute symptomatic seizures, which resolve with control of hypertension.

3.4 | Photosensitive occipital lobe epilepsy

POLE is a rare epilepsy syndrome that has onset in childhood and adolescence and is characterized by the presence

of photic-induced, focal seizures involving the occipital lobe in individuals with normal development, neurological examination, and intellect (Table 5). At seizure onset, the patient experiences a visual aura with involuntary head version with intact awareness. Prognosis is variable.

3.4.1 | Epidemiology

The prevalence of POLE is low. Epidemiological data are limited, but estimates suggest that POLE accounts for 0.7% of childhood epilepsies.⁷⁴

3.4.2 | Clinical context

Age at onset is between 1 and 50 years, but is most commonly between 4 and 17 years (mean = 11 years), although rare cases with adult onset are also reported.⁷⁵ There is a strong female predominance.⁷⁴ Antecedent and birth history is unremarkable, and development is normal. Head size and neurological examination are normal.

3.4.3 | Course of illness

Prognosis varies; some patients will have only a few seizures, others have seizure remission over time, and others continue to have photic-induced seizures.⁷⁶

3.4.4 | Seizures

Photic-induced, focal sensory visual seizures (induced for example by flickering sunlight) are mandatory for diagnosis and the main seizure type. Young children may find the aura hard to describe but they can sometimes draw a picture of what they see. Visual sensory symptoms include lights, colored spots, formed visual hallucinations, or visual blurring/loss that moves across the visual field. There is associated head and eye version in which the patient feels they are following the visual phenomenon. Seizures can be induced by video games or other photic stimuli, and in the past were often induced by older analog televisions with slower frequency outputs.⁷⁷

Seizures are typically brief (<3 min), although prolonged seizures may occur. Seizures may progress to a cephalic sensation (including headache), autonomic epigastric sensation or vomiting, and impaired awareness or to a focal to bilateral tonic-clonic seizure.^{74,78} Infrequently, seizures can arise from sleep without photic induction.

TABLE 5 Photosensitive occipital lobe epilepsy

	Mandatory	Alerts	Exclusionary
Seizures	Focal sensory visual seizures (see text), which may evolve to bilateral tonic-clonic seizures Seizures are triggered by photic stimuli, such as flickering sunlight	Prolonged seizures lasting >15 min	Eyelid myoclonia Progressive myoclonus
EEG	Occipital epileptiform abnormalities facilitated by eye closure and IPS	Sustained focal slowing not limited to the postictal phase Photoparoxysmal response at slow photic frequency (1–2 Hz; suggest CLN2 disease)	
Age at onset		<4 years or >17 years	<1 year or >50 years
Development at onset		Moderate to profound intellectual disability	Neurocognitive regression
Neurological exam		Any significant neurological examination abnormality	Permanent visual field deficit
Imaging			Causal lesion on brain MRI
An MRI is required for diagnosis to exclude a causal lesion. An ictal EEG is not required for diagnosis.			
Syndrome without laboratory confirmation: In resource-limited regions, at a minimum, an EEG and MRI are required to confidently diagnose this syndrome.			

Note: Alert criteria are absent in the vast majority of cases, but rarely can be seen. Their presence should result in caution in diagnosing the syndrome and consideration of other conditions.

Abbreviations: CLN2, ceroid lipofuscinosis type 2; EEG, electroencephalogram; IPS, intermittent photic stimulation; MRI, magnetic resonance imaging.

Some patients also have focal sensory visual occipital seizures without visual induction.⁷⁴ An overlap between this syndrome and the IGEs is well described,^{79–81} and thus myoclonic, absence, and generalized tonic-clonic seizures may also be seen. The frequency of seizures is variable.

3.4.5 | Electroencephalogram

The background EEG is normal. Interictal occipital spikes or spike-and-wave abnormalities may be seen. Generalized spike-and-wave complexes or centrotemporal spikes may coexist. Occipital spike-and-wave or polyspike-and-wave complexes are facilitated by eye closure and intermittent photic stimulation (Figure S3). Generalized spike-and-wave or polyspike-and-wave (with posterior predominance) complexes may also occur with photic stimulation.⁷⁴ Epileptiform activity is elicited by sleep deprivation and by sleep.

Ictal onset is in the contralateral occipital lobe to the visual field containing the visual sensory phenomena, and to the direction of head and eye deviation.^{74,76} Occipital ictal patterns may spread to the ipsilateral temporal lobe or the contralateral occipital lobe.

3.4.6 | Imaging

Neuroimaging is normal.

3.4.7 | Genetics

A family history is reported in one third of patients.⁷⁴ A few families with affected members in multiple generations have been reported.^{79,82,83} There is considerable overlap with the IGEs and with SeLECTS.^{80,84} No known gene exists.

3.4.8 | Differential diagnosis

Other epilepsies:

- Epilepsy with eyelid myoclonia (EEM) is differentiated by the prominent eyelid myoclonia and by the absence of visual hallucinations and head and eye version.
- SeLEAS is differentiated by prominent dry retching/vomiting and other autonomic features that are seen at seizure onset.

- COVE is distinguished by frequent focal sensory seizures with visual symptoms that are not triggered by photic stimuli.
- Focal seizures due to a structural brain abnormality: If present, focal sensory seizures with visual symptoms are not triggered by photic stimuli.
- Ceroid lipofuscinosis type 2 (CLN2) disease presents in younger children (<5 years of age), and the EEG characteristically shows a photoparoxysmal response at low frequencies (1–3 Hz). Children have progressive cognitive regression, ataxia, and visual loss.
- Lafora disease presents with focal sensory visual seizures but is associated with a progressive myoclonic epilepsy with disabling myoclonus, cognitive impairment, and ataxia.

Other conditions:

- Migraine with visual aura has visual phenomena that are longer in duration and qualitatively different (linear, zig-zag, or fortification spectral phenomena as opposed to colored circles or light flashes that change in size or move horizontally).

4 | GENETIC GENERALIZED EPILEPSY SYNDROMES OF CHILDHOOD

Essentially all generalized epilepsy syndromes that have onset in childhood have a genetic etiology. They are regarded as following complex inheritance, which means they have a polygenic basis, with or without a contribution from environmental factors. Among the genetic generalized epilepsies with onset in childhood, the most common and best delineated is the IGE syndrome of CAE, which is discussed in the IGE paper.² Recent studies have highlighted that some IGE syndromes may also be due to monogenic disorders such as glucose transporter 1 (GLUT1) deficiency syndrome.⁸⁵ Genetic etiologies such as Angelman syndrome or 15q inversion-deletion are important causes of the more severe DEEs, and typically arise de novo in the patient.

Other childhood genetic generalized epilepsy syndromes include two distinct syndromes, epilepsy with myoclonic absence (EMA) and epilepsy with eyelid myoclonia (EEM). These syndromes have a more variable prognosis than CAE, with a higher proportion of cases having drug-resistant seizures and more frequent cognitive comorbidities. Although there is often a positive family history of epilepsy, the type of epilepsy in family members may include IGE syndromes as well as genetic epilepsy with febrile seizures plus. Epilepsy with myoclonic-atonic seizures (EMAtS) is also a generalized epilepsy syndrome

that is classified under the DEEs, as children typically show developmental stagnation or regression during the period of frequent seizures. See [Figure 3](#).

4.1 | Epilepsy with eyelid myoclonia

4.1.1 | Overview

This syndrome (previously known as Jeavons syndrome) is characterized by the triad of frequent eyelid myoclonia, with or without absences, induced by eye closure and photic stimulation. Eyelid myoclonia is often most prominent on awakening ([Table 6](#)).

A subgroup of patients with EEM have prominent photic induction of eyelid myoclonia (with or without absence), and absence or myoclonic seizures.⁸⁶ This subgroup has previously been referred to as “sunflower syndrome,” due to sun-seeking behavior, as they may turn their faces to the sun as a light source at seizure onset.⁸⁷ This subgroup can be termed “EEM with prominent photic induction.”

4.1.2 | Epidemiology

This syndrome is rare, and there are no population-based studies on incidence. Several studies from epilepsy centers have shown that it accounts for 1.2%–2.7% of all epilepsy cases seen.^{88,89}

4.1.3 | Clinical context

The peak age at onset is 6–8 years, with a range of 2–14 years.^{89–91} There is a 2:1 female:male predominance.^{89–91} Antecedent and birth history is normal. Development and cognition are often normal, although individuals with borderline intellectual functioning and intellectual disability are seen. In the subgroup with prominent photic induction, approximately half have intellectual disability or attentional problems, which may become more apparent with age.⁸⁷ Neurological examination is normal.

4.1.4 | Course of illness

EEM is often, but not invariably, drug-resistant.^{92–94} Generalized tonic-clonic seizures are often controlled with ASMs, whereas eyelid myoclonia are not fully controlled. In adult life, eyelid myoclonia alone may not be associated with EEG change, and thus represents a movement disorder.⁹⁵ EEM is often a life-long condition.^{93,94}

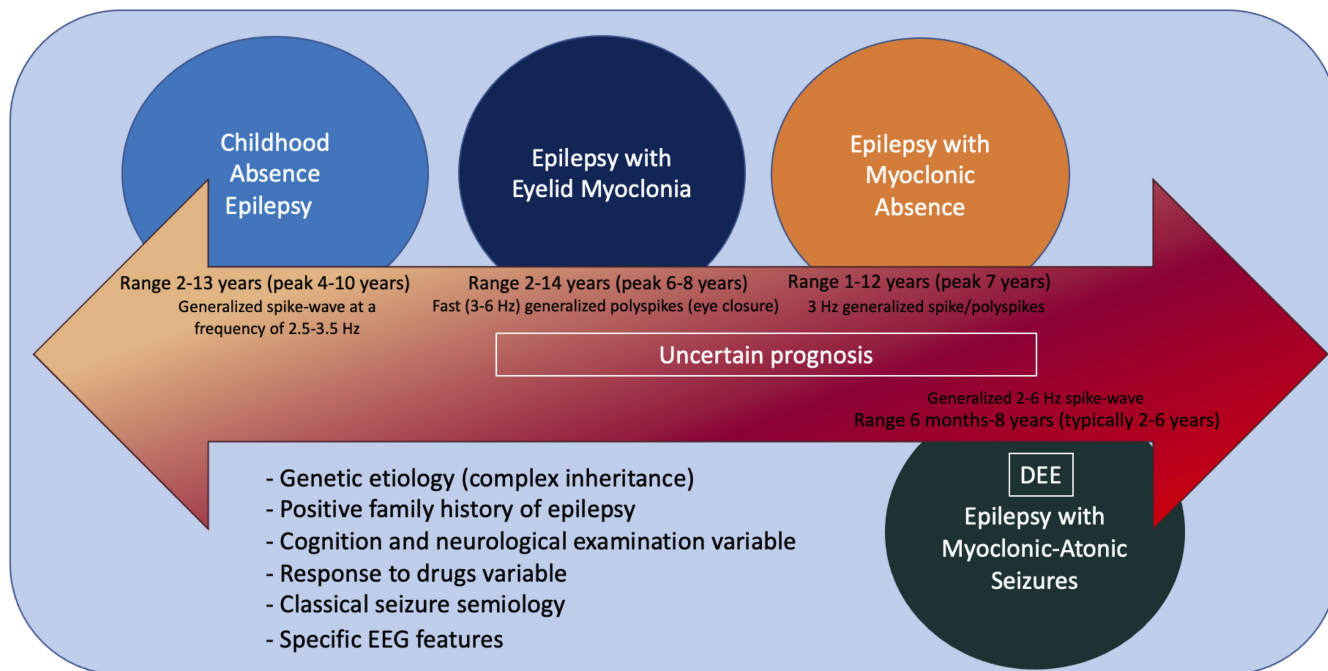


FIGURE 3 Genetic generalized epilepsies of childhood are a group of conditions characterized by genetic etiology with complex inheritance, namely, with polygenic basis. A positive family history of epilepsy is frequent. Cognition, neurological examination, and response to drugs are variable. Seizure semiology and electroencephalographic (EEG) features are specific for each of the syndromes included in this group. Genetic generalized epilepsies of childhood encompass childhood absence epilepsy, which is discussed in the paper on idiopathic generalized epilepsy syndromes,² epilepsy with eyelid myoclonia, epilepsy with myoclonic absence, and epilepsy with myoclonic atonic seizures. Epilepsy with myoclonic absence and epilepsy with eyelid myoclonia have a variable prognosis. Epilepsy with Myoclonic Atonic Seizures is classified under the developmental and/or epileptic encephalopathies (DEEs), as children typically show developmental stagnation or regression. In the figure are represented the age at onset and EEG findings for each of the syndromes

In the subgroup with prominent photic induction, behavioral management may be important to avoid excessive medication, but is very challenging, particularly in those with intellectual disability. Environmental measures to reduce light exposure are important in these patients, which include wearing wide-brimmed hats and wrap-around sunglasses. Specific blue lenses (Z1) may attenuate the photosensitive response in some patients.⁹⁶

4.1.5 | Seizures

Eyelid myoclonia, consisting of brief, repetitive, and often rhythmic 3–6-Hz myoclonic jerks of the eyelids, with simultaneous upward deviation of the eyeballs and extension of the head, is mandatory for diagnosis. These seizures are very brief (typically <1 to 3 s, always <6 s) and occur multiple times each day, even many times per hour. They are typically induced by involuntary or voluntary slow eye closure or exposure to bright light or sunlight.⁹⁷ During eyelid myoclonia, awareness may be intact or mildly impaired; impaired awareness may be subtle and not recognized by the patient.

Up to 20% of patients develop eyelid myoclonic status epilepticus, with repetitive, recurrent eyelid myoclonia associated with mildly impaired awareness and responsiveness. Eyelid myoclonia may also be associated with absence seizures, with mildly impaired awareness. In addition, some patients have typical absence seizures without eyelid myoclonia.

Generalized tonic-clonic seizures occur in the majority of cases but are usually infrequent. They may be provoked by sleep deprivation, alcohol, or photic stimulation.

In the patients with prominent photic induction, eyelid myoclonia (with or without absence), absence, or myoclonic seizures are typically associated with behaviors such as facing a light source and hand-waving in front of the eyes, rubbing the forehead, going up close to an analog television, or using other means to create a flickering effect of light.^{86,87,98} Sustained triggering can result in a generalized tonic-clonic seizure.

Febrile seizures occur in 3%–13% patients.^{92,99} Patients may also have myoclonic and typical absence seizures even if at relatively lesser frequency than eyelid myoclonias. The presence of frequent limb myoclonus should suggest an alternative syndrome diagnosis. Focal seizures are exclusionary.

TABLE 6 Epilepsy with eyelid myoclonia

	Mandatory	Alerts	Exclusionary
Seizures	Eyelid myoclonia (see text)	Inability to induce eyelid myoclonia in the office by slow eye closure during exposure to bright light in an untreated patient Myoclonic jerks affecting limbs—strongly consider JME	Any of the following seizure types: <ul style="list-style-type: none"> • Myoclonic–absence seizures • Focal seizures
EEG	Eye closure and intermittent photic stimulation elicits fast (3–6 Hz) generalized polyspikes or polyspike-and-wave complexes		Focal slowing Consistently unilateral focal spikes Generalized slow spike-and-wave pattern at frequency < 2.5 Hz (unless it is at the end of a higher frequency burst) Diffuse background slowing that is not limited to the postictal period Lack of EEG correlate with typical clinical event
Age at onset			<2 years or >14 years
Neurological exam		Focal neurological findings	
Imaging		Potentially relevant abnormal neuroimaging, excluding incidental findings (see text)	Abnormal neuroimaging with causative lesion
Course of illness			Progressive cognitive decline over the course of the epilepsy

An MRI is not required for diagnosis.

An ictal EEG is not required for diagnosis, provided that eyelid myoclonia has been observed clinically by the diagnosing provider and the interictal study shows fast (3–6 Hz) generalized polyspikes or polyspike-and-wave complexes induced by eye closure or intermittent photic stimulation. However, most untreated patients will have recorded photoparoxysmal response with eyelid myoclonia on a routine EEG performed during intermittent light stimulation.

Syndrome without laboratory confirmation: In resource-limited regions, epilepsy with eyelid myoclonia can be diagnosed in persons who meet all other mandatory and exclusionary clinical criteria if they have eyelid myoclonia witnessed by the examiner or captured on home video.

Note: Alert criteria are absent in the vast majority of cases, but rarely can be seen. Their presence should result in caution in diagnosing the syndrome and consideration of other conditions.

Abbreviations: EEG, electroencephalogram; JME, juvenile myoclonic epilepsy; MRI, magnetic resonance imaging.

4.1.6 | Electroencephalogram

The background activity is normal; significant EEG background slowing should suggest an alternative diagnosis. Interictally, brief bursts of fast (3–6 Hz) irregular generalized polyspike-and-wave complexes are frequent. Fixation-off sensitivity, which can be induced by eye closure, and intermittent photic stimulation activate the epileptiform abnormality and often elicit eyelid myoclonia with/without absence seizures (Figure 4).^{100,101} Young patients typically show photic sensitivity, which becomes less apparent with age and ASM. Similarly, sensitivity to eye closure may reduce with age. The epileptiform activity is also elicited by hyperventilation.

In the subgroup with photic induction, generalized spike-and-wave abnormalities are also provoked by photic induction. In those patients, intermittent photic

stimulation may trigger brief eyelid myoclonia, typical absence, or myoclonic seizures.

Bursts of generalized spike-and-wave activity often become briefer and fragmented in sleep. Fragmented generalized spike-and-wave complexes can appear as focal or multifocal spike-and-wave complexes but are not consistently localized to one area. The morphology of the focal spike-and-wave complexes resembles that of the generalized spike-and-wave pattern.

Ictal recordings of eyelid myoclonia show high-amplitude, irregular generalized polyspike or polyspike-and-wave complexes, which may be followed by rhythmic spike or polyspike-and-wave complexes at a frequency of 3–6 Hz. Eyelid myoclonia with/without absence is terminated with complete elimination of light. Eyelid myoclonia may or may not be associated with loss of awareness.

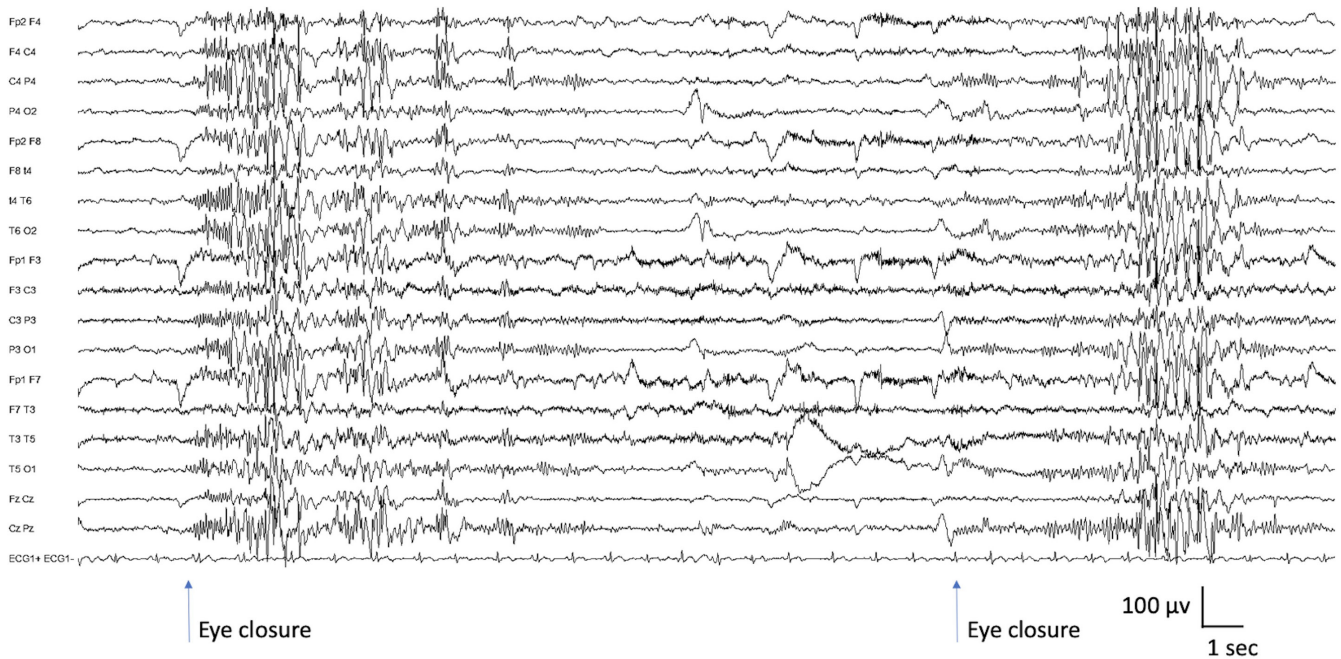


FIGURE 4 Ictal electroencephalogram of 14-year-old patient with epilepsy with eyelid myoclonia. Background activity is normal. Each time the patient closes the eyes (eye closure artifact is seen), there is a generalized polyspike-and-wave discharge lasting between 6 and 8 s, clinically associated with eyelid myoclonia. During the second event, soon after eye closure, there is a fast activity discharge that builds up

4.1.7 | Imaging

An MRI is not required with a typical clinical presentation, but if done, shows no causal abnormality.

4.1.8 | Genetics

This syndrome likely has shared genetic etiologies with other idiopathic generalized epilepsies. A family history of seizures or epilepsy is present in 25%–83% of cases, with nearly all affected relatives having generalized seizures.^{92,99} In approximately 20% of cases, there is a family history of an IGE—CAE, juvenile absence epilepsy, juvenile myoclonic epilepsy, or generalized tonic-clonic seizure alone—and nearly half the patients have a family history consistent with genetic epilepsy with febrile seizures plus.⁹⁹

No single pathogenic gene variant is identified in the majority of patients. In patients with this syndrome in the setting of a DEE, several monogenic disease genes have been implicated, including *CHD2*,¹⁰² *SYNGAP1*¹⁰³ and *NEXMIF*¹⁰⁴ (formerly known as *KIAA2022*); some patients with pathogenic variants in these genes have this syndrome without a DEE.

4.1.9 | Differential diagnosis

Other epilepsies:

- IGE syndromes with absence seizures (CAE, juvenile absence epilepsy, and juvenile myoclonic epilepsy) may have photosensitivity on EEG; however, prominent eyelid myoclonia is not seen.
- *POLE* presents with visually induced seizures but without eyelid myoclonia.
- Other early onset epilepsies with myoclonus and photosensitivity,⁹⁷ including rare monogenic epilepsies such as neuronal ceroid lipofuscinosis.

Other conditions:

- Facial tics.
- Compulsive blinking.

4.2 | Epilepsy with myoclonic absence

EMA is a very rare childhood epilepsy syndrome that presents with daily myoclonic absence seizures (Table 7).

TABLE 7 Epilepsy with myoclonic absences

	Mandatory	Alerts	Exclusionary
Seizures	Myoclonic absence seizures as predominant type (see text)		Focal seizures Atonic, myoclonic–atonic, or tonic seizures
EEG	Regular 3-Hz generalized spike-and-wave pattern time-locked with myoclonic jerks		Focal slowing Consistently unilateral focal spikes Generalized slow spike-and-wave pattern at frequency < 2 Hz (unless it is at the end of a higher frequency burst) Diffuse background slowing that is not limited to the postictal period
Age at onset			<1 year or >12 years
Neurological exam		Moderate or greater intellectual disability Focal neurological findings	
Imaging			Abnormal neuroimaging with causative lesion
Course of illness			Progressive cognitive decline over the course of epilepsy

An MRI should be considered to exclude other causes.

An ictal EEG is not required for diagnosis, provided that myoclonic absences have been observed clinically by the diagnosing provider and the interictal study shows regular 3-Hz generalized spike-and-wave complexes. However, most untreated patients will have recorded myoclonic absence seizure on routine EEG.

Syndrome without laboratory confirmation: In resource-limited regions, epilepsy with myoclonic absences can be diagnosed in persons who meet all other mandatory and exclusionary clinical criteria if they have myoclonic absence seizures witnessed by the examiner or captured on home video.

Note: Alert criteria are absent in the vast majority of cases, but rarely can be seen. Their presence should result in caution in diagnosing the syndrome and consideration of other conditions.

Abbreviations: EEG, electroencephalogram; MRI, magnetic resonance imaging.

4.2.1 | Epidemiology

The exact incidence is unknown. This syndrome accounted for 0.5%–1% of all epilepsies observed in a specialty epilepsy clinic, Saint Paul Center in Marseille.¹⁰⁵

4.2.2 | Clinical context

Peak age at onset is approximately 7 years, with a range of 1–12 years, and males are more commonly affected (70%).^{105,106} The antecedent and birth history is unremarkable; however, at presentation approximately half of patients have developmental impairment. Intellectual disability may become evident with age, and is ultimately seen in 70% of cases.^{105–107} Neurological examination is typically normal.

4.2.3 | Course of illness

The evolution of EMA is variable.^{105,106} Remission occurs in approximately 40% of patients. In the remainder, myoclonic absences persist, or the epilepsy may evolve with the development of other generalized seizure types. Prognosis is more favorable if myoclonic absence seizures are the only seizure type and are controlled with medication.¹⁰⁵

4.2.4 | Seizures

Myoclonic absence seizures are mandatory for diagnosis.¹⁰⁵ Absence seizures are associated with rhythmic 3-Hz jerks of the upper limbs, superimposed on tonic abduction of the arms during the seizure (giving a ratcheting appearance). The seizures have an abrupt onset and offset. The patient, if standing, typically bends forward during the

seizure, but falling is uncommon. The myoclonic jerks are typically bilateral and symmetric but can be unilateral or asymmetric. Perioral myoclonia and rhythmic jerks of the head and legs may also occur. Seizures last 10–60 s and occur multiple times per day.¹⁰⁷ Alertness varies from complete loss of awareness to retained awareness. Occasionally, autonomic manifestations, such as a change in breathing or urinary incontinence¹⁰⁵ or complex gestural automatisms, may be seen.¹⁰⁸ Myoclonic absences are the only seizure type seen in one third of patients. Myoclonic absence status epilepticus is rare. Generalized tonic-clonic (seen in 45%), clonic, atonic, or typical absence seizures may also occur; multiple seizure types may indicate a more unfavorable prognosis. Only 4% of patients also have typical absence seizures without myoclonic jerks. Focal seizures are exclusionary.

4.2.5 | Electroencephalogram

The background activity is normal. Occipital intermittent rhythmic delta activity is typically not seen.¹⁰⁵ Interictal 3-Hz generalized spike-and-wave and polyspike-and-wave abnormalities may occur (approximately one third of cases). Focal abnormalities that arise consistently from one region should raise consideration of an alternative diagnosis of a structural etiology.

Generalized spike-and-wave discharges may be provoked by hyperventilation, which may also trigger myoclonic absence seizures. Intermittent photic stimulation

triggers generalized spike-and-wave abnormalities in a minority of patients (14%). Generalized spike-and-wave complexes are also activated by sleep deprivation, drowsiness, and sleep. Similar to other generalized epilepsies, generalized spike-and-wave complexes often become fragmented with sleep deprivation or sleep. The pattern may appear as focal or multifocal spike-and-wave complexes but is not consistently seen in a single area. The morphology of the focal abnormalities appears similar to the generalized spike-and-wave activity.

Regular 3-Hz generalized spike-and-wave complexes accompany myoclonic absence seizures. The 3-Hz discharge is time-locked with the myoclonic jerks (Figure 5). The electromyographic (EMG) recording shows that the myoclonic jerks precede the marked tonic contraction of both deltoids.¹⁰⁵

4.2.6 | Imaging

An MRI should be considered to exclude other causes, but if done, it should be normal or may show mild diffuse atrophy.

4.2.7 | Genetics

A family history (usually of generalized seizures) is present in 20% of cases. Rarely, there is a family history of febrile seizures. Although EMA is considered to be genetic,

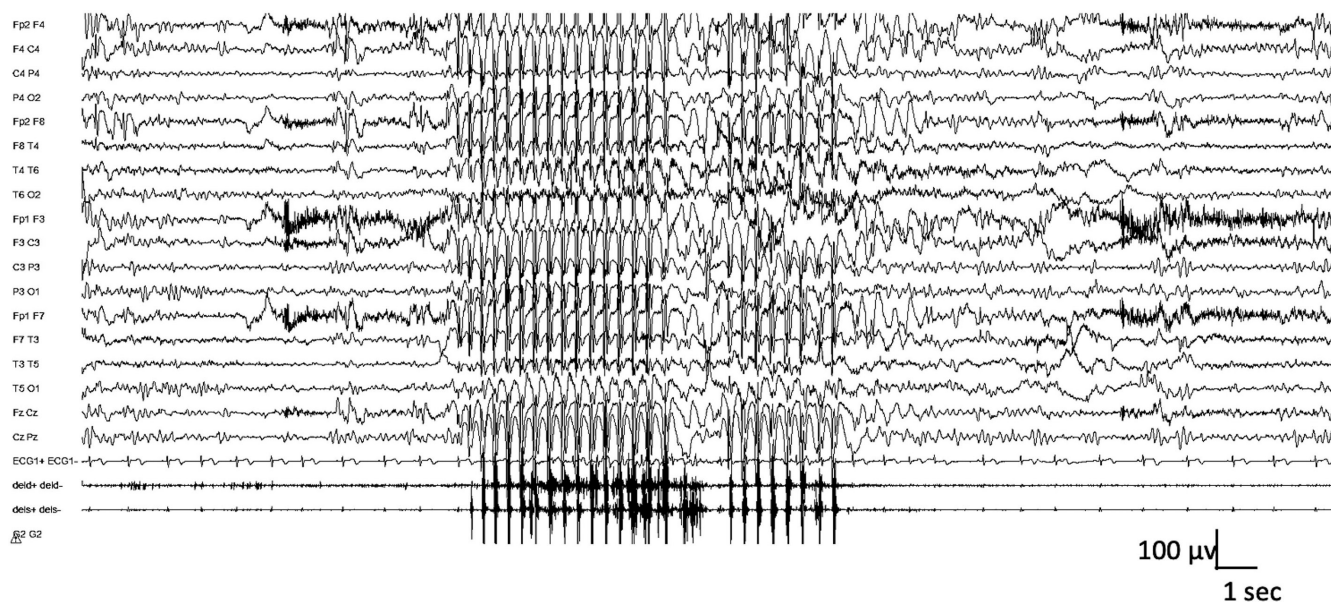


FIGURE 5 Ictal polygraphic electroencephalographic recording in an 8-year-old child with epilepsy with myoclonic absences, showing a paroxysmal generalized 3-Hz spike-and-wave discharge. Electromyographic channels (right and left deltoids) show bilateral myoclonic jerks synchronous with epileptiform abnormalities, and between jerks there is a sustained increase in muscle tone

there are only isolated case reports of specific pathogenic genetic variants,^{109,110} with most cases likely to be polygenic. This syndrome is presumed to have shared genetic etiologies with the IGEs.¹¹¹

4.2.8 | Differential diagnosis

Other epilepsies:

- CAE: Although subtle myoclonic jerks may be seen with absences in CAE, they are low amplitude, do not have the sustained rhythmicity, and are not associated with the stepwise (ratcheting) tonic abduction of the arms.
- LGS often has atypical absences with rhythmic jerking or loss of tone; however, the presence of slow spike-and-wave (≤ 2.5 Hz), generalized paroxysmal fast activity and tonic seizures should suggest the diagnosis.
- Myoclonic absence seizures may rarely be seen in other DEEs but are not the predominant seizure type.¹¹⁰

5 | DEES OR EPILEPTIC ENCEPHALOPATHIES WITH ONSET IN CHILDHOOD

“Epileptic encephalopathies” are defined as diseases in which the epileptic activity itself contributes to severe cognitive and behavioral impairments above and beyond that expected from the underlying etiology alone. These disorders are characterized by frequent epileptiform activity associated with developmental slowing and often regression. They may occur on a background of normal or abnormal development.

In the 2017 Classification of the Epilepsies, additional terminology was introduced with the word “developmental” added to denote those children who had abnormal development secondary to the underlying cause in addition to an epileptic encephalopathy.¹¹² This term was introduced because many pathogenic gene variants cause developmental impairment in their own right, with the epileptic encephalopathy superimposed on the pre-existing impairment, further impacting developmental outcome.¹¹³

Conversely, a “developmental encephalopathy” refers to developmental impairment without frequent epileptiform activity, such as in a child or adult with intellectual disability.¹¹²

Moreover, the task force reviewed the use of the term “developmental encephalopathy” in persons who had fully completed development and agreed to establish a wider term “epilepsy syndromes with progressive neurological deterioration” in addition to developmental

encephalopathy. This can be applicable in older individuals with FIRES or Rasmussen syndrome.

In this section, we describe EMAtS, LGS, and DEE-SWAS. We also include two syndromes characterized by acute encephalopathy, followed by a developmental and epileptic encephalopathy, namely, FIRES and HHE.

5.1 | Epilepsy with myoclonic atonic seizures

EMAtS, formerly known as Doose syndrome, begins in early childhood, in the setting of normal development in two thirds of cases.¹¹⁴ The full complement of clinical and EEG features may be absent early in the course and take time to appear. These children typically show developmental stagnation or even regression during the active seizures (stormy) phase, which improves once seizures are controlled. See [Table 8](#).

5.1.1 | Epidemiology

EMAtS has an incidence of approximately 1 in 10 000 children and accounts for approximately 2% of childhood epilepsies.¹¹⁵

5.1.2 | Clinical context

EMAtS typically begins at between 2 and 6 years (range = 6 months to 8 years). Boys are more commonly affected.¹¹⁶ Approximately one quarter of children have a history of a febrile seizure,^{117–120} and such a history is associated with a more favorable long-term outcome.¹²⁰ Development prior to seizure onset is normal in two thirds of patients, and neurological examination is typically unremarkable at onset. Moderate to severe developmental delay preceding seizure onset should be considered as an alert for diagnosis.¹²¹

5.1.3 | Course of illness

The onset of EMAtS is often abrupt, with explosive “stormy” onset of many seizures and seizure types often generalized tonic-clonic and myoclonic. In other cases, it evolves more slowly, requiring careful follow-up over the first year to distinguish it from LGS. Seizures often are drug-resistant, particularly during the high seizure frequency (explosive or stormy) phase, and recurrent bouts of nonconvulsive status epilepticus with increased frequency of other generalized seizure types are seen. During this phase, developmental plateauing or even regression,

TABLE 8 Epilepsy with myoclonic atonic seizures

	Mandatory	Alerts	Exclusionary
Seizures	Myoclonic–atonic seizures	Tonic seizures within 12 months of epilepsy onset	Epileptic spasms or IESS prior to diagnosis Focal seizures
EEG	Generalized 2–6-Hz spike-wave or polyspike-and-wave abnormalities	Generalized paroxysmal fast activity in sleep Generalized slow spike-and-wave complexes of <2 Hz Photoparoxysmal response at low frequencies (suggests <i>CLN2</i> disease)	Persistent focal abnormalities Hypsarrhythmia
Age at onset			<6 months or >8 years
Development at onset		Moderate to severe developmental delay preceding seizure onset	
Neurological exam		Focal neurological findings	
Imaging			Causal lesion on MRI
An MRI is not required for diagnosis but is typically done to exclude other causes.			
An ictal EEG is not required for diagnosis. However, in a child with alerts or with clinical features that may suggest Lennox–Gastaut syndrome or infantile epileptic spasms, a video at least is essential and ideally an ictal EEG should be recorded.			
Syndrome-in-evolution: Epilepsy with myoclonic atonic seizures should be suspected in the case of explosive onset of multiple generalized seizure types in an appropriately aged child without other alerts or exclusionary features.			
Syndrome without laboratory confirmation: In resource-limited regions, epilepsy with myoclonic atonic seizures can be presumptively diagnosed without EEG if the clinician has personally witnessed myoclonic atonic seizures, either directly by observing the patient, or on video provided by the family. However, an EEG is strongly recommended.			

Note: Alert criteria are absent in the vast majority of cases, but rarely can be seen. Their presence should result in caution in diagnosing the syndrome and consideration of other conditions.

Abbreviations: CLN2, ceroid lipofuscinosis type 2; EEG, electroencephalogram; IESS, infantile epileptic spasms syndrome; MRI, magnetic resonance imaging.

predominantly on behavior and executive functions, and ataxia are often evident. Behavior disorders such as hyperactivity and aggression, and sleep disturbances are also common during the active phase, and typically improve or remit after seizure control is achieved.

Despite seizures being drug-resistant initially, two thirds of children achieve remission, usually within 3 years of onset, and can be weaned off antiseizure therapies.^{120,122} In the remaining third, persisting seizures, cognitive impairment, aggression, and hyperactivity are often seen. Once seizures are controlled and the EEG improves, developmental progress is seen. Development may return to premorbid levels of function, or the child may be left with a variable degree of intellectual disability. Factors predictive of poorer outcome include tonic seizures, recurrent nonconvulsive status epilepticus, and an EEG showing very frequent or nearly continuous irregular generalized spike-and-wave, slow spike-and-wave, or generalized paroxysmal fast activity.^{120,122–125}

5.1.4 | Seizures

Myoclonic–atonic seizures are mandatory for diagnosis and are characterized by a brief myoclonic jerk

affecting the proximal muscles, often associated with a slight vocalization, followed by a very brief atonic component, which may be subtle, with a head nod, or more prominent, with an abrupt fall (Video S1). Conversely, pure atonic seizures, which are also commonly seen, lack the myoclonic component at onset, and lead to an abrupt but brief loss of axial tone, with head nods or a sudden fall.

Other seizures that are frequently seen include myoclonic (which are brief [<100 ms] and can also lead to falls),¹²⁶ absence, and generalized tonic–clonic seizures. The latter may occur with or without fever and are the presenting seizure type in approximately two thirds of cases.^{117,119,122}

Tonic seizures appear in some patients later in the course and are associated with a poorer long-term outcome.¹²⁰

Nonconvulsive status epilepticus is also common and may be inaugural. It manifests as impaired awareness, lasting hours to days, with atypical absence, myoclonic, and atonic features, associated with somnolence, unsteadiness, drooling, speech disorders, and erratic myoclonus predominating in the face and upper limbs. Recurrent nonconvulsive status epilepticus is associated with a less favorable outcome.^{120,124} Epileptic spasms and focal seizures are exclusionary.

5.1.5 | Electroencephalogram

The background activity shows a normal, age-appropriate posterior dominant rhythm at onset. Monomorphic, biparietal theta rhythms are characteristic of EMAtS but are not seen in all patients. With increased seizure frequency, generalized, higher amplitude background slowing may be seen.

Interictal abnormalities comprised of generalized 2–6-Hz spike-and-wave or polyspike-and-wave complexes often occurring in bursts lasting 2–6 s are seen (Figure 6A). Long sequences of generalized irregular spike-and-wave discharges should raise the question of nonconvulsive status epilepticus. The generalized discharges can become fragmented, and a consistent spike focus is not seen. Generalized spike-and-wave abnormalities are activated with sleep. Generalized paroxysmal fast activity, consisting of bursts of diffuse or bilateral fast (10 Hz or more) polyspikes during sleep, is rarely seen and should suggest LGS. Hyperventilation may elicit generalized spike-and-wave discharges and absence seizures. Photosensitivity is rare.

Ictal recordings of myoclonic–atonic seizures show generalized polyspike or spike discharges with the myoclonus, followed by a high-voltage slow wave accompanying the atonic component (Figure 6B,C). Simultaneous recording of EMG with EEG is recommended for ictal recordings; polyspikes correlate with brief myoclonus in the neck muscles, whereas the slow wave correlates with loss of muscle activity in the proximal limb muscles. Absence seizures are associated with 2–6-Hz generalized spike-and-wave complexes.

During nonconvulsive status epilepticus, the EEG shows long runs of high-amplitude, 2–3-Hz irregular, generalized spike-and-wave activity, with background slowing.

5.1.6 | Imaging

The MRI is normal.

5.1.7 | Genetics

A family history of epilepsy or febrile seizures is found in approximately one third of cases^{117,119,122,123,127} and is associated with a more favorable long-term outcome.¹²⁰ The familial epilepsy syndrome of genetic epilepsy with febrile seizures plus is seen in families of probands with EMAtS.^{128,129}

In the majority of children, EMAtS has complex inheritance with a polygenic pattern. In some cases,

pathogenic variants have been seen in genes including *SCN1A*,¹³⁰ *SCN1B*,¹³¹ *SCN2A*,¹³² *STX1B*,¹³³ *SLC6A1*,¹³⁴ *CHD2*,¹⁰² *SYNGAP1*,¹⁰³ *NEXMIF*¹⁰⁴ *KIAA2022*.¹³⁵ Approximately 5% of patients with EMAtS have GLUT1 deficiency associated with pathogenic variants in *SLC2A1*.⁸⁵

5.1.8 | Differential diagnosis

Other epilepsies:

- LGS can be distinguished by the presence of tonic seizures early in the disease and the EEG, which shows slow spike-and-wave <2.5-Hz and generalized paroxysmal fast activity in sleep. Additionally, children with LGS more commonly have delayed development prior to seizure onset and may have a history of infantile spasms syndrome.
- Myoclonic epilepsy of infancy is distinguished by the lack of myoclonic–atonic and atypical absence seizures, and typically presents earlier than EMAtS.
- Dravet syndrome is distinguished by prolonged, hemiclonic seizures triggered by fever/illness in the first year of life and absence of myoclonic–atonic seizures.
- DEE-SWAS or EE-SWAS is associated with regression and marked activation of epileptiform abnormalities in sleep, with nearly continuous diffuse spike-and-wave complexes; myoclonic–atonic seizures are not seen.
- Subacute sclerosing panencephalitis is a rare condition associated with fulminant/rapid progression of myoclonic seizures, and episodes of falls. The EEG pattern is diagnostic.
- CLN2 disease typically begins in children with normal development or isolated speech delay. Children may present with a phenotype of EMAtS; however, there is progressive motor and cognitive decline and ataxia. The EEG shows a photoparoxysmal response at 1–3 Hz, so low-frequency testing is important.

5.2 | Lennox–Gastaut syndrome

LGS is a DEE associated with a wide range of etiologies. It results from high-frequency, synchronized activity in bilaterally distributed brain networks that develops in a susceptible age period in childhood.¹³⁶ This syndrome is characterized by the presence of (1) multiple types of drug-resistant seizures with onset prior to 18 years (one of which must include tonic); (2) cognitive and often behavioral impairments, which may not be present at

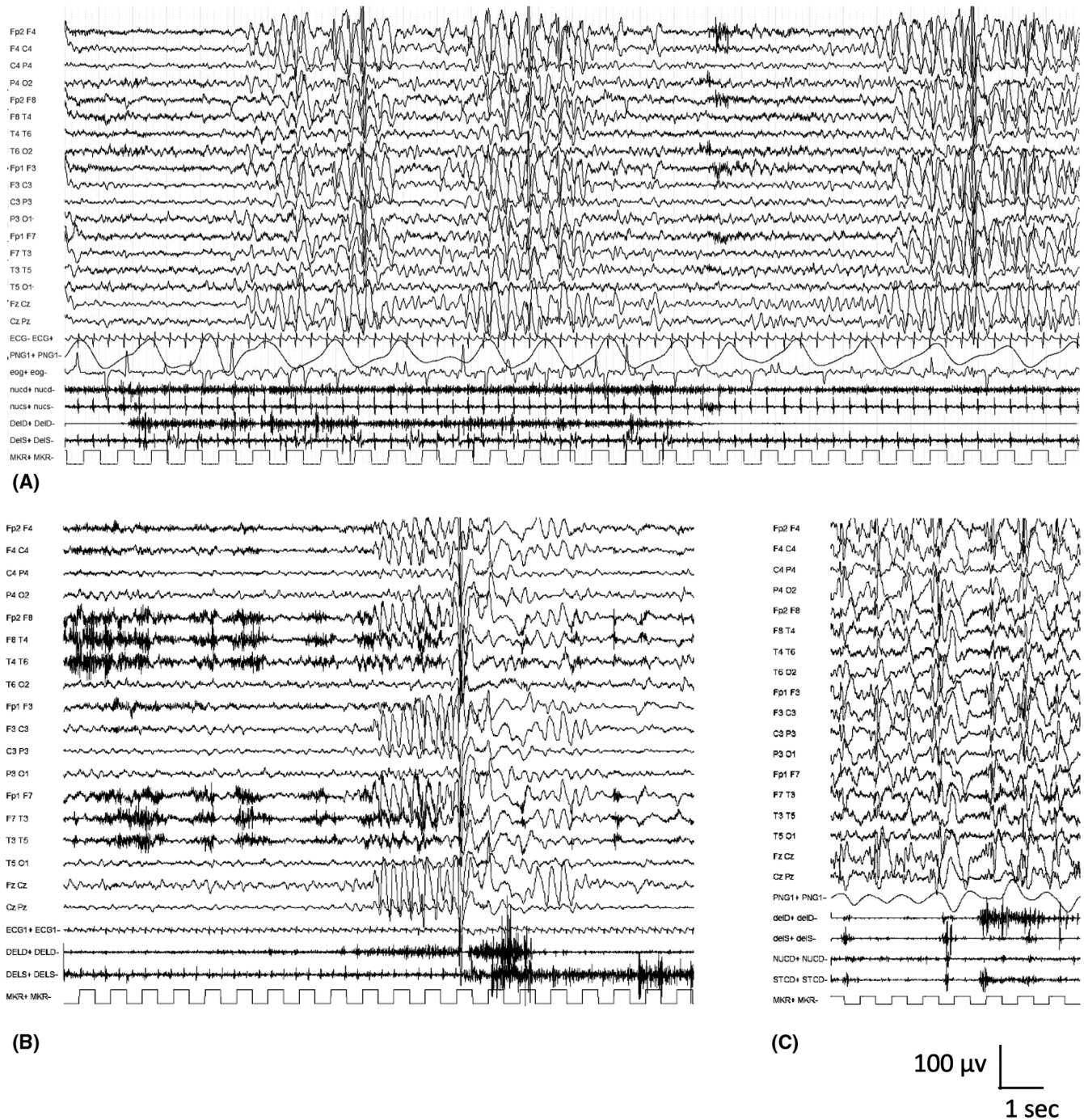


FIGURE 6 Interictal and ictal polygraphic electroencephalographic (EEG) recordings in a 3-year-old child with epilepsy with myoclonic atonic seizures. (A) Interictal EEG shows bilateral posterior slow waves (4–6 Hz). There are generalized abnormalities characterized by high-amplitude spikes and spike-and-wave abnormalities intermingled with high-amplitude delta waves without any clinical changes. (B, C) Examples of myoclonic atonic seizures associated with a generalized spike-and-wave discharge of brief duration. Electromyographic channels show loss of tone in the deltoids (B) and in nuchal and sternocleidomastoid muscles (C). Clinically, the child experiences abrupt falls with both events

seizure onset; and (3) diffuse slow spike-and-wave and generalized paroxysmal fast activity on EEG (Table 9). Many clinicians use the term “LGS” to describe any severe, early onset epilepsy with intractable seizures

leading to falls. This approach is incorrect, as it fails to recognize the specific features of LGS, and to distinguish it from EMaTS, which often has a markedly better outcome, and many other severe epilepsies starting

TABLE 9 Lennox–Gastaut syndrome

	Mandatory	Alerts	Exclusionary
Seizures	Tonic seizures (see text) In addition to tonic seizures, at least one additional seizure type must be present, which may include any of the following: <ul style="list-style-type: none"> • Atypical absences • Atonic • Myoclonic • Focal impaired awareness • Generalized tonic–clonic • Nonconvulsive status epilepticus • Epileptic spasms 		
EEG	Generalized slow spike-and-wave complexes of <2.5 Hz (or history of this finding on prior EEG) Generalized paroxysmal fast activity in sleep (or history of this finding on prior EEG)	Photoparoxysmal response at low frequencies (consider CLN2 disease)	Persistent focal abnormalities without generalized spike-and-wave pattern
Age at onset	<18 years	>8 years	
Long-term outcome	Drug-resistant epilepsy Mild to profound intellectual disability		

An MRI is not required for diagnosis but is usually performed to evaluate for underlying etiology.

An ictal EEG is not required for diagnosis. However, it should be strongly considered in a child with alerts or with clinical features that may suggest epilepsy with myoclonic atonic seizures syndrome.

Syndrome-in-evolution: Approximately 50% of infants with a severe DEE, e.g., IESS or early infantile DEE, evolve over time to Lennox–Gastaut syndrome.

Syndrome without laboratory confirmation: In resource-limited regions, at a minimum, an interictal EEG showing characteristic generalized slow spike-and-wave pattern during wakefulness is required for diagnosis.

Note: Alert criteria are absent in the vast majority of cases, but rarely can be seen. Their presence should result in caution in diagnosing the syndrome and consideration of other conditions.

Abbreviations: CLN2, ceroid lipofuscinosis type 2; IESS, infantile epileptic spasms syndrome; DEE, developmental and/or epileptic encephalopathy; EEG, electroencephalogram; MRI, magnetic resonance imaging.

in childhood. The full complement of clinical and EEG features is often absent early in the course and takes time to appear. Young children presenting with characteristic seizure types but lacking all the features need close follow-up for evolution to LGS. In particular, a number of severe infantile epilepsy syndromes, such as infantile epileptic spasms syndrome, early infantile DEE, and epilepsy of infancy with migrating focal seizures, often evolve to LGS. Repetitive assessment for LGS criteria may be helpful to access to ASMs licensed for LGS.

5.2.1 | Epidemiology

LGS accounts for approximately 1%–2% of all persons with epilepsy. In children, LGS is rarely diagnosed at initial seizure onset (0.6%). LGS often evolves from another severe infantile epilepsy syndrome or etiology, with

approximately 20% of cases evolving from infantile epileptic spasms syndrome.¹³⁷ Ultimately, 3.6% of all children with epilepsy, and 19% of children with seizures starting in infancy, evolve to LGS.¹³⁸

5.2.2 | Clinical context

LGS usually begins between 18 months and 8 years of age, with a peak age at onset of 3–5 years. Onset in the second decade is rare.¹³⁹ It is slightly more common in males. Abnormalities on neurological examination (for example pyramidal signs) are often found and are related to the underlying etiology. Most children have developmental impairment that predates seizure onset in LGS, but developmental stagnation or decline can occur with onset of frequent seizures. Less commonly, development and behavior may be normal at seizure onset.

5.2.3 | Course of illness

LGS persists into adulthood in nearly all cases, and seizures remain drug-resistant.¹³⁹ Atypical absence and tonic seizures remain frequent in adults, whereas atonic seizures often settle.¹⁴⁰

Over time, there is developmental slowing, plateauing, or regression, culminating in moderate to severe intellectual disability in >90% of patients.^{140–142} Behavior disorders such as hyperactivity, aggression, autism spectrum disorder, and sleep disturbances are common in childhood and adolescence.^{140,141}

5.2.4 | Seizures

Tonic seizures, consisting of a sustained increase in axial and limb muscle contraction lasting from 3 s to 2 min, are mandatory for diagnosis and are most prominent in sleep. They may be subtle, with slow upward eye rolling or deviation, at times with facial grimace or flexor movements of the head and/or trunk, or more clinically obvious, with a brief cry, apnea, abduction, and elevation of the limbs with a vibratory component and bilateral fist clenching. If occurring while the patient is standing, they may forcefully throw the patient off balance, leading to a fall (drop attack), with the patient often sustaining an injury. Tonic seizures may be exacerbated by medications that lead to increased sleepiness, such as acute use of high-dose benzodiazepines.

In addition to tonic seizures, a second seizure type is mandatory for the diagnosis of LGS and may include any of the following seizure types:

1. Atypical absence seizures: These are often frequent and consist of periods of impaired awareness. They may be challenging to identify with confidence due to their gradual onset and offset in a patient with underlying cognitive impairment.
2. Atonic seizures: These lead to an abrupt loss of axial tone, with head nods or a sudden fall (drop attacks), often causing injury. They are frequent, particularly in younger children with LGS. They are typically brief, lasting only one to a few seconds.
3. Myoclonic seizures: Myoclonic seizures are also very brief (<100 ms) and may lead to falls (drop attacks). If

myoclonic–atonic seizures are present, the diagnosis of EMAtS should be strongly considered.

4. Focal impaired awareness seizures: These may remain focal or evolve to bilateral tonic–clonic seizures.
5. Generalized tonic–clonic seizures.
6. Nonconvulsive status epilepticus: Approximately half to three quarters of patients with LGS have one or more episodes of nonconvulsive status epilepticus, which consist of ongoing atypical absence seizures with altered awareness, with erratic, generalized, or multifocal myoclonic and atonic components, and interspersed clusters of brief tonic seizures.
7. Epileptic spasms.

5.2.5 | Electroencephalogram

The background activity is abnormal, with diffuse theta–delta slowing, which may be more pronounced focally, depending on the underlying etiology. If prominent biparietal theta rhythms are seen, EMAtS should be considered. Two interictal patterns are mandatory for the diagnosis of LGS:

1. Generalized slow spike-and-wave: This interictal slow spike-and-wave pattern is characterized by spikes (<70 ms) or sharp waves (70–200 ms), followed by negative high-voltage slow waves (350–400 ms), which are bilaterally synchronous, often anterior predominant, and occur at a frequency of ≤ 2.5 Hz (Figure 7A). The slow spike-and-wave pattern is abundant and often occurs in runs. It can be associated with atypical absence seizures, but often waxes and wanes without any clinical correlate both in wakefulness and particularly in sleep. Generalized slow spike-and-wave (≤ 2.5 Hz) complexes are more frequently present in young children, whereas in adolescence and adulthood there is a decrease in the frequency of the spike-and-wave pattern. After the age of 16 years, the majority of patients no longer exhibit the typical slow spike-and-wave pattern.^{143–145}
2. Generalized paroxysmal fast activity: This pattern consists of bursts of diffuse or bilateral fast (10 Hz or more) activity often seen during sleep. These typically are brief, lasting a few seconds or less (Figure 7B).

FIGURE 7 Lennox–Gastaut syndrome. Interictal and ictal polygraphic electroencephalographic (EEG) recordings are shown. (A) Generalized slow spike-and-wave abnormalities (between 2 and 2.5 Hz) are seen, lasting 8 s, not associated with any clinical signs. (B) Generalized paroxysmal 10-Hz fast activity. The discharge is seen during sleep and is not associated with any clinical signs. (C) Ictal EEG showing a generalized electrodecremental response lasting 4 s associated with bilateral tonic contraction of the upper limbs, consistent with a generalized tonic seizure

Focal or multifocal slow spike-and-wave pattern may also be seen. Abnormalities are not typically activated by photic stimulation.

Tonic seizures, which are often subtle, and may not be recognized by families, are typically recorded on sleep EEG. The EEG pattern of tonic seizures consists of a burst of bilateral 10-Hz or higher frequency fast activity with a recruiting rhythm—an initial diffuse decrement followed by gradual increase in amplitude (Figure 7C). Polygraphic recordings during tonic seizures often show a brief apnea with electromyographic axial muscle contraction. Because of these characteristic findings, a sleep recording can be beneficial to distinguish LGS from other epilepsy syndromes.

Atypical absence seizures are associated with slow spike-and-wave (<3 Hz) complexes, although it can be challenging to clearly distinguish between ictal and interictal slow spike-and-wave patterns.

5.2.6 | Imaging

As structural causes are the most common etiology, MRI at onset is strongly recommended, as this may impact on treatment decision-making.¹⁴⁶ A variety of structural etiologies may be found, including focal or diffuse cortical malformations, tuberous sclerosis complex, tumors, or acquired brain injury such as hypoxic–ischemic encephalopathy. Reinvestigation of older patients with LGS can result in identification of structural etiologies missed on previous imaging.¹⁴⁷ MRI may also be normal.

5.2.7 | Genetics

Pathogenic variants in many genes have been associated with the etiologies that causes LGS and are usually de novo in the child.^{148,149} A range of chromosomal abnormalities and copy number variants have been associated with LGS, so chromosomal microarray is essential. A range of next generation sequencing approaches can be taken, ideally with whole exome sequencing, or an epilepsy gene panel, particularly if no etiology is found after clinical examination and MRI. Furthermore, genetic testing should also be considered for patients with structural brain disorders suggestive of an underlying genetic cause.

5.2.8 | Metabolic testing

Rarely, LGS can be due to a neurometabolic disorder. Metabolic testing should be considered if an underlying etiology is not found with imaging or genetic studies.

5.2.9 | Differential diagnosis

Other epilepsies:

- Infantile Epileptic Spasms syndrome may progress to LGS, and distinction between these syndromes during the transition can be challenging. In distinction to spasms, tonic seizures are typically longer than 3 s and do not occur in clusters on waking.
- EMaTS is distinguished by normal development prior to seizure onset in many cases, myoclonic–atonic seizures, and faster generalized spike-and-wave pattern, which is typically >3 Hz.
- Dravet syndrome is distinguished by prolonged, hemiconic seizures triggered by seizures in the first year of life; tonic seizures (if present) do not occur until later.
- Other early onset DEEs with multiple seizure types.
- DEE-SWAS or EE-SWAS is associated with regression and marked activation of epileptiform abnormalities in sleep, with nearly continuous diffuse spike-and-wave complexes.
- Ring (20) syndrome is associated with refractory epilepsy, intellectual disability, and behavioral abnormalities; tonic seizures usually appear during sleep, whereas awake patients frequently experience nonconvulsive status epilepticus.
- Frontal lobe epilepsy may present with bilateral tonic seizures, often with asymmetrical features. Slow spike-and-wave and generalized paroxysmal fast activity are not seen.
- Rare metabolic disorders may lead to an LGS phenotype. CLN2 disease typically begins in children with normal development or isolated speech delay. Following onset of seizures, there is progressive motor and cognitive decline and ataxia. The EEG characteristically shows a photoparoxysmal response at 1–3 Hz.

5.3 | DEE-SWAS and EE-SWAS

DEE-SWAS and EE-SWAS refer to a spectrum of conditions that are characterized by various combinations of cognitive, language, behavioral, and motor regression associated with marked spike-and-wave activation in sleep. Regression is seen within weeks from the EEG pattern. DEE-SWAS and EE-SWAS share similar clinical features (Table 10) and management implications. They are grouped together because they carry similar implications, and the syndrome highlights the need to inquire about specific clinical features when seeing a child, such as auditory agnosia, global regression of behavior and motor skills, and negative myoclonus. This syndrome is intended to replace syndromes previously named epileptic encephalopathy

TABLE 10 Developmental and epileptic encephalopathy with SWAS and epileptic encephalopathy with SWAS

	Mandatory	Alerts	Exclusionary
Seizures		Tonic seizures during sleep	Epileptic spasms
EEG	Slow (1.5–2 Hz) spike-and-wave abnormalities in N-REM sleep Abnormalities are markedly activated in sleep	Generalized paroxysmal fast activity in sleep (consider Lennox–Gastaut syndrome) Generalized slow spike-and-wave complexes of <2.5 Hz in both awake and asleep states (consider Lennox–Gastaut syndrome)	
Age at onset		>1 and <2 years	<1 year or >12 years
Development at onset	Cognitive, behavioral, or motor regression or plateauing temporally related to SWAS on EEG		
Long-term outcome	Remission of SWAS pattern on EEG by mid adolescence, although EEG often remains abnormal		

An MRI is not required for diagnosis but is often performed to evaluate for underlying etiology.
A sleep EEG is mandatory for diagnosis.

Syndrome without laboratory confirmation: In resource-limited regions, this syndrome cannot be presumptively diagnosed without a sleep EEG.

Note: Alert criteria are absent in the vast majority of cases, but rarely can be seen. Their presence should result in caution in diagnosing the syndrome and consideration of other conditions.

Abbreviations: EEG, electroencephalogram; MRI, magnetic resonance imaging; N-REM, non-rapid eye movement; SWAS, spike-and-wave activation in sleep.

with continuous spike-and-wave in sleep and atypical benign partial epilepsy (pseudo-Lennox syndrome). Landau-Kleffner syndrome (LKS) is a specific subtype of EE-SWAS, where regression affects mainly language, with an acquired auditory agnosia, and the eponym used to describe this syndrome should be retained (Figure 8).

Sleep EEG must be performed to confirm the diagnosis. The EEG pattern associated with EE-SWAS and DEE-SWAS was known as electrical status epilepticus in sleep (ESES).^{11,150} Historically, ESES was defined as nearly constant epileptiform activity that occupies >85% of slow wave sleep; however, lower percentages of sleep may also be associated with significant regression in cognitive or behavioral function.

EE-SWAS is now recognized in patients with pre-existing normal development with an activation of slow (1.5–2 Hz) spike-and-wave complexes in non-rapid eye movement (N-REM) sleep.

DEE-SWAS occurs in patients with pre-existing neurodevelopmental disorders and is defined on the basis of a documented persisting worsening of various combinations of cognitive, language, behavioral, and motor functions concomitant with significant activation of spike-and-wave complexes during sleep. Caution is needed not to overdiagnose the syndrome in the absence of clear and persisting regression.

Specific focal epilepsy syndromes, such as SeLECTs and SeLEAS, or other structural focal epilepsies, may evolve to EE-SWAS, either transiently or for a prolonged period.

5.3.1 | Epidemiology

DEE-SWAS and EE-SWAS are rare, accounting for 0.5%–0.6% of all epilepsy presentations seen at pediatric tertiary epilepsy centers.^{151–153}

5.3.2 | Clinical context

DEE-SWAS and EE-SWAS are characterized by onset of seizures at between 2 and 12 years of age (peak = 4–5 years), with the EEG developing spike-and-wave activation in sleep 1–2 years after seizure onset in association with cognitive/behavioral regression or plateauing. Both sexes are affected equally. Antecedent and birth history are often normal; however, structural brain lesions are a risk factor for DEE-SWAS and EE-SWAS. Specifically, thalamic injury in early life¹⁵⁴ and malformations such as bilateral perisylvian polymicrogyria are associated with this syndrome; therefore, neuroimaging, particularly MRI, is recommended whenever possible. Neurological examination and developmental level may be normal or reflect an underlying structural brain abnormality. Regression in cognitive, behavioral, or psychiatric functioning is the cardinal symptom of this syndrome. All cognitive domains can be affected, including language and communication, temporospatial orientation, attention, and social interaction. Motor regression with dyspraxia or dystonic features may also occur.¹⁵⁵ Follow-up visits with clinical assessment, EEGs, and neuropsychological

EE or DEE with spike-wave activation in sleep

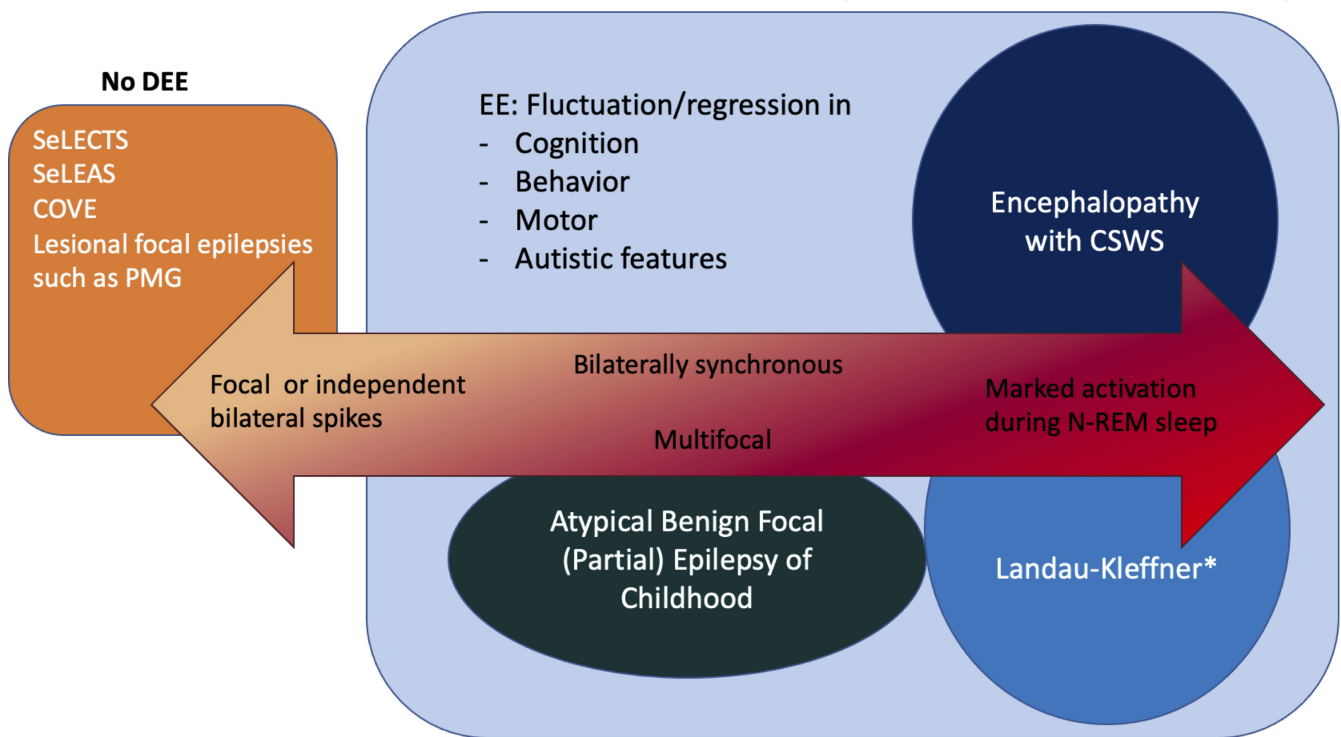


FIGURE 8 Developmental and/or epileptic encephalopathy (DEE) and epileptic encephalopathy (EE) with spike-and-wave activation in sleep (SWAS) refer to a spectrum of conditions that are characterized by various combinations of cognitive, language, behavioral, and motor regression associated with marked spike-and-wave activation in sleep. Regression is seen within weeks from the electroencephalographic pattern. This syndrome is intended to replace syndromes previously named Epileptic Encephalopathy with Continuous Spike-and-Wave in Sleep and Atypical Benign Partial Epilepsy (pseudo-Lennox syndrome). *Landau-Kleffner syndrome is a specific subtype of EE-SWAS, where regression affects mainly language with an acquired auditory agnosia. Specific focal epilepsy syndromes, such as self-limited epilepsy with centrotemporal spikes (SeLECTS) and self-limited epilepsy with autonomic seizures (SeLEAS), or other structural focal epilepsies, may evolve to EE-SWAS, either transiently or for a prolonged period. CSWS, continuous spike-and-wave complexes during sleep, N-REM, non-rapid eye movement; PMG, polymicrogyria

testing should be scheduled at baseline and during the follow-up to assess the evolution.¹⁵⁶

5.3.3 | Course of illness

Clinical seizures typically remit around puberty, even in patients with a structural lesion.¹⁵⁷ Resolution of clinical seizures may precede, coincide with, or follow the resolution of the EEG pattern.¹⁵⁷ The SWAS pattern on EEG also resolves, typically by adolescence.^{158,159} Focal abnormalities may persist during both wakefulness and sleep. Sleep architecture normalizes with resolution of SWAS.¹⁵⁸

Neurocognitive and behavioral improvement is typically seen, with resolution of the SWAS on EEG.¹⁶⁰ However, many patients have residual impairment, which is severe enough to limit independent functioning in approximately half of the patients.^{161,162} The duration and etiology of DEE-SWAS and EE-SWAS are the most important predictors of cognitive outcome; the risk of poor outcome

is higher if it is present for >2 years.¹⁶³ Poorer outcomes are also seen with younger onset of DEE-SWAS.¹⁶³ Thus, early diagnosis is of paramount importance to enable initiation of treatment to improve long-term outcome even if some causes are not treatable (the etiology prevails), and there may be no clinical improvement for some when the EEG pattern is abolished. Nevertheless, residual deficits may remain following remission of seizures and SWAS, which may occur from months to 7 years after onset.

5.3.4 | Seizures

There is no mandatory seizure type. Seizure type is dependent on the underlying etiology. Furthermore, EE-SWAS and DEE-SWAS may occur in patients who do not have clinical seizures.

In most patients, infrequent and drug-responsive seizures are observed during the initial phase at between 2 and 5 years of age. These early seizures are typically focal

motor, with or without impaired awareness, and focal to bilateral tonic-clonic seizures. Seizures typically worsen with the evolution of multiple seizure types. These include focal seizures with or without impaired awareness, typical and atypical absence seizures, atonic seizures, and focal motor seizures with negative myoclonus.

5.3.5 | Electroencephalogram

The EEG pattern depends on the underlying etiology. The background activity during wakefulness may show focal or diffuse slowing and often contains focal or multifocal abnormalities, but it may be normal (Figure 9A).

Epileptiform abnormalities during wakefulness are not continuous. In drowsiness and sleep, there is marked activation of epileptiform activity, with slow (1.5–2 Hz) spike-and-wave complexes in N-REM sleep. Typically, this activity is also seen in Stage II sleep (Figure 9B). SWAS is usually diffuse but may occur more focally (typically frontally) or multifocally. In rapid eye movement sleep, the abnormalities become less frequent or may even be absent. Normal sleep architecture (vertex sharp waves, sleep spindles, and K complexes) is absent or difficult to distinguish. An overnight sleep EEG may be required, as slow wave sleep may not be achieved on an outpatient sleep EEG. The ictal EEG correlates with the seizure type.

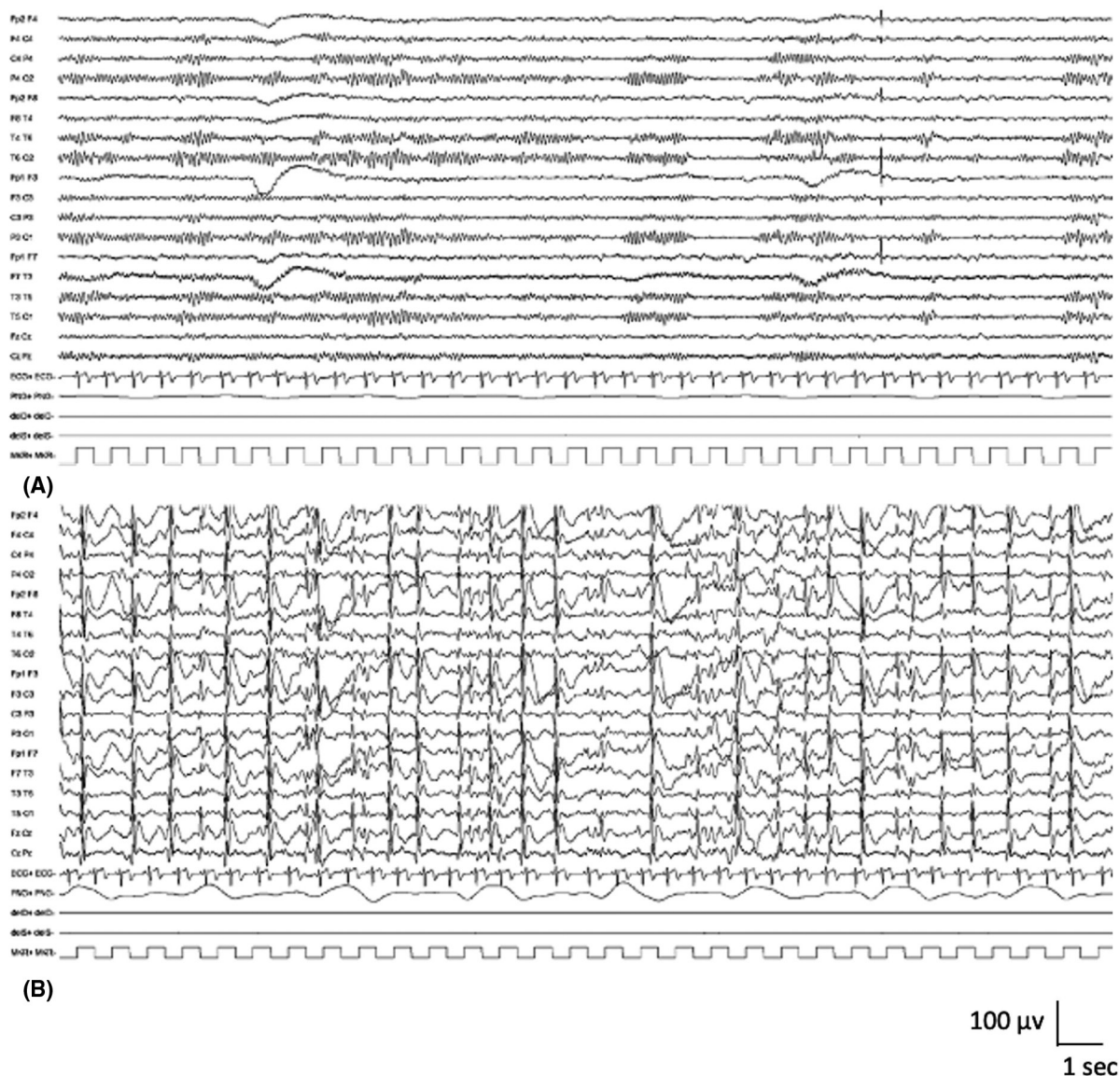


FIGURE 9 Epileptic encephalopathy with spike-and-wave activation in sleep. Awake and sleep polygraphic electroencephalographic (EEG) recordings are shown. (A) Awake EEG shows a background activity characterized by 9–10-Hz alpha rhythm, with lower amplitude, fast activity seen over the bilateral anterior regions. There are no epileptiform abnormalities. (B) During sleep, there are continuous generalized spike-and-wave abnormalities

5.3.6 | Imaging

Neuroimaging may be normal or demonstrate underlying structural brain abnormalities that may be developmental (e.g., perisylvian polymicrogyria) or acquired (thalamic abnormalities can be observed).

5.3.7 | Genetics

Some cases have a genetic basis and may follow monogenic or complex inheritance. A family history of seizures is seen in up to 50% patients with DEE-SWAS or EE-SWAS.¹⁶⁴ The major monogenic cause is *GRIN2A*, which encodes the N-methyl-D-aspartate (NMDA) receptor glutamate receptor alpha 2 subunit.¹² Pathogenic variants are associated with a range of severity of DEE-SWAS phenotypes.^{13–15} These individuals have a characteristic speech pattern, which may persist into adult life.¹⁶⁵

5.3.8 | Differential diagnosis

Other epilepsy syndromes:

- SeLFEs can have marked activation of epileptiform abnormalities in sleep, but there is not temporally related cognitive or behavioral regression with the EEG finding of SWAS.
- Structural focal epilepsies may have abundant focal abnormalities that may activate in sleep, but there is not temporally related cognitive or behavioral regression with the EEG finding of SWAS.
- LGS is distinguished by the EEG, which shows prominent slow spike-and-wave complexes during both wakefulness and sleep, and by the sleep EEG, which shows generalized paroxysmal fast activity, and often tonic seizures are captured.

Other conditions:

- Children with autism spectrum disorders with or without intellectual disability but without regression may show activation of epileptiform abnormalities in sleep.
- Cognitive regression due to other etiologies.

5.4 | Febrile infection-related epilepsy syndrome

FIRES (previously also known as acute encephalitis with refractory, repetitive partial seizures, or devastating

epileptic encephalopathy in school-aged children) is one cause of new onset refractory status epilepticus, which occurs predominantly in children and adolescents (Table 11). A prior febrile infection occurs, starting between 24 h and 2 weeks, prior to an explosive onset of superrefractory status epilepticus; there may or may not be fever at onset of status epilepticus.¹⁶⁶ The acute phase, during which the seizure burden is very high, lasts 1–12 weeks,¹⁶⁷ and during this phase, mortality and morbidity are significant. This is followed by a chronic phase, where most survivors are left with drug-resistant multifocal epilepsy and a variable degree of intellectual disability or learning difficulties. The cause is not known, but growing evidence suggests a heterogeneous etiology resulting in fulminant non-antibody-mediated neuroinflammation.^{168,169}

5.4.1 | Epidemiology

This is a rare syndrome, which is likely underrecognized, with an estimated incidence of 1 per million.¹⁷⁰

5.4.2 | Clinical context

FIRES occurs most commonly in school-aged children (mean = 8 years) with a typical range of 2–17 years.^{166,169,171} It is exceedingly infrequent under the age of 2 years and can begin at a variable age, but may rarely occur in young adulthood. Both sexes are affected, with a slight male predominance.¹⁷¹ Perinatal history is typically normal. At presentation, children are developmentally normal, without a history of prior neurological disease including epilepsy, and have normal head size.

All children have a history of a prior febrile infection, most commonly upper respiratory or gastrointestinal, between 24 h and 2 weeks before onset of refractory status epilepticus. At the time of seizure onset, patients may still be febrile, or may have had recent resolution of the fever.

At presentation, patients are typically encephalopathic and have frequent seizures despite ASMs. Head size is normal. Persistent focal abnormalities on examination are unusual, but transient Todd paresis may be seen.

5.4.3 | Course of illness

The prognosis is variable but often poor.¹⁷¹ Mortality is approximately 10% in the acute phase, due to intensive care complications such as sepsis, or uncontrolled status

TABLE 11 Febrile infection-related epilepsy syndrome

	Mandatory	Alerts	Exclusionary
Seizures	History of nonspecific febrile illness in the 2 weeks preceding seizure onset Focal and multifocal seizures that often evolve to bilateral tonic-clonic seizures Seizures progress in frequency and severity to culminate in superrefractory status epilepticus typically within 2 weeks of onset		History of epilepsy prior to onset of symptoms
EEG	Slowing of the background activity with multifocal epileptiform abnormalities and frequent, focal electrographic and electroclinical seizures	Unifocal seizures	
Age at onset		<2 years	<1 year or >30 years
Development at onset	Acute encephalopathy with onset of frequent seizures	Intellectual disability prior to seizure onset	
Neurological exam		Neurological exam abnormalities prior to onset of seizures	
Imaging			At presentation, MRI shows an epileptogenic lesion concordant with seizure onset (see text)
Other testing			Lumbar puncture showing evidence of central nervous system infection Causal antibody on CSF or plasma autoimmune testing Documented metabolic or genetic etiology Documented toxic encephalopathy
Long-term outcome		Lack of drug-resistant focal or multifocal epilepsy Lack of learning difficulties or intellectual disability Lack of variable degrees of cerebral atrophy on MRI	

An MRI is required for diagnosis to exclude a causal lesion.

An ictal EEG is required for diagnosis to confirm frequency and multifocality of seizures.

Syndrome without laboratory confirmation: In resource-limited regions, this syndrome cannot be presumptively diagnosed without EEG and MRI studies.

Note: Alert criteria are absent in the vast majority of cases, but rarely can be seen. Their presence should result in caution in diagnosing the syndrome and consideration of other conditions.

Abbreviations: CSF, cerebrospinal fluid; EEG, electroencephalogram; MRI, magnetic resonance imaging.

epilepticus. Following the acute phase, most children are left with drug-resistant, multifocal epilepsy.

Developmentally, in the acute stage, most children regress, and at follow-up, in the chronic phase, the majority are left with varying degrees of intellectual disability.¹⁷¹ Approximately one third of survivors have normal or borderline cognition (often learning disorders), one third have mild to moderate intellectual disability, and

one third have severe to profound disability or are vegetative. Poorer outcome was associated with longer duration of medically induced burst-suppression coma and younger age at onset.¹⁷¹ Attention and behavior problems, including aggression, are also common in survivors.

In the chronic phase, many patients will have evidence of motor dysfunction.

5.4.4 | Seizures

Focal or multifocal seizures are mandatory for diagnosis and may evolve to bilateral tonic-clonic seizures. Common ictal symptoms are eye deviation and hemifacial twitching. Seizures progress in frequency and severity rapidly to culminate in superrefractory status epilepticus (defined as >24 h) in the acute phase.

5.4.5 | Electroencephalogram

The EEG background activity is typically abnormal, with slowing and multifocal abnormalities. Recurrent extreme delta brush, consisting of a paroxysmal beta-delta complex of 15–18-Hz beta superimposed on 1–3-Hz delta in the frontal and central head regions, is often seen (Figure S4A,B).¹⁷² This pattern may be modified by anesthetic agents used for the treatment for status epilepticus.

Prolonged video-EEG monitoring at diagnosis shows a gradual increase in seizure burden over the first days to week of illness. Initially, seizure burden may be low, but over time, frequent, multifocal subclinical and clinical seizures are recorded, usually with a frequency of several per hour.¹⁷² A typical seizure pattern, consisting of focal activity of >10 Hz of low to moderate amplitude, evolving to well-formed, rhythmic spikes and spike-and-wave complexes, is seen, and ictal activity often shifts from one hemisphere to the other (Figure S4C).¹⁷²

5.4.6 | Neuroimaging

During the acute stage, the MRI is normal in approximately two thirds of cases. Approximately one third may show T2 hyperintense changes in bilateral temporal regions, insula, basal ganglia, and/or thalami, which may be subtle. Leptomeningeal enhancement may also be seen but is not specific to this syndrome.¹⁷³

During the chronic stage, the MRI usually shows variable degrees of diffuse cerebral atrophy, and/or signal changes over the temporal lobes, cerebral cortex, periventricular white matter, hippocampi, and basal ganglia.¹⁷³

5.4.7 | Genetics

This disorder is not suspected to be genetic, and no causal genes have been identified. There is usually no family history of seizures.

5.4.8 | Other laboratory studies

Examination of cerebrospinal fluid (CSF) is required to exclude infection. The CSF is typically normal but may show a mild pleocytosis. CSF protein and lactate are normal. Oligoclonal bands are negative. An immune etiology should be excluded, but in FIRES, no causal antibodies have yet been found.¹⁶⁹ Serum and CSF autoimmune panels are negative. It has been reported that Th1 chemokines (CXCL9, CXCL10, etc.) are predominantly upregulated in CSF, independently of interleukin-1 receptor (IL-1R) signaling.¹⁷⁴ Metabolic studies are unremarkable. In some cases, excessive neuroinflammation, which may be secondary to functional deficiency in IL-1R antagonist, has been reported.^{175,176}

5.4.9 | Differential diagnosis

Other epilepsy syndromes:

- Dravet syndrome is distinguished by its presentation predominantly in the first year of life, and history of intermittent prolonged seizures with interval recovery, as opposed to a singular superrefractory status epilepticus with the development of persistent morbidity.
- *PCDH19* clustering epilepsy is distinguished by its presentation in the first 3 years of life, and history of a cluster of seizures usually induced by fever. Superrefractory status epilepticus is unusual.

Other conditions:

- Meningitis or encephalitis.
- Specific autoimmune-mediated encephalopathies such as anti-NMDA receptor encephalitis.
- Toxic encephalopathies.
- Metabolic disorders such as mitochondrial disease.

5.5 | Hemiconvulsion–hemiplegia–epilepsy syndrome

HHE is a rare consequence of focal motor status epilepticus in infancy and early childhood (Table 12). The initiating event for this syndrome is a focal clonic status epilepticus typically occurring in the context of a febrile illness in children <4 years of age.¹⁷⁷ Neuroradiological studies at the time of the status epilepticus show unilateral edematous swelling of the affected hemisphere. The acute phase is followed by hemispheric atrophy with subsequent appearance of

TABLE 12 Hemiconvulsion–hemiplegia–epilepsy syndrome

	Mandatory	Alerts	Exclusionary
Seizures	Diagnosis requires both a history of acute stage and chronic stage disease Acute stage: Episode of febrile, hemiclonic status epilepticus, which is immediately followed by permanent hemiparesis Chronic stage: After a variable time (usually <3 years after initial status epilepticus), unilateral focal motor or focal to bilateral tonic–clonic seizures appear		Transient hemiparesis (Todd paresis) Unilateral focal motor seizures that progress in a crescendo pattern over months to years, with late development of progressive hemiparesis (consider Rasmussen encephalitis)
EEG	Slowing of background activity over the affected hemisphere Focal or multifocal epileptiform abnormalities over the affected hemisphere in the chronic phase		
Age at onset		>4 years	>6 years
Development at onset		Intellectual disability prior to seizure onset	
Neurological exam		Focal neurological abnormalities prior to initial episode of febrile status epilepticus Facial angioma suggestive of Sturge–Weber syndrome	
Imaging	MRI immediately following febrile status epilepticus (acute stage) shows diffuse signal change with T2 hyperintensity and restricted diffusion of the subcortical region of the affected hemisphere, often with severe edema Over time (chronic stage), there is atrophy of the affected hemisphere		Other structural causes predisposing to focal status epilepticus
Other testing			Alternative cause of hemiparesis found such as acute ischemic stroke, intracranial infection, etc.
Long-term outcome	Drug-resistant epilepsy Permanent focal motor deficit		

An MRI is required to diagnosis.

An ictal EEG is not required for diagnosis.

Syndrome-in-evolution: Children with acute permanent hemiparesis following an episode of focal convulsive febrile status epilepticus, with mandatory MRI findings, but who have not yet progressed to the chronic phase of the disease with recurrent, drug-resistant focal motor or focal to bilateral tonic–clonic seizures should be suspected of having emerging hemiconvulsion–hemiplegia–epilepsy syndrome.

Syndrome without laboratory confirmation: In resource-limited regions, hemiconvulsion–hemiplegia–epilepsy syndrome can be presumptively diagnosed without EEG in cases that meet all mandatory and exclusionary clinical criteria without alerts. However, an imaging study (CT or MRI) is required to exclude other causes.

Note: Alert criteria are absent in the vast majority of cases, but rarely can be seen. Their presence should result in caution in diagnosing the syndrome and consideration of other conditions.

Abbreviations: CT, computed tomography; EEG, electroencephalogram; MRI, magnetic resonance imaging.

focal seizures, which are drug-resistant. The majority of patients have a resultant permanent motor deficit. The etiology and the underlying mechanisms are not understood.

5.5.1 | Epidemiology

HHE is a rare syndrome and its incidence has declined markedly in resource-equipped countries over the past

30 years since the instigation of aggressive treatment for prolonged seizures or status epilepticus.¹⁷⁸

5.5.2 | Clinical context

Age at onset is typically <4 years, and there is no sex predilection.^{178,179} Birth and antecedent history are noncontributory, and previous development and neurological examination are normal. Children present with prolonged focal status epilepticus and then develop immediate hemiparesis. The diagnosis of HHE should be considered when a persistent hemiplegia is observed after febrile status epilepticus in a child younger than 4 years. Aphasia may also be present acutely in up to one quarter of cases, if the dominant hemisphere is involved.¹⁸⁰

5.5.3 | Course of illness

The majority of children are left with a permanent motor deficit. However, this deficit may be minimal or resolve within 12 months in 20%.¹⁷⁷ If present, aphasia most commonly resolves within 2 months¹⁸⁰ but may persist.¹⁸¹ Subsequent focal seizures appear after a variable duration, with 85% having seizure onset within 3 years of the initial status epilepticus.¹⁷⁸ Focal seizures during the chronic phase are typically drug-resistant,¹⁷⁹ but may be amenable to surgical treatment, such as hemispherotomy.^{178,182} Many children are also left with variable degrees of intellectual disability.¹⁷⁸

5.5.4 | Seizures

The first seizure is typically focal clonic febrile status epilepticus. The clonic component may be subtle. There is typically a seizure-free period after the focal status epilepticus that can last months to years. After a variable period, focal motor seizures and/or focal to bilateral tonic-clonic seizures appear, and usually become drug-resistant. Seizures may localize solely to the temporal lobe or may arise from extratemporal regions or be multifocal.¹⁸²

5.5.5 | Electroencephalogram

If an EEG is obtained during the acute focal status epilepticus, the ictal discharge is characterized by rhythmic (2–3 Hz) slow waves that are usually bilateral with higher amplitude over the affected hemisphere (Figure S5A,B).¹⁷⁸ In addition, over the affected hemisphere,

recruiting rhythms (10 Hz) are frequently seen.¹⁷⁸ The background activity may be normal at onset, but during the chronic phase, there is excess slowing (often asymmetric) and epileptiform abnormalities, which are most prominent over the affected hemisphere, but may be bilateral.

5.5.6 | Imaging

MRI immediately following the status epilepticus demonstrates diffuse hemispheric signal abnormalities with T2 hyperintensity and restricted diffusion, predominantly of the subcortical white matter of the affected hemisphere.¹⁸³ Edema of the affected hemisphere can be severe, leading to mass effect and possible herniation (Figure S5C–F).¹⁷⁸ If magnetic resonance spectroscopy is done, it shows decreased N-acetyl aspartate and mildly increased lactate in the affected hemisphere. On Day 8–15 after status epilepticus, cytotoxic edema decreases, with normalization of apparent diffusion coefficient images and ongoing T2 hyperintensity, with evolving volume loss. Within 1 month, atrophy of the affected cerebral hemisphere is clearly evident. Hippocampal sclerosis is also commonly seen (Figure S5G–J).¹⁸²

5.5.7 | Genetics and other testing

Genetic testing and evaluation for coagulation, metabolic, infective, and immune disorders are typically normal.^{178,184}

5.5.8 | Differential diagnosis

Other epilepsy syndromes:

- Dravet syndrome presents in infancy with prolonged hemiclonic seizures in the context of a febrile illness, which may result in transient Todd paresis. However, this deficit resolves, and the typical MRI abnormalities of HHE are not present.
- Sturge–Weber syndrome may present with focal motor status epilepticus, but the skin lesions and MRI showing the typical features of this syndrome should suggest the diagnosis.
- Rasmussen syndrome presents with unilateral focal motor seizures, but the progression is much slower, and focal status epilepticus is seen later in the evolution and is a more persistent feature when it occurs. MRI may be normal at seizure onset or show

mild insular atrophy but evolves to focal white matter changes and hemispheric atrophy over months to years.

- Focal febrile status epilepticus or focal status epilepticus due to other etiologies can be followed by Todd paresis, which typically resolves within 24 h.

Other conditions:

- Meningitis and encephalitis.
- Hemorrhagic or ischemic stroke.
- Polymerase gamma- or MELAS-related mitochondrial disease.

6 | DISCUSSION

Although not every child with epilepsy can be classified as having a specific epilepsy syndrome, identification of a syndrome can provide guidance on management and prognosis. An electroclinical approach, combining a detailed clinical history and an EEG recording, is needed to reach a syndrome diagnosis. Most of the syndromes described above have a mandatory seizure type or types and often mandatory interictal EEG features. A diagnostic hypothesis is crucial to ensure adequate EEG studies, including both wakefulness and sleep, are recorded to inform syndrome diagnosis. A sleep EEG is required to identify mandatory EEG patterns in some syndromes, such as LGS, DEE-SWAS, and EE-SWAS. Moreover, detailed seizure semiology based on history is adequate to diagnose many seizure types without obtaining an ictal recording. However, for seizure types in certain syndromes, an ictal EEG recording is required for diagnosis. For example, it is not easy to determine a specific seizure type for a “drop attack” based on history alone. Even the use of home video recordings, which are undoubtedly helpful in many cases, cannot always confirm a definitive seizure type. Based on the diagnostic hypothesis, a specific EEG type (sleep-deprived, prolonged video-EEG) may be required to confirm a syndrome diagnosis.

In many but not all cases, syndrome identification informs likely etiology. This allows clinicians to initiate the highest yield investigations to minimize discomfort and invasive investigations for the patient, and to reach a specific diagnosis, in the most cost-effective manner. Specific comorbidities also correlate strongly with specific syndrome, and thus identification of an epilepsy syndrome may assist in their earlier recognition and management. In the context of a specific epilepsy syndrome, the occurrence of comorbidities is of paramount importance, as they may be responsible for a greater burden for the

patient than the seizures. Increasingly, precision therapies are being identified that target specific etiologies, and recent clinical trials in epilepsy are targeting specific syndromes.

Whereas some syndromes are highly correlated with specific etiologies, others are associated with a diverse group of etiologies. Despite well-recognized electroclinical epilepsy syndromes, evolution and outcome are often still challenging to predict accurately and often depend upon the underlying etiology. With rapid advances in genetics, immunology, and imaging, it is likely that further etiology-specific syndromes will be identified, and it might be possible to predict which patients will respond best to a specific treatment, or to identify a specific or novel therapy based on the causative genes or pathway responsible for the disorder. Use of therapies that target the underlying neurobiological process that leads to epileptogenesis may significantly ameliorate comorbidities as well as seizures.

Furthermore, it is well recognized that specific ASMs may exacerbate certain conditions, such as sodium channel agents for many of the IGEs. Moreover, some ASMs are more likely to be effective for several seizure types, such as absence seizures and generalized tonic-clonic seizures. Thus, early syndrome identification will allow for selection of the optimal therapy, which is most likely to lead to early seizure control and to prevention of other seizure types that may evolve into a specific syndrome.

Accurate syndrome definition will often inform natural history and likelihood of remission. Some syndromes are self-limited over time. For these, we can provide reassurance to families of the favorable long-term outcome and can also avoid excessively prolonged use of chronic ASMs, and unnecessary diagnostic tests or treatments. Conversely, other syndromes have a much poorer outcome, such as LGS, HHE, or FIRES. In those, we understand from their onset that evolution will be unfavorable, typically with drug-resistant and life-long seizures and adverse neurodevelopmental sequelae. In such cases, a more aggressive treatment approach may be undertaken, with regular review, to attempt to ameliorate overall function and quality of life outcomes. However, it should be acknowledged that treatment options for these syndromes are often limited, the choice of the most appropriate medication is not always clear from studies to date, and polytherapy might increase the risk for adverse events or in some cases, cause seizure aggravation. Many patients with these syndromes might benefit from participation in future clinical trials of novel medications. Some syndromes do not fall clearly into a self-limited epilepsy or DEE, but rather they might have an uncertain evolution: EMA, EEM, EMAtS, and EE-SWAS. Outcome is variable, in terms of both seizure remission and cognitive and

psychiatric comorbidities. In these latter conditions, there is a spectrum of severity; patients might present with or evolve to intellectual disability ranging from mild to severe, with variable degrees of neurological impairment. Sometimes, even if seizures remit, neurological sequelae persist.

As described above, some syndromes may evolve to another syndrome over time, such as SeLEAS to SeLECTS, and SeLECTS to EE-SWAS. This raises the question of the possible neurobiological links between these syndromes. To date, it is unclear why the majority of children have just one syndrome, whereas others evolve. Such evolution is likely to be due to underlying neurobiological factors. As future research provides insights into the underlying etiology, we may be able to more accurately distinguish the patients who will not show progression from one syndrome to another. Such insights will modify therapeutic approaches from the onset of their epilepsy. Identification of biomarkers may allow intervention to prevent such evolution.

The most significant nosological changes in the childhood syndromes are in the SeLFEs, which were formerly known as “benign” or “idiopathic” focal epilepsies, and DEE-SWAS or EE-SWAS, which was formerly known by the terms LKS, ESES, and epileptic encephalopathy-continuous spike-and-waves during sleep.

The nomenclature “SeLFE” was chosen to reflect the key features of the natural history, and the clinical phenotype. The term “benign” is inappropriate, as many children have associated cognitive and psychiatric comorbidities. For each syndrome, the nomenclature used reflects the major phenotypic features, such as centrotemporal spikes in SeLECTs, autonomic seizures in SeLEAS, occipital semiology and EEG findings in COVE, and photic-induced focal sensory visual seizures and genetic predisposition in POLE. Similarly, the terms DEE-SWAS and EE-SWAS comprise the two essential components, cognitive regression and the characteristic EEG pattern.

We elected to keep the term LGS for several reasons. Most importantly, the term LGS is crucial in allowing patients to acquire the multiple supports including medical and disability support therapies that they require on a daily basis. Replacing this term would lead to a lapse in services that these patients critically require. Additionally, the syndrome comprises multiple seizure type and etiologies, which would be challenging to capture in a succinct name.

Our hope is that using clearer language, with terms directly expressing the seizure semiology that are consistent with the 2017 Epilepsy and Seizure classification, will facilitate both recognition and accurate diagnoses, for health care professionals and families caring for children with epilepsy. The definitions for epilepsy syndromes provided in this paper will require validation in longitudinal

studies and may be further refined as new data are published over time. Future work may expand on the definitions of more etiology-specific epilepsy syndromes. This may aid earlier clinical recognition of some etiologies that benefit from prompt targeted treatment.

ACKNOWLEDGMENTS

We gratefully acknowledge the input from the following persons outside of our Nosology and Definitions Task Force who assisted with the Delphi Panels: Drs Birinus Adikaibe, Raidah Al Baradi, Danielle Andrade, Thomas Bast, Ahmed Beydoun, Christian Bien, Roberto Caraballo, Ana Carolina Coan, Mary Connolly, John Dunne, Sheryl Haut, Floor Jansen, Barbara Jobst, Reetta Kalviainen, Angela Kakooza, Mitsuhiro Kato, Kelly Knupp, Silvia Kochen, Lieven Lagae, Luis Carlos Mayor, Natela Okujava, Kurupath Radakishnan, Eliane Roulet-Perez, Loreto Rios, Lynette Sadleir, Daniel San Juan-Orta, Jose Serratos, Renee Shellhaas, Meng-Han Tsai, Vrajesh Udani, Helen Yue-Hua Zhang, and Dong Zhou.

S.L.M. is the Charles Frost Chair in Neurosurgery and Neurology and acknowledges grant support from the National Institutes of Health (U54 NS100064 and NS43209), US Department of Defense (W81XWH-18-1-0612), the Heffer Family and the Segal Family Foundations, and the Abbe Goldstein/Joshua Lurie and Laurie Marsh/Dan Levitz families. R.P.'s research is supported by the National Institute of Health Research (NIHR) Biomedical Research Centre at Great Ormond Street Hospital, Cambridge Biomedical Research Centre, the NIHR, and the Evelyn Trust. The views expressed are those of the authors and not necessarily those of funders.

CONFLICT OF INTEREST

N.S. has served on scientific advisory boards for GW Pharma, BioMarin, Arvelle, Marinus, and Takeda; has received speaker honoraria from Eisai, BioMarin, LivaNova, and Sanofi; and has served as an investigator for Zogenix, Marinus, BioMarin, UCB, and Roche. E.C.W. has served as a paid consultant for Encoded Therapeutics and BioMarin. She is the Editor-in-Chief of Epilepsy.com. I.E.S. has served on scientific advisory boards for UCB, Eisai, GlaxoSmithKline, BioMarin, Nutricia, Rogcon, Chiesi, Encoded Therapeutics, and Xenon Pharmaceuticals; has received speaker honoraria from GlaxoSmithKline, UCB, BioMarin, Biocodex, and Eisai; has received funding for travel from UCB, Biocodex, GlaxoSmithKline, BioMarin, and Eisai; has served as an investigator for Zogenix, Zynerva, Ultragenyx, GW Pharma, UCB, Eisai, Anavex Life Sciences, Ovid Therapeutics, Epigenyx, Encoded Therapeutics, and Marinus; and has consulted for Zynerva Pharmaceuticals, Atheneum Partners, Ovid

Therapeutics, Care Beyond Diagnosis, Epilepsy Consortium, and UCB. R.N. has served as principal investigator in clinical trials for Novartis, Nutricia, Eisai, UCB, GW Pharma, and LivaNova. She received consulting fees from Biogene, BioMarin, GW Pharma, Zogenix, Novartis, Nutricia, Stoke, Ionis, Targeon, and Takeda and honoraria from Nutricia, Biocodex, Zogenix, GW Pharma, Advicennes, and Eisai. She has received unrestricted research grants from Eisai, UCB, LivaNova, and GW Pharma and academic research grants from EJP-RD (horizons 2020) and IDEAL-EPISTOP. S.M.Z. has received research support from Epilepsy Research UK, Tenovus Foundation, Glasgow Children's Hospital Charity, and Scottish Government Technology Enabled Care. He has received honoraria for educational symposia, advisory boards, and consultancy work from GW Pharma, Zogenix, Arvelle Therapeutics, and Encoded Therapeutics. J.M.W. has received paid honorarium for activities as Associate Editor of *Epilepsia*. R.P. is an investigator for studies with UCB and does consultancy work for Kephala, Ireland. She has served as a speaker and/or on advisory boards for Natus, GW, Eisai, and UCB. E.H. has received honoraria from UCB, Eisai, LivaNova, Novartis, and GW Pharmaceuticals. S.W. has received unrestricted educational grants from UCB Pharma, Eisai, and Sunovion. H.J.C. has acted as an investigator for studies with GW Pharma, Zogenix, Vitaflo, and Marinius. She has been a speaker and on advisory boards for GW Pharma, Zogenix, and Nutricia; all remuneration has been paid to her department. Her research is supported by the NIHR Biomedical Research Centre at Great Ormond Street Hospital. She holds an endowed chair at UCL Great Ormond Street Institute of Child Health; she holds grants from NIHR, EPSRC, GOSH Charity, ERUK, and the Waterloo Foundation. P.T. received speaker's or consultancy fees from Arvelle, Eisai, GW Pharma, LivaNova, UCB Pharma, Xenon Pharma, and Zogenix. S.A. has served as consultant or received honoraria for lectures from Biocodex, Biomarin, Eisai, GW Pharma, Neuraxpharm, Nutricia, UCB Pharma, Xenon, and Zogenix. He has been an investigator for clinical trials for Eisai, UCB Pharma, and Zogenix. He is an Associate Editor for *Epilepsia*. K.R. has received speaker honoraria, advisory board payments, and/or research funding from UCB, Eisai, Novartis, Zogenix, SK Lifesciences, AFT Pharmaceuticals, LivaNova, Queensland Genomic Health Alliance, Department of Health (Australia), Medicare International, Novartis, and Janssen-Cilag. S.L.M. serves as an Associate Editor of *Neurobiology of Disease*. He is on the editorial board of *Brain and Development*, *Pediatric Neurology*, *Annals of Neurology*, *MedLink*, and *Physiological Research*. He receives compensation from Elsevier for his work as

Associate Editor of *Neurobiology of Disease* and from *MedLink* for his work as Associate Editor; and royalties from two books he coedited. E.P. has received speaker and/or consultancy fees from Angelini, Arvelle, Biogen, Biopas, Eisai, GW Pharma, Sanofi, SK Life Science, Takeda, UCB Pharma, Xenon Pharma, and Zogenix, and royalties from Wiley, Elsevier, and Wolters Kluwer. None of the other authors has any conflict of interest to disclose. We confirm that we have read the Journal's position on issues involved in ethical publication and affirm that this report is consistent with those guidelines.

ORCID

Nicola Specchio  <https://orcid.org/0000-0002-8120-0287>

Elaine C. Wirrell  <https://orcid.org/0000-0003-3015-8282>

Ingrid E. Scheffer  <https://orcid.org/0000-0002-2311-2174>

Rima Nabhout  <https://orcid.org/0000-0001-5877-4074>

Kate Riney  <https://orcid.org/0000-0002-1122-3555>

Pauline Samia  <https://orcid.org/0000-0002-7427-0439>

Jo M. Wilmschurst  <https://orcid.org/0000-0001-7328-1796>

Elissa Yozawitz  <https://orcid.org/0000-0001-8230-8364>

Ronit Pressler  <https://orcid.org/0000-0002-2905-6839>

Edouard Hirsch  <https://orcid.org/0000-0003-0833-8850>

Sam Wiebe  <https://orcid.org/0000-0002-1061-9099>

Helen J. Cross  <https://orcid.org/0000-0001-7345-4829>

Emilio Perucca  <https://orcid.org/0000-0001-8703-223X>

Solomon L. Moshé  <https://orcid.org/0000-0001-9427-9476>

Stéphane Auvin  <https://orcid.org/0000-0003-3874-9749>

REFERENCES

1. Riney K, Bogacz A, Somerville E, Hirsch E, Nabhout R, Scheffer I. Classification and definition of epilepsy syndromes with onset in adolescents, adults, and at a variable age: position statement by the ILAE Task Force on Nosology and Definitions. *Epilepsia*. In press.
2. Hirsch E, French J, Scheffer I, Zuberi S, Trinka E, Specchio N. Definition of the idiopathic generalized epilepsy syndromes: position paper by the ILAE Task Force on Nosology and Definitions. *Epilepsia*. In press.
3. Caraballo RH, Sologuestua A, Grañana N, Adi JN, Cersósimo RO, Mazza E, et al. Idiopathic occipital and absence epilepsies appearing in the same children. *Pediatr Neurol*. 2004;30(1):24–8.
4. Verrotti A, D'Alonzo R, Rinaldi VE, Casciato S, D'Aniello A, Di Gennaro G. Childhood absence epilepsy and benign epilepsy with centro-temporal spikes: a narrative review analysis. *World J Pediatr*. 2017;13(2):106–11.
5. Wirrell EC, Grossardt BR, Wong-Kisiel LCL, Nickels KC. Incidence and classification of new-onset epilepsy and epilepsy syndromes in children in Olmsted County, Minnesota from 1980 to 2004: a population-based study. *Epilepsy Res*. 2011;95(1–2):110–8.

6. Camfield P, Camfield C. Incidence, prevalence and aetiology of seizures and epilepsy in children. *Epileptic Disord.* 2015;17(2):117–23.
7. Wirrell E, Nabbout R, Scheffer I, Alsaadi T, Bogacz A. Methodology for classification and definition of epilepsy syndromes with list of syndromes: report of the ILAE Task Force on Nosology and Definitions. *Epilepsia*. In press.
8. Bureau M, Genton P, Dravet C, Antonio D-E, Guerrini R, Alberto TC. In: Bureau M, Genton P, Dravet C, Antonio D-E, Guerrini R, Alberto TC, et al., editors. *Epileptic syndromes of infancy, childhood and adolescence*. 6th ed. Montrouge, France: John Libbey Eurotext; 2019.
9. Wirrell EC, Grossardt BR, So EL, Nickels KC. A population-based study of long-term outcomes of cryptogenic focal epilepsy in childhood: cryptogenic epilepsy is probably not symptomatic epilepsy. *Epilepsia*. 2011;52(4):738–45.
10. Berg AT, Rychlik K, Levy SR, Testa FM. Complete remission of childhood-onset epilepsy: stability and prediction over two decades. *Brain*. 2014;137(12):3213–22.
11. Berg AT, Berkovic SF, Brodie MJ, Buchhalter J, Cross JH, van Emde Boas W, et al. Revised terminology and concepts for organization of seizures and epilepsies: report of the ILAE Commission on Classification and Terminology, 2005–2009. *Epilepsia*. 2010;51(4):676–85.
12. Lesca G, Møller RS, Rudolf G, Hirsch E, Hjalgrim H, Szepletowski P. Update on the genetics of the epilepsy-aphasia spectrum and role of GRIN2A mutations. *Epileptic Disord.* 2019;21(S1):41–7.
13. Lemke JR, Lal D, Reinthaler EM, Steiner I, Nothnagel M, Alber M, et al. Mutations in GRIN2A cause idiopathic focal epilepsy with rolandic spikes. *Nat Genet.* 2013;45(9):1067–72.
14. Lesca G, Rudolf G, Bruneau N, Lozovaya N, Labalme A, Boutry-Kryza N, et al. GRIN2A mutations in acquired epileptic aphasia and related childhood focal epilepsies and encephalopathies with speech and language dysfunction. *Nat Genet.* 2013;45(9):1061–6.
15. Carvill GL, Regan BM, Yendle SC, O’Roak BJ, Lozovaya N, Bruneau N, et al. GRIN2A mutations cause epilepsy-aphasia spectrum disorders. *Nat Genet.* 2013;45(9):1073–6.
16. Demirbilek V, Bureau M, Cokar O, Panayiotopoulos CP. Self-limited focal epilepsies in childhood. In: Bureau M, Genton P, Dravet C, Delgado-Escueta A, Guerrini R, Tassinari C, et al., editors. *Epileptic syndromes in infancy childhood and adolescence*. 6th ed. Montrouge, France: John Libbey Eurotext; 2019. p. 219–60.
17. Panayiotopoulos CP, Michael M, Sanders S, Valeta T, Koutroumanidis M. Benign childhood focal epilepsies: assessment of established and newly recognized syndromes. *Brain*. 2008;131(9):2264–86.
18. Taylor I, Berkovic SF, Kivity S, Scheffer IE. Benign occipital epilepsies of childhood: clinical features and genetics. *Brain*. 2008;131(9):2287–94.
19. Loiseau P, Beaussart M. The seizures of benign childhood epilepsy with Rolandic paroxysmal discharges. *Epilepsia*. 1973;14(4):381–9.
20. Dalla Bernardina B, Sgrò V, Caraballo R, Fontana E, Colamaria V, Zullini E, et al. Sleep and benign partial epilepsies of childhood: EEG and evoked potentials study. *Epilepsy Res Suppl.* 1991;2:83–96.
21. Pal DK, Ferrie C, Addis L, Akiyama T, Capovilla G, Caraballo R, et al. Idiopathic focal epilepsies: the “lost tribe”. *Epileptic Disord.* 2016;18(3):252–88.
22. Vears DF, Tsai M-H, Sadleir LG, Grinton BE, Lillywhite LM, Carney PW, et al. Clinical genetic studies in benign childhood epilepsy with centrotemporal spikes. *Epilepsia*. 2012;53(2):319–24.
23. Camfield CS, Camfield PR, Gordon K, Wirrell E, Dooley JM. Incidence of epilepsy in childhood and adolescence: a population-based study in Nova Scotia from 1977 to 1985. *Epilepsia*. 1996;37(1):19–23.
24. Weir E, Gibbs J, Appleton R. Panayiotopoulos syndrome and benign partial epilepsy with centro-temporal spikes: a comparative incidence study. *Seizure*. 2018;57:66–9.
25. Astradsson A, Olafsson E, Ludvigsson P, Bjorgvinsson H, Hauser WA. Rolandic Epilepsy: an incidence study in Iceland. *Epilepsia*. 1998;39(8):884–6.
26. Berg AT, Shinnar S, Levy SR, Testa FM. Newly diagnosed epilepsy in children: presentation at diagnosis. *Epilepsia*. 1999;40(4):445–52.
27. Beaussart M. Benign epilepsy of children with Rolandic (centro-temporal) paroxysmal foci. A clinical entity. Study of 221 cases. *Epilepsia*. 1972;13(6):795–811.
28. Larsson K, Eeg-Olofsson O. A population based study of epilepsy in children from a Swedish county. *Eur J Paediatr Neurol.* 2006;10(3):107–13.
29. Caraballo R, Cersósimo R, Fejerman N. Panayiotopoulos syndrome: a prospective study of 192 patients. *Epilepsia*. 2007;48(6):1054–61.
30. Overvliet GM, Aldenkamp AP, Klinkenberg S, Vles JSH, Hendriksen J. Impaired language performance as a precursor or consequence of Rolandic epilepsy? *J Neurol Sci.* 2011;304(1–2):71–4.
31. Bouma PAD, Bovenkerk AC, Westendorp RGJ, Brouwer OF. The course of benign partial epilepsy of childhood with centrotemporal spikes: a meta-analysis. *Neurology.* 1997;48(2):430–7.
32. Goldberg-Stern H, Gonen OM, Sadeh M, Kivity S, Shuper A, Inbar D. Neuropsychological aspects of benign childhood epilepsy with centrotemporal spikes. *Seizure*. 2010;19(1):12–6.
33. Filippini M, Ardu E, Stefanelli S, Boni A, Gobbi G, Benso F. Neuropsychological profile in new-onset benign epilepsy with centrotemporal spikes (BECTS): focusing on executive functions. *Epilepsy Behav.* 2016;54:71–9.
34. Deonna T. Rolandic epilepsy: neuropsychology of the active epilepsy phase. *Epileptic Disord.* 2000;2(Suppl 1):S59–61.
35. Camfield PR, Camfield CS. What happens to children with epilepsy when they become adults? Some facts and opinions. *Pediatr Neurol.* 2014;51(1):17–23.
36. Camfield P, Camfield C. Unprovoked status epilepticus: the prognosis for otherwise normal children with focal epilepsy. *Pediatrics.* 2012;130(3):e501–6.
37. Wirrell EC, Camfield PR, Gordon KE, Dooley JM, Camfield CS. Benign Rolandic epilepsy: atypical features are very common. *J Child Neurol.* 1995;10(6):455–8.
38. Hirsch LJ, Fong MWK, Leitinger M, LaRoche SM, Beniczky S, Abend NS, et al. American clinical neurophysiology society’s standardized critical care EEG terminology: 2021 version. *J Clin Neurophysiol.* 2021;38(1):1–29.

39. Panayiotopoulos CP. Elementary visual hallucinations, blindness, and headache in idiopathic occipital epilepsy: differentiation from migraine. *J Neurol Neurosurg Psychiatry*. 1999;66(4):536–40.
40. Deonna TR, Roulet Perez E, de Tiege X, Van Bogaert P. The epilepsy aphasia spectrum: from Landau-Kleffner syndrome to Rolandic epilepsy. Chichester, UK: Wiley; 2017.
41. De MP, Tassinari CA. Extreme somatosensory evoked potential (ESEP): an EEG sign forecasting the possible occurrence of seizures in children. *Epilepsia*. 1981;22(5):569–75.
42. Scheffer IE, Jones L, Pozzebon M, Howell RA, Saling MM, Berkovic SF. Autosomal dominant rolandic epilepsy and speech dyspraxia: a new syndrome with anticipation. *Ann Neurol*. 1995;38(4):633–42.
43. Capovilla G, Beccaria F, Bianchi A, Canevini MP, Giordano L, Gobbi G, et al. Ictal EEG patterns in epilepsy with centrotemporal spikes. *Brain Dev*. 2011;33(4):301–9.
44. Alving J, Fabricius M, Rosenzweig I, Beniczky S. Ictal source imaging and electroclinical correlation in self-limited epilepsy with centrotemporal spikes. *Seizure*. 2017;52:7–10.
45. Saint-Martin AD, Carcangiu R, Arzimanoglou A, Massa R, Thomas P, Motte J, et al. Semiology of typical and atypical Rolandic epilepsy: a video-EEG analysis. *Epileptic Disord*. 2001;3(4):173–82.
46. Gelisse P, Corda D, Raybaud C, Dravet C, Bureau M, Genton P. Abnormal neuroimaging in patients with benign epilepsy with centrotemporal spikes. *Epilepsia*. 2003;44(3):372–8.
47. Jabbari K, Bobbili DR, Lal D, Reinthaler EM, Schubert J, Wolking S, et al. Rare gene deletions in genetic generalized and Rolandic epilepsies. *PLoS One*. 2018;13(8):e0202022.
48. Berry-Kravis E. Epilepsy in fragile X syndrome. *Dev Med Child Neurol*. 2002;44(11):724–8.
49. Musumeci SA, Hagerman RJ, Ferri R, Bosco P, Bernardina BD, Tassinari CA, et al. Epilepsy and EEG findings in males with fragile X syndrome. *Epilepsia*. 1999;40(8):1092–9.
50. Ferrie CD, Caraballo R, Covanis A, Demirbilek V, Derwent A, Fejerman N, et al. Autonomic status epilepticus in Panayiotopoulos syndrome and other childhood and adult epilepsies: a consensus view. *Epilepsia*. 2007;48(6):1165–72.
51. Specchio N, Trivisano M, Di Ciommo V, Cappelletti S, Masciarelli G, Volkov J, et al. Panayiotopoulos syndrome: a clinical, EEG, and neuropsychological study of 93 consecutive patients. *Epilepsia*. 2010;51(10):2098–107.
52. Panayiotopoulos CP. Vomiting as an ictal manifestation of epileptic seizures and syndromes. *J Neurol Neurosurg Psychiatry*. 1988;51(11):1448–51.
53. Okanishi T, Maegaki Y, Ohno K, Togari H. Underlying neurologic disorders and recurrence rates of status epilepticus in childhood. *Brain Dev*. 2008;30(10):624–8.
54. Panayiotopoulos CP. Panayiotopoulos syndrome: a common and benign childhood epileptic syndrome. Eastleigh, England: John Libbey & Company; 2002.
55. Lada C, Skiadas K, Theodorou V, Loli N, Covanis A. A study of 43 patients with Panayiotopoulos syndrome, a common and benign childhood seizure susceptibility. *Epilepsia*. 2003;44(1):81–8.
56. Durá-Travé T, Yoldi-Petri ME, Gallinas-Victoriano F. Incidence of epilepsies and epileptic syndromes among children in Navarre, Spain: 2002 through 2005. *J Child Neurol*. 2008;23(8):878–82.
57. Ferrie C, Caraballo R, Covanis A, Demirbilek V, Derwent A, Kivity S, et al. Panayiotopoulos syndrome: a consensus view. *Dev Med Child Neurol*. 2006;48(3):236–40.
58. Specchio N, Trivisano M, Claps D, Battaglia D, Fusco L, Vigeveno F. Documentation of autonomic seizures and autonomic status epilepticus with ictal EEG in Panayiotopoulos syndrome. *Epilepsy Behav*. 2010;19(3):383–93.
59. Grosso S, Orrico A, Galli L, Di Bartolo R, Sorrentino V, Balestri P. SCN1A mutation associated with atypical Panayiotopoulos syndrome. *Neurology*. 2007;69(6):609–11.
60. Livingston JH, Cross JH, McLellan A, Birch R, Zuberi SM. A novel inherited mutation in the voltage sensor region of SCN1A is associated with Panayiotopoulos syndrome in siblings and generalized epilepsy with febrile seizures plus. *J Child Neurol*. 2009;24(4):503–8.
61. Martín del Valle F, Díaz Negrillo A, Ares Mateos G, Sanz Santaefemia FJ, Del Rosal Rabes T, González-Valcárcel Sánchez-Puelles FJ. Panayiotopoulos syndrome: probable genetic origin, but not in SCN1A. *Eur J Paediatr Neurol*. 2011;15(2):155–7.
62. Gastaut H. A new type of epilepsy: benign partial epilepsy of childhood with occipital spike-waves. *Clin Electroencephalogr*. 1982;13(1):13–22.
63. Gastaut H, Zifkin BG. Benign epilepsy of childhood with occipital spike and wave complexes. In: Andermann F, Lugaresi E, editors. *Migraine and epilepsy*. Boston, MA: Butterworths; 1987. p. 47–81.
64. Verrotti A, Laino D, Rinaldi VE, Suppiej A, Giordano L, Toldo I, et al. Clinical dissection of childhood occipital epilepsy of Gastaut and prognostic implication. *Eur J Neurol*. 2016;23(2):241–6.
65. Gastaut H, Roger J, Bureau M. Benign epilepsy of childhood with occipital paroxysms. In: Roger J, Bureau M, Dravet C, Dreifuss F, Perret A, Wolf P, editors. *Epileptic syndromes in infancy, childhood and adolescence*. 2nd ed. London, UK: John Libbey & Company; 1992. p. 201–17.
66. Caraballo RH, Cersósimo RO, Fejerman N. Childhood occipital epilepsy of Gastaut: a study of 33 patients. *Epilepsia*. 2008;49(2):288–97.
67. Caraballo R, Koutroumanidis M, Panayiotopoulos CP, Fejerman N. Idiopathic childhood occipital epilepsy of Gastaut: a review and differentiation from migraine and other epilepsies. *J Child Neurol*. 2009;24(12):1536–42.
68. Thomas P, Arzimanoglou A, Aicardi J. Benign idiopathic occipital epilepsy: report of a case of the late (Gastaut) type [corrected]. *Epileptic Disord*. 2003;5(1):57–9.
69. Ferrari-Marinho T, Macedo EF, Costa Neves RS, Costa LV, Tudesco ISS, Carvalho KC, et al. Gastaut type idiopathic childhood occipital epilepsy. *Epileptic Disord*. 2013;15(1):80–3.
70. Caraballo RH, Cersósimo RO, Fejerman N. Late-onset, “Gastaut type”, childhood occipital epilepsy: an unusual evolution. *Epileptic Disord*. 2005;7(4):341–6.
71. Wakamoto H, Nagao H, Fukuda M, Watanabe S, Motoki T, Ohmori H, et al. Idiopathic childhood occipital epilepsy of Gastaut: report of 12 patients. *Pediatr Neurol*. 2011;44(3):183–6.
72. Tsai M-L, Lo H-Y, Chaou W-T. Clinical and electroencephalographic findings in early and late onset benign childhood epilepsy with occipital paroxysms. *Brain Dev*. 2001;23(6):401–5.
73. Adcock JE, Panayiotopoulos CP. Occipital lobe seizures and epilepsies. *J Clin Neurophysiol*. 2012;29(5):397–407.

74. Guerrini R, Dravet C, Genton P, Bureau M, Bonanni P, Ferrari AR, et al. Idiopathic photosensitive occipital lobe epilepsy. *Epilepsia*. 1995;36(9):883–91.
75. Koutroumanidis M, Tsirka V, Panayiotopoulos C. Adult-onset photosensitivity: clinical significance and epilepsy syndromes including idiopathic (possibly genetic) photosensitive occipital epilepsy. *Epileptic Disord*. 2015;17(3):275–86.
76. Parmeggiani L, Guerrini R. Idiopathic photosensitive occipital lobe epilepsy. In: Panayiotopoulos CP, editor. *Atlas of epilepsies*. London, UK: Springer; 2010. p. 1077–80.
77. Ricci S, Vigeveno F, Manfredi M, Kasteleijn-Nolst Trenite DGA. Epilepsy provoked by television and video games: safety of 100-Hz screens. *Neurology*. 1998;50(3):790–3.
78. Walker MC, Smith SJM, Sisodiya SM, Shorvon SD. Case of simple partial status epilepticus in occipital lobe epilepsy misdiagnosed as migraine: clinical, electrophysiological, and magnetic resonance imaging characteristics. *Epilepsia*. 1995;36(12):1233–6.
79. Taylor I. Juvenile myoclonic epilepsy and idiopathic photosensitive occipital lobe epilepsy: is there overlap? *Brain*. 2004;127(8):1878–86.
80. Taylor I, Berkovic SF, Scheffer IE. Genetics of epilepsy syndromes in families with photosensitivity. *Neurology*. 2013;80(14):1322–9.
81. Gómez-Porro P, Serrano AA, Toledano R, García-Morales I, Gil-Nagel A. Genetic (idiopathic) generalized epilepsy with occipital semiology. *Epileptic Disord*. 2018;20(5):434–9.
82. Brinciotti M, Trasatti G, Pelliccia A, Matricardi M. Pattern-sensitive epilepsy: genetic aspects in two families. *Epilepsia*. 1992;33(1):88–92.
83. Destina Yalçın A, Kaymaz A, Forta H. Reflex occipital lobe epilepsy. *Seizure*. 2000;9(6):436–41.
84. Guerrini R, Bonanni P, Parmeggiani L, Belmonte A. Adolescent onset of idiopathic photosensitive occipital epilepsy after remission of benign rolandic epilepsy. *Epilepsia*. 1997;38(7):777–81.
85. Arsov T, Mullen SA, Rogers S, Phillips AM, Lawrence KM, Damiano JA, et al. Glucose transporter 1 deficiency in the idiopathic generalized epilepsies. *Ann Neurol*. 2012;72(5):807–15.
86. Ames FR, Saffer D. The sunflower syndrome. A new look at “self-induced” photosensitive epilepsy. *J Neurol Sci*. 1983;59(1):1–11.
87. Baumer FM, Porter BE. Clinical and electrographic features of sunflower syndrome. *Epilepsy Res*. 2018;142:58–63.
88. Wang X-L, Bao J-X, Liang-Shi, Tie-Ma, Deng Y-C, Zhao G, et al. Jeavons syndrome in China. *Epilepsy Behav*. 2014;32:64–71.
89. Giannakodimos S, Panayiotopoulos CP. Eyelid myoclonia with absences in adults: a clinical and video-EEG study. *Epilepsia*. 1996;37(1):36–44.
90. Covanis A. Eyelid myoclonia and absence. *Adv Neurol*. 2005;95:185–96.
91. Appleton RE, Panayiotopoulos CP, Acomb BA, Beirne M. Eyelid myoclonia with typical absences: an epilepsy syndrome. *J Neurol Neurosurg Psychiatry*. 1993;56(12):1312–6.
92. Smith KM, Youssef PE, Wirrell EC, Nickels KC, Payne ET, Britton JW, et al. Jeavons syndrome: clinical features and response to treatment. *Pediatr Neurol*. 2018;86:46–51.
93. Panayiotopoulos CP. Syndromes of idiopathic generalized epilepsies not recognized by the International League Against Epilepsy. *Epilepsia*. 2005;46(Suppl 9):57–66.
94. Striano S, Striano P, Nocerino C, Boccella P, Bilo L, Meo R, et al. Eyelid myoclonia with absences: an overlooked epileptic syndrome? *Neurophysiol Clin Neurophysiol*. 2002;32(5):287–96.
95. Camfield CS, Camfield PR, Sadler M, Rahey S, Farrell K, Chayasirisobon S, et al. Paroxysmal eyelid movements: a confusing feature of generalized photosensitive epilepsy. *Neurology*. 2004;63(1):40–2.
96. Belcastro V, Striano P. Self-induction seizures in sunflower epilepsy: a video-EEG report. *Epileptic Disord*. 2014;16(1):93–5.
97. Striano S, Capovilla G, Sofia V, Romeo A, Rubboli G, Striano P, et al. Eyelid myoclonia with absences (Jeavons syndrome): a well-defined idiopathic generalized epilepsy syndrome or a spectrum of photosensitive conditions? *Epilepsia*. 2009;50:15–9.
98. Singhi PD, Bansal D. Self induced photosensitive epilepsy. *Indian J Pediatr*. 2004;71(7):649–51.
99. Sadleir LG, Vears D, Regan B, Redshaw N, Bleasel A, Scheffer IE. Family studies of individuals with eyelid myoclonia with absences. *Epilepsia*. 2012;53(12):2141–8.
100. Kasteleijn-Nolst Trenité D, Rubboli G, Hirsch E, Martins da Silva A, Seri S, Wilkins A, et al. Methodology of photic stimulation revisited: updated European algorithm for visual stimulation in the EEG laboratory. *Epilepsia*. 2012;53(1):16–24.
101. Capovilla G, Striano P, Gambardella A, Beccaria F, Hirsch E, Casellato S, et al. Eyelid fluttering, typical EEG pattern, and impaired intellectual function: a homogeneous epileptic condition among the patients presenting with eyelid myoclonia. *Epilepsia*. 2009;50(6):1536–41.
102. Thomas RH, Zhang LM, Carvill GL, Archer JS, Heavin SB, Mandelstam SA, et al. CHD2 myoclonic encephalopathy is frequently associated with self-induced seizures. *Neurology*. 2015;84(9):951–8.
103. Vlaskamp DRM, Shaw BJ, Burgess R, Mei D, Montomoli M, Xie H, et al. SYNGAP1 encephalopathy. *Neurology*. 2019;92(2):e96–107.
104. Stamberger H, Hammer TB, Gardella E, Vlaskamp DRM, Bertelsen B, Mandelstam S, et al. NEXMIF encephalopathy: an X-linked disorder with male and female phenotypic patterns. *Genet Med*. 2021;23(2):363–73.
105. Bureau M, Tassinari CA. Epilepsy with myoclonic absences. *Brain Dev*. 2005;27(3):178–84.
106. Genton P, Bureau M. Epilepsy with myoclonic absences. *CNS Drugs*. 2006;20(11):911–6.
107. Zanzmera P, Menon RN, Karkare K, Soni H, Jagtap S, Radhakrishnan A. Epilepsy with myoclonic absences: electroclinical characteristics in a distinctive pediatric epilepsy phenotype. *Epilepsy Behav*. 2016;64:242–7.
108. Myers KA, Scheffer IE. Myoclonic absence seizures with complex gestural automatisms. *Eur J Paediatr Neurol*. 2018;22(3):532–5.
109. Elia M, Guerrini R, Musumeci SA, Bonanni P, Gambardella A, Aguglia U. Myoclonic absence-like seizures and chromosome abnormality syndromes. *Epilepsia*. 1998;39(6):660–3.
110. Myers KA, Scheffer IE. Myoclonic absence seizures in Dravet syndrome. *Pediatr Neurol*. 2017;70:67–9.
111. Bahi-Buisson N, El Sabbagh S, Soufflet C, Escande F, Boddart N, Valayannopoulos V, et al. Myoclonic absence epilepsy with photosensitivity and a gain of function mutation in glutamate dehydrogenase. *Seizure*. 2008;17(7):658–64.
112. Scheffer IE, Berkovic S, Capovilla G, Connolly MB, French J, Guilhoto L, et al. ILAE classification of the epilepsies:

- position paper of the ILAE Commission for Classification and Terminology. *Epilepsia*. 2017;58(4):512–21.
113. Specchio N, Curatolo P. Developmental and epileptic encephalopathies: what we do and do not know. *Brain*. 2021;144(1):32–43.
 114. Doose H. Myoclonic-astatic epilepsy. *Epilepsy Res Suppl*. 1992;6:163–8.
 115. Kelley SA, Kossoff EH. Doose syndrome (myoclonic-astatic epilepsy): 40 years of progress. *Dev Med Child Neurol*. 2010;52(11):988–93.
 116. Tang S, Pal DK. Dissecting the genetic basis of myoclonic-astatic epilepsy. *Epilepsia*. 2012;53(8):1303–13.
 117. Doose H, Gerken H, Leonhardt R, Völzke E, Völz C. Centrencephalic myoclonic-astatic petit mal 1—clinical and genetic investigations. *Neuropediatrics*. 1970;2(1):59–78.
 118. Neubauer BA, Hahn A, Doose H, Tuxhorn I. Myoclonic-astatic epilepsy of early childhood—definition, course, nosography, and genetics. *Adv Neurol*. 2005;95:147–55.
 119. Kilaru S, Bergqvist AGC. Current treatment of myoclonic astatic epilepsy: clinical experience at the Children's Hospital of Philadelphia. *Epilepsia*. 2007;48(9):1703–7.
 120. Kaminska A, Ickowicz A, Plouin P, Bru M, Dellatolas G, Dulac O. Delineation of cryptogenic Lennox-Gastaut syndrome and myoclonic astatic epilepsy using multiple correspondence analysis. *Epilepsy Res*. 1999;36(1):15–29.
 121. Joshi C, Nickels K, Demarest S, Eltze C, Cross JH, Wirrell E. Results of an international Delphi consensus in epilepsy with myoclonic atonic seizures/Doose syndrome. *Seizure*. 2021;85:12–8.
 122. Oguni H, Tanaka T, Hayashi K, Funatsuka M, Sakauchi M, Shirakawa S, et al. Treatment and long-term prognosis of myoclonic-astatic epilepsy of early childhood. *Neuropediatrics*. 2002;33(3):122–32.
 123. Trivisano M, Specchio N, Cappelletti S, Di Ciommo V, Claps D, Specchio LM, et al. Myoclonic astatic epilepsy: an age-dependent epileptic syndrome with favorable seizure outcome but variable cognitive evolution. *Epilepsy Res*. 2011;97(1–2):133–41.
 124. Caraballo RH, Chamorro N, Darra F, Fortini S, Arroyo H. Epilepsy with myoclonic atonic seizures: an electroclinical study of 69 patients. *Pediatr Neurol*. 2013;48(5):355–62.
 125. Eschbach K, Moss A, Joshi C, Angione K, Smith G, Dempsey A, et al. Diagnosis switching and outcomes in a cohort of patients with potential epilepsy with myoclonic-astatic seizures. *Epilepsy Res*. 2018;147:95–101.
 126. Oguni H, Hayashi K, Imai K, Funatsuka M, Sakauchi M, Shirakawa S, et al. Idiopathic myoclonic-astatic epilepsy of early childhood—nosology based on electrophysiologic and long-term follow-up study of patients. *Adv Neurol*. 2005;95:157–74.
 127. Nabbout R. Absence of mutations in major GEFs+ genes in myoclonic astatic epilepsy. *Epilepsy Res*. 2003;56(2–3):127–33.
 128. Scheffer I. Generalized epilepsy with febrile seizures plus. A genetic disorder with heterogeneous clinical phenotypes. *Brain*. 1997;120(3):479–90.
 129. Singh R, Scheffer IE, Crossland K, Berkovic SF. Generalized epilepsy with febrile seizures plus: a common childhood-onset genetic epilepsy syndrome. *Ann Neurol*. 1999;45(1):75–81.
 130. Wallace RH, Scheffer IE, Barnett S, Richards M, Dibbens L, Desai RR, et al. Neuronal sodium-channel α 1-subunit mutations in generalized epilepsy with febrile seizures plus. *Am J Hum Genet*. 2001;68(4):859–65.
 131. Wallace RH, Wang DW, Singh R, Scheffer IE, George AL, Phillips HA, et al. Febrile seizures and generalized epilepsy associated with a mutation in the Na⁺-channel β 1 subunit gene SCN1B. *Nat Genet*. 1998;19(4):366–70.
 132. Wolff M, Johannesen KM, Hedrich UBS, Masnada S, Rubboli G, Gardella E, et al. Genetic and phenotypic heterogeneity suggest therapeutic implications in SCN2A-related disorders. *Brain*. 2017;140(5):1316–36.
 133. Schubert J, Siekierska A, Langlois M, May P, Huneau C, Becker F, et al. Mutations in STX1B, encoding a presynaptic protein, cause fever-associated epilepsy syndromes. *Nat Genet*. 2014;46(12):1327–32.
 134. Carvill G, McMahon J, Schneider A, Zemel M, Myers C, Saykally J, et al. Mutations in the GABA transporter SLC6A1 cause epilepsy with myoclonic-astatic seizures. *Am J Hum Genet*. 2015;96(5):808–15.
 135. Routier L, Verny F, Barcia G, Chemaly N, Desguerre I, Colleaux L, et al. Exome sequencing findings in 27 patients with myoclonic-astatic epilepsy: is there a major genetic factor? *Clin Genet*. 2019;96(3):254–60.
 136. Warren AEL, Harvey AS, Vogrin SJ, Bailey C, Davidson A, Jackson GD, et al. The epileptic network of Lennox-Gastaut syndrome. *Neurology*. 2019;93(3):e215–26.
 137. Genton P, Guerrini R, Dravet C. The Lennox-Gastaut syndrome. In: Meinardi H, editor. *Handbook of clinical neurology: the epilepsies*. Amsterdam, the Netherlands: Elsevier; 2000. p. 211–22.
 138. Berg AT, Levy SR, Testa FM. Evolution and course of early life developmental encephalopathic epilepsies: focus on Lennox-Gastaut syndrome. *Epilepsia*. 2018;59(11):2096–105.
 139. Goldsmith IL, Zupanc ML, Buchhalter JR. Long-term seizure outcome in 74 patients with Lennox-Gastaut syndrome: effects of incorporating MRI head imaging in defining the cryptogenic subgroup. *Epilepsia*. 2000;41(4):395–9.
 140. Vignoli A, Oggioni G, De Maria G, Peron A, Savini MN, Zambrelli E, et al. Lennox-Gastaut syndrome in adulthood: long-term clinical follow-up of 38 patients and analysis of their recorded seizures. *Epilepsy Behav*. 2017;77:73–8.
 141. Kerr M, Kluger G, Philip S. Evolution and management of Lennox-Gastaut syndrome through adolescence and into adulthood: are seizures always the primary issue? *Epileptic Disord*. 2011;13(S1):15–26.
 142. Kim HJ, Kim HD, Lee JS, Heo K, Kim D-S, Kang H-C. Long-term prognosis of patients with Lennox-Gastaut syndrome in recent decades. *Epilepsy Res*. 2015;110:10–9.
 143. Ferlazzo E, Nikaronova M, Italiano D, Bureau M, Dravet C, Calarese T, et al. Lennox-Gastaut syndrome in adulthood: clinical and EEG features. *Epilepsy Res*. 2010;89(2–3):271–7.
 144. Ohtsuka Y, Amano R, Mizukawa M, Ohtahara S. Long-term prognosis of the Lennox-Gastaut syndrome. *Psychiatry Clin Neurosci*. 1990;44(2):257–64.
 145. Hughes JR, Patil VK. Long term electro-clinical changes in the Lennox-Gastaut syndrome before, during, and after the slow spike-wave pattern. *Clin Electroencephalogr*. 2002;33(1):1–7.
 146. Lee YJ, Kang H-C, Lee JS, Kim SH, Kim D-S, Shim K-W, et al. Resective pediatric epilepsy surgery in Lennox-Gastaut syndrome. *Pediatrics*. 2010;125(1):e58–66.
 147. Pillay N, Archer JS, Badawy RAB, Flanagan DF, Berkovic SF, Jackson G. Networks underlying paroxysmal fast activity and slow spike and wave in Lennox-Gastaut syndrome. *Neurology*. 2013;81(7):665–73.

148. Epi4K Consortium, Epilepsy Phenome/Genome Project, Allen AS, Berkovic SF, Cossette P, Delanty N, et al. De novo mutations in epileptic encephalopathies. *Nature*. 2013;501(7466):217–21.
149. Asadi-Pooya AA. Lennox-Gastaut syndrome: a comprehensive review. *Neurol Sci*. 2018;39(3):403–14.
150. Fernández IS, Chapman KE, Peters JM, Kothare SV, Nordli DR, Jensen FE, et al. The Tower of Babel: survey on concepts and terminology in electrical status epilepticus in sleep and continuous spikes and waves during sleep in North America. *Epilepsia*. 2013;54(4):741–50.
151. Eksioglu Y, Tas E, Takeoka M, Sarco D, Rotemberg A. Clinical presentation and acute treatment of electrical status epilepticus in sleep and sleep potentiated spikes. Philadelphia, PA: Medical Publishing Practice; 2009. p. A434.
152. Morikawa T, Seino M, Watanabe Y, Watanabe M, Yagi K. Clinical relevance of continuous spike-waves during slow wave sleep. In: Manelis S, Bental E, Loeber J, Dreifuss F, editors. *Advances in epileptology*. New York, NY: Raven Press; 1989. p. 359–63.
153. Singhal NS, Sullivan JE. Continuous spike-wave during slow wave sleep and related conditions. *ISRN Neurol*. 2014;2014:1–6.
154. Kersbergen KJ, de Vries LS, Leijten FSS, Braun KPJ, Nievelstein RAJ, Groenendaal F, et al. Neonatal thalamic hemorrhage is strongly associated with electrical status epilepticus in slow wave sleep. *Epilepsia*. 2013;54(4):733–40.
155. Neville BGR, Boyd SG. Selective epileptic gait disorder. *J Neurol Neurosurg Psychiatry*. 1995;58(3):371–3.
156. van den Munckhof B, Arzimanoglou A, Perucca E, van Teeseling HC, Leijten FSS, Braun KPJ, et al. Corticosteroids versus clobazam in epileptic encephalopathy with ESES: a European multicentre randomised controlled clinical trial (RESCUE ESES*). *Trials*. 2020;21(1):957.
157. Caraballo R, Pavlidis E, Nikanorova M, Loddenkemper T. Encephalopathy with continuous spike-waves during slow-wave sleep: evolution and prognosis. *Epileptic Disord*. 2019;21(S1):15–21.
158. Gardella E, Cantalupo G, Larsson PG, Fontana E, Bernardina BD, Rubboli G, et al. EEG features in encephalopathy related to status epilepticus during slow sleep. *Epileptic Disord*. 2019;21(S1):22–30.
159. Loddenkemper T, Fernández IS, Peters JM. Continuous spike and waves during sleep and electrical status epilepticus in sleep. *J Clin Neurophysiol*. 2011;28(2):154–64.
160. Tassinari CA, Cantalupo G, Rios-Pohl L, Della GE, Rubboli G. Encephalopathy with status epilepticus during slow sleep: “the Penelope syndrome”. *Epilepsia*. 2009;50:4–8.
161. Perez ER, Davidoff V, Desplard P-A, Deonna T. Mental and behavioural deterioration of children with epilepsy and CSWS: acquired epileptic frontal syndrome. *Dev Med Child Neurol*. 2008;35(8):661–74.
162. Tassinari CA, Rubboli G. Cognition and paroxysmal EEG activities: from a single spike to electrical status epilepticus during sleep. *Epilepsia*. 2006;47(Suppl 2):40–3.
163. Van Bogaert P. Epileptic encephalopathy with continuous spike-waves during slow-wave sleep including Landau-Kleffner syndrome. *Handb Clin Neurol*. 2013;111:635–40.
164. Tsai M-H, Vears DF, Turner SJ, Smith RL, Berkovic SF, Sadleir LG, et al. Clinical genetic study of the epilepsy-aphasia spectrum. *Epilepsia*. 2013;54(2):280–7.
165. Turner SJ, Mayes AK, Verhoeven A, Mandelstam SA, Morgan AT, Scheffer IE. GRIN2A: an aptly named gene for speech dysfunction. *Neurology*. 2015;84(6):586–93.
166. Hirsch LJ, Gaspard N, van Baalen A, Nabbout R, Demeret S, Loddenkemper T, et al. Proposed consensus definitions for new-onset refractory status epilepticus (NORSE), febrile infection-related epilepsy syndrome (FIRES), and related conditions. *Epilepsia*. 2018;59(4):739–44.
167. Van Baalen A, Häusler M, Boor R, Rohr A, Sperner J, Kurlemann G, et al. Febrile infection-related epilepsy syndrome (FIRES): a nonencephalitic encephalopathy in childhood. *Epilepsia*. 2010;51(7):1323–8.
168. Payne ET, Koh S, Wirrell EC. Extinguishing febrile infection-related epilepsy syndrome: pipe dream or reality? *Semin Neurol*. 2020;40(2):263–72.
169. Specchio N, Pietrafusa N. New-onset refractory status epilepticus and febrile infection-related epilepsy syndrome. *Dev Med Child Neurol*. 2020;62(8):897–905.
170. van Baalen A, Häusler M, Plecko-Startinig B, Strautmanis J, Vlaho S, Gebhardt B, et al. Febrile infection-related epilepsy syndrome without detectable autoantibodies and response to immunotherapy: a case series and discussion of epileptogenesis in FIRES. *Neuropediatrics*. 2012;43(4):209–16.
171. Kramer U, Chi C-S, Lin K-L, Specchio N, Sahin M, Olson H, et al. Febrile infection-related epilepsy syndrome (FIRES): pathogenesis, treatment, and outcome. *Epilepsia*. 2011;52(11):1956–65.
172. Farias-Moeller R, Bartolini L, Staso K, Schreiber JM, Carpenter JL. Early ictal and interictal patterns in FIRES: the sparks before the blaze. *Epilepsia*. 2017;58(8):1340–8.
173. Lee H-F, Chi C-S. Febrile infection-related epilepsy syndrome (FIRES): therapeutic complications, long-term neurological and neuroimaging follow-up. *Seizure*. 2018;56:53–9.
174. Sakuma H, Tanuma N, Kuki I, Takahashi Y, Shiomi M, Hayashi M. Intrathecal overproduction of proinflammatory cytokines and chemokines in febrile infection-related refractory status epilepticus. *J Neurol Neurosurg Psychiatry*. 2015;86(7):820–2.
175. Clarkson BDS, LaFrance-Corey RG, Kahoud RJ, Farias-Moeller R, Payne ET, Howe CL. Functional deficiency in endogenous interleukin-1 receptor antagonist in patients with febrile infection-related epilepsy syndrome. *Ann Neurol*. 2019;85(4):526–37.
176. Kothur K, Bandodkar S, Wienholt L, Chu S, Pope A, Gill D, et al. Etiology is the key determinant of neuroinflammation in epilepsy: elevation of cerebrospinal fluid cytokines and chemokines in febrile infection-related epilepsy syndrome and febrile status epilepticus. *Epilepsia*. 2019;60(8):1678–88.
177. Gastaut H, Poirier F, Payan H, Salamon G, Toga M, Vigouroux MHHE. Syndrome hémiconvulsions, hémiplegia, epilepsy. *Epilepsia*. 1959;1(1–5):418–47.
178. Auvin S, Bellavoine V, Merdarius D, Delanoë C, Elmaleh-Bergés M, Gressens P, et al. Hemiconvulsion–hemiplegia–epilepsy syndrome: current understandings. *Eur J Paediatr Neurol*. 2012;16(5):413–21.
179. Albakaye M, Belaïdi H, Lahjouji F, Errguig L, Kuate C, Maiga Y, et al. Clinical aspects, neuroimaging, and electroencephalography of 35 cases of hemiconvulsion-hemiplegia syndrome. *Epilepsy Behav*. 2018;80:184–90.
180. Aicardi J, Amsili J, Chevrie JJ. Acute hemiplegia in infancy and childhood. *Dev Med Child Neurol*. 2008;11(2):162–73.

181. van Toorn R, Janse van Rensburg P, Solomons R, Ndondo AP, Schoeman JF. Hemiconvulsion-hemiplegia-epilepsy syndrome in South African children: insights from a retrospective case series. *Eur J Paediatr Neurol*. 2012;16(2):142–8.
182. Kim DW, Kim KK, Chu K, Chung CK, Lee SK. Surgical treatment of delayed epilepsy in hemiconvulsion-hemiplegia-epilepsy syndrome. *Neurology*. 2008;70(22 Part 2):2116–22.
183. Toldo I, Calderone M, Boniver C, Dravet C, Guerrini R, Laverda AM. Hemiconvulsion–hemiplegia–epilepsy syndrome: early magnetic resonance imaging findings and neuroradiological follow-up. *Brain Dev*. 2007;29(2):109–11.
184. Kim DW, Lim BC, Kim KJ, Chae JH, Lee R, Lee SK. Low incidence of SCN1A genetic mutation in patients with hemiconvulsion–hemiplegia–epilepsy syndrome. *Epilepsy Res*. 2013;106(3):440–5.

SUPPORTING INFORMATION

Additional supporting information may be found in the online version of the article at the publisher's website.

How to cite this article: Specchio N, Wirrell EC, Scheffer IE, Nabbout R, Riney K, Samia P, et al. International League Against Epilepsy classification and definition of epilepsy syndromes with onset in childhood: Position paper by the ILAE Task Force on Nosology and Definitions. *Epilepsia*. 2022;00:1–45. <https://doi.org/10.1111/epi.17241>