Manuscript Click here to view linked References

Advances and Controversies in Frontotemporal Dementia: Characterization, Diagnosis, Biomarkers, and Therapeutic Considerations

Bradley F. Boeve, MD[1]
Adam L. Boxer, MD, PhD[2]
Fiona Kumfor, PhD[3]
Yolande Pijnenburg, MD, PhD[4]
Jonathan D. Rohrer, FRCP, PhD[5]

[1]Department of Neurology, Mayo Clinic, Rochester, Minnesota, USA
[2]Department of Neurology, University of California San Francisco, San Francisco, California, USA
[3]School of Psychology and Brain & Mind Centre, University of Sydney, Sydney, New South Wales, Australia
[4]Alzheimer Center Amsterdam, Department of Neurology, Amsterdam Neuroscience, Vrije Universiteit Amsterdam, Amsterdam UMC, Amsterdam, The Netherlands
[5]Dementia Research Centre, University College London Queen Square Institute of Neurology, London, UK

Running head: THELANCETNEUROLOGY-D-21-00318R1

Keywords: Frontotemporal dementia, frontotemporal lobar degeneration, genetics, tau, TDP-43, therapeutics

Title: 12 words (115 characters)
Abstract: 123 words
Word count: 4848
References: 89
Tables: 1
Figures: 3
Panels: 2
Appendices: 2

Correspondence to:
Bradley F. Boeve, M.D.
Mayo Clinic
Department of Neurology
200 First Street SW
Rochester, MN 55905
Phone: 507-538-1038
Fax: 507-538-6012
Email: bboeve@mayo.edu

Abstract

Frontotemporal dementia (FTD) is an umbrella term that encompasses a group of clinical syndromes due to an underlying neurodegenerative disease characterized by progressive changes in behavior, executive function or language. The group of neurodegenerative diseases that manifest clinically as FTD are known as the frontotemporal lobar degeneration (FTLD) spectrum pathologies, and these disorders are related to proteinopathies that are associated with frontotemporal neural network dysfunction. Recent advances in the clinical, biofluid, genetic, imaging, and molecular characterization have provided many new insights into FTD/FTLD. Several large natural history cohort studies are also now in progress. This update reviews these advances as well as some controversies, and covers current and anticipated interventions that target problematic clinical features and the molecular underpinnings designed to optimize management.

Disclosures

Dr. Boeve has no relevant disclosures for this paper. He has served as an investigator for clinical trials sponsored by Alector, Biogen, and EIP Pharma. He serves on the Scientific Advisory Board for the Tau Consortium. He receives funding from the NIH, the Mangurian Foundation, and the Little Family Foundation.

Dr. Boxer receives research support from the NIH, the Rainwater Charitable Foundation, the Association for Frontotemporal Degeneration, Bluefield Project to Cure Frontotemporal Dementia, the Alzheimer's Drug Discovery Foundation and the Alzheimer's Association. He has served as a consultant for Alector, AGTC, Arkuda, Arvinas, AZTherapies, GSK, Oligomerix, Ono, Regeneron, Roche, Samumed, Stealth, Third Rock, Transposon and Wave, and received research support from Biogen, Eisai and Regeneron.

Dr. Kumfor has no relevant disclosures for this paper. She receives funding from the National Health and Medical Research Council.

Dr. Pijnenburg has no relevant disclosures for this paper. She receives funding from the Dioraphte Foundation, Health Holland, and ZonMW.

Dr. Rohrer has no relevant disclosures for this paper. He has served on the Medical Advisory Board for Alector, Wave Life Sciences, Arkuda Therapeutics and Prevail Therapeutics. He receives funding from the UK Medical Research Council, National Institute for Health Research, Association for Frontotemporal Degeneration, Alzheimer's Association and the Bluefield Project.

Search strategy and selection criteria

We searched PubMed for articles published from Jan 01, 2016, to June 1, 2021, in English journals, using the search terms “frontotemporal dementia”, “frontotemporal lobar degeneration”, “FTD”, “FTLD”, “tau protein”, “TDP-43”, and “tauopathy”. Additional articles were included from reference lists, review articles, and the authors' own files. The final reference list was generated on the basis of originality and relevance to the topics covered in this Review.

Introduction

Frontotemporal dementia (FTD) is an umbrella term that encompasses a group of clinical syndromes due to an underlying neurodegenerative disease characterized by progressive changes in behavior, executive function or language.[1] These syndromes include the behavioral variant of frontotemporal dementia (bvFTD) and the nonfluent and semantic variants of primary progressive aphasia (nfvPPA and svPPA), each of which can also be accompanied by amyotrophic lateral sclerosis (ALS). The clinical characteristics and cognitive profiles of the FTD subtypes are presented in **Panel 1**.

Frontotemporal lobar degeneration (FTLD) is the overarching pathological term for a group of neurodegenerative disorders that involve one or more proteinopathies and are typically associated with progressive degeneration particularly in the frontotemporal neural networks. In any given individual, the FTD syndrome is typically (but not always) due to an underlying FTLD spectrum disease. The histopathologically-defined disorders of corticobasal degeneration (CBD) and progressive supranuclear palsy (PSP) are generally considered under the FTLD term, whereas the clinical phenotypes of corticobasal syndrome (CBS) and progressive supranuclear palsy/Richardson's syndrome (PSP-RS) represent the clinical syndromes that are usually (but not always) a reflection of an underlying FTLD spectrum pathology. This review will use the term FTD when focusing on the clinical syndromes of bvFTD, nfvPPA and svPPA (+/- ALS), and use the term FTLD when referring to the neurodegenerative pathologies that manifest as FTD.[2]

Recent research in the clinical, biofluid, genetic, imaging, and molecular characterization of FTD/FTLD has provided many new insights as well as generated some degree of controversy. Several large natural history cohort studies are also now in progress. This update reviews these advances and controversies. Many nonpharmacologic and

particularly pharmacologic interventions have been tested over recent years, and many trials are in progress or planned. This review will also cover current and anticipated interventions designed to optimize management.

Clinical Presentation and Characterization of FTD

Differentiating FTD vs non-FTD disorders

The clinical diagnosis of bvFTD is based on current consensus diagnostic criteria that have been derived from an international cohort of 406 pathologically verified FTD cases.[3] Based on these criteria, a degree of probability of underlying FTLD can be attributed to cases presenting with at least three out of five behavioural and one cognitive criterion (See also **Panel 1**). The main clinical differential diagnosis of bvFTD consists of Alzheimer's disease (AD), primary psychiatric disease, vascular dementia, and dementia with Lewy bodies (DLB), with the differentiation of bvFTD from AD and psychiatric disease being most challenging. In general, episodic memory impairment is more prominent in AD than bvFTD, although a dysexecutive/behavioural AD variant is recognized.[4] With the current state-of the-art biomarkers of underlying amyloid pathology, bvFTD can be reliably differentiated from AD, although it can never be fully excluded that a subject with bvFTD has AD co-pathology. Notably, increased CSF tau levels and medial temporal lobe atrophy on MRI are often considered AD biomarkers, but these findings are not specific for AD as these can be seen in a proportion of FTD cases as well.[5,6]

Neuropsychiatric presentations have been seen in a number of FTD syndromes, and these are reported more commonly in people with chromosome 9 open reading frame 72 (*C9orf72*) expansions.[7] The *C9orf72* expansion is the most common genetic cause of FTD and/or ALS.[8] Here there can be the added difficulty of an insidious onset and very slowly

progress of symptoms. Like other slowly progressive degenerative FTD syndromes, this can be difficult to diagnose initially as it has a similar presentation to the so-called "FTD phenocopy syndrome," which in the majority of cases is non-neurodegenerative.[9] The FTD phenocopy syndrome also highlights that there can be mimics of bvFTD, and that caution is always needed in making the diagnosis on a purely symptomatic basis, particularly in the absence of evidence of neurodegeneration on biomarker studies. Therefore, longer term clinical and neuroimaging follow-up is warranted in any individual with bvFTD features who does not fulfill established criteria for probable bvFTD[3] and/or supportive biomarker evidence of a neurodegenerative process is lacking.

An international group of neurologists and psychiatrists, The Neuropsychiatric International Consortium for FTD, has recently established recommendations for the distinction between bvFTD and primary psychiatric disorders.[10,11]

Structural brain imaging is essential to exclude mass lesions in the frontal or temporal lobes, hydrocephalus, etc. One mimic that has been described and is important to consider is an FTD-like clinical presentation associated with intracranial hypotension, termed by some as frontotemporal brain sagging syndrome,[12] which in contrast to FTD can be reversible.

Atypical presentations of FTD

Although the canonical FTD clinical syndromes are well-described, it has become clear in recent years that, firstly, there can be a number of atypical presentations of these syndromes, and secondly, genetic forms of FTD can present with the clinical features of other neurodegenerative disorders. It is common to assess people who turn out to have FTD, but initially have a 'halo' presentation with atypical clinical features (**Figure 1**). Two key syndromes are often seen: firstly, those with a neuropsychiatric presentation (e.g. with

prominent features of psychosis as described above);[7] and secondly, prominent amnestic symptoms, with only mild behavioural change that becomes prominent later on.[13] One important amnestic group to recognize are those with specific mutations in the microtubule associated protein tau (*MAPT*) gene including V337M, Q351R and R406W who may look very much like Alzheimer's disease dementia initially, although often then have a slowly progressive degenerative disorder with later prominent behavioural symptoms +/- parkinsonism.[13] This group also has similar tau pathology as seen in AD (although without the amyloid) and so can have strongly positive tau PET imaging.[14]

Although separate core and supportive clinical criteria have been defined for each of the PPA variants,[15] on a clinical basis it can still be challenging to differentiate them among themselves, and from psychiatric presentations or stroke syndromes. Moreover, the presentation of these variants is not always 'pure' as described in the clinical criteria. In particular, mixed phenotypes or expanded clinical phenotypes occur in cases with underlying Alzheimer's disease.[16] In these instances, linguistic examination and determination of Alzheimer's disease biomarkers might be useful.

Differential diagnosis of nfvPPA from the logopenic variant of PPA (lvPPA) relies largely on expert qualitative assessment of spontaneous speech, but classification of speech errors such as apraxia and phonological errors are notoriously difficult. Features which are quantifiable such as reading prosody,[17] as well as non-speech features such as working memory and visuospatial function[18] are therefore useful when classifying these patients.

One of the more controversial aspects of the PPA spectrum is the overlap and distinction between people with a primary progressive apraxia of speech (PPAOS, i.e. a motor speech disorder with no language problems)[19] and those with nfvPPA. Whilst many people develop features of both aphasia and apraxia of speech as the disease develops, there do seem

to be a small number of people who remain with either PPAOS without language impairment, or nfvPPA (usually with agrammatism predominantly) without motor speech problems, as the disease progresses.[20] Nonetheless, these may still be part of the same pathological spectrum, with many cases of both PPAOS or mixed PPAOS/nfvPPA having tau pathology such as PSP, CBD or Pick's disease at postmortem (and many developing additional parkinsonian disorders as the disease progresses).[21] Whether nfvPPA without apraxia of speech is separate pathologically remains to be understood.[22,23] Important to note is that there are a group of people who present with features of multiple FTD phenotypes at the same time with both bvFTD and a progressive aphasia at onset.[24]

Lastly, whilst people with FTD-causing mutations usually have a disorder within the FTD spectrum, there are a group of people that have genetic FTD with another phenotype.[13] For example, *C9orf72* expansions have been described with a Huntington's disease-like hyperkinetic disorder.[25]

Characterizing the left vs right temporal predominant variants of FTD

The term primary progressive aphasia emphasizes the predominant language presentation in the first few years of the disorder. The atrophy pattern in svPPA consists of bilateral anterior temporal lobe atrophy, which is usually more prominent on the left. A mirror radiological variant with predominant right anterior temporal atrophy can present without aphasia, which has been termed the right temporal variant of FTD (rtvFTD; **Panel 1, Figure 2,**).[26,27] Its main clinical features are prosopagnosia, episodic memory impairment, and behavioural change.[26] Consensus criteria and nosology for this variant of FTD are still being refined.

The FTLD Proteinopathies

The primary proteinopathies associated with the FTLD-spectrum disorders include tau (often termed the "tauopathies"), TAR DNA binding protein 43 (TDP-43) proteinopathies, and the FET related proteins (**Appendix 1**).[28] It is worth emphasizing that while clinicians typically attempt to predict the single most likely proteinopathy that most likely underlies any particular patient's dementia syndrome, a significant minority of patients have two or more proteinopathies identified at autopsy.[29]

Limbic-predominant age-related TDP-43 encephalopathy (LATE) is a recently-characterized entity, in which stereotypical TDP-43 protein inclusions are present with or without coexisting hippocampal sclerosis; these histologic findings represent LATE neuropathologic change (LATE-NC).[30] The typical clinical presentation of LATE is an amnestic dementia syndrome, and the prevalence appears to increase with increasing age. Whether LATE is a distinct disease entity separate from FTLD with TDP-43 pathology is controversial; see Josephs *et al*. for more details on key controversies.[31]

Accurate and Early Diagnosis

Prodromal FTLD

While the presence of an overt FTLD-spectrum disorder phenotype can be defined based on established criteria, there are no such criteria for the prodromal FTLD-spectrum disorders except for PSP.[32] One would predict that the prodromal features of the major FTLD syndromes would be subtle/mild changes in one or more of the core features of each syndrome. For bvFTD, mild changes in behavior, personality, or comportment without major changes in social/occupational functioning would be expected. Similarly, a change in speech/language functioning would be expected in those with evolving PPA. However, as

described above, there are individuals with evolving FTD who present with atypical cognitive or behavioral manifestations such as anterograde memory impairment, or changes in complex visual processing (i.e., visual agnosia), or psychosis. Others exhibit changes in motor functioning such as parkinsonism or limb apraxia or monomelic motor neuron disease findings without any cognitive or behavioral changes.[33]

One framework that can be applied to FTLD-spectrum disorders expands the concept of mild cognitive impairment (MCI) to include the concepts/terms of mild behavioral impairment (MBI) and mild motor impairment (MMI) (**Figure 3**). Each term is intended to represent the intermediate clinical stage between normal aging and an overt neurodegenerative phenotype. Each designation requires that clinical manifestations represent a change from a premorbid state and prior level of functioning.

Characterizing prodromal FTLD is complicated by the clinical variability inherent in the FTLD-spectrum disorders, with cognitive, behavioral and motor manifestations that are heterogenous within and across individuals. Furthermore, considering that clinical diagnosis is often delayed in sporadic FTD syndromes, the most practical approaches to characterize prodromal FTLD would be 1) to evaluate asymptomatic and minimally symptomatic mutation carriers among familial FTD kindreds in a longitudinal and comprehensive manner (see natural history cohorts below), and 2) identify and analyze sporadic cases which were recognized very early in their clinical course and evaluated prospectively in a similar manner as described above.

The conceptual framework presented herein is one perspective on characterizing prodromal FTLD, and more discussion will likely be required to develop consensus on the finer details of the core features under each domain and precise terminology.

Novel clinical and neuropsychological measures

The typical cognitive/neuropsychological profiles for key FTD syndromes are outlined in **Panel 1**.

Behavioral variant FTD. With respect to the neuropsychological profile, the bvFTD diagnostic criteria emphasise executive dysfunction with relative sparing of episodic memory and visuospatial ability, and this profile has been supported by more recent cross-sectional and longitudinal analyses.[2,34-36] For executive function, growing evidence indicates that tests which tap ventromedial prefrontal cortex function, such as error sensitivity,[37] verbal fluency,[37] inhibition,[38] as well as decision-making and neuroeconomics derived tasks[39] are more sensitive than dorsolateral prefrontal tasks such as cognitive control and attention.[37] Episodic memory performance is variable. A recent meta-analysis reported large memory deficits in bvFTD compared to controls, albeit to a lesser extent than seen in AD.[40] Memory also declines with disease progression[41]. Measures of learning and recall[40] as well as spatial memory[42] may be better at differentiating between bvFTD and AD. With respect to visuospatial ability, drawing and spatial orientation,[43] and may be useful in discriminating between these diagnoses. Some studies have also highlighted praxis as potentially useful.[44] Given the distinct cognitive profile of bvFTD, neuropsychological assessment therefore plays an important role in diagnosis.

Assessment of the behavioural features of bvFTD (i.e., apathy, disinhibition, stereotypical behaviours and changes in eating behaviour) has largely been based on clinical interview, and while recent analyses support this approach is data collection,[2] it can be influenced by the availability and knowledge of an informant and patient insight. Therefore, the development of reliable, valid and objective measures is needed to complement the clinical interview; many of these measures assess social cognition (**Appendix 2**).

Primary progressive aphasia. Differential diagnosis of the PPA variants is important to provide potential insight into underlying pathology, as well as the nature and likely progression of deficits. A number of neuropsychological tests have been developed which are tailored for PPA (See Henry & Grasso, 2018 [45] for recent comprehensive review). In addition to purposely designed aphasia batteries (e.g., Sydney Language Battery; Progressive Aphasia Severity Scale), tests which assess non-verbal semantic knowledge (e.g., Repeat and Point Test), word repetition and picture naming are useful. Irregular word reading, word-picture matching and tests of semantic association are more impaired in svPPA than nfvPPA.[36] Conversely, sentence reading, sentence ordering and aspects of dictation are more impaired in nfvPPA.[46] Efforts to objectively assess syntax and grammar (e.g., Test for Reception of Grammar, Northwestern Anagram Test) can be useful in detecting nfvPPA, but patients with lvPPA may also be impaired due to working memory deficits. Agrammatism may also be elicited during writing tasks (e.g., picture description tasks).

Undoubtedly, while there has been rapid development of new clinical assessment tools under clinical characterization of these disorders, translation into clinical practice remains a substantial hurdle. Distinction from healthy controls and differentiation between groups is typically demonstrated at the group level, however, diagnostic accuracy (i.e., sensitivity and specificity at the individual level) is essential for clinical assessment. Normative data for novel experimental tools are scant, and rarely consider cultural differences. Moreover, many of these tests will require further iterations (e.g., short versions, practical considerations for psychophysiological and behavioral assessment approaches) before they are clinic-ready.

Biomarkers

Blood proteins. In the last decade, neurofilament light chain (NfL) has become a biomarker of interest in FTLD, since it is a sensitive marker of neurodegeneration and its levels are correlated with the rate of clinical progression and therefore with prognosis.[47-51] NfL levels in plasma correlate well with those in CSF.[47,50] Compared to various other diseases in which NfL levels are increased, levels in FTLD as a group are relatively high, but it must be taken into account that there is still overlap with controls.[52] A few recent studies have highlighted the use of NfL as a biomarker in the distinction between bvFTD and primary psychiatric disorders with areas under the curve between 0.84 and 0.94.[53,54] Although replication on a larger scale is needed, plasma NfL may become increasingly used in clinical practice when it comes to this particular differential diagnostic dilemma. NfL has recently been shown to predict future clinical progression during the prodromal stages of genetic FTD.[51] This has led to its use in clinical trials as a method of inclusion for presymptomatic carriers. Plasma measures of phosphorylated tau at residues 181 or 217 have comparable diagnostic accuracy to amyloid PET or CSF measures for the differential diagnosis from AD, and these may eventually supplant these biomarkers for clinical diagnosis.[49,55]

Cerebrospinal fluid (CSF). There are a growing number of CSF markers that are or may be useful in FTD. NfL in the CSF is elevated in FTD, but levels do not differentiate FTLD from non-FTLD pathology, nor do they distinguish the different proteinopathies in FTLD.[47,49,50] However, CSF NfL increases with disease progression in FTLD,[56] underscoring its potential use as a biomarker of neurodegeneration in therapeutic trials. While total tau and beta-amyloid levels are not sensitive or specific for any of the FTLD-spectrum proteinopathies, elevated phosphorylated tau levels in either CSF or plasma are useful for ruling out AD as a cause of FTD.[49,55] Of particular interest is the development of CSF assays which can detect markers of key proteinopathies in FTLD. Recent data on TDP-43 real-time

quaking induced conversion (RT-QuIC) seeding activity in CSF of ALS and FTD patients appears encouraging.[57] Truncated stathmin-2 was recently identified as a marker for TDP-43 dysfunction in FTD based on analyses of tissue,[58] and RT-QuIC seeding activity of tau in tissue AD and FTLD-tau brains[59] has also shown promise. Whether levels of truncated stathmin-2 and RT-QuIC seeding assays for TDP-43 and tau in antemortem CSF will be predictive of TDP-43 vs tau pathology in humans requires further study.

Genetic testing. Genetic testing (with pre- and post-test counseling in appropriate individuals) for the known gene mutations is reasonable in those with FTD and a positive family history of dementia, parkinsonism or ALS. The genes worthy of testing include, but are not limited to, the so-called "big three of FTD" – *C9orf72*, *MAPT* and *GRN*.[13,60] It is well known, however, that family histories in *C9orf72* mutation carriers can be negative or ambiguous due to the large variation in clinical phenotype, including psychiatric and other atypical presentations.[61] Whether to perform genetic testing in those without a compelling family history is controversial, and should depend on individual circumstances and the testing parameters that are established in certain countries. As more clinical trials begin, and especially if one or more treatments are shown to be effective for any of the genetically-mediated FTLD-spectrum disorders, genetic testing will likely expand.

Structural brain imaging. Brain imaging is standard in the assessment of any individual with cognitive/behavioral changes and a neurologic etiology is suspected, and this is typically accomplished using brain MRI. Atrophy in the frontal and/or temporal lobes, which can be symmetric or very focal/asymmetric, supports the clinical suspicion of FTD. [3,15] However, as noted above, the absence of obvious atrophy does not preclude an underlying neurodegenerative disorder. Volumetric MRI analyses are valuable in the assessment of individuals with sporadic and familial FTD, particularly to inform clinical trial design.[34,62-66]

Functional brain imaging. FDG-PET is often used to support the clinical suspicion of FTD – particularly when brain MRI findings are not diagnostic. While the clinical and research utility of FDG-PET has been demonstrated,[63] the findings are not 100% sensitive or specific for an FTLD-spectrum disorder.

Molecular PET brain imaging. Amyloid PET imaging identifies those individuals with amyloid deposition in the brain, and can be used to differentiate underlying AD from non-AD disorders in those with FTD (realizing that the interpretation of findings is challenging in those presumably uncommon individuals with coexisting FTLD and AD pathology, which can usually only be discovered at autopsy).[67] Tau PET imaging was initially considered to be a potential major breakthrough in differentiating a tauopathy vs a non-tauopathy among those with an underlying FTLD-spectrum disorder, but this has not been borne out.[68] For example, the currently used tau ligands bind to tau filaments similar in structure to AD NFTs, which occurs in only a few of the *MAPT* mutations (e.g., V337M, R406W) but not in most other *MAPT* mutations nor in the other primary tauopathies.[14,68] Furthermore, there is off-target binding that can lead to false-positive tau PET scans in those with non-tauopathies.[68,69] Therefore, the current first-generation tau ligands do not have sufficient clinical or research utility in FTD. Other ligands for tau as well as TDP-43 and other non-AD proteins are being vigorously developed and studied.

Current State of Management/Treatment

Early and accurate clinical diagnosis is essential to ensure appropriate management and treatment (as this becomes available). An accurate diagnosis and information about likely prognosis is also often invaluable to family members and carers who often experience disproportionate stress and burden.[10] Patient evaluations should consider potential risks to the

patient and or community. Patients with bvFTD often lack the capacity to avoid danger, due to disinhibition, apathy, and poor understanding of the internal state of others. Although they rarely exhibit violent behaviors, FTD patients are at risk of physical or financial victimization due to their impairments in social cognition. Of these concerns, driving safety and home firearms are also among the most urgent safety concerns. Suicide ideation is rare but should be considered in individuals with good insight or concurrent psychological distress (e.g., issues around adjustment, anxiety and depression). Several nonpharmacologic interventions for managing problematic FTD features[70-77] are shown in **Panel 2**.

Treatment Trials and Future Planning

Trials in progress or planned

Most current therapeutic programs target autosomal dominant forms of FTLD including *C9orf72* repeat expansions, *GRN* or *MAPT* mutations. A small number of programs have targeted sporadic forms of FTLD-tau, most commonly PSP. A summary of trials is shown in the **Table**.

Progranulin Deficiency. Patients with heterozygous loss of *GRN* function mutations develop FTD due to progranulin haploinsufficiency, and several clinical trials have sought to measure the pharmacodynamic effects of therapeutic interventions on raising progranulin levels in the blood and CSF. The calcium channel blocker nimodipine failed to raise progranulin levels in participants with *GRN* haploinsufficiency enrolled in an 8-week, open-label trial.[78] Histone deacetylase (HDAC) inhibitors substantially increase progranulin transcription, but the HDAC inhibitor FRM-0334 failed to raise plasma progranulin levels in participants with *GRN* haploinsufficiency enrolled in a double-blind placebo controlled trial (NCT02149160). More encouraging results have been observed in clinical trials of AL001, a

monoclonal antibody targeting sortilin, a protein central to the degradation of progranulin. A phase 3 trial of AL001 for progranulin deficiency is now underway (NCT04374136), which requires an elevated Nfl level for inclusion in the asymptomatic mutation carrier arm of the protocol. Two pharmaceutical companies have announced progranulin gene therapy programs using adeno-associated virus (AAV) vector therapies, including the AAV1-based PBFT02 (NCT04747431) and the AAV9-based PR006 (NCT04408625). Additionally, DNL593, a peripherally administered recombinant progranulin protein, modified to cross the blood-brain barrier has been announced as an imminent clinical trial candidate.[79]

C9orf72. A variety of pathogenic mechanisms have been proposed for *C9orf72* repeat expansion toxicity, including toxic inclusions of abnormally expanded RNA, toxic gain of function from dipeptides abnormally transcribed from the expanded RNA, and haploinsufficiency.[80,81] One approach for targeting C9orf72 expansion is suppression of the abnormally expanded RNA transcript using antisense oligonucleotides (ASOs). ASOs require intrathecal infusion, but they offer diverse and highly specific mechanisms to target discrete C9orf72 RNA transcripts. So far, clinical therapeutic trials of intrathecal ASOs designed to target expanded C9orf72 transcripts (including BIIB078 and *afinersen*) have only occurred in patients with an ALS phenotype. BIIB078 is currently being investigated in a phase 1 trial enrolling patients with ALS (NCT03626012). While both of these clinical programs have so far excluded patients with cognitive or behavioral features of *C9orf72* expansion, they provide the opportunity to establish biological proof of concept (eg, reduction of C9orf72 dipeptide repeats in CSF which has been reported for afinersen) that may lay the foundation for future trials *C9orf72*-related FTD. Aside from ASO therapies, the anti-sortilin antibody AL001 is also being explored in a phase 2 trial in symptomatic *C9orf72* expansion carriers, in an effort

to investigate the impact of increasing progranulin levels in other FTLD-TDP cohorts (NCT03987295).

FTLD-Tau. A multitude of potential therapies are currently under consideration for treatment of FTLD-tau, and given the importance of tau pathology in Alzheimer's disease, a number of clinical trials in FTLD-tau have sought to repurpose therapies from Alzheimer's development pipelines. Potential therapeutic mechanisms include enhancement of tau clearance, suppression of the prion-like behavior of toxic tau molecules, mitigation of toxic loss of microtubule function, suppression of tau production, augmentation of mRNA splicing, and augmentation of tau post translational modifications.[82]

Passive immunization, using anti-tau monoclonal antibodies, is a potential modality to improving tau clearance and suppress the spread of self-templating forms of tau (ie, prion like tau). It is not yet clear what epitopes are most important different tauopathies, and a multitude of potential therapeutic targets are being explored in trials, including antibodies against specific tau fragments (e.g. the N-terminal, proline rich, microtubule binding domain, or c-terminal regions of tau) as well as specific hyperphosphorylated forms of tau, specific confirmations of misfolded tau, monomeric tau, and oligomeric tau. In two well-powered phase 2 trials, antibodies directed against N-terminal tau epitopes (BIIB092, ABBV-8E12) failed to impact the rate of clinical progression in patients with PSP (NCT03413319, NCT03068468). Moreover, termination of Biogen's BIIB092 program in PSP led to an early termination in the phase 1 basket trial of BIIB092, enrolling patients with CBS, nfvPPA, *MAPT*-mutations, and traumatic encephalopathy (NCT03658135). Newer antibodies target different regions or three dimensional conformations of tau, with the hope that those that bind closer to the tau aggregation domains may be more efficacious.[83] While it is unclear how well

each of these antibodies can engage tau in different forms of tau pathology, they present a theoretical opportunity for additional therapeutic trials in FTLD-tau.

Active immunization strategies are a less explored pathway for tau therapy, but offer the potential benefits of decreased treatment burden and generation of multiple antibodies against a variety of epitopes. The AADvac1 vaccine (containing tau peptide aa 294-305/4R) has been shown to be safe and well tolerated in an open label trial enrolling patients with AD[84] and has subsequently been investigated in a phase 1 trial enrolling patients with nfvPPA (NCT03174886) although results have not yet been reported.

Direct augmentation of tau expression remains relatively unexplored in FTLD development pipelines, but ASOs offer a diverse range of methods to impact the expression of tau. In non-human primates, intrathecal infusions of an ASO that knocks down tau expression, BIIB080 (IONIS-$MAPT_{Rx}$)**,** were well tolerated and led to a 75% reduction of MAPT mRNA in the cortex.[85] Currently BIIB080 is only being investigated in clinical trials enrolling patients with mild Alzheimer's disease (NCT03186989), and it may provide a viable mechanism to suppress tau pathology in FTLD-tau.

Oxytocin. There were encouraging results in a recent study using intranasal oxytocin in FTD,[86] and a phase 2 trial that is currently in progress (NCT01386333).

Transcranial stimulation. Transcranial DC stimulation is being studied in FTLD-GRN (NCT02999282), and transcranial magnetic stimulation is being studied in PPA and bvFTD (NCT03406429).

Natural history study cohorts

In recent years there has been a move from small single site observational studies to large multicentre natural history cohorts of FTD. The Genetic FTD Initiative (GENFI) is a

European and Canadian study focused on both presymptomatic and symptomatic genetic forms of FTD (www.genfi.org). This cohort has recruited over 1100 participants over the last nine years with a focus on developing robust biomarkers of disease onset and progression in genetic FTD. Important work from this group includes the identification of presymptomatic imaging changes[87] as well as changes in key fluid biomarkers such as NfL[48] and GFAP.[88] The Advancement in Research and Treatment in Frontotemporal Lobar Degeneration (ARTFL; focused on sporadic and familial FTLD) and Longitudinal Evaluation of Familial Frontotemporal Dementia Subjects (LEFFTDS; focused on familial FTLD) both began enrolling participants in 2014. The efforts in both programs were combined as part of the ARTFL LEFFTDS Longitudinal Frontotemporal Lobar Degeneration (ALLFTD; www.allftd.org) Consortium which involves 19 sites in North America and includes over 1500 participants evaluated thus far.[2,34,89] The Dominantly Inherited Non-Alzheimer Dementias (DINAD) program in Australia, the New Zealand Genetic FTD (FTDGeNZ) study and Research Dementia Latin America (ReDLAT; www.lac-cd.org/en/proyects/) study have also built FTD cohorts, and together with GENFI and ALLFTD, have come together to form the FTD Prevention Initiative (FPI; www.thefpi.org). The aim of the FPI is to bring together a worldwide cohort of familial FTD, with a minimum shared dataset that is collected across all participants, helping to compare and contrast a more diverse set of patients with FTD. The addition of cohorts from Asia (e.g. within Japan, South East Asia and Korea) to the FPI will allow comparison of geographical frequency, with genetic FTD occurring at much lower rates in some regions. Overall, the overarching aim of the FPI is to work together with industry to promote clinical trials of new therapies that might prevent FTD: creation of an international database of participants eligible for trials and uniform standards for conducting such trials will be the first steps in this process.

Conclusions

The major achievements in FTD research over the last decade include the formation of large (inter)national study cohorts, enabling us to identify the earliest clinical, biomarker, and neuroimaging changes in presymptomatic mutation carriers and to define intermediate stages between onset of symptomatology and overt FTD. It is encouraging that various drug trials have been initiated, in particular aimed at the genetic forms of FTD. We have learned about the clinical spectrum associated with the common autosomal dominant mutation in the *C9orf72* gene, which will hopefully lead to a better detection of FTD among patients with a psychiatric presentation. Finding biomarkers that predict the underlying FTLD pathology, after years of research, remains an ongoing quest and would represent an enormous breakthrough with respect to diagnostic specificity, treatment development and disease monitoring.

Contributors

All authors contributed to the review of the literature, writing of the initial draft, and manuscript editing and revision.

Acknowledgments

Supported by grants NIH grants AG063911 (BFB, ALB), AG045390 (BFB, ALB), NS092089 (BFB, ALB), AG038791 (BFB, ALB), AG062677 (BFB), AG052943 (BFB), U24AG057437 (ALB), Rainwater Charitable Foundation (ALB), Bluefield Project to Cure FTD (ALB), Association for Frontotemporal Degeneration (ALB), University of California Cures AD Program (ALB), NHMRC Career Development Fellowship GNT1158762 (FK), MRC MR/M008525/1; MR/M023664/1 (JR), NIHR BRC149/NS/MH (JR), JPND 2019-02248 (JR).

We thank our many colleagues with whom we collaborate on clinical and research activities in FTD. We particularly thank our patients and families for participating in FTD research.

Figure Legends

Figure 1. The core and halo of clinical presentations within the FTLD pathological spectrum

The core syndromes are shown in blue. The syndromes shown in green represent overlap syndromes within the FTD spectrum, and those depicted in red represent clinical presentations classically outside of the FTD spectrum.

Abbreviations: AD=Alzheimer's disease, ALS=amyotrophic lateral sclerosis, bvFTD=behavioral variant frontotemporal dementia, CBS=corticobasal syndrome, FTD-ALS=frontotemporal dementia plus amyotrophic lateral sclerosis, HD=Huntington's disease, nfvPPA=nonfluent variant primary progressive aphasia, PD=Parkinson's disease, PPA=primary progressive aphasia, PPAOS=primary progressive apraxia of speech, PSP=progressive supranuclear palsy, rtvFTD = right temporal variant FTD, svPPA=semantic variant primary progressive aphasia. The term semantic dementia here is used to describe a syndrome where semantic impairment is prominent initially – this can either be verbal (svPPA) or non-verbal/emotional (rtvFTD).

Figure 2. MRI characteristics in right temporal variant FTLD vs semantic variant PPA

A. Representative coronal T1-weighted images of a 70 year old male with behavioral changes, prosopagnosia and naming difficulties, showing marked right anterior temporal lobe atrophy; these clinical and imaging findings are typical of the right temporal variant of frontotemporal lobar degeneration. **B**. Representative coronal T1-weighted images of a 64 year old female with fluent but empty speech and marked dysnomia, showing the marked left anterior temporal lobe atrophy; these clinical and imaging findings are typical of the semantic variant of primary progressive aphasia.

Abbreviations: L-left, R-right

Figure 3 – Conceptual Framework of Prodromal FTLD

A. Prodromal FTLD represents the intermediate state between normal neurologic functioning and an overt FTLD-spectrum clinical syndrome, with each of the prodromal states intending to reflect a change from baseline yet activities of daily living are largely preserved. The MCI state represents the classic decline in one or more cognitive domains. The MBI state represents a change in personality/behavior/comportment including but not limited to two or more of the features described. The MMI state represents a change in decline in motor functioning, with elements of extrapyramidal dysfunction, upper motor neuron disease dysfunction, lower motor neuron disease dysfunction, or some combination of these. Each prodromal phase is intended to have elements of overlap with normal neurologic functioning on the mild end (reflecting the challenges differentiating normal vs very mildly abnormal) and overt FTLD on the more severe end (reflecting the challenges differentiating mildly abnormal vs an overt clinical syndrome). **B**. The diagram is intended to reflect the overlap in cognitive and behavioral features, behavioral and motor features, cognitive and motor features, or cognitive and behavioral and motor features that certain individuals exhibit in this prodromal FTLD state. **C**. Among those destined to develop an overt FTLD spectrum disorder, which prodromal state is exhibited while likely predict which eventual overt disorder will evolve, with some degree of variability. MCI is hypothesized to most likely evolve into bvFTD or PPA (with the language predominant form of MCI undoubtedly evolving into PPA moreso than bvFTD), whereas MBI is hypothesized to most likely evolve into bvFTD +/- ALS, and MMI is hypothesized to most likely evolve into CBS or PSP/RS or ALS (the hypothesized likelihood of evolution is reflected by the weighting of the lines).

Abbreviations: ALS-amyotrophic lateral sclerosis, bvFTD=behavioral variant frontotemporal dementia, CBS=corticobasal syndrome, FTD/ALS=frontotemporal dementia plus amyotrophic lateral sclerosis, MBI=mild behavioral impairment, MCI=mild cognitive impairment, MMI=mild motor impairment, PPA=primary progressive aphasia, PSP/RS=progressive supranuclear palsy/Richardson's syndrome

References

1. Bang J, Spina S, Miller B. Frontotemporal dementia. *Lancet* 2015; **386**: 1672-82.

2. Heuer HW, Wang P, Rascovsky K, et al. Comparison of sporadic and familial behavioral variant frontotemporal dementia (FTD) in a North American cohort. *Alzheimers Dement* 2020; **16**(1): 60-70.

3. Rascovsky K, Hodges JR, Knopman D, et al. Sensitivity of revised diagnostic criteria for the behavioural variant of frontotemporal dementia. *Brain* 2011; **134**: 2456-77.

4. Townley RA, Graff-Radford J, Mantyh WG, et al. Progressive dysexecutive syndrome due to Alzheimer's disease: a description of 55 cases and comparison to other phenotypes. *Brain Commun* 2020; **2**(1): fcaa068.

5. Falgas N, Sanchez-Valle R, Bargallo N, et al. Hippocampal atrophy has limited usefulness as a diagnostic biomarker on the early onset Alzheimer's disease patients: A comparison between visual and quantitative assessment. *Neuroimage Clin* 2019; **23**: 101927.

6. Swift IJ, Sogorb-Esteve A, Heller C, et al. Fluid biomarkers in frontotemporal dementia: past, present and future. *J Neurol Neurosurg Psychiatry* 2021; **92**(2): 204-15.

7. Snowden JS, Rollinson S, Thompson JC, et al. Distinct clinical and pathological characteristics of frontotemporal dementia associated with C9ORF72 mutations. *Brain* 2012; **135**(Pt 3): 693-708.

8. Abramzon YA, Fratta P, Traynor BJ, Chia R. The Overlapping Genetics of Amyotrophic Lateral Sclerosis and Frontotemporal Dementia. *Front Neurosci* 2020; **14**: 42.

9. Valente E, Caramelli P, Gambogi L, et al. Phenocopy syndrome of behavioral variant frontotemporal dementia: a systematic review. *Alz Res Ther* 2019; **11**(1): 1-15.

10. Ducharme S, Dols A, Laforce R, et al. Recommendations to distinguish behavioural variant frontotemporal dementia from psychiatric disorders. *Brain* 2020; **143**(6): 1632-50.

11. Pressman PS, Matlock D, Ducharme S. Distinguishing Behavioral Variant Frontotemporal Dementia From Primary Psychiatric Disorders: A Review of Recently Published Consensus Recommendations From the Neuropsychiatric International Consortium for Frontotemporal Dementia. *J Neuropsychiatry Clin Neurosci* 2021: appineuropsych20090238.

12. Schievink W, May aM, Barnard Z, et al. Behavioral Variant Frontotemporal Dementia as a Serious Complication of Spontaneous Intracranial Hypotension. *Oper Neurosurg* 2018; **15**(5): 505-15.

13. Moore KM, Nicholas J, Grossman M, et al. Age at symptom onset and death and disease duration in genetic frontotemporal dementia: an international retrospective cohort study. *Lancet Neurol* 2020; **19**(2): 145-56.

14. Jones DT, Knopman DS, Graff-Radford J, et al. In vivo (18)F-AV-1451 tau PET signal in MAPT mutation carriers varies by expected tau isoforms. *Neurology* 2018; **90**(11): e947-e54.

15. Gorno-Tempini ML, Hillis AE, Weintraub S, et al. Classification of primary progressive aphasia and its variants. *Neurology* 2011; **76**: 1006-14.

16. Louwersheimer E, Keulen MA, Steenwijk MD, et al. Heterogeneous Language Profiles in Patients with Primary Progressive Aphasia due to Alzheimer's Disease. *J Alzheimers Dis* 2016; **51**(2): 581-90.

17. Matias-Guiu JA, Suarez-Coalla P, Pytel V, et al. Reading prosody in the non-fluent and logopenic variants of primary progressive aphasia. *Cortex* 2020; **132**: 63-78.

18. Kamath V, Sutherland ER, Chaney GA. A Meta-Analysis of Neuropsychological Functioning in the Logopenic Variant of Primary Progressive Aphasia: Comparison with the Semantic and Non-Fluent Variants. *J Int Neuropsychol Soc* 2020; **26**(3): 322-30.

19. Botha H, Josephs KA. Primary Progressive Aphasias and Apraxia of Speech. *Continuum (Minneap Minn)* 2019; **25**(1): 101-27.

20. Tetzloff KA, Duffy JR, Clark HM, et al. Progressive agrammatic aphasia without apraxia of speech as a distinct syndrome. *Brain* 2019; **142**(8): 2466-82.

21. Seckin ZI, Duffy JR, Strand EA, et al. The evolution of parkinsonism in primary progressive apraxia of speech: A 6-year longitudinal study. *Parkinsonism Relat Disord* 2020; **81**: 34-40.

22. Mesulam MM, Weintraub S, Rogalski EJ, Wieneke C, Geula C, Bigio EH. Asymmetry and heterogeneity of Alzheimer's and frontotemporal pathology in primary progressive aphasia. *Brain* 2014; **137**(Pt 4): 1176-92.

23. Giannini LAA, Xie SX, McMillan CT, et al. Divergent patterns of TDP-43 and tau pathologies in primary progressive aphasia. *Ann Neurol* 2019; **85**(5): 630-43.

24. Murley AG, Coyle-Gilchrist I, Rouse MA, et al. Redefining the multidimensional clinical phenotypes of frontotemporal lobar degeneration syndromes. *Brain* 2020; **143**(5): 1555-71.

25. Ida CM, Butz ML, Lundquist PA, Dawson DB. C9orf72 Repeat Expansion Frequency among Patients with Huntington Disease Genetic Testing. *Neurodegener Dis* 2018; **18**(5-6): 239-53.

26. Ulugut Erkoyun H, Groot C, Heilbron R, et al. A clinical-radiological framework of the right temporal variant of frontotemporal dementia. *Brain* 2020; **143**(9): 2831-43.

27. Ulugut Erkoyun H, van der Lee SJ, Nijmeijer B, et al. The Right Temporal Variant of Frontotemporal Dementia Is Not Genetically Sporadic: A Case Series. *J Alzheimers Dis* 2021; **79**(3): 1195-201.

28. Neumann M, Mackenzie IRA. Review: Neuropathology of non-tau frontotemporal lobar degeneration. *Neuropathol Appl Neurobiol* 2019; **45**(1): 19-40.

29. Spina S, La Joie R, Petersen C, et al. Comorbid neuropathological diagnoses in early versus late-onset Alzheimer's disease. *Brain* 2021.

30. Nelson PT, Dickson DW, Trojanowski JQ, et al. Limbic-predominant age-related TDP-43 encephalopathy (LATE): consensus working group report. *Brain* 2019; **142**(6): 1503-27.

31. Josephs KA, Mackenzie I, Frosch MP, et al. LATE to the PART-y. *Brain* 2019; **142**(9): e47.

32. Boxer AL, Yu JT, Golbe LI, Litvan I, Lang AE, Hoglinger GU. Advances in progressive supranuclear palsy: new diagnostic criteria, biomarkers, and therapeutic approaches. *The Lancet Neurology* 2017; **16**(7): 552-63.

33. Estevez-Fraga C, Magrinelli F, Hensman Moss D, et al. Expanding the Spectrum of Movement Disorders Associated With C9orf72 Hexanucleotide Expansions. *Neurol Genet* 2021; **7**(2): e575.

34. Olney NT, Ong E, Goh SM, et al. Clinical and volumetric changes with increasing functional impairment in familial frontotemporal lobar degeneration. *Alzheimers Dement* 2020; **16**(1): 49-59.

35. Staffaroni AM, Bajorek L, Casaletto KB, et al. Assessment of executive function declines in presymptomatic and mildly symptomatic familial frontotemporal dementia: NIH-EXAMINER as a potential clinical trial endpoint. *Alzheimers Dement* 2020; **16**(1): 11-21.

36. Staffaroni AM, Weintraub S, Rascovsky K, et al. Uniform data set language measures for bvFTD and PPA diagnosis and monitoring. *Alzheimers Dement (Amst)* 2021; **13**(1): e12148.

37. Ranasinghe KG, Rankin KP, Lobach IV, et al. Cognition and neuropsychiatry in behavioral variant frontotemporal dementia by disease stage. *Neurology* 2016; **86**(7): 600-10.

38. Hughes LE, Rittman T, Robbins TW, Rowe JB. Reorganization of cortical oscillatory dynamics underlying disinhibition in frontotemporal dementia. *Brain* 2018; **141**(8): 2486-99.

39. Wong S, Irish M, O'Callaghan C, et al. Should I trust you? Learning and memory of social interactions in dementia. *Neuropsychologia* 2017; **104**: 157-67.

40. Poos JM, Jiskoot LC, Papma JM, van Swieten JC, van den Berg E. Meta-analytic Review of Memory Impairment in Behavioral Variant Frontotemporal Dementia. *J Int Neuropsychol Soc* 2018: 1-13.

41. Ramanan S, Bertoux M, Flanagan E, et al. Longitudinal Executive Function and Episodic Memory Profiles in Behavioral-Variant Frontotemporal Dementia and Alzheimer's Disease. *J Int Neuropsychol Soc* 2017; **23**(1): 34-43.

42. Tu S, Spiers HJ, Hodges JR, Piguet O, Hornberger M. Egocentric versus Allocentric Spatial Memory in Behavioral Variant Frontotemporal Dementia and Alzheimer's Disease. *J Alzheimers Dis* 2017; **59**(3): 883-92.

43. Salimi S, Irish M, Foxe D, Hodges JR, Piguet O, Burrell JR. Visuospatial dysfunction in Alzheimer's disease and behavioural variant frontotemporal dementia. *J Neurol Sci* 2019; **402**: 74-80.

44. Johnen A, Reul S, Wiendl H, Meuth SG, Duning T. Apraxia profiles-A single cognitive marker to discriminate all variants of frontotemporal lobar degeneration and Alzheimer's disease. *Alzheimers Dement (Amst)* 2018; **10**: 363-71.

45. Henry ML, Grasso SM. Assessment of Individuals with Primary Progressive Aphasia. *Semin Speech Lang* 2018; **39**(3): 231-41.

46. Harris JM, Saxon JA, Jones M, Snowden JS, Thompson JC. Neuropsychological differentiation of progressive aphasic disorders. *J Neuropsychol* 2019; **13**(2): 214-39.

47. Meeter LH, Dopper EG, Jiskoot LC, et al. Neurofilament light chain: a biomarker for genetic frontotemporal dementia. *Annals of clinical and translational neurology* 2016; **3**(8): 623-36.

48. van der Ende EL, Meeter LH, Poos JM, et al. Serum neurofilament light chain in genetic frontotemporal dementia: a longitudinal, multicentre cohort study. *Lancet Neurol* 2019; **18**(12): 1103-11.

49. Thijssen EH, La Joie R, Wolf A, et al. Diagnostic value of plasma phosphorylated tau181 in Alzheimer's disease and frontotemporal lobar degeneration. *Nat Med* 2020; **26**(3): 387-97.

50. Illan-Gala I, Lleo A, Karydas A, et al. Plasma Tau and Neurofilament Light in Frontotemporal Lobar Degeneration and Alzheimer Disease. *Neurology* 2021; **96**(5): e671-e83.

51. Rojas JC, Wang P, Staffaroni AM, et al. Plasma Neurofilament Light for Prediction of Disease Progression in Familial Frontotemporal Lobar Degeneration. *Neurology* 2021; **96**(18): e2296-e312.

52. Bridel C, van Wieringen WN, Zetterberg H, et al. Diagnostic Value of Cerebrospinal Fluid Neurofilament Light Protein in Neurology: A Systematic Review and Meta-analysis. *JAMA Neurol* 2019; **76**(9): 1035-48.

53. Eratne D, Loi SM, Walia N, et al. A pilot study of the utility of cerebrospinal fluid neurofilament light chain in differentiating neurodegenerative from psychiatric disorders: A 'C-reactive protein' for psychiatrists and neurologists? *Aust N Z J Psychiatry* 2020; **54**(1): 57-67.

54. Katisko K, Cajanus A, Jaaskelainen O, et al. Serum neurofilament light chain is a discriminative biomarker between frontotemporal lobar degeneration and primary psychiatric disorders. *J Neurol* 2020; **267**(1): 162-7.

55. Palmqvist S, Janelidze S, Quiroz YT, et al. Discriminative Accuracy of Plasma Phospho-tau217 for Alzheimer Disease vs Other Neurodegenerative Disorders. *Jama* 2020; **324**(8): 772-81.

56. Panman JL, Venkatraghavan V, van der Ende EL, et al. Modelling the cascade of biomarker changes in GRN-related frontotemporal dementia. *J Neurol Neurosurg Psychiatry* 2021.

57. Scialò C, Tran TH, Salzano G, et al. TDP-43 real-time quaking induced conversion reaction optimization and detection of seeding activity in CSF of amyotrophic lateral sclerosis and frontotemporal dementia patients. *Brain Commun* 2020; **2**(2): fcaa142.

58. Prudencio M, Humphrey J, Pickles S, et al. Truncated stathmin-2 is a marker of TDP-43 pathology in frontotemporal dementia. *J Clin Invest* 2020; **130**(11): 6080-92.

59. Tennant JM, Henderson DM, Wisniewski TM, Hoover EA. RT-QuIC detection of tauopathies using full-length tau substrates. *Prion* 2020; **14**(1): 249-56.

60. Ramos EM, Dokuru DR, Van Berlo V, et al. Genetic screening of a large series of North American sporadic and familial frontotemporal dementia cases. *Alzheimers Dement* 2020; **16**(1): 118-30.

61. Khan BK, Yokoyama JS, Takada LT, et al. Atypical, slowly progressive behavioural variant frontotemporal dementia associated with C9ORF72 hexanucleotide expansion. *J Neurol Neurosurg Psychiatry* 2012; **83**(4): 358-64.

62. Chen Q, Boeve BF, Senjem M, et al. Rates of lobar atrophy in asymptomatic MAPT mutation carriers. *Alzheimers Dement (N Y)* 2019; **5**: 338-46.

63. Bejanin A, Tammewar G, Marx G, et al. Longitudinal structural and metabolic changes in frontotemporal dementia. *Neurology* 2020; **95**(2): e140-e54.

64. Boxer AL, Gold M, Feldman H, et al. New directions in clinical trials for frontotemporal lobar degeneration: Methods and outcome measures. *Alzheimers Dement* 2020; **16**(1): 131-43.

65. Rosen HJ, Boeve BF, Boxer AL. Tracking disease progression in familial and sporadic frontotemporal lobar degeneration: Recent findings from ARTFL and LEFFTDS. *Alzheimers Dement* 2020; **16**(1): 71-8.

66. Staffaroni AM, Cobigo Y, Goh SM, et al. Individualized atrophy scores predict dementia onset in familial frontotemporal lobar degeneration. *Alzheimers Dement* 2020; **16**(1): 37-48.

67. Ghirelli A, Tosakulwong N, Weigand SD, et al. Sensitivity-Specificity of Tau and Amyloid beta Positron Emission Tomography in Frontotemporal Lobar Degeneration. *Ann Neurol* 2020; **88**(5): 1009-22.

68. Tsai RM, Bejanin A, Lesman-Segev O, et al. (18)F-flortaucipir (AV-1451) tau PET in frontotemporal dementia syndromes. *Alzheimers Res Ther* 2019; **11**(1): 13.

69. Makaretz SJ, Quimby M, Collins J, et al. Flortaucipir tau PET imaging in semantic variant primary progressive aphasia. *J Neurol Neurosurg Psychiatry* 2018; **89**(10): 1024-31.

70. Volkmer A, Rogalski E, Henry M, et al. Speech and language therapy approaches to managing primary progressive aphasia. *Pract Neurol* 2020; **20**(2): 154-61.

71. Henry ML, Hubbard HI, Grasso SM, et al. Treatment for Word Retrieval in Semantic and Logopenic Variants of Primary Progressive Aphasia: Immediate and Long-Term Outcomes. *J Speech Lang Hear Res* 2019; **62**(8): 2723-49.

72. Suarez-Gonzalez A, Savage SA, Caine D. Successful short-term re-learning and generalisation of concepts in semantic dementia. *Neuropsychol Rehabil* 2018; **28**(7): 1095-109.

73. Cotelli M, Manenti R, Ferrari C, Gobbi E, Macis A, Cappa SF. Effectiveness of language training and non-invasive brain stimulation on oral and written naming performance in Primary Progressive Aphasia: A meta-analysis and systematic review. *Neurosci Biobehav Rev* 2020; **108**: 498-525.

74. Henry ML, Hubbard HI, Grasso SM, et al. Retraining speech production and fluency in non-fluent/agrammatic primary progressive aphasia. *Brain* 2018; **141**(6): 1799-814.

75. Rogalski EJ, Khayum B. A Life Participation Approach to Primary Progressive Aphasia Intervention. *Semin Speech Lang* 2018; **39**(3): 284-96.

76. O'Connor CMC, Mioshi E, Kaizik C, Fisher A, Hornberger M, Piguet O. Positive behaviour support in frontotemporal dementia: A pilot study. *Neuropsychol Rehabil* 2020: 1-24.

77. Casaletto KB, Staffaroni AM, Wolf A, et al. Active lifestyles moderate clinical outcomes in autosomal dominant frontotemporal degeneration. *Alzheimers Dement* 2020; **16**(1): 91-105.

78. Sha SJ, Miller ZA, Min SW, et al. An 8-week, open-label, dose-finding study of nimodipine for the treatment of progranulin insufficiency from GRN gene mutations. *Alzheimers Dement (N Y)* 2017; **3**(4): 507-12.

79. Pipeline DT. https://www.denalitherapeutics.com/pipeline.

80. Todd TW, Petrucelli L. Insights into the pathogenic mechanisms of Chromosome 9 open reading frame 72 (C9orf72) repeat expansions. *J Neurochem* 2016; **138 Suppl 1**: 145-62.

81. Jiang J, Zhu Q, Gendron TF, et al. Gain of Toxicity from ALS/FTD-Linked Repeat Expansions in C9ORF72 Is Alleviated by Antisense Oligonucleotides Targeting GGGGCC-Containing RNAs. *Neuron* 2016; **90**(3): 535-50.

82. VandeVrede L, Boxer AL, Polydoro M. Targeting tau: Clinical trials and novel therapeutic approaches. *Neurosci Lett* 2020; **731**: 134919.

83. Sandusky-Beltran LA, Sigurdsson EM. Tau immunotherapies: Lessons learned, current status and future considerations. *Neuropharmacology* 2020; **175**: 108104.

84. Novak P, Schmidt R, Kontsekova E, et al. FUNDAMANT: an interventional 72-week phase 1 follow-up study of AADvac1, an active immunotherapy against tau protein pathology in Alzheimer's disease. *Alzheimers Res Ther* 2018; **10**(1): 108.

85. Mignon L, Kordasiewicz H, Lane R. Design of the first-in-human study of IONIS-MAPTRx, a tau-lowering antisense oligonucleotide, in patients with Alzheimer disease. *Neurology* 2018; **90**(**15 Supplement**): S2.006.

86. Oliver LD, Stewart C, Coleman K, et al. Neural effects of oxytocin and mimicry in frontotemporal dementia: A randomized crossover study. *Neurology* 2020; **95**(19): e2635-e47.

87. Rohrer JD, Nicholas JM, Cash DM, et al. Presymptomatic cognitive and neuroanatomical changes in genetic frontotemporal dementia in the Genetic Frontotemporal dementia Initiative (GENFI) study: a cross-sectional analysis. *The Lancet Neurology* 2015; **14**(3): 253-62.

88. Heller C, Chan E, Foiani MS, et al. Plasma glial fibrillary acidic protein and neurofilament light chain are measures of disease severity in semantic variant primary progressive aphasia. *J Neurol Neurosurg Psychiatry* 2020.

89. Boeve B, Bove J, Brannelly P, et al. The longitudinal evaluation of familial frontotemporal dementia subjects protocol: Framework and methodology. *Alzheimers Dement* 2020; **16**(1): 22-36.

Manuscript Click here to view linked References

Advances and Controversies in Frontotemporal Dementia: Characterization, Diagnosis, Biomarkers, and Therapeutic Considerations

Bradley F. Boeve, MD[1]
Adam L. Boxer, MD, PhD[2]
Fiona Kumfor, PhD[3]
Yolande Pijnenburg, MD, PhD[4]
Jonathan D. Rohrer, FRCP, PhD[5]

[1]Department of Neurology, Mayo Clinic, Rochester, Minnesota, USA
[2]Department of Neurology, University of California San Francisco, San Francisco, California, USA
[3]School of Psychology and Brain & Mind Centre, University of Sydney, Sydney, New South Wales, Australia
[4]Alzheimer Center Amsterdam, Department of Neurology, Amsterdam Neuroscience, Vrije Universiteit Amsterdam, Amsterdam UMC, Amsterdam, The Netherlands
[5]Dementia Research Centre, University College London Queen Square Institute of Neurology, London, UK

Running head: THELANCETNEUROLOGY-D-21-00318R1

Keywords: Frontotemporal dementia, frontotemporal lobar degeneration, genetics, tau, TDP-43, therapeutics

Title: 12 words (115 characters)
Abstract: 123 words
Word count: 4848
References: 89
Tables: 1
Figures: 3
Panels: 2
Appendices: 2

Correspondence to:
Bradley F. Boeve, M.D.
Mayo Clinic
Department of Neurology
200 First Street SW
Rochester, MN 55905
Phone: 507-538-1038
Fax: 507-538-6012
Email: bboeve@mayo.edu

Abstract

Frontotemporal dementia (FTD) is an umbrella term that encompasses a group of clinical syndromes due to an underlying neurodegenerative disease characterized by progressive changes in behavior, executive function or language. The group of neurodegenerative diseases that manifest clinically as FTD are known as the frontotemporal lobar degeneration (FTLD) spectrum pathologies, and these disorders are related to proteinopathies that are associated with frontotemporal neural network dysfunction. Recent advances in the clinical, biofluid, genetic, imaging, and molecular characterization have provided many new insights into FTD/FTLD. Several large natural history cohort studies are also now in progress. This update reviews these advances as well as some controversies, and covers current and anticipated interventions that target problematic clinical features and the molecular underpinnings designed to optimize management.

Disclosures

Dr. Boeve has no relevant disclosures for this paper. He has served as an investigator for clinical trials sponsored by Alector, Biogen, and EIP Pharma. He serves on the Scientific Advisory Board for the Tau Consortium. He receives funding from the NIH, the Mangurian Foundation, and the Little Family Foundation.

Dr. Boxer receives research support from the NIH, the Rainwater Charitable Foundation, the Association for Frontotemporal Degeneration, Bluefield Project to Cure Frontotemporal Dementia, the Alzheimer's Drug Discovery Foundation and the Alzheimer's Association. He has served as a consultant for Alector, AGTC, Arkuda, Arvinas, AZTherapies, GSK, Oligomerix, Ono, Regeneron, Roche, Samumed, Stealth, Third Rock, Transposon and Wave, and received research support from Biogen, Eisai and Regeneron.

Dr. Kumfor has no relevant disclosures for this paper. She receives funding from the National Health and Medical Research Council.

Dr. Pijnenburg has no relevant disclosures for this paper. She receives funding from the Dioraphte Foundation, Health Holland, and ZonMW.

Dr. Rohrer has no relevant disclosures for this paper. He has served on the Medical Advisory Board for Alector, Wave Life Sciences, Arkuda Therapeutics and Prevail Therapeutics. He receives funding from the UK Medical Research Council, National Institute for Health Research, Association for Frontotemporal Degeneration, Alzheimer's Association and the Bluefield Project.

Search strategy and selection criteria

We searched PubMed for articles published from Jan 01, 2016, to June 1, 2021, in English journals, using the search terms “frontotemporal dementia”, “frontotemporal lobar degeneration”, “FTD”, “FTLD”, “tau protein”, “TDP-43”, and “tauopathy”. Additional articles were included from reference lists, review articles, and the authors' own files. The final reference list was generated on the basis of originality and relevance to the topics covered in this Review.

Introduction

Frontotemporal dementia (FTD) is an umbrella term that encompasses a group of clinical syndromes due to an underlying neurodegenerative disease characterized by progressive changes in behavior, executive function or language.[1] These syndromes include the behavioral variant of frontotemporal dementia (bvFTD) and the nonfluent and semantic variants of primary progressive aphasia (nfvPPA and svPPA), each of which can also be accompanied by amyotrophic lateral sclerosis (ALS). The clinical characteristics and cognitive profiles of the FTD subtypes are presented in **Panel 1**.

Frontotemporal lobar degeneration (FTLD) is the overarching pathological term for a group of neurodegenerative disorders that involve one or more proteinopathies and are typically associated with progressive degeneration particularly in the frontotemporal neural networks. In any given individual, the FTD syndrome is typically (but not always) due to an underlying FTLD spectrum disease. The histopathologically-defined disorders of corticobasal degeneration (CBD) and progressive supranuclear palsy (PSP) are generally considered under the FTLD term, whereas the clinical phenotypes of corticobasal syndrome (CBS) and progressive supranuclear palsy/Richardson's syndrome (PSP-RS) represent the clinical syndromes that are usually (but not always) a reflection of an underlying FTLD spectrum pathology. This review will use the term FTD when focusing on the clinical syndromes of bvFTD, nfvPPA and svPPA (+/- ALS), and use the term FTLD when referring to the neurodegenerative pathologies that manifest as FTD.[2]

Recent research in the clinical, biofluid, genetic, imaging, and molecular characterization of FTD/FTLD has provided many new insights as well as generated some degree of controversy. Several large natural history cohort studies are also now in progress. This update reviews these advances and controversies. Many nonpharmacologic and

particularly pharmacologic interventions have been tested over recent years, and many trials are in progress or planned. This review will also cover current and anticipated interventions designed to optimize management.

Clinical Presentation and Characterization of FTD

Differentiating FTD vs non-FTD disorders

The clinical diagnosis of bvFTD is based on current consensus diagnostic criteria that have been derived from an international cohort of 406 pathologically verified FTD cases.[3] Based on these criteria, a degree of probability of underlying FTLD can be attributed to cases presenting with at least three out of five behavioural and one cognitive criterion (See also **Panel 1**). The main clinical differential diagnosis of bvFTD consists of Alzheimer's disease (AD), primary psychiatric disease, vascular dementia, and dementia with Lewy bodies (DLB), with the differentiation of bvFTD from AD and psychiatric disease being most challenging. In general, episodic memory impairment is more prominent in AD than bvFTD, although a dysexecutive/behavioural AD variant is recognized.[4] With the current state-of the-art biomarkers of underlying amyloid pathology, bvFTD can be reliably differentiated from AD, although it can never be fully excluded that a subject with bvFTD has AD co-pathology. Notably, increased CSF tau levels and medial temporal lobe atrophy on MRI are often considered AD biomarkers, but these findings are not specific for AD as these can be seen in a proportion of FTD cases as well.[5,6]

Neuropsychiatric presentations have been seen in a number of FTD syndromes, and these are reported more commonly in people with chromosome 9 open reading frame 72 (*C9orf72*) expansions.[7] The *C9orf72* expansion is the most common genetic cause of FTD and/or ALS.[8] Here there can be the added difficulty of an insidious onset and very slowly

progress of symptoms. Like other slowly progressive degenerative FTD syndromes, this can be difficult to diagnose initially as it has a similar presentation to the so-called "FTD phenocopy syndrome," which in the majority of cases is non-neurodegenerative.[9] The FTD phenocopy syndrome also highlights that there can be mimics of bvFTD, and that caution is always needed in making the diagnosis on a purely symptomatic basis, particularly in the absence of evidence of neurodegeneration on biomarker studies. Therefore, longer term clinical and neuroimaging follow-up is warranted in any individual with bvFTD features who does not fulfill established criteria for probable bvFTD[3] and/or supportive biomarker evidence of a neurodegenerative process is lacking.

An international group of neurologists and psychiatrists, The Neuropsychiatric International Consortium for FTD, has recently established recommendations for the distinction between bvFTD and primary psychiatric disorders.[10,11]

Structural brain imaging is essential to exclude mass lesions in the frontal or temporal lobes, hydrocephalus, etc. One mimic that has been described and is important to consider is an FTD-like clinical presentation associated with intracranial hypotension, termed by some as frontotemporal brain sagging syndrome,[12] which in contrast to FTD can be reversible.

Atypical presentations of FTD

Although the canonical FTD clinical syndromes are well-described, it has become clear in recent years that, firstly, there can be a number of atypical presentations of these syndromes, and secondly, genetic forms of FTD can present with the clinical features of other neurodegenerative disorders. It is common to assess people who turn out to have FTD, but initially have a 'halo' presentation with atypical clinical features (**Figure 1**). Two key syndromes are often seen: firstly, those with a neuropsychiatric presentation (e.g. with

prominent features of psychosis as described above);[7] and secondly, prominent amnestic symptoms, with only mild behavioural change that becomes prominent later on.[13] One important amnestic group to recognize are those with specific mutations in the microtubule associated protein tau (*MAPT*) gene including V337M, Q351R and R406W who may look very much like Alzheimer's disease dementia initially, although often then have a slowly progressive degenerative disorder with later prominent behavioural symptoms +/- parkinsonism.[13] This group also has similar tau pathology as seen in AD (although without the amyloid) and so can have strongly positive tau PET imaging.[14]

Although separate core and supportive clinical criteria have been defined for each of the PPA variants,[15] on a clinical basis it can still be challenging to differentiate them among themselves, and from psychiatric presentations or stroke syndromes. Moreover, the presentation of these variants is not always 'pure' as described in the clinical criteria. In particular, mixed phenotypes or expanded clinical phenotypes occur in cases with underlying Alzheimer's disease.[16] In these instances, linguistic examination and determination of Alzheimer's disease biomarkers might be useful.

Differential diagnosis of nfvPPA from the logopenic variant of PPA (lvPPA) relies largely on expert qualitative assessment of spontaneous speech, but classification of speech errors such as apraxia and phonological errors are notoriously difficult. Features which are quantifiable such as reading prosody,[17] as well as non-speech features such as working memory and visuospatial function[18] are therefore useful when classifying these patients.

One of the more controversial aspects of the PPA spectrum is the overlap and distinction between people with a primary progressive apraxia of speech (PPAOS, i.e. a motor speech disorder with no language problems)[19] and those with nfvPPA. Whilst many people develop features of both aphasia and apraxia of speech as the disease develops, there do seem

to be a small number of people who remain with either PPAOS without language impairment, or nfvPPA (usually with agrammatism predominantly) without motor speech problems, as the disease progresses.[20] Nonetheless, these may still be part of the same pathological spectrum, with many cases of both PPAOS or mixed PPAOS/nfvPPA having tau pathology such as PSP, CBD or Pick's disease at postmortem (and many developing additional parkinsonian disorders as the disease progresses).[21] Whether nfvPPA without apraxia of speech is separate pathologically remains to be understood.[22,23] Important to note is that there are a group of people who present with features of multiple FTD phenotypes at the same time with both bvFTD and a progressive aphasia at onset.[24]

Lastly, whilst people with FTD-causing mutations usually have a disorder within the FTD spectrum, there are a group of people that have genetic FTD with another phenotype.[13] For example, *C9orf72* expansions have been described with a Huntington's disease-like hyperkinetic disorder.[25]

Characterizing the left vs right temporal predominant variants of FTD

The term primary progressive aphasia emphasizes the predominant language presentation in the first few years of the disorder. The atrophy pattern in svPPA consists of bilateral anterior temporal lobe atrophy, which is usually more prominent on the left. A mirror radiological variant with predominant right anterior temporal atrophy can present without aphasia, which has been termed the right temporal variant of FTD (rtvFTD; **Panel 1, Figure 2,**).[26,27] Its main clinical features are prosopagnosia, episodic memory impairment, and behavioural change.[26] Consensus criteria and nosology for this variant of FTD are still being refined.

The FTLD Proteinopathies

The primary proteinopathies associated with the FTLD-spectrum disorders include tau (often termed the "tauopathies"), TAR DNA binding protein 43 (TDP-43) proteinopathies, and the FET related proteins (**Appendix 1**).[28] It is worth emphasizing that while clinicians typically attempt to predict the single most likely proteinopathy that most likely underlies any particular patient's dementia syndrome, a significant minority of patients have two or more proteinopathies identified at autopsy.[29]

Limbic-predominant age-related TDP-43 encephalopathy (LATE) is a recently-characterized entity, in which stereotypical TDP-43 protein inclusions are present with or without coexisting hippocampal sclerosis; these histologic findings represent LATE neuropathologic change (LATE-NC).[30] The typical clinical presentation of LATE is an amnestic dementia syndrome, and the prevalence appears to increase with increasing age. Whether LATE is a distinct disease entity separate from FTLD with TDP-43 pathology is controversial; see Josephs *et al*. for more details on key controversies.[31]

Accurate and Early Diagnosis

Prodromal FTLD

While the presence of an overt FTLD-spectrum disorder phenotype can be defined based on established criteria, there are no such criteria for the prodromal FTLD-spectrum disorders except for PSP.[32] One would predict that the prodromal features of the major FTLD syndromes would be subtle/mild changes in one or more of the core features of each syndrome. For bvFTD, mild changes in behavior, personality, or comportment without major changes in social/occupational functioning would be expected. Similarly, a change in speech/language functioning would be expected in those with evolving PPA. However, as

described above, there are individuals with evolving FTD who present with atypical cognitive or behavioral manifestations such as anterograde memory impairment, or changes in complex visual processing (i.e., visual agnosia), or psychosis. Others exhibit changes in motor functioning such as parkinsonism or limb apraxia or monomelic motor neuron disease findings without any cognitive or behavioral changes.[33]

One framework that can be applied to FTLD-spectrum disorders expands the concept of mild cognitive impairment (MCI) to include the concepts/terms of mild behavioral impairment (MBI) and mild motor impairment (MMI) (**Figure 3**). Each term is intended to represent the intermediate clinical stage between normal aging and an overt neurodegenerative phenotype. Each designation requires that clinical manifestations represent a change from a premorbid state and prior level of functioning.

Characterizing prodromal FTLD is complicated by the clinical variability inherent in the FTLD-spectrum disorders, with cognitive, behavioral and motor manifestations that are heterogenous within and across individuals. Furthermore, considering that clinical diagnosis is often delayed in sporadic FTD syndromes, the most practical approaches to characterize prodromal FTLD would be 1) to evaluate asymptomatic and minimally symptomatic mutation carriers among familial FTD kindreds in a longitudinal and comprehensive manner (see natural history cohorts below), and 2) identify and analyze sporadic cases which were recognized very early in their clinical course and evaluated prospectively in a similar manner as described above.

The conceptual framework presented herein is one perspective on characterizing prodromal FTLD, and more discussion will likely be required to develop consensus on the finer details of the core features under each domain and precise terminology.

Novel clinical and neuropsychological measures

The typical cognitive/neuropsychological profiles for key FTD syndromes are outlined in **Panel 1**.

Behavioral variant FTD. With respect to the neuropsychological profile, the bvFTD diagnostic criteria emphasise executive dysfunction with relative sparing of episodic memory and visuospatial ability, and this profile has been supported by more recent cross-sectional and longitudinal analyses.[2,34-36] For executive function, growing evidence indicates that tests which tap ventromedial prefrontal cortex function, such as error sensitivity,[37] verbal fluency,[37] inhibition,[38] as well as decision-making and neuroeconomics derived tasks[39] are more sensitive than dorsolateral prefrontal tasks such as cognitive control and attention.[37] Episodic memory performance is variable. A recent meta-analysis reported large memory deficits in bvFTD compared to controls, albeit to a lesser extent than seen in AD.[40] Memory also declines with disease progression[41]. Measures of learning and recall[40] as well as spatial memory[42] may be better at differentiating between bvFTD and AD. With respect to visuospatial ability, drawing and spatial orientation,[43] and may be useful in discriminating between these diagnoses. Some studies have also highlighted praxis as potentially useful.[44] Given the distinct cognitive profile of bvFTD, neuropsychological assessment therefore plays an important role in diagnosis.

Assessment of the behavioural features of bvFTD (i.e., apathy, disinhibition, stereotypical behaviours and changes in eating behaviour) has largely been based on clinical interview, and while recent analyses support this approach is data collection,[2] it can be influenced by the availability and knowledge of an informant and patient insight. Therefore, the development of reliable, valid and objective measures is needed to complement the clinical interview; many of these measures assess social cognition (**Appendix 2**).

Primary progressive aphasia. Differential diagnosis of the PPA variants is important to provide potential insight into underlying pathology, as well as the nature and likely progression of deficits. A number of neuropsychological tests have been developed which are tailored for PPA (See Henry & Grasso, 2018 [45] for recent comprehensive review). In addition to purposely designed aphasia batteries (e.g., Sydney Language Battery; Progressive Aphasia Severity Scale), tests which assess non-verbal semantic knowledge (e.g., Repeat and Point Test), word repetition and picture naming are useful. Irregular word reading, word-picture matching and tests of semantic association are more impaired in svPPA than nfvPPA.[36] Conversely, sentence reading, sentence ordering and aspects of dictation are more impaired in nfvPPA.[46] Efforts to objectively assess syntax and grammar (e.g., Test for Reception of Grammar, Northwestern Anagram Test) can be useful in detecting nfvPPA, but patients with lvPPA may also be impaired due to working memory deficits. Agrammatism may also be elicited during writing tasks (e.g., picture description tasks).

Undoubtedly, while there has been rapid development of new clinical assessment tools under clinical characterization of these disorders, translation into clinical practice remains a substantial hurdle. Distinction from healthy controls and differentiation between groups is typically demonstrated at the group level, however, diagnostic accuracy (i.e., sensitivity and specificity at the individual level) is essential for clinical assessment. Normative data for novel experimental tools are scant, and rarely consider cultural differences. Moreover, many of these tests will require further iterations (e.g., short versions, practical considerations for psychophysiological and behavioral assessment approaches) before they are clinic-ready.

Biomarkers

Blood proteins. In the last decade, neurofilament light chain (NfL) has become a biomarker of interest in FTLD, since it is a sensitive marker of neurodegeneration and its levels are correlated with the rate of clinical progression and therefore with prognosis.[47-51] NfL levels in plasma correlate well with those in CSF.[47,50] Compared to various other diseases in which NfL levels are increased, levels in FTLD as a group are relatively high, but it must be taken into account that there is still overlap with controls.[52] A few recent studies have highlighted the use of NfL as a biomarker in the distinction between bvFTD and primary psychiatric disorders with areas under the curve between 0.84 and 0.94.[53,54] Although replication on a larger scale is needed, plasma NfL may become increasingly used in clinical practice when it comes to this particular differential diagnostic dilemma. NfL has recently been shown to predict future clinical progression during the prodromal stages of genetic FTD.[51] This has led to its use in clinical trials as a method of inclusion for presymptomatic carriers. Plasma measures of phosphorylated tau at residues 181 or 217 have comparable diagnostic accuracy to amyloid PET or CSF measures for the differential diagnosis from AD, and these may eventually supplant these biomarkers for clinical diagnosis.[49,55]

Cerebrospinal fluid (CSF). There are a growing number of CSF markers that are or may be useful in FTD. NfL in the CSF is elevated in FTD, but levels do not differentiate FTLD from non-FTLD pathology, nor do they distinguish the different proteinopathies in FTLD.[47,49,50] However, CSF NfL increases with disease progression in FTLD,[56] underscoring its potential use as a biomarker of neurodegeneration in therapeutic trials. While total tau and beta-amyloid levels are not sensitive or specific for any of the FTLD-spectrum proteinopathies, elevated phosphorylated tau levels in either CSF or plasma are useful for ruling out AD as a cause of FTD.[49,55] Of particular interest is the development of CSF assays which can detect markers of key proteinopathies in FTLD. Recent data on TDP-43 real-time

quaking induced conversion (RT-QuIC) seeding activity in CSF of ALS and FTD patients appears encouraging.[57] Truncated stathmin-2 was recently identified as a marker for TDP-43 dysfunction in FTD based on analyses of tissue,[58] and RT-QuIC seeding activity of tau in tissue AD and FTLD-tau brains[59] has also shown promise. Whether levels of truncated stathmin-2 and RT-QuIC seeding assays for TDP-43 and tau in antemortem CSF will be predictive of TDP-43 vs tau pathology in humans requires further study.

Genetic testing. Genetic testing (with pre- and post-test counseling in appropriate individuals) for the known gene mutations is reasonable in those with FTD and a positive family history of dementia, parkinsonism or ALS. The genes worthy of testing include, but are not limited to, the so-called "big three of FTD" – *C9orf72*, *MAPT* and *GRN*.[13,60] It is well known, however, that family histories in *C9orf72* mutation carriers can be negative or ambiguous due to the large variation in clinical phenotype, including psychiatric and other atypical presentations.[61] Whether to perform genetic testing in those without a compelling family history is controversial, and should depend on individual circumstances and the testing parameters that are established in certain countries. As more clinical trials begin, and especially if one or more treatments are shown to be effective for any of the genetically-mediated FTLD-spectrum disorders, genetic testing will likely expand.

Structural brain imaging. Brain imaging is standard in the assessment of any individual with cognitive/behavioral changes and a neurologic etiology is suspected, and this is typically accomplished using brain MRI. Atrophy in the frontal and/or temporal lobes, which can be symmetric or very focal/asymmetric, supports the clinical suspicion of FTD. [3,15] However, as noted above, the absence of obvious atrophy does not preclude an underlying neurodegenerative disorder. Volumetric MRI analyses are valuable in the assessment of individuals with sporadic and familial FTD, particularly to inform clinical trial design.[34,62-66]

Functional brain imaging. FDG-PET is often used to support the clinical suspicion of FTD – particularly when brain MRI findings are not diagnostic. While the clinical and research utility of FDG-PET has been demonstrated,[63] the findings are not 100% sensitive or specific for an FTLD-spectrum disorder.

Molecular PET brain imaging. Amyloid PET imaging identifies those individuals with amyloid deposition in the brain, and can be used to differentiate underlying AD from non-AD disorders in those with FTD (realizing that the interpretation of findings is challenging in those presumably uncommon individuals with coexisting FTLD and AD pathology, which can usually only be discovered at autopsy).[67] Tau PET imaging was initially considered to be a potential major breakthrough in differentiating a tauopathy vs a non-tauopathy among those with an underlying FTLD-spectrum disorder, but this has not been borne out.[68] For example, the currently used tau ligands bind to tau filaments similar in structure to AD NFTs, which occurs in only a few of the *MAPT* mutations (e.g., V337M, R406W) but not in most other *MAPT* mutations nor in the other primary tauopathies.[14,68] Furthermore, there is off-target binding that can lead to false-positive tau PET scans in those with non-tauopathies.[68,69] Therefore, the current first-generation tau ligands do not have sufficient clinical or research utility in FTD. Other ligands for tau as well as TDP-43 and other non-AD proteins are being vigorously developed and studied.

Current State of Management/Treatment

Early and accurate clinical diagnosis is essential to ensure appropriate management and treatment (as this becomes available). An accurate diagnosis and information about likely prognosis is also often invaluable to family members and carers who often experience disproportionate stress and burden.[10] Patient evaluations should consider potential risks to the

patient and or community. Patients with bvFTD often lack the capacity to avoid danger, due to disinhibition, apathy, and poor understanding of the internal state of others. Although they rarely exhibit violent behaviors, FTD patients are at risk of physical or financial victimization due to their impairments in social cognition. Of these concerns, driving safety and home firearms are also among the most urgent safety concerns. Suicide ideation is rare but should be considered in individuals with good insight or concurrent psychological distress (e.g., issues around adjustment, anxiety and depression). Several nonpharmacologic interventions for managing problematic FTD features[70-77] are shown in **Panel 2**.

Treatment Trials and Future Planning

Trials in progress or planned

Most current therapeutic programs target autosomal dominant forms of FTLD including *C9orf72* repeat expansions, *GRN* or *MAPT* mutations. A small number of programs have targeted sporadic forms of FTLD-tau, most commonly PSP. A summary of trials is shown in the **Table**.

Progranulin Deficiency. Patients with heterozygous loss of *GRN* function mutations develop FTD due to progranulin haploinsufficiency, and several clinical trials have sought to measure the pharmacodynamic effects of therapeutic interventions on raising progranulin levels in the blood and CSF. The calcium channel blocker nimodipine failed to raise progranulin levels in participants with *GRN* haploinsufficiency enrolled in an 8-week, open-label trial.[78] Histone deacetylase (HDAC) inhibitors substantially increase progranulin transcription, but the HDAC inhibitor FRM-0334 failed to raise plasma progranulin levels in participants with *GRN* haploinsufficiency enrolled in a double-blind placebo controlled trial (NCT02149160). More encouraging results have been observed in clinical trials of AL001, a

monoclonal antibody targeting sortilin, a protein central to the degradation of progranulin. A phase 3 trial of AL001 for progranulin deficiency is now underway (NCT04374136), which requires an elevated Nfl level for inclusion in the asymptomatic mutation carrier arm of the protocol. Two pharmaceutical companies have announced progranulin gene therapy programs using adeno-associated virus (AAV) vector therapies, including the AAV1-based PBFT02 (NCT04747431) and the AAV9-based PR006 (NCT04408625). Additionally, DNL593, a peripherally administered recombinant progranulin protein, modified to cross the blood-brain barrier has been announced as an imminent clinical trial candidate.[79]

C9orf72. A variety of pathogenic mechanisms have been proposed for *C9orf72* repeat expansion toxicity, including toxic inclusions of abnormally expanded RNA, toxic gain of function from dipeptides abnormally transcribed from the expanded RNA, and haploinsufficiency.[80,81] One approach for targeting C9orf72 expansion is suppression of the abnormally expanded RNA transcript using antisense oligonucleotides (ASOs). ASOs require intrathecal infusion, but they offer diverse and highly specific mechanisms to target discrete C9orf72 RNA transcripts. So far, clinical therapeutic trials of intrathecal ASOs designed to target expanded C9orf72 transcripts (including BIIB078 and *afinersen*) have only occurred in patients with an ALS phenotype. BIIB078 is currently being investigated in a phase 1 trial enrolling patients with ALS (NCT03626012). While both of these clinical programs have so far excluded patients with cognitive or behavioral features of *C9orf72* expansion, they provide the opportunity to establish biological proof of concept (eg, reduction of C9orf72 dipeptide repeats in CSF which has been reported for afinersen) that may lay the foundation for future trials *C9orf72*-related FTD. Aside from ASO therapies, the anti-sortilin antibody AL001 is also being explored in a phase 2 trial in symptomatic *C9orf72* expansion carriers, in an effort

to investigate the impact of increasing progranulin levels in other FTLD-TDP cohorts (NCT03987295).

FTLD-Tau. A multitude of potential therapies are currently under consideration for treatment of FTLD-tau, and given the importance of tau pathology in Alzheimer's disease, a number of clinical trials in FTLD-tau have sought to repurpose therapies from Alzheimer's development pipelines. Potential therapeutic mechanisms include enhancement of tau clearance, suppression of the prion-like behavior of toxic tau molecules, mitigation of toxic loss of microtubule function, suppression of tau production, augmentation of mRNA splicing, and augmentation of tau post translational modifications.[82]

Passive immunization, using anti-tau monoclonal antibodies, is a potential modality to improving tau clearance and suppress the spread of self-templating forms of tau (ie, prion like tau). It is not yet clear what epitopes are most important different tauopathies, and a multitude of potential therapeutic targets are being explored in trials, including antibodies against specific tau fragments (e.g. the N-terminal, proline rich, microtubule binding domain, or c-terminal regions of tau) as well as specific hyperphosphorylated forms of tau, specific confirmations of misfolded tau, monomeric tau, and oligomeric tau. In two well-powered phase 2 trials, antibodies directed against N-terminal tau epitopes (BIIB092, ABBV-8E12) failed to impact the rate of clinical progression in patients with PSP (NCT03413319, NCT03068468). Moreover, termination of Biogen's BIIB092 program in PSP led to an early termination in the phase 1 basket trial of BIIB092, enrolling patients with CBS, nfvPPA, *MAPT*-mutations, and traumatic encephalopathy (NCT03658135). Newer antibodies target different regions or three dimensional conformations of tau, with the hope that those that bind closer to the tau aggregation domains may be more efficacious.[83] While it is unclear how well

each of these antibodies can engage tau in different forms of tau pathology, they present a theoretical opportunity for additional therapeutic trials in FTLD-tau.

Active immunization strategies are a less explored pathway for tau therapy, but offer the potential benefits of decreased treatment burden and generation of multiple antibodies against a variety of epitopes. The AADvac1 vaccine (containing tau peptide aa 294-305/4R) has been shown to be safe and well tolerated in an open label trial enrolling patients with AD[84] and has subsequently been investigated in a phase 1 trial enrolling patients with nfvPPA (NCT03174886) although results have not yet been reported.

Direct augmentation of tau expression remains relatively unexplored in FTLD development pipelines, but ASOs offer a diverse range of methods to impact the expression of tau. In non-human primates, intrathecal infusions of an ASO that knocks down tau expression, BIIB080 (IONIS-$MAPT_{Rx}$)**,** were well tolerated and led to a 75% reduction of MAPT mRNA in the cortex.[85] Currently BIIB080 is only being investigated in clinical trials enrolling patients with mild Alzheimer's disease (NCT03186989), and it may provide a viable mechanism to suppress tau pathology in FTLD-tau.

Oxytocin. There were encouraging results in a recent study using intranasal oxytocin in FTD,[86] and a phase 2 trial that is currently in progress (NCT01386333).

Transcranial stimulation. Transcranial DC stimulation is being studied in FTLD-GRN (NCT02999282), and transcranial magnetic stimulation is being studied in PPA and bvFTD (NCT03406429).

Natural history study cohorts

In recent years there has been a move from small single site observational studies to large multicentre natural history cohorts of FTD. The Genetic FTD Initiative (GENFI) is a

European and Canadian study focused on both presymptomatic and symptomatic genetic forms of FTD (www.genfi.org). This cohort has recruited over 1100 participants over the last nine years with a focus on developing robust biomarkers of disease onset and progression in genetic FTD. Important work from this group includes the identification of presymptomatic imaging changes[87] as well as changes in key fluid biomarkers such as NfL[48] and GFAP.[88] The Advancement in Research and Treatment in Frontotemporal Lobar Degeneration (ARTFL; focused on sporadic and familial FTLD) and Longitudinal Evaluation of Familial Frontotemporal Dementia Subjects (LEFFTDS; focused on familial FTLD) both began enrolling participants in 2014. The efforts in both programs were combined as part of the ARTFL LEFFTDS Longitudinal Frontotemporal Lobar Degeneration (ALLFTD; www.allftd.org) Consortium which involves 19 sites in North America and includes over 1500 participants evaluated thus far.[2,34,89] The Dominantly Inherited Non-Alzheimer Dementias (DINAD) program in Australia, the New Zealand Genetic FTD (FTDGeNZ) study and Research Dementia Latin America (ReDLAT; www.lac-cd.org/en/proyects/) study have also built FTD cohorts, and together with GENFI and ALLFTD, have come together to form the FTD Prevention Initiative (FPI; www.thefpi.org). The aim of the FPI is to bring together a worldwide cohort of familial FTD, with a minimum shared dataset that is collected across all participants, helping to compare and contrast a more diverse set of patients with FTD. The addition of cohorts from Asia (e.g. within Japan, South East Asia and Korea) to the FPI will allow comparison of geographical frequency, with genetic FTD occurring at much lower rates in some regions. Overall, the overarching aim of the FPI is to work together with industry to promote clinical trials of new therapies that might prevent FTD: creation of an international database of participants eligible for trials and uniform standards for conducting such trials will be the first steps in this process.

Conclusions

The major achievements in FTD research over the last decade include the formation of large (inter)national study cohorts, enabling us to identify the earliest clinical, biomarker, and neuroimaging changes in presymptomatic mutation carriers and to define intermediate stages between onset of symptomatology and overt FTD. It is encouraging that various drug trials have been initiated, in particular aimed at the genetic forms of FTD. We have learned about the clinical spectrum associated with the common autosomal dominant mutation in the *C9orf72* gene, which will hopefully lead to a better detection of FTD among patients with a psychiatric presentation. Finding biomarkers that predict the underlying FTLD pathology, after years of research, remains an ongoing quest and would represent an enormous breakthrough with respect to diagnostic specificity, treatment development and disease monitoring.

Contributors

All authors contributed to the review of the literature, writing of the initial draft, and manuscript editing and revision.

Acknowledgments

Supported by grants NIH grants AG063911 (BFB, ALB), AG045390 (BFB, ALB), NS092089 (BFB, ALB), AG038791 (BFB, ALB), AG062677 (BFB), AG052943 (BFB), U24AG057437 (ALB), Rainwater Charitable Foundation (ALB), Bluefield Project to Cure FTD (ALB), Association for Frontotemporal Degeneration (ALB), University of California Cures AD Program (ALB), NHMRC Career Development Fellowship GNT1158762 (FK), MRC MR/M008525/1; MR/M023664/1 (JR), NIHR BRC149/NS/MH (JR), JPND 2019-02248 (JR).

We thank our many colleagues with whom we collaborate on clinical and research activities in FTD. We particularly thank our patients and families for participating in FTD research.

Figure Legends

Figure 1. The core and halo of clinical presentations within the FTLD pathological spectrum

The core syndromes are shown in blue. The syndromes shown in green represent overlap syndromes within the FTD spectrum, and those depicted in red represent clinical presentations classically outside of the FTD spectrum.

Abbreviations: AD=Alzheimer's disease, ALS=amyotrophic lateral sclerosis, bvFTD=behavioral variant frontotemporal dementia, CBS=corticobasal syndrome, FTD-ALS=frontotemporal dementia plus amyotrophic lateral sclerosis, HD=Huntington's disease, nfvPPA=nonfluent variant primary progressive aphasia, PD=Parkinson's disease, PPA=primary progressive aphasia, PPAOS=primary progressive apraxia of speech, PSP=progressive supranuclear palsy, rtvFTD = right temporal variant FTD, svPPA=semantic variant primary progressive aphasia. The term semantic dementia here is used to describe a syndrome where semantic impairment is prominent initially – this can either be verbal (svPPA) or non-verbal/emotional (rtvFTD).

Figure 2. MRI characteristics in right temporal variant FTLD vs semantic variant PPA

A. Representative coronal T1-weighted images of a 70 year old male with behavioral changes, prosopagnosia and naming difficulties, showing marked right anterior temporal lobe atrophy; these clinical and imaging findings are typical of the right temporal variant of frontotemporal lobar degeneration. **B**. Representative coronal T1-weighted images of a 64 year old female with fluent but empty speech and marked dysnomia, showing the marked left anterior temporal lobe atrophy; these clinical and imaging findings are typical of the semantic variant of primary progressive aphasia.

Abbreviations: L-left, R-right

Figure 3 – Conceptual Framework of Prodromal FTLD

A. Prodromal FTLD represents the intermediate state between normal neurologic functioning and an overt FTLD-spectrum clinical syndrome, with each of the prodromal states intending to reflect a change from baseline yet activities of daily living are largely preserved. The MCI state represents the classic decline in one or more cognitive domains. The MBI state represents a change in personality/behavior/comportment including but not limited to two or more of the features described. The MMI state represents a change in decline in motor functioning, with elements of extrapyramidal dysfunction, upper motor neuron disease dysfunction, lower motor neuron disease dysfunction, or some combination of these. Each prodromal phase is intended to have elements of overlap with normal neurologic functioning on the mild end (reflecting the challenges differentiating normal vs very mildly abnormal) and overt FTLD on the more severe end (reflecting the challenges differentiating mildly abnormal vs an overt clinical syndrome). **B**. The diagram is intended to reflect the overlap in cognitive and behavioral features, behavioral and motor features, cognitive and motor features, or cognitive and behavioral and motor features that certain individuals exhibit in this prodromal FTLD state. **C**. Among those destined to develop an overt FTLD spectrum disorder, which prodromal state is exhibited while likely predict which eventual overt disorder will evolve, with some degree of variability. MCI is hypothesized to most likely evolve into bvFTD or PPA (with the language predominant form of MCI undoubtedly evolving into PPA moreso than bvFTD), whereas MBI is hypothesized to most likely evolve into bvFTD +/- ALS, and MMI is hypothesized to most likely evolve into CBS or PSP/RS or ALS (the hypothesized likelihood of evolution is reflected by the weighting of the lines).

Abbreviations: ALS-amyotrophic lateral sclerosis, bvFTD=behavioral variant frontotemporal dementia, CBS=corticobasal syndrome, FTD/ALS=frontotemporal dementia plus amyotrophic lateral sclerosis, MBI=mild behavioral impairment, MCI=mild cognitive impairment, MMI=mild motor impairment, PPA=primary progressive aphasia, PSP/RS=progressive supranuclear palsy/Richardson's syndrome

References

1. Bang J, Spina S, Miller B. Frontotemporal dementia. *Lancet* 2015; **386**: 1672-82.

2. Heuer HW, Wang P, Rascovsky K, et al. Comparison of sporadic and familial behavioral variant frontotemporal dementia (FTD) in a North American cohort. *Alzheimers Dement* 2020; **16**(1): 60-70.

3. Rascovsky K, Hodges JR, Knopman D, et al. Sensitivity of revised diagnostic criteria for the behavioural variant of frontotemporal dementia. *Brain* 2011; **134**: 2456-77.

4. Townley RA, Graff-Radford J, Mantyh WG, et al. Progressive dysexecutive syndrome due to Alzheimer's disease: a description of 55 cases and comparison to other phenotypes. *Brain Commun* 2020; **2**(1): fcaa068.

5. Falgas N, Sanchez-Valle R, Bargallo N, et al. Hippocampal atrophy has limited usefulness as a diagnostic biomarker on the early onset Alzheimer's disease patients: A comparison between visual and quantitative assessment. *Neuroimage Clin* 2019; **23**: 101927.

6. Swift IJ, Sogorb-Esteve A, Heller C, et al. Fluid biomarkers in frontotemporal dementia: past, present and future. *J Neurol Neurosurg Psychiatry* 2021; **92**(2): 204-15.

7. Snowden JS, Rollinson S, Thompson JC, et al. Distinct clinical and pathological characteristics of frontotemporal dementia associated with C9ORF72 mutations. *Brain* 2012; **135**(Pt 3): 693-708.

8. Abramzon YA, Fratta P, Traynor BJ, Chia R. The Overlapping Genetics of Amyotrophic Lateral Sclerosis and Frontotemporal Dementia. *Front Neurosci* 2020; **14**: 42.

9. Valente E, Caramelli P, Gambogi L, et al. Phenocopy syndrome of behavioral variant frontotemporal dementia: a systematic review. *Alz Res Ther* 2019; **11**(1): 1-15.

10. Ducharme S, Dols A, Laforce R, et al. Recommendations to distinguish behavioural variant frontotemporal dementia from psychiatric disorders. *Brain* 2020; **143**(6): 1632-50.

11. Pressman PS, Matlock D, Ducharme S. Distinguishing Behavioral Variant Frontotemporal Dementia From Primary Psychiatric Disorders: A Review of Recently Published Consensus Recommendations From the Neuropsychiatric International Consortium for Frontotemporal Dementia. *J Neuropsychiatry Clin Neurosci* 2021: appineuropsych20090238.

12. Schievink W, May aM, Barnard Z, et al. Behavioral Variant Frontotemporal Dementia as a Serious Complication of Spontaneous Intracranial Hypotension. *Oper Neurosurg* 2018; **15**(5): 505-15.

13. Moore KM, Nicholas J, Grossman M, et al. Age at symptom onset and death and disease duration in genetic frontotemporal dementia: an international retrospective cohort study. *Lancet Neurol* 2020; **19**(2): 145-56.

14. Jones DT, Knopman DS, Graff-Radford J, et al. In vivo (18)F-AV-1451 tau PET signal in MAPT mutation carriers varies by expected tau isoforms. *Neurology* 2018; **90**(11): e947-e54.

15. Gorno-Tempini ML, Hillis AE, Weintraub S, et al. Classification of primary progressive aphasia and its variants. *Neurology* 2011; **76**: 1006-14.

16. Louwersheimer E, Keulen MA, Steenwijk MD, et al. Heterogeneous Language Profiles in Patients with Primary Progressive Aphasia due to Alzheimer's Disease. *J Alzheimers Dis* 2016; **51**(2): 581-90.

17. Matias-Guiu JA, Suarez-Coalla P, Pytel V, et al. Reading prosody in the non-fluent and logopenic variants of primary progressive aphasia. *Cortex* 2020; **132**: 63-78.

18. Kamath V, Sutherland ER, Chaney GA. A Meta-Analysis of Neuropsychological Functioning in the Logopenic Variant of Primary Progressive Aphasia: Comparison with the Semantic and Non-Fluent Variants. *J Int Neuropsychol Soc* 2020; **26**(3): 322-30.

19. Botha H, Josephs KA. Primary Progressive Aphasias and Apraxia of Speech. *Continuum (Minneap Minn)* 2019; **25**(1): 101-27.

20. Tetzloff KA, Duffy JR, Clark HM, et al. Progressive agrammatic aphasia without apraxia of speech as a distinct syndrome. *Brain* 2019; **142**(8): 2466-82.

21. Seckin ZI, Duffy JR, Strand EA, et al. The evolution of parkinsonism in primary progressive apraxia of speech: A 6-year longitudinal study. *Parkinsonism Relat Disord* 2020; **81**: 34-40.

22. Mesulam MM, Weintraub S, Rogalski EJ, Wieneke C, Geula C, Bigio EH. Asymmetry and heterogeneity of Alzheimer's and frontotemporal pathology in primary progressive aphasia. *Brain* 2014; **137**(Pt 4): 1176-92.

23. Giannini LAA, Xie SX, McMillan CT, et al. Divergent patterns of TDP-43 and tau pathologies in primary progressive aphasia. *Ann Neurol* 2019; **85**(5): 630-43.

24. Murley AG, Coyle-Gilchrist I, Rouse MA, et al. Redefining the multidimensional clinical phenotypes of frontotemporal lobar degeneration syndromes. *Brain* 2020; **143**(5): 1555-71.

25. Ida CM, Butz ML, Lundquist PA, Dawson DB. C9orf72 Repeat Expansion Frequency among Patients with Huntington Disease Genetic Testing. *Neurodegener Dis* 2018; **18**(5-6): 239-53.

26. Ulugut Erkoyun H, Groot C, Heilbron R, et al. A clinical-radiological framework of the right temporal variant of frontotemporal dementia. *Brain* 2020; **143**(9): 2831-43.

27. Ulugut Erkoyun H, van der Lee SJ, Nijmeijer B, et al. The Right Temporal Variant of Frontotemporal Dementia Is Not Genetically Sporadic: A Case Series. *J Alzheimers Dis* 2021; **79**(3): 1195-201.

28. Neumann M, Mackenzie IRA. Review: Neuropathology of non-tau frontotemporal lobar degeneration. *Neuropathol Appl Neurobiol* 2019; **45**(1): 19-40.

29. Spina S, La Joie R, Petersen C, et al. Comorbid neuropathological diagnoses in early versus late-onset Alzheimer's disease. *Brain* 2021.

30. Nelson PT, Dickson DW, Trojanowski JQ, et al. Limbic-predominant age-related TDP-43 encephalopathy (LATE): consensus working group report. *Brain* 2019; **142**(6): 1503-27.

31. Josephs KA, Mackenzie I, Frosch MP, et al. LATE to the PART-y. *Brain* 2019; **142**(9): e47.

32. Boxer AL, Yu JT, Golbe LI, Litvan I, Lang AE, Hoglinger GU. Advances in progressive supranuclear palsy: new diagnostic criteria, biomarkers, and therapeutic approaches. *The Lancet Neurology* 2017; **16**(7): 552-63.

33. Estevez-Fraga C, Magrinelli F, Hensman Moss D, et al. Expanding the Spectrum of Movement Disorders Associated With C9orf72 Hexanucleotide Expansions. *Neurol Genet* 2021; **7**(2): e575.

34. Olney NT, Ong E, Goh SM, et al. Clinical and volumetric changes with increasing functional impairment in familial frontotemporal lobar degeneration. *Alzheimers Dement* 2020; **16**(1): 49-59.

35. Staffaroni AM, Bajorek L, Casaletto KB, et al. Assessment of executive function declines in presymptomatic and mildly symptomatic familial frontotemporal dementia: NIH-EXAMINER as a potential clinical trial endpoint. *Alzheimers Dement* 2020; **16**(1): 11-21.

36. Staffaroni AM, Weintraub S, Rascovsky K, et al. Uniform data set language measures for bvFTD and PPA diagnosis and monitoring. *Alzheimers Dement (Amst)* 2021; **13**(1): e12148.

37. Ranasinghe KG, Rankin KP, Lobach IV, et al. Cognition and neuropsychiatry in behavioral variant frontotemporal dementia by disease stage. *Neurology* 2016; **86**(7): 600-10.

38. Hughes LE, Rittman T, Robbins TW, Rowe JB. Reorganization of cortical oscillatory dynamics underlying disinhibition in frontotemporal dementia. *Brain* 2018; **141**(8): 2486-99.

39. Wong S, Irish M, O'Callaghan C, et al. Should I trust you? Learning and memory of social interactions in dementia. *Neuropsychologia* 2017; **104**: 157-67.

40. Poos JM, Jiskoot LC, Papma JM, van Swieten JC, van den Berg E. Meta-analytic Review of Memory Impairment in Behavioral Variant Frontotemporal Dementia. *J Int Neuropsychol Soc* 2018: 1-13.

41. Ramanan S, Bertoux M, Flanagan E, et al. Longitudinal Executive Function and Episodic Memory Profiles in Behavioral-Variant Frontotemporal Dementia and Alzheimer's Disease. *J Int Neuropsychol Soc* 2017; **23**(1): 34-43.

42. Tu S, Spiers HJ, Hodges JR, Piguet O, Hornberger M. Egocentric versus Allocentric Spatial Memory in Behavioral Variant Frontotemporal Dementia and Alzheimer's Disease. *J Alzheimers Dis* 2017; **59**(3): 883-92.

43. Salimi S, Irish M, Foxe D, Hodges JR, Piguet O, Burrell JR. Visuospatial dysfunction in Alzheimer's disease and behavioural variant frontotemporal dementia. *J Neurol Sci* 2019; **402**: 74-80.

44. Johnen A, Reul S, Wiendl H, Meuth SG, Duning T. Apraxia profiles-A single cognitive marker to discriminate all variants of frontotemporal lobar degeneration and Alzheimer's disease. *Alzheimers Dement (Amst)* 2018; **10**: 363-71.

45. Henry ML, Grasso SM. Assessment of Individuals with Primary Progressive Aphasia. *Semin Speech Lang* 2018; **39**(3): 231-41.

46. Harris JM, Saxon JA, Jones M, Snowden JS, Thompson JC. Neuropsychological differentiation of progressive aphasic disorders. *J Neuropsychol* 2019; **13**(2): 214-39.

47. Meeter LH, Dopper EG, Jiskoot LC, et al. Neurofilament light chain: a biomarker for genetic frontotemporal dementia. *Annals of clinical and translational neurology* 2016; **3**(8): 623-36.

48. van der Ende EL, Meeter LH, Poos JM, et al. Serum neurofilament light chain in genetic frontotemporal dementia: a longitudinal, multicentre cohort study. *Lancet Neurol* 2019; **18**(12): 1103-11.

49. Thijssen EH, La Joie R, Wolf A, et al. Diagnostic value of plasma phosphorylated tau181 in Alzheimer's disease and frontotemporal lobar degeneration. *Nat Med* 2020; **26**(3): 387-97.

50. Illan-Gala I, Lleo A, Karydas A, et al. Plasma Tau and Neurofilament Light in Frontotemporal Lobar Degeneration and Alzheimer Disease. *Neurology* 2021; **96**(5): e671-e83.

51. Rojas JC, Wang P, Staffaroni AM, et al. Plasma Neurofilament Light for Prediction of Disease Progression in Familial Frontotemporal Lobar Degeneration. *Neurology* 2021; **96**(18): e2296-e312.

52. Bridel C, van Wieringen WN, Zetterberg H, et al. Diagnostic Value of Cerebrospinal Fluid Neurofilament Light Protein in Neurology: A Systematic Review and Meta-analysis. *JAMA Neurol* 2019; **76**(9): 1035-48.

53. Eratne D, Loi SM, Walia N, et al. A pilot study of the utility of cerebrospinal fluid neurofilament light chain in differentiating neurodegenerative from psychiatric disorders: A 'C-reactive protein' for psychiatrists and neurologists? *Aust N Z J Psychiatry* 2020; **54**(1): 57-67.

54. Katisko K, Cajanus A, Jaaskelainen O, et al. Serum neurofilament light chain is a discriminative biomarker between frontotemporal lobar degeneration and primary psychiatric disorders. *J Neurol* 2020; **267**(1): 162-7.

55. Palmqvist S, Janelidze S, Quiroz YT, et al. Discriminative Accuracy of Plasma Phospho-tau217 for Alzheimer Disease vs Other Neurodegenerative Disorders. *Jama* 2020; **324**(8): 772-81.

56. Panman JL, Venkatraghavan V, van der Ende EL, et al. Modelling the cascade of biomarker changes in GRN-related frontotemporal dementia. *J Neurol Neurosurg Psychiatry* 2021.

57. Scialò C, Tran TH, Salzano G, et al. TDP-43 real-time quaking induced conversion reaction optimization and detection of seeding activity in CSF of amyotrophic lateral sclerosis and frontotemporal dementia patients. *Brain Commun* 2020; **2**(2): fcaa142.

58. Prudencio M, Humphrey J, Pickles S, et al. Truncated stathmin-2 is a marker of TDP-43 pathology in frontotemporal dementia. *J Clin Invest* 2020; **130**(11): 6080-92.

59. Tennant JM, Henderson DM, Wisniewski TM, Hoover EA. RT-QuIC detection of tauopathies using full-length tau substrates. *Prion* 2020; **14**(1): 249-56.

60. Ramos EM, Dokuru DR, Van Berlo V, et al. Genetic screening of a large series of North American sporadic and familial frontotemporal dementia cases. *Alzheimers Dement* 2020; **16**(1): 118-30.

61. Khan BK, Yokoyama JS, Takada LT, et al. Atypical, slowly progressive behavioural variant frontotemporal dementia associated with C9ORF72 hexanucleotide expansion. *J Neurol Neurosurg Psychiatry* 2012; **83**(4): 358-64.

62. Chen Q, Boeve BF, Senjem M, et al. Rates of lobar atrophy in asymptomatic MAPT mutation carriers. *Alzheimers Dement (N Y)* 2019; **5**: 338-46.

63. Bejanin A, Tammewar G, Marx G, et al. Longitudinal structural and metabolic changes in frontotemporal dementia. *Neurology* 2020; **95**(2): e140-e54.

64. Boxer AL, Gold M, Feldman H, et al. New directions in clinical trials for frontotemporal lobar degeneration: Methods and outcome measures. *Alzheimers Dement* 2020; **16**(1): 131-43.

65. Rosen HJ, Boeve BF, Boxer AL. Tracking disease progression in familial and sporadic frontotemporal lobar degeneration: Recent findings from ARTFL and LEFFTDS. *Alzheimers Dement* 2020; **16**(1): 71-8.

66. Staffaroni AM, Cobigo Y, Goh SM, et al. Individualized atrophy scores predict dementia onset in familial frontotemporal lobar degeneration. *Alzheimers Dement* 2020; **16**(1): 37-48.

67. Ghirelli A, Tosakulwong N, Weigand SD, et al. Sensitivity-Specificity of Tau and Amyloid beta Positron Emission Tomography in Frontotemporal Lobar Degeneration. *Ann Neurol* 2020; **88**(5): 1009-22.

68. Tsai RM, Bejanin A, Lesman-Segev O, et al. (18)F-flortaucipir (AV-1451) tau PET in frontotemporal dementia syndromes. *Alzheimers Res Ther* 2019; **11**(1): 13.

69. Makaretz SJ, Quimby M, Collins J, et al. Flortaucipir tau PET imaging in semantic variant primary progressive aphasia. *J Neurol Neurosurg Psychiatry* 2018; **89**(10): 1024-31.

70. Volkmer A, Rogalski E, Henry M, et al. Speech and language therapy approaches to managing primary progressive aphasia. *Pract Neurol* 2020; **20**(2): 154-61.

71. Henry ML, Hubbard HI, Grasso SM, et al. Treatment for Word Retrieval in Semantic and Logopenic Variants of Primary Progressive Aphasia: Immediate and Long-Term Outcomes. *J Speech Lang Hear Res* 2019; **62**(8): 2723-49.

72. Suarez-Gonzalez A, Savage SA, Caine D. Successful short-term re-learning and generalisation of concepts in semantic dementia. *Neuropsychol Rehabil* 2018; **28**(7): 1095-109.

73. Cotelli M, Manenti R, Ferrari C, Gobbi E, Macis A, Cappa SF. Effectiveness of language training and non-invasive brain stimulation on oral and written naming performance in Primary Progressive Aphasia: A meta-analysis and systematic review. *Neurosci Biobehav Rev* 2020; **108**: 498-525.

74. Henry ML, Hubbard HI, Grasso SM, et al. Retraining speech production and fluency in non-fluent/agrammatic primary progressive aphasia. *Brain* 2018; **141**(6): 1799-814.

75. Rogalski EJ, Khayum B. A Life Participation Approach to Primary Progressive Aphasia Intervention. *Semin Speech Lang* 2018; **39**(3): 284-96.

76. O'Connor CMC, Mioshi E, Kaizik C, Fisher A, Hornberger M, Piguet O. Positive behaviour support in frontotemporal dementia: A pilot study. *Neuropsychol Rehabil* 2020: 1-24.

77. Casaletto KB, Staffaroni AM, Wolf A, et al. Active lifestyles moderate clinical outcomes in autosomal dominant frontotemporal degeneration. *Alzheimers Dement* 2020; **16**(1): 91-105.

78. Sha SJ, Miller ZA, Min SW, et al. An 8-week, open-label, dose-finding study of nimodipine for the treatment of progranulin insufficiency from GRN gene mutations. *Alzheimers Dement (N Y)* 2017; **3**(4): 507-12.

79. Pipeline DT. https://www.denalitherapeutics.com/pipeline.

80. Todd TW, Petrucelli L. Insights into the pathogenic mechanisms of Chromosome 9 open reading frame 72 (C9orf72) repeat expansions. *J Neurochem* 2016; **138 Suppl 1**: 145-62.

81. Jiang J, Zhu Q, Gendron TF, et al. Gain of Toxicity from ALS/FTD-Linked Repeat Expansions in C9ORF72 Is Alleviated by Antisense Oligonucleotides Targeting GGGGCC-Containing RNAs. *Neuron* 2016; **90**(3): 535-50.

82. VandeVrede L, Boxer AL, Polydoro M. Targeting tau: Clinical trials and novel therapeutic approaches. *Neurosci Lett* 2020; **731**: 134919.

83. Sandusky-Beltran LA, Sigurdsson EM. Tau immunotherapies: Lessons learned, current status and future considerations. *Neuropharmacology* 2020; **175**: 108104.

84. Novak P, Schmidt R, Kontsekova E, et al. FUNDAMANT: an interventional 72-week phase 1 follow-up study of AADvac1, an active immunotherapy against tau protein pathology in Alzheimer's disease. *Alzheimers Res Ther* 2018; **10**(1): 108.

85. Mignon L, Kordasiewicz H, Lane R. Design of the first-in-human study of IONIS-MAPTRx, a tau-lowering antisense oligonucleotide, in patients with Alzheimer disease. *Neurology* 2018; **90**(**15 Supplement**): S2.006.

86. Oliver LD, Stewart C, Coleman K, et al. Neural effects of oxytocin and mimicry in frontotemporal dementia: A randomized crossover study. *Neurology* 2020; **95**(19): e2635-e47.

87. Rohrer JD, Nicholas JM, Cash DM, et al. Presymptomatic cognitive and neuroanatomical changes in genetic frontotemporal dementia in the Genetic Frontotemporal dementia Initiative (GENFI) study: a cross-sectional analysis. *The Lancet Neurology* 2015; **14**(3): 253-62.

88. Heller C, Chan E, Foiani MS, et al. Plasma glial fibrillary acidic protein and neurofilament light chain are measures of disease severity in semantic variant primary progressive aphasia. *J Neurol Neurosurg Psychiatry* 2020.

89. Boeve B, Bove J, Brannelly P, et al. The longitudinal evaluation of familial frontotemporal dementia subjects protocol: Framework and methodology. *Alzheimers Dement* 2020; **16**(1): 22-36.

Click here to access/download;Figure;FTLDupdateTLNFig1-corehalo.pptx

Figure 1. The core and halo of clinical presentations within the FTLD pathological spectrum

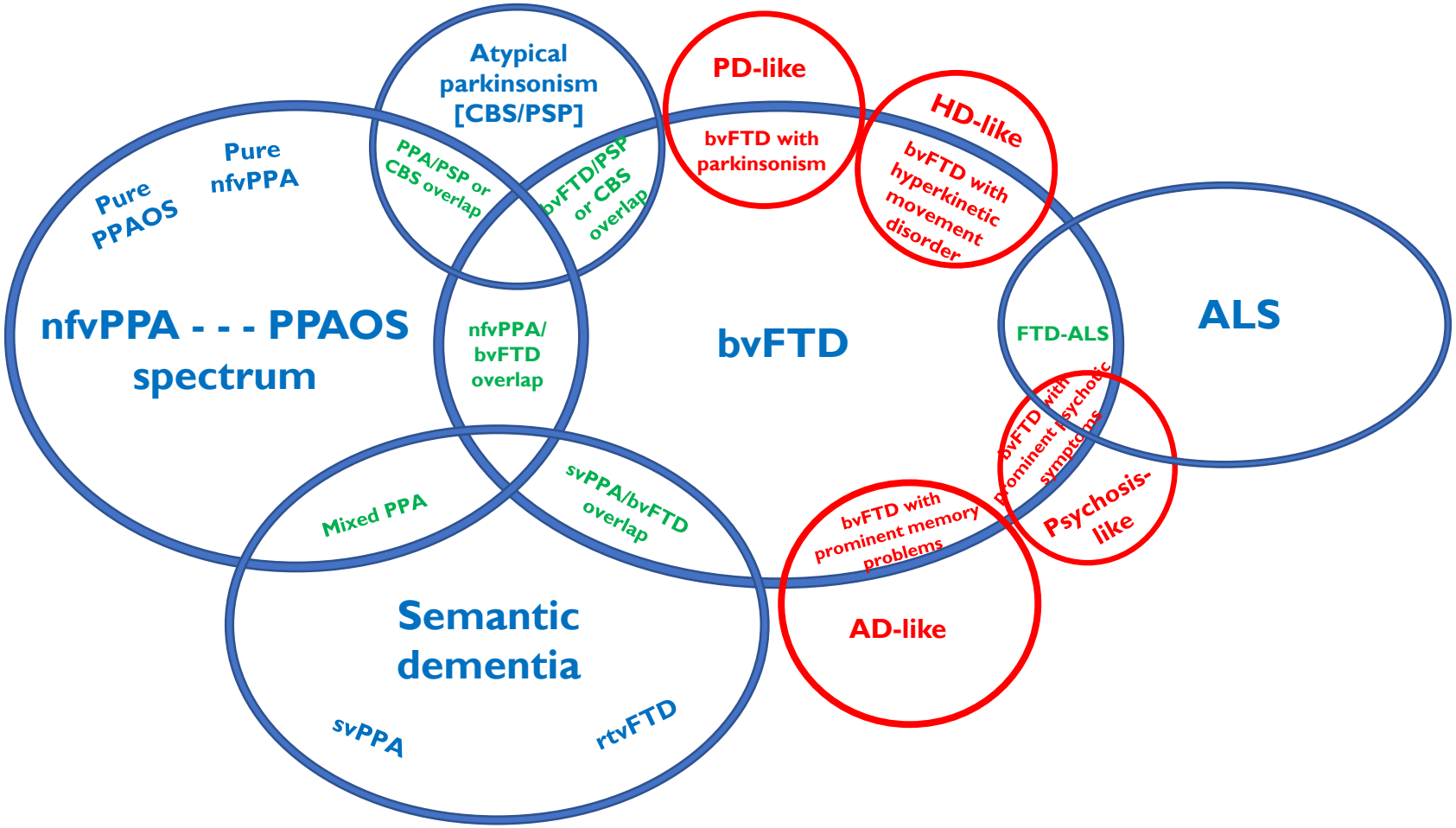

Click here to access/download;Figure;FTLDupdateTLNFig2Rev-RvsLtemporal.pptx

Figure 2. MRI characteristics in right temporal variant FTLD vs semantic variant PPA

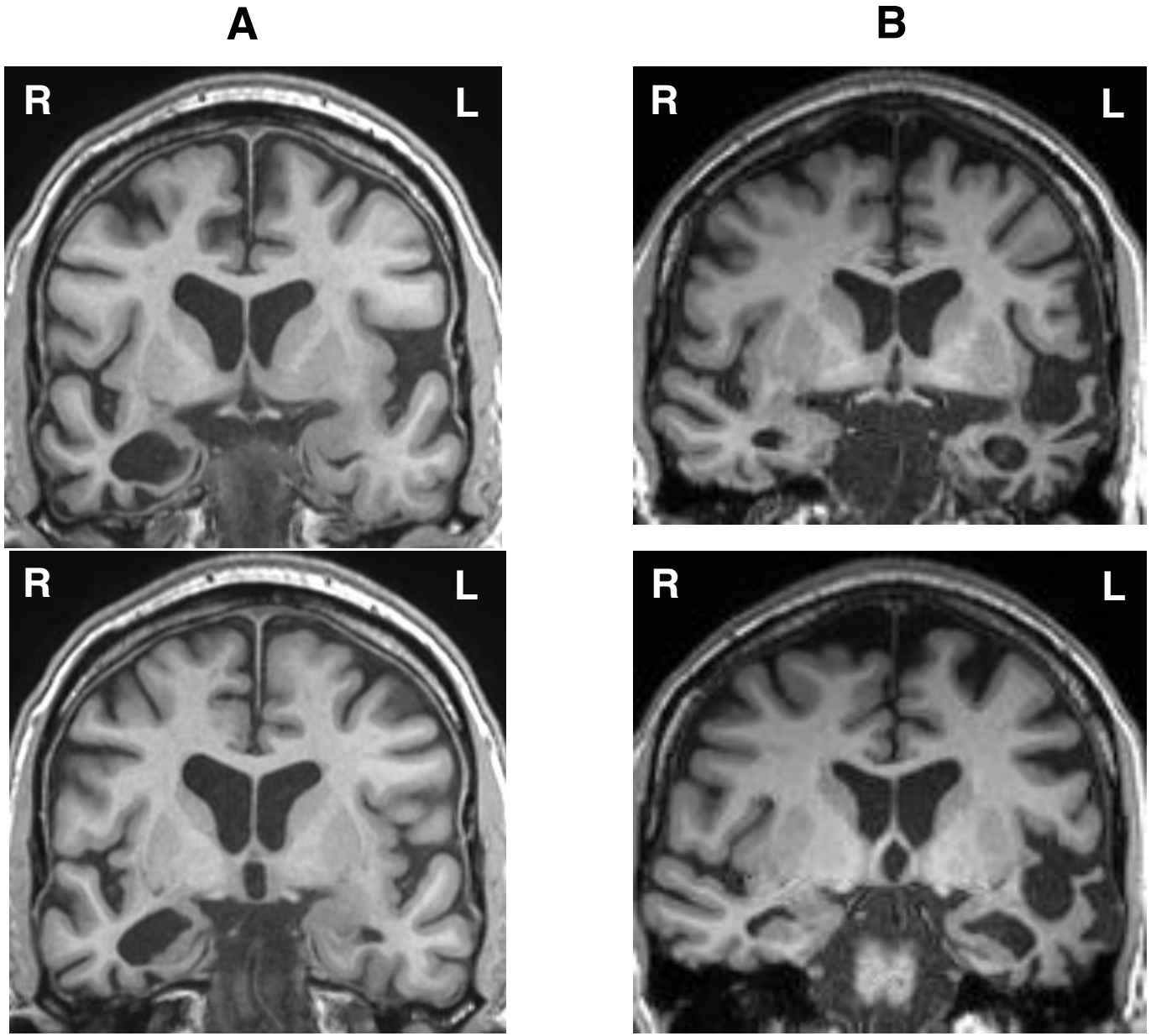

Click here to access/download;Figure;FTLDupdateTLNFig3Rev-Prodromal.pptx

Figure 3. Conceptual Framework of Prodromal FTLD

A

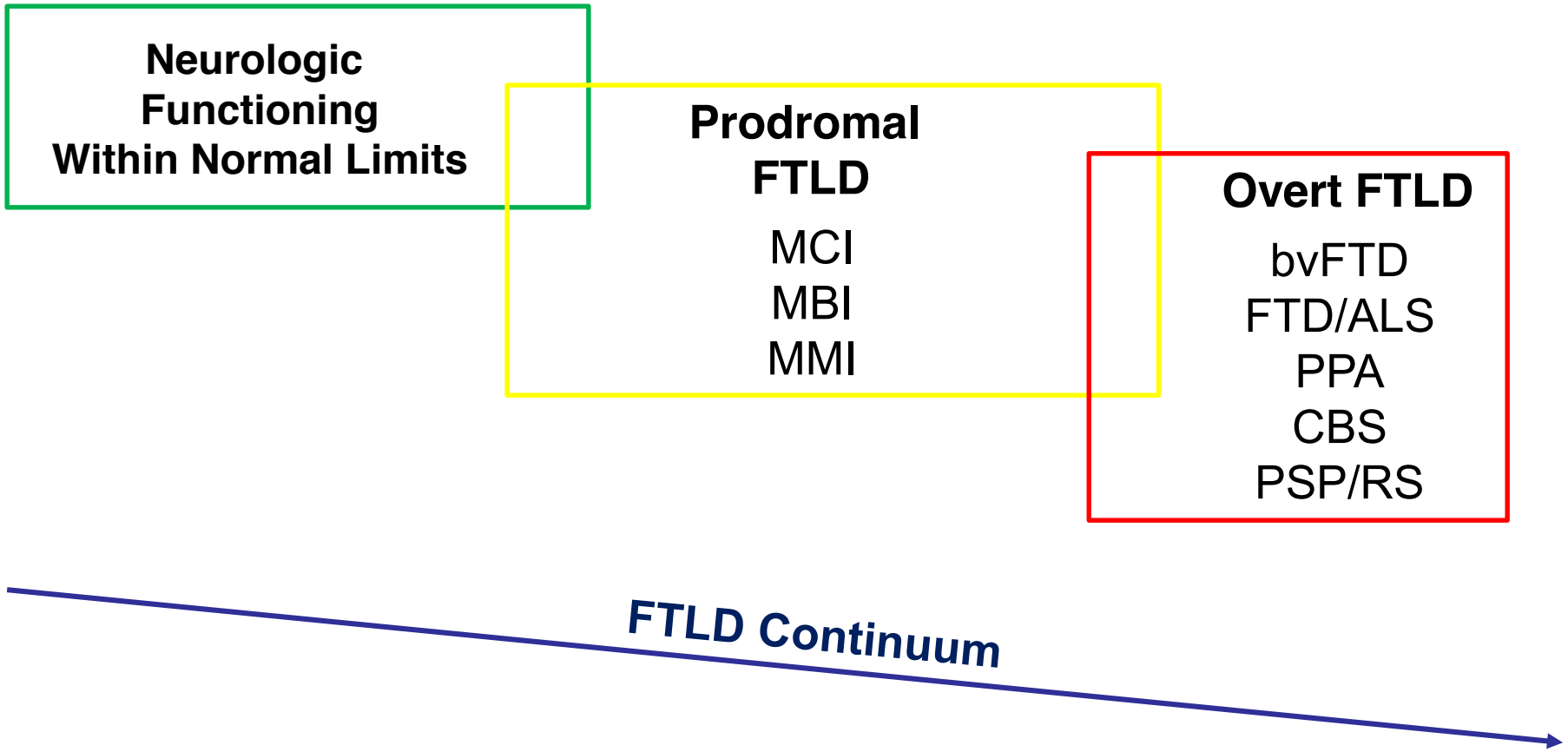

Figure 3. Conceptual Framework of Prodromal FTLD

B

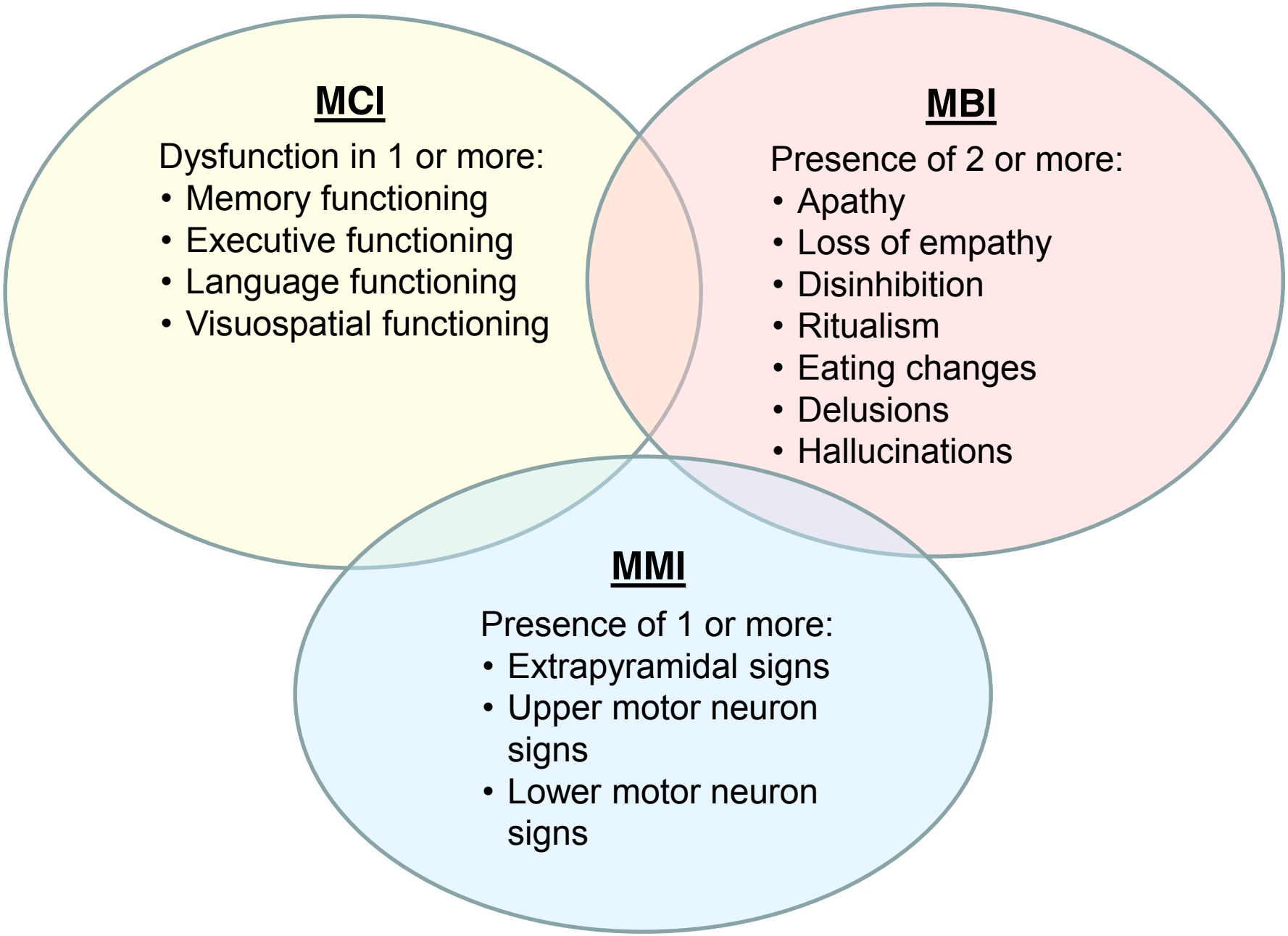

Figure 3. Conceptual Framework of Prodromal FTLD

C

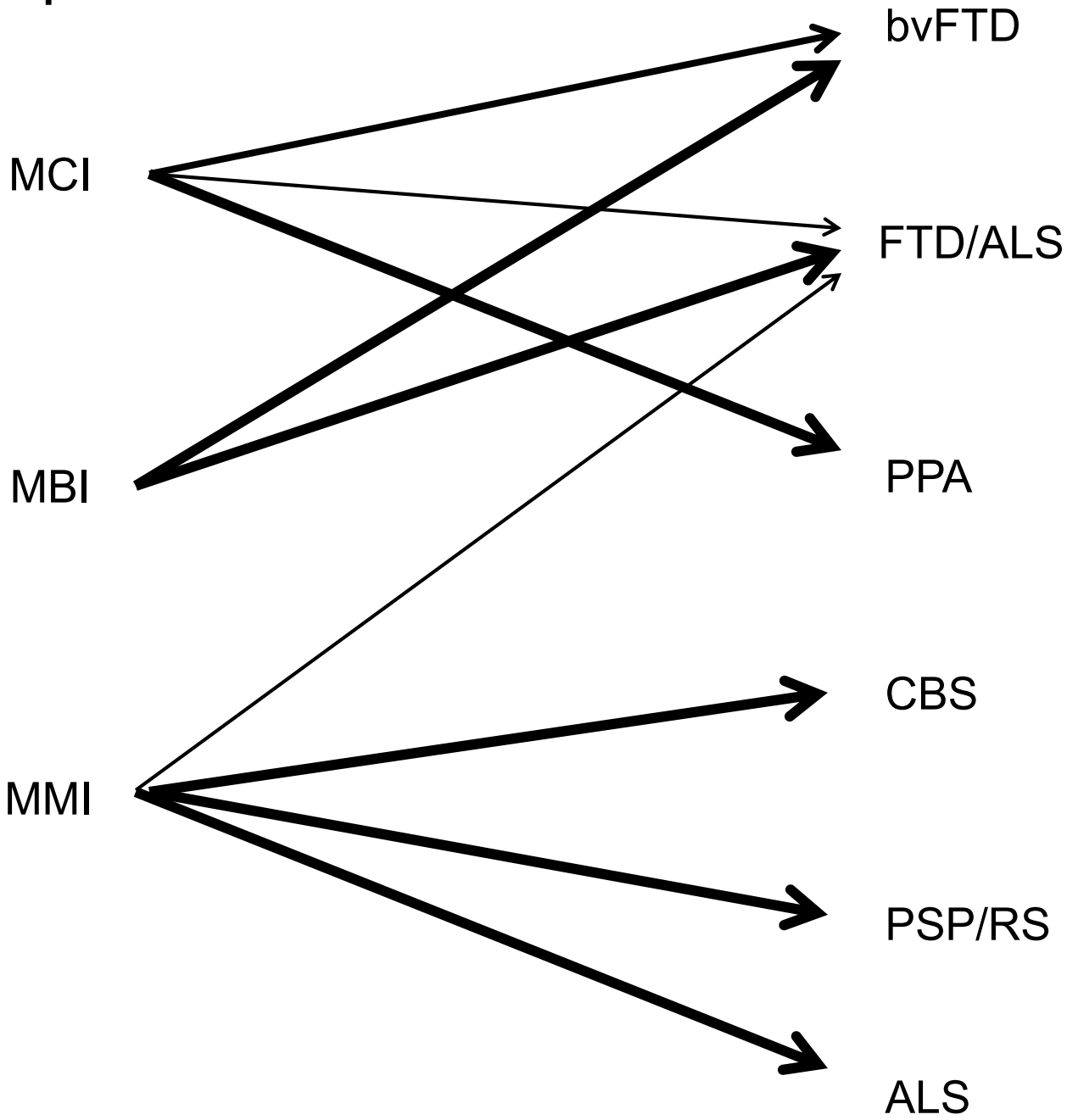

Table

Table. Potential Therapeutics in FTLD					
Agent	**Mechanism**	**Indication**	**Phase**	**ClinicalTrials.gov Identifier**	**Status**
Potential therapies for *GRN* Haploinsufficiency					
Nimodipine	Calcium channel blocker	FTLD-*GRN*	1	NCT01835665	negative
FRM-0334	HDAC inhibitor	FTLD-*GRN*	2	NCT02149160	negative
AL001	Anti Sortilin Antibody	FTLD-*GRN*	2/3	NCT03987295 NCT04374136	ongoing
PBFT02	AAV1-based gene therapy	FTLD-*GRN*		NCT04747431	pending
PR006	AVV9-based gene therapy	FTLD-*GRN*		NCT04408625	pending
Potential therapies for *C9orf72* Expansion					
BIIB078	ASO	ALS-*C9orf72*	1	NCT03626012	ongoing
AL001	Anti Sortilin Antibody	FTLD-*C9orf72*	2/3	NCT03987295 NCT04374136	ongoing
Potential Therapies for FTLD-tau					
ABBV-8E12 (C2N-8E12)	Anti-tau antibody (N-terminus)	PSP	2	NCT03413319	negative
BIIB092 (BMS-986168)	Anti-tau antibody (N-terminus)	PSP	2	NCT03068468	negative
		CBD, nfvPPA, TES, *MAPT*	1	NCT03658135	terminated
LY3303560	Anti-tau antibody (N-terminus)	AD	2	NCT03518073	active
RO 7105705 (RG 6100)	Anti-tau antibody (N-terminus)	AD	2	NCT03289143	active
UCB0107	Anti-tau antibody (Mid domain)	PSP	1	NCT04185415	active
JNJ-63733657	Anti-tau antibody (Mid domain)	AD	1	NCT03375697	unavailable
BIIB076	Anti-tau antibody (Monomer & filament)	AD	1	NCT03056729	active
AADvac1	Tau vaccine	nfvPPA	1	NCT03174886	active
TPI-287	Microtubule Stabilization	AD, PSP, CBD	I	NCT01966666, NCT02133846	negative
BIIB080	ASO	AD		NCT03186989	active
TRx0237 (LMTM)	Tau aggregation inhibition	bvFTD	3	NCT03446001	negative
ASN001	o- GlcNACase inhibitor	-	1	-	-
Salsalate	Tau acetylation inhibition	PSP	1	NCT02422485	negative
Lithium Carbonate	Glycogen synthase kinase inhibitor	bvFTD	2	NCT02862210	active

Young plasma transfusions	Alter peripheral cell signaling	PSP	1	NCT02460731	negative
Symptomatic FTLD Treatments					
Oxytocin	Augmenting social apathy	FTD	2	NCT01386333	active
Transcranial DC stim.	Electrical Current Stimulation	FTLD-*GRN*	N/A	NCT02999282	active
Transcranial magnetic stim.	Magnetic Field Stimulation	PPA, bvFTD	N/A	NCT03406429	active

Abbreviations: ALS-*C9orf72*, amyotrophic lateral sclerosis due to chromosome 9 open reading frame 72 expansion; AD, Alzheimer's disease; bvFTD, behavioral variant frontotemporal dementia; CBD, corticobasal degeneration; FTLD, frontotemporal lobar degeneration; FTLD-*GRN*, FTLD due to progranulin haploinsufficiency; *MAPT*; microtubule associated protein tau mutation; nfvPPA, non-fluent variant primary progressive aphasia; PPA, primary progressive aphasias; PSP, progressive supranuclear palsy; TES; traumatic encephalopathy syndrome.

Click here to access/download;Figure;FTLDupdateTLNAppendix1-

Appendix 1. The FTLD Proteinopathies

Among the tauopathies, there are six different tau isoforms generated by alternative splicing, with three of the isoforms being derived from splicing out exon 10 (yielding three repeat or 3R tau) and three of the isoforms including exon 10 (resulting in four repeat or 4R tau). The primary tauopathies can be subdivided into the 3R-predominant tauopathies, the 4R-predominant tauopathies and the mixed 3R/4R-tauopathies. The secondary tauopathies include AD and other disorders in which abnormal tau deposition is integral to the pathogenesis of the disorder, but not the primary driver of pathology. The primary tauopathies include Pick's disease (PiD), which has 3R-predominant tau pathology, the 4R tauopathies [i.e., progressive supranuclear palsy (PSP), corticobasal degeneration (CBD), argyrophilic grain disease (AGD), globular glial tauopathy (GGT),{Ahmed, 2013 #9046} and age-related tau astrogliopathy (ARTAG){Kovacs, 2016 #9051}], and the mixed 3R/4R tauopathies [i.e., primary age-related tauopathy (PART){Crary, 2014 #9048}]. FTLD associated with mutations in *MAPT* have 3R, 4R, or mixed 3R/4R tau pathology depending on the mechanism by which each mutation affects the tau isoforms. Alzheimer's disease (AD), chronic traumatic encephalopathy (CTE), the immunoglobulin-like cell adhesion molecule type 5 (IgLON5) encephalopathy{Gelpi, 2016 #9053} and other disorders have mixed 3R/4R tau pathology; these disorders represent the secondary tauopathies.

The original classification systems used in characterizing the neuropathologic findings in FTLD-TDP were harmonized into the system that is most widely used at present, in which the subtypes are based on the relative abundance of different types of TDP+ neuronal inclusions and their laminar distribution within the cerebral neocortex.{Mackenzie, 2011 #5518} Many of the genes associated with FTLD-TDP and/or amyotrophic lateral sclerosis (ALS) include *C9orf72*, superoxide dismutase 1 (*SOD1*), *GRN*, valosin-containing protein (*VCP*), transactive response DNA binding protein (*TARDBP*), TANK-binding kinase

1 (*TBK1*), among others. Perry syndrome is associated with mutations in dynactin-1 (*DCTN1*). Lewy body disease (LBD) and the polyglutamine expansion disorders (PG), as well as the primary tauopathies, AD and CTE can occur as mixed or secondary proteinopathies associated with TDP-43.

The other proteinopathies represent approximately 10% of the FTLD-spectrum disorders. The fused in sarcoma (FUS), Ewing sarcoma (EWS), and TATA-binding protein-associated factor 15 (TAF15) proteins comprise the FET protein family of disorders: basophilic inclusion body disease (BIBD), neuronal intermediate filament inclusion body disease (NIFID), and atypical FTLD with ubiquitin-positive inclusions (aFTLD-U). These disorders can be associated with mutations in fused in sarcoma (*FUS*). Other more rare proteinopathies include FTLD with inclusions labeled with markers of the ubiquitin/proteasome system (UPS) – often due to mutations in the charged multivesicular body protein 2B (*CHMP2B*) gene, hereditary diffuse leukoencephalopathy with spheroids (HDLS) associated with mutations in the colony stimulating factor 1 receptor (*CSF1R*) gene, and disorders with other genes. See{Neumann, 2019 #9045} for more details.

See associated figure.

Click here to access/download;Figure;FTLDupdateTLNAppendix1figure-proteinopathies.pptx

Figure in Appendix 1. The FTLD Proteinopathies

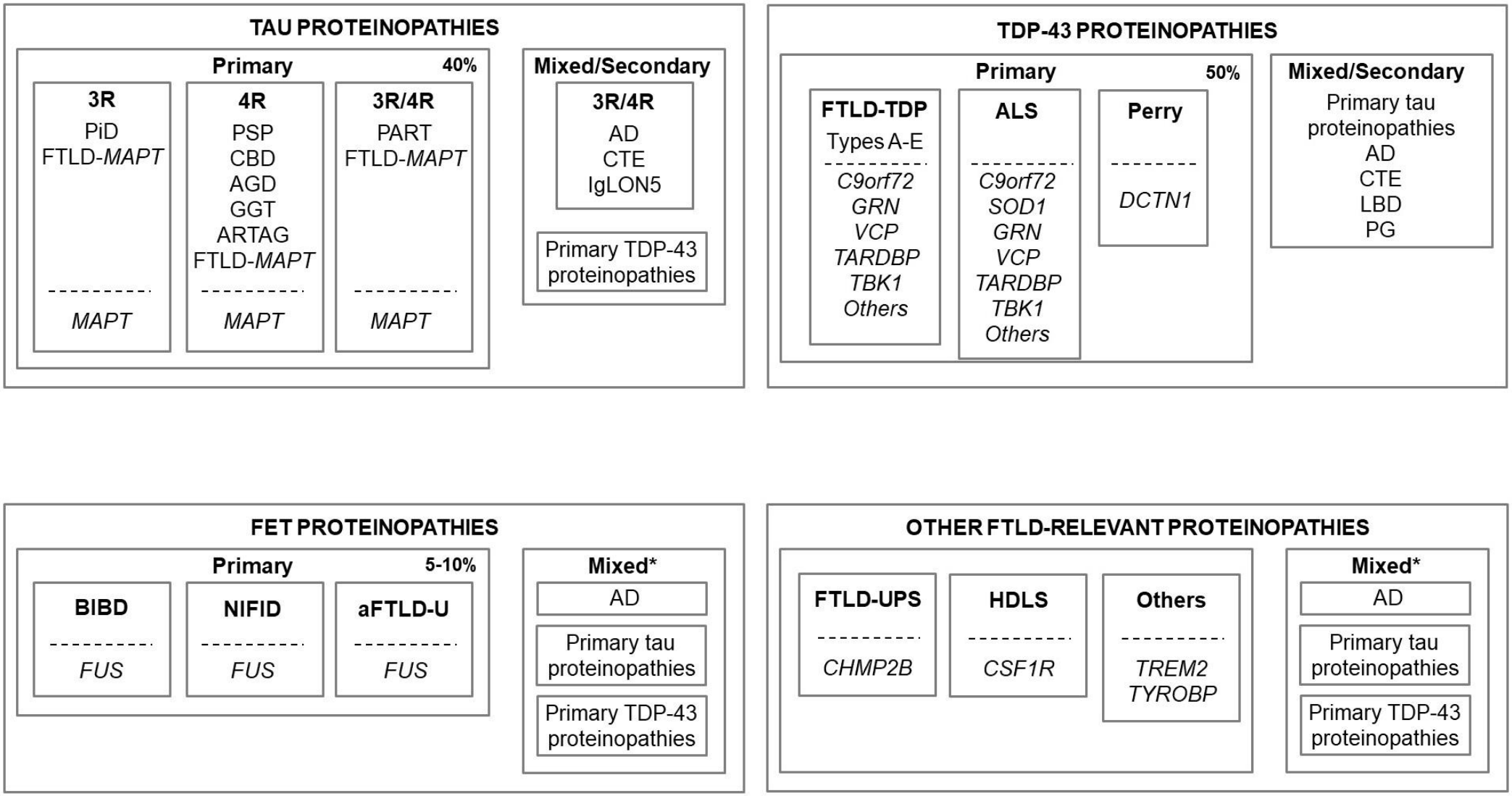

 Click here to access/download;Figure;FTLDupdateTLNAppendix2-SocialCognition.docx

Appendix 2. Measures Assessing Social Cognition

Formal assessment of eating changes, using an ad libitum breakfast test meal, has shown that bvFTD but not AD patients, have increased caloric intake and strong sucrose preference{Ahmed, 2016 #9088} underscoring eating changes as a diagnostic marker of bvFTD.{Ducharme, 2018 #9092;Lansdall, 2019 #9093} New tests which formally measure apathy have also been developed including computerised measures of goal-directed behaviour{Massimo, 2015 #9094} and observations of exploration behaviour{Batrancourt, 2019 #9095}. While traditionally conceptualised as a unitary construct, the complexity of apathy is increasingly recognized,{Ducharme, 2018 #9092} as well as its relevance for prognosis and survival.{Lansdall, 2019 #9093} Understanding the different dimensions of apathy may improve its diagnostic utility, with bvFTD patients tending to show more emotional/affective apathy than AD.{Kumfor, 2018 #9099} While the behavioural symptoms of bvFTD are conventionally assessed and interpreted independently, a new framework has suggested that these behavioural symptoms which superficially appear unrelated may reflect a reduction in goal-directed behaviour and a concomitant over-reliance on habitual behaviours.{Wong, 2018 #9105} This new framework may help to harmonise methodologies across species and improve translation from animal models to clinical settings.{Toller, 2020 #8750;Rankin, 2021 #9406;Matias-Guiu, 2020 #9109;Kamath, 2020 #9111} Although not part of the current diagnostic criteria, a surge of research has focused on social cognition as a potential surrogate marker for the behavioural features which are present early in bvFTD and rtvFTD and emerge with disease progression in PPA (particularly the semantic variant).{Kumfor, 2016 #9116} Social cognition refers to the abilities needed to perceive, interpret and respond to social cues. Patients with bvFTD show profound impairment in their ability to recognise emotions from faces, bodies, voices, music and non-verbal sounds,{Kumfor, 2018 #9123} which may even be detectable in some pre-

symptomatic patients.{Jiskoot, 2021 #9128} Responses to social cues are also abnormal. Patients with bvFTD show reduced facial expressions (measured by surface facial electromyography) when viewing emotional stimuli.{Kumfor, 2019 #9135} Arousal (measured by skin conductance level) is also dampened.{Kumfor, 2019 #9135} People with bvFTD also show reduced capacity to take another's perspective (i.e., mentalizing, also known as theory of mind) compared to healthy older adults and AD patients (when cognitive impairment is taken into account).{Kumfor, 2017 #9141} In line with the diagnostic criteria, empathy is reduced. Changes in moral reasoning have also been reported,{Strikwerda-Brown, 2021 #9146} with some patients showing antisocial or even criminal behaviour.{Liljegren, 2019 #9147} Thus, impairments in social cognition are profound and wide ranging. It is increasingly recognised that tests of social cognition are useful in differentiating bvFTD from AD{Moura, 2020 #9148} as well as from primary psychiatric disorders such as bipolar disorder and schizophrenia.{Ducharme, 2020 #8924} As yet, no consensus has been reached regarding the "best" test of social cognition. Measures which have been validated include the Revised Self-Monitoring Scale (RSMS),{Toller, 2020 #8750} Interpersonal Adjectives Scales, The Awareness of Social Inference Test (TASIT), among several others (well-described in{Rankin, 2021 #9406}). See **Appendix 2 Table** for summary of selected measures for assessing social cognition.

Appendix 2 Table. Selected measures for assessing social cognition

Domain	Emotion recognition	Mentalising (including theory of mind and empathy)	Questionnaire and informant measures	Behavioural measures
Test examples	• Photos [e.g., Ekman Faces; NimStim, Bodily Expressive Action Stimulus Test (BEAST); Social Cognition and Emotional Assessment (SEA)/Mini-SEA] • Mini-SEA • Prosody (e.g., Florida Affect Battery) • Videos [e.g., The Awareness of Social Inference Test (TASIT-Emotion Evaluation); Dynamic Affect Recognition Test]	• Faux pas test/Mini-SEA • False-belief tasks • TASIT-Social Inference • Moral dilemmas (e.g., Trolley car dilemma) • Theory of Mind Cartoons • Multi-faceted empathy test • Story-based empathy task • Reading the mind in the eyes test	• Revised self-monitoring scale • Interpersonal adjectives scales • Socioemotional Questionnaire • Interpersonal Reactivity Index • Social norms questionnaire	• Psychophysiology (e.g., skin conductance, facial electromyography, heart rate variability) • Eyetracking • Behaviour coding (e.g., facial expressions, vocal prosody, non-verbal behavior, ethnographic coding, clinician behavior ratings)

References

Click here to access/download;Figure;FTLDupdateTLNPanel1-FTDClinicalCharacteristics.docx

Panel 1. Clinical characteristics and cognitive profiles of key FTD subtypes

	Clinical characteristics and behavior	Cognitive/neuropsychological profile					Social cognition
		Attention and orientation	Language	Memory	Visuospatial and praxis	Executive functioning	
Behavioral-variant frontotemporal dementia (bvFTD)	Early and insidious change in behavior and personality • Disinhibition • Apathy • Stereotyped behavior • Reduced sympathy/empathy • Changes in eating habits • Limited insight	Usually oriented to time and place	Nature of difficulties similar to sv-PPA, but less severe (may be intact in some patients)	Variable. Spatial memory may be better able to distinguish from Alzheimer's disease	Intact. Complex figure copy tasks may be compromised due to poor organisational approach; praxis intact	Impaired on tasks tapping the ventromedial prefrontal cortex i.e., error sensitivity, verbal fluency, inhibition, decision-making and neuroeconomics tasks	• Profound impairment in emotion recognition, theory of mind/mentalising and empathy • Growing evidence of impaired moral reasoning, affective decision making, interoception, social cooperation
Semantic variant primary progressive aphasia (svPPA)	• Fluent but empty speech; reduced single-word comprehension. • Impaired knowledge of meaning of words objects, and other sensory	Intact	Impaired semantic knowledge irrespective of testing modality; Anomia, reduced single word comprehension,	Intact on tasks with limited conceptual demands	Intact visuospatial ability. Reduced object pantomime and limb imitation	Variable. Prominent executive dysfunction may indicate non-TDP-43 pathology	• Impaired emotion recognition, mentalising/theory of mind, empathy • Qualitatively similar profile to bvFTD

	perceptions e.g., sounds, tastes • Behavioural changes may occur early in the disease course and are more common with disease progression. Can affect conversation (e.g., stereotyped storytelling, decreased social interaction and impairments in turn-taking)		relatively preserved phonology, grammar and syntax; naming nouns < verbs.				
Right temporal variant of FTD (rtvFTD)	• Prosopagnosia, episodic memory impairment, and behavioural change • Behavioural changes common (disinhibition, obsessive personality) • May show hypochondria, increased spirituality possibly reflecting	Can be disoriented to time/place	May be present early in disease and becomes more impaired with disease progression. Similar language profile to sv-PPA	Impaired.	Impaired. Difficulties with navigation common	Variable but less affected than bvFTD	• Prosopagnosia • Impaired face perception and face memory • Impaired emotion recognition • Reduced empathy

	a complex semantic impairment						
Nonfluent variant primary progressive aphasia (nfvPPA)	• Effortful, laboured speech production (slow speech, decreased output and phrase length) • Agrammatical and/or apraxia of speech in the context of preserved semantic knowledge • Behavioural features increase with disease progression (e.g., difficulty in social interactions, changes in eating/drinking, change in social emotions, repetitive behaviors)	Intact	Reduced utterance length, high phonemic errors, poor sentence ordering. Comprehension relatively preserved except for syntactically complex sentences.	Non-verbal memory intact. Visuospatial memory impairment may be suggestive of underlying Alzheimer's pathology	Praxis (esp. orofacial) impaired	Mild executive dysfunction. Reduced verbal fluency/generativity.	• Limited available evidence shows impaired emotion recognition. Most evidence from facial stimuli. • Subtle impairments in empathy but not to the same extent as bvFTD; increase with disease progression.

Click here to access/download;Figure;FTLDupdateTLNPanel2-NonDrugInterventions+Ref.docx

Panel 2. Nonpharmacologic interventions for managing problematic FTD features

Speech and cognitive therapies. In the absence of disease modifying treatments or cures, interventions have focused on symptom management to address language and behavioral symptoms, improve patient functioning and reduce carer burden. Substantial progress has been made to improve language symptoms.[70] While generalization of training is variable and tends to be context dependent,[71] enriched encoding may enhance generalization to other exemplars and situations.[72] Recently, attempts to combine language training with non-invasive brain stimulation such as transcranial Direct Current Stimulation have been gaining interest, but randomized control trials are lacking (for a full review see[73]). In nfvPPA, several interventions have been developed to enhance speech production and fluency.[74] Internet-based speech and language therapy has also shown to be effective in people with PPA, but require further large scale replication.[75]

Behavioral interventions. For the behavioral symptoms, small case studies suggest that tailored activities or positive behavior support may improve neuropsychiatric and behavioral symptoms and alleviate carer distress.[76] Given the profound lack of insight in bvFTD, interventions which target carers can also be appropriate. For example, teaching carers techniques in cognitive appraisal and coping to change their interpretation of patients' behaviors can help to provide a sense of control for carers and in turn reduce burden. In addition, environmental modifications can be considered. For example, for apathy providing incentives and capitalizing on routines may enhance motivation; for people with agitation, assessment for pain and investigation of environmental triggers is important; for people with disinhibition monitoring of finances should be considered and for people with compulsive behaviors, distraction and/or harm reduction should be implemented. Recent evidence

suggests that among familial FTD mutation carriers, greater physical and cognitive activities were associated with slower clinical decline and rate of atrophy on MRI.[77] Whether the same occurs in those with sporadic FTD remains to be seen, but regardless, promoting physical, cognitive and leisure activities among symptomatic and at-risk individuals is reasonable clinical advice.