

University of Groningen

## Quantitative-imaging in cardiac transthyretin amyloidosis (I-CARE)

Tingen, H.S.A.; Tubben, A.; van der Meer, Peter; Nienhuis, Hans; Slart, R.H.J.A.

*Published in:*  
 Tijdschrift voor Nucleaire Geneeskunde

**IMPORTANT NOTE: You are advised to consult the publisher's version (publisher's PDF) if you wish to cite from it. Please check the document version below.**

*Document Version*  
 Publisher's PDF, also known as Version of record

*Publication date:*  
 2021

[Link to publication in University of Groningen/UMCG research database](#)

### *Citation for published version (APA):*

Tingen, H. S. A., Tubben, A., van der Meer, P., Nienhuis, H., & Slart, R. H. J. A. (2021). Quantitative-imaging in cardiac transthyretin amyloidosis (I-CARE): A European multicentre study. *Tijdschrift voor Nucleaire Geneeskunde*, 43(4), 2762-2765.  
<https://www.tijdschriftvoornucleairegeneeskunde.nl/quantitative-imaging-in-cardiac-transthyretin-amyloidosis-i-care>

### **Copyright**

Other than for strictly personal use, it is not permitted to download or to forward/distribute the text or part of it without the consent of the author(s) and/or copyright holder(s), unless the work is under an open content license (like Creative Commons).

The publication may also be distributed here under the terms of Article 25fa of the Dutch Copyright Act, indicated by the "Taverne" license. More information can be found on the University of Groningen website: <https://www.rug.nl/library/open-access/self-archiving-pure/taverne-amendment>.

### **Take-down policy**

If you believe that this document breaches copyright please contact us providing details, and we will remove access to the work immediately and investigate your claim.

*Downloaded from the University of Groningen/UMCG research database (Pure): <http://www.rug.nl/research/portal>. For technical reasons the number of authors shown on this cover page is limited to 10 maximum.*

# Quantitative-imaging in cardiac transthyretin amyloidosis (I-CARE)

*A European multicentre study*

H.S.A. Tingen, MD<sup>1</sup>; A. Tubben, MD<sup>2</sup>; Prof. P. van der Meer, MD, PhD<sup>2</sup>; H.L.A. Nienhuis, MD, PhD<sup>3</sup>; Prof. R.H.J.A. Slart, MD, PhD<sup>1</sup>

*Amyloidosis Center of Expertise, <sup>1</sup>Department of Nuclear Medicine & Molecular Imaging, <sup>2</sup>Department of Cardiology and <sup>3</sup>Department of Internal Medicine, University Medical Center Groningen*

## Introduction

The I-CARE (quantitative imaging in cardiac transthyretin amyloidosis) project is an international, prospective, multicentre study performed at four centres in three European countries. The aim is to develop a precision medicine tool to guide the diagnosis and monitoring of transthyretin amyloidosis cardiomyopathy (ATTR-CM) using [<sup>18</sup>F]sodiumfluoride (Na[<sup>18</sup>F] F) PET, a total of one hundred subjects with ATTR-CM will be included. As an extension, a quantitative innervation study (I-NERVE) with Iodine-123 labelled meta-iodobenzylguanidine ([<sup>123</sup>I]mIBG) will be performed in the UMCG.

## A brief summary on ATTR-CM

ATTR-CM is a gradually progressive, ultimately fatal condition caused by the deposition of misfolded liver-derived transthyretin (TTR) fibrils in the myocardial extracellular space. ATTR can be inherited (ATTRv) or acquired (ATTRwt) and mostly affects patients in the 7<sup>th</sup> decade of their life. Median survival is 2.6 and 3.6 years respectively, depending on the type and stage of disease (1,2). TTR fibril deposition inhibits the normal diastolic relaxation of the heart muscle resulting in heart failure with preserved ejection fraction (HFpEF) and indirectly increasing the risk of thromboembolic complications. Additionally, there is an increased risk of cardiac arrhythmias and conduction disorders due to cardiac sympathetic denervation (3).

Until recently ATTR-CM was thought to be a rare condition and

diagnostic delay was significant.

Through advancements in diagnostic techniques, increased awareness and due to an aging population, there has been an increase in newly diagnosed ATTR-CM (4). Although the exact prevalence of ATTR-CM is unknown, ATTR-CM is most recently estimated to be 16% in patients with severe aortic stenosis requiring transcatheter aortic valve replacement and 10% and 2.2% in male and female patients with HFpEF respectively (5,6). Estimating half of the patients in the Netherlands with heart failure (n=232,000) to have HFpEF, this could attribute to a considerable, yet to be diagnosed, ATTR-CM population (7).

An important aspect of the treatment of ATTR-CM is halting or delaying deposition of TTR fibrils.

Pharmacological advancements have led to the registration of a TTR stabilizer, named tafamidis, as the only treatment for ATTR-CM showing improved survival. Several other treatments are still under investigation (8). Gene silencing therapy with patisiran or inotersen can be used to treat patients with ATTRv polyneuropathy, but cannot yet be prescribed for patients suffering from ATTR-CM (9-11).

Although exciting new times for the treatment of ATTR-CM, important problems remain unsolved (figure 1). Firstly, there is no quantitative method of determining the disease burden as currently bone scintigraphy is used for the diagnosis. Despite its high diagnostic accuracy, cardiac tracer uptake can only be depicted

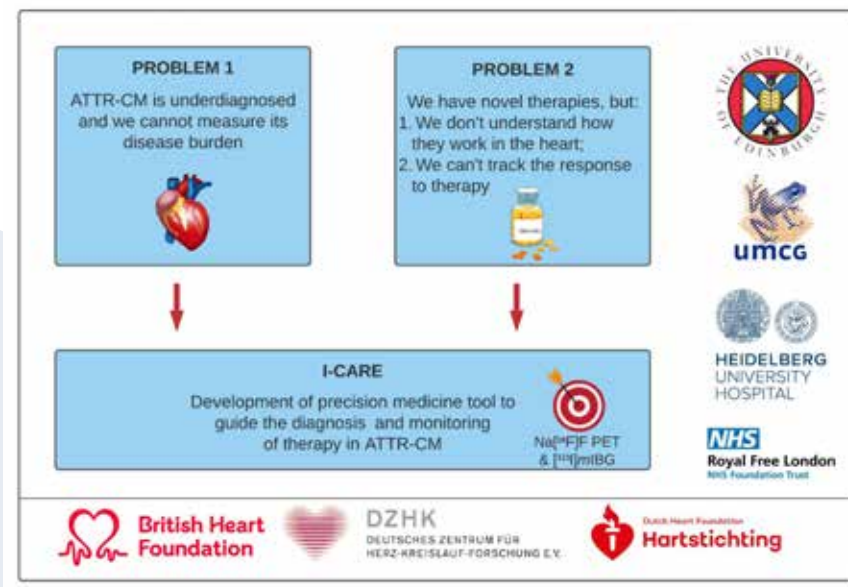


Figure 1. Summary of the problems faced in ATTR-CM and the aimed solution of I-CARE. With foundations and involved centres.

in a semi-quantitative manner, not allowing for interindividual comparison or tracking of treatment response (12). Secondly the specific mechanism of action of tafamidis in the myocardium remains unclear. Thirdly, to date there are no easily attainable and reliable techniques to detect improvements in structural or functional cardiac markers, apart from mid-global longitudinal strain on echocardiography (9). This contributes to a lack of understanding of the interindividual differences in therapy response.

### The I-CARE study

The I-CARE study is an international, prospective, observational study, which will be carried out in four centres in the United Kingdom, Germany and the Netherlands. Together, we will recruit one hundred subjects with ATTR-CM to develop a fully quantitative imaging method for tracking disease burden, therapy response and to identify responders and non-responders to treatment with tafamidis at an early stage. With expected new therapies available soon, being able to change from a non-effective therapy at an early stage could mean a vast prognostic improvement by individualised treatment strategy options for patients with a still limited prognosis. Additionally this could save healthcare costs, since the annual costs of tafamidis is 130.955 euro per patient. The hypothesis of I-CARE is threefold:

1. A delayed imaging protocol and state-of-the-art PET motion correction will optimise Na<sup>[18F]</sup>F PET imaging in ATTR-CM and provide a clear threshold in myocardial tissue to background ratio (TBR) values for the diagnosis of ATTR-CM;
2. The optimised Na<sup>[18F]</sup>F PET will provide a quantitative marker of the ATTR-CM burden that will allow disease progression and treatment response to be tracked;

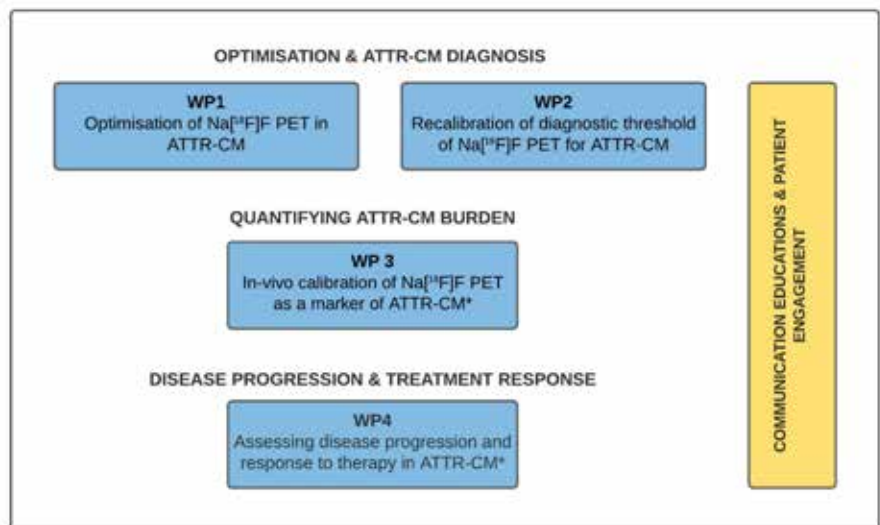


Figure 2. Illustration of the I-CARE Work Packages. \*<sup>[123I]</sup>mIBG imaging will be performed additionally in WP3 and 4 in the Netherlands.

3. Myocardial Na<sup>[18F]</sup>F TBR values will reduce in patients responding to tafamidis treatment and increase in non-responders and patients not receiving therapy.

To test the hypothesis, the study is divided in four subsequent work-packages (WP) (figure 2). In WP1, the Na<sup>[18F]</sup>F PET scanning protocol will be optimised by scanning at different time intervals between tracer injection and imaging. In WP2 we will establish the TBR on the optimised Na<sup>[18F]</sup>F scans that best differentiates ATTR-CM from other phenocopies, using control subjects with hypertrophic cardiomyopathy (n=20) and light-chain amyloidosis (n=20). The objective of WP3 is to validate Na<sup>[18F]</sup>F PET as a marker of cardiac ATTR burden *in vivo*, calibrating optimised TBR values against extracellular volume, late gadolinium enhancement and T1 mapping on cardiac magnetic resonance imaging (CMR) (n=100 ATTR-CM). The objective of WP4 is to investigate the ability of Na<sup>[18F]</sup>F PET to track disease progression and response to therapy in patients with established ATTR-CM after one year of treatment with tafamidis. As an extension we will perform a

Quantitative Innervation Imaging Study (I-NERVE) in the Netherlands. Because ATTR-CM poses a risk of arrhythmia due to amyloid infiltration of the cardiac conduction system and the myocardial tissue, early detection of cardiac sympathetic innervation disturbances has become of major clinical interest (13). By performing <sup>[123I]</sup>mIBG imaging in forty ATTR-CM patients we aim to quantify the amount of cardiac sympathetic denervation. We hypothesise that <sup>[123I]</sup>mIBG will help to identify responders and non-responders to treatment with tafamidis at an early stage by tracking disease progression through quantifying myocardial denervation. The addition of I-NERVE to I-CARE allows us to compare many different conventional and novel imaging modalities directly.

### Added value of a multicentre, international study

In the case of the I-CARE study, it was clear to us that an international study had multiple advantages over a local or national study and was the most suitable study structure for the purpose of the study. The first advantage of an international study is the expertise of the different

centres. As diagnosing and monitoring patients with ATTR-CM is complex, it is concentrated in specialised national centres. Different centres have different world leading expertise and an international collaboration provides the opportunity to integrate all the knowledge and skills available, resulting in a high quality, innovative study. Furthermore, all centres have their own collaborations with other specialised centres, creating a unique support system of experts around this study.

Another advantage of the current international cooperation with the three largest amyloid centres in Europe is the unique access to a large international cohort of ATTR-CM patients.

Finally, the successful formation of this new trans-European I-CARE collaboration, lays the foundations for future successful collaborative projects in ATTR-CM as well as other forms of cardiac amyloidosis. This network will provide unique and unparalleled access to amyloid patients coupled with state-of-the-art imaging expertise and treatments.

### Financial aspects

A total of € 1.2 M has been awarded to I-CARE consortium to facilitate international research in the Netherlands, Germany and the United Kingdom. This funding is provided by the Dutch Heart Foundation, the British Heart Foundation and the German Center for Cardiovascular Research. Projects financed by the Heart Foundation in this context contribute to a lasting relationship between research groups from the three countries. I-NERVE is awarded as an additional matching grant by the industry, and assigned as a sub study solely run in the Netherlands. In total two PhD students (The Netherlands), one post-doc (UK), and a data manager (Germany) are appointed and working now on the projects. A substantial part of the budget is spent

on PET and MRI imaging, furthermore the previously mentioned research team and patient reimbursements will be paid from the budget.

### Initiation of a multicentre, international study

During the initiation of this study, we focused on making practical agreements and establishing a good communication plan. First of all, each centre chose a communicating and leading principal investigator (PI), who would be in the lead and responsible for the study parts at their centre. Then, the entire project was divided in smaller work packages and these were assigned to the different centres. We agreed that all centres will recruit and include patients, which will allow us to include the target number of patients and control subjects within a year, something that would be

impossible for each of the individual centres. All other tasks were divided based on the expertise per centre (figure 3).

The current collaboration between centres originated from the already existing collaboration between individual centres. The amyloidosis centres in Groningen and London already had an established collaboration that extends back over more than forty years. Another long-standing collaboration was present between the centres of Heidelberg and Groningen. The centres in London and Edinburgh have also worked closely together before. These already existing collaborations have led to the formation of this new international collaboration and shows the collaborative potential of this group. International collaborations can bring multiple advantages but can

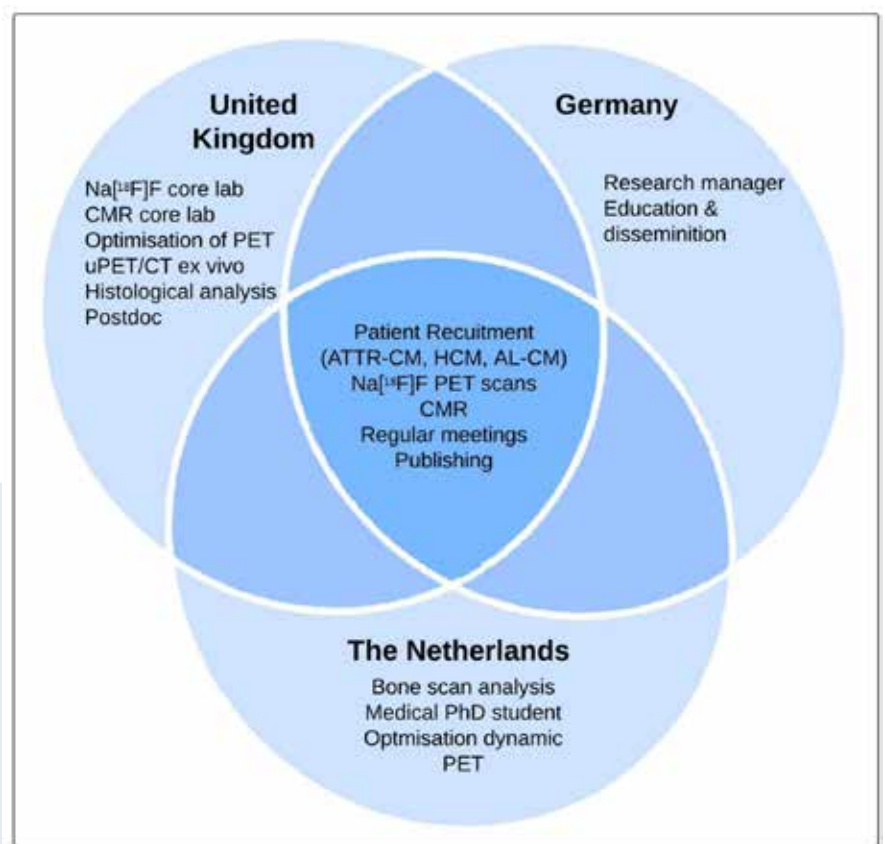


Figure 3. Overview of the tasks in each of the three countries.

be difficult to establish. Using pre-existing collaborations can facilitate the process of initiating a large international collaboration. When initiating such a collaboration, practical agreements need to be made and a clear division of tasks should be present, if possible, based on the relevant expertise and contact network per centre. Once a successful collaboration has been established, more collaborations might follow, leading to the conduction of high-quality research.

[r.h.j.a.slart@umcg.nl](mailto:r.h.j.a.slart@umcg.nl) ♦

## References

- Grogan M, Scott CG, Kyle RA, Zeldenrust SR, Gertz MA, Lin G, et al. Natural History of Wild-Type Transthyretin Cardiac Amyloidosis and Risk Stratification Using a Novel Staging System. *J Am Coll Cardiol*. 2016;68(10):1014-20
- Gillmore JD, Damy T, Fontana M, Hutchinson M, Lachmann HJ, Martinez-Naharro A, et al. A new staging system for cardiac transthyretin amyloidosis. *Eur Heart J*. 2018;39(30):2799-806
- Giancaterino S, Urey MA, Darden D, Hsu JC. Management of Arrhythmias in Cardiac Amyloidosis. *JACC Clin Electrophysiol*. 2020;6(4):351-61
- Lane T, Fontana M, Martinez-Naharro A, Quarta CC, Whelan CJ, Petrie A, et al. Natural History, Quality of Life, and Outcome in Cardiac Transthyretin Amyloidosis. *Circulation*. 2019;140(1):16-26
- Castano A, Narotsky DL, Hamid N, Khalique OK, Morgenstern R, DeLuca A, et al. Unveiling transthyretin cardiac amyloidosis and its predictors among elderly patients with severe aortic stenosis undergoing transcatheter aortic valve replacement. *Eur Heart J*. 2017;38(38):2879-87
- AbouEzzeddine OF, Davies DR, Scott CG, Fayyaz AU, Askew JW, McKie PM, et al. Prevalence of Transthyretin Amyloid Cardiomyopathy in Heart Failure With Preserved Ejection Fraction. *JAMA Cardiol* [Internet]. 2021 Aug 25; Available from: <https://jamanetwork.com/journals/jamacardiology/fullarticle/2783400>
- Boer AR De, Rutten FH, Valk MJM, Brugts JJ, Deckers JW. 2 Hartfalen in Nederland. 2017
- Garcia-Pavia P, Rapezzi C, Adler Y, Arad M, Basso C, Brucato A, et al. Diagnosis and treatment of cardiac amyloidosis: a position statement of the ESC Working Group on Myocardial and Pericardial Diseases. *Eur Heart J*. 2021;42(16):1554-68
- Maurer MS, Schwartz JH, Gundapaneni B, Elliott PM, Merlini G, Waddington-Cruz M, et al. Tafamidis Treatment for Patients with Transthyretin Amyloid Cardiomyopathy. *N Engl J Med*. 2018;379(11):1007-16
- Solomon SD, Adams D, Kristen A, Grogan M, González-Duarte A, Maurer MS, et al. Effects of Patisiran, an RNA Interference Therapeutic, on Cardiac Parameters in Patients with Hereditary Transthyretin-Mediated Amyloidosis: Analysis of the APOLLO Study. *Circulation*. 2019;139(4):431-43
- Benson MD, Waddington-Cruz M, Berk JL, Polydefkis M, Dyck PJ, Wang AK, et al. Inotersen Treatment for Patients with Hereditary Transthyretin Amyloidosis. *N Engl J Med*. 2018;379(1):22-31
- Castano A, DeLuca A, Weinberg R, Pozniakoff T, Blaner WS, Pirmohamed A, et al. Serial scanning with technetium pyrophosphate (99mTc-PYP) in advanced ATTR cardiac amyloidosis. *J Nucl Cardiol*. 2016;23(6):1355-63
- Slart RHJA, Glaudemans AWJM, Hazenberg BPC, Noordzij W. Imaging cardiac innervation in amyloidosis. *J Nucl Cardiol*. 2019;26(1):174-87