

University of Groningen

## Machine Perfusion of Donation After Circulatory Death Liver and Lungs Before Combined Liver-lung Transplantation

van Leeuwen, Otto B.; Bruggenwirth, Isabel M. A.; de Kleine, Ruben H. J.; van den Berg, Aad P.; Verschuuren, Erik A. M.; Erasmus, Michiel E.; Porte, Robert J.

*Published in:*  
Transplantation direct

*DOI:*  
[10.1097/TXD.0000000000001165](https://doi.org/10.1097/TXD.0000000000001165)

**IMPORTANT NOTE: You are advised to consult the publisher's version (publisher's PDF) if you wish to cite from it. Please check the document version below.**

*Document Version*  
Publisher's PDF, also known as Version of record

*Publication date:*  
2021

[Link to publication in University of Groningen/UMCG research database](#)

*Citation for published version (APA):*

van Leeuwen, O. B., Bruggenwirth, I. M. A., de Kleine, R. H. J., van den Berg, A. P., Verschuuren, E. A. M., Erasmus, M. E., & Porte, R. J. (2021). Machine Perfusion of Donation After Circulatory Death Liver and Lungs Before Combined Liver-lung Transplantation. *Transplantation direct*, 7(7), 1-4. [718]. <https://doi.org/10.1097/TXD.0000000000001165>

### Copyright

Other than for strictly personal use, it is not permitted to download or to forward/distribute the text or part of it without the consent of the author(s) and/or copyright holder(s), unless the work is under an open content license (like Creative Commons).

The publication may also be distributed here under the terms of Article 25fa of the Dutch Copyright Act, indicated by the "Taverne" license. More information can be found on the University of Groningen website: <https://www.rug.nl/library/open-access/self-archiving-pure/taverne-amendment>.

### Take-down policy

If you believe that this document breaches copyright please contact us providing details, and we will remove access to the work immediately and investigate your claim.

Downloaded from the University of Groningen/UMCG research database (Pure): <http://www.rug.nl/research/portal>. For technical reasons the number of authors shown on this cover page is limited to 10 maximum.

## OPEN

# Machine Perfusion of Donation After Circulatory Death Liver and Lungs Before Combined Liver-lung Transplantation

Otto B. van Leeuwen, PhD,<sup>1</sup> Isabel M.A. Brüggewirth, BSc,<sup>1</sup> Ruben H.J. de Kleine, MD,<sup>1</sup> Aad P. van den Berg, MD, PhD,<sup>2</sup> Erik A.M. Verschuuren, MD, PhD,<sup>3</sup> Michiel E. Erasmus, MD, PhD,<sup>4</sup> and Robert J. Porte, MD, PhD<sup>1</sup>

**Abstract.** Shortage of deceased donor organs for transplantation has led to the increased use of organs from donation after circulatory death (DCD) donors. There are currently no reports describing outcomes after multiorgan transplantation with DCD livers. The use of DCD organs for multiorgan transplantation can be enhanced if the detrimental effects of prolonged cold ischemia and subsequent ischemia-reperfusion injury are overcome. We present a case in which the liver and lungs of a DCD donor were preserved using ex situ machine perfusion for combined liver-lung transplantation. The recipient was a 19-year-old male patient requiring bilateral lung transplantation for severe progressive pleural parenchymal fibroelastosis and portal hypertension with portal vein thrombosis. The donor liver was preserved with dual hypothermic oxygenated machine perfusion, whereas the lungs were perfused using ex vivo lung perfusion. With ex vivo lung perfusion, total preservation time of right and left lung reached 17 and 21 h, respectively. Now, 2 y after transplantation, liver function is normal and lung function is improving. To conclude, we suggest that combined transplantation of DCD liver and lungs is feasible when cold ischemia is reduced with ex situ machine perfusion preservation.

(Transplantation Direct 2021;7: e718; doi: 10.1097/TXD.0000000000001105. Published online 18 June, 2021.)

## INTRODUCTION

Shortage of deceased donor organs for transplantation has led to the increased use of organs from donation after circulatory

Received 16 February 2021. Revision received 16 March 2021.

Accepted 18 March 2021.

<sup>1</sup> Department of Surgery, Section of Hepatobiliary Surgery and Liver Transplantation, University of Groningen, University Medical Center Groningen, Groningen, The Netherlands.

<sup>2</sup> Department of Gastroenterology and Hepatology, University Medical Center Groningen, University of Groningen, Groningen, The Netherlands.

<sup>3</sup> Department of Pulmonary Diseases, University of Groningen, University Medical Center Groningen, Groningen, The Netherlands.

<sup>4</sup> Department of Cardiothoracic Surgery, University of Groningen, University Medical Center Groningen, Groningen, The Netherlands.

Clinical implementation of machine perfusion techniques is funded by the Dutch Ministry of Health, Welfare and Sports.

The authors declare no conflicts of interest.

O.B.v.L., I.M.A.B., and R.J.P. participated in research design and wrote the article. R.H.J.d.K., A.P.v.d.B., E.A.M.V., and M.E.E. participated in data analysis and revised the article.

Correspondence: Robert J. Porte, MD, PhD, Section of Hepatobiliary Surgery and Liver Transplantation, Department of Surgery, University Medical Center Groningen, P.O. Box 30.001, 9700 RB Groningen, The Netherlands. (r.j.porte@umcg.nl).

Copyright © 2021 The Author(s). Transplantation Direct. Published by Wolters Kluwer Health, Inc. This is an open-access article distributed under the terms of the Creative Commons Attribution-Non Commercial-No Derivatives License 4.0 (CCBY-NC-ND), where it is permissible to download and share the work provided it is properly cited. The work cannot be changed in any way or used commercially without permission from the journal.

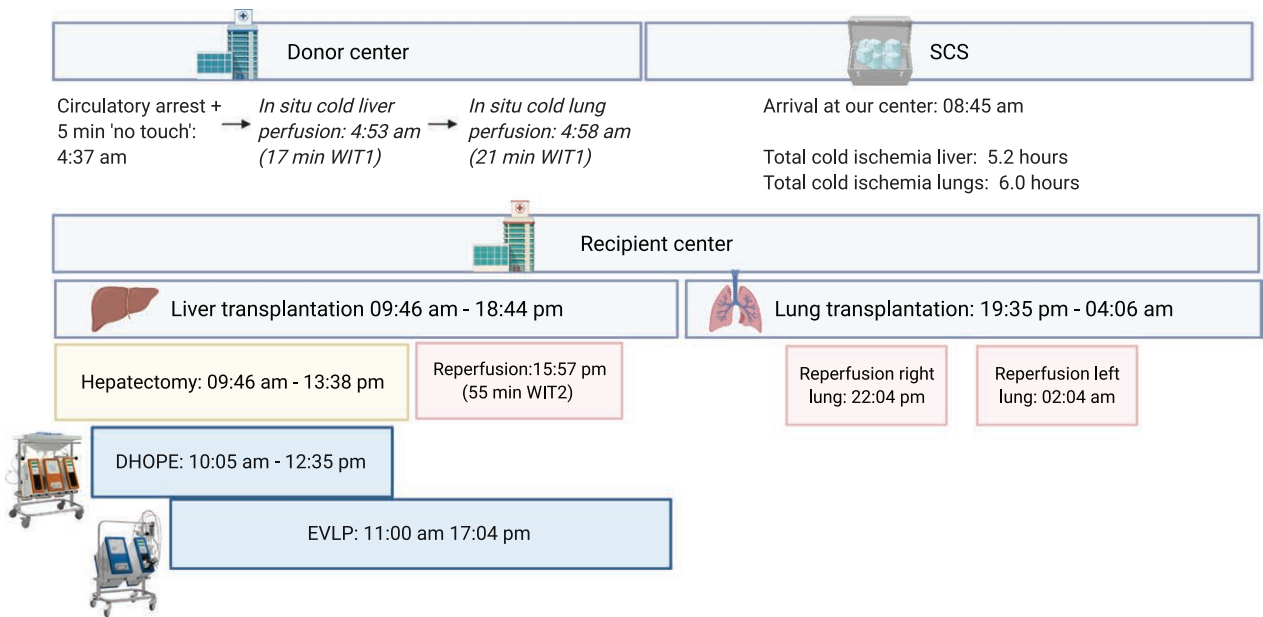
ISSN: 2373-8731

DOI: 10.1097/TXD.0000000000001165

death (DCD) donors.<sup>1</sup> Despite, transplant surgeons tend to avoid use of DCD organs for more complex transplantations with expected longer ischemia times. Safe use of DCD livers for retransplantation has recently been described.<sup>2</sup> However, there are currently no reports describing outcomes after multiorgan transplantation with DCD livers. The use of DCD organs for multiorgan transplantation can be enhanced if the detrimental effects of prolonged cold ischemia and subsequent ischemia-reperfusion injury are overcome. Ex situ machine perfusion has proven to be an effective technique to reduce cold ischemia and resuscitate organs before transplantation.<sup>3,4</sup> We present a case in which the liver and lungs of a DCD donor were preserved using ex situ machine perfusion for combined liver-lung transplantation.

## CASE DESCRIPTION

The recipient was a 19-year-old male patient requiring bilateral lung transplantation for severe progressive pleural-parenchymal fibroelastosis and portal hypertension, most likely as a late complication of previous chemotherapy treatment for rhabdomyosarcoma of the bladder at the age of 1. Hampering successful lung transplantation was extensive portal hypertension due to portal vein thrombosis, which was present from the portomesenteric confluence up to the intrahepatic branches with large abdominal and thoracic collaterals. A transjugular intrahepatic portosystemic shunt procedure was not possible because of the severity of the portal vein thrombosis. Therefore, the patient was listed for combined liver-lung transplantation.

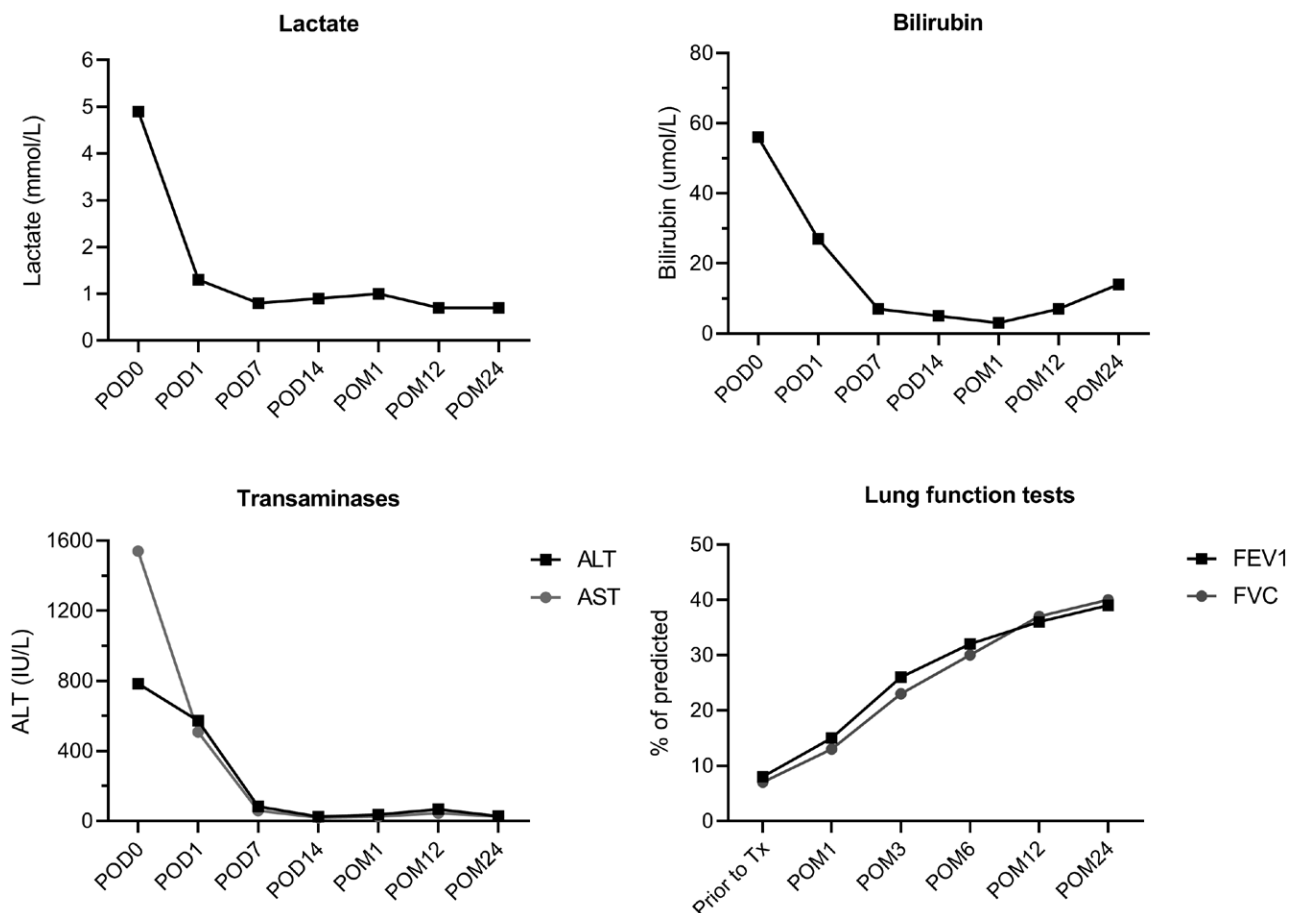


**FIGURE 1.** Timeline of the combined liver-lung transplantation using machine preservation for both organs. DHOPE, dual hypothermic oxygenated machine perfusion; EVLP, ex vivo lung perfusion; SCS, static cold storage; WIT, warm ischemia time.

The DCD donor was a 31-year-old female, with a body mass index of 23, who had suffered severe cerebral injury following a cerebrovascular attack. After withdrawal of life support, circulatory arrest occurred in 17 minutes. In situ cold

perfusion of the liver and lungs was performed 17 and 21 minutes after circulatory arrest, respectively.

To reduce cold ischemia time (CIT), both the donor liver and lungs were preserved with ex situ machine perfusion



**FIGURE 2.** Postoperative course after combined liver-lung transplantation. ALT, alanine aminotransferase; AST, aspartate aminotransferase; FEV1, forced expiratory volume in 1 s; FVC, forced vital capacity; POD, postoperative day; POM, postoperative month.

immediately after arrival at our transplant center. According to our dual hypothermic oxygenated machine perfusion (DHOPE) protocol, the liver was perfused hypothermically (10°C), using low perfusion pressures for both the portal vein (4 mmHg) and the hepatic artery (25 mmHg).<sup>3</sup> Before connection to the perfusion device, the liver was preserved by static cold storage for 5.2 hours. Dual HOPE was performed with the Liver Assist device (Organ Assist, Groningen, the Netherlands) using University of Wisconsin Machine Perfusion Solution (CarnaMedica, Warsaw, Poland) and oxygenation with 100% FiO<sub>2</sub> at 1L/min. The donor lungs were perfused with the Lung Assist device (Organ Assist, Groningen, the Netherlands) using Steen solution (XVIVO, Gothenburg, Sweden). The lungs were placed in a perfusion dome at room temperature and slowly rewarmed to 37°C according to the ex vivo lung perfusion (EVLP) protocol as described previously.<sup>4</sup> Before connection to the perfusion device, the lungs were preserved by static cold storage for 6 hours. A timeline is depicted in Figure 1.

While preparing the donor organs for machine perfusion, the recipient surgery was started in a separate operating room. The recipient hepatectomy was classified as difficult due to severe portal hypertension and resulted in 7.5L of blood loss. After 2.5 hours of DHOPE, the recipient hepatectomy and portal thrombectomy were finished and the donor liver was disconnected from the perfusion machine and implanted using standard piggyback-technique. Graft reperfusion was uneventful and with early recovery of bile production. Total preservation time of the liver had been 10.2 hours. Subsequently, thoracotomy was performed and central extracorporeal life support (ECLS) was started. The donor lungs were disconnected from the perfusion machine after a total perfusion time of 6 hours, during which the liver transplant had been performed (Figure 1). Without the use of EVLP, the CIT of the lungs would have exceeded 16 hours. With EVLP, total preservation time of the right lung reached 17 hours and 21 hours for the left lung. Before implantation of the left lung, a lobectomy of the left lower lobe was performed due to a small thoracic cavity. Both lungs were successfully transplanted with good reperfusion, but with development of some ischemia-reperfusion, lung-edema. Primary graft dysfunction stages at 24, 48, and 72 hours was scored grade 3 due to the continuation of ECLS, but the patient was improving clinically. On the intensive care unit, liver function restored rapidly (Figure 2) and transaminases and bilirubin decreased to normal levels within the first week after transplantation. Hypercapnia persisted due to a very rigid thoracic cavity and diaphragmatic paresis, and several rethoracotomies were performed in the first postoperative week because of rebleeding. The patient was disconnected from the ECLS on postoperative day (POD) 18, followed by extubation on POD 21. He recovered well and was discharged on POD 40. Maintenance immunosuppressive therapy is administered according to standard lung transplantation protocol, with mycophenolic acid, prednisolone, and tacrolimus. Now, over 2 years after combined liver-lung transplantation, the patient is doing relatively well, plays soccer in a transplant team and goes to university. Lung function is improving, but with restrictions during sports, and liver and kidney function have normalized. One long-term biliary stricture developed at the site of the anastomosis, which was treated endoscopically.

## DISCUSSION

To the best of our knowledge, this is the first published case of combined liver and lung ex situ machine perfusion for subsequent combined liver-lung transplantation. This report illustrates that ex situ machine perfusion may be used as a tool to reduce CIT in case of combined organ transplantation.

Prolonged cold ischemia is an established risk factor for diminished outcome in both liver and lung transplantation, especially when grafts are derived from DCD donors. In liver transplantation, CIT is preferably kept under 6 hours.<sup>5,6</sup> Prolonged cold ischemia has been associated with an increased risk of graft loss and the development of nonanastomotic biliary strictures.<sup>7,8</sup> In lung transplantation, the current maximum CIT used clinically is around 8 hours in most centers.<sup>9</sup> Studies have shown reduced graft survival and more airway complications when CIT is prolonged.<sup>10,11</sup> Ex situ machine perfusion could be used to reduce CIT and prolong preservation time to facilitate transplant logistics, such as for combined organ transplantation.

Combined transplantation of the lungs and liver is a complex surgery and there are only a few case series published in the literature. The lungs are usually transplanted first with reported cold ischemic times of the liver ranging between 7 and 18 hours.<sup>12-16</sup> A report from Leuven describes the “liver first” principle with use of EVLP to prolong lung preservation, but these organs were derived from a DBD donor.<sup>17</sup> Machine perfusion of donor liver and lungs allows the transplant team to modify the sequence of the transplantation based on recipient-specific requirements. A liver first approach rapidly reduces portal hypertension in the thoracic collateral circulation, as was the case here. Lung transplantation first allows for maximum oxygenation with optimal positioning of extracorporeal systems. More importantly, combined liver and lung transplantation always comes with a complex logistical planning (eg, long anesthesia induction time, 2 separate transplant teams, possible difficulties with either transplant), which makes the elimination of concerns about prolonged CITs of crucial importance.

To conclude, we suggest that combined transplantation of DCD liver and lungs is feasible when CITs are reduced with ex situ machine perfusion preservation.

## REFERENCES

1. Bodzin AS, Baker TB. Liver transplantation today: where we are now and where we are going. *Liver Transpl*. 2018;24:1470-1475.
2. van Reeve M, van Leeuwen OB, van der Helm D, et al. Selected liver grafts from donation after circulatory death can be safely used for retransplantation—a multicenter retrospective study. *Transpl Int*. 2020;33:667-674.
3. Schlegel A, de Rougemont O, Graf R, et al. Protective mechanisms of end-ischemic cold machine perfusion in DCD liver grafts. *J Hepatol*. 2013;58:278-286.
4. van Rijn R, Schurink IJ, de Vries Y, et al; DHOPE-DCD Trial Investigators. Hypothermic machine perfusion in liver transplantation—a randomized trial. *N Engl J Med*. 2021;384:1391-1401.
5. Dutkowski P, Oberkofler CE, Slankamenac K, et al. Are there better guidelines for allocation in liver transplantation? A novel score targeting justice and utility in the model for end-stage liver disease era. *Ann Surg*. 2011;254:745-753.
6. Schlegel A, Kalisvaart M, Scalera I, et al. The UK DCD risk score: a new proposal to define futility in donation-after-circulatory-death liver transplantation. *J Hepatol*. 2018;68:456-464.
7. Foley DP, Fernandez LA, Levenson G, et al. Biliary complications after liver transplantation from donation after cardiac death donors: an analysis of risk factors and long-term outcomes from a single center. *Ann Surg*. 2011;253:817-825.

8. Guichelaar MM, Benson JT, Malinchoc M, et al. Risk factors for and clinical course of non-anastomotic biliary strictures after liver transplantation. *Am J Transplant.* 2003;3:885–890.
9. Okamoto T, Wheeler D, Farver CF, et al. Transplant suitability of rejected human donor lungs with prolonged cold ischemia time in low-flow acellular and high-flow cellular ex vivo lung perfusion systems. *Transplantation.* 2019;103:1799–1808.
10. Nęcki M, Antończyk R, Pandel A, et al. Impact of cold ischemia time on frequency of airway complications among lung transplant recipients. *Transplant Proc.* 2020;52:2160–2164.
11. Ghaidan H, Fakhro M, Lindstedt S. Impact of allograft ischemic time on long-term survival in lung transplantation: a Swedish monocentric study. *Scand Cardiovasc J.* 2020;54:322–329.
12. Barshes NR, DiBardino DJ, McKenzie ED, et al. Combined lung and liver transplantation: the United States experience. *Transplantation.* 2005;80:1161–1167.
13. Corno V, Dezza MC, Lucianetti A, et al. Combined double lung-liver transplantation for cystic fibrosis without cardio-pulmonary by-pass. *Am J Transplant.* 2007;7:2433–2438.
14. Grannas G, Neipp M, Hoepfer MM, et al. Indications for and outcomes after combined lung and liver transplantation: a single-center experience on 13 consecutive cases. *Transplantation.* 2008;85:524–531.
15. Desie N, Van Raemdonck DE, Ceulemans LJ, et al. Combined or serial liver and lung transplantation for epithelioid hemangioendothelioma: a case series. *Am J Transplant.* 2015;15:3247–3254.
16. Ceulemans LJ, Strypstein S, Neyrinck A, et al. Combined liver-thoracic transplantation: single-center experience with introduction of the 'liver-first' principle. *Transpl Int.* 2016;29:715–726.
17. Ceulemans LJ, Monbaliu D, Verslype C, et al. Combined liver and lung transplantation with extended normothermic lung preservation in a patient with end-stage emphysema complicated by drug-induced acute liver failure. *Am J Transplant.* 2014;14:2412–2416.