

University of Groningen

Novel cryoballoon 180° ablation system for treatment of Barrett's esophagus-related neoplasia

Overwater, Anouk; van Munster, Sanne N; Nagengast, Wouter B; Pouw, Roos E; Bergman, Jacques J G H M; Schoon, Erik J; Weusten, Bas L A M

Published in:
Endoscopy

DOI:
[10.1055/a-1381-7562](https://doi.org/10.1055/a-1381-7562)

IMPORTANT NOTE: You are advised to consult the publisher's version (publisher's PDF) if you wish to cite from it. Please check the document version below.

Document Version
Publisher's PDF, also known as Version of record

Publication date:
2022

[Link to publication in University of Groningen/UMCG research database](#)

Citation for published version (APA):

Overwater, A., van Munster, S. N., Nagengast, W. B., Pouw, R. E., Bergman, J. J. G. H. M., Schoon, E. J., & Weusten, B. L. A. M. (2022). Novel cryoballoon 180° ablation system for treatment of Barrett's esophagus-related neoplasia: a first-in-human study. *Endoscopy*, 54(1), 64-70. <https://doi.org/10.1055/a-1381-7562>

Copyright

Other than for strictly personal use, it is not permitted to download or to forward/distribute the text or part of it without the consent of the author(s) and/or copyright holder(s), unless the work is under an open content license (like Creative Commons).

The publication may also be distributed here under the terms of Article 25fa of the Dutch Copyright Act, indicated by the "Taverne" license. More information can be found on the University of Groningen website: <https://www.rug.nl/library/open-access/self-archiving-pure/taverne-amendment>.


Take-down policy

If you believe that this document breaches copyright please contact us providing details, and we will remove access to the work immediately and investigate your claim.

Downloaded from the University of Groningen/UMCG research database (Pure): <http://www.rug.nl/research/portal>. For technical reasons the number of authors shown on this cover page is limited to 10 maximum.

Novel cryoballoon 180° ablation system for treatment of Barrett's esophagus-related neoplasia: a first-in-human study

Authors

Anouk Overwater^{1,2} , Sanne N. van Munster^{1,3}, Wouter B. Nagengast⁴, Roos E. Pouw³, Jacques J. G. H. M. Bergman³, Erik J. Schoon⁵, Bas L. A. M. Weusten^{1,2}

Institutions

- 1 Dept. of Gastroenterology and Hepatology, St. Antonius Hospital, Nieuwegein, The Netherlands
- 2 Dept. of Gastroenterology and Hepatology, University Medical Center Utrecht, Utrecht University, The Netherlands
- 3 Dept. of Gastroenterology and Hepatology, Amsterdam University Medical Centers, The Netherlands
- 4 Dept. of Gastroenterology and Hepatology, University Medical Center Groningen, University of Groningen, The Netherlands
- 5 Dept. of Gastroenterology and Hepatology, Catharina Hospital Eindhoven, The Netherlands

submitted 30.9.2020

accepted after revision 19.1.2021

published online 2021

Bibliography

Endoscopy

DOI 10.1055/a-1381-7562

ISSN 0013-726X

© 2021. Thieme. All rights reserved.

Georg Thieme Verlag KG, Rüdigerstraße 14,
70469 Stuttgart, Germany

 Appendix 1s

Supplementary material is available under
<https://doi.org/10.1055/a-1381-7562>

Corresponding author

B.L.A.M. Weusten, MD, PhD, Department of Gastroenterology, St. Antonius Hospital and University Medical Center Utrecht, Koekoekslaan 1, 3435 CM Nieuwegein, The Netherlands
b.weusten@antoniusziekenhuis.nl

ABSTRACT

Background The novel 180° cryoballoon (CbAS¹⁸⁰) enables semicircumferential treatment over a length of 3 cm per application. This first-in-human study evaluates its feasibility, efficacy, and safety for the treatment of Barrett's esophagus (BE) neoplasia.

Methods This multicenter study consisted of dose-finding and extension phases. Dose-finding started with the lowest dose possible (1.0 mm/s). For each dose, six patients were treated circumferentially over a 3-cm length. The dose was increased until the median BE regression was $\geq 60\%$ without serious adverse events (SAEs). In the extension phase, the dose was confirmed in 19 new patients. The outcomes were technical success, BE regression after one treatment, and SAEs.

Results 25 patients (median Prague C0M3) were included (6 dose-finding/19 extension). In two patients, the CbAS¹⁸⁰ could not be applied because of unstable balloon positioning. The technical success rate was 96% (22/23). In the six dose-finding patients, the starting dose resulted in median BE regression of 94% (95% confidence interval [CI] 60%–97%) without SAEs and was thus considered effective. Overall median BE regression was 80% (95%CI 60%–90%).

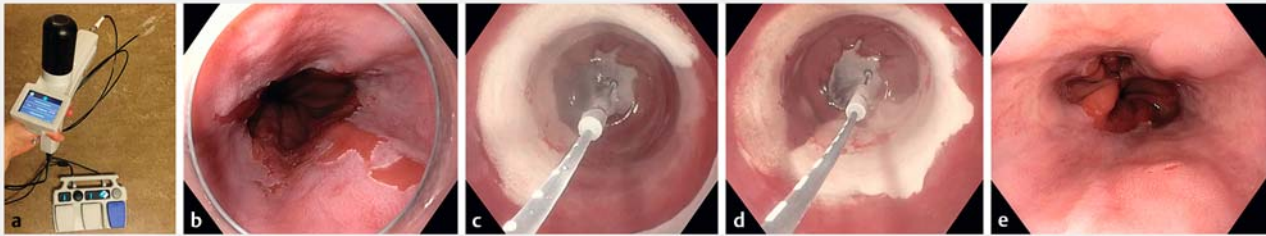
Conclusion Single-session CbAS¹⁸⁰ seems feasible, safe, and effective, and is a promising technique for the treatment of patients with BE neoplasia.

Introduction

Cryoballoon ablation (CbAS) is one of the ablation techniques available for the eradication of Barrett's esophagus (BE)-related neoplasia and may have better patient tolerability than the current standard of care, radiofrequency ablation (RFA) [1–4]. Another advantage of CbAS is that it preserves the extracellular matrix and therefore might allow for deeper ablation with low stricture rates [5, 6].

At first, focal CbAS was introduced, with each ablation resulting in a treated area of approximately 2 cm². Although previous studies have shown that focal CbAS is feasible, safe, and effective for the treatment of short BE segments and BE islands [7, 8], treatment of long BE segments with only the focal device would be cumbersome. Further maturation of CbAS required the addition of a large-area device.

Recently, a first-in-human study has shown that the large-area CbAS technique is feasible [9]. For this first clinical study,



► Fig. 1 Use of the Cryoballoon 180° Ablation System. **a** The CbAS¹⁸⁰ consists of a foot pedal, balloon catheter, and controller, with a cartridge of nitrous oxide placed under the black cap. **b–e** Endoscopic images showing: **b** a patient with a COM3 Barrett's esophagus (BE) with high grade dysplasia prior to CbAS¹⁸⁰ treatment; **c** the first CbAS¹⁸⁰ application being performed, starting at the gastroesophageal junction and moving proximally over 3 cm (the circles on the spray catheter indicate the spray direction); **d** a second CbAS¹⁸⁰ application being performed after repositioning of the spray catheter in the opposite direction (the opposite side of the spray catheter is marked with rectangles) to complete the circumferential treatment; **e** the appearance after 8 weeks, with 99% BE regression (a small remaining BE island is seen at 4 o'clock).

the Cryoballoon 90° Ablation System (CbAS⁹⁰) was used. CbAS⁹⁰ ablates a quarter of the esophageal circumference over a length of 3 cm per application. Technical development has now enabled amplification of the 90° spray angle to 180°, resulting in semicircumferential ablation over a 3-cm length per application. The use of this CbAS¹⁸⁰ would facilitate ablation of larger BE areas, while decreasing the risk of overlap between ablations and shortening procedure times. The current study is the first-in-human study to assess the feasibility, dose-related efficacy, and safety of CbAS¹⁸⁰ in patients with BE-related neoplasia.

Methods

Patients

In this multicenter prospective single-arm study, patients from five Dutch tertiary BE referral centers were included. Patients (≥ 18 years) with short BE segments (maximum circumferential extent of 3 cm) and an indication for ablation therapy were eligible for study participation. Ablation therapy was deemed to be indicated for patients with flat dysplastic BE or patients with residual BE after endoscopic resection of a visible lesion containing dysplasia or low risk early esophageal adenocarcinoma (i.e. an invasion depth of $< 500 \mu\text{m}$, good/moderate differentiation grade, no lymphovascular invasion, negative deep resection margins) [1].

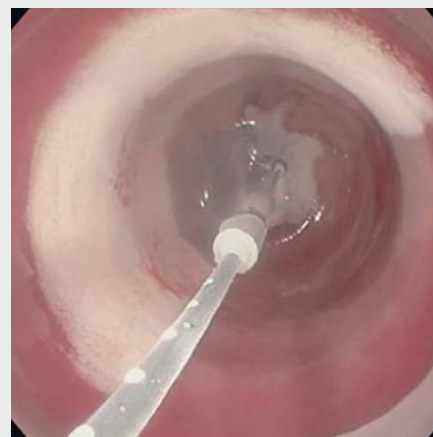Exclusion criteria were the presence of visible lesions (any mucosal irregularity within the BE segment that raised the endoscopist's suspicion of neoplasia), prior extensive endoscopic resection (> 2 cm length and/or $> 50\%$ of the esophageal circumference), prior endoscopic ablation, esophagitis (higher than Los Angeles grade A), a stricture preventing advancement of a therapeutic endoscope, or esophageal varices.

The C2 Cryoballoon 180° Ablation System (CbAS¹⁸⁰)

The C2 CbAS (Pentax Medical, Redwood City, California, USA) comprises a controller, foot pedal, balloon catheter, and cartridge with nitrous oxide (► Fig. 1a). The system is compatible with therapeutic endoscopes with a working channel diameter of at least 3.7 mm. The balloon is highly compliant and auto-

matically adjusts to the size of the esophagus. A spray diffuser is located in the center of the balloon, and can be rotated and positioned using the foot pedal. The type of balloon catheter used determines the size of the treatment area.

For this study, the CbAS¹⁸⁰ catheter (standard balloon shape) was used for all procedures, which enables semicircumferential ablation over a 3-cm length in a single step. After the spray diffuser has been positioned and the ablation started using the foot pedal, a continuous flow of nitrous oxide is delivered over half of the esophageal circumference, while the spray diffuser is automatically withdrawn along the 3-cm long axis of the balloon (► Video 1). The pullback speed of the spray diffuser determines the treatment dose and can be adjusted in the controller settings. A lower pullback speed results in a longer duration of the ablation, and thus a higher dose.



► Video 1 Treatment is performed with the Cryoballoon 180° Ablation System.

Online content viewable at:
<https://doi.org/10.1055/a-1381-7562>

Study design

The study consisted of two phases: a dose-finding phase to establish the effective dose for CbAS¹⁸⁰, followed by an extension phase. The effective dose was defined as the lowest dose that resulted in BE regression of $\geq 60\%$ after 8 (± 2) weeks in the absence of dose-related serious adverse events (DR-SAEs). DR-SAEs were defined as severe retrosternal pain (score >6 on both day 1 and day 7 post-treatment) and strictures requiring dilation. The starting dose was 1.0 mm/s, the lowest CE-marked dose, and this was increased by lowering the pullback speed by 0.1 mm/s until the earlier of the effective dose being determined or a DR-SAE occurring.

Six patients were treated per dose. After establishing the effective dose in the dose-finding phase, 19 additional patients were included in the extension phase, being managed in exactly the same manner to arrive at a total of 25 patients treated with the effective dose.

Treatment

All participating endoscopists have extensive experience in endoscopic treatment of BE (W.N., E.S., R.P., J.B., B.W.). All study procedures were performed with the patient under conscious sedation using midazolam and fentanyl or monitored deep sedation with propofol.

First, the BE segment was carefully inspected and the Prague C&M score was reported. Photos and videos were recorded using both white-light endoscopy (WLE) and narrow-band imaging (NBI) or blue-light imaging (BLI), depending on the endoscopy system used at the site of inclusion. Subsequently, electrocoagulation markings were placed at the gastroesophageal junction (GEJ) to optimally visualize the position of the balloon after inflation. The balloon catheter was then advanced through the endoscope and circumferential ablation was performed over a length of 3 cm, with two adjacent CbAS¹⁸⁰ applications, starting from the markings at the GEJ and moving proximally (► **Fig. 1**; ► **Video 1**). The duration of the endoscopy was defined as the time between introduction and removal of the endoscope and the ablation time was defined as the time between insertion and removal of the CbAS¹⁸⁰ catheter.

All patients were prescribed proton pump inhibitors twice daily after treatment and additional medication to achieve optimal acid control could be added.

Follow-up

Patients were contacted on days 0 (after treatment, before discharge), 1, 7, and 30 after treatment to evaluate (DR-)SAEs, retrosternal pain, dysphagia, and analgesics use. Retrosternal pain was scored on a numeric rating scale (NRS) from 0–10, with 0 indicating no pain and 10 the worst pain ever experienced. Dysphagia was evaluated using a validated score from 0–4, with 0 indicating no dysphagia and 4 complete dysphagia even for liquids [10, 11].

During the follow-up endoscopy after an interval of 8 (± 2) weeks, photos and videos of the original BE segment were again recorded with both WLE and NBI/BLI. BE regression (the percentage of treated BE that had converted to neosquamous

epithelium after one CbAS¹⁸⁰ treatment) was scored by the treating endoscopist, and four biopsies were taken from the neosquamous epithelium (two per CbAS¹⁸⁰ application, with a lower number of biopsies if there was a low BE regression percentage).

Thereafter, BE regression was evaluated by the adjudication committee, consisting of three independent BE expert endoscopists who were not involved in the study. Initially, two committee members compared pre- and post-treatment images and videos in a systematic manner to determine the regression percentage. If their evaluations differed more than 20%, or if their estimations were above or below the threshold of 60%, the third adjudication committee member additionally reviewed the images and videos. The median of the two, or three, readings was used. The adjudication committee's determination was used for data reporting and to decide whether or not the efficacy criteria had been satisfied. The adjudicators were blinded for the evaluation of the treating endoscopist and the dosage used.

Outcomes

The primary outcomes were feasibility, efficacy, and safety. To determine feasibility, we evaluated technical success (defined as CbAS¹⁸⁰ treatment of all of the BE as intended), device malfunctions (technical failure of CbAS¹⁸⁰ with the need for device replacement), and the endoscopy and ablation times. Efficacy was defined as the median BE regression percentage after one CbAS¹⁸⁰ treatment (i.e. circumferential treatment over a 3-cm length) as evaluated by the adjudication committee. Safety was defined as the incidence of DR-SAEs. Secondary outcomes were other (S)AEs, tolerability (retrosternal pain/dysphagia/analgesics use), and the presence of subsquamous intestinal metaplasia (SIM) or buried BE in the biopsies taken from the neosquamous epithelium.

Histopathological analysis

Biopsies were fixed in formalin (10%), embedded in paraffin, and stained with hematoxylin and eosin. All biopsies taken from the neosquamous epithelium during follow-up endoscopies in the extension cohort were reviewed by experienced BE pathologists for the presence of SIM.

Sample size calculation and statistical analysis

The sample size calculation was based on the primary outcome efficacy, defined as median BE regression after one treatment session. Assuming a median regression of 85% after one treatment session (based on regression rates after single RFA treatment varying between 78%–90% [12–14]), 22 patients were required to estimate the expected proportion with 15% absolute precision (lower boundary of the 95% confidence interval [CI] cannot be below 70%) with 95% confidence, which resulted in 25 patients in total incorporating a 10% drop-out rate (<http://statulator.com/SampleSize/ss1P.html>). With regards to safety, at a sample size of 25 patients, the lower limit of the 95%CI for the percentage of patients with strictures requiring dilation would be above 10% when six strictures had occurred (calculated with R version 3.5.1 for Windows).

Statistical analysis was performed using R version 3.6.2 for Mac (R Foundation for Statistical Computing, Vienna, Austria). For baseline descriptive statistics, continuous variables were reported as medians with 25th and 75th percentiles (p25–p75). Outcome variables were reported as medians with adjusted 95 %CIs, which were obtained with simple bootstrapping with 10 000 samples.

Ethics

The Medical Ethics Committees United reviewed and approved the study protocol and subsequent amendments. Written informed consent was obtained from all patients participating in the study and all patients included before amending the protocol were notified of the changes in study design (Appendix 1 s, see online-only Supplementary material). The manuscript was written in accordance with the STROBE guidelines [15].

Results

In total, 25 patients were enrolled between August 2018 and June 2020. Their baseline characteristics are summarized in Table 1.

Feasibility

Two patients (2/25; 8%) could not be treated with CbAS¹⁸⁰ owing to unstable positioning of the balloon at the GEJ: despite optimal procedural circumstances, the balloon repeatedly slipped into the hiatal hernia. Therefore 23 patients (23/25; 92%) were treated with CbAS¹⁸⁰ (6 in the dose-finding phase, 17 in the extension phase; Fig. 2).

The technical success rate was 88% (22/25) according to intention-to-treat analysis and 96% (22/23) on per-protocol analysis. In one patient who was treated with CbAS¹⁸⁰, 5 mm of the BE segment was left untreated because of a device malfunction at the end of the procedure. All results hereafter are reported per protocol (n = 23).

Device malfunctions occurred in three of the 23 CbAS¹⁸⁰ treatments performed (13%): one during set-up and two during treatment. In two patients, the procedure was successfully completed after replacement of a CbAS¹⁸⁰ component (controller and/or balloon catheter). In the third patient, the device malfunction occurred just before completing CbAS¹⁸⁰ treatment and 5 mm of the BE segment was left untreated, as mentioned above.

The median ablation time was 6 minutes (95%CI 5–12 minutes) and the median total endoscopy time was 21 minutes (95%CI 17–28 minutes).

Efficacy

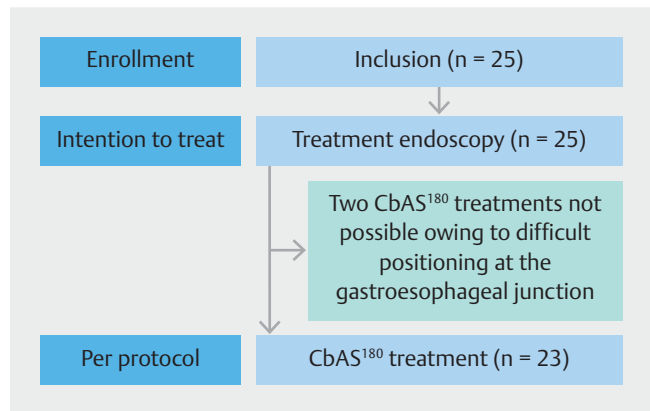
The median BE regression after CbAS¹⁸⁰ with the starting dose of 1.0 mm/s in the first six patients in the dose-escalation phase was 94% (95%CI 60%–97%) based on the adjudication committee evaluations. The first dose of 1.0 mm/s was therefore effective and the study was continued into the extension phase.

Overall, the median BE regression after CbAS¹⁸⁰ (n = 23) was 80% (95%CI 60%–90%) based on the adjudication committee

► **Table 1** Baseline characteristics of the 25 patients with Barrett’s esophagus (BE) who underwent treatment with the Cryoballoon 180° Ablation System (CbAS¹⁸⁰).

Sex, male, n (%)	23 (92)	
Age, median (p25–p75), years	69 (66–75)	
Hiatal hernia length, median (p25–p75), cm	3 (2–5)	
Hiatal hernia ≥ 3 cm, n (%)	13 (52)	
Prior endoscopic resection, n (%)	14 (56) (10 EAC, 1 HGD, 3 LGD)	
Worst pre-treatment histology, n (%)	LGD	10 (40)
	HGD	5 (20)
	EAC	10 (40)
Pre-ablation BE extent, median (p25–p75), cm	Circumferential	0 (0–2)
	Maximum	3 (3–5)

p25–p75, 25th to 75th percentile; LGD, low grade dysplasia; HGD, high grade dysplasia; EAC, esophageal adenocarcinoma.



► **Fig. 2** Flow diagram of patient inclusion and treatment.

evaluations. Overall, the median BE regression as evaluated by the treating physicians was 90% (95%CI 70%–90%).

Six patients (6/23; 26%) had BE regression below 50%. In two of these six patients, inflammation was seen at the first follow-up endoscopy and a second treatment was postponed. Both patients reported non-adherence to their proton-pump inhibitor intake.

Safety

One patient (1/23; 4%), included in the extension phase, developed a stricture that was resolved with two dilations. No severe bleeding, perforation, or other SAEs occurred. Other adverse events were reported for five patients. Three patients had moderate strictures (circumferential scarring, passable with an endoscope) not requiring dilation. One patient contacted the hospital because of dark colored stools (no melena), which resolved spontaneously. Finally, one patient experienced heavy

chest pain on the day of CbAS¹⁸⁰ treatment; additional analgesics were prescribed after an electrocardiogram ruled out a cardiac cause.

Tolerability

Patients reported limited retrosternal pain after CbAS¹⁸⁰. Pain scores were highest on the day of treatment before discharge (median score of 2, 95%CI 1–3). The course of pain and analgesic use is reported in ► Fig.3. The median dysphagia score was 0 at all follow-up points (95%CI on day 1 was 0–1 and 0–0 for all other follow-up points).

Histopathology

In one patient (1/23; 4%), one of the four biopsies taken from the neosquamous epithelium potentially showed SIM: presence of intestinal metaplasia along with squamous epithelium. This patient had remaining BE, with a median BE regression percentage of 70%. In all other patients, no SIM was found in any of the biopsies of the neosquamous epithelium.

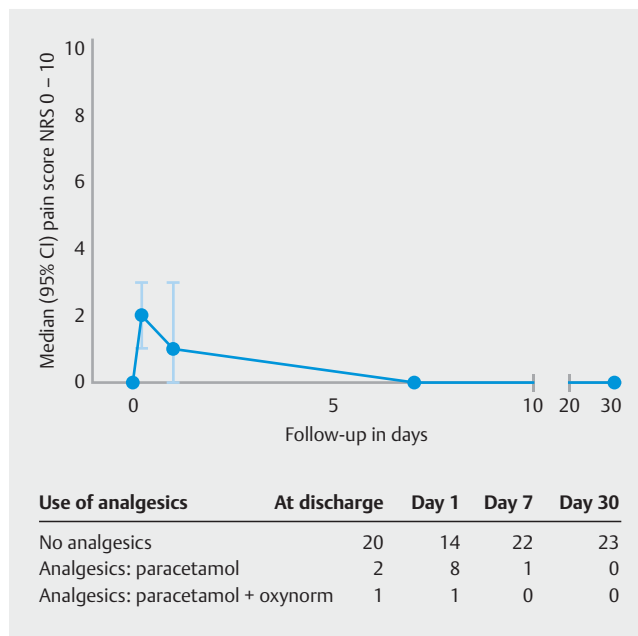
Discussion

This first-in-human study suggests that CbAS¹⁸⁰ is feasible, effective, and safe for the treatment of patients with BE-related neoplasia. Ablative therapy for dysplastic BE often starts with a large-area device, followed by subsequent focal treatment sessions to eradicate all remaining BE. Focal CbAS has been shown to be feasible, safe, and effective [7, 8]. Therefore, the addition of a large-area device is an important prerequisite for further maturation of the CbAS technique.

CbAS¹⁸⁰ enables the most extensive CbAS treatment currently possible. The area that is treated with a single CbAS¹⁸⁰ application has been doubled compared with the first large-area CbAS to be introduced, the CbAS⁹⁰ [9, 16]. With the CbAS¹⁸⁰ only two applications are required for circumferential treatment, reducing the risk of overlap of ablations and shortening the procedure time.

Single-session CbAS¹⁸⁰ at a dose of 1.0 mm/s resulted in median BE regression of 80% (95%CI 60%–90%), which appears comparable to that reported after single-session RFA (78%–90%) [12–14]. The BE regression percentage after one treatment session is a surrogate end point. In clinical daily practice, the final outcome of interest is complete eradication of IM [1]. However, to achieve complete eradication of IM, multiple treatment modalities will often be combined in consecutive treatment sessions, whereas for this dose-finding study we were solely interested in CbAS¹⁸⁰.

The stricture rate in the current study was low (4%). It is important to note that this stricture rate is based on single-session CbAS¹⁸⁰ with the extent of treatment limited to 3 cm. Hence, this stricture rate cannot be compared directly with the stricture rates reported for RFA with repetitive treatment sessions and stacked ablations to eradicate all BE [17]. Also, the percentage of patients that had prior endoscopic resection was lower than previously reported [18]. Because this study was designed as a dose-escalation study and the starting dose was already effective, we only evaluated a dose of 1.0 mm/s. It



► Fig. 3 Tolerability of the treatment in terms of retrosternal pain scores (graph) and analgesic use (table) in the days after the CbAS¹⁸⁰ treatment. NRS, numeric rating score; CI, confidence interval.

would be interesting to evaluate whether the dose could be lowered to optimally balance safety and efficacy.

The feasibility of CbAS¹⁸⁰ is reflected by a short procedure time (median 6 minutes to ablate the 3-cm segment) and high technical success rate (96%; 22/23). At the same time, this first-in-human application of CbAS¹⁸⁰ also revealed opportunities for refinement of the technique. Two patients could not be treated with CbAS¹⁸⁰ owing to unstable positioning of the cryoballoon at the GEJ (2/25; 8%). For focal CbAS, two different balloon shapes are available: the standard and pear-shaped balloon. For CbAS¹⁸⁰, only a standard straight balloon is currently available. Development of a pear-shaped CbAS¹⁸⁰ balloon might help to ensure stable positioning of the balloon at the GEJ and thereby lower the number of technical failures. Second, the occurrence of device malfunctions (3/23; 13%) was bothersome; however, continuous technical advancements decreased the frequency over the course of the study and even with these device malfunctions ablation time remained short.

One of the most important advantages of cryoballoon ablation is good patient tolerability. For focal CbAS, lower post-treatment pain and dysphagia scores are reported than for RFA [4]. The low post-treatment pain and dysphagia scores in this study are in accordance with these previous results.

Biopsies of the neosquamous epithelium were taken to evaluate the incidence of SIM after CbAS¹⁸⁰. In one patient, one of the four biopsies of the neosquamous epithelium potentially showed SIM. Yet, whether this truly represents SIM can be disputed. A study on the presence of SIM in neosquamous epithelium after RFA showed SIM in 21% of patients with remaining BE islands versus 0.1% of patients without endoscopic visible BE [19]. Because the patient in this study had remaining BE (medi-

an BE regression of 70%), it could well be that a biopsy was unintentionally taken from the remaining BE. Future studies with complete eradication of IM as the final outcome after consecutive CbAS treatments will result in more reliable data on the incidence of SIM after CbAS.

This is the first-in-human application of CbAS¹⁸⁰ and its relevance for the application of CbAS in daily practice is an important strength of this study. Furthermore, the study has been performed in a multicenter setting in BE expert centers and all CbAS¹⁸⁰ treatments were performed by experienced endoscopists. The BE regression percentages were assessed by independent expert endoscopists using images and videos, and histopathologic evaluation of biopsies was done by experienced BE pathologists.

This study is not without limitations. First, the 60% boundary to define the effective dose in this study is arbitrary. This boundary was based on BE regression percentages after single-session RFA treatment. Studies on single-session RFA treatment report BE regression percentages between 78% and 90% [12–14], including large BE segments. In our study, with the inclusion of only short BE segments, remaining BE islands have a larger impact on the BE regression percentage. Therefore, the boundary was adjusted accordingly. Other limitations mainly concern the generalizability of the study results as a consequence of choices made with regard to the study design and have already been addressed above. Most notably, for this dose-finding study, the surrogate end point BE regression after one treatment session was used to solely focus on CbAS¹⁸⁰ and, as this was the first clinical application of CbAS¹⁸⁰ treatment, the extent was limited to 3 cm.

Several next steps should be considered before introducing CbAS¹⁸⁰ into daily clinical practice. First, the results of the current study warrant further investigation of lower dosages for CbAS¹⁸⁰. Because the lowest dose within the CE-marked range was already effective, there seems to be room to optimize the safety profile by lowering the dose. Especially as the next steps, successive CbAS¹⁸⁰ treatment sessions to eradicate all BE and stacked ablations to treat larger BE segments, might increase the risk of stricture formation. Ultimately, one would want to combine CbAS¹⁸⁰ with subsequent CbAS¹⁸⁰ or focal CbAS treatment sessions, depending on the disease extent after initial treatment, and to evaluate the efficacy, safety, and durability with complete eradication of IM as the outcome parameter.

In conclusion, single-session CbAS¹⁸⁰ appears feasible, safe, and effective and is a promising technique for the treatment of patients with BE-related neoplasia. Further research on lower dosages is needed before its widespread application in patients with longer BE segments.

Acknowledgments

We kindly thank the members of the Adjudication Committee (Prof. Bisschops, Prof. Seewald, and Dr. Haidry) for their evaluations of the regression percentages.

Competing interests

A. Overwater has received reimbursement of study-related travel costs from Pentax Medical for an IRB-approved European, multicenter prospective study. J.J.G.H.M. Bergman has received research funding from Pentax, C2 Therapeutics, Medtronic, Aqua Medical, Olympus, and Fuji-film. B.L.A.M. Weusten has received research funding from Pentax, C2 Therapeutics, and Aqua Medical. The remaining authors declare that they have no conflict of interest.

Funding

Pentax Medical of America, Inc.

Clinical trial

Trial Registration: Netherlands National Trial Register (www.trialregister.nl) | Registration number (trial ID): NL6495 | Type of study: Prospective, single-arm, multi-center study

References

- [1] Weusten B, Bisschops R, Coron E et al. Endoscopic management of Barrett's esophagus: European Society of Gastrointestinal Endoscopy (ESGE) Position Statement. *Endoscopy* 2017; 49: 191–198
- [2] Fitzgerald RC, di Pietro M, Raganath K et al. British Society of Gastroenterology guidelines on the diagnosis and management of Barrett's oesophagus. *Gut* 2014; 63: 7–42
- [3] Shaheen NJ, Falk GW, Iyer PG et al. ACG Clinical Guideline: Diagnosis and management of Barrett's esophagus. *Am J Gastroenterol* 2016; 111: 30–50
- [4] van Munster SN, Overwater A, Haidry R et al. Focal cryoballoon versus radiofrequency ablation of dysplastic Barrett's esophagus: impact on treatment response and postprocedural pain. *Gastrointest Endosc* 2018; 88: 795–803.e2
- [5] Baust JG, Gage AA, Bjerklund Johansen TE et al. Mechanisms of cryoablation: clinical consequences on malignant tumors. *Cryobiology* 2014; 68: 1–11
- [6] Baust JG, Gage AA. The molecular basis of cryosurgery. *BJU Int* 2005; 95: 1187–1191
- [7] Künzli H, Schölvinck D, Meijer S et al. Efficacy of the CryoBalloon Focal Ablation System for the eradication of dysplastic Barrett's esophagus islands. *Endoscopy* 2016; 49: 169–175
- [8] Canto MI, Shaheen NJ, Almarino JA et al. Multifocal nitrous oxide cryoballoon ablation with or without EMR for treatment of neoplastic Barrett's esophagus (with video). *Gastrointest Endosc* 2018; 88: 438–446.e2
- [9] van Munster SN, Overwater A, Raicu MGM et al. A novel cryoballoon ablation system for eradication of dysplastic Barrett's esophagus: a first-in-human feasibility study. *Endoscopy* 2020; 52: 193–201
- [10] Persson J, Engström C, Bergquist H et al. Validation of instruments for the assessment of dysphagia due to malignancy of the esophagus. *Dis Esophagus* 2019; 32: doy125
- [11] Ogilvie AL, Dronfield MW, Ferguson R et al. Palliative intubation of oesophagogastric neoplasms at fiberoptic endoscopy. *Gut* 1982; 23: 1060–1067
- [12] van Vilsteren FGI, Alvarez Herrero L, Pouw RE et al. Predictive factors for initial treatment response after circumferential radiofrequency

- ablation for Barrett's esophagus with early neoplasia: a prospective multicenter study. *Endoscopy* 2013; 45: 516–525
- [13] Belghazi K, Pouw R, Sondermeijer C et al. A single-step sizing and radiofrequency ablation catheter for circumferential ablation of Barrett's esophagus: Results of a pilot study. *United Eur Gastroenterol J* 2018; 6: 990–999
- [14] van Vilsteren FGI, Phoa KN, Alvarez Herrero L et al. Circumferential balloon-based radiofrequency ablation of Barrett's esophagus with dysplasia can be simplified, yet efficacy maintained, by omitting the cleaning phase. *Clin Gastroenterol Hepatol* 2013; 11: 491–498.e1
- [15] von Elm E, Altman DG, Egger M et al. The Strengthening the Reporting of Observational Studies in Epidemiology (STROBE) Statement: Guidelines for reporting observational studies. *Int J Surg* 2014; 12: 1495–1499
- [16] Trindade A, Canto M. Circumferential treatment of long-segment Barrett's esophagus using the next-generation cryoballoon. *Endoscopy* 2019; 51: E69–E70
- [17] Qumseya BJ, Wani S, Desai M et al. Adverse events after radiofrequency ablation in patients with Barrett's esophagus: a systematic review and meta-analysis. *Clin Gastroenterol Hepatol* 2016; 14: 1086–1095.e6
- [18] Phoa KN, Pouw RE, Bisschops R et al. Multimodality endoscopic eradication for neoplastic Barrett oesophagus: results of an European multicentre study (EURO-II). *Gut* 2016; 65: 555–562
- [19] Pouw RE, Visser M, Odze RD et al. Pseudo-buried Barrett's post radiofrequency ablation for Barrett's esophagus, with or without prior endoscopic resection. *Endoscopy* 2014; 46: 105–109