

University of Groningen

## Limited diagnostic accuracy and clinical impact of single-operator peroral cholangioscopy for indeterminate biliary strictures

de Vries, Adriaan B; van der Heide, Frans; Ter Steege, Rinze W F; Koornstra, Jan Jacob; Buddingh, Karel T; Gouw, Annette S H; Weersma, Rinse K

*Published in:*  
Endoscopy

*DOI:*  
[10.1055/a-1061-7067](https://doi.org/10.1055/a-1061-7067)

**IMPORTANT NOTE: You are advised to consult the publisher's version (publisher's PDF) if you wish to cite from it. Please check the document version below.**

*Document Version*  
Publisher's PDF, also known as Version of record

*Publication date:*  
2020

[Link to publication in University of Groningen/UMCG research database](#)

### *Citation for published version (APA):*

de Vries, A. B., van der Heide, F., Ter Steege, R. W. F., Koornstra, J. J., Buddingh, K. T., Gouw, A. S. H., & Weersma, R. K. (2020). Limited diagnostic accuracy and clinical impact of single-operator peroral cholangioscopy for indeterminate biliary strictures. *Endoscopy*, 52(2), 107-114. <https://doi.org/10.1055/a-1061-7067>

### **Copyright**

Other than for strictly personal use, it is not permitted to download or to forward/distribute the text or part of it without the consent of the author(s) and/or copyright holder(s), unless the work is under an open content license (like Creative Commons).

The publication may also be distributed here under the terms of Article 25fa of the Dutch Copyright Act, indicated by the "Taverne" license. More information can be found on the University of Groningen website: <https://www.rug.nl/library/open-access/self-archiving-pure/taverne-amendment>.

### **Take-down policy**

If you believe that this document breaches copyright please contact us providing details, and we will remove access to the work immediately and investigate your claim.

Downloaded from the University of Groningen/UMCG research database (Pure): <http://www.rug.nl/research/portal>. For technical reasons the number of authors shown on this cover page is limited to 10 maximum.

# Limited diagnostic accuracy and clinical impact of single-operator peroral cholangioscopy for indeterminate biliary strictures

## Authors

Adriaan B. de Vries<sup>1</sup>, Frans van der Heide<sup>1</sup>, Rinze W. F. ter Steege<sup>2</sup>, Jan Jacob Koornstra<sup>1</sup>, Karel T. Buddingh<sup>3</sup>, Annette S. H. Gouw<sup>4</sup>, Rinse K. Weersma<sup>1</sup>

## Institutions

- 1 Department of Gastroenterology and Hepatology, University Medical Center Groningen, Groningen, The Netherlands
- 2 Department of Gastroenterology and Hepatology, Martini Ziekenhuis, Groningen, The Netherlands
- 3 Department of Urology, HagaZiekenhuis, Den Haag, The Netherlands
- 4 Department of Pathology, University Medical Center Groningen, Groningen, The Netherlands

submitted 10.1.2019

accepted after revision 14.10.2019

## Bibliography

DOI <https://doi.org/10.1055/a-1061-7067>

Published online: 13.12.2019 | *Endoscopy* 2020; 52: 107–114

© Georg Thieme Verlag KG Stuttgart · New York

ISSN 0013-726X

## Corresponding author

A. B. de Vries, MD, Department of Gastroenterology and Hepatology, University Medical Center Groningen, Groningen, The Netherlands

Fax: +31-50-3619331

[a.b.de.vries01@umcg.nl](mailto:a.b.de.vries01@umcg.nl)

 Supplementary material

Online content viewable at:

<https://doi.org/10.1055/a-1061-7067>

## ABSTRACT

**Background** Single-operator peroral cholangioscopy (sPOCS) is considered a valuable diagnostic modality for indeterminate biliary strictures. Nevertheless, studies show large variation in its characteristics and measures of diagnostic accuracy. Our aim was to estimate the diagnostic accuracy of sPOCS visual assessment and targeted biopsies for indeterminate biliary strictures. Additional aims were: estimation of the clinical impact of sPOCS and comparison of diagnostic accuracy with brush cytology.

**Methods** A retrospective single-center study of adult patients who underwent sPOCS for indeterminate biliary strictures was performed. Diagnostic accuracy was defined as sensitivity, specificity, positive predictive value (PPV), and negative predictive value (NPV). The clinical impact of sPOCS was assessed by review of medical records, and classified according to its influence on patient management.

**Results** 80 patients were included, with 40% having primary sclerosing cholangitis (PSC). Prior ERCP was performed in 88%, with removal of a biliary stent prior to sPOCS in 55%. The sensitivity, specificity, PPV, and NPV for sPOCS visual impression and targeted biopsies were 64%, 62%, 41%, and 84%, and 15%, 65%, 75%, and 69%, respectively. The clinical impact of sPOCS was limited; outcome changed management in 17% of patients. Sequential brush cytology sensitivity, specificity, PPV, and NPV were 47%, 95%, 80%, and 83%.

**Conclusions** The diagnostic accuracy of sPOCS for indeterminate biliary strictures was found to be inferior to brush cytology, with a low impact on patient management. These findings are obtained from a select patient population with a high prevalence of PSC and plastic stents in situ prior to sPOCS.

## Introduction

Indeterminate biliary strictures are strictures of the intra- or extrahepatic bile ducts with no mass or lesion detectable on abdominal imaging, and without a clear explanation from the clinical context (e.g. traumatic or iatrogenic causes of biliary strictures, such as recent surgery), in which conventional work-up is non-diagnostic [1, 2]. The main goal of diagnostic work-up is to establish or exclude a malignant etiology. Strictures in the context of primary sclerosing cholangitis (PSC) require additional

vigilance, as these patients have an increased risk of developing cholangiocarcinoma.

Although several approaches have been proposed, the optimal diagnostic work-up for indeterminate biliary strictures has not been established [2, 3]. Conventional imaging consists of computed tomography (CT) and magnetic resonance cholangiopancreatography (MRCP), with the aim of establishing vascular and other organ involvement. Diagnosis of an indeterminate stricture relies on tissue sampling, often through brush cy-

tology during endoscopic retrograde cholangiopancreatography (ERCP).

While the specificity of brush cytology is high, it is hampered by a low sensitivity of 45%, resulting in frequent false-negative results [4]. Curative treatment for malignant strictures consists of major surgery or, in selected cases, liver transplantation. Nonetheless, the prognosis of pancreaticobiliary malignancy is poor as detection of early stage disease is difficult and a minority of patients present with resectable tumors at the time of diagnosis [5]. These factors can cause a tendency for early surgical treatment in the setting of negative brush cytology to prevent treatment delay. This carries a risk of unnecessary surgical treatment for benign disease, which is estimated to occur in 15% of patients with presumed perihilar cholangiocarcinoma [6] and in 5%–10% with presumed pancreatic cancer [7].

Single-operator peroral cholangioscopy (sPOCS) allows direct visualization of the luminal bile ducts in combination with tissue sampling through targeted biopsies. Several authors have reported sPOCS to be a valuable addition in the diagnostic work-up of indeterminate biliary strictures, finding an improved diagnostic yield over ERCP with brush cytology [8–11]. Although these results are promising, the studies have had a large variation in population size, disease definition, and reported outcome parameters. Furthermore, the impact of sPOCS on patient management is scarcely reported. Insight into these parameters is important to determine the efficacy of a diagnostic modality such as sPOCS, and its place in the diagnostic work-up for indeterminate biliary strictures.

The aim of this study was to estimate the diagnostic accuracy of sPOCS visual assessment and targeted biopsies for indeterminate biliary strictures. In addition, the clinical impact of sPOCS on patient management and comparison with the diagnostic accuracy of brush cytology were evaluated.

## Methods

A retrospective single-center open-label cohort study was performed in all patients examined with sPOCS for indeterminate biliary strictures at our tertiary referral center between November 2007 and September 2018. Indeterminate biliary strictures were defined as strictures of the intra- or extrahepatic bile ducts with no mass or lesion detectable on abdominal imaging, in which conventional work-up was non-diagnostic.

### Main outcome

The main outcome parameter was the diagnostic accuracy of sPOCS visual assessment and targeted biopsies of indeterminate biliary strictures. The pathology report of the surgical resection specimen was considered the gold standard. Apart from resection specimens, percutaneous biopsies or biopsies taken during exploratory surgery that were positive for malignant disease were also considered the gold standard. Strictures in patients who did not undergo surgical treatment that showed no development of malignant features during 6 months of follow-up were considered benign.

Additional outcomes were: the clinical impact of sPOCS on the management of patients with indeterminate biliary strictures,

and a comparison between the diagnostic accuracy of sPOCS and that of standard brush cytology.

### Patients

Patients  $\geq 18$  years who underwent sPOCS for an indeterminate biliary stricture were included. Patients without a diagnosis and with follow-up of less than 6 months after undergoing sPOCS were excluded. The diagnosis of PSC was based on the criteria established in international guidelines [12]. Although strictures developing in PSC cannot strictly be deemed of indeterminate cause, the diagnostic challenge is similar to strictures developing in patients without PSC. In clinical practice, both groups are frequently referred for diagnostic work-up. Therefore, PSC was not seen as an exclusion criterion.

### Data collection

Data on the endoscopic procedure, histopathology, and follow-up were gathered retrospectively from the medical records. All CT, MRCP, ERCP, and endoscopic ultrasound (EUS) procedures performed for diagnosis of the indeterminate biliary stricture within 12 months prior to the sPOCS were recorded. In patients with multiple sPOCS procedures, only data from the first successful procedure were recorded.

All patient data were recorded anonymously. Because of the retrospective nature of this study no additional permission from the institutional review board was required.

### Cholangioscopy procedure

Procedures were performed with the patient under conscious sedation, general anesthesia, or propofol sedation. ERCP was performed with a side-viewing duodenoscope (Olympus). When present, plastic biliary stents were removed at the start of the procedure. Patients received ceftriaxone prophylaxis before the procedure.

After cannulation and contrast cholangiography, a cholangioscope was inserted via the “mother–baby” technique [13]. All procedures were performed with the image fiber-based SpyGlass and second-generation digital SpyGlass DS cholangioscopy systems (Boston Scientific Netherlands BV, Kerkrade). The SpyGlass DS offers a markedly improved imaging quality in comparison to the first generation and was used from October 2016 onward in our center. The endoscopists (R.W., R.t.S., F.v.d.H.) were not blinded to the patient’s clinical history and previous diagnostic results. A standardized report was used by all endoscopists performing sPOCS, which included stricture features, presence of neovascularization, and suspected etiology. Adverse events within 14 days of the procedure were noted.

### sPOCS visual impression and targeted biopsies

Previously published visual features were used to distinguish benign from malignant strictures. The presence of irregular, vulnerable, or polypoid tissue were deemed consistent with a malignant etiology [14]. Special attention was paid to the presence of neovascularization as this has been associated with malignant etiology [14,15]. At the present time, no validated criteria for sPOCS visual assessment exist. The preliminary diag-

nosis based on visual impression was gathered from endoscopy reports and recorded as malignant, benign, or inconclusive.

Targeted biopsies of the strictures were obtained under direct view using a specific biopsy forceps (SpyBite; Boston Scientific Netherlands BV, Kerkrade). The number of biopsies taken was left to the discretion of the endoscopist performing the procedure. When possible, brush cytology was performed after sPOCS. Biopsies and brush cytology were suspended in Cytolyt (Hologic Inc., Marlborough, Massachusetts, USA).

## Histopathological examination

The majority of histopathological analyses were performed by an experienced hepatobiliary pathologist (A.G.). Based on the pathology report, biopsy and brush results were classified as malignant, benign, or inconclusive; the number of biopsies received was also recorded. Reactive changes and atypical cells were considered benign unless the pathologist expressed a strong suspicion of malignancy. Results were deemed inconclusive when the specimen was inadequate for histopathological analysis owing to small size or low tissue yield.

## Clinical impact

The impact of sPOCS on patient management was evaluated by review of medical records by the first author (A.B.d.V.), who did not partake in the clinical care of the included patients. The impact of sPOCS was classified into three categories: (1) change in, (2) confirmation of, or (3) no influence on patient manage-

ment. A change in patient management was defined as the sPOCS (visual impression and/or targeted biopsies) being the sole reason for a change in management, for example finding malignant cells on the sPOCS biopsy when previous tissue sampling had shown benign findings. Confirmation was defined as the sPOCS confirming a previous diagnosis, for example the sPOCS yielding benign findings consistent with previous brush cytology or imaging. No influence was defined as an sPOCS outcome that did not confirm the diagnosis or result in a change in patient management, for example the results of the sPOCS were unclear or the sPOCS was followed by repeated diagnostic modalities because the diagnosis remained unclear. The clinical impact of sPOCS was recorded as unknown when it could not be deduced from medical records.

## Statistical analysis

Diagnostic accuracy was defined as sensitivity, specificity, positive predictive value (PPV), and negative predictive value (NPV), all of which are reported with a 95% confidence interval (CI). Sensitivity and specificity were calculated with an intention-to-diagnose analysis, including inconclusive results [16]. In addition, likelihood ratios, post-test probabilities, and number-needed-to-diagnose were calculated, allowing for extensive quantification of diagnostic accuracy [17] (**Table 1s**; see online-only Supplementary material). Statistical analysis was performed with SPSS 23.0 (IBM, Armonk, New York, USA).

## Results

### Patients

Between November 2007 and September 2018, a total of 185 sPOCS procedures were performed in our center, among these 86 patients underwent sPOCS for the evaluation of an indeterminate biliary stricture. After the exclusion of six patients who did not have a histopathological diagnosis and had not been followed up for at least 6 months, 80 patients were included for analysis. The majority of patients were men and PSC was present in 40%. A previous ERCP had been performed in 88% of the patients, with brush cytology being the most common form of tissue sampling prior to sPOCS. A plastic biliary stent was in situ and removed prior to sPOCS in 44 patients (55%). The characteristics of the included patients are summarized in **Table 1**.

### Outcome

The location of the biliary strictures and their etiology are presented in **Table 2**. There were 22 patients (28%) diagnosed with a malignant stricture and four patients (5%) had a premalignant lesion. A benign stricture was found in 43 patients (54%), including inflammatory causes and dominant strictures in PSC. Eight patients (10%) had bile duct stones; no visible stenosis was seen during cholangioscopy in three patients (4%).

### sPOCS procedure details

sPOCS for indeterminate strictures was performed with first-generation SpyGlass (Legacy) cholangioscopy system in 66 patients and the second-generation SpyGlass DS in 14 patients. Cholangioscopy was performed with the patients under con-

**Table 1** Characteristics of the 80 patients who underwent single-operator peroral cholangioscopy (sPOCS) for diagnosis of an indeterminate biliary stricture.

Patient characteristics	
Sex, male, n (%)	52 (65%)
Age, median (IQR), years	59.5 (46–68.75)
Follow-up, median (IQR), months	31 (13.25–50)
Deceased during follow-up, n (%)	26 (33%)
Primary sclerosing cholangitis, n (%)	32 (40%)
Previous imaging, n (%)	
▪ MRCP	50 (63%)
▪ CT	50 (63%)
Previous endoscopic procedures, n (%)	
▪ ERCP	70 (88%)
▪ ERCP > 1	29 (36%)
▪ EUS	31 (39%)
Previous pathological examinations, n (%)	
▪ ERCP-guided brush cytology	48 (60%)
▪ EUS-FNA	11 (14%)

IQR, interquartile range; MRCP, magnetic resonance cholangiopancreatography; CT, computed tomography; ERCP, endoscopic retrograde cholangiopancreatography; EUS, endoscopic ultrasound; FNA, fine needle aspiration.

► **Table 2** Stricture location and etiology for the 80 included patients.

Stricture characteristics	
Location of indeterminate biliary stricture, n (%)	
▪ Hilar	36 (45%)
▪ Mid CBD	14 (18%)
▪ Distal CBD	21 (26%)
▪ Intrahepatic	3 (4%)
▪ Diffuse/multifocal	6 (7%)
Stricture etiology, n (%)	
▪ Cholangiocarcinoma	17 (21%)
▪ Other malignant lesion <sup>1</sup>	5 (6%)
▪ Premalignant lesion <sup>2</sup>	4 (5%)
▪ Benign stricture	18 (23%)
▪ Dominant stricture in PSC	20 (25%)
▪ Inflammatory <sup>3</sup>	5 (6%)
▪ Stone	8 (10%)
▪ No visible stricture during sPOCS	3 (4%)

CBD, common bile duct; PSC, primary sclerosing cholangitis; sPOCS, single-operator peroral cholangioscopy.

<sup>1</sup> Metastasis of occult colon carcinoma (n = 1); chloroma (n = 1); recurrence gallbladder carcinoma (n = 1); suspected cholangiocarcinoma but no definitive pathological diagnosis or resection (n = 2).

<sup>2</sup> Intraductal papillary mucinous neoplasm of the bile duct (n = 2); low grade dysplastic adenoma (n = 1); focal high grade dysplasia (n = 1).

<sup>3</sup> IgG4-mediated disease (n = 2); chronic inflammation (n = 1); reactive secondary sclerosis (n = 2).

scious sedation (n = 51 [64%]) and under propofol sedation or general anesthesia (n = 29 [36%]). Visibility during sPOCS was considered good in 70 patients (88%), reasonable in eight (10%), and poor in two (2%).

### sPOCS visual assessment

The diagnostic accuracy of sPOCS visual assessment is summarized in ► **Table 3**. Stricture visual assessment was specified in 80 patients, with 34 having malignant features and 43 showing benign features. In three patients (4%), sPOCS visual assessment was inconclusive. The sensitivity and specificity for sPOCS visual assessment were 64% (95%CI 44%–84%) and 62% (95%CI 50%–75%), respectively. The PPV was 41% (95%CI 25%–58%) and the NPV was 84% (95%CI 73%–95%). Previous studies [8–11, 14, 18–24] reporting on diagnostic accuracy of sPOCS visual assessment for indeterminate biliary strictures are summarized in ► **Table 4**.

### Neovascularization

Neovascularization was seen in 28 patients (35%) during sPOCS visual assessment. Of these 28 patients, 20 (71%) had a stent in situ that was removed prior to sPOCS. In the 52 patients without neovascularization, 24 (46%) had a stent in situ prior to sPOCS procedure. In the 22 patients with a malignant biliary

stricture, 12 (55%) had signs of neovascularization. In the 58 patients with a benign biliary stricture, 16 (28%) had signs of neovascularization.

### sPOCS targeted biopsies

Cholangioscopic targeted biopsies were taken in 57 patients as is shown in ► **Table 3**. The number of biopsies was specified in 43 patients, with a median of three biopsies (IQR 2–5) per patient. Targeted biopsies yielded malignant cells in four patients and benign findings in 35 patients. In 18 patients (33%), the biopsies were insufficient for pathological assessment. This resulted in a sensitivity of 15% (95%CI 0%–31%), a specificity of 65% (95%CI 49%–80%), and a PPV and NPV of 75% (95%CI 33%–100%) and 69% (95%CI 53%–84%), respectively. Previous studies [8–11, 14, 18–24] that have reported on the diagnostic accuracy of sPOCS targeted biopsies for indeterminate biliary strictures are summarized in ► **Table 4**.

### Clinical impact of sPOCS

The impact of the sPOCS visual assessment and targeted biopsy result was retrieved by review of medical charts in 77 patients. In 13 patients (17%), the outcome resulted in a change of patient management. In contrast, for 25 patients (32%), the outcome of sPOCS did not influence patient management or confirm a previously established diagnosis, resulting in subsequent diagnostic procedures being performed. In 39 patients (51%), sPOCS resulted in confirmation of the previous findings and the chosen patient management.

### Sequential brush cytology

The diagnostic accuracy of brush cytology performed during the ERCP sPOCS procedure is shown in ► **Table 3**. Brush cytology was performed in 58 patients. Cytology yielded malignant cells in 10 patients (17%), benign results in 47 patients (81%) and was inconclusive in one patient (2%). The sensitivity was 47% (95%CI 23%–71%) and the specificity was 95% (95%CI 89%–100%). The PPV was 80% (95%CI 55%–100%) and NPV was 83% (95%CI 72%–94%). Two false-positive brush results were seen in patients without PSC but with a plastic stent in situ prior to the sPOCS procedure.

### Adverse events

A total of 10 patients (13%) suffered adverse events after the sPOCS procedure. These were mild in six patients (8%) who had self-limiting myalgia and abdominal pain, and serious in three patients (4%), with two episodes of bacterial cholangitis and one of post-ERCP pancreatitis. A further severe complication was seen in one patient who suffered a cardiac arrest during cholangioscopy followed by a stroke. The patient recovered with minimal neurological disability but later died from progressive malignant biliary disease.

## Discussion

In this single-center retrospective cohort study, the diagnostic accuracy and clinical impact of sPOCS in a population of 80 patients with indeterminate biliary strictures was evaluated. This

**► Table 3** Comparison of single-operator peroral cholangioscopy (sPOCS) visual impression and targeted biopsy, and brush cytology: **a** vs. the gold-standard diagnosis; **b** summary of accuracy measures.

<b>(a)</b>										
		sPOCS visual impression (n = 80)			sPOCS biopsy (n = 57)			Brush cytology (n = 58)		
		M	B	I	M	B	I	M	B	I
Gold standard	M	14	7	1	3	11	6	8	8	1
	B	20	36	2	1	24	12	2	39	0
<b>(b)</b>										
Sensitivity (95%CI)		64% (44–84)			15% (0–31)			47% (23–71)		
Specificity (95%CI)		62% (50–75)			65% (49–80)			95% (89–100)		
PPV (95%CI)		41% (25–58)			75% (33–100)			80% (55–100)		
NPV (95%CI)		84% (73–95)			69% (53–84)			83% (72–94)		
Accuracy		63%			47%			81%		
LR+		1.9			5.5			9.7		
LR-		0.5			0.9			0.5		
DOR		3.6			6.6			19.6		
NND		3.4			8.1			2.4		
ΔPPPTP		14%			40%			51%		
ΔNPPTP		12%			3%			12%		

M, malignant; B, benign; I, inconclusive; CI, confidence interval; PPV, positive predictive value; NPV, negative predictive value; LR+, positive likelihood ratio; LR-, negative likelihood ratio; DOR, diagnostic odds ratio; NND, number needed to diagnose; ΔPPPTP, difference between positive post- and pre-test probability; ΔNPPTP, difference between negative post- and pre-test probability.

study population represents a difficult-to-diagnose subset of patients with a high prevalence of PSC and prior stenting. In 22 patients a malignant stricture was diagnosed, resulting in a disease prevalence of 28%.

An appealing feature of sPOCS is the direct impression of a biliary stricture it offers, allowing for a visual diagnosis. A prospective multicenter study reported a sensitivity and specificity of 78% and 88%, respectively, for sPOCS visual assessment in 95 patients with indeterminate biliary strictures [8]. Another prospective study in 45 patients showed a sensitivity and specificity of 83% [18]. The yield of sPOCS visual assessment for indeterminate biliary strictures in our cohort was lower, for which we believe the cause to be twofold.

First, a plastic stent was present and removed prior to sPOCS in 55% of our patients. In our experience, stents affect the biliary epithelium through friction, and these changes can be mistaken for neoplastic changes, hampering visual assessment and increasing the rate of false-positive diagnosis. This is supported by our frequent finding of neovascularization in patients without a malignant stricture but with a stent in situ prior to sPOCS. Both the presence of a stent prior to sPOCS and its effect on visual assessment is scarcely reported. One study found no visible effects of stents during sPOCS assessment [19]; however, only 13% of their patients had a previous stent and the time of removal was not specified.

Second, the prevalence of PSC in comparison to previous studies is high [18, 19]. In our experience, sPOCS visual assess-

ment is difficult in PSC. This is supported by our comparison of sPOCS in PSC and non-PSC patients, where we found the lowest sensitivity and specificity in the former (**Table 2s**). A prospective study with 47 PSC patients showed similar results and found that sPOCS visual assessment was insufficient to differentiate between benign and malignant strictures [25]. The difficulty of visual assessment for indeterminate strictures is illustrated in ► **Fig. 1**, which shows sPOCS images and cholangiograms with different outcomes.

The diagnostic accuracy of sPOCS targeted biopsies in our study was low, with a high number of inconclusive results. Studies reporting the sensitivity of sPOCS targeted biopsies in indeterminate biliary lesions show a large variation ranging from 48%–85%, with an approximate specificity of 90% [8, 11, 18]. A comparison of these results is difficult, as the criteria for pathological assessment and the methods for processing targeted biopsies are poorly reported. In the present study, malignant cells or atypical cells with a strong suspicion of malignancy were classified as malignant; atypical cells without specification were classified as benign. We believe this classification represents daily practice most accurately, as atypia is insufficient to establish a malignant diagnosis [26].

The large number of inconclusive results primarily affected specificity as the number of false-positive biopsies was low. This is illustrated by the exclusion of inconclusive results, which increased the sensitivity and specificity of cholangioscopic targeted biopsies to 21.4% and 95.6%, respectively. Although un-

► **Table 4** Previous studies of single-operator peroral cholangioscopy (sPOCS) for indeterminate biliary strictures.

Author	Design: Pro- vs. retrospective; multi- vs. single center	Patients in study (with PSC)	sPOCS generation	sPOCS visual assessment		sPOCS biopsy	
				Sensitivity	Specificity	Sensitivity	Specificity
Chen [8]	Pro; multi	226 <sup>1</sup> (N/S)	1st	78 %	82 %	49 %	98 %
Ramchandani [14]	Pro; single	36 (2)	1st	95 %	79 %	82 %	82 %
Kalaitzakis [10]	Retro; multi	130 (16)	1st	N/S	N/S	43 %	100 %
Draganov [9]	Pro; single	26 (Excluded)	1st	N/S	N/S	77 %	100 %
Hartman [21]	Retro; single	89 <sup>2</sup> (N/S)	1st	88 %	86 %	57 %	100 %
Manta [22]	Pro; single	52 (N/S)	1st	N/S	N/S	88 %	94 %
Woo [23]	Retro; single	31 (N/S)	1st	100 %	90 %	64 %	100 %
Navaneethan [20]	Retro; multi	44 (8)	2nd	90 %	96 %	85 %	100 %
Kurihara [11]	Pro; multi	89 (3)	1st	95 %	93 %	65 %	89 %
Laleman [18]	Retro; single	45 (14)	1st	83 %	83 %	85 %	100 %
Shah [24]	Retro; multi	74 <sup>3</sup> (6)	2nd	97 %	93 %	86 %	100 %
Robles-Medranda [19]	Pro; single	106 (0)	2nd	96 %	92 %	83 %	98 %
Present paper	Retro; single	80 (32)	Both	64 %	62 %	15 %	65 %

PSC, primary sclerosing cholangitis; N/S, not specified.

<sup>1</sup> Sensitivity, specificity of sPOCS visual assessment and biopsy was calculated on a subset of 95 patients in whom ERCP impression, sPOCS visual assessment and sPOCS biopsy and a final diagnosis was available.

<sup>2</sup> SpyBite biopsies were taken in 29 patients.

<sup>3</sup> SpyBite biopsies were taken in 49 patients.

desirable from a methodological standpoint, it shows that our results for targeted biopsies are representative, as their specificity is similar to that of brush cytology and previously reported data [4, 20]. A review of targeted biopsy methods and processing did not reveal an explanation for the large number of inconclusive samples. The analysis of second-generation sPOCS did however reveal a trend toward a higher number of biopsies and lower rate of inconclusive samples (**Table 3s**). This is supported by a previous study, which found less inconclusive results when at least four targeted biopsies were taken [10]. In addition, studies reporting the lowest rates (<6%) of inconclusive samples, took a minimum of four biopsies [18, 19]. The number of biopsies taken in the present study are a likely explanation for the high number of inconclusive samples. Based on these findings we therefore recommend a minimum of four biopsies be taken during sPOCS, ideally with a pathologist on site to examine the yield.

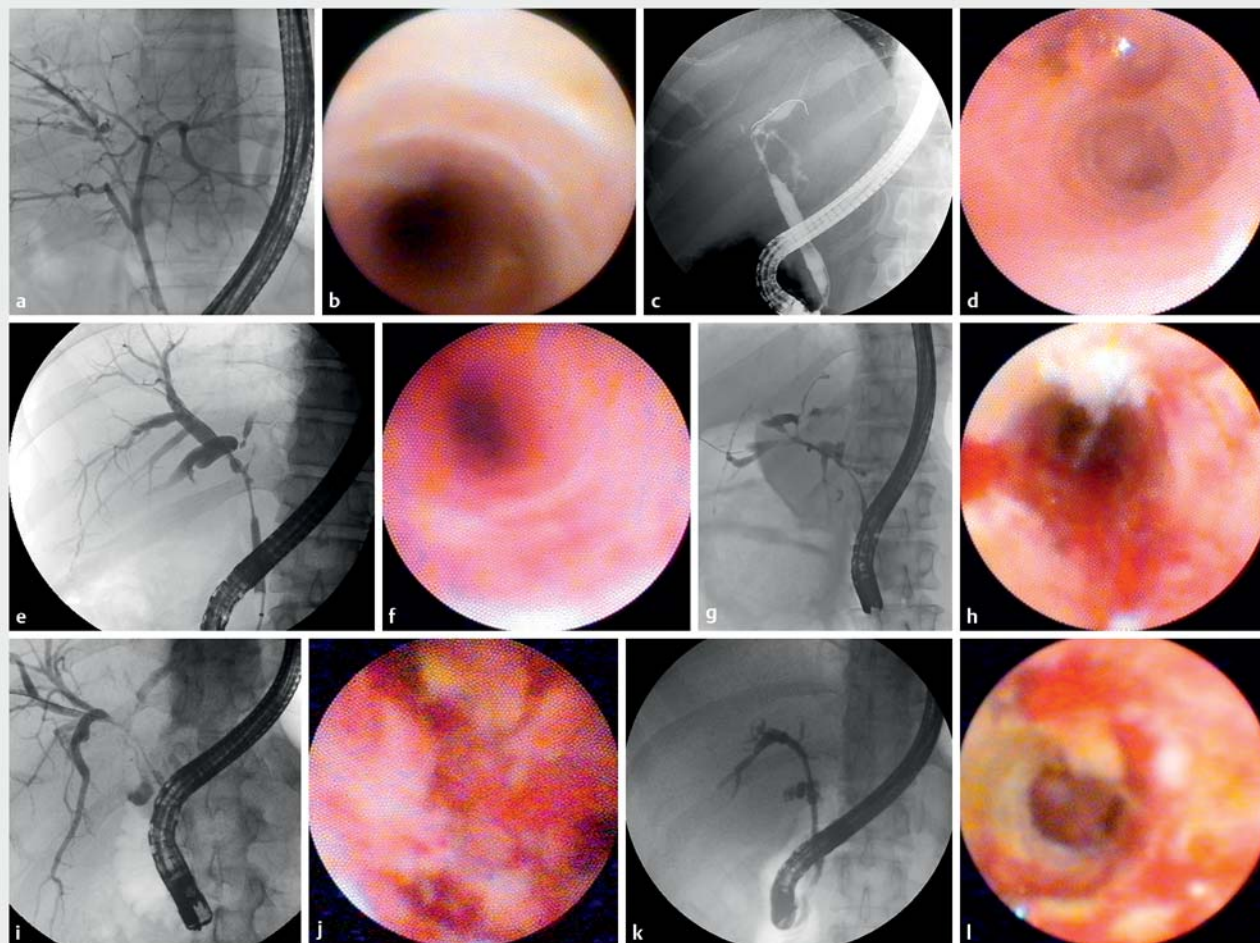
Previous studies have reported sPOCS to be a valuable utility for indeterminate biliary strictures based on sensitivity, specificity, and accuracy [10, 11, 18]. These parameters give insight into test performance but lack information on the clinical impact, which is a scarcely reported outcome for sPOCS. In our cohort, the impact of sPOCS was limited, as the outcome resulted in a change of management in only 17% of the patients. A previous study found that sPOCS altered clinical management in 64% of the patients [8] but, as this was based on the judgement of the attending investigators, a possible overestimation of the impact of sPOCS cannot be excluded.

The cost of sPOCS is estimated to be €4680 (\$5482) per patient [27]. As healthcare costs in the Western world continue to rise, the incorporation of a diagnostic modality into the standard of care should be carefully evaluated. Future prospective studies should therefore determine the impact of sPOCS and its cost-effectiveness, in addition to the commonly reported parameters of test validity.

To our knowledge, only one previous study has reported the results of sPOCS and sequential brush cytology for indeterminate biliary strictures [9], with a sensitivity of 5.8% for brush cytology and 76.5% for sPOCS targeted biopsies. The present study found the diagnostic accuracy of brush cytology to be superior to the diagnostic accuracy of sPOCS visual assessment and targeted biopsies. Our results for the diagnostic accuracy of brush cytology were comparable to those found in a systematic review [4], which reported a pooled sensitivity and specificity of 45% and 99% for brush cytology in malignant strictures.

Adverse effects after an ERCP sPOCS procedure were seen in 13% of the patients in our study. The reported rate of adverse events for sPOCS ranges widely, from 2.8% [19] to 21.4% [18], based on differences in definition and registration.

The present study has several limitations that should be taken into account. First, our data has been gathered over an extended period of time, with two generations of sPOCS devices being used. The majority of procedures were performed with first-generation cholangioscopes, which has a reduced image quality compared with the second-generation device, and could have resulted in lower diagnostic accuracy for both visual assess-



► **Fig. 1** Examples illustrating the difficulties of visual assessment for indeterminate strictures using single-operator peroral cholangioscopy (sPOCS) visual assessment are shown with radiographic images (**a, c, e, g, i, k**) and the corresponding cholangioscopic appearance (**b, d, f, h, j, l**) for cases that turned out to be: **a, b** a true-negative sPOCS visual assessment, (benign impression and benign etiology); **c–f** false-negative sPOCS visual assessments (benign impression and malignant etiology); **g, h** a true-positive sPOCS visual assessment (malignant impression and malignant etiology); **i–l** false-positive sPOCS assessments (malignant impression and benign etiology).

ment and targeted biopsies. It is important to note however that, as can be seen in ► **Table 4**, only a small proportion of the previous studies were performed with the second-generation cholangioscopes. The perceived value of sPOCS for indeterminate biliary strictures is therefore largely based on results from studies performed with first-generation cholangioscopes.

A second limitation of our study is that endoscopists and pathologists were not blinded to the results of previous diagnostic tests, which could have influenced their assessment of the visual features and tissue samples. Although methodologically suboptimal, this reflects clinical practice as endoscopists and pathologists are never blinded to previous diagnostic results. Furthermore, we would expect non-blinding to increase the diagnostic accuracy of sPOCS. In contrast, diagnostic accuracy was found to be lower in comparison to previous studies.

Another limitation is the high prevalence of stents prior to the sPOCS procedure, which is a potential confounder that could influence the diagnostic accuracy of sPOCS visual impres-

sion, targeted biopsies, and brush cytology. The recent removal of a plastic biliary stent or the procurement of targeted biopsies could result in a higher yield of the subsequently performed brush cytology. The presence of stents prior to sPOCS is inherent in clinical practice as the majority of patients are referred when their initial diagnostic work-up has proved inconclusive and an ERCP and stent placement have already been performed. The present study did not find an increase in the diagnostic accuracy of brush cytology in comparison to previous studies; however, a potential influence of stents or biopsy on the diagnostic yield of brush cytology cannot be excluded and should be evaluated in future studies.

Finally, as our data were collected in a tertiary referral center, there is a risk of selection bias that could have negatively impacted the diagnostic accuracy of sPOCS. In addition, there is a high prevalence of PSC. Both of these limitations are difficult to circumvent as an indeterminate biliary stricture, with or without PSC, is a challenging and complex disease, which re-



quires the advanced modalities and experienced clinicians more often found in specialized centers. Therefore, we believe our study population accurately represents the group of patients encountered in clinical practice for whom diagnostic sPOCS was intended.

In conclusion, we found the diagnostic accuracy of sPOCS for indeterminate biliary strictures to be inferior to brush cytology and to have a low impact on patient management. Our findings are obtained from a select patient population with indeterminate biliary strictures, and with a high prevalence of PSC and plastic stents in situ prior to sPOCS. Based on our results, we advocate the initiation of future prospective studies to further determine the diagnostic accuracy and cost benefit of diagnostic sPOCS, before incorporating this modality as a standard of care for indeterminate biliary strictures.

## Acknowledgments

The authors gratefully acknowledge the contributions of Ms. S. Hintzen in her support with data extraction from the endoscopy database and Ms. F. M. Toxopeus for her help with study registration in our local research database.

## Competing interests

The authors declare that they have no conflict of interest.

## References

- [1] Levy MJ, Baron TH, Clayton AC et al. Prospective evaluation of advanced molecular markers and imaging techniques in patients with indeterminate bile duct strictures. *Am J Gastroenterol* 2008; 103: 1263–1273
- [2] Bowlus CL, Olson KA, Gershwin ME. Evaluation of indeterminate biliary strictures. *Nat Rev Gastroenterol Hepatol* 2016; 13: 28–37
- [3] Coté GA, Sherman S. Biliary stricture and negative cytology: What next? *Clin Gastroenterol Hepatol* 2011; 9: 739–743
- [4] Navaneethan U, Njei B, Lourdasamy V et al. Comparative effectiveness of biliary brush cytology and intraductal biopsy for detection of malignant biliary strictures: A systematic review and meta-analysis. *Gastrointest Endosc* 2015; 81: 168–176
- [5] Rizvi S, Eaton J, Yang JD et al. Emerging technologies for the diagnosis of perihilar cholangiocarcinoma. *Semin Liver Dis* 2018; 38: 160–169
- [6] Roos E, Hubers LM, Coelen RJS et al. IgG4-associated cholangitis in patients resected for presumed perihilar cholangiocarcinoma: a 30-year tertiary care experience. *Am J Gastroenterol* 2018; 113: 765–772
- [7] Wolfson D, Barkin JS, Chari ST et al. Management of pancreatic masses. *Pancreas* 2005; 31: 203–217
- [8] Chen YK, Parsi MA, Binmoeller KF et al. Single-operator cholangioscopy in patients requiring evaluation of bile duct disease or therapy of biliary stones (with videos). *Gastrointest Endosc* 2011; 74: 805–814
- [9] Draganov PV, Chauhan S, Wagh MS et al. Diagnostic accuracy of conventional and cholangioscopy-guided sampling of indeterminate biliary lesions at the time of ERCP: A prospective, long-term follow-up study. *Gastrointest Endosc* 2012; 75: 347–353
- [10] Kalaitzakis E, Webster GJ, Oppong KW et al. Diagnostic and therapeutic utility of single-operator peroral cholangioscopy for indeterminate biliary lesions and bile duct stones. *Eur J Gastroenterol Hepatol* 2012; 24: 656–664
- [11] Kurihara T, Yasuda I, Isayama H et al. Diagnostic and therapeutic single-operator cholangiopancreatography in biliopancreatic diseases: Prospective multicenter study in Japan. *World J Gastroenterol* 2016; 22: 1891–1901
- [12] Chapman R, Fevery J, Kalloo A et al. Diagnosis and management of primary sclerosing cholangitis. *Hepatology* 2010; 51: 660–678
- [13] Chen YK, Pleskow DK. SpyGlass single-operator peroral cholangiopancreatography system for the diagnosis and therapy of bile-duct disorders: a clinical feasibility study (with video). *Gastrointest Endosc* 2007; 65: 832–841
- [14] Ramchandani M, Reddy DN, Gupta R et al. Role of single-operator peroral cholangioscopy in the diagnosis of indeterminate biliary lesions: A single-center, prospective study. *Gastrointest Endosc* 2011; 74: 511–519
- [15] Kim HJ, Kim MH, Lee SK et al. Tumor vessel: A valuable cholangioscopic clue of malignant biliary stricture. *Gastrointest Endosc* 2000; 52: 635–638
- [16] Schuetz GM, Schlattmann P, Dewey M. Use of 3×2 tables with an intention to diagnose approach to assess clinical performance of diagnostic tests: Meta-analytical evaluation of coronary CT angiography studies. *BMJ* 2012; 345: 1–10
- [17] Scott IA, Greenberg PB, Poole PJ. Cautionary tales in the clinical interpretation of studies of diagnostic tests. *Intern Med J* 2008; 38: 120–129
- [18] Laleman W, Verraes K, Van Steenberghe W et al. Usefulness of the single-operator cholangioscopy system SpyGlass in biliary disease: a single-center prospective cohort study and aggregated review. *Surg Endosc Other Interv Tech* 2017; 31: 2223–2232
- [19] Robles-Medranda C, Valero M, Soria-Alcivar M et al. Reliability and accuracy of a novel classification system using peroral cholangioscopy for the diagnosis of bile duct lesions. *Endoscopy* 2018; 50: 1059–1070
- [20] Navaneethan U, Hasan MK, Lourdasamy V et al. Single-operator cholangioscopy and targeted biopsies in the diagnosis of indeterminate biliary strictures: A systematic review. *Gastrointest Endosc* 2015; 82: 608–614
- [21] Hartman DJ, Slivka A, Giusto DA et al. Tissue yield and diagnostic efficacy of fluoroscopic and cholangioscopic techniques to assess indeterminate biliary strictures. *Clin Gastroenterol Hepatol* 2012; 10: 1042–1046
- [22] Manta R, Frazzoni M, Conigliaro R et al. SpyGlass® single-operator peroral cholangioscopy in the evaluation of indeterminate biliary lesions: A single-center, prospective, cohort study. *Surg Endosc Other Interv Tech* 2013; 27: 1569–1572
- [23] Woo YS, Lee JK, Oh SH et al. Role of SpyGlass peroral cholangioscopy in the evaluation of indeterminate biliary lesions. *Dig Dis Sci* 2014; 59: 2565–2570
- [24] Shah RJ, Raijman I, Brauer B et al. Performance of a fully disposable, digital, single-operator cholangiopancreatroscope. *Endoscopy* 2017; 49: 651–658
- [25] Arnelo U, Von Seth E, Bergquist A. Prospective evaluation of the clinical utility of single-operator peroral cholangioscopy in patients with primary sclerosing cholangitis. *Endoscopy* 2015; 47: 696–702
- [26] Pitman MB, Centeno BA, Ali SZ et al. Standardized terminology and nomenclature for pancreatobiliary cytology: The Papanicolaou Society of Cytopathology Guidelines. *Cytojournal* 2014; 11: (Suppl. 01): 3
- [27] Deprez PH, Garces Duran R, Moreels T et al. The economic impact of using single-operator cholangioscopy for the treatment of difficult bile duct stones and diagnosis of indeterminate bile duct strictures. *Endoscopy* 2018; 50: 109–118