

University of Groningen

Ablation of atrial fibrillation

de Maat, Gijs Eduard

IMPORTANT NOTE: You are advised to consult the publisher's version (publisher's PDF) if you wish to cite from it. Please check the document version below.

Document Version

Publisher's PDF, also known as Version of record

Publication date:

2018

[Link to publication in University of Groningen/UMCG research database](#)

Citation for published version (APA):

de Maat, G. E. (2018). *Ablation of atrial fibrillation: Moving to a heart team approach*. [Thesis fully internal (DIV), University of Groningen]. Rijksuniversiteit Groningen.

Copyright

Other than for strictly personal use, it is not permitted to download or to forward/distribute the text or part of it without the consent of the author(s) and/or copyright holder(s), unless the work is under an open content license (like Creative Commons).

The publication may also be distributed here under the terms of Article 25fa of the Dutch Copyright Act, indicated by the "Taverne" license. More information can be found on the University of Groningen website: <https://www.rug.nl/library/open-access/self-archiving-pure/taverne-amendment>.

Take-down policy

If you believe that this document breaches copyright please contact us providing details, and we will remove access to the work immediately and investigate your claim.

Downloaded from the University of Groningen/UMCG research database (Pure): <http://www.rug.nl/research/portal>. For technical reasons the number of authors shown on this cover page is limited to 10 maximum.

Chapter 10

Atrial remodeling and function: implications for atrial fibrillation surgery

S. Benussi, G.E. de Maat

Eur J Cardiothor Surg 2018; In press

SUMMARY

The exact mechanism of atrial fibrillation (AF) is still incompletely understood. A number of alterations that impact focal electrical discharge, the atrial substrate and modulating factors contribute to its pathogenesis. Atrial remodeling (resulting in atrial cardiomyopathy) sets the stage for AF development. Once present, AF results in the loss of synchronized atrial contraction, which affects ventricular filling and atrial reservoir and conduit functions. Passive atrial function is particularly important in patients with left ventricular diastolic dysfunction. AF can cause tachycardiomyopathy, a mostly reversible cardiac alteration induced by tachycardia. At a structural level, atrial support is also instrumental to the function of the atrio-ventricular valves. All of these functions can be recovered to variable degrees via rhythm control strategies. Surgical and hybrid ablation show very promising results, especially in patients with a more advanced disease substrate. This review highlights the pathophysiologic aspects of AF related to left atrial function and their practical implications for surgical rhythm management.

INTRODUCTION

The exact mechanism of atrial fibrillation (AF) is multifactorial and still not completely understood¹. Atrial remodeling, resulting in atrial cardiomyopathy, sets the stage for AF development². Once present, AF causes loss of atrial mechanical function^{3,4}. In addition to palpitations, AF can cause tachycardiomyopathy - reversible alterations of ventricular function⁵. At a structural level, atrial support is instrumental to atrio-ventricular valve function⁶. These functions can be recovered through rhythm control strategies. Despite numerous studies on electrophysiology procedures and novel imaging techniques, left atrial function has not been thoroughly investigated. Also, the long-term results of percutaneous AF ablation are still far from satisfactory⁷. Standalone surgical and hybrid ablation has shown very promising results, especially in patients who are refractory to medical and transcatheter therapies⁸⁻¹⁰. Patients with heart failure (HF) could benefit from a preserved atrial function. Concomitant ablation offers the possibility to aid reverse remodeling and improve atrial function. This review highlights the pathophysiologic aspects of AF with regard to left atrial function, and aims to illustrate the practical implications for surgical rhythm management.

Pathogenesis

The pathogenesis of AF is driven by 3 elements: An electrical trigger for arrhythmia initiation, an arrhythmogenic substrate for its maintenance and modulating factors.

Electrical Trigger

A focal source in the pulmonary veins (PV) can trigger AF, and ablation of this source can prevent recurrence of AF¹¹. The mechanism inducing focal activity may involve triggered activity, rotors and localized reentry^{12,13}. Stable micro-reentrant sources have been documented as mechanisms of paroxysmal AF and in some patients with persistent AF¹⁴. Back in the 1950's, Moe and Abildskov proposed that AF can be perpetuated by continuous conduction of multiple independent wavelets activating the atrial wall in an apparently chaotic manner¹⁵. Three decades later this was confirmed both experimentally and clinically by Cox et al.¹⁶ Remote fibrillatory propagation from focal sources of AF is usually undistinguishable from multiple wavelet propagation, as it follows similar propagation patterns¹⁷.

Atrial remodeling and substrate

Stretch – caused by pressure and volume overload, but also ageing, hypertension, HF and AF itself – results in progressive structural remodeling of the atria^{18,19}. Fibroblast activation with connective tissue deposition leads to atrial fibrosis. Research has shown that already 6 weeks after the onset of AF, a significant increase in fibrosis and impaired mechanical left

atrial (LA) function is observed²⁰. In addition to fibrosis, inflammatory infiltrates, necrosis, fatty infiltration, amyloidosis and cardiomyocyte hypertrophy are commonly observed in remodeled atria^{21, 22}. These changes can lead to contractile dysfunction and chamber dilatation, and are usually more pronounced in the left atrium. Within the left atrium, the atrial area tends to be affected more than the left atrial appendage (LAA)²³. Since a combination of such factors is found in many conditions predisposing for AF prior to the onset of arrhythmia, there is growing consensus that a definition of “atrial cardiomyopathy” would be more appropriate². Structural remodeling also results in alteration to ion channels, electrical dissociation between muscle bundles, and local conduction heterogeneity²⁴, favouring focal firing and electrical re-entry²⁵. Structural remodeling in the right atrium has been associated with sinus node dysfunction²⁶. Atrial dysfunction also results in a prothrombotic status due to blood stasis, which is more pronounced in the LAA. Even short AF episodes can result in a prothrombotic state due to myocardial damage and endocardial expression of prothrombotic factors²⁷. Structural remodeling is a progressive process and most of its features are only partially reversible. The treatment success of stand-alone catheter ablation appears to be related to the extent of atrial fibrosis as detected by late gadolinium enhancement magnetic resonance imaging (MRI)²⁸. Early diagnosis and aggressive treatment is important, not only for AF burden reduction but also to prevent progression of structural remodeling²⁹.

Modulating factors

Reverse remodeling does not seem to occur consistently in patients with lone AF after successful ablation³⁰. In patients with mitral stenosis and sinus rhythm, loss of cardiomyocytes and endocardial scarring is observed, suggesting atrial myopathy precedes AF³¹. In patients with MS who undergo balloon commissurotomy, reduced LA pressure promotes LA volume reduction, indicating progressive reverse remodeling³². Mitral regurgitation (MR) also leads to atrial remodeling, including fibrosis and LA dilatation³³. As is the case for mitral stenosis, reverse remodeling with LA volume reduction occurs soon after surgical correction of chronic severe MR³⁴. Aortic stenosis can also cause reversible LA dilatation, leading to a higher risk for AF³⁵.

Left atrial mechanical functions

During ventricular systole, the LA collects and stores incoming blood, serving as a “reservoir”. During the early phase of ventricular diastole, the LA empties passively into the left ventricle (LV), working as a “conduit”. Finally, through its “booster” function, during the late ventricular diastole, the LA actively “kicks” more blood into the LV.

1) The LA reservoir function is the result of an interplay between atrial compliance during ventricular systole, atrial contraction and relaxation, and apical displacement of the atrioventricular valves as a result of ventricular contraction³⁶. Because of its increased

compliance and relevant volume, the LAA contributes substantially to the reservoir function of the LA.

2) The conduit function occurs during early diastole and accounts for about one-third of the atrial flow³⁷. It is more related to LV compliance and strongly interdependent with the reservoir function. LA size increases in response to increased pressure and volume. This physiological compensation initially accounts for a gain in contraction of the atrial myocardium. Progressive dilatation and stretching of the atrial cardiomyofibers results in impaired atrial contractility, in line with the Frank-Starling curve³⁸

3) The LA booster function depends not only on the contractile properties of the atrium but also on venous return and on LV end-diastolic pressure. It accounts for about 15-30% of left ventricular filling in a normal heart under resting conditions^{3, 4, 39}.

These described LA functions can be quantified using echocardiographic speckle-tracking strain and strain rate assessment. This has made it possible to quantify these functional components of the LA independently from left ventricular diastolic function⁴⁰. Reservoir strain and strain rate are predictors of SR recovery after ablation as they are indices of atrial fibrosis and remodeling. It is currently recommended to perform echocardiography analysis to assess valvular disease, LV size and function and atrial size. Left atrial function analysis is not yet recommended, and we believe this should be included as a part of clinical and research practice, both pre-ablation and during follow-up⁹. Besides echocardiography assessment, LA functional parameters can also be measured using cardiac magnetic resonance imaging (CMRI). This has proved to provide very reliable LA function quantification⁴¹. CMRI can be used as an alternative when detailed assessment is required and is considered to be a gold standard. In addition to left atrial function analysis, CMRI offers the potential to assess atrial scars and fibrosis, which is related to the degree of atrial remodeling and ablation outcomes²⁸. However, the role of functional CMRI still needs to be evaluated in large clinical studies and is costly, time consuming and incompatible with patients who carry implanted ferro-magnetic materials. Moreover, an irregular heart rhythm reduces the image quality of CMRI compared with sinus rhythm. Improvement of the available CMRI techniques could increase the potential of this method. Furthermore, very limited data are available for CMRI in patients with AF and mitral valve disease.

Atrial mechanical function in heart failure patients

AF and heart failure can cause and exacerbate each other, while treatment of either condition may reduce the progression of both⁴². The contribution of the atrial booster pump function is believed to increase to 30-40% in the presence of impaired left ventricular filling⁴³. Reservoir and conduit functions of the left atrium are currently believed to play an important role in determining the diverse phenotypes of LV diastolic dysfunction. In fact, only a limited proportion of patients with LV diastolic dysfunction develop heart failure with preserved ejection fraction (HFpEF). Although atrial dysfunction in HFpEF has tra-

ditionally been regarded as secondary and proportional to the degree of LV impairment, recent findings suggest that mechanical LA failure is an early driver of HFpEF. Together with the loss of booster function, a global worsening of reservoir and conduit functions (reduced atrial strain) typically occurs after AF onset in these patients, and prompts a worsening of functional capacity⁴⁴.

Atrial mechanical function and ablation

The recovery of LA booster function has been traditionally regarded the main benefit of sinus rhythm recovery, although the amount of post-ablation LA contraction recovery has been found to be reduced when compared with non-ablated controls in SR⁴⁵⁻⁴⁷. It should be noted that any form of cardiac surgery alters atrial function (most probably due to adhesions following pericardiotomy), also in non-AF patients. A strict interaction was detected between postoperative LA reverse remodeling and LA contractility recovery, as a decrease of LA size favored the atrial “kick” reappearance and viceversa. Patients with lone AF have impaired myocardial energetics and subtle LV dysfunction, which does not always normalize following ablation, even after AF has been abolished⁴⁸.

Independently of rhythm outcome, the probability of recovering of active atrial contraction seems reduced once a certain degree of atrial remodeling has been reached. Tinetti et al. found recovery of LA contraction to occur only in 37% of rheumatic heart patients following concomitant maze surgery for persistent AF⁴⁹. A longer duration of AF, and the amount of atrial remodeling were found to predict AF recurrence^{49, 50}.

Scarring and electrical exclusion of areas of atrial myocardium caused by ablation surgery can impair recovery of atrial contraction⁵¹⁻⁵³. Our group demonstrated minimally invasive epicardial ablation for AF results in a significant reduction of LA conduit and reservoir function⁵².

Different lesion sets have been applied in order to preserve the LA contractile function^{45, 54}. Nevertheless, lesion sets without a posterior en-block “box” isolation of the pulmonary veins are associated with poorer efficacy¹⁰. Current echocardiography guidelines actively recommend the evaluation of LA function after AF ablation to predict the maintenance of sinus rhythm and also identify patients at risk for LA failure or arrhythmias⁵⁵.

Tachycardiomyopathy

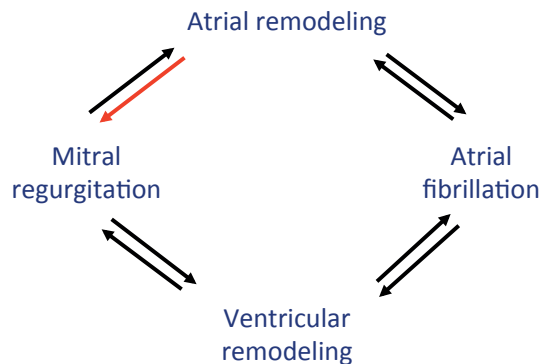
AF can lead to systolic dysfunction and ventricular dilatation. Tachycardia-mediated HF due to AF was first described in 1913,⁵⁶ but the pathogenesis is still not completely understood. Calcium overload and high-energy phosphates depletion, decreased myocardial perfusion and oxidative stress contribute to the pathogenesis of tachycardia-mediated myopathy or tachycardiomyopathy^{5, 57}. This condition affects all cardiac chambers, but the most relevant changes occur in the LV. Cardiac output is decreased, filling pressure is increased and mitral regurgitation can occur due to the loss of intrinsic contractility and progressive

dilatation without hypertrophy⁵⁸. To a lesser extent, tachycardiomyopathy affects also ventricular diastolic function due to incomplete relaxation. Most of these functional aspects of tachycardiomyopathy are reversible, although hypertrophy and diastolic dysfunction can remain⁵⁹. For these reasons, management of arrhythmia is pivotal in patients with tachycardiomyopathy. Patients with AF and HF with reduced EF (HFrEF), have proved to respond much better to rhythm control by ablation than to ablate-and-pace strategy⁶⁰. Assessing the contributory role of tachycardiomyopathy in the context of persistent AF and ventricular dysfunction remains challenging. Echocardiographic assessment may aid in determining the AF-related component⁶⁰.

Atrial function-related mitral regurgitation

LA enlargement, distension and remodeling are the main pathophysiological determinants of AF onset in patients with mitral disease. Both MR and AF-induced tachycardiomyopathy can initiate a vicious circle by promoting left ventricular dysfunction and remodelling^{60, 61} and potentially increasing mitral regurgitation (**Figure 1**). AF also promotes tricuspid and mitral annular dilatation by causing atrial remodeling and dilatation, resulting in MR and tricuspid regurgitation (TR), irrespective of left ventricular size and function^{6, 62, 63}. This “atrial functional MR” has been found to occur in up to 6% of patients undergoing AF transcatheter AF and appears to be reversible in more than two-third of patients⁶. Similarly, Maze surgery concomitant to mitral valve repair has shown to prevent dilatation of atria and the tricuspid annulus⁶⁴.

Figure 1. Interplay of atrial fibrillation, mitral regurgitation and cardiac remodeling



The role of the left atrial appendage

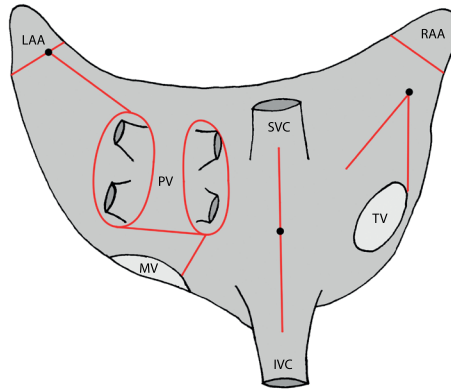
Approximately 90% of atrial thrombi in non-rheumatic AF and 60% of thrombi in patients with rheumatic mitral valve disease are found within the LAA⁶⁵. This finding prompted an increased interest in surgical and endovascular closure of the LAA. Open cardiac surgery

offers the unique opportunity to amputate, clip or suture the appendage. But complete LA exclusion has proved challenging, and incomplete closure or amputation may cause a higher risk for thromboembolic events^{66, 67}. Recently, epicardial clipping of the LAA has provided a means for a consistent occlusion and electrical isolation of the LAA^{68, 69}. However, the beneficial effect on morbidity and mortality has yet to be demonstrated. Use of the percutaneous LAA exclusion device showed no clear-cut advantage over oral anticoagulants, with a persistent risk of ischemic stroke in the device groups, and one third of the patients with a residual leak^{70, 71}. Moreover, the potential effects of LAA exclusion on LA function have not been thoroughly studied. This notwithstanding, the LAA is amputated or closed by a clip on a large scale in stand-alone and concomitant AF surgery. The recently published Clinical Practice Guidelines for the Surgical Treatment of AF have promoted a Class IIA recommendation (level of evidence C) to routinely perform LAA exclusion in patients undergoing concomitant or stand-alone ablation surgery or in any AF patient undergoing cardiac surgery⁷². The ongoing LAAOS III trial, randomizing 4700 open cardiac surgery patients to either LAA occlusion or not, will hopefully shed some light on this issue⁷³. Accurate detection of possible underlying cardiomyopathies should be pursued, and the benefits of LAA occlusion, in terms of thromboembolic prophylaxis, and possibly also in terms of rhythm control, should be balanced against the potential for hemodynamic impairment, especially in patients without persistent arrhythmias.

In recent years, novel oral anticoagulant (NOAC) medications have become available: rivaroxaban, apixaban and dabigatran. The main advantage is that NOAC do not require bloodwork monitoring and have minimal interaction with other medication. However, NOACS are not approved for patients with valvular disease. The only approved oral anticoagulant for patients with mechanical heart valves is warfarin. A randomized trial (RE-ALIGN) of dabigatran versus warfarin in patients with mechanical valves showed an increase in ischemic events and bleeding in patients using dabigatran. For AF patients without mechanical valve prosthesis, randomized controlled trials showed that NOACs were as effective (rivaroxaban and apixaban) or more effective (dabigatran) in reducing stroke risk compared with warfarin⁷⁴. Recent real-world data confirmed these results⁷⁵. Of the available NOACs, only apixaban was associated with overall mortality reduction compared with warfarin. For transcatheter ablation, NOACs have proven to be effective in periprocedural stroke risk⁷⁶. However, during stand-alone thoracoscopic pulmonary vein isolation and hybrid AF ablation warfarine is still the oral anticoagulant of choice to reduce the risk of stroke.

Concomitant AF ablation

Considering the potential benefit of reverse remodeling in patients with valvular disease, a more aggressive approach to concomitant ablation would seem reasonable. Unlike lone AF, surgical correction of the cause of volume/pressure overload, combined with Maze

Figure 2. Cox-Maze IV

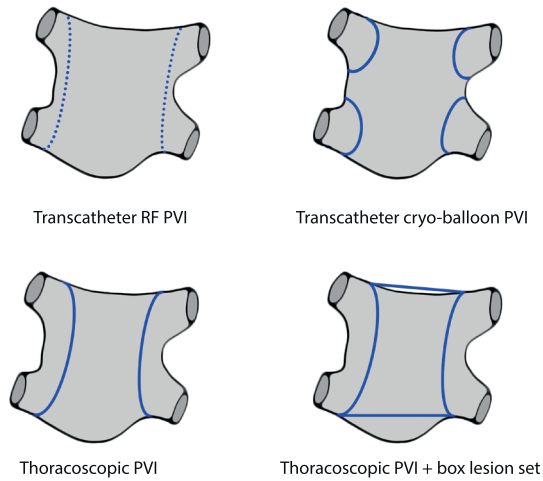
Cox-Maze IV lesion set using a bipolar radiofrequency clamp. IVC= Inferior Vena Cava, LAA= Left atrial appendage, PV= Pulmonary Veins, MV= Mitral Valve, TV = Tricuspid Valve, SVC = Superior Vena Cava

surgery (**Figure 2**), can restore atrial function. Particularly when left ventricular dysfunction is present, combining maze surgery provides the double advantage of reversing the tachycardiomyopathy and promoting reverse atrial remodeling⁷⁷. When concomitant diastolic dysfunction is present (aortic stenosis, HOCM, severe hypertension, advanced age and HFpEF in general), recovery of SR and reverse atrial remodeling provides optimal improvement of LA mechanical function, also favoring diastolic filling. Experienced centers have demonstrated that the added risk of concomitant ablation is negligible⁷⁸. Additionally, performing a concomitant maze procedure at the time of open surgery can also enhance regression of intermediate functional MR and prevent subsequent development of tricuspid regurgitation by ruling out the functional component of atrio-ventricular annulus dilation⁶⁴. LA reduction surgery proposed by some authors as an adjunct to maze, to improve rhythm outcome, must be considered with caution as it can potentially reduce the LA reservoir function⁷⁹. More extensive electrical isolation of the basal posterior LA through ablation can be a valuable and likely safer alternative for substrate modification.

Stand-alone AF ablation

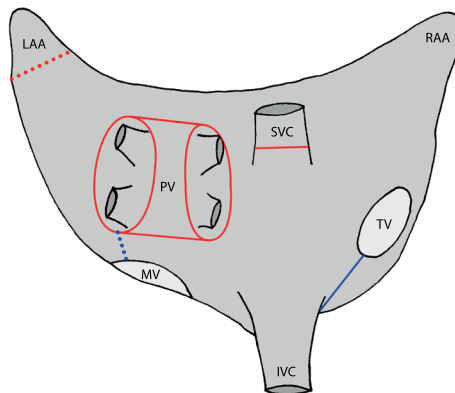
As the benefits of rhythm control for persistent and long-standing persistent AF become more evident, and the results of catheter ablation remain hampered⁷, the interest for lone AF surgery is growing^{9, 72} (**Figure 3**). Both thoracoscopic and open rhythm surgery are not likely to completely revert the underlying atrial myopathy, but they provide high probability of sinus rhythm and durable symptom relief^{8, 10}. Early stand-alone ablation can prevent tachycardiomyopathy and also improves left ventricular function⁸⁰. However, little is known on the long-term effects on cardiac function and further research is warranted on this topic. A deeper insight into atrial myopathy/remodeling would help refine the

Figure 3. Minimally invasive left atrial ablation methods



Transcatheter radiofrequency point-by-point wide circumferential ablation, Transcatheter cryo-balloon PVI, Thoracoscopic bipolar radiofrequency PVI and Thoracoscopic bipolar radiofrequency PVI with a box lesion set created with a linear bipolar ablation pen. RF= radiofrequency, PVI = Pulmonary vein isolation

Figure 4. Hybrid epi- and endocardial lesion



Hybrid epi- and endocardial lesion set, red lines depict the thoracoscopically applied lesions, blue lines depict transcatheter lesions. Dotted lines imply optional lesions; the LAA amputation (surgical) and MV isthmus line (transcatheter). IVC= Inferior Vena Cava, LAA= Left atrial appendage, PV= Pulmonary Veins, MV= Mitral Valve, TV = Tricuspid Valve, SVC = Superior Vena Cava

indications for standalone ablation surgery and would be instrumental to determining the hierarchy of the ablation procedure to be performed.

In cases of non-advanced myopathy, catheter ablation could be attempted initially, while thoracoscopic, hybrid thoracoscopic (**Figure 4**) and transcatheter ablation or even open ablation surgery may be appropriate choices for cases with advanced remodeling.

CONCLUSIONS AND IMPLICATIONS FOR AF SURGERY

Although AF is associated with impaired quality of life, stroke, HF and mortality, studies have shown that a rate control strategy is non-inferior to rhythm control, and that rhythm control is only indicated for reduction of symptoms, not for improvement of survival. Therefore, the reason for ablation must be considered carefully. The main benefits of (concomitant) ablation are symptom reduction, improvement of ventricular/cardiac function and prevention of tachycardiomyopathy. AF impairs not only the left “atrial kick”, but it also impairs the atrial reservoir/conduit function. Modern rhythm management surgery offers the unique opportunity to revert most of the negative effects of AF at a ventricular, atrial and valvular level. Because AF is a progressive disease, aggressive application of durable, transmural and continuous lesion sets can prevent electrical and structural remodeling of the left atrium. Structural assessment of atrial function and fibrosis (echocardiographically or by means of CMRI) is recommended and can aid in patient selection and may predict the capacity of re-remodeling following ablation, eventually improving ablation outcomes. To reduce the risk for thrombo-embolic events and to improve rhythm outcome, exclusion of the LAA is performed on a large scale but beneficial effect of these techniques are yet to be demonstrated. Also, the long-term effect of LAA exclusion on LA and left ventricular function is still unknown, (long-term) follow-up by means of echocardiography or cardiac MRI is recommended. A better understanding of AF pathophysiology and underlying atrial disease may help transition towards a more personalized approach to identifying more appropriate indications and guide the choice of procedure for the individual patient.

REFERENCES

- [1] Lau DH, Schotten U, Mahajan R, Antic NA, Hatem SN, Pathak RK, Hendriks JM, Kalman JM, Sanders P. Novel mechanisms in the pathogenesis of atrial fibrillation: Practical applications. *Eur Heart J* 2016; 37:1573-81.
- [2] Goette A, Kalman JM, Aguinaga L, Akar J, Cabrera JA, Chen SA, Chugh SS, Corradi D et al., Expert consensus on atrial cardiomyopathies: Definition, characterization, and clinical implication. *Europace* 2016;18:1455-90.
- [3] Mor-Avi V, Lang RM, Badano LP, Belohlavek M, Cardim NM, Derumeaux G, Galderisi M, Marwick T et al. Current and evolving echocardiographic techniques for the quantitative evaluation of cardiac mechanics: consensus statement on methodology and indications. *Eur J Echocardiogr* 2011;12: 167-205.
- [4] Mitchell JH, Shapiro W. Atrial function and the hemodynamic consequences of atrial fibrillation in man. *Am J Cardiol* 1969;23:556-67.
- [5] Gupta S, Figueredo VM. Tachycardia mediated cardiomyopathy: Pathophysiology, mechanisms, clinical features and management. *Int J Cardiol* 2014;172:40-6.
- [6] Gertz ZM, Raina A, Saghy L, Zado ES, Callans DJ, Marchlinski FE, Keane MG, Silvestry FE. Evidence of atrial functional mitral regurgitation due to atrial fibrillation: Reversal with arrhythmia control. *J Am Coll Cardiol* 2011;58:1474-81.
- [7] Tilz RR, Rillig A, Thum AM, Arya A, Wohlmuth P, Metzner A, Mathew S, Yoshiga Y, Wissner E, Kuck KH, Ouyang F. Catheter ablation of long-standing persistent atrial fibrillation: 5-year outcomes of the hamburg sequential ablation strategy. *J Am Coll Cardiol* 2012;60:1921-9.
- [8] Boersma LV, Castella M, van Boven W, Berrueto A, Yilmaz A, Nadal M, Sandoval E, Calvo N, Brugada J, Kelder J, Wijffels M, Mont L. Atrial fibrillation catheter ablation versus surgical ablation treatment (FAST): A 2-center randomized clinical trial. *Circulation* 2012;125:23-30.
- [9] Kirchhof P, Benussi S, Kotecha D, Ahlsson A, Atar D, Casadei B, Castella M, Diener HC, et al. ESC guidelines for the management of atrial fibrillation developed in collaboration with EACTS. *Eur Heart J* 2016;37:2893-962.
- [10] Weimar T, Schena S, Bailey MS, Maniar HS, Schuessler RB, Cox JL, Damiano RJ, Jr. The cox-maze procedure for lone atrial fibrillation: A single-center experience over 2 decades. *Circ Arrhythm Electrophysiol* 2012;5:8-14.
- [11] Haissaguerre M, Jais P, Shah DC, Takahashi A, Hocini M, Quiniou G, Garrigue S, Le Mouroux A, Le Metayer P, Clementy J. Spontaneous initiation of atrial fibrillation by ectopic beats originating in the pulmonary veins. *N Engl J Med* 1998;339:659-66.
- [12] Patterson E, Jackman WM, Beckman KJ, Lazzara R, Lockwood D, Scherlag BJ, Wu R, Po S. Spontaneous pulmonary vein firing in man: Relationship to tachycardia-pause early afterdepolarizations and triggered arrhythmia in canine pulmonary veins in vitro. *J Cardiovasc Electrophysiol* 2007;18: 1067-75.
- [13] Atienza F, Almendral J, Moreno J, Vaidyanathan R, Talkachou A, Kalifa J, Arenal A, Villacastin JP, Torrecilla EG, Sanchez A, Ploutz-Snyder R, Jalife J, Berenfeld O. Activation of inward rectifier potassium channels accelerates atrial fibrillation in humans: Evidence for a reentrant mechanism. *Circulation* 2006;114:2434-42.
- [14] Sanders P, Nalliah CJ, Dubois R, Takahashi Y, Hocini M, Rotter M, Rostock T, Sacher F, Hsu LF, Jonsson A, O'Neill MD, Jais P, Haissaguerre M. Frequency mapping of the pulmonary veins in paroxysmal versus permanent atrial fibrillation. *J Cardiovasc Electrophysiol* 2006;17:965-72.

- [15] MOE GK, ABILDSKOV JA. Atrial fibrillation as a self-sustaining arrhythmia independent of focal discharge. *Am Heart J* 1959;58:59-70.
- [16] Cox JL, Canavan TE, Schuessler RB, Cain ME, Lindsay BD, Stone C, Smith PK, Corr PB, Boineau JP. The surgical treatment of atrial fibrillation. II. intraoperative electrophysiologic mapping and description of the electrophysiologic basis of atrial flutter and atrial fibrillation. *J Thorac Cardiovasc Surg* 1991;101:406-26.
- [17] Haissaguerre M, Hocini M, Denis A, Shah AJ, Komatsu Y, Yamashita S, Daly M, Amraoui S, Zellerhoff S, Picat MQ, Quotb A, Jesel L, Lim H, Ploux S, Bordachar P, Attuel G, Meillet V, Ritter P, Derval N, Sacher F, Bernus O, Cochet H, Jais P, Dubois R. Driver domains in persistent atrial fibrillation. *Circulation* 2014;130:530-8.
- [18] Ohtani K, Yutani C, Nagata S, Koretsune Y, Hori M, Kamada T. High prevalence of atrial fibrosis in patients with dilated cardiomyopathy. *J Am Coll Cardiol* 1995;25:1162-9.
- [19] Bailey GW, Braniff BA, Hancock EW, Cohn KE. Relation of left atrial pathology to atrial fibrillation in mitral valvular disease. *Ann Intern Med* 1968;69:13-20.
- [20] Kazui T, Henn MC, Watanabe Y, Kovacs SJ, Lawrance CP, Greenberg JW, Moon M, Schuessler RB, Damiano RJ, Jr. The impact of 6 weeks of atrial fibrillation on left atrial and ventricular structure and function. *J Thorac Cardiovasc Surg* 2015;150:1602-8.
- [21] Frustaci A, Chimenti C, Bellocci F, Morgante E, Russo MA, Maseri A. Histological substrate of atrial biopsies in patients with lone atrial fibrillation. *Circulation* 1997;96:1180-4.
- [22] Venteclef N, Guglielmi V, Balse E, Gaborit B, Cotillard A, Atassi F, Amour J, Leprince P, Dutour A, Clement K, Hatem SN. Human epicardial adipose tissue induces fibrosis of the atrial myocardium through the secretion of adipo-fibrokinases. *Eur Heart J* 2015;36:795-805a.
- [23] Corradi D, Callegari S, Benussi S, Nascimbene S, Pastori P, Calvi S, Maestri R, Astorri E, Pappone C, Alfieri O. Regional left atrial interstitial remodeling in patients with chronic atrial fibrillation undergoing mitral-valve surgery. *Virchows Arch* 2004;445:498-505.
- [24] Allesie MA, de Groot NM, Houben RP, Schotten U, Boersma E, Smeets JL, Crijns HJ. Electropathological substrate of long-standing persistent atrial fibrillation in patients with structural heart disease: Longitudinal dissociation. *Circ Arrhythm Electrophysiol* 2010;3:606-15.
- [25] Schotten U, Verheule S, Kirchhof P, Goette A. Pathophysiological mechanisms of atrial fibrillation: A translational appraisal. *Physiol Rev* 2011;91:265-325.
- [26] Jackson LR, 2nd, Rathakrishnan B, Campbell K, Thomas KL, Piccini JP, Bahnson T, Stiber JA, Daubert JP. Sinus node dysfunction and atrial fibrillation: A reversible phenomenon?. *Pacing Clin Electrophysiol* 2017;40:442-50.
- [27] Lim HS, Willoughby SR, Schultz C, Gan C, Alasady M, Lau DH, Leong DP, Brooks AG, Young GD, Kistler PM, Kalman JM, Worthley MI, Sanders P. Effect of atrial fibrillation on atrial thrombogenesis in humans: Impact of rate and rhythm. *J Am Coll Cardiol* 2013;61:852-60.
- [28] Marrouche NF, Wilber D, Hindricks G, Jais P, Akoum N, Marchlinski F, Kholmovski E, Burgon N, et al. Association of atrial tissue fibrosis identified by delayed enhancement MRI and atrial fibrillation catheter ablation: The DECAAF study. *JAMA* 2014;311:498-506.
- [29] Cosio FG, Aliot E, Botto GL, Heibuchel H, Geller CJ, Kirchhof P, De Haro JC, Frank R, Villacastin JP, Vijgen J, Crijns H. Delayed rhythm control of atrial fibrillation may be a cause of failure to prevent recurrences: Reasons for change to active antiarrhythmic treatment at the time of the first detected episode. *Europace* 2008;10:21-7.
- [30] Teh AW, Kistler PM, Lee G, Medi C, Heck PM, Spence SJ, Morton JB, Sanders P, Kalman JM. Long-term effects of catheter ablation for lone atrial fibrillation: Progressive atrial electroanatomic substrate remodeling despite successful ablation. *Heart Rhythm* 2012;9:473-80.

- [31] John B, Stiles MK, Kuklik P, Chandy ST, Young GD, Mackenzie L, Szumowski L, Joseph G, Jose J, Worthley SG, Kalman JM, Sanders P. Electrical remodelling of the left and right atria due to rheumatic mitral stenosis. *Eur Heart J* 2008;29:2234-43.
- [32] John B, Stiles MK, Kuklik P, Brooks AG, Chandy ST, Kalman JM, Sanders P. Reverse remodeling of the atria after treatment of chronic stretch in humans: Implications for the atrial fibrillation substrate. *J Am Coll Cardiol* 2010;55:1217-26.
- [33] Verheule S, Wilson E, Everett T, 4th, Shanbhag S, Golden C, Olgin J. Alterations in atrial electrophysiology and tissue structure in a canine model of chronic atrial dilatation due to mitral regurgitation. *Circulation* 2003;107:2615-22.
- [34] Le Bihan DC, Della Togna DJ, Barretto RB, Assef JE, Machado LR, Ramos AI, Abdulmassih Neto C, Moises VA, Sousa AG, Campos O. Early improvement in left atrial remodeling and function after mitral valve repair or replacement in organic symptomatic mitral regurgitation assessed by three-dimensional echocardiography. *Echocardiography* 2015;32:1122-30.
- [35] Triposkiadis F, Pitsavos C, Boudoulas H, Trikas A, Kallikazaros I, Stefanadis C, Toutouzas P. Left atrial volume and function in valvular aortic stenosis. *J Heart Valve Dis* 1993;2:104-13.
- [36] Barbier P, Solomon SB, Schiller NB, Glantz SA. Left atrial relaxation and left ventricular systolic function determine left atrial reservoir function. *Circulation* 1999;100:427-36.
- [37] Hitch DC, Nolan SP. Descriptive analysis of instantaneous left atrial volume—with special reference to left atrial function. *J Surg Res* 1981;30:110-20.
- [38] Triposkiadis F, Tentolouris K, Androulakis A, Trikas A, Toutouzas K, Kyriakidis M, Gialafos J, Toutouzas P. Left atrial mechanical function in the healthy elderly: New insights from a combined assessment of changes in atrial volume and transmitral flow velocity. *J Am Soc Echocardiogr* 1995;8:801-9.
- [39] Pagel PS, Kehl F, Gare M, Hettrick DA, Kersten JR, Warltier DC. Mechanical function of the left atrium: New insights based on analysis of pressure-volume relations and doppler echocardiography. *Anesthesiology* 2003;98:975-94.
- [40] Vieira MJ, Teixeira R, Goncalves L, Gersh BJ. Left atrial mechanics: Echocardiographic assessment and clinical implications. *J Am Soc Echocardiogr* 2014;27:463-78.
- [41] Panovsky R, Pleva M, Feitova V, Kruzliak P, Meluzin J, Kincl V, Novotny P, Vanicek J. Left atrium assessment: The evolving role of MRI. *J Cardiovasc Med (Hagerstown)* 2015;16:671-80.
- [42] Kotecha D, Lam CS, Van Veldhuisen DJ, Van Gelder IC, Voors AA, Rienstra M. Heart failure with preserved ejection fraction and atrial fibrillation: Vicious twins. *J Am Coll Cardiol* 2016;68:2217-28.
- [43] Tsang TS, Barnes ME, Gersh BJ, Bailey KR, Seward JB. Risks for atrial fibrillation and congestive heart failure in patients ≥ 65 years of age with abnormal left ventricular diastolic relaxation. *Am J Cardiol* 2004;93:54-8.
- [44] Freed BH, Daruwalla V, Cheng JY, Aguilar FG, Beussink L, Choi A, Klein DA, Dixon D, Baldrige A, Rasmussen-Torvik LJ, Maganti K, Shah SJ. Prognostic utility and clinical significance of cardiac mechanics in heart failure with preserved ejection fraction: Importance of left atrial strain. *Circ Cardiovasc Imaging* 2016;9:10.1161/CIRCIMAGING.115.003754.
- [45] Voeller RK, Zierer A, Lall SC, Sakamoto S, Chang NL, Schuessler RB, Moon MR, Damiano RJ, Jr. The effects of the Cox maze procedure on atrial function. *J Thorac Cardiovasc Surg* 2008;136:1257,64, 1264.e1-3.
- [46] Feinberg MS, Waggoner AD, Kater KM, Cox JL, Lindsay BD, Perez JE. Restoration of atrial function after the maze procedure for patients with atrial fibrillation. assessment by doppler echocardiography. *Circulation* 1994;90:11285-92.

- [47] Benussi S, Pappone C, Nascimbene S, Oreto G, Caldarola A, Stefano PL, Casati V, Alfieri O. A simple way to treat chronic atrial fibrillation during mitral valve surgery: The epicardial radiofrequency approach. *Eur J Cardiothorac Surg* 2000;17:524-9.
- [48] Wijesurendra RS, Liu A, Eichhorn C, Ariga R, Levelt E, Clarke WT, Rodgers CT, Karamitsos TD, Bashir Y, Ginks M, Rajappan K, Betts T, Ferreira VM, Neubauer S, Casadei B. Lone atrial fibrillation is associated with impaired left ventricular energetics that persists despite successful catheter ablation. *Circulation* 2016;134:1068-81.
- [49] Tinetti M, Costello R, Cardenas C, Piazza A, Iglesias R, Baranchuk A. Persistent atrial fibrillation is associated with inability to recover atrial contractility after MAZE IV surgery in rheumatic disease. *Pacing Clin Electrophysiol* 2012;35:999-1004.
- [50] Albirini A, Scalia GM, Murray RD, Chung MK, McCarthy PM, Griffin BP, Arheart KL, Klein AL. Left and right atrial transport function after the maze procedure for atrial fibrillation: An echocardiographic doppler follow-up study. *J Am Soc Echocardiogr* 1997;10:937-45.
- [51] Compier MG, Tops LF, Braun J, Zeppenfeld K, Klautz RJ, Schalij MJ, Trines SA. Limited left atrial surgical ablation effectively treats atrial fibrillation but decreases left atrial function. *Europace* 2017;19:560-7.
- [52] De Maat GE, Benussi S, Hummel YM, Krul S, Pozzoli A, Driessen AH, Mariani MA, Van Gelder IC, Van Boven WJ, de Groot JR. Surgical left atrial appendage exclusion does not impair left atrial contraction function: A pilot study. *Biomed Res Int* 2015;2015:318901.
- [53] Hof IE, Vonken EJ, Velthuis BK, Wittkamp FH, van der Heijden JF, Neven KG, Kassenberg W, Meine M, Cramer MJ, Hauer RN, Loh P. Impact of pulmonary vein antrum isolation on left atrial size and function in patients with atrial fibrillation. *J Interv Card Electrophysiol* 2014;39:201-9.
- [54] Ishii Y, Nitta T, Fujii M, Ogasawara H, Iwaki H, Ohkubo N, Tanaka S. Serial change in the atrial transport function after the radial incision approach. *Ann Thorac Surg* 2001;71:572-6.
- [55] Debonnaire P, Leong DP, Witkowski TG, Al Amri I, Joyce E, Katsanos S, Schalij MJ, Bax JJ, Delgado V, Marsan NA. Left atrial function by two-dimensional speckle-tracking echocardiography in patients with severe organic mitral regurgitation: Association with guidelines-based surgical indication and postoperative (long-term) survival. *J Am Soc Echocardiogr* 2013;26:1053-62.
- [56] Gossage AM, Braxton Hicks JA. On auricular fibrillation. *QJM* 1913;6:435,-440.
- [57] Selby DE, Palmer BM, LeWinter MM, Meyer M. Tachycardia-induced diastolic dysfunction and resting tone in myocardium from patients with a normal ejection fraction. *J Am Coll Cardiol* 2011;58:147-54.
- [58] Shinbane JS, Wood MA, Jensen DN, Ellenbogen KA, Fitzpatrick AP, Scheinman MM. Tachycardia-induced cardiomyopathy: A review of animal models and clinical studies. *J Am Coll Cardiol* 1997;29:709-15.
- [59] Dandamudi G, Rampurwala AY, Mahenthiran J, Miller JM, Das MK. Persistent left ventricular dilatation in tachycardia-induced cardiomyopathy patients after appropriate treatment and normalization of ejection fraction. *Heart Rhythm* 2008;5:1111-4.
- [60] Anselmino M, Matta M, D'Ascenzo F, Bunch TJ, Schilling RJ, Hunter RJ, Pappone C, Neumann T, Noelker G, Fiala M, Bertaglia E, Frontera A, Duncan E, Nalliah C, Jais P, Weerasooriya R, Kalman JM, Gaita F. Catheter ablation of atrial fibrillation in patients with left ventricular systolic dysfunction: A systematic review and meta-analysis. *Circ Arrhythm Electrophysiol* 2014;7:1011-8.
- [61] Edner M, Caidahl K, Bergfeldt L, Darpo B, Edvardsson N, Rosenqvist M. Prospective study of left ventricular function after radiofrequency ablation of atrioventricular junction in patients with atrial fibrillation. *Br Heart J* 1995;74:261-7.

- [62] Kihara T, Gillinov AM, Takasaki K, Fukuda S, Song JM, Shiota M, Shiota T. Mitral regurgitation associated with mitral annular dilation in patients with lone atrial fibrillation: An echocardiographic study. *Echocardiography* 2009;26:885-9.
- [63] Zhou X, Otsuji Y, Yoshifuku S, Yuasa T, Zhang H, Takasaki K, Matsukida K, Kisanuki A, Minagoe S, Tei C. Impact of atrial fibrillation on tricuspid and mitral annular dilatation and valvular regurgitation. *Circ J* 2002;66:913-6.
- [64] Yoo JS, Kim JB, Jung SH, Choo SJ, Chung CH, Lee JW. Impact of the maze procedure and postoperative atrial fibrillation on progression of functional tricuspid regurgitation in patients undergoing degenerative mitral repair. *Eur J Cardiothorac Surg* 2013;43:520-5.
- [65] Al-Saady NM, Obel OA, Camm AJ. Left atrial appendage: Structure, function, and role in thromboembolism. *Heart* 1999;82:547-54.
- [66] Healey JS, Crystal E, Lamy A, Teoh K, Semelhago L, Hohnloser SH, Cybulsky I, Abouzahr L, et al. Left atrial appendage occlusion study (LAAOS): Results of a randomized controlled pilot study of left atrial appendage occlusion during coronary bypass surgery in patients at risk for stroke. *Am Heart J* 2005;150:288-93.
- [67] Kanderian AS, Gillinov AM, Pettersson GB, Blackstone E, Klein AL. Success of surgical left atrial appendage closure: Assessment by transesophageal echocardiography. *J Am Coll Cardiol* 2008;52:924-9.
- [68] Ailawadi G, Gerdisch MW, Harvey RL, Hooker RL, Damiano RJ, Jr, Salamon T, Mack MJ. Exclusion of the left atrial appendage with a novel device: Early results of a multicenter trial. *J Thorac Cardiovasc Surg* 2011;142:1002,9, 1009.e1.
- [69] Benussi S, Mazzone P, Maccabelli G, Vergara P, Grimaldi A, Pozzoli A, Spagnolo P, Alfieri O, Della Bella P. Thoracoscopic appendage exclusion with an atriclip device as a solo treatment for focal atrial tachycardia. *Circulation* 2011;123:1575-8.
- [70] Viles-Gonzalez JF, Kar S, Douglas P, Dukkipati S, Feldman T, Horton R, Holmes D, Reddy VY. The clinical impact of incomplete left atrial appendage closure with the watchman device in patients with atrial fibrillation: A PROTECT AF substudy. *J Am Coll Cardiol* 2012;59:923-9.
- [71] Piccini JP, Sievert H, Patel MR. Left atrial appendage occlusion: Rationale, evidence, devices, and patient selection. *Eur Heart J* 2016.
- [72] Badhwar V, Rankin JS, Damiano RJ, Jr, Gillinov AM, Bakaeen FG, Edgerton JR, Philpott JM, McCarthy PM, et al. The society of thoracic surgeons 2017 clinical practice guidelines for the surgical treatment of atrial fibrillation. *Ann Thorac Surg* 2017;103:329-41.
- [73] Whitlock R, Healey J, Vincent J, Brady K, Teoh K, Royse A, Shah P, Guo Y, Alings M, Folkeringa RJ, Paparella D, Colli A, Meyer SR, Legare JF, Lamontagne F, Reents W, Boning A, Connolly S. Rationale and design of the left atrial appendage occlusion study (LAAOS) III. *Ann Cardiothorac Surg* 2014;3:45-54.
- [74] Ruff CT, Giugliano RP, Braunwald E, Hoffman EB, Deenadayalu N, Ezekowitz MD, Camm AJ, Weitz JJ, Lewis BS, Parkhomenko A, Yamashita T, Antman EM. Comparison of the efficacy and safety of new oral anticoagulants with warfarin in patients with atrial fibrillation: A meta-analysis of randomised trials. *Lancet* 2014;383:955-62.
- [75] Yao X, Abraham NS, Sangaralingham LR, Bellolio MF, McBane RD, Shah ND, Noseworthy PA. Effectiveness and safety of dabigatran, rivaroxaban, and apixaban versus warfarin in nonvalvular atrial fibrillation. *J Am Heart Assoc* 2016;5:10.1161/JAHA.116.003725.
- [76] Rillig A, Lin T, Plesman J, Heeger CH, Lemes C, Metzner A, Mathew S, Wissner E, Wohlmuth P, Ouyang F, Kuck KH, Tilz RR. Apixaban, rivaroxaban, and dabigatran in patients undergoing atrial fibrillation ablation. *J Cardiovasc Electrophysiol* 2016;27:147-53.

- [77] Ad N, Henry L, Hunt S. The impact of surgical ablation in patients with low ejection fraction, heart failure, and atrial fibrillation. *Eur J Cardiothorac Surg* 2011;40:70-6.
- [78] Saint LL, Damiano RJ,Jr, Cuculich PS, Guthrie TJ, Moon MR, Munfakh NA, Maniar HS. Incremental risk of the cox-maze IV procedure for patients with atrial fibrillation undergoing mitral valve surgery. *J Thorac Cardiovasc Surg* 2013;146:1072-7.
- [79] Sunderland N, Nagendran M, Maruthappu M. In patients with an enlarged left atrium does left atrial size reduction improve maze surgery success?. *Interact Cardiovasc Thorac Surg* 2011;13: 635-41.
- [80] Pozzoli A, Taramasso M, Coppola G, Kamami M, La Canna G, Bella PD, Alfieri O, Benussi S. Maze surgery normalizes left ventricular function in patients with persistent lone atrial fibrillation. *Eur J Cardiothorac Surg* 2014.

