

University of Groningen

Late onset cardiomyopathy as presenting sign of ATTR A45G amyloidosis caused by a novel TTR mutation (p.A65G)

Klaassen, Sebastiaan H. C.; Lemmink, Henny H.; Bijzet, Johan; Glaudemans, Andor W. J. M.; Bos, Reinhard; Plattel, Wouter; van den Berg, Maarten P.; Slart, Riemer H. J. A.; Nienhuis, Hans L. A.; van Veldhuisen, Dirk J.

Published in:
 Cardiovascular Pathology

DOI:
[10.1016/j.carpath.2017.04.002](https://doi.org/10.1016/j.carpath.2017.04.002)

IMPORTANT NOTE: You are advised to consult the publisher's version (publisher's PDF) if you wish to cite from it. Please check the document version below.

Document Version
 Publisher's PDF, also known as Version of record

Publication date:
 2017

[Link to publication in University of Groningen/UMCG research database](#)

Citation for published version (APA):

Klaassen, S. H. C., Lemmink, H. H., Bijzet, J., Glaudemans, A. W. J. M., Bos, R., Plattel, W., van den Berg, M. P., Slart, R. H. J. A., Nienhuis, H. L. A., van Veldhuisen, D. J., & Hazenberg, B. P. C. (2017). Late onset cardiomyopathy as presenting sign of ATTR A45G amyloidosis caused by a novel TTR mutation (p.A65G). *Cardiovascular Pathology*, 29, 19-22. <https://doi.org/10.1016/j.carpath.2017.04.002>

Copyright

Other than for strictly personal use, it is not permitted to download or to forward/distribute the text or part of it without the consent of the author(s) and/or copyright holder(s), unless the work is under an open content license (like Creative Commons).

The publication may also be distributed here under the terms of Article 25fa of the Dutch Copyright Act, indicated by the "Taverne" license. More information can be found on the University of Groningen website: <https://www.rug.nl/library/open-access/self-archiving-pure/taverne-amendment>.

Take-down policy

If you believe that this document breaches copyright please contact us providing details, and we will remove access to the work immediately and investigate your claim.



Clinical Case Report

Late onset cardiomyopathy as presenting sign of ATTR A45G amyloidosis caused by a novel *TTR* mutation (p.A65G)

Sebastiaan H.C. Klaassen^{a,*}, Henny H. Lemmink^b, Johan Bijzet^c, Andor W.J.M. Glaudemans^d, Reinhard Bos^e, Wouter Plattel^c, Maarten P. van den Berg^a, Riemer H.J.A. Slart^{d,f}, Hans L.A. Nienhuis^c, Dirk J. van Veldhuisen^a, Bouke P.C. Hazenberg^c

^a Department of Cardiology, University of Groningen, University Medical Center Groningen, The Netherlands

^b Department of Medical Genetics, University of Groningen, University Medical Center Groningen, The Netherlands

^c Department of Rheumatology & Clinical Immunology, University of Groningen, University Medical Center Groningen, The Netherlands

^d Department of Nuclear Medicine & Molecular Imaging, University of Groningen, University Medical Center Groningen, The Netherlands

^e Department of Medical Center Leeuwarden, The Netherlands

^f Department of Biomedical Photonic Imaging, University of Twente, Enschede, The Netherlands

ARTICLE INFO

Article history:

Received 11 December 2016

Received in revised form 24 February 2017

Accepted 10 April 2017

Keywords:

ATTR A45G Amyloidosis

Transthyretin

Cardiomyopathy

CTS

ABSTRACT

Objective: The clinical description of a novel *TTR* gene mutation characterized by a late onset amyloid cardiomyopathy. **Methods and Results:** A 78-year-old man of Dutch origin with recent surgery for bilateral carpal tunnel syndrome (CTS) was admitted to our hospital because of heart failure with preserved ejection fraction (55%). Cardiac ultrasound showed thickened biventricular walls, and cardiac magnetic resonance imaging also showed late gadolinium enhancement. Early signs of a polyneuropathy were found by neurophysiological testing. A few months later, his 72-year-old sister was admitted to an affiliated hospital because of heart failure caused by a restrictive cardiomyopathy. In both patients, a subcutaneous abdominal fat aspirate was stained with Congo red and DNA was analyzed by direct sequencing of exons 1 to 4 of the transthyretin (*TTR*) gene. Both fat aspirates revealed transthyretin-derived (ATTR) amyloid. ^{99m}Tc-diphosphonate scintigraphy further confirmed cardiac ATTR amyloidosis in the male patient. DNA analysis of both patients showed a novel *TTR* mutation c.194C > G that encodes for the gene product *TTR* (p.A65G) ending up as the mature protein *TTR* A45G. The 56-year-old daughter of the male patient had the same *TTR* mutation. A full diagnostic workup did not reveal any signs of amyloidosis yet.

Conclusions: A novel amyloidogenic *TTR* mutation was found in a Dutch family. The clinical presentation of ATTR A45G amyloidosis in the affected family members was heart failure due to a late-onset cardiomyopathy. The systemic nature of this disease was reflected by bilateral CTS and by early signs of a polyneuropathy in the index patient.

© 2017 Elsevier Inc. All rights reserved.

1. Introduction

The etiology of hereditary transthyretin-derived (ATTR) amyloidosis is the deposition of amyloid fibrils in the extracellular matrix due to mutations of the gene encoding transthyretin (*TTR*). More than 110 *TTR* mutations have been associated with hereditary ATTR amyloidosis [1,2]. Disease presentation, severity, and clinical course of ATTR amyloidosis are variable. Usually the disease starts with the clinical picture of a polyneuropathy accompanied by autonomic neuropathy, but sometimes, a cardiomyopathy is the presenting manifestation. In addition, albeit less

frequent, other organs can be affected leading to carpal tunnel syndrome (CTS), vitreous opacities, or loss of renal function [1–3]. Clinical course and disease severity vary among different mutations [4]. Despite an initial monosymptomatic presentation, other organ involvement usually develops during disease progression. In the current report, we describe a Dutch family with a novel *TTR* mutation with late-onset cardiomyopathy, that is, not symptomatic before the sixth decade [5]. Although cardiac presentation was the prominent feature, a recent history of bilateral CTS and preclinical involvement of the peripheral nervous system were recognized in one of the two cases reflecting the systemic nature of the disease.

2. Patients and methods

A 78-year-old man and his 72-year-old sister, both known with atrial fibrillation (AF), presented with symptoms of heart failure at a hospital a couple of months after each other. Amyloidosis was considered a possible cause; consequently, a subcutaneous abdominal fat tissue aspirate was obtained that showed the presence of amyloid in both cases,

Funding sources: This research did not receive any specific grant from funding agencies in the public, commercial or not-for-profit sectors.

Disclosures: None

Journal Subject Terms: Cardiomyopathy, Heart Failure, Atrial Fibrillation, Genetics

* Corresponding author at: Department of Cardiology, University Medical Center Groningen, P.O. Box 30.001, 9700RB Groningen, The Netherlands. Tel.: +31-503613432; fax: +31-503619308.

E-mail address: s.h.c.klaassen@umcg.nl (S.H.C. Klaassen).

and subsequently, both cases were referred to our Amyloidosis Center of Expertise. A 56-year-old daughter of the male patient was referred later for clinical investigation.

Ample (more than 100 mg) subcutaneous abdominal fat tissue was aspirated using a 16-Gauge needle. Amyloid was extracted in 6-M guanidine hydrochloride and further analyzed as described [6]. The TTR concentration in fat tissue of the extracted amyloid was assessed immunochemically using an indirect enzyme-linked immunosorbent assay [7] and also chemically by proteomics using a selected reaction-monitoring-mass spectrometry assay (SRM-MS; kindly provided by Paula Picotti and Paul Boersema, Zürich, Switzerland). The amount of Congo red-stained birefringent material was assessed semiquantitatively [8].

DNA was analyzed in all cases by direct sequencing of exons 1 to 4 of the *TTR* gene. The primary translation product is 20 amino acids longer than the mature TTR protein because the signal peptide and propeptides are included. This leads to amino acid position numbers of the translation product that are 20 higher than those of the corresponding mature protein [2].

A full clinical investigation to detect other organs affected by amyloid was offered to all patients. Due to the observational nature of this study, according to Dutch law, informed consent and permission of the local institutional review board were not required.

3. Results

3.1. Case 1

A 78-year-old man, known with AF for the last 2 years, presented with symptoms of heart failure at our hospital. Plasma levels of NT-proBNP and hs-Troponin T were 1877 ng/l ($N < 125$) and 48 ng/l ($N < 14$), respectively. One year before, he suffered from CTS in both hands, which was successfully treated by surgery. His electrocardiogram showed AF, low-voltage QRS complexes, and a left anterior fascicular block. A 24-h rhythm monitoring did not reveal other arrhythmias. Echocardiography showed concentric left ventricular wall hypertrophy and a left ventricular ejection fraction (EF) of 55%. Hypertrophy of the right ventricular wall (7 mm) was also observed. A multigated acquisition scan showed a left ventricular EF > 65% and a right ventricular EF of 44%. Cardiac magnetic resonance (CMR) imaging showed late gadolinium enhancement and a thickened interventricular septum (18 mm). Based on these clinical findings, amyloidosis was considered to be present. Easily accessible subcutaneous abdominal fat tissue was aspirated as screening biopsy for amyloidosis. The tissue was stained with Congo red, which indeed showed the presence (abundant, visual grade 4+) of amyloid (Fig. 1) [8]. No signs of immunoglobulin free light chain overproduction (serum kappa free light chain 13.1 mg/l ($N < 20$) and lambda free light chain 13.0 mg/l ($N < 32$)) nor other signs of a plasma cell dyscrasia were found in serum, urine, or bone marrow.

These findings made light chain-derived systemic AL amyloidosis very unlikely. The creatinine clearance was 74 ml/min, and no proteinuria was observed. ^{123}I -Serum Amyloid P component (SAP) scintigraphy showed some splenic uptake, whereas $^{99\text{m}}\text{Tc}$ -diphosphonate bone scintigraphy showed strongly increased (3+) cardiac uptake (Fig. 2) [9]. ^{123}I -metaiodobenzylguanidine (^{123}I -MIBG) scintigraphy showed an increased washout (34%) and low heart-mediastinum ratio (late uptake 1.16) indicative of cardiac denervation [10]. A fine needle subcutaneous abdominal fat aspirate yielded a TTR concentration of amyloid in fat of 658-ng/mg fat tissue ($N < 7.5$ ng/mg) [6,7]. These findings indicated ATTR amyloidosis to be present. Wild-type ATTR amyloidosis was excluded because subsequent *TTR* gene analysis showed a novel mutation c.194C > G that encodes the primary translation product (p.A65G) and the mature protein TTR A45G [11]. SRM-MS proteomics confirmed the specific TTR mutation in the amyloid extracted from fat tissue. The patient was therefore diagnosed with hereditary ATTR A45G amyloidosis with prominent cardiac involvement and CTS. He had not noticed any symptoms of peripheral or autonomic neuropathy. Neurophysiological testing, however, revealed an early-stage length-dependent axonal sensory polyneuropathy in the feet of the patient. Quantitative sensory testing of the ankle also showed thin fiber neuropathy. He was treated with the TTR tetramer-stabilizing drug tafamidis for his polyneuropathy [12], and the clinical condition of both his heart and nerves seemed to stabilize during the next 2 years of follow-up.

3.2. Case 2

Family history of Case 1 revealed that the 72-year-old sister of the patient suffered from paroxysmal AF. She was admitted to an affiliated hospital because of heart failure caused by restrictive cardiomyopathy a few months after presentation of her brother. Upon further clinical investigation, she had no clear signs of CTS, polyneuropathy, or autonomic dysfunction. However, fat tissue analysis also showed amyloid (moderate, 3+) [8]. The TTR concentration of amyloid in fat was 122-ng/mg fat tissue ($N < 7.5$ ng/mg) [6]. *TTR* gene analysis identified the same *TTR* mutation. Therefore, the sister was also diagnosed with hereditary ATTR A45G amyloidosis. She was not interested in further clinical investigations nor in disease monitoring during follow-up.

3.3. Case 3

The daughter of Case 1 presented at the age of 56 at the outpatient clinic with nonspecific complaints. *TTR* gene analysis showed the same genotype as her father and aunt. A full diagnostic work-up for amyloidosis was initiated: symptoms and signs of polyneuropathy and autonomic neuropathy were lacking, NT-proBNP was marginally elevated (145 ng/L) with a normal hs-Troponin T (10 ng/l), no cardiac uptake was visible on the $^{99\text{m}}\text{Tc}$ -diphosphonate bone scintigraphy, and fat

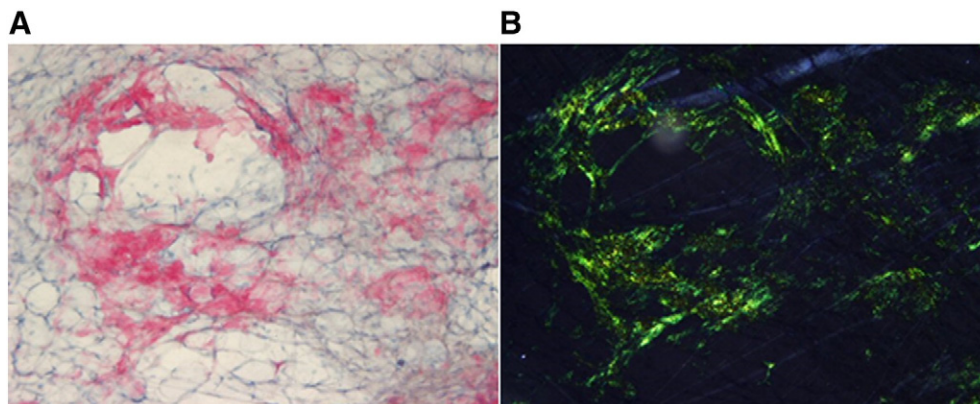


Fig. 1. Congo red-stained fine needle aspiration of abdominal fat tissue of Case 1. (A) Amyloid (4+) is red in bright light. (B) Amyloid is green in polarized light.

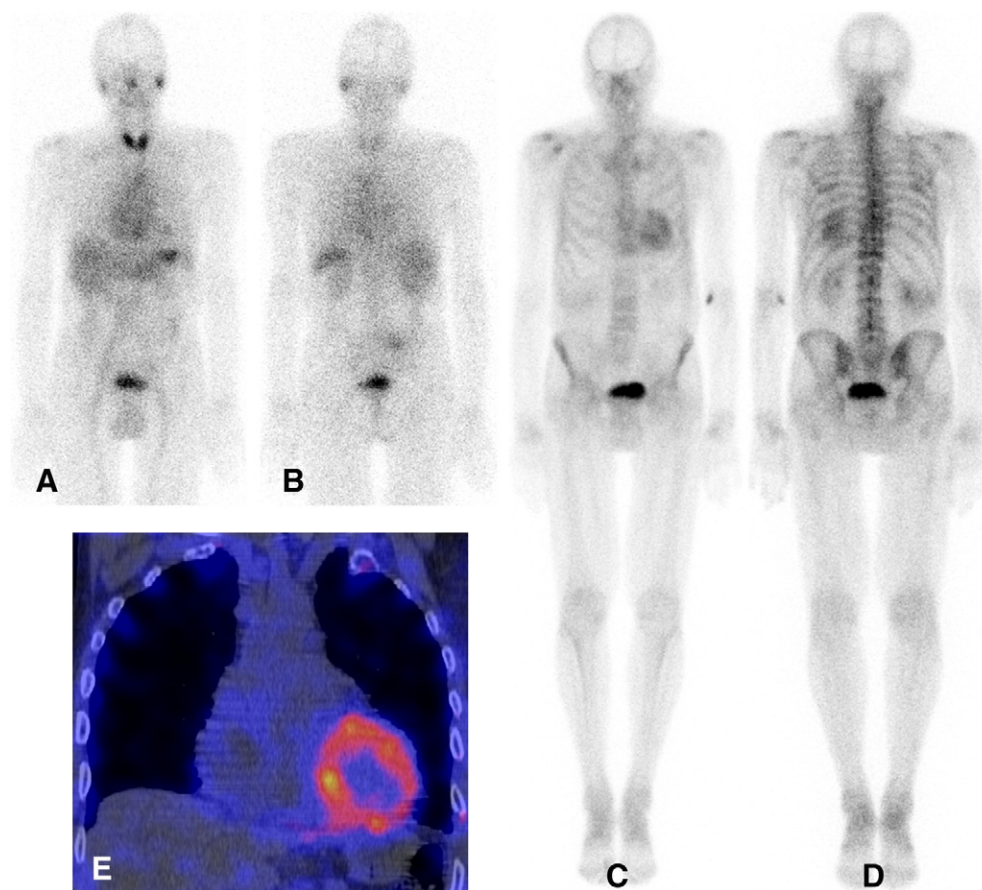


Fig. 2. (A–B) Anterior and posterior view ^{123}I -SAP scintigraphy of Case 1 with slightly increased uptake in the spleen (1+). Nonspecific uptake can be seen in thyroid gland, nasopharynx, stomach, and bladder. (C–D) Total body anterior and posterior view of $^{99\text{m}}\text{Tc}$ -hydroxymethylene diphosphonate (HDP) bone scintigraphy with increased uptake in the left ventricle (3+), increased uptake in soft tissues, and decreased uptake in the peripheral bones, indicating amyloid deposition. (E) Coronal fusion image Single Photon Emission Computed Tomography (CT) of the HDP bone scintigraphy showing again the highly increased uptake in the left ventricle (red and yellow color of the tracer), much higher than the physiological uptake in the bones (white CT image merged with blue color of the tracer).

tissue analysis did not show any amyloid deposits. Therefore, at that time, amyloidosis could not be diagnosed in the daughter, and she was scheduled for regular follow-up as a carrier of the mutation.

4. Discussion

A novel amyloidogenic *TTR* mutation, c.194C>G that encodes for the primary translation product (p.A65G) and the mature protein *TTR* A45G, was found in a Dutch family. This mutation was presented during the International Symposium on Amyloidosis in Indianapolis in 2014 and subsequently included in the *TTR* mutations registry [2]. The clinical picture of ATTR amyloidosis in the two affected family members was foremost a late-onset cardiomyopathy [4,5,13]. $^{99\text{m}}\text{Tc}$ -diphosphonate scintigraphy is currently considered useful in clinical practice and more specific than ultrasound and CMR for noninvasive detection of an ATTR amyloid cardiomyopathy [9].

Late-onset cardiomyopathy, frequently preceded by CTS, is typically caused by wild-type ATTR amyloidosis [14]. Initially, this diagnosis was considered in our index patient. However, some mutations causing hereditary ATTR amyloidosis are characterized by late-onset cardiomyopathy, such as in Afro-Caribbean patients with ATTR V122I amyloidosis who present with cardiac failure at median age 75 (range, 50–90) years [15]. In the Italian population with different mutations, the median age at onset of exclusive cardiomyopathy in hereditary ATTR amyloidosis is 70 (62–75) years [4]. A German focus with ATTR V20I amyloidosis with exclusive cardiomyopathy and occasionally CTS has a median age at onset of 60 years [5]. Therefore, in an elderly man

with ATTR amyloid cardiomyopathy and CTS a search for a *TTR* mutation is mandatory.

The *TTR* c.194C>G mutation is located at the end of exon 2 on the *TTR* gene. A single base change, a cytosine nucleotide replaced by a guanine nucleotide, is predicted to result in an amino acid change from alanine to glycine. Our group reported in 2014 this novel mutation to the Website concerning *TTR* mutations in hereditary amyloidosis [2]. Key features of both cases were biventricular hypertrophy and AF. Neurologic manifestations were also present, albeit less prominent. In 2016, another case with this *TTR* (p.A65G) mutation and amyloid cardiomyopathy was reported briefly [13]. These observations are in line with reports on all three other mutations of the same amino acid 65 of the *TTR* gene: (p.A65S), (p.A65T), and (p.A65D), in which the amino acid alanine (A) has been replaced by serine (S), threonine (T), and aspartic acid (D), respectively; therefore, all four mutations on this position 65 present as a cardiomyopathy [13,16–18]. However, neurologic sequelae can be present and should be sought for. In particular, a history of CTS – especially bilateral – in patients presenting with restrictive cardiomyopathy is a strong indicator that amyloidosis may be present [19]. By using the American College of Medical Genetics criteria for the interpretation of sequence variants the current *TTR* c.194C>G mutation can be classified as pathogenic [20].

Obvious limitations of this study are the small number of patients in this family that were studied and the short follow-up period. Another limitation is the absence of proof of actual presence of ATTR amyloid in cardiac tissue. Only one case history of a patient with both AL and ATTR amyloid simultaneously present in the heart has convincingly been documented [21]. Besides, a clearly elevated serum lambda free

light chain was found in this case. The specificity of intense cardiac uptake on diphosphonate scintigraphy is currently accepted as noninvasive evidence of the presence of ATTR amyloid in the myocardium in patients without an elevated free light chain in the blood [9]. Exclusion of AL amyloid is necessary but not sufficient for a diagnosis of ATTR amyloid. The conformation of both TTR and its particular mutation in amyloid by direct typing using SRM-MS is requisite for typing this amyloid as ATTR. Although the heart was not directly sampled, the imaging, the clinical scenario, and proof of ATTR amyloid in the fat tissue are sufficiently compelling.

Diuretic treatment is currently the only rational treatment option of heart failure with preserved ejection fraction (HFpEF) [22]. However, in ATTR amyloidosis the progression of polyneuropathy slows down after tetramer-stabilizing treatment by tafamidis and diflunisal in which the circulating TTR, a tetramer consisting of four identical molecules surrounding in the middle a tunnel for the transport of thyroxine, is protected against dissociation into highly amyloidogenic TTR dimers and monomers [12,23]. The possible effect of tafamidis on progression of ATTR amyloid cardiomyopathy is currently studied in a randomized clinical trial, the ATTR-ACT study [24]. A second trial in which the effect of siRNA on TTR production by the liver and thereby on progression of hereditary ATTR polyneuropathy is currently studied in the APOLLO trial [25]. A comparable ENDEAVOUR trial on hereditary ATTR cardiomyopathy has been stopped recently because of unexplained increased mortality in the treatment arm. The results of the ongoing two trials are expected in 2018. A favorable result might have big consequences for patients with hereditary ATTR cardiomyopathy but also for elderly men suffering from HFpEF caused by wild-type ATTR amyloid cardiomyopathy [26].

5. Conclusion

The novel *TTR* c.194C > G mutation found in this family is clinically characterized by late-onset cardiomyopathy, CTS, and less prominent neurological involvement.

Acknowledgments

None.

References

- [1] Connors LH, Lim A, Prokavova T, Roskens VA, Costello CE. Tabulation of human transthyretin (TTR) variants, 2003. *Amyloid* 2003;10:160–84.
- [2] Rowczenio D, Wechalekar A. Mutations in hereditary amyloidosis: Mutations in Transthyretin gene (*TTR*). <http://amyloidosismutations.com/mut-attr.php>. [Accessed September 12, 2016].
- [3] Semigran MJ. Transthyretin Amyloidosis: A “Zebra” of Many Stripes. *J Am Coll Cardiol* 2016;68:173–5.
- [4] Rapezzi C, Quarta CC, Obici L, Perfetto F, Longhi S, Salvi F, et al. Disease profile and differential diagnosis of hereditary transthyretin-related amyloidosis with exclusively cardiac phenotype: an Italian perspective. *Eur Heart J* 2013;34:520–8.
- [5] Bauer R, Dikow N, Brauer A, Kreuter M, Buss S, Evers C, et al. The “Wagshurst study”: p.Val40Ile transthyretin gene variant causes late-onset cardiomyopathy. *Amyloid* 2014;21:267–75.
- [6] Bijzet J, van Gameren II, Hazenberg BP. Fat tissue analysis in the management of patients with systemic amyloidosis. In: Picken MM, Dogan A, Herrera GA, editors. *Amyloid and related disorders: Surgical Pathology and clinical Correlations*. 2nd ed. New York: Humana Press; 2015. p. 229–48.
- [7] Hazenberg BP, van Schijndel B, Bijzet J, Limburg PC, Bos R, Haagsma EB. Diagnostic performance of transthyretin measurement in fat tissue of patients with ATTR amyloidosis. *Amyloid* 2011;18(Suppl. 1):79.
- [8] Hazenberg BP, Bijzet J, Limburg PC, Skinner M, Hawkins PN, Butrimiene I, et al. Diagnostic performance of amyloid A protein quantification in fat tissue of patients with clinical AA amyloidosis. *Amyloid* 2007;14:133–40.
- [9] Gillmore JD, Maurer MS, Falk RH, Merlini G, Damy T, Dispenzieri A, et al. Non-Biopsy Diagnosis of Cardiac Transthyretin Amyloidosis. *Circulation* 2016;133:2404–12.
- [10] Noordzij W, Glaudemans AW, van Rheeën RW, Hazenberg BP, Tio RA, Dierckx RA, et al. (123)I-Labelled metaiodobenzylguanidine for the evaluation of cardiac sympathetic denervation in early stage amyloidosis. *Eur J Nucl Med Mol Imaging* 2012;39:1609–17.
- [11] Sipe JD, Benson MD, Buxbaum JN, Ikeda S, Merlini G, Saraiva MJ, et al. Amyloid fibril proteins and amyloidosis: chemical identification and clinical classification International Society of Amyloidosis 2016 Nomenclature Guidelines. *Amyloid* 2016;23:209–13.
- [12] Coelho T, Maia LF, Martins da Silva A, Waddington Cruz M, Planté-Bordeneuve V, Lozeron P, et al. Tafamidis for transthyretin familial amyloid polyneuropathy: a randomized, controlled trial. *Neurology* 2012;79:785–92.
- [13] Pilebro B, Suhr OB, Näsland U, Westermarck P, Lindqvist P, Sundström T. 99mTc-DPD uptake reflects amyloid fibril composition in hereditary transthyretin amyloidosis. *Ups J Med Sci* 2016;121:17–24.
- [14] Mohammed SF, Mirzoyev SA, Edwards WD, Dogan A, Grogan DR, Dunlay SM, et al. Left ventricular amyloid deposition in patients with heart failure and preserved ejection fraction. *JACC Heart Fail* 2014;2:113–22.
- [15] Dzungu JN, Papadopoulos SA, Wykes K, Mahmood I, Marshall J, Valencia O, et al. Afro-Caribbean Heart Failure in the United Kingdom: Cause, Outcomes, and ATTR V122I Cardiac Amyloidosis. *Circ Heart Fail* 2016;9:e003352.
- [16] Saraiva MJ, Almeida MR, Sherman W, Gawinowicz M, Costa P, Costa PP, et al. A new transthyretin mutation associated with amyloid cardiomyopathy. *Am J Hum Genet* 1992;50:1027–30.
- [17] Saraiva MJ. Transthyretin mutations in health and disease. *Hum Mutat* 1995;5:191–6.
- [18] Janunger T, Anan I, Holmgren G, Lövhelm O, Ohlsson PI, Suhr OB, et al. Heart failure caused by a novel amyloidogenic mutation of the transthyretin gene: ATTR Ala45Ser. *Amyloid* 2000;7:137–40.
- [19] Conceição I, González-Duarte A, Obici L, Schmidt HH, Simoneau D, Ong ML, et al. “Red-flag” symptom clusters in transthyretin familial amyloid polyneuropathy. *J Peripher Nerv Syst* 2016;21:5–9.
- [20] Richards S, Aziz N, Bale S, Bick D, Das S, Gastier-Foster J, et al. Standards and guidelines for the interpretation of sequence variants: a joint consensus recommendation of the American College of Medical Genetics and Genomics and the Association for Molecular Pathology. *Genet Med* 2015;17:405–24.
- [21] Mahmood S, Gilbertson JA, Rendell N, Whelan CJ, Lachmann HJ, Wechalekar AD, et al. Two types of amyloid in a single heart. *Blood* 2014;124:3025–7.
- [22] Ponikowski P, Voors AA, Anker SD, Bueno H, Cleland JG, Coats AJ, et al. 2016 ESC Guidelines for the diagnosis and treatment of acute and chronic heart failure: The Task Force for the diagnosis and treatment of acute and chronic heart failure of the European Society of Cardiology (ESC). Developed with the special contribution of the Heart Failure Association (HFA) of the ESC. *Eur Heart J* 2016;37:2129–200.
- [23] Berk JL, Suhr OB, Obici L, Sekijima Y, Zeldenrust SR, Yamashita T, et al. Repurposing diflunisal for familial amyloid polyneuropathy: a randomized clinical trial. *JAMA* 2013;310:2658–67.
- [24] Cho Y, Baranczak A, Helmke S, Teruya S, Horn EM, Maurer MS, et al. Personalized medicine approach for optimizing the dose of tafamidis to potentially ameliorate wild-type transthyretin amyloidosis (cardiomyopathy). *Amyloid* 2015;22:175–80.
- [25] Coelho T, Adams D, Silva A, Lozeron P, Hawkins PN, Mant T, et al. Safety and efficacy of RNAi therapy for transthyretin amyloidosis. *N Engl J Med* 2013;369:819–29.
- [26] González-López E, Gallego-Delgado M, Guzzo-Merello G, de Haro-Del Moral FJ, Cobo-Marcos M, Robles C, et al. Wild-type transthyretin amyloidosis as a cause of heart failure with preserved ejection fraction. *Eur Heart J* 2015;36:2585–94.