

University of Groningen

## Different aspects of hyperthermic isolated limb perfusion

Ginkel, Robert Johannes van

**IMPORTANT NOTE: You are advised to consult the publisher's version (publisher's PDF) if you wish to cite from it. Please check the document version below.**

*Document Version*

Publisher's PDF, also known as Version of record

*Publication date:*

2002

[Link to publication in University of Groningen/UMCG research database](#)

*Citation for published version (APA):*

Ginkel, R. J. V. (2002). *Different aspects of hyperthermic isolated limb perfusion*. s.n.

**Copyright**

Other than for strictly personal use, it is not permitted to download or to forward/distribute the text or part of it without the consent of the author(s) and/or copyright holder(s), unless the work is under an open content license (like Creative Commons).

The publication may also be distributed here under the terms of Article 25fa of the Dutch Copyright Act, indicated by the "Taverne" license. More information can be found on the University of Groningen website: <https://www.rug.nl/library/open-access/self-archiving-pure/taverne-amendment>.

**Take-down policy**

If you believe that this document breaches copyright please contact us providing details, and we will remove access to the work immediately and investigate your claim.

*Downloaded from the University of Groningen/UMCG research database (Pure): <http://www.rug.nl/research/portal>. For technical reasons the number of authors shown on this cover page is limited to 10 maximum.*

---

# **5** Isolated limb perfusion of an irradiated foot with TNF, interferon and melphalan

**Robert J. van Ginkel<sup>1</sup>**

**Harald J. Hoekstra<sup>1</sup>**

**Alex M.M. Eggermont<sup>2</sup>**

**Elisabeth Pras<sup>3</sup>**

**Heimen Schraffordt Koops<sup>1</sup>**

Departments of Surgical Oncology<sup>1</sup>, Radiotherapy<sup>3</sup>, University Hospital Groningen, Groningen, The Netherlands and Dr. Daniel den Hoed Cancer Center<sup>2</sup>, Rotterdam, The Netherlands.

*Archives of Surgery* 1996; **131**: 672-674.

### Abstract

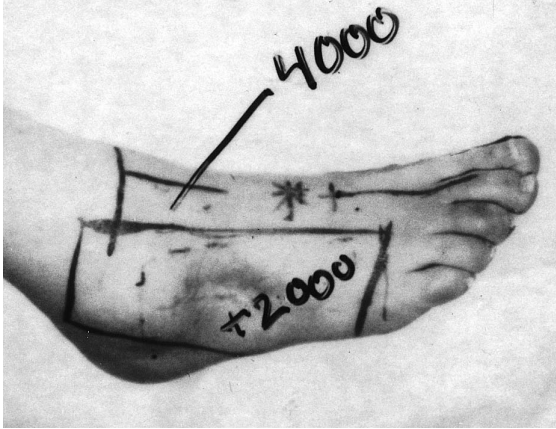
*Hyperthermic isolated limb perfusion (HILP) with tumor necrosis factor alpha (TNF), interferon gamma (IFN) and melphalan is a highly effective limb-saving treatment in patients with irresectable soft tissue sarcoma or satellitosis and in-transit metastases of melanoma. A 57-yr old woman presented with the second recurrence of a high grade malignant fibrous histiocytoma of the right foot following previous local resection plus curative adjuvant radiotherapy. The first recurrence of the lesion was treated by HILP with cisplatin; the second recurrence was treated by HILP with TNF, IFN and melphalan. The tumor and the area that had been irradiated showed a bluish color a few hours after tumor necrosis factor perfusion. Nine days after TNF perfusion a lower leg amputation had to be performed because of severe necrosis of the foot.*

### Introduction

Recently Lienard and colleagues described the magnificent effect of hyperthermic isolated limb perfusion (HILP) with recombinant tumor necrosis factor alfa (TNF), recombinant interferon gamma (IFN) and melphalan in 23 patients with locally advanced melanomas and soft tissue sarcomas of the extremities.<sup>1</sup> The effect on the tumors was striking: 19 (83%) complete responses and four (17%) partial responses after a single perfusion with the triple-drug regimen. Local toxicity in the perfused limb was minimal, 88% grade II and 12% grade III classified according to Wieberdink.<sup>2</sup> These figures are comparable with local tissue toxicity in patients treated with melphalan as the single perfusion agent. The preliminary results of this study suggested that high-dose TNF can be administrated safely by regional perfusion. HILP of the limb with this triple drug regimen was started in 1991 at Groningen University Hospital in the Netherlands, one of several institutions participating in a multicenter study. The effect of this new combined modality therapy of isolated limb perfusion and delayed surgery in a patient with a previous history of irradiation of the foot is described.

### Case report

In 1988 a 57-yr old woman presented with a 5 x 6 cm high grade malignant fibrous histiocytoma on the lateral side of the right foot without distant metastases. She refused a curative amputation of the lower leg. Therefore a marginal resection was performed, followed by 60 Gy external beam radiotherapy, 40 Gy (2 Gy per day) on the whole foot, and a 20 Gy boost on the tumor (*Fig. 1*). Two years after initial treatment the tumor recurred locally without evidence of distant metastases. Again she refused a lower leg amputation. In an attempted to render the tumor resectable,

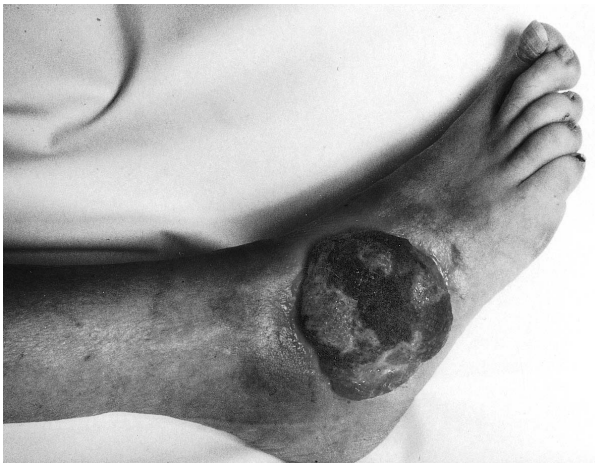

**Fig. 1** Clinical appearance of the patients right foot demonstrating the radiation field and dosages of the initial treatment

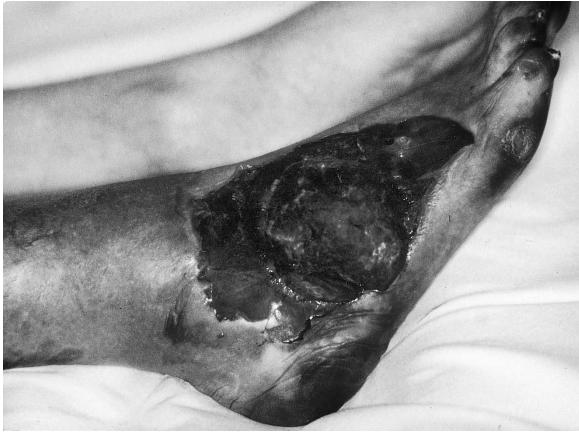HILP through the popliteal vessels with 100 mg cisplatin (30mg cisplatin per liter limb volume) was performed. Histologic biopsy specimens of the tumor obtained 1 and 2 weeks after cisplatin perfusion showed no viable tumor cells, and a complete remission was observed clinically.

In January 1991 the second local recurrence without distant metastases was observed, again with persistent refusal by the patient for a curative amputation. During six months the patient withdrew from follow-up but presented in June 1991 with a local ulcerating tumor measuring 10 x 12 cm, still without metastatic disease (*Fig. 2*).

Because of the patients persistent refusal to undergo an amputation, a HILP with TNF, IFN and melphalan was suggested and informed consent was obtained. One and 2 days before HILP, a dose of 0,2 mg of IFN (Boehringer Ingelheim, Ingelheim, Germany) was administered subcutaneously. A 90-minute mild hyperthermic (39°C to 40°C), popliteal perfusion was performed with 0,2 mg of IFN, 4 mg of TNF



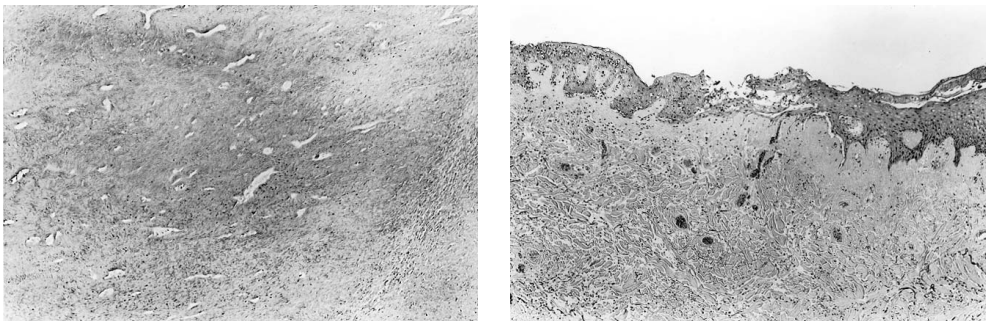
**Fig. 2** Clinical appearance of the patients right foot demonstrating the second recurrence



**Fig. 3** The right foot and ankle region 2 days after hyperthermic isolated limb perfusion with TNF, IFN and melphalan. The tumor is black necrotic and the rest of the foot is blue, sharply delineated at the edge of the radiation field.

(Boehringer Ingelheim), and 45 mg of melphalan (10 mg/L of limb volume)(Burroughs Wellcome, London, England). Leakage to the systemic circulation measured with  $^{131}\text{I}$  labeled albumin as a tracer was 2.8 %.<sup>3</sup> ECG, urine output, blood pressure, venous and pulmonary pressures were recorded during and after perfusion until the second postoperative day. A continuous infusion of dopamine at 2.8 mg/kg/min for 18 hours was given. Postoperatively the patient experienced fever and chills but no hematological, hepatic or renal toxicity was observed.

A few hours after TNF perfusion, the entire right foot appeared bluish up to a definite line at the ankle; the rest of the leg had a normal circulation. Two days after perfusion, the tumor was black and necrotic in concordance with the 60-Gy total dose



**Fig 4** Left, A necrotic tumor tissue specimen after tumor necrosis factor perfusion (hematoxylin-eosin, x64) Right, The border area between nonirradiated normal skin (right) and irradiated skin (left). The irradiated site demonstrates infiltration of both the dermis and the epidermis with granulocytes and marked stasis with thrombosis of the microcirculation. In the nonirradiated area, normal vascular structures are seen (hematoxylin-eosin, x64).

radiotherapy field, while the rest of the foot (40-Gy field) was blue and showed some dry shrinkage of the skin (*Fig. 3*). Because of the severe necrosis, amputation of the right foot below the knee had to be performed 9 days after TNF perfusion. Histological findings were consistent with complete necrosis of the tumor (*Fig. 4, left*). The amputation wound healed without complications, and the patient is alive without evidence of disease 3 years after TNF perfusion and subsequent amputation.

### Discussion

In 1975, Carswell et al. showed that tumor-necrotizing activity in the sera of animals given injections of endotoxin was due to a host factor named tumor necrosis factor (TNF).<sup>4</sup> The mechanisms of the anti tumor activity of TNF however, are still not elucidated and basis of further research. The results of intralesional or intravenous administration of recombinant human TNF in mice with solid Meth A sarcoma of the skin were recently described by van de Wiel and Bloksma.<sup>5</sup> Treatment with TNF caused red discoloration and necrosis of the central portion of the tumor within 24 hours. However, incubation of Meth A cells in the presence of TNF *in vitro* did not affect their capacity to incorporate tritiated thymidine, indicating resistance of the Meth A cells to TNF *in vitro* and supporting the thought that other mechanisms are responsible for the observed discoloration and necrosis of the tumor *in vivo*. Microscopic investigations of the tumors showed hyperemia, congestion, endothelial damage and hemorrhage in the central part of the tumor, while just outside the tumor edema and an infiltrate of polymorphonuclear cells was seen. Locally injected normal skins with TNF showed moderate vascular effects without necrosis. This and other investigations demonstrated that the vascular endothelial cells in particular are the main target cells of this TNF induced antitumor effect.<sup>6,7</sup> When incubated with TNF, cultured endothelial monolayers show two phenomena. Stolpen et al. demonstrated that TNF causes morphological changes of the endothelial cells, they become elongated, overlap, rearrange their actin filaments and lose their stainable fibronectin matrix.<sup>8</sup> Suppression of anticoagulant mechanisms and the production of the procoagulant cofactor tissue factor, is the second phenomenon<sup>9</sup>. These TNF-induced changes are more prominent in areas with growing and/or migrating endothelial cells, a situation that occurs within the tumor bed and explaining why the tumor vasculature is more susceptible for TNF compared with normal vessels.<sup>10</sup> A higher expression of TNF receptors on the endothelial cell surface of dividing and growing endothelial cells seem to be the cause of this high sensitivity for TNF.<sup>10,11</sup> In summary; TNF exposure emerges an altered endothelial cell phenotype, anticoagulant mechanisms are suppressed and tissue factor is produced, leading to fibrin accumulation at the endothelial cell surface<sup>12</sup> and thrombus formation in the tumor vessel, causing



circulatory stasis and ischemia inside the tumor followed by necrosis of the tumor. Besides this early vascular phenomenon, a latter in time occurring immune effect with polymorphonuclear cell binding to the activated endothelium,<sup>7,13,14</sup> and a direct cytotoxic effect of TNF demonstrated in vitro against a variety of cell lines<sup>15,16</sup> are two other mechanisms that could contribute in the anti-tumor effect of TNF.

In our case, not only the vascularization of the tumor was affected by TNF exposure but also the microvascularization of the area that had been irradiated 3 years earlier. Microscopical examination of the border area between irradiated and nonirradiated areas revealed infiltration of both dermis and the epidermis with granulocytes, and marked stasis with thrombosis of the micro circulation of the irradiated area, causing necrosis. These phenomena were absent from the perfused nonirradiated area (*Fig. 4, right*).

Late effects of normal tissues after radiotherapy are well known. Hopewell demonstrated that arteries of the hamsters cheek pouch showed localized constrictions after irradiation.<sup>17</sup> These constrictions were caused by clones of dividing endothelial cells and might be the predominant factor influencing the degeneration of the capillary bed after radiotherapy.<sup>18</sup> Evidence of this occlusive effect of vessels by proliferating endothelial cells after radiation have also been reported by other investigators.<sup>19</sup> Since dividing and migrating endothelial cells are more sensitive to TNF than quiescent endothelial cells, it is likely that not only the dividing and migrating endothelial cells of the tumor bed but also the endothelial cells in the irradiated area of the foot in this patient were activated by TNF, causing stasis and thrombosis of the microcirculation in both areas. Recently Milas and coworkers also demonstrated a synergistic effect between radiotherapy and TNF.<sup>20,21</sup>

One and a half year before TNF perfusion, this patient received HILP with cisplatin. No literature is available describing the acute or long term effect of cisplatin on the endothelial cells, however treatment with antineoplastic agents is associated with vascular toxicity.<sup>22</sup> With regard to cisplatin Vogelzang et al. described the relation between hypomagnesemia and an increased risk of Raynaud's phenomenon after cisplatin, vinblastine and bleomycin treatment.<sup>23</sup> Jackson et al. described a thrombotic microangiopathic syndrome characterized by renal insufficiency, microangiopathic hemolytic anemia and thrombocytopenia in patients treated with an identical regimen.<sup>24</sup> Histological examination of renal biopsy specimens showed marked luminal narrowing of small arteries as a result of thrombus formation and subintimal thickening. Whether cisplatin is the sole agent responsible for this vascular effect remains unclear especially since it is known that bleomycin in this combination chemotherapy has a prominent effect on endothelial cells.<sup>25</sup> Analysis of cisplatin perfusions data, performed at our clinic showed severe neurotoxicity, yet no signs of

vascular disturbances were found (i.e. Raynaud's phenomenon).<sup>26</sup> A synergistic effect between cisplatin and radiotherapy is known when cisplatin is administered shortly before or after radiotherapy,<sup>27</sup> in this patient the interval between radiotherapy and cisplatin perfusion lasted too long to make synergism likely.

Other radiation-related or radiation-independent factors may also be contributory, i.e., the radiation dosage, time interval between radiation and TNF perfusion, and the irradiated anatomical site. To distinguish the contribution of each of these different factors experimental investigations should be performed. Awaiting the results of such experiments, we would like to alert surgeons and radiation oncologists to the possible complications that may occur after TNF perfusion, when the perfused limb has already been irradiated.



### References

- 1 Lienard D, Ewalenko P, Delmotte JJ, Renard N, Lejeune FJ. High-dose recombinant tumor necrosis factor alpha in combination with interferon gamma and melphalan in isolation perfusion of the limbs for melanoma and sarcoma. *J Clin Oncol* 1992; **10**: 52-60.
- 2 Wieberdink J, Benckhuysen C, Braat RP, Van Slooten EA, Olthuis GAA. Dosimetry in isolation perfusion of the limb by assessment of perfused tissue volume and grading of toxic tissue reactions. *Eur J Cancer Clin Oncol* 1982; **18**: 905-910.
- 3 Hoekstra HJ, Naujocks T, Schraffordt Koops H, et al. Continuous leakage monitoring during hyperthermic isolated regional perfusion of the lower limb: techniques and results. *Reg Cancer Treat* 1992; **4**: 301-304.
- 4 Carswell EA, Old LJ, Kassel RL. An endotoxin induced serum factor that causes necrosis of tumors. *Proc Natl Acad Sci USA* 1975; **72**: 3666-3670.
- 5 Van de Wiel PA, Bloksma N, Kuper CF, Hofhuis FM, Willers JM. Macroscopic and microscopic early effects of tumor necrosis factor on murine Meth A sarcoma, and relation to curative activity. *J Pathol* 1989; **157**: 65-73.
- 6 Van de Wiel PA, Pieters RH, van der Pijl A, Bloksma N. Synergic action between tumor necrosis factor and endotoxins or poly(A.U) on cultured bovine endothelial cells. *Cancer Immunol Immunother* 1989; **29**: 23-28.
- 7 Palladino MAJR, Shalaby MR, Kramer SM, et al. Characterization of the antitumor activities of human tumor necrosis factor- $\alpha$  and the comparison with other cytokines: induction of tumor-specific immunity. *J Immunol* 1987; **138** : 4023-4032.
- 8 Stolpen AH, Guinan EC, Fiers W, Pober JS. Recombinant tumor necrosis factor and immune interferon act singly and in combination to reorganize human vascular endothelial cell monolayers. *Am J Pathol* 1986; **123**: 16-24.
- 9 Nawroth PP, Stern DM. Modulation of endothelial cell hemostatic properties by tumor necrosis factor. *J Exp Med* 1986; **163**: 740-745.
- 10 Gerlach H, Lieberman H, Bach R, et al. Enhanced responsiveness of endothelium in the growing/motile state to tumor necrosis factor/cachectin [published erratum appears in *J Exp Med* 1989 Nov 1;170(5):1793]. *J Exp Med* 1989; **170**: 913-931.
- 11 Espevik TP, Brockhaus M, Loetscher H, Nonstad U, Shalaby R. Characterization of binding and biological effects of monoclonal antibodies against a human tumor necrosis factor receptor. *J Exp Med* 1990; **171**: 415-426.
- 12 Nawroth P, Handley D, Matsueda G, et al. Tumor necrosis factor/cachectin-induced intravascular fibrin formation in meth A fibrosarcomas. *J Exp Med* 1988; **168**: 637-647.
- 13 Gamble JR, Harlan JM, Klebanoff SJ, Vadas MA. Stimulation of the adherence of neutrophils to umbilical vein endothelium by human recombinant tumor necrosis factor. *Proc Natl Acad Sci U S A* 1985; **82**: 8667-8671.
- 14 Renard N, Lienard D, Lespagnard L, et al. Early endothelium activation and polymorphonuclear cell invasion precede specific necrosis of human melanoma and sarcoma treated by intravascular high-dose tumor necrosis factor alpha (TNF). *Int J Cancer* 1994; **57**: 656-663.
- 15 Helson L, Green S, Carswell E, Old LJ. Effect of tumor necrosis factor on cultured human melanoma cells. *Nature* 1975; **258**: 731-732.

- 16 Sugarman BJ, Aggarwal BB, Hass PE, Figari IS, Palladino MA. Recombinant human tumor necrosis factor-alpha: effects on proliferation of normal and transformed cells in vitro. *Science* 1985; **230**: 943-945.
- 17 Hopewell JW. Early and late changes in the functional vascularity of the hamster cheek pouch after local x-irradiation. *Radiat Res* 1975; **63**: 157-164.
- 18 Hopewell JW. Letter: The late vascular effects of radiation. *Br J Radiol* 1974; **47**: 157-158.
- 19 Fajardo LF, Stewart JR. Capillary injury preceding radiation-induced myocardial fibrosis. *Radiology* 1971; **101**: 429-433.
- 20 Nishiguchi I, Willingham V, Milas L. Tumor necrosis factor as an adjunct to fractionated radiotherapy in the treatment of murine tumors. *Int J Radiat Oncol Biol Phys* 1990; **18**: 555-558.
- 21 Sersa G, Willingham V, Milas L. Anti-tumor effects of tumor necrosis factor alone or combined with radiotherapy. *Int J Cancer* 1988; **42**: 129-134.
- 22 Doll DC, Ringenberg QS, Yarbrow JW. Vascular toxicity associated with antineoplastic agents. *J Clin Oncol* 1986; **4**: 1405-1417.
- 23 Vogelzang NJ, Torkelson JL, Kennedy BJ. Hypomagnesemia, renal dysfunction, and Raynaud's phenomenon in patients treated with cisplatin, vinblastine, and bleomycin. *Cancer* 1985; **56**: 2765-2770.
- 24 Jackson AM, Rose BD, Graff LG, et al. Thrombotic microangiopathy and renal failure associated with antineoplastic chemotherapy. *Ann Intern Med* 1984; **101**: 41-44.
- 25 Nicolson GL, Custead SE. Effects of chemotherapeutic drugs on platelet and metastatic tumor cell-endothelial cell interactions as a model for assessing vascular endothelial integrity. *Cancer Res* 1985; **45**: 331-336.
- 26 Hoekstra HJ, Schraffordt Koops H, De Vries EGE, Van Weerden TW, Oldhoff J. Toxicity of hyperthermic isolated limb perfusion with cisplatin for recurrent melanoma of the lower extremity after previous perfusion treatment. *Cancer* 1993; **72**: 1224-1229.
- 27 Vokes EE. Interactions of chemotherapy and radiation. *Semin Oncol* 1993; **20**: 70-79.

