

University of Groningen

The microenvironment as determinant of testicular germ cell tumor biology

Timmer, Albertus

IMPORTANT NOTE: You are advised to consult the publisher's version (publisher's PDF) if you wish to cite from it. Please check the document version below.

Document Version

Publisher's PDF, also known as Version of record

Publication date:

1995

[Link to publication in University of Groningen/UMCG research database](#)

Citation for published version (APA):

Timmer, A. (1995). *The microenvironment as determinant of testicular germ cell tumor biology*. [S.n.].

Copyright

Other than for strictly personal use, it is not permitted to download or to forward/distribute the text or part of it without the consent of the author(s) and/or copyright holder(s), unless the work is under an open content license (like Creative Commons).

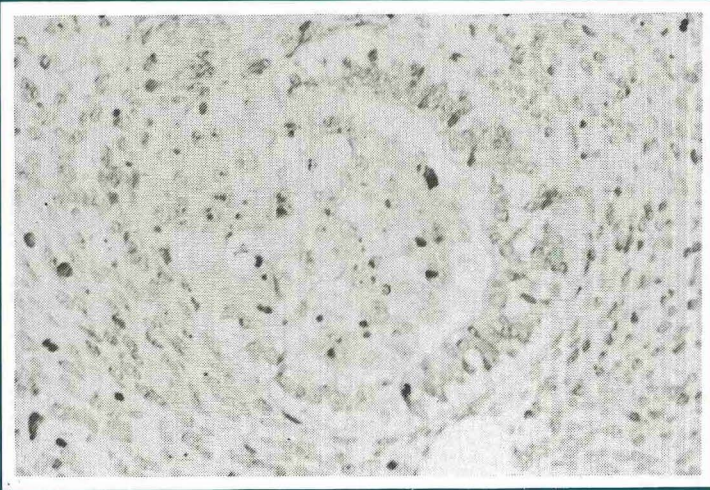
The publication may also be distributed here under the terms of Article 25fa of the Dutch Copyright Act, indicated by the "Taverne" license. More information can be found on the University of Groningen website: <https://www.rug.nl/library/open-access/self-archiving-pure/taverne-amendment>.

Take-down policy

If you believe that this document breaches copyright please contact us providing details, and we will remove access to the work immediately and investigate your claim.

Downloaded from the University of Groningen/UMCG research database (Pure): <http://www.rug.nl/research/portal>. For technical reasons the number of authors shown on this cover page is limited to 10 maximum.

**THE MICROENVIRONMENT AS DETERMINANT OF
TESTICULAR GERM CELL TUMOR BIOLOGY**



ALBERTUS TIMMER

**THE MICROENVIRONMENT AS DETERMINANT OF
TESTICULAR GERM CELL TUMOR BIOLOGY**

STELLINGEN

behorende bij het proefschrift:

THE MICROENVIRONMENT AS DETERMINANT OF TESTICULAR GERM CELL TUMOR BIOLOGY.

1. Maligne tumoren zijn een karikatuur van het proces van normale weefselvernieuwing en embryogenese.

Pierce et al., Cancer Res 1988, 48: 1196-1204

2. Het micromilieu is essentieel voor de fenotypische expressie van testiculaire kiemceltumoren.

3. Het Tera/Tera-CP model is niet alleen geschikt voor de bestudering van mechanismen welke ten grondslag liggen aan de (intrinsieke en verworven) resistentie voor cisplatin, maar kan ook gebruikt worden voor de bestudering van de relatie tussen resistentie, differentiatie (inductie) en tumor biologisch gedrag.

4. De genen die coderen voor nucleaire retinoïd receptoren kunnen worden beschouwd als tumor suppressor genen. De betrokkenheid van deze genen in de pathogenese en differentiatie van testiculaire kiemceltumoren dient nader te worden onderzocht.

5. De classificatie van (maligne) tumoren dient recht te doen aan de pathogenese en biologie van de tumor. Het is daarom te overwegen in het geval van testiculaire kiemceltumoren de term carcinoma in situ te vervangen door intratubular germ cell neoplasia of, nog beter: gonocytoma in situ.

6. Het is te verwachten dat moleculair pathologisch onderzoek een belangrijk aanvullend hulpmiddel wordt bij de diagnostiek van (maligne) tumoren. Nieuw op te leiden assistenten dienen dan ook tijdens de opleiding vertrouwd te worden gemaakt met deze nieuwe vorm van diagnostiek.

7. Een (kort durende) stage op de afdeling Pathologie zou onderdeel moeten uitmaken van de opleiding tot medisch specialist en draagt bij tot een reëel verwachtingspatroon van de betrokken medisch specialist ten aanzien van de patholoog.

8. Door uit het publieke bestel te treden heeft Veronica niet alleen zichzelf, maar ook de publieke omroepen een dienst bewezen.

9. Een goede gezondheid is niet zo vanzelfsprekend als het lijkt. Vanuit dit gezichtspunt is de prenatale geslachtsbepaling zonder medische indicatie van triviaal belang.

10. Na een lang bestaand unilateraal cataract dient men vóór een eventuele operatie een goed onderzoek te verrichten naar de binoculaire functies.

Jolanda Timmer, afstudeerscriptie Orthoptie 1991

11. De filmkritieken in de krant zeggen meer over de persoonlijke voorkeur van de recensent dan over de amusementswaarde van de film.
12. De emancipatie van vrouwen en mannen wordt (sterk) geremd door het beperken van de toegankelijkheid tot adequate kinderopvang.
13. Dat nog steeds met enige vertedering over het slechte handschrift van artsen wordt gesproken wekt verwondering. Klaarblijkelijk is de patiënt nog niet mondig genoeg.
14. Een patholoog is geen gekloneerde "Dr. Rusteloos".

Albertus Timmer, oktober 1995

RIJKSUNIVERSITEIT GRONINGEN

**THE MICROENVIRONMENT AS DETERMINANT OF
TESTICULAR GERM CELL TUMOR BIOLOGY**

Proefschrift

ter verkrijging van het doctoraat in de
Geneeskunde
aan de Rijksuniversiteit Groningen
op gezag van de
Rector Magnificus Dr F. van der Woude
in het openbaar te verdedigen op
woensdag 29 november 1995
des namiddags te 4.00 uur

door

Albertus Timmer

geboren op 10 mei 1963
te Assen

Promotores: Prof. Dr. W. Timens

Prof. Dr. N.H. Mulder

Prof. Dr. J.W. Oosterhuis

Referent: Dr. E.G.E. de Vries

Promotiecommissie:

Prof. Dr. P. Herrlich

Prof. Dr. B. de Jong

Prof. Dr. G. Stoter

ISBN 90 367 0550 9

STICHTING DRUKKERIJ



REGENBOOG

Aan mijn ouders

CONTENTS

Chapter 1	General introduction	13
Chapter 2.1	Morphology, behavior, and function of cells are regulated by integrin mediated interactions with the extracellular matrix	35
Chapter 2.2	The tumor microenvironment: possible role of integrins and the extracellular matrix in tumor biological behavior of intratubular germ cell neoplasia and testicular seminomas <i>Am J Pathol 1994, 144: 1035-1044</i>	59
Chapter 2.3	Integrins and extracellular matrix proteins in testicular nonseminomas	79
Chapter 3	Retinoic acid and cisdiamminedichloroplatinum in the treatment of murine teratocarcinomas in vivo in a nullipotent model <i>J Immunother 1993, 13: 261-266</i>	99
Chapter 4.1	Cis-diamminedichloroplatinum(II) resistance in vitro and in vivo in human embryonal carcinoma cells <i>Cancer Res 1993, 53: 5707-5713</i>	111
Chapter 4.2	Combination of cisplatin and 13-cis retinoic acid for the treatment of cisplatin-sensitive and -resistant human embryonal carcinoma xenografts in mice	129
Chapter 4.3	Expression of integrin subunits in the human embryonal carcinoma cell line Tera and its cisplatin resistant subline Tera-CP	143
Chapter 5	Summary, general discussion, and future prospects	153
Chapter 6	Nederlandse samenvatting	167
Dankwoord		175

Chapter 1

GENERAL INTRODUCTION

EPIDEMIOLOGY AND HISTOLOGY OF TESTICULAR GERM CELL TUMORS

Testicular germ cell tumors are relatively rare (1-3% of all malignant tumors). However, between 15 and 45 years of age testicular germ cell tumors are the most frequent tumors encountered in the male population, and the incidence is reported to be increasing ^{1,2}.

According to the World Health Organization (WHO) testicular germ cell tumors histopathologically can be divided into seminomas (SE) (50%) and nonseminomas (NS) (40%)². In the WHO classification the tumors in which a SE and NS component both are present are classified as NS ³, whereas in the British classification these tumors are referred to as combined tumors (10%) ⁴. Based on histopathological characteristics SE have been divided into four subtypes: classical SE, anaplastic SE, SE with syncytiotrophoblastic giant cells, and spermatocytic seminoma. NS may be composed of embryonal carcinoma, teratoma (immature, mature, and with malignant transformation), yolk sac tumor, and choriocarcinoma. In the majority of NS more than one histological subtype can be found ². The median age of clinical presentation for tumors arising after puberty is ± 25 years for NS, ± 40 years for SE, and for combined tumors it is in between ⁵.

Infantile testicular germ cell tumors are considered as a separate entity because of their epidemiology, clinical behavior, histology, ploidy and chromosomal constitution. Unlike tumors of adolescents and adults the majority of germ cell tumors of the infantile testis is composed of pure yolk sac tumor or teratoma ⁶⁻¹¹.

Although morphologically spermatocytic seminomas of elderly men (median age of clinical presentation ± 55 years) superficially resemble spermatogenic cells, in many aspects these tumors differ from SE and other germ cell tumors. Initial reports suggested a postmeiotic origin of these tumors, but recent data counteract this suggestion remaining the origin of spermatocytic seminoma to be resolved ¹²⁻¹⁵.

INTRATUBULAR GERM CELL NEOPLASIA

In seminiferous tubules of the adult testis in the vicinity of invasive tumors large atypical cells may be found with a morphology reminiscent of SE. These cells, also known as carcinoma in situ, or intratubular germ cell neoplasia are lined along the tubular basement membrane in a niche created by Sertoli cells. The germ cell origin of intratubular germ cell neoplasia is undebatable and is supported by morphological, ultrastructural and immunohistochemical similarities between intratubular germ cell neoplasia and primitive germ cells ¹⁶⁻²¹.

The finding of intratubular germ cell neoplasia in high frequency adjacent to invasive tumors ^{18,21,22}, and the observed progression of intratubular germ cell neoplasia to invasive tumors ²³ is in support of a histogenetic relationship between intratubular germ cell neoplasia and testicular germ cell tumors. Actually it is believed that nearly all germ cell tumors of the adult testis with the exception of spermatocytic seminomas develop through a intratubular germ cell neoplasia stage ²⁴⁻²⁷.

The testicular parenchyma adjacent to germ cell tumors of the infantile testis most often is devoid of intratubular germ cell neoplasia ²⁸. Yet, in recent case reports intratubular germ cell neoplasia has been reported to be present in seminiferous tubules adjacent to infantile tumors ²⁹⁻³¹, suggesting that at least some of these tumors have a pathogenesis similar to testicular germ cell tumors of adolescents and adults ²⁶.

PATHOGENESIS OF TESTICULAR GERM CELL TUMORS

The susceptibility of developing testicular germ cell tumors seems to be determined by genetic background, but exogenous factors operative in early life or even before birth during the critical period of urogenital development probably are responsible for the actual incidence of testicular germ cell tumors ^{32,33}.

The phenotypic similarity of intratubular germ cell neoplasia to that of primordial germ cells before the 10th week of development ²⁰, and the observation that 5% of the testicular germ cell tumors are bilateral ²⁶, favors the hypothesis that initiation takes place during the critical period of urogenital development, before primordial germ cells reach the genital ridges ²⁴. Once intratubular germ cell neoplasia has been established invasive tumors will develop inevitably ^{24-26,34}.

Historically two theories exist on the pathogenesis of testicular germ cell tumors ³⁵. The theory proposed by Pierce and Abel ³⁶ assumes that SE and NS are not related to each other and have separate precursors with inherently different potential for development. In contrast, the model depicted by Ewing and Friedman ^{37,38} suggests a linear relationship between SE and NS, in which SE represents an intermediate stage between intratubular germ cell neoplasia and NS. Supportive for the latter model are age-specific incidence patterns of SE, combined tumors, and NS ⁵, HLA-studies ³⁹, ploidy-studies ⁵, similarities in chromosomal constitution between SE and NS ⁴⁰, tumors with histology intermediate between SE and NS ⁴¹, cell lines with SE as well as NS characteristics ⁴², and the finding of NS metastases after treatment of a pure SE ⁴³.

An early event in the tumorigenesis of testicular germ cell tumors is tetraploidization ⁴⁰, but the time, trigger and mechanism by which this occurs can only be speculated about ²⁴. Probably the tetraploid cell is genetically unstable which provides the initiated primordial germ cells the means to undergo progression with net loss of chromosomes ²⁴. As revealed by ploidy ⁵ and karyotype ⁴⁰ the chromosome number in SE is higher (hypertriploid) than in NS (hypotriploid) with a specific pattern of over- and underrepresentation of chromosomes for both tumors. The amplification of 12p sequences, in 80% of the testicular germ cell tumors as i(12p), suggests a crucial role for genes present on 12p in the pathogenesis of these tumors ⁴⁰. In the remaining i(12p) negative tumors chromosomal rearrangements involving 12p are frequently noticed ⁴⁴⁻⁴⁶. The formation of i(12p) is preceded by polyploidization as heterozygosity of the long arm of chromosome 12 is retained ⁴⁷.

Intratubular germ cell neoplasia adjacent to SE or NS is similar with respect to morphology, immunohistochemistry, and ploidy. However, at the chromosomal level the in situ component adjacent to SE and NS may diverge, and undergo a karyotype evolution that is in part similar to that of the invasive counterpart ⁴⁸. Based on this observation it has been hypothesized that intratubular germ cell neoplasia adjacent to SE and NS may have a distinct developmental potential that only becomes apparent upon invasion and engagement of tumor cells to microenvironmental factors outside the seminiferous tubules ^{24,49}.

In the majority of combined tumors, the SE and NS component have a common precursor that progresses to SE and NS (either directly or through an invasive SE stage). A minority of combined tumors are biclonal, and in these tumors SE and NS each have their own precursor ⁵⁰.

SPONTANEOUS DIFFERENTIATION IN TESTICULAR GERM CELL TUMORS

The factors controlling differentiation of germ cell tumors of the testis into the germ cell, embryonal, and extra-embryonal lineages are largely unknown²⁴. As these tumors can be considered as caricatures of normal tissue renewal and early embryogenesis⁵¹ it is likely that mechanisms involved in early embryonic development are conserved in testicular germ cell tumors⁵².

Similarities in ploidy⁵ and karyotype^{53,54}, between different histological subtypes of NS suggest that epigenetic factors may be involved in the control of testicular germ cell tumor differentiation. Of these factors genomic imprinting might offer an elegant explanation to the plethora of tissues present in these tumors. Analogous to results obtained in pronuclear-transfer experiments, in testicular germ cell tumors a paternal imprinting would favor extraembryonic differentiation, whereas maternal imprinting may stimulate differentiation into embryonal tissues^{49,55,56}.

During testicular development the imprinting status of the primordial germ cell changes from biparental (pre-erased stage) to paternal (post-erased stage)⁵⁷. The time of initiation has been hypothesized to be essential to the developmental repertoire of the tumor; the pluripotent nature of NS would require a biparental imprinting status (pre-erased stage) of the initiated primordial germ cell. On the other hand, differentiation along the germ cell lineage in SE would be favored by a paternal imprinting (post-erased stage). Loss of (certain parts) of chromosomes during progression of testicular germ cell tumors might mimic biparental imprinting, and thereby favor differentiation into the embryonal or extraembryonal lineage⁴⁹. Analogous to the derivation of pluripotent embryonic stem cells from murine primordial germ cells⁵⁸ it has been suggested that seminoma cells may be reprogrammed to pluripotency⁴⁹.

METASTATIC BEHAVIOR OF TESTICULAR GERM CELL TUMORS

The aggressiveness of testicular germ cell tumors is determined by tumor progression and the inherent aggressiveness of histological subtypes^{24,59,60}. Staging of testicular germ cell tumors is generally performed according to the staging classification proposed by Peckham: stage I tumor confined to the testis; stage II tumor with regional lymphatic metastases; stage III tumor with metastases above the diaphragm: mediastinal and supraclavicular lymph nodes; stage IV tumor with metastases to extra-lymphatic sites⁶¹. However, a distinction should be made between clinical and biological stage^{60,62}. Biological stage is the clinical stage at the time previously occult metastases have become clinically apparent, and thus this stage determines the success of locoregional therapy⁶².

The majority of testicular germ cell tumors does metastasize in a predictable pattern. The retroperitoneal lymph nodes are the first station encountered⁶¹. Lung metastases develop hematogenously, either directly or indirectly via abdominal, thoracic, and supraclavicular lymph nodes and the thoracic duct⁶¹. Parenchymatous metastases including brain and liver metastases, are nearly always preceded by or coincide with lung metastases^{60,63,64}.

The histological composition of metastases is a reflection of the primary tumor. Pure tumors, either SE or NS tend to metastasize as such. In combined tumors the metastatic competence of both components is nearly identical to that of their pure counterparts⁶⁰. In tumors with mixed histology, the components hardly ever differ from those in the primary

tumor. Yet, according to the model of metastatic selection ⁶⁵ there tends to be an overrepresentation of components with the highest propensity to metastatic spread ⁶⁰. The finding of a NS component after treatment of a pure SE may be explained by reprogramming to pluripotency ⁴⁹ or a sampling error in the initial orchidectomy specimen ⁶⁰.

Compatible with a relatively indolent metastatic behavior, more than one-half of the patients with SE are cured by orchidectomy alone (biological stage I), whereas a minority of patients presents with distant metastases (clinical stage III/IV) ^{60,66}. The clinical relevance of subtyping SE (classical, anaplastic and SE with syncytiotrophoblastic giant cells) is controversial ².

NS are highly aggressive, and only in 25-30% of the patients the tumor is confined to the testis (biological stage I). Over 50% of the patients with a NS have metastases beyond the regional lymph nodes at the time of diagnosis (biological stage III/IV) ⁶⁰. The higher aggressiveness of NS compared to SE is in agreement with the proposed progression model in which SE represents an intermediate stage between intratubular germ cell neoplasia and NS ^{5,40}.

It appears that the clinical behavior of NS is largely determined by the histological composition of the primary tumor ^{59,60}. Choriocarcinoma has a high metastatic ability, due to its tendency to early hematogenous spread ⁶⁰. Concordantly, tumors with a choriocarcinoma component behave clinically aggressive and tend to present with distant metastases ⁶⁷.

Likewise, (pure) embryonal carcinoma behaves clinically aggressive ⁶⁸⁻⁷⁰, and together with choriocarcinoma, embryonal carcinoma shows a tendency to overrepresentation in distant metastases from mixed testicular germ cell tumors ⁶⁰.

In contrast to embryonal carcinoma and choriocarcinoma, teratoma has a low metastatic potential ^{59,60}. In fact some authors suggest that the teratoma component of NS metastasizes rarely or not at all, and if it does it is believed that differentiation of metastatic embryonal carcinoma cells is responsible for the finding of teratoma in metastases ⁷¹.

Although data on metastatic potential of yolk sac tumor are rather scarce, it seems likely that in adolescents and adults these tumors have a relatively high propensity to metastatic spread, since brain metastases frequently contain pure yolk sac tumor ⁶⁰. Similarly, with the exception of pure yolk sac tumors in children less than one year of age, the yolk sac tumor component of infantile tumors may clinically behave aggressive ⁶⁻⁸.

FIRST-LINE THERAPY OF TESTICULAR GERM CELL TUMORS

Testicular germ cell tumors have become a model for curable cancer. Presently about 85% of all patients with testicular germ cell tumors are cured ⁷². The choice of therapy is dependent on the histology of primary tumor (SE versus NS), clinical stage, and anticipated biological stage. The latter may be extrapolated from clinical, pathological, biological and genetic parameters.

Seminomas

SE presenting with localized disease (clinical stage I) or low to moderate volume stage II disease (clinical stage IIa/b) are treated by orchidectomy and adjuvant radiotherapy to pelvic and retroperitoneal lymph nodes with survival rates approximating 100% ⁷³. Due to

the relatively low metastatic potential of SE a substantial proportion of patients with clinically localized disease is cured by orchidectomy alone. However, 15-20% of the patients require salvage therapy due to the clinical manifestation of (at the time of orchidectomy occult) metastases (biological stage > I)⁷³⁻⁷⁷. Relapses occur predominantly in the retroperitoneal lymph nodes, and in less than 10% beyond the diaphragm⁷³.

Several patho-clinical variables have been correlated to metastatic disease including tumor size, necrosis, histological subtype (classical versus anaplastic), lymphatic and vascular invasion^{77,78}, local tumor extension⁷⁶, and post-orchidectomy β human chorionic gonadotropin (HCG) level⁷⁹. However, based on these parameters high risk patients that should be offered adjuvant therapy after orchidectomy are difficult to identify⁸⁰.

Advanced SE (bulky stage II (IIc), stage III/IV) are treated by platinum-based chemotherapy, and cure rates up to 90% have been reported⁸¹⁻⁸⁴.

Nonseminomas

Two major treatment strategies are available for patients with clinical stage I NS: orchidectomy with nerve-sparing retroperitoneal lymphadenectomy, or orchidectomy with surveillance. 20-30% of the patients with clinical stage I NS actually have occult metastases (biological stage > I) and thus can not be cured by orchidectomy alone^{85,86}. To restrict treatment to orchidectomy alone, parameters are needed that predict the aggressiveness of the tumor, e.g., predict whether there are, at the time of orchidectomy, occult metastases. Several pathological, clinical, biological and genetic parameters are associated with disseminated disease, and a selection of these are summarized in Table 1.

Table 1. Parameters associated with disseminated disease in testicular nonseminomas.

Clinical parameters	preoperative elevated serum AFP and/or β HCG ⁸⁷ rate of decrease of serum AFP and/or β HCG after orchidectomy ^{87,88}
Pathological parameters	presence of embryonal carcinoma ^{68,69,88-94} absence of yolk sac tumor ^{68,69,93} absence of teratoma ^{68,69,88,91,94} vascular and/or lymphatic invasion ^{68,69,88,91,92,94} local tumor extension ⁶⁸
Biological parameters	proliferating cellular nuclear antigen (PCNA) score ⁹² MIB-1 (ki-67) score ⁷⁰ microvessel count ⁹³ p53 protein expression in embryonal carcinoma ⁹⁰
Genetic parameters	percentage of S-phase of the aneuploid population ^{89,91,94} presence of multiple aneuploid stem-lines ⁹⁵ presence of hypertetraploid stem-lines ⁷⁰ structural changes of chromosome 1 ⁹⁶ higher copy number of i(12p) ^{96,97}

AFP, α -foetoprotein; HCG, β human chorionic gonadotropin.

Among the different parameters, in clinical stage I NS, pathological parameters including the presence of embryonal carcinoma and vascular and/or lymphatic invasion were shown to be the most powerful. However, the accuracy of this prediction remains low and additional parameters are needed to decide which patients should be offered additional therapy after orchidectomy ⁸⁵.

Patients with small to moderate volume stage II disease (stage IIa/b) can be cured by orchidectomy followed by retroperitoneal lymph node dissection alone, or by orchidectomy followed by primary cisplatin-based chemotherapy. Both treatment strategies give excellent tumor control with survival rates of more than 95% ^{87,98}. However, to obtain these excellent results in each treatment group about 30% of the patients will need adjuvant therapy, either cisplatin-based chemotherapy or retroperitoneal lymph node dissection ⁹⁹.

Based on the probability of cure patients with advanced NS can be divided into two groups. 70-80% of the patients respond well to first-line chemotherapy with treatment failure in 10-15% of the patients. The anticipated disease-free survival of the remaining group of patients is about 50-70% ¹⁰⁰. The response to therapy may be extrapolated from a wide variety of prognostic factors ^{87,100,101}, including tumor histology ¹⁰², tumor bulk ¹⁰², site and extent of metastases ¹⁰²⁻¹⁰⁴, high serum levels of α -foetoprotein (AFP), β HCG, and lactate dehydrogenase ^{102,104}, high proliferation rate ¹⁰⁵, and abnormal karyotype ¹⁰⁶. Unlike a previous report ¹⁰⁷ the presence of multiple copies of i(12p) seems not to be associated with response to therapy ¹⁰⁶. Post-chemotherapy, the rate of tumor marker decline (AFP and β HCG) ¹⁰⁸, and site and extent of residual disease ^{103,109} were shown to be of prognostic value. Currently, among others these parameters are used to treat patients according to prognostic groups ^{87,100,101}.

Residual disease after chemotherapy in patients with advanced nonseminomas

Approximately 30% of the patients receiving chemotherapy are left with persistent, radiographically evident disease. Histopathological analysis of the resected specimens reveals fibrosis and/or necrosis, residual mature teratoma (RMT), or viable cancer, with either germ cell and/or non-germ cell elements ¹¹⁰⁻¹¹⁵.

The presence of RMT in resected specimen of patients treated for disseminated NS is probably due to a selective survival of cells capable of somatic differentiation ¹¹⁶ and is significantly associated with primary tumors containing a teratoma component ^{59,110}. Surgical resection of RMT is indicated as RMT is genetically highly abnormal ^{110,112} and may continue to grow (growing teratoma syndrome) due to the presence of proliferating atypical cells ^{117,118}. The development of non-germ cell elements in a substantial number of patients with RMT, and the association of RMT with late recurrences are additional arguments to resect this lesion ¹¹⁹. When resected, RMT has a relatively good prognosis with a 5-year relapse free survival of more than 85% ^{103,109,120}.

The growing teratoma syndrome and residual masses with immature teratoma and non-germ cell elements are related to relapse, but surgical resection of these tumors is potentially curative ¹¹¹⁻¹¹⁵.

The presence of viable cancer in resected specimens adversely affects prognosis, and cure rates will not exceed 80% ^{100,103,109,121}. Treatment failure is correlated to incompleteness of surgical resection ^{103,109,121}. However, it has been suggested that the adverse prognosis is rather due to intrinsic tumor characteristics than to the incompleteness of resection, as first relapses in the majority of patients occurred outside the resection area ^{103,109}.

DIFFERENTIATION INDUCTION AS PART OF ANTI-CANCER THERAPY IN TESTICULAR GERM CELL TUMORS

Cancer has been described as an impairment of terminal differentiation⁵¹ which is genetically defined by an imbalance in tumor suppressor genes and oncogenes¹²². For example, arrested maturation of primordial germ cells is thought to be one of the key features in the pathogenesis of testicular germ cell tumors, whereas progression of the initiated primordial germ cell to intratubular germ cell neoplasia, and subsequently invasive SE and/or NS is associated with marked changes in ploidy, karyotype^{5,40}, and expression of tumor suppressor genes and oncogenes^{49,123}.

The well documented spontaneous terminal differentiation of neuroblastoma IV-S into ganglioneuromas¹²⁴ lends support to the concept that induction of terminal differentiation by exogenous factors may be a way to overcome the maturation block in malignant tumors¹²⁵. Such a therapy would especially be promising in tumors that inherently demonstrate extensive differentiation and thus have retained genes that control normal proliferation and differentiation. In other words, differentiation induction as part of anti-cancer therapy assumes that cancer is a dynamic potentially reversible process in which growth, invasion, and development of metastases are highly regulated. According to this regulatory model the success of differentiation induction as part of anti-cancer therapy is dependent on the ability of a therapeutic agent to restore normal inter- and intracellular signal transduction pathways¹²⁶.

Substances that affect differentiation can be classified into polar-planar compounds (dimethylformamide, dimethyl sulfoxide), hormones, regulatory peptides and chemotherapeutic drugs¹²⁷. Among these, in chemoprevention and therapy of malignant tumors, retinoids (vitamin A, and its biologically active synthetic derivatives) are the most widely studied^{128,129}.

Retinoids

Retinoids exert their actions by binding to nuclear receptors, that belong to the supergene family of steroid hormone receptors¹³⁰. Cytoplasmic cellular retinol binding proteins (CRBPs) and cellular retinoic acid binding proteins (CRABPs) are supposed to control the intracellular concentration and metabolism of retinoids. Intracellular all-trans retinoic acid is derived from oxidation of retinol in the cytoplasm, or by simple diffusion of all-trans retinoic acid present in the circulation. 9-cis retinoic acid, 11-cis retinoic acid, and 13-cis retinoic acid are converted from all-trans retinoic acid by intracellular isomerases^{130,131}.

In the cell nucleus the biologically active metabolites all-trans retinoic acid and 9-cis retinoic acid bind to retinoic acid receptors (RAR α , β , γ) and retinoid X receptors (RXR α , β , γ)¹³⁰. The specificity and affinity for all-trans retinoic acid and 9-cis retinoic acid is receptor (subtype) dependent. Upon (hetero)dimerization of RARs and RXRs the complex acts as a transcription factor by binding to hormone responsive elements in the promoter region of target genes¹³⁰.

Many genes are directly or indirectly under control of retinoids, including those that encode for cytoskeletal proteins, integrins, extracellular matrix (ECM) proteins, and ECM degrading enzymes, suggesting that retinoids exert their action on (tumor) cells at least in part through modulation of (tumor) cell-matrix interactions¹³²⁻¹³⁶.

Nuclear retinoid receptors in tumorigenesis

Aberrant expression of nuclear retinoid receptors is thought to play an active role in the pathogenesis of some epithelial and non-epithelial tumors¹³⁷. For example, acute promyelocytic leukemia is characterized by a balanced translocation involving the long arms of chromosome 15 and 17. Due to this translocation the RAR α gene on chromosome 17 and the PML gene on chromosome 15 are fused¹³⁸⁻¹⁴⁰. Putatively, the activity of the PML/RAR- α fusion protein contributes to both the blockage of the leukemic promyelocyte in an early proliferative state of its differentiation, and to the sensitivity of leukemic promyelocytes to the differentiating activity of all-trans retinoic acid. Treatment of leukemic promyelocytes with all-trans retinoic acid might overcome the dominant negative role of the PML/RAR- α fusion protein thereby restoring gene pathways essential to granulocyte differentiation¹³⁸⁻¹⁴⁰.

The anti-cancer action of retinoids

The action of retinoids is not restricted to induction of differentiation, and other properties of retinoids may be involved in its anti-cancer action, including inhibition of proliferation without a concomitant effect on differentiation, induction of apoptosis, inhibition of angiogenesis, immunomodulation, and modulation of oncogene and suppressor gene expression^{129,141,142}.

It might be beneficial to combine retinoids with chemotherapeutic drugs as the overall response rate of differentiation induction alone in therapy of cancers is rather unsatisfactory, and due to the development of retinoid resistance, of brief duration^{129,143-145}. From a theoretical viewpoint resistance to retinoids may be genetically defined by mutations in the nuclear retinoid receptors. Indeed, in acute promyelocytic leukemia further mutations in the RAR- α gene have been identified in addition to the genetic abnormalities described above. It is believed however, that these additional mutations do not account for the development of retinoid resistance. In a clinical setting, alterations in the metabolism of all-trans retinoic acid are the major cause of resistance to retinoids^{143,145}.

Reduction of tumor load by cytotoxic drugs may facilitate differentiation and diminish the size of residual tumor. It is likely that some tumor cells are resistant to chemotherapy as malignant tumors are heterogeneous due to tumor progression^{146,147}. In the resistant tumor cell population reversion of the malignant phenotype would especially be warranted, as evidence is emerging that resistant cells compared to non-resistant cells are characterized by more aggressive malignant properties¹⁴⁸. Conversely, heterogeneity of malignant tumors may also have implications for the application of retinoids as individual tumor cells may differ in their response to retinoids¹⁴⁹.

Differentiation induction as part of anti-cancer therapy in testicular nonseminomas

Testicular NS are considered to represent the neoplastic counterpart of early embryos^{51,52}. Yet, in contrast to embryonic stem cells, embryonal carcinoma cells, considered to represent the pluripotent stem cell population of NS, are arrested in their maturation, resulting in continuous disorganized growth of not terminally differentiated embryonal and extraembryonal tissues⁵¹.

The level of differentiation in testicular NS is dependent on the percentage of embryonal carcinoma cells, the stage of maturation arrest of embryonal carcinoma cell

derived tumor cells, and the ability of tumor cells to overcome the maturation arrest and to (terminally) differentiate^{51,150}. Induction of terminal differentiation as part of anti-cancer therapy might force undifferentiated embryonal carcinoma cells and arrested not terminally differentiated cells, into terminally differentiated nonproliferative, noninvasive cells^{125,150}.

The feasibility of differentiation induction as a therapy in testicular germ cell tumors is supported by experimental data. In vitro, murine as well as human embryonal carcinoma cells are responsive to differentiation inducing agents like all-trans retinoic acid and 9-cis retinoic acid¹⁵¹⁻¹⁵⁶. Induction of differentiation in vitro not only leads to impairment of proliferation but also to decreased tumorigenicity upon injection of tumor cells into nude mice¹⁵⁷. The studies by Strickland and Sawey¹⁵⁵, Speers¹⁵⁸⁻¹⁶⁰, and McCue¹⁶¹ using murine teratocarcinomas (tumors composed of embryonal carcinoma and teratoma) as a model for the study of human NS lends support to the concept that retinoids may be effective in controlling growth of testicular germ cell tumors in vivo as well. Speers, using a combination of all-trans retinoic acid and dimethylacetamide cured 4 out of 18 mice with murine teratocarcinoma, with complete differentiation of embryonal carcinoma into mature teratoma¹⁵⁸. Transplants of retinoid-induced residual lesions were found to be histologically mature (cystic) teratomas. Some of these mature teratomas showed a slow growth¹⁵⁹, analogous to the growing teratomas after chemotherapy of testicular NS^{113,114}. Two transplants grew more rapidly, and gave rise to a chondrosarcoma and a mixed chondrosarcoma/glioma¹⁶⁰, and these tumors can be considered as the murine counterpart of non-germ cell malignancies developing in a RMT following chemotherapy for a testicular NS^{111,112,115}. Thus, although murine and human embryonal carcinoma cells are different in many aspects¹⁶², it seems that murine teratocarcinomas are applicable as a model for the study of retinoid-induced differentiation as part of anti-cancer therapy in NS.

In humans with advanced NS two Phase II trials have been published thus far. The first study, using 13-cis retinoic acid at a daily total dose of 100 mg/m² for 21 days, resulted in stable disease in 4 out of 15 patients for 5-7.5 months. In 1 patient the autopsy findings demonstrated large masses of mature teratoma with foci of viable cancer. No complete remissions were observed¹⁶³. In the second study, using all-trans retinoic acid at a daily total dose of 80 mg/m² for 7 weeks, no clinical responses were observed¹⁶⁴.

OUTLINE OF THE THESIS

In the past years attention has been focussed on the pathogenesis of testicular germ cell tumors. The relation of invasive tumors to intratubular germ cell neoplasia has been firmly established. Moreover, it has become apparent that the progression of intratubular germ cell neoplasia to invasive tumors is different for SE and NS. Data on metastatic spread as revealed by clinical presentation and reaction to therapy demonstrate a pronounced heterogeneity with respect to metastatic competence of tumor cells of different histological subtype. However, the properties of intratubular germ cell neoplasia, SE and NS necessary to invade and metastasize have not been extensively studied. One of the factors that plays a pivotal role in invasion and metastasis is the interaction of tumor cells with the ECM, and it is likely that this also holds true for testicular germ cell tumors. Data on the distribution of integrins and ECM proteins can be expected to be important for our understanding of the biology of testicular germ cell tumors. In a clinical setting differences of biological

parameters between tumors of one histological subtype may be predictive for the biology of the tumor and contribute to the choice of treatment.

The central issue in Chapter 2 is the integrin-mediated interaction of cells with the ECM. In Paragraph 2.1.1 ECM proteins and integrins are introduced briefly. By using testicular development as a model in Paragraph 2.1.2 a review is given on the relevance of cell-matrix interactions in determining cell morphology, behavior and function, whereas in Paragraph 2.1.3 the biology of malignant tumors is discussed with emphasis on the role of integrins in tumorigenesis and metastasis formation. The biological properties of testicular germ cell tumors make them a suitable model for the study of tumor progression and differentiation. In Chapter 2.2 the distribution of integrins and ECM proteins in normal testis, testis containing intratubular germ cell neoplasia, primary SE and metastases of SE is described. Differences in the expression of integrins of tumor cells in subsequent stages of the metastatic cascade may point to biologically relevant molecules in the process of invasion and metastasis. Results on the distribution of integrins and ECM proteins in primary NS are presented in Chapter 2.3. The results will be discussed in relation to differentiation and the biology of the histological subtypes. A comparison will be made with the normal non-neoplastic counterparts of the tissues present in NS.

A major challenge in the treatment of patients with testicular germ cell tumors is the cure of patients with tumors that are inherently resistant or have become resistant to chemotherapeutic drugs. Salvage therapies have been developed and are under investigation. At the worst still 20% of patients with advanced NS can not be cured. Potentially retinoids might play a role in better treatment results in these groups. Combination of chemotherapy and induction of (terminal) differentiation by means of retinoids might theoretically be fruitful as the mechanisms of action are quite different: tumor cell kill and in addition reversion of malignant phenotype of (chemotherapy resistant) tumor cells into terminally differentiated non-proliferating, noninvasive cells.

In Chapter 3 data are presented on the combination therapy of all-trans retinoic acid and cisplatin in the treatment of three murine teratocarcinomas, each with a different level of spontaneous somatic differentiation. Tumor size and percentage of differentiated tissues were used to evaluate the response.

In Chapter 4.1 the development and characterization of a cisplatin resistant subline (Tera-CP) of the human EC cell line NTera2/D1(Tera) is discussed. Since microenvironmental factors may have impact on the sensitivity of tumor cells to cytotoxic drugs¹⁶⁵ the sensitivity of Tera-CP to cisplatin was tested *in vivo* as well. Results from the application of combining cisplatin and 13-cis retinoic acid in the treatment of cisplatin sensitive- (Tera) and resistant (Tera-CP) human embryonal xenografts are given in Chapter 4.2. Two treatment strategies were used (cisplatin followed by 13-cis retinoic acid or 13-cis retinoic acid followed by cisplatin) as the response of tumor cells may depend on the sequence in which a differentiation inducer and chemotherapeutic drug are given¹⁶⁶. Tumor response was measured by tumor size and determination of the percentage of differentiated tissue. In Chapter 4.3 the *in vitro* expression of integrins in Tera as well as Tera-CP before and after application of all-trans retinoic acid is reported. Knowledge about molecules that mediate cell-cell and cell-matrix interactions in Tera and Tera-CP may be useful for future studies on the role of tumor cell-cell and cell-matrix interactions in differentiation and sensitivity to chemotherapeutic drugs in this model.

Finally, in Chapter 5 a summary is given of our studies. The results will be discussed and will be put into a broader context. Some perspectives to future studies will be briefly mentioned.

REFERENCES

1. Swerdlow A J: The epidemiology of testicular cancer. *Eur Urol* 1993, 23: 35-38
2. Ulbright T M: Germ cell neoplasms of the testis. *Am J Surg Pathol* 1993, 17: 1075-1091
3. Mostofi FK, Sobin LH. International histological classification of tumours (no. 16): histological typing of testis tumours. Geneva: WHO, 1977
4. Collins D H, Pugh R C B: The pathology of testicular tumors. *Br J Urol* 1964, 36 (suppl): 1-11
5. Oosterhuis J W, Castedo S M M, de Jong B, Cornelisse C J, Dam A, Sleijfer D T, Schraffordt Koops H: Ploidy of primary germ cell tumors of the testis. Pathogenetic and clinical relevance. *Lab Invest* 1989, 60: 14-21
6. Harms D, Jänig U: Germ cell tumors of childhood. Report of 170 cases including 59 pure and partial yolk-sac tumours. *Virchows Arch [Pathol Anat]* 1986, 409: 223-239
7. Dehner L P: Gonadal and extragonadal germ cell neoplasia of childhood. *Hum Pathol* 1983, 14: 493-511
8. Levy D A, Kay R, Elder J S: Neonatal testis tumors: A review of the prepubertal testis tumor registry. *J Urol* 1994, 151: 715-717
9. Visfeldt J, Jørgensen N, Müller J, Møller H, Skakkebak N E: Testicular germ cell tumours of childhood in Denmark, 1943- 1989: Incidence and evaluation of histology using immunohistochemical techniques. *J Pathol* 1994, 174: 39-47
10. Oosterhuis J W, Castedo S M, de Jong B: Cytogenetics, ploidy and differentiation of human testicular, ovarian and extragonadal germ cell tumours. *Cancer Surv* 1990, 9: 321-332
11. Hoffner L, Deka R, Chakravarti A, Surti U: Cytogenetics and origins of pediatric germ cell tumors. *Cancer Genet Cytogenet* 1994, 74: 54-58
12. Talerma A: Spermatocytic seminoma. Clinicopathological study of 22 cases. *Cancer* 1980, 45: 2169-2176
13. Dekker I, Rozeboom T, Delemarre J, Dam A, Oosterhuis J W: Placental-like alkaline phosphatase and DNA flow cytometry in spermatocytic seminoma. *Cancer* 1992, 69: 993-996
14. Cummings O W, Ulbright T M, Eble J N, Roth L M: Spermatocytic seminoma: An immunohistochemical study. *Hum Pathol* 1994, 25: 54-59
15. Eble J N: Spermatocytic seminoma. *Hum Pathol* 1994, 25: 1035-1042

16. Holstein A F, Schütte B, Becker H, Hartmann M: Morphology of normal and malignant germ cells. *Int J Androl* 1987, 10: 1-18
17. Gondos B: Ultrastructure of developing and malignant germ cells. *Eur Urol* 1993, 23: 68-75
18. Hustin J, Collette J, Franchimont P: Immunohistochemical demonstration of placental alkaline phosphatase in various states of testicular development and in germ cell tumours. *Int J Androl* 1987, 10: 29-35
19. Jørgensen N, Giwercman A, Müller J, Skakkebak N E: Immunohistochemical markers of carcinoma in situ of the testis also expressed in normal infantile germ cells. *Histopathology* 1993, 22: 373-378
20. Jørgensen N, Rajpert-De Meyts E, Græm N, Müller J, Giwercman A, Skakkebak N E: Expression of immunohistochemical markers for testicular carcinoma in situ by normal human fetal germ cells. *Lab Invest* 1995, 72: 223-231
21. Hustin J, Gillerot Y, Collette J, Franchimont P: Placental alkaline phosphatase in developing normal and abnormal gonads and in germ-cell tumours. *Virchows Arch A Pathol Anat Histopathol* 1990, 417: 67-72
22. Jacobsen G K, Henriksen O B, v der Maase H: Carcinoma in situ of testicular tissue adjacent to malignant germ-cell tumors: a study of 105 cases. *Cancer* 1981, 47: 2660-2662
23. Müller J, Skakkebak N E, Nielsen O H, Græm N: Cryptorchidism and testis cancer. Atypical infantile germ cells followed by carcinoma in situ and invasive carcinoma in adulthood. *Cancer* 1984, 54: 629-634
24. Oosterhuis J W, Looijenga L H J: The biology of human germ cell tumours: Retrospective speculations and new perspectives. *Eur Urol* 1993, 23: 245-250
25. Jørgensen N, Muller J, Giwercman A, Skakkebak N E: Clinical and biological significance of carcinoma in situ of the testis. *Cancer Surv* 1990, 9: 287-302
26. Dieckmann K P, Loy V: Testicular intraepithelial neoplasia: the precursor of testicular germ cell tumors. *Onkologie* 1993, 16: 61-68
27. Skakkebak N E, Berthelsen J G, Giwercman A, Müller J: Carcinoma in situ of the testis: possible origin from gonocytes and precursor of all types of germ cell tumours except spermatocytoma. *Int J Androl* 1987, 10: 19-27
28. Manivel J C, Simonton S, Wold L E, Dehner L P: Absence of intratubular germ cell neoplasia in testicular yolk sac tumors in children. A histochemical and immunohistochemical study. *Arch Pathol Lab Med* 1988, 112: 641-645
29. Min Hu L, Phillipson J, Barsky S H: Intratubular germ cell neoplasia in infantile yolk sac tumor. Verification by tandem repeat sequence in situ hybridization. *Diagn Mol Pathol* 1992, 1: 118-128
30. Stamp I M, Barlebo H, Rix M, Jacobsen G K: Intratubular germ cell neoplasia in an infantile testis with immature teratoma. *Histopathology* 1993, 22: 69-72

31. Renedo D E, Trainer T D: Intratubular germ cell neoplasia (ITGCN) with p53 and PCNA expression and adjacent mature teratoma in an infant testis: an immunohistochemical and morphologic study with a review of the literature. *Am J Surg Pathol* 1994, 18: 947-952
32. Møller H: Clues to the aetiology of testicular germ cell tumours from descriptive epidemiology. *Eur Urol* 1993, 23: 8-15
33. Rajpert-De Meyts E, Skakkebaek N E: The possible role of sex hormones in the development of testicular cancer. *Eur Urol* 1993, 23: 54-61
34. Giwercman A, von der Maase H, Skakkebaek N E: Epidemiological and clinical aspects of carcinoma in situ of the testis. *Eur Urol* 1993, 23: 104-114
35. Damjanov I: Is seminoma a relative or a precursor of embryonal carcinoma? *Lab Invest* 1989, 60: 1-3
36. Pierce G B, Abell M R: Embryonal carcinoma of the testis. *Pathol Annual* 1970, 5: 27-60
37. Ewing J: Teratoma testis and its derivatives. *Surg Gynecol Obstet* 1911, 12: 230
38. Friedman N B: The comparative morphogenesis of extragenital and gonadal teratoid tumors. *Cancer* 1951, 4: 265-276
39. Oliver R T D: HLA phenotype and clinicopathological behaviour of germ cell tumours: possible evidence for clonal evolution from seminomas to nonseminomas. *Int J Androl* 1987, 10: 85-93
40. de Jong B, Oosterhuis J W, Castedo S M, Vos A, te Meerman G J: Pathogenesis of adult testicular germ cell tumors. A cytogenetic model. *Cancer Genet Cytogenet* 1990, 48: 143-167
41. Damjanov I, Niejadlik D C, Rabuffo J V, Donadio J A: Cribriform and sclerosing seminoma devoid of lymphoid infiltrates. *Arch Pathol Lab Med* 1980, 104: 527-530
42. Damjanov I, Horvat B, Gibas Z: Retinoic acid-induced differentiation of the developmentally pluripotent human germ cell tumor-derived cell line, NCCIT. *Lab Invest* 1993, 68: 220-232
43. Oliver R T D: Clues from natural history and results of treatment supporting the monoclonal origin of germ cell tumours. *Cancer Surv* 1990, 9: 333-368
44. Suijkerbuijk R F, Sinke R J, Meloni A M, Parrington J M, Van Echten J, de Jong B, Oosterhuis J W, Sandberg A A, Geurts van Kessel A: Overrepresentation of chromosome 12p sequences and karyotypic evolution in i(12p)-negative testicular germ-cell tumors revealed by fluorescence in situ hybridization. *Cancer Genet Cytogenet* 1993, 70: 85-93
45. Suijkerbuijk R F, Looijenga L, de Jong B, Oosterhuis J W, Cassiman J J, Geurts van Kessel A: Verification of isochromosome 12p and identification of other chromosome 12 aberrations in gonadal and extragonadal human germ cell tumors by bicolor double fluorescence in situ hybridization. *Cancer Genet Cytogenet* 1992, 63: 8-16

46. Suijkerbuijk R F, Sinke R J, Olde Weghuis D E M, Roque L, Forus A, Stellink F, Siepman A, van de Kaa C, Soares J, Geurts van Kessel A: Amplification of chromosome subregion 12p11.2-p12.1 in a metastasis of an i(12p)-negative seminoma: relationship to tumor progression? *Cancer Genet Cytogenet* 1994, 78: 145-152
47. Geurts van Kessel A, van Drunen E, de Jong B, Oosterhuis J W, Langeveld A, Mulder M P: Chromosome 12q heterozygosity is retained in i(12p)-positive testicular germ cell tumor cells. *Cancer Genet Cytogenet* 1989, 40: 129-134
48. Looijenga L H J, Gillis A J M, Van Putten W L J, Oosterhuis J W: In situ numeric analysis of centromeric regions of chromosomes 1, 12, and 15 of seminomas, nonseminomatous germ cell tumors, and carcinoma in situ of human testis. *Lab Invest* 1993, 68: 211-219
49. Looijenga L H J. Pathobiology of germ cell tumors of the adult testis: views and news. Thesis, Erasmus Universiteit, Rotterdam 1994
50. Gillis A J M, Looijenga L H J, de Jong B, Oosterhuis J W: Clonality of combined testicular germ cell tumors of adults. *Lab Invest* 1994, 71: 874-878
51. Sell S, Pierce G B: Maturation arrest of stem cell differentiation is a common pathway for the cellular origin of teratocarcinomas and epithelial cancers. *Lab Invest* 1994, 70: 6-22.
52. Roach S, Cooper S, Bennett W, Pera M F: Cultured cell lines from human teratomas: Windows into tumour growth and differentiation and early human development. *Eur Urol* 1993, 23: 82-88
53. de Graaff W E, Oosterhuis J W, de Jong B, Van Echten-Arends J, Wiersema-Buist J, Schraffordt Koops H, Sleijfer D T: Cytogenetic analysis of the mature teratoma and the choriocarcinoma component of a testicular mixed nonseminomatous germ cell tumor. *Cancer Genet Cytogenet* 1992, 61: 67-73
54. de Graaff W E, de Jong B, Oosterhuis J W, Van Echten-Arends J, Wiersema-Buist J, Schraffordt Koops H, Sleijfer D T: Separate cytogenetic analysis of the mature and immature teratoma components of a metastatic testicular nonseminomatous germ cell tumor. *Cancer Genet Cytogenet* 1991, 57: 59-68
55. Hall J G: Genomic Imprinting: review and relevance to human diseases. *Am J Human Genet* 1990, 46: 857-873
56. Tycko B: Genomic imprinting: mechanisms and role in human pathology. *Am J Pathol* 1994, 144: 431-443
57. Rossant J: Immortal germ cells? The derivation of permanent pluripotent stem cell lines directly from mouse germ cells in vitro promises to provide a new source of stem cells for genetic manipulation of mammals. *Curr Biol* 1993, 3: 47-49
58. Matsui Y, Zsebo K, Hogan B L M: Derivation of pluripotential embryonic stem cells from murine primordial germ cells in culture. *Cell* 1992, 70: 841-847

59. de Graaff W E, Oosterhuis J W, van der Linden S, Homan van der Heide J N, Schraffordt Koops H, Sleijfer D Th: Residual mature teratoma after chemotherapy for nonseminomatous germ cell tumors of the testis occurs significantly less often in lung than in retroperitoneal lymph node metastasis. *J Urogen Pathol* 1991, 1: 75-81
60. Oosterhuis JW. The metastasis of human teratomas. In: Damjanov I, Knowles B, Solter D, eds. *The human teratomas*. Clifton New Jersey: Humana Press, 1983:137-171.
61. Peckham MJ. Investigation and staging: general aspects and staging classification. In: Peckham MJ, ed. *The management of testicular tumours*. London: Arnold, E., 1981:89-101.
62. Hellman S, Weichselbaum R R: Oligometastases. *J Clin Oncol* 1995, 13: 8-10
63. Raina V, Singh S P, Kamble N, Tanwar R, Rao K, Dawar R, Rath G K: Brain metastasis as the site of relapse in germ cell tumor of testis. *Cancer* 1993, 72: 2182-2185
64. Williams S D, Einhorn L H: Brain metastases in disseminated germinal neoplasms. *Cancer* 1979, 44: 1514-1516
65. Fidler I J: Tumor heterogeneity and the biology of cancer invasion and metastasis. *Cancer Res* 1978, 38: 2651-2660
66. Gilliland F D, Key C R: Male genital cancers. *Cancer* 1995, 75 (suppl): 295
67. Vugrin D, Cvitkovic E, Posner J, Hajdu S, Golbey R B: Neurological complications of malignant germ cell tumors of the testis. *Biology of brain metastases (I)*. *Cancer* 1979, 44: 2349-2353
68. Moul J W, McCarthy W F, Fernandez E B, Sesterhenn I A: Percentage of embryonal carcinoma and of vascular invasion predicts pathological stage in clinical stage I nonseminomatous testicular cancer. *Cancer Res* 1994, 54: 362-364
69. Sesterhenn I A, Weiss R B, Mostofi F K, Stablein D M, Rowland R G, Falkson G, Rivkind S E, Vogelzang N J: Prognosis and other clinical correlates of pathologic review in stage I and II testicular carcinoma: a report from the testicular cancer intergroup study. *J Clin Oncol* 1992, 10: 69-78
70. Albers P, Miller G A, Orazi A, Ulbright T M, Albers J, Donohue J P, Foster R S: Immunohistochemical assessment of tumor proliferation and volume of embryonal carcinoma identify patients with clinical stage A nonseminomatous testicular germ cell tumor at low risk for occult metastasis. *Cancer* 1995, 75: 844-850
71. Snyder R N: Completely mature pulmonary metastasis from testicular teratocarcinoma. Case report and review of the literature. *Cancer* 1969, 24: 810-819
72. Einhorn L H: Treatment of testicular cancer: a new and improved model. *J Clin Oncol* 1990, 8: 1777-1781
73. Horwich A, Dearnaley D P: Treatment of seminoma. *Semin Oncol* 1992, 19: 171-180
74. Duchesne G M, Horwich A, Dearnaley D P, Nicholls J, Jay G, Peckham M J, Hendry W F: Orchiectomy alone for stage I seminoma of the testis. *Cancer* 1990, 65: 1115-1118

75. Thomas G M, Sturgeon J F, Alison R, Jewett M, Goldberg S, Sugar L, Rideout D, Gospodarowicz M K, Duncan W: A study of post-orchidectomy surveillance in stage I testicular seminoma. *J Urol* 1989, 142: 313-316
76. von der Maase H, Specht L, Jacobsen G K, Jakobsen A, Madsen E L, Pedersen M, Rorth M, Schultz H: Surveillance following orchidectomy for stage I seminoma of the testis. *Eur J Cancer [A]* 1993, 29A: 1931-1934
77. Horwich A, Alsanjari N, A'Hern R, Nicholls J, Dearnaley D P, Fisher C: Surveillance following orchidectomy for stage I testicular seminoma. *Br J Cancer* 1992, 65: 775-778
78. Marks L B, Rutgers J L, Shipley W U, Walker T, Stratcher M S, Waltman A C, Geller S C: Testicular seminoma: clinical and pathological features that may predict para-aortic lymphnode metastases. *J Urol* 1990, 143: 524-527
79. Dosmann M A, Zagars G K: Postorchidectomy radiotherapy for stages I and II testicular seminoma. *Int J Radiat Oncol Biol Phys* 1993, 26: 381-390
80. Zagars G K: Stage I testicular seminoma following orchidectomy--To treat or not to treat. *Eur J Cancer [A]* 1993, 29A: 1923-1924
81. Motzer R J: Optimal treatment for advanced seminoma. *Cancer* 1993, 72: 3-4
82. Mencil P J, Motzer R J, Mazumdar M, Vlamis V, Bajorin D F, Bosl G J: Advanced seminoma: treatment results, survival, and prognostic factors in 142 patients. *Journal of Clinical Oncology* 1994, 12: 120-126
83. Fossá S D, Droz J P, Stoter G, Kaye S B, Vermeylen K, Sylvester R, EORTC GU Group : Cisplatin, vincristine and ifosfamide combination chemotherapy of metastatic seminoma: Results of EORTC trial 30874. *Br J Cancer* 1995, 71: 619-624
84. Fossá S D, Droz J P, Stoter G, Kaye S B, Vermeylen K, Sylvester R: Cisplatin, vincristine and ifosfamide combination chemotherapy of metastatic seminoma: results of EORTC trial 30874. EORTC GU Group. *Br J Cancer* 1995, 71: 619-624
85. Jewett M A S: Testis cancer. *J Urol* 1994, 152: 1150-1151
86. Droz J P, Van Oosterom A T: Treatment options in clinical stage I non-seminomatous germ cell tumours of the testis: A wager on the future? A review. *Eur J Cancer [A]* 1993, 29A: 1038-1044
87. Hesketh P J, Krane R J: Prognostic assessment in nonseminomatous testicular cancer: implications for therapy. *J Urol* 1990, 144: 1-9
88. Gels M E, Hoekstra H J, Sleijfer D Th, Marrink J, de Bruijn H W A, Molenaar W M, Freling N J M, Droste J H J, Schraffordt Koops H: Detection of recurrence in patients with clinical stage I nonseminomatous testicular germ cell tumors and consequences for further follow-up: A single-center 10-year experience. *J Clin Oncol* 1995, 13: 1188-1194
89. Moul J W, Foley J P, Hitchcock C L, McCarthy W F, Sesterhenn I A, Becker R L, Griffin J L: Flow cytometric and quantitative histological parameters to predict occult disease in clinical stage I nonseminomatous testicular germ cell tumors. *J Urol* 1993, 150: 879-883

90. Lewis D J, Sesterhenn I A, McCarthy W F, Moul J W: Immunohistochemical expression of P53 tumor suppressor gene protein in adult germ cell testis tumors: clinical correlation in stage I disease. *J Urol* 1994, 152: 418-423
91. De Riese W T, Albers P, Walker E B, Ulbright T M, Crabtree W N, Reister T, Foster R S, Donohue J P: Predictive parameters of biologic behavior of early stage nonseminomatous testicular germ cell tumors. *Cancer* 1994, 74: 1335-1341
92. Fernandez E B, Sesterhenn I A, McCarthy W F, Mostofi F K, Moul J W: Proliferating cell nuclear antigen expression to predict occult disease in clinical stage I nonseminomatous testicular germ cell tumors. *J Urol* 1994, 152: 1133-1138
93. Olivarez D, Ulbright T, DeRiese W, Foster R, Reister T, Einhorn L, Sledge G: Neovascularization in clinical stage A testicular germ cell tumor: prediction of metastatic disease. *Cancer Res* 1994, 54: 2800-2802
94. De Riese W T W, De Riese C, Ulbright T M, Walker E B, Messemer J, Jones J A, Reister T, Albers P, Allhoff E P, Foster R S, Donohue J P: Flow-cytometric and quantitative histologic parameters as prognostic indicators for occult retroperitoneal disease in clinical-stage-I non-seminomatous testicular germ-cell tumors. *Int J Cancer* 1994, 57: 628-633
95. de Graaff W E, Sleijfer D Th, de Jong B, Dam A, Schraffordt Koops H, Oosterhuis J W: Significance of aneuploid stemlines in testicular nonseminomatous germ cell tumors. *Cancer* 1993, 72: 1300-1304
96. Delozier-Blanchet C D, Walt H, Engel E, Vuagnat P: Cytogenetic studies of human testicular germ cell tumors. *Int J Androl* 1987, 10: 69-77
97. Peltomäki P, Halme A, De la Chapelle A: Human testicular cancer. Changes in autosomal dosage. *Cancer Genet Cytogenet* 1990, 48: 1-12
98. Horwich A, Norman A, Fisher C, Hendry W F, Nicholls J, Dearnaley D P: Primary chemotherapy for stage II nonseminomatous germ cell tumors of the testis. *J Urol* 1994, 151: 72-77
99. Donohue J P, Thornhill J A, Foster R S, Bihle R, Rowland R G, Einhorn L H: The role of retroperitoneal lymphadenectomy in clinical stage B testis cancer: the Indiana University experience. *J Urol* 1995, 153: 85-89
100. Mead G M: Identification and management of poor prognosis germ cell tumours-a need for consensus. *Eur J Cancer* 1993, 29A: 2217-2218
101. Droz J P, Kramar A, Rey A: Prognostic factors in metastatic disease. *Semin Oncol* 1992, 19: 181-189
102. Mead G M, Stenning S P, Parkinson M C, Horwich A, Fosså S D, Wilkinson P M, Kaye S B, Newlands E S, Cook P A: The second Medical Research Council study of prognostic factors in nonseminomatous germ cell tumors. *J Clin Oncol* 1992, 10: 85-94
103. Steyerberg E W, Keizer H J, Zwartendijk J, Van Rijk G L, Van Groeningen C J, Habbema J D F, Stoter G: Prognosis after resection of residual masses following chemotherapy for metastatic nonseminomatous testicular cancer: a multivariate analysis. *Br J Cancer* 1993, 68: 195-200

104. Bajorin D, Katz A, Chan E, Geller N, Vogelzang N, Bosl G J: Comparison of criteria for assigning germ cell tumor patients to "good risk" and "poor risk" studies. *J Clin Oncol* 1988, 6: 786-792
105. Sledge G W, Jr., Eble J N, Roth B J, Wuhrman B P, Fineberg N, Einhorn L H: Relation of proliferative activity to survival in patients with advanced germ cell cancer. *Cancer Res* 1988, 48: 3864-3868
106. Bosl G J, Ilson D H, Rodriguez E, Motzer R J, Reuter V E, Chaganti R S K: Clinical relevance of the i(12p) marker chromosome in germ cell tumors. *J Natl Cancer Inst* 1994, 86: 349-355
107. Bosl G J, Dmitrovsky E, Reuter V E, Samaniego F, Rodriguez E, Geller N L, Chaganti R S: Isochromosome of the short arm of chromosome 12: clinically useful markers for male germ cell tumors. *J Natl Cancer Inst* 1989, 81: 1874-1878
108. Toner G C, Geller N L, Tan C, Nisselbaum J, Bosl G J: Serum tumor marker half-life during chemotherapy allows early prediction of complete response and survival in nonseminomatous germ cell tumors. *Cancer Res* 1990, 50: 5904-5910
109. Jansen R L H, Sylvester R, Sleijfer D Th, Ten Bokkel Huinink W W, Kaye S B, Jones W G, Keizer J, Van Oosterom A T, Meyer S, Vendrik C P J, De Pauw M, Stoter G: Long-term follow-up on non-seminomatous testicular cancer patients with mature teratoma or carcinoma at postchemotherapy surgery. *Eur J Cancer* 1991, 27: 695-698
110. Steyerberg E W, Keizer H J, Stoter G, Habbema J D F: Predictors of residual mass histology following chemotherapy for metastatic non-seminomatous testicular cancer: a quantitative overview of 996 resections. *Eur J Cancer Part A* 1994, 30A: 1231-1239
111. Little J S, Jr., Foster R S, Ulbright T M, Donohue J P: Unusual neoplasms detected in testis cancer patients undergoing post-chemotherapy retroperitoneal lymphadenectomy. *J Urol* 1994, 152: 1144-1149
112. Molenaar W M, Oosterhuis J W, Meiring A, Sleijfer D Th, Schraffordt Koops H, Cornelisse C J: Histology and DNA contents of a secondary malignancy arising in a mature residual lesion six years after chemotherapy for a disseminated nonseminomatous germ cell tumor. *Cancer* 1986, 58: 264-268
113. Logothetis C J, Samuels M L, Trindade A, Johnson D E: The growing teratoma syndrome. *Cancer* 1982, 50: 1629-1635
114. Loehrer P J, Hui S, Clark S, Seal M, Einhorn L H, Williams S D, Ulbright T, Mandelbaum I, Rowland R, Donohue J P: Teratoma following cisplatin-based combination chemotherapy for nonseminomatous germ cell tumors: a clinicopathological correlation. *J Urol* 1986, 135: 1183-1189
115. Ulbright T M, Loehrer P J, Roth L M, Einhorn L H, Williams S D, Clark S A: The development of non-germ cell malignancies within germ cell tumors. A clinicopathologic study of 11 cases. *Cancer* 1984, 54: 1824-1833
116. Oosterhuis JW, Andrews PW, de Jong B. Mechanisms of therapy-related differentiation in testicular germ cell tumors. In: McBrien DCH, Slater TF, eds. *Biochemical mechanisms of platinum antitumour drugs*. Oxford: IRL Press, 1986: 65-90

117. Sella A, Naggar A E, Ro J Y, Dexeus F H, Amato R J, Lee J S, Finn L, Logothesis C J: Evidence of malignant features in histologically mature teratoma. *J Urol* 1991, 146: 1025-1028
118. Davey D D, Ulbright T M, Loehrer P J, Einhorn L H, Donohue J P, Williams S D: The significance of atypia within teratomatous metastases after chemotherapy for malignant germ cell tumors. *Cancer* 1987, 59: 533-539
119. Bajorin D F, Herr H, Motzer R J, Bosl G J: Current perspectives on the role of adjunctive surgery in combined modality treatment for patients with germ cell tumors. *Semin Oncol* 1992, 19: 148-158
120. Mead G M, Stenning S P, Parkinson M C, Horwich A, Fossá S D, Wilkinson P M, Kaye S B, Newlands E S, Cook P A: The Second Medical Research Council study of prognostic factors in nonseminomatous germ cell tumors. Medical Research Council Testicular Tumour Working Party. *J Clin Oncol* 1992, 10: 85-94
121. Fox E P, Weathers T D, Williams S D, Loehrer P J, Ulbright T M, Donohue J P, Einhorn L H: Outcome analysis for patients with persistent nonteratomatous germ cell tumor in postchemotherapy retroperitoneal lymph node dissections. *J Clin Oncol* 1993, 11: 1294-1299
122. Bishop J M: Molecular themes in oncogenesis. *Cell* 1991, 64: 235-248
123. Strohmeier T G, Slamon D J: Proto-oncogenes and tumor suppressor genes in human urological malignancies. *J Urol* 1994, 151: 1479-1497
124. Haas D, Ablin A R, Miller C, Zoger S, Matthay K K: Complete pathologic maturation and regression of stage IVS neuroblastoma without treatment. *Cancer* 1988, 62: 818-825
125. Pierce G B, Speers W C: Tumors as caricatures of the process of tissue renewal: prospects for therapy by directing differentiation. *Cancer Res* 1988, 48: 1996-2004
126. Schipper H, Goh C R, Wang T L: Shifting the cancer paradigm: must we kill to cure? *J Clin Oncol* 1995, 13: 801
127. Freshney R I: Induction of differentiation in neoplastic cells. *Anticancer Res* 1985, 5: 111-130
128. Lippman S M, Benner S E, Ki Hong W: Cancer chemoprevention. *J Clin Oncol* 1994, 12: 851-873
129. Smith M A, Parkinson D R, Cheson B D, Friedman M A: Retinoids in cancer therapy. *J Clin Oncol* 1992, 10: 839-864
130. Giguère V: Retinoic acid receptors and cellular retinoid binding proteins: Complex interplay in retinoid signaling. *Endocrine Rev* 1994, 15: 61-79
131. Ross A C: Cellular metabolism and activation of retinoids: roles of cellular retinoid-binding proteins. *FASEB J* 1993, 7: 317-327

132. Leoncini L, Pacenti L, Rusciano D, Burrioni D, Garbisa S, Cintonino M, Terrana B: Correlation between differentiation and lung colonization by retinoic acid-treated F9 cells as revealed by the expression pattern of extracellular matrix and cell surface antigens. *Am J Pathol* 1988, 130: 505-514
133. Rusciano D, Lorenzoni P, Burger M M: The role of both specific cellular adhesion and growth promotion in liver colonization by F9 embryonal carcinoma cells. *Int J Cancer* 1991, 48: 450-456
134. Ross S A, Ahrens R A, De Luca L M: Retinoic acid enhances adhesiveness, laminin and integrin β 1 synthesis, and retinoic acid receptor expression in F9 teratocarcinoma cells. *J Cell Physiol* 1994, 159: 263-273
135. Gaetano C, Melchiori A, Albini A, Benelli R, Falcioni R, Modesti A, Modica A, Scarpa S, Sacchi A: Retinoic acid negatively regulates β 4 integrin expression and suppresses the malignant phenotype in a Lewis lung carcinoma cell line. *Clin Exp Metastasis* 1994, 12: 63-72
136. Helige C, Smolle J, Zellnig G, Hartmann E, Fink-Puches R, Kerl H, Tritthart H A: Inhibition of K1735-M2 melanoma cell invasion in vitro by retinoic acid. *Clin Exp Metastasis* 1993, 11: 409-418
137. Love J M, Gudas L J: Vitamin A, differentiation and cancer. *Curr Opin Cell Biol* 1994, 6: 825-831
138. Trayner I D, Farzaneh F: Retinoid receptors and acute promyelocytic leukaemia. *Eur J Cancer [A]* 1993, 29A: 2046-2054
139. Pemrick S M, Lucas D A, Grippo J F: The retinoid receptors. *Leukemia* 1994, 8 Suppl. 3: S1-S10
140. Warrell R P, Jr., de The H, Wang Z Y, Degos L: Acute promyelocytic leukemia. *N Engl J Med* 1993, 329: 177-189
141. Bollag W, Majewski S, Jablonska S: Cancer combination chemotherapy with retinoids: Experimental rationale. *Leukemia* 1994, 8: 1453-1457
142. Bollag W: Experimental basis of cancer combination chemotherapy with retinoids, cytokines, 1,25-dihydroxyvitamin D₃, and analogs. *J Cell Biochem* 1994, 56: 427-435
143. Warrell R P, Jr.: Retinoid resistance in acute promyelocytic leukemia: New mechanisms, strategies, and implications. *Blood* 1993, 82: 1949-1953
144. Guchelaar H J, Uges D R, de Vries E G, Oosterhuis J W, Mulder N H: Combination therapy with cisplatin: modulation of activity and tumour sensitivity. *Clin Oncol* 1992, 4: 388-393
145. Raymond P, Warrell R P, Jr.: Retinoid resistance in acute promyelocytic leukemia: new mechanisms, strategies, and implications. *Blood* 1993, 82: 1949-1953
146. Heppner G H: Tumor heterogeneity. *Cancer Res* 1984, 44: 2259-2265
147. Nicolson G L: Tumor cell instability, diversification, and progression to the metastatic phenotype: from oncogene to oncofetal expression. *Cancer Res* 1987, 47: 1473-1487

148. Kerbel R S, Kobayashi H, Graham C H: Intrinsic or acquired drug resistance and metastasis: Are they linked phenotypes. *J Cell Biochem* 1994, 56: 37-47
149. Lotan R: Effects of vitamin A and its analogs (retinoids) on normal and neoplastic cells. *Biochim Biophys Acta* 1980, 605: 33-91
150. Reiss M, Gamba-Vitalo C, Sartorelli A C: Induction of tumor cell differentiation as a therapeutic approach: preclinical models for hematopoietic and solid neoplasms. *Cancer Treat Rep* 1986, 70: 201-218
151. Andrews P W: Retinoic acid induces neuronal differentiation of a cloned human embryonal carcinoma cell line in vitro. *Dev Biol* 1984, 103: 285-293
152. Andrews P W, Gonczol E, Plotkin S A, Dignazio M, Oosterhuis J W: Differentiation of TERA-2 human embryonal carcinoma cells into neurons and HCMV permissive cells. Induction by agents other than retinoic acid. *Differentiation* 1986, 31: 119-126
153. Kurie J M, Buck J, Eppinger T M, Moy D, Dmitrovsky E: 9-cis And all-trans retinoic acid induce a similar phenotype in human teratocarcinoma cells. *Differentiation* 1993, 54: 123-129
154. Damjanov I, Horvat B, Gibas Z: Retinoic acid-induced differentiation of the developmentally pluripotent human germ cell tumor-derived cell line, NCCIT. *Lab Invest* 1993, 68: 220-232
155. Strickland S, Sawey M J: Studies on the effect of retinoids on the differentiation of teratocarcinoma stem cells in vitro and in vivo. *Dev Biol* 1980, 78: 76-85
156. Speers W C, Birdwell C R, Dixon F J: Chemically induced bidirectional differentiation of embryonal carcinoma cells in vitro. *Am J Pathol* 1979, 97: 563-584
157. Dmitrovsky E, Moy D, Miller W H, Jr., Li A, Masui H: Retinoic acid causes a decline in TGF-alpha expression, cloning efficiency, and tumorigenicity in a human embryonal cancer cell line. *Oncogene Res* 1990, 5: 233-239
158. Speers W C: Conversion of malignant murine embryonal carcinomas to benign teratomas by chemical induction of differentiation in vivo. *Cancer Res* 1982, 42: 1843-1849
159. Speers W C, Altmann M: Chemically induced differentiation of murine embryonal carcinoma in vivo: transplantation of differentiated tumors. *Cancer Res* 1984, 44: 2129-2135
160. Speers W C, Altmann M: Malignant neoplasms of differentiated cells occurring after retinoic acid treatment of murine embryonal carcinomas in vivo. *Cancer Res* 1984, 44: 2136-2143
161. McCue P A, Thomas R S, Schroeder D, Gubler M L, Shermann M I: Effects of dietary retinoids upon growth and differentiation of tumors derived from several murine embryonal carcinoma cell lines. *Cancer Res* 1988, 48: 3772-3779
162. Pera M F, Roach S, Ellis C: Comparative biology of mouse and human embryonal carcinoma. *Cancer Surv* 1990, 9: 243-262
163. Gold E J, Bosl G J, Itri L M: Phase II trial of 13-cis-retinoic acid in patients with advanced nonseminomatous germ cell tumors. *Cancer Treat Rep* 1984, 68: 1287-1288

164. Moasser M M, Motzer R J, Khoo K -S, Lyn P, Murphy B A, Bosl G J, Dmitrovsky E: All-trans retinoic acid for treating germ cell tumors. In vitro activity and results of a phase II trial. *Cancer* 1995, 76: 680-686
165. Teicher B A, Herman T S, Holden S A, Wang Y, Pfeffer M R, Crawford J W, Frei E: Tumor resistance to alkylating agents conferred by mechanisms operative only in vivo. *Science* 1990, 247: 1457-1461
166. Iwakawa M, Tofilon P J, Arundel C, Milas L: Combination of N-methylformamide with cis-diamminedichlorocisplatinum(II) in murine mammary carcinoma: importance of timing. *Cancer Res* 1989, 49: 1640-1643

Chapter 2.1

**MORPHOLOGY, BEHAVIOR, AND FUNCTION OF CELLS
ARE REGULATED BY INTEGRIN-MEDIATED
INTERACTIONS WITH THE EXTRACELLULAR MATRIX**

INTRODUCTION

The role of the extracellular matrix (ECM) in determining cell morphology, behavior, and function is increasingly acknowledged. It has become evident that the ECM not only serves as a mechanical scaffold in which cells reside. The interaction of cells with the ECM has also dynamic aspects. Cells may synthesize, secrete and deposit ECM proteins and contribute to the organization of the ECM by facilitating assembly of ECM proteins. On the other hand ECM proteins themselves may modulate cell function by interacting with integrin and nonintegrin receptors on the cell surface, or with cytokines.

In this chapter we discuss some aspects of the integrin mediated interaction of cells with the ECM by means of focussing on the role of ECM proteins in testicular development and homeostasis, and the role of integrins in biology of malignant tumors.

The extracellular matrix

ECM proteins can be divided into four classes of macromolecules: collagens, elastin, proteoglycans, structural glycoproteins¹. These molecules are organized into meshworks that constitute basement membranes (BMs) and connective tissue. The BM is a specialized structure that demarcates epithelia, endothelial cells, muscle cells, lipocytes and Schwann's cells from the connective tissue². Ultrastructurally, the basement membrane can be divided into three layers: a central lamina densa, flanked by a lamina lucida, and a variably present lamina fibroreticularis at the interface of the lamina densa and the connective tissue. The lamina densa consists of a meshwork of collagen type IV which is covered by other components and into which laminin is interwoven. The lamina fibroreticularis anchors cells resting on the BM to the connective tissue. Finally, the lamina lucida is the area in which cells contact the BM, either by specific integrin mediated interactions or by nonspecific interactions that include interactions of BM components with the cell surface².

Integrins

Integrins constitute a family of cell surface receptors that mediate cell-cell as well as cell-matrix interactions. Integrin-mediated adhesive interactions are essential to numerous physiological and pathological processes including placentation, embryonic development, wound healing, leucocyte homing and activation, and biological behavior of malignant tumors.

Integrins are heterodimeric proteins composed of related noncovalently linked α and β chains. Structurally, the integrins are composed of a large extracellular domain, two transmembrane segments, and two short C-terminal cytoplasmic tails, all formed by both subunits. The extracellular domain functions as the ligand binding site and both α and β subunits contribute to ligand binding³. The β subunit carboxyl terminal cytoplasmic domain is linked to the cytoskeleton via a chain of linking proteins (α -actinin, talin, etc)^{4,5}. The cytoplasmic domain of the $\beta 4$ integrin subunit, however, is localized in hemidesmosomes and is associated with intermediate filaments rather than with the actin containing cytoskeleton^{5,6}.

Initially, integrins were divided into three subfamilies: very late activation antigens (VLA) or $\beta 1$ integrins, leucam or $\beta 2$ integrins, and cytoadhesins or $\beta 3$ integrins. Due to the discovery of many new α and β subunits, integrins are currently divided into at least eight

Table 1 The Integrin family.

Receptor CD	Other names	Mr	Ligands	Main cellular distribution	
I Very Late Activations antigens or $\beta 1$-integrins					
$\alpha 1\beta 1$	CD49a/CD29	VLA-1	210,130	Coll(I,IV), Ln	F,M,BM,activated T and B-ly, Mus
$\alpha 2\beta 1$	CD49b/CD29	VLA-2	170,130	Coll(I-III,IV)Ln	Pl,F,EN,Ep,activated T
$\alpha 3\beta 1$	CD49c/CD29	VLA-3	130/25,130	Coll(I),Ln,Fn,Epil	Ep,F,BM,B-ly
$\alpha 4\beta 1$	CD49d/CD29	VLA-4,LPAM2	150,130	Fn,VCAM-1,ICAM-2	M,Eo,Ly,F,NC,NK,Th
$\alpha 5\beta 1$	CD49e/CD29	VLA-5	135/25,130	Fn, Inv	Th,T-Ly,F,Ep,EN,Pl,PMN,M, Mus
$\alpha 6\beta 1$	CD49f/CD29	VLA-6	120/30,130	Ln, Inv	Pl,T-ly,Ep,Th,M
$\alpha 7\beta 1$	--/CD29	VLA-7	100,130	Ln	Mus
$\alpha 8\beta 1$	--/CD29	VLA-8	160	?	?
$\alpha V\beta 1$	CD51/CD29	altFnR	125/24,130	Fn	NC,F
II LeuCAM or $\beta 2$-integrins					
$\alpha L\beta 2$	CD11a/CD18	LFA-1	180,95	ICAM-1(CD54), ICAM-2, ICAM-3	All leukocytes
$\alpha M\beta 2$	CD11b/CD18	Mac-1,CR3	170,95	ICAM-1, iC3b, Factor X	PMN,M,Ep,NK
$\alpha X\beta 2$	CD11c/CD18	p150,95,CR4	150,95	iC3b, Fb, Tsp	activated B and T-Ly, PMN,M,Eo,NK
III Cytoadhesins or $\beta 3$-integrins					
$\alpha II\beta 3$	CD41/CD61	gpIIb-IIIa	123/23, 105	Fb, Fn, vWF, Vn, Tsp	Pl,EN,MK
$\alpha V\beta 3$	CD51/CD61	VnR	125/24, 105	Fb, Fn, vWF, Vn, Tsp, Coll, Ost	Activated B-Ly,M,EN,Pl
IV Other integrins					
$\alpha 6\beta 4$	CD49f/CD104	Tsp180	120-130, 210	Ln	Ep
$\alpha V\beta 5$	CD51/-	$\alpha v\beta 5$, $\alpha v\beta x$, alt VNR	125/24, 100	Fn,Vn	M,Ep,F,
$\alpha V\beta 6$	CD51/-	-	125/24, 106	Fn	Ep
$\alpha MLA\beta 7$	CD103/CD107	HML-1 ,Bly7, M290/EL, βp	175, 105	?	Ly-subsets, intra-epithelial Ly
$\alpha 4\beta p/7$	CD49d/CD107	LPAM-1	120,-	Fn,VCAM-1,MAdCAM	T-Ly-subsets
$\alpha V\beta 8$	CD51/-	-	125/24, 95	?	?

CD, cluster of differentiation; Coll, collagen; Epil, Epiligrin; Fb, fibrinogen; Fn, fibronectin; HML, Human Mucosal Lymphocyte Antigen; ICAM, intercellular adhesion molecule; Inv, invasin; LFA, lymphocyte function antigen; Ln, laminin; LPAM, lymphocyte Peyer's patch specific adhesion molecule; MLA, mucosal lymphocyte antigen; MAdCAM, Mucosal Addressin Cell Adhesion Molecule; Ost, osteopontin; Tsp, trombospondin; VCAM, vascular cell adhesion molecule; Vn, vitronectin; VNR, vitronectin receptor; vWF, von Willebrand's factor.

Distribution: BM, basement membrane associated; EN, endothelial cells; Eo, eosinophils; Ep, epithelial cells; F, fibroblasts; Ly, lymphocytes; M, monocytes/macrophages; MK, megakaryocytes; Mus, muscle; NC, neural crest cells, melanocytes; NK, natural killer cells; PL, platelets; PMN, polymorphonuclear cell (neutrophil); Th, thymocytes.

subfamilies, each defined by a common β subunit (Table 1). Both subunits are promiscuous in their behavior. For example, the $\beta 1$ integrin subunit associates with at least 10 different α integrin subunits, whereas the αv integrin subunit not only associates with the $\beta 1$ integrin subunit but also with $\beta 3$, $\beta 5$, $\beta 6$, and $\beta 8$ integrin subunits³. Alternative splicing of integrin cytoplasmic domains⁷, redundancies in integrin ligand binding preferences⁸, and the existence of multiple affinity states for many integrins⁹ adds additional complexity to the integrin family of cell adhesion molecules.

The conformation-dependent recognition site for several of the integrins is the amino-acid sequence arginine-glycine-aspartic acid (RGD) present in many, but not all, ECM proteins. Other integrins recognize different sequences or bind to ligands other than ECM proteins, including bacterial and viral proteins, plasma proteins, and cellular membrane molecules involved in cell-cell interactions^{8,10,11}. The ligand binding specificity is dependent on the cellular microenvironment¹².

The modulation of integrin affinity and specificity by signals from inside the cell is known as inside-out signalling, and this type of signalling determines the adhesive properties of cells. On the other hand, upon ligand binding and clustering, integrins may transduce signals into the cell either by reorganization of the integrin associated cytoskeletal network or by activation of intracellular signal transduction pathways (cytoplasmic alkalization, raised calcium levels, tyrosine phosphorylation and increased inositol turnover) (outside-in signalling)^{3,5,9,13-17}. Both ways of signal transduction are mediated by means of conformational changes⁵, and act in concert with signals transduced by other cell surface molecules, including tyrosine kinase-linked growth factor receptors, G protein-coupled receptors, and cytokines and immune response receptors^{3,9,13,15-17}.

THE TESTICULAR MICROENVIRONMENT: THE EXTRACELLULAR MATRIX AND INTEGRINS IN THE DEVELOPING AND MATURE TESTIS

Primordial germ cells

The morphogenesis of the embryonic and fetal male gonad remains controversial¹⁸. However, the role of primordial germ cells as precursors of gonocytes and spermatogenic cells is undebatable. In the mouse, primordial germ cell can be found by the end of gastrulation at the eight day of development in the extraembryonic mesoderm, posterior to the primitive streak, and deep to the allantoic diverticulum¹⁹. In the next four days primordial germ cells home to the genital ridges next to the mesonephric kidney. The homing stage of primordial germ cells can be divided into a nonmigratory and migratory stage²⁰. By a translocation mechanism primordial germ cells reach the epithelium of the hindgut (8-9 days post-coitum), whereas subsequent movement of primordial germ cells to the dorsal mesentery (10 days post-coitum) and genital ridges requires active migration. By day 13 primordial germ cell migration ceases. During this migration the primordial germ cells divide. Initially at the site of origin less than 100 primordial germ cells can be recognized, whereas at the end of migration the number of primordial germ cells increases to 20.000-25.000 cells^{19,21}. The above sequence is not specific to mice and can be found in all vertebrates (migratory stage in humans between 4 and 6 weeks of development)¹⁹.

Based on experimental data and analogous to the migration of neural crest cells¹ it is supposed that the interaction between primordial germ cells and fibronectin may be

important in regulating onset, guidance, and cessation of primordial germ cell migration^{22,23}. In the mouse at 9.5-11 days post-coitum increased staining to fibronectin coincides with the migration of primordial germ cells in the dorsal mesentery, whereas at 12 days post-coitum on the arrival of primordial germ cells in the genital ridges weakened or absent staining is observed²⁴. Similar findings concerning the expression of ECM proteins are reported by others^{22,23,25-27}. Primordial germ cells themselves do not contribute to the formation of fibronectin rich migration pathways as they do not express fibronectin messenger RNA²².

The adhesion of primordial germ cells to fibronectin appears to be developmentally regulated^{22,23}. At the nonmigratory stage primordial germ cells firmly attach to fibronectin, whereas migratory primordial germ cells show a decreased adhesion to fibronectin^{22,23}. In the primitive gonad further impairment of primordial germ cell adhesion to fibronectin coincides with increased adhesion of these cells to somatic cells²². In parallel to this, *in vitro* migration of primordial germ cells isolated at the migratory stage but not in the nonmigratory stage can be enhanced by adding exogenous fibronectin to embryonic hindgut explant cultures²².

Antibodies to the integrin fibronectin receptor $\alpha 5\beta 1$ and RGD peptides reduce adhesion of primordial germ cells to fibronectin, suggesting a role for integrins in adhesion of primordial germ cells to this ligand²³. However, it is likely that additional factors are needed to promote primordial germ cell motility, as the morphology of primordial germ cells remains spherical after adhesion to fibronectin and does not exhibit the characteristics of motile cells (elongation, filopodia, pseudopodia)²³.

As the migration pathway of primordial germ cells consists of different types of cells and matrices it can be supposed that primordial germ cells use multiple cell adhesion receptors in order to alter their adhesive properties during migration. Indeed, post-migratory primordial germ cells express multiple integrins ($\alpha 3\beta 1$, $\alpha 5\beta 1$, $\alpha 6\beta 1$), but their developmental regulation during the migratory stage is presently not clear²¹. Analogous to the homing of leukocytes to sites of inflammation, regulation of (integrin-mediated) adhesiveness and homing of primordial germ cells may be under control of additional (soluble) factors^{28,29}.

Testicular cord formation

In the genital ridges primordial germ cells interact with cells derived from the coelomic epithelium and mesonephric mesenchyme. The earliest recognizable event in the development of the male rat testis is the differentiation and clustering of somatic cells in Sertoli cell precursors around primordial germ cells at 13-14 days post-coitum²⁰. Initially, the formation of testicular cords is accompanied by the disappearance of fibronectin from the presumptive testicular cord cells³⁰. Subsequently a discontinuous layer of laminin, entactin, collagen type IV and V, and heparan sulphate proteoglycan is formed. At the time the testicular cords anastomose they are surrounded by a continuous BM³¹.

In vitro data underline the pivotal role of a laminin containing BM in the development of testicular cords and the establishment of a polarized Sertoli cell phenotype. In a threedimensional culture system Sertoli cells organize into cords with the formation of tight junctional complexes, that divide the cord lumen into a peripheral (basal) compartment and a central (adluminal) compartment. The formation of these cords is abrogated by antibodies directed against laminin and entactin and synthetic peptides that compete with binding sites on laminin^{31,32}. As two different synthetic peptides (RGDS-NH₂, YIGSR-NH₂) interfere with testicular cord formation, it seems likely that Sertoli cells use multiple cell

adhesion molecules in recognition of laminin^{31,32}. Apart from the 60 kDA laminin binding protein (recognized by the anti-67 kDA laminin receptor antibody), additional ECM binding proteins have been identified including integrins³³⁻³⁵.

One of the integrin receptors involved in morphogenesis of testicular cords may be the $\alpha 6$ integrin subunit (associated with either the $\beta 1$ or $\beta 4$ integrin subunit), as reaggregation of testicular embryonic cells on a reconstituted BM (Matrigel) in vitro is prevented by addition of antibodies against the $\alpha 6$ integrin subunit to the culture system³⁶. In the primitive gonad the transient expression of the $\alpha 6$ integrin subunit at sites of epithelial cell aggregation suggests a *in vivo* role of this integrin as well³⁷. However, presently it is not yet clear whether cell-matrix interactions provide the initial signal that activates the morphogenetic cascade or whether soluble factors initially are involved.

After formation of testicular cords, actin and myosin positive myoid cell precursors develop out of mesenchymal cells around the testicular cords³⁸. Around this time collagen type VI can be found in the space between the lamina densa and the Sertoli cells and between the lamina densa and the interstitial tissue outside of the myoid cells. The limited, predominantly myoid cell associated distribution of collagen type VI suggests that this ECM protein is important in the differentiation of myoid cells and plays a role in anchoring Sertoli and myoid cells to the ECM³⁹.

Basement membrane formation is dependent on the cooperative activity of myoid cells and Sertoli cells

In rats, the lamina propria surrounding the seminiferous tubules consists of three layers: an inner acellular zone that includes the tubular BM, a single layer of myoid cells, and an outer acellular zone that lines between the myoid cells and the lymphatic endothelial cells⁴⁰. The inner acellular zone is composed of laminin, collagen type I and IV, heparan sulphate proteoglycan and nidogen/entactin, whereas the outer acellular zone contains laminin, type IV collagen, heparan sulphate proteoglycan and fibronectin⁴⁰. Although the rat testis can be used as a model to study BM structure and function, one has to keep in mind that there is considerable interspecies variance with respect to the composition and size of the lamina propria³¹. Moreover, age-dependent variations in the quantity and quality of the testicular ECM have been reported, adding further complexity to the role of the BM in testicular homeostasis⁴¹⁻⁴³.

In vitro, Sertoli cells synthesize laminin, entactin, collagen type IV, and proteoglycans, whereas peritubular myoid cells are capable of producing merosin, collagen type I and IV, fibronectin, and proteoglycans. The synthesis and deposition of ECM proteins by myoid cells and Sertoli cells is dependent on the interaction of both cell types, since in monocultures Sertoli cells and myoid cells predominantly demonstrate intracellular localization of ECM proteins with scant deposition of ECM proteins in pericellular BM structures⁴⁴⁻⁴⁹. The sequential deposition of BM components in cocultures of Sertoli cells and myoid cells illustrates that BM formation is a complex and highly regulated process that may include feedback mechanisms of ECM proteins regulating their own synthesis⁴⁹.

The ECM affects Sertoli cell morphology and function

Sertoli cells, when cultured on and in Matrigel⁵⁰, on seminiferous-tubule biomatrix⁵¹, or a combination of collagen type IV and laminin⁵², resume a morphology that is

reminiscent to the morphology of Sertoli cells *in vivo*. Moreover, ECM proteins affect the vectorial secretory pattern of Sertoli cells³¹. These effects on protein synthesis and secretion are not consistent, as ECM induced structural differentiation of Sertoli cells not necessarily leads to changes in Sertoli cell function at the molecular level⁵³, and differential effects of ECM proteins on protein secretion are observed³¹. The effects of ECM proteins on the barrier function and vectorial secretion can be substituted by myoid cells, emphasizing the importance of myoid cell-Sertoli cell interactions⁵⁴⁻⁵⁶.

The effects of ECM proteins on Sertoli cells are dependent on a transmembrane link between extracellular laminin and elements of the cytoskeleton elements^{57,58}, and are mediated by common intracellular signal transduction pathways that include enhancement of the Gs complex of adenylyl cyclase and mobilization of intracellular Ca⁺⁺ pools³¹. Recent studies suggest that activation of c-fos (a early response oncogene that may serve as a transcription factor) is involved in attachment and spreading of Sertoli cells on different ECM substrates^{31,59}. Despite these observations the mechanisms by which ECM proteins modulate cell morphology, behavior and function are largely unknown.

Spermatogenesis

Postnatally, gonocytes re-initiate cell division and move from the center of the tubuli to the BM zone⁶⁰. Although some experimental data point to a role for ECM proteins in the development of gonocytes after birth⁶¹, it is supposed that the BM has no direct effect on this process. Probably the activation of gonocyte proliferation relies on intratesticular paracrine regulators and direct interaction of gonocytes with Sertoli cells⁶⁰.

In the adult testis the adhesion of spermatogenic cells to Sertoli cells contributes to their differentiation and extended viability, that is supposed to be mediated by multiple cell adhesion molecules, including integrins²⁰. In the rat testis the expression of $\alpha 6$ and $\beta 1$ integrin subunits varies depending on the developmental stage (prepubertal versus adult) and maturation stage of the seminiferous epithelium⁶². In the prepubertal testis both integrin subunits are present at distinct intercellular sites within the seminiferous epithelium. In the adult testis both integrin subunits are present on the heads of elongating and maturing spermatids (stages I-XIV) and as a discontinuous suprabasal line above spermatogonia (stages I-IX, XIII, and XIV)^{34,62}. In the human testis $\alpha 3$, $\alpha 5$, $\alpha 6$ and $\beta 1$ integrin subunits are present on spermatocytes, spermatids and spermatozoa *in situ* and on ejaculated sperm as well³⁵. Additionally, the $\alpha 4$ integrin subunit is detected on ejaculated sperm, but not on spermatogenic cells *in situ*⁶³.

These data suggest that cell-cell as well as cell-matrix interactions during (specific stages) of spermatogenesis are at least in part mediated by integrins. It has been hypothesized that integrins, including the $\alpha 6$ and $\beta 1$ integrin subunits are located at tight junctions at the side of ectoplasmic specializations between neighboring Sertoli cells and at sites of intercellular attachment of Sertoli cells and adjacent spermatids^{62,64}. This way integrins may modulate the migration of spermatogenic cells into the adluminal compartment and contribute to their maturation. Whether integrins are involved in adhesion of spermatogonia to the BM has to be elucidated.

The basement membrane in testicular pathology

Disturbance of testicular homeostasis as seen in a variety of local and systemic pathological conditions is often accompanied by qualitative and quantitative abnormalities in the structure of the seminiferous tubules³¹. In addition to changes in Sertoli cells and spermatogenic cells, the diameter of seminiferous tubules is often reduced. The tubular BM is thickened, multilayered and displays deep invaginations into the tubular lumen. As revealed by electron microscopy, abnormal structures and lucent areas may be present in the BM⁶⁵⁻⁶⁷. It is supposed that the changes described above eventually progress to complete hyalinization of seminiferous tubules with filling of the tubule lumen by collagen in the absence of Sertoli cells and spermatogenic cells⁶⁸. These changes suggest that the balance between production and breakdown of BM constituents is lost either by increased deposition or by decreased degradation of BM components. However, at this moment it is impossible to determine whether impaired spermatogenesis is the trigger that leads to tubular hyalinization or whether the impaired spermatogenesis is secondary to the changes that occur in the tubular BM³¹.

Summary and conclusions

Similar to morphogenetic processes in other organ systems it appears that ECM proteins play a pivotal role in testicular development. For example, the selective distribution of fibronectin along the migration pathway of primordial germ cells suggests that migration of primordial germ cells is at least in part dependent on their interaction with fibronectin. The onset of testicular cord formation is associated with marked changes in the distribution of ECM proteins. However, presently it is not clear whether cell-matrix interactions provide the initial signal that activates the morphogenetic cascade or whether initially soluble factors are involved. The coordinated interaction of both myoid cells and Sertoli cells is essential for the formation of the basement membrane (BM) that surrounds testicular cords and, later on, the seminiferous tubules. Conversely, in the adult testis normal seminiferous tubule function including spermatogenesis seems to be dependent on the cooperative action of Sertoli and myoid cells, in which the tubular BM plays an essential role.

INTEGRINS IN THE BIOLOGY OF METASTASIS

The metastatic cascade

The process of tumor cell invasion and metastasis is highly complex and constitutes a sequence of events in which adhesion to and penetration of epithelial BMs at the primary site is one of the most important^{69,70}. However, penetration of the ECM also occurs at other stages of the metastatic cascade. Tumor cells have to penetrate the subendothelial BM to gain access to the circulation. At distant sites, arrest and extravasation of tumor cells requires degradation of the subendothelial BM and its underlying interstitial matrix, apart from integrin and nonintegrin mediated adhesion of tumor cells to the endothelium and the subendothelial BM⁷¹. Analogous to the development of hematogenous metastases, tumor cell-ECM interactions are supposed to be essential to the development of lymphogenic metastases too⁷².

The process of BM degradation by tumor cells was first described by Liotta as part of the "the three step hypothesis of invasion" ^{69,70}. It is supposed that the transition from in situ to invasive stage is achieved by loosening cell-cell and cell-matrix contacts and degradation of BM components like laminin and collagen type IV by tumor and/or host cell derived proteinases at the leading edge of tumor cells ^{16,73}. Vice versa, by binding to tumor cells (partially degraded) ECM proteins can modulate the secretion of proteolytic enzymes ⁷⁴, stimulate chemotaxis and haptotaxis of tumors cells ⁷⁵, and modulate the expression of their own receptors ⁷⁶, thereby stimulating the invasive process. The final step is the integrin mediated locomotion of tumor cells through the zone of BM lysis that may be regulated by tumor cell derived cytokines and/or host organ-derived chemoattractants ⁷³. Once the tumor cells have invaded the surrounding tissue they elicit the formation of a primitive stroma, composed of plasma derived cross-linked fibrin and fibronectin. The fibrin-fibronectin gel serves as a provisional matrix that facilitates and regulates the influx of endothelial cells, fibroblasts, and other host cells. Subsequently, by deposition of tumor or host cell-derived collagen type III and I, the provisional matrix is replaced by mature stroma and a tumor specific microenvironment is created that permits and promotes the survival and proliferation of tumor cells ⁷⁷⁻⁷⁹.

Distribution of integrin and their ligands in malignant tumors

The immunohistochemical distribution of integrin subunits in malignant tumors has been studied extensively, and a selection of data published in recent years is summarized in Table 2. However, the interpretation of these data is rather difficult. One of the major problems encountered in these studies is that detection of integrin subunits by immunohistochemistry does not provide information on functional activity. Moreover, various studies are difficult to compare by differences in tumor sampling, technical procedures, antibodies and interpretation of staining patterns. Yet, specific changes in integrin subunit expression upon malignant transformation may be informative about mechanisms involved in the biology of malignant tumors.

In situ, normal tissues show cell-lineage dependent integrin distribution patterns that may be conserved in their malignant counterparts ⁸⁰⁻⁸². For example, $\alpha 2$ and $\alpha 3$ integrin subunits are expressed in epithelia, the epithelial component of epithelial-mesenchymal tumors, and carcinomas, whereas benign and malignant mesenchymal tumors, and the desmoplastic stroma of carcinomas in general show expression of $\alpha 1$ and $\alpha 5$ integrin subunits ⁸⁰. However, in contrast to an often localized pattern on the membrane of normal cells, in malignancy integrins lack the normal spatial organization and are diffusely distributed over the cell surface with a greater degree of variability ^{80,83,84}. The abnormal distribution probably reflects loss of function, although at least in some tumors the function of integrins seems to be conserved ⁸⁵. Interestingly, in some tumors integrins may be considered as oncodevelopmental antigens as in some tumors "embryonal integrins" are reexpressed upon malignant transformation. The reexpression of embryonal $\alpha 4$, $\alpha 5$, and $\alpha 6$ integrin subunits in human rhabdomyosarcomas is an example of this phenomenon ⁸¹.

In general malignant (epithelial) tumors show a tendency to express reduced levels of integrins, in particular integrins that have affinity to BM components like laminin and collagen type IV ⁸⁶. The expression of BM components parallels the expression of the corresponding receptors ^{87,88}. The tumors that are more invasive lack intact BMs and receptors that bind to components of BMs ⁸⁶.

Table 2 Integrin subunit expression in malignant tumors and their noninvasive precursors (I).

Integrin subunit	$\alpha 1$	$\alpha 2$	$\alpha 3$	$\alpha 4$	$\alpha 5$	$\alpha 6$	αv	$\beta 1$	$\alpha v \beta 3$	$\alpha 6 \beta 4$	$\beta 5$
Astrocytoma ⁹⁷		↓	↑	-	-	+	-	↑	-	-	
Glioblastoma ⁹⁷		↓	↑	-	-	+	dn ↑	↑	dn ↑	-	
Basal cell carcinoma ⁹⁸	dn ↑	↑	↑					↑			
Basal cell carcinoma ⁹⁹		+	↓		-			+			
Basal cell carcinoma ¹⁰⁰											↓
Basal cell carcinoma ¹⁰¹											↓
Basal cell carcinoma ¹⁰²											↓
Bladder cancer ¹⁰³	dn ↑	↓	↓	-	dn ↑		-				
Bladder cancer ¹⁰⁴						↓					↓
Breast cancer (CIS) ⁸⁹	-	↓	↑	-	-	+	↑	↓	-		↓
Breast cancer (nos) ⁹⁶						↓					
Breast cancer (nos) ¹⁰⁵						↓		↓			↓
Breast cancer (nos) ¹⁰⁶	dn ↑	↓	↓	dn ↑	dn ↑	↓		+			
Breast cancer (nos) ⁸⁸	dn ↑	↓	+	-	+	↓					
Breast cancer (ductal) ¹⁰⁷		↓				↓	↓	↓			↓
Breast cancer (ductal) ⁸⁹	↑	↑	+	-	↑	↑	↑	↑	-		↓
Breast cancer (lobular) ¹⁰⁷		↓				↓	↓	↓			↓
Breast cancer (lobular) ⁸⁹	↑	↓	+	-	-	↑	+	↑	-		↓
Cholangiocarcinoma ⁸²	-	↓	↓			↓	↓	↓			↓

Expression of integrin subunits: (-), negative, unchanged; (+), positive, unchanged; (↑), increased; (dn ↑), denovo; (↓), decreased; nos, not otherwise specified; SCC, squamous cell carcinoma; WT, Wilms tumor.

Table 2 Integrin subunit expression in malignant tumors and their noninvasive precursors (II).

Integrin subunit	$\alpha 1$	$\alpha 2$	$\alpha 3$	$\alpha 4$	$\alpha 5$	$\alpha 6$	αv	$\beta 1$	$\alpha v\beta 3$	$\alpha 6\beta 4$	$\beta 5$
Colorectal adenoma ¹⁰⁸	+	+					+				
Colorectal adenoma ¹⁰⁹	-	+	↓	-	↓	+		+		+	
Colorectal adenoma ⁸⁴		↓				+		+			
Colorectal adenoma ¹¹⁰	↑	↓	↑	-	-	↑	+	↑	↓	↑	
Colorectal cancer ⁸⁴		↓				+		↓			
Colorectal cancer ¹¹¹		↓				↓	↓	↓	↓/↑		↑/↓
Colorectal cancer ¹⁰⁸		↓	↓					↓			
Colorectal cancer ¹⁰⁹	-	↓	↓	-	↓	↓		↓		↓	
Colorectal cancer ¹¹⁰	↓	↓	↓	-	-	↓	↓	↓	↓	↓	↑
Leiomyosarcoma ⁸¹	↓	dn ↑	↓	dn ↑	↓	dn ↑	↓	+			
Hepatocellular carcinoma ⁸²	↑	dn ↑	dn ↑			dn ↑	dn ↑	↑		-	
Malignant schwannoma ¹¹²	↓	↓	dn ↑	dn ↑	dn ↑	↓	↓	+	↑	↓	
Melanoma ¹¹³ (review)	dn ↑	dn ↑	↑	dn ↑	dn ↑	↓	+	+	dn ↑	dn ↑	dn ↑
Prostate cancer ⁸³						+		+			
Renal cell carcinoma ⁸⁷	+	+	+	-	-	↓	dn ↑	+	dn ↑	dn ↑	
Rhabdomyosarcoma ⁸¹	dn ↑	-	dn ↑	dn ↑	dn ↑	dn ↑	dn ↑	+			
SCC (cervix) ¹¹⁴											↓
SCC (head and neck) ^{95,115,116}											↑
SCC (head and neck) ¹¹⁷		+	+			↓		+			↓
SCC (skin) ¹¹⁰	↓	↓		dn ↑	↓		↓				
SCC (skin) ¹⁰¹						↑					↑
Papillary carcinoma (thyroid) ¹¹⁸	↑	↑	↑	dn ↑	↑	↑		↑			
WT (blastema) ¹¹⁹	↓	-	dn ↑	↓	↓	dn ↑		+		-	

In some tumors an enhanced expression of integrins is seen that may be limited to the invasive front of the tumor⁸⁹, whereas other integrins are diffusely upregulated or de novo expressed^{89,90}. However, changes in integrin subunit expression are complex and not limited to one particular integrin subunit. For example in human melanomas changes in multiple integrin subunits are reported to be associated with progression including down regulation of $\alpha 1$, $\alpha 6$, and $\beta 4$ integrin subunits, and upregulation of $\alpha 2$, $\alpha 3$, $\alpha 4$, $\alpha 5$, $\alpha 7$, αv , $\alpha 1 b$, and $\beta 3$ integrin subunits⁹¹. Of these integrin subunits $\alpha 1$, $\alpha 4$, and $\alpha 6$ correlate with tumor thickness, whereas only $\alpha 4$ and $\alpha 6$ integrin subunits are associated with the development of metastasis. The association of specific integrin subunits with grade^{87,92}, stage^{84,93}, disease-free survival^{93,94}, and overall-survival^{93,95,96} supports the view that integrins may be used as prognostic factors that aid in the evaluation of the risk for metastases formation and in the choice of adequate therapy.

Experimental studies on the role of integrins in tumorigenesis, invasion and development of metastasis

The relevance of tumor cell-ECM interactions in invasion and development of metastases was suggested by studies in which tumor cells with an enhanced metastatic ability could be selected by their adhesion on collagen type IV coated surfaces in the presence of laminin^{120,121}. Barsky et al. extended these results by showing that the development of metastases in vivo was modulated by injection of tumor cells together with intact laminin or laminin fragments¹²². Occupation of the laminin receptor by the cell binding fragment of laminin inhibits the formation of metastases in vivo, whereas preincubation of tumor cells with intact laminin that contains the collagen type IV binding site, stimulates the formation of metastases. Putatively, this latter effect is caused by forming a bridge between the laminin receptor on tumor cells and the subendothelial BM containing collagen type IV.

A role for integrins in invasion and metastasis was demonstrated by studies in which in vitro invasion of tumor cells was blocked by antibodies directed against integrins or synthetic RGD peptides that competed for the binding of integrins to ECM proteins^{123,124}. Similarly, in vivo the dissemination of tumor cells was prevented by coinjection of tumor cells with synthetic RGD peptides¹²⁵.

Recently, results have been obtained on experimental manipulation of specific integrin subunit expression. From these studies it became clear that changes in integrin expression explain at least in part some of the phenotypic characteristics of malignant tumor cells, including their tumorigenicity, invasiveness and metastatic potential. For example, the study by Giancotti et al. shows that integrins may have inhibitory effects on proliferation¹²⁶. Transfection of $\alpha 5$ and $\beta 1$ cDNA in $\alpha 5$ - $\beta 1$ -transformed Chinese Hamster Ovary (CHO) cells followed by methotrexate induced amplification results in (over)expression of the $\alpha 5 \beta 1$ integrin. Functionally, the transfected cells are nontumorigenic when injected subcutaneously into nude mice. Conversely, loss of expression of the $\alpha 5 \beta 1$ integrin in CHO cells is associated with increased tumorigenicity¹²⁷. In contrast, the $\alpha v \beta 3$ integrin when expressed on melanoma cells exerts a positive regulatory signal that stimulates proliferation. Melanoma variants lacking the $\alpha v \beta 3$ integrin show decreased proliferation in vivo, whereas transfection of the αv integrin subunit into $\alpha v \beta 3$ negative melanoma cells restores tumorigenicity¹²⁸.

The property of tumor cells to escape programmed cell death is only recently appreciated as a sign of tumor progression^{129,130}, that disturbs the balance of proliferation and cell death leading to progressive growth^{129,130}. Escape to programmed cell death especially

is warranted in poorly vascularized regions of tumors, or at the initial stage of tumor development (primary tumor or metastasis) when vascularization is inefficient and accounts for deficiencies in oxygenation and nutrient supply^{131,132}. It has been hypothesized that tumor cells become insensitive to anoikis (apoptotic cell response after detachment of cells from the ECM) by altering intracellular signal transduction pathways, as abrogation of this process seems to be a prerequisite to the acquisition of anchorage-independent growth during transformation^{133,134}. On the other hand recent data suggest that ECM proteins (present in the microenvironment or secreted by tumor cells) act as survival factors by binding to integrins on the tumor cell surface¹³⁵, as programmed cell death of human melanoma cells in the absence of exogenous growth factors is prevented by ECM mediated ligation of the $\alpha v\beta 3$ integrin.

Integrins may inhibit as well as promote the formation of metastases, and play different roles at different metastatic stages^{136,137}. Transfection of $\alpha 4$ cDNA in highly invasive $\alpha 4\text{-}\beta 1$ B16 melanoma cells results in vitro in decreased Matrigel invasion, whereas in vivo decreased formation of pulmonary metastases after subcutaneous (spontaneous metastasis system) but not after tail vein injection (experimental metastasis system) of transfected cells is noticed. These data suggest a suppressive role of the $\alpha 4\beta 1$ integrin during the invasive stage of metastases formation which is present after subcutaneous but not after intravenous injection of tumor cells. However, rather than mediating cell-matrix interactions, in this model it seems likely that the $\alpha 4\beta 1$ integrin exerts its action by mediating homotypic intercellular adhesion since antibodies directed against this integrin abrogate intercellular melanoma cell adhesion and increase Matrigel invasion¹³⁶. Conversely, transfection of $\alpha 2$ cDNA into human rhabdomyosarcoma cells results in an enhanced metastatic propensity of tumor cells that becomes apparent both after subcutaneous and tail vein injection of tumor cells. As transfected cells demonstrate an enhanced adhesion to collagen and laminin the effect on metastasis formation seems at least in part mediated by an altered interaction of tumor cells with the ECM¹³⁷. In both experiments no effects on growth of tumor cells in vitro or in vivo were observed, implying that effects of integrins on tumor cell growth and the propensity to metastasize are not necessarily linked.

The phenomena of integrin mediated outside-in and inside-out signalling lead to the assumption that biological behavior of tumor cells is affected by their pattern of integrin expression, and conversely, integrin expression is also dependent on tumor progression thereby reflecting the degree of malignancy of the cell¹³⁸. Loss of integrins may decrease adhesiveness of tumor cells in their microenvironment and render them refractory to growth regulatory (inhibitory) signals¹³⁹, whereas denovo expression of integrins may change the adhesiveness of tumor cells to unfamiliar matrices and heterotypic cells¹⁶. However, it should be emphasized that the mechanisms used by tumor cells to invade and metastasize are analogous to the ones used by normal cells. Analogous the homing of leukocytes to sites of inflammation¹⁴⁰, it is supposed that tumor cells use multiple cell adhesion molecules during the process of invasion and metastasis⁷¹. The aggressive behavior of malignant tumors however, is the result of an imbalance between positive and negative regulatory factors which are operative during physiological processes as well^{73,141}. Hence, the biology of malignant tumors is at least in part determined by the properties of their normal counterparts as is nicely illustrated in testicular germ cell tumors¹⁴².

Summary and conclusions

Upon malignant transformation and subsequent tumor progression the pattern of integrin expression changes and becomes disorganized. However, lineage specific integrin distribution patterns may be conserved in malignant tumors, and occasionally reexpression of embryonal integrins may be observed. Compared to their benign counterparts malignant tumors in general show a tendency to express reduced levels of integrins, although in some tumors integrins may be upregulated, or expressed de novo. Functionally, integrins may have inhibitory as well stimulatory effects on tumor cell growth, that may be related to conferral of resistance to anoikis (apoptotic cell response after detachment of cells from the ECM) or rescue from programmed cell death by ECM-mediated ligation of integrins present on the tumor cell surface. Furthermore, integrins may inhibit as well as promote the formation of metastases, and play different roles at different metastatic stages. In line with current concepts on metastasis formation it appears that the effects of integrins on tumor growth and metastasis formation are not necessarily linked. Thus, although the redundancy in integrin-ligand interactions is enormous, experimental data point to different roles for specific integrins at different stages of the metastatic cascade. The association of specific integrin subunits with grade, stage, disease-free survival and overall-survival supports the view that integrins may be used as biological parameters that aid in the evaluation of the risk for metastasis formation and in the choice of adequate therapy.

REFERENCES

1. Hay ED. Cell biology of the extracellular matrix. 2nd ed. New York and London: Plenum Press, 1991
2. Merker H -J: Morphology of the basement membrane. *Micros Res Tech* 1994, 28: 95-124
3. Hynes R O: Integrins: Versatility, modulation, and signaling in cell adhesion. *Cell* 1992, 69: 11-25
4. Burridge K, Fath K, Nuckolls G, Turner C: Focal adhesions: transmembrane junctions between the extracellular matrix and the cytoskeleton. *Ann Rev Cell Biol* 1988, 4: 487-525
5. Sastry S K, Horwitz A F: Integrin cytoplasmic domains: Mediators of cytoskeletal linkages and extra- and intracellular initiated transmembrane signalling. *Curr Opin Cell Biol* 1993, 5: 819-831
6. Sonnenberg A, Calafat J, Janssen H, Daams H, van der Raaij-Helmer L M, Falcioni R, Kennel S J, Aplin J D, Baker J, Loizidou M: Integrin alpha 6/beta 4 complex is located in hemidesmosomes, suggesting a major role in epidermal cell-basement membrane adhesion. *J Cell Biol* 1991, 113: 907-917
7. Tamura R N, Cooper H M, Collo G, Quaranta V: Cell type-specific integrin variants with alternative α chain cytoplasmic domains. *Dev Biol* 1991, 88: 10183-10187
8. Haas T A, Plow E F: Integrin-ligand interactions: A year in review. *Curr Opin Cell Biol* 1994, 6: 656-662

9. Ginsberg M H, Du X, Plow E F: Inside-out integrin signalling. *Curr Opin Cell Biol* 1992, 4: 766-771
10. Humphries M J: Peptide recognition motifs involved in the binding of integrins to their ligands. *Kidney Int* 1992, 41: 645-649
11. Yamada Y, Kleinman H K: Functional domains of cell adhesion molecules. *Curr Opin Cell Biol* 1992, 4: 819-823
12. Chan B M C, Hemler M E: Multiple functional forms of the integrin VLA-2 can be derived from a single $\alpha 2$ cDNA clone: Interconversion of forms induced by an anti- $\beta 1$ antibody. *J Cell Biol* 1993, 120: 537-543
13. Damsky C H, Werb Z: Signal transduction by integrin receptors for extracellular matrix: Cooperative processing of extracellular information. *Curr Opin Cell Biol* 1992, 4: 772-781
14. Bissell M J, Hall H G, Parry G: How does the extracellular matrix direct gene expression? *J Theor Biol* 1982, 99: 31-68
15. Juliano R L, Haskill S: Signal transduction from the extracellular matrix. *J Cell Biol* 1993, 120: 577-585
16. Hynes R O, Lander A D: Contact and adhesive specificities in the associations, migrations and targeting of cells and axons. *Cell* 1992, 68: 303-322
17. Clark E A, Brugge J S: Integrins and signal transduction pathways: the road taken. *Science* 1995, 268: 233-239
18. Satoh M: Histogenesis and organogenesis of the gonad in human embryos. *J Anat* 1991, 177: 85-107
19. Wylie C C: The biology of primordial germ cells. *Eur Urol* 1993, 23: 62-67
20. Kierszenbaum A L: Mammalian spermatogenesis in vivo and in vitro: A partnership of spermatogenic and somatic cell lineages. *Endocrine Rev* 1994, 15: 116-134
21. De Felici M, Dolci S, Pesce M: Cellular and molecular aspects of mouse primordial germ cell migration and proliferation in culture. *Int J Dev Biol* 1992, 36: 205-213
22. Ffrench-Constant C, Hollingsworth A, Heasman J, Wylie C C: Response to fibronectin of mouse primordial germ cells before, during and after migration. *Development* 1991, 113: 1365-1373
23. De Felici M, Dolci S: In vitro adhesion of mouse fetal germ cells to extracellular matrix components. *Cell Differ Dev* 1989, 26: 87-96
24. Fujimoto T, Yoshinaga K, Kono I: Distribution of fibronectin on the migratory pathway of primordial germ cells in mice. *Anat Rec* 1985, 211: 271-278
25. Heasman J, Hynes R O, Swan A P, Thomas V, Wylie C C: Primordial germ cells of *Xenopus* embryos: the role of fibronectin in their adhesion during migration. *Cell* 1981, 27: 437-447

26. Alvarez-Buylla A, Merchant-Larios H: Mouse primordial germ cells use fibronectin as a substrate for migration. *Exp Cell Res* 1986, 165: 362-368
27. Urven L E, Abbott U K, Erickson C A: Distribution of extracellular matrix in the migratory pathway of avian primordial germ cells. *Anat Rec* 1989, 224: 14-21
28. Godin I, Wylie C, Heasman J: Genital ridges exert long range effects on mouse primordial germ cell numbers and direction of migration in culture. *Development* 1990, 108: 357-363
29. Godin I, Wylie C C: TGF beta 1 inhibits proliferation and has a chemotropic effect on mouse primordial germ cells in culture. *Development* 1991, 113: 1451-1457
30. Pelliniemi L J, Paranko J, Grund S K, Föjdman K, Foidart J M, Lakkala-Paranko T: Extracellular matrix in testicular differentiation. *Ann N Y Acad Sci* 1984, 438: 405-416
31. Dym M: Basement membrane regulation of Sertoli cells. *Endocrine Rev* 1994, 15: 102-115
32. Hadley M A, Weeks B S, Kleinman H K, Dym M: Laminin promotes formation of cord-like structures by Sertoli cells in vitro. *Dev Biol* 1990, 140: 318-327
33. Davis C M, Papadopoulos V, Jia M C, Yamada Y, Kleinman H K, Dym M: Identification and partial characterization of laminin binding proteins in immature rat Sertoli cells. *Exp Cell Res* 1991, 193: 262-273
34. Palombi F, Salanova M, Tarone G, Farini D, Stefanini M: Distribution of $\beta 1$ integrin subunit in rat seminiferous epithelium. *Biol Reprod* 1992, 47: 1173-1182
35. Schaller J, Glander H J, Dethloff J: Evidence of $\beta 1$ integrins and fibronectin on spermatogenic cells in human testis. *Hum Reprod* 1993, 8: 1873-1878
36. Pesce M, Siracusa G, Giustiniani Q, De Felici M: Histotypic in vitro reorganization of dissociated cells from mouse fetal gonads. *Differentiation* 1994, 56: 137-142
37. Fröjdman K, Pelliniemi L J: Differential distribution of the $\alpha 6$ subunit of integrins in the development and sexual differentiation of the mouse testis. *Differentiation* 1994, 57: 21-29
38. Parenko J, Pelliniemi L J: Differentiation of smooth muscle cells in the fetal rat testis and ovary: localization of alkaline phosphatase, smooth muscle myosin, F-actin, and desmin. *Cell Tissue Res* 1992, 268: 521-530
39. Sawada H, Yazama F: Type VI collagen in the rat testis: monoclonal antibody, isolation, and localization during development. *Biol Reprod* 1994, 50: 702-710
40. Hadley M A, Dym M: Immunocytochemistry of extracellular matrix in the lamina propria of the rat testis: electron microscopic localization. *Biol Reprod* 1987, 37: 1283-1289
41. Rodriguez J P, Fernandez M, Minguell J J: Interstitial collagen synthesis by somatic testicular cells in culture. *Cell Biochem Funct* 1991, 9: 63-67

42. Gelly J L, Richoux J P, Leheup B P, Grignon G: Immunolocalization of type IV collagen and laminin during rat gonadal morphogenesis and postnatal development of the testis and epididymis. *Histochemistry* 1989, 93: 31-37
43. Paniagua R, Nistal M, Saez F J, Fraile B: Ultrastructure of the aging human testis. *J Electron Microsc Tech* 1991, 19: 241-260
44. Skinner M K, Tung P S, Fritz I B: Cooperativity between Sertoli cells and testicular peritubular cells in the production and deposition of extracellular matrix components. *J Cell Biol* 1985, 100: 1941-1947
45. Lian G, Miller K A, Enders G C: Localization and synthesis of entactin in seminiferous tubules of the mouse. *Biol Reprod* 1992, 47: 316-325
46. Borland K, Muffly K E, Hall P F: Production of components of extracellular matrix by cultured rat Sertoli. *Biol Reprod* 1986, 35: 997-1008
47. Davis C M, Papadopoulos V, Sommers C L, Kleinman H K, Dym M: Differential expression of extracellular matrix components in rat Sertoli cells. *Biol Reprod* 1990, 43: 860-869
48. Skinner M K, Stallard B, Anthony C T, Griswold M D: Cellular localization of fibronectin gene expression in the seminiferous tubule. *Mol Cell Endocrinol* 1989, 66: 45-52
49. Richardson : Basement membrane gene expression by Sertoli cells and peritubular myoid cells in vitro in the rat. *Biol Reprod* 1995, 52: 320-330
50. Hadley M A, Byers S W, Suarez-Quian C A, Kleinman H K, Dym M: Extracellular matrix regulates Sertoli cell differentiation, testicular cord formation, and germ cell development in vitro. *J Cell Biol* 1985, 101: 1511-1522
51. Tung P S, Fritz I B: Extracellular matrix promotes rat Sertoli cell histotypic expression in vitro. *Biol Reprod* 1984, 30: 213-229
52. Suarez-Quian C A, Hadley M A, Dym M: Effect of substrate on the shape of Sertoli cells in vitro. *Ann N Y Acad Sci* 1984, 438: 417-434
53. Anthony C T, Skinner M K: Actions of extracellular matrix on Sertoli cell morphology and function. *Biol Reprod* 1989, 40: 691-702
54. Janecki A, Steinberger A: Vectorial secretion of transferrin and androgen binding protein in Sertoli cell cultures: effect of extracellular matrix, peritubular myoid cells and medium composition. *Mol Cell Endocrinol* 1987, 52: 125-135
55. Ailenberg M, Tung P S, Pelletier M, Fritz I B: Modulation of Sertoli cell functions in the two-chambered assembly by peritubular cells and by extracellular matrix. *Endocrinology* 1988, 122: 2604-2612
56. Skinner M K: Cell-cell interactions in the testis. *Endocrine Rev* 1991, 12: 45-77

57. Tung P S, Fritz I B: Interactions of Sertoli cells with laminin are essential to maintain integrity of the cytoskeleton and barrier functions of cells in culture in the two-chambered assembly. *J Cell Physiol* 1993, 156: 1-11
58. Tung P S, Fritz I B: Role of laminin in the morphogenetic cascade during coculture of Sertoli cells with peritubular cells. *J Cell Physiol* 1994, 161: 77-88
59. Papadopoulos V, Dym M: Sertoli cell differentiation on basement membrane is mediated by the c-fos proto-oncogene. *Proc Natl Acad Sci USA* 1994, 91: 7027-7031
60. McGuinness M P, Orth J M: Reinitiation of gonocyte mitosis and movement of gonocytes to the basement membrane in testes of newborn rats in vivo and in vitro. *Anat Rec* 1992, 233: 527-537
61. Orth J M, McGuinness M P: Neonatal gonocytes co-cultured with Sertoli cells on a laminin-containing matrix resume mitosis and elongate. *Endocrinology* 1991, 129: 1119-1121
62. Salanova M, Stefanini M, De Curtis I, Palombi F: Integrin receptor $\alpha 6 \beta 1$ is localized at specific sites of cell-to-cell contact in the rat seminiferous epithelium. *Biol Reprod* 1995, 52: 79-87
63. Glander H -J, Schaller J: Beta 1-integrins of spermatozoa: A flow cytophotometric analysis. *Int J Androl* 1993, 16: 105-111
64. Pfeiffer D C, Dedhar S, Byers S W, Vogl A W: Evidence that an integrin may be present at specialized sites ('ectoplasmic specializations') of intercellular adhesion in the seminiferous epithelium. *J Cell Biol* 1991, 115 (suppl): 482
65. Salomon F, Hedinger C E: Abnormal basement membrane structures of seminiferous tubules in infertile men. *Lab Invest* 1982, 47: 543-554
66. Jarow J P, Budin R E, Dym M, Zirkin B R, Noren S, Marshall F F: Quantitative pathologic changes in the human testis after vasectomy: a controlled study. *N Engl J Med* 1987, 313: 1252-1256
67. Paniagua R, Martinez-Onsurbe P, Santamaria L, Saez F J, Amat P, Nistal M: Quantitative and ultrastructural alterations in the lamina propria and Sertoli cells in human cryptorchid testes. *Int J Androl* 1990, 13: 470-487
68. Söderström K O: Tubular hyalinization in human testis. *Andrologia* 1986, 18: 97-103
69. Liotta L A, Rao C N, Barsky H: Tumor invasion and the extracellular matrix. *Lab Invest* 1983, 49: 636-649
70. Liotta L A: Tumor invasion and metastases-role of the extracellular matrix. *Cancer Res* 1986, 46: 1-7
71. Honn K V, Tang D G: Adhesion molecules and tumor cell interaction with endothelium and subendothelial matrix. *Cancer Metastasis Rev* 1992, 11: 353-375
72. Brodt P: Adhesion mechanisms in lymphatic metastasis. *Cancer Metastasis Rev* 1991, 10: 23-32
73. Liotta L A, Steeg P S, Stetler-Stevenson W G: Cancer metastasis and angiogenesis: an imbalance of positive and negative regulation. *Cell* 1991, 64: 327-336

74. Emonard H, Christiane Y, Smet M, Grimaud J A, Foidart J M: Type IV and interstitial collagenolytic activities in normal and malignant trophoblastic cells are specifically regulated by the extracellular matrix. *Cancer Inv Metastasis* 1990, 10: 170-177
75. Aznavoorian S, Stracke M L, Kruttsch H, Schiffmann E, Liotta L A: Signal transduction for chemotaxis and haptotaxis by matrix molecules in tumor cells. *J Cell Biol* 1990, 110: 1427-1438
76. Blood C H, Zetter B R: Laminin regulates a tumor cell chemotaxis receptor through the laminin-binding integrin subunit α_6 . *Cancer Res* 1993, 53: 2661-2666
77. Dvorak H F: Tumors: wounds that do not heal. Similarities between tumor stroma generation and wound healing. *N Engl J Med* 1986, 315: 1650-1659
78. Dvorak H F, Nagy J A, Berse B, Brown L F, Yeo K -T, Yeo T -K, Dvorak A M, van de Water L, Sioussat T M, Senger D R: Vascular permeability factor, fibrin, and the pathogenesis of tumor stroma formation. *Ann NY Acad Sci* 1992, 667: 101-111
79. Nagy J A, Brown L F, Senger D R, Lanir N, van de Water L, Dvorak A M, Dvorak H F: Pathogenesis of tumor stroma generation: a critical role for leaky blood vessels and fibrin deposition. *Biochim Biophys Acta* 1989, 948: 305-326
80. Miettinen M, Castello R, Wayner E, Schwarting R: Distribution of VLA integrins in solid tumors. *Am J Pathol* 1993, 142: 1009-1018
81. Mechtersheimer G, Barth T, Quentmeier A, Möller P: Differential expression of $\beta 1$ integrins in nonneoplastic smooth and striated muscle cells and in tumors derived from these cells. *American J Pathol* 1994, 144: 1172-1182
82. Volpes R, van den Oord J J, Desmet V J: Integrins as differential cell lineage markers of primary liver tumors. *Am J Pathol* 1993, 142: 1483-1492
83. Knox J D, Cress A E, Clark V, Manriquez L, Affinito K S, Dalkin B L, Nagle R B: Differential expression of extracellular matrix molecules and the $\alpha 6$ -integrins in the normal and neoplastic prostate. *Am J Pathol* 1994, 145: 167-174
84. Koretz K, Schlag P, Boumsell L, Möller P: Expression of VLA- $\alpha 2$, VLA- $\alpha 6$, and VLA- $\beta 1$ chains in normal mucosa and adenomas of the colon, and in colon carcinomas and their liver metastases. *Am J Pathol* 1991, 138: 741-750
85. Pignatelli M, Liu D, Nasim M M, Stamp G W H, Hirano S, Takeichi M: Morphoregulatory activities of E-cadherin and beta-1 integrins in colorectal tumour cells. *Br J Cancer* 1992, 66: 629-634
86. Albelda S M: Role of integrins and other cell adhesion molecules in tumor progression and metastasis. *Lab Invest* 1993, 68: 4-17
87. Korhonen M, Laitinen L, Yläne J, Koukoulis G K, Quaranta V, Juusela H, Gould V E, Virtanen I: Integrin distributions in renal cell carcinomas of various grades of malignancy. *Am J Pathol* 1992, 141: 1161-1171

88. D'Ardenne J, Richman P I, Horton M A, McAuly A E, Jordan S: Co-ordinate expression of the alpha-6 integrin laminin receptor sub-unit and laminin in breast cancer. *J Pathol* 1991, 165: 213-220
89. Koukoulis G K, Virtanen I, Korhonen M, Laitinen L, Quaranta V, Gould V E: Immunohistochemical localization of integrins in the normal, hyperplastic, and neoplastic breast. *Am J Pathol* 1991, 139: 787-799
90. Albelda S M, Mette S A, Elder D E, Stewart R M, Damjanovich L, Herlyn M, Buck C A: Integrin distribution in malignant melanoma: association of the $\beta 3$ subunit with tumor progression. *Cancer Res* 1990, 50: 6757-6764
91. Weterman M A J, van Muijen G N P, Bloemers H P J, Ruiter D J: Molecular markers of melanocytic tumor progression. *Lab Invest* 1994, 70: 593-608
92. Pignatelli M, Vessey C J: Adhesion molecules: Novel molecular tools in tumor pathology. *Hum Pathol* 1994, 25: 849-856
93. Schadendorf D, Heidel J, Gawlik C, Suter L, Czarnetzki B M: Association with clinical outcome of expression of VLA-4 in primary cutaneous malignant melanoma as well as P-selectin and E-selectin on intratumoral vessels. *J Natl Cancer Inst* 1995, 87: 366-371
94. Wolf G T, Carey T E, Schmaltz S P, McClatchey K D, Poore J, Glaser L, Hayashida D J S, Hsu S: Altered antigen expression predicts outcome in squamous cell carcinoma of the head and neck. *J Natl Cancer Inst* 1982, 82: 1566-1572
95. Carey T E, Wolf G T, Hsu S, Poore J, Petorsen K, McClatchey K D: Expression of the A9 antigen and loss of blood group antigens as determinants of survival in patients with head and neck squamous carcinoma. *Otolaryngology-Head and Neck Surgery* 1987, 96: 221-230
96. Friedrichs K, Ruiz P, Franke F, Gille I, Terpe H J, Imhof B A: High expression level of $\alpha 6$ integrin in human breast carcinoma is correlated with reduced survival. *Cancer Res* 1995, 55: 901-906
97. Paulus W, Baur I, Schuppan D, Roggendorf W: Characterization of integrin receptors in normal and neoplastic human brain. *Am J Pathol* 1993, 143: 154-163
98. Stamp G W H, Pignatelli M: Distribution of $\beta 1$, $\alpha 1$, $\alpha 2$ and $\alpha 3$ integrin chains in basal cell carcinomas. *J Pathol* 1991, 163: 307-313
99. Peltonen J, Larjava H, Jaakkola S, Gralnick H, Akiyama S K, Yamada S S, Yamada K M, Uitto J: Localization of integrin receptors for fibronectin, collagen, and laminin in human skin. Variable expression in basal and squamous cell carcinomas. *J Clin Invest* 1989, 84: 1916-1923
100. Sollberg S, Peltonen J, Uitto J: Differential expression of laminin isoforms and $\beta 4$ integrin epitopes in the basement membrane zone of normal human skin and basal cell carcinomas. *J Invest Dermatol* 1992, 98: 864-870
101. Rossen K, Dahlstrom K K, Mercurio A M, Wewer U M: Expression of the $\alpha 6 \beta 4$ integrin by squamous cell carcinomas and basal cell carcinomas: possible relation to invasive potential? *Acta Derm Venereol (Stockh)* 1994, 74: 101-105

102. Kimmel K A, Carey T E: Altered expression in squamous carcinoma cells of an orientation restricted epithelial antigen detected by monoclonal antibody A9. *Cancer Res* 1986, 46: 3614-3623
103. Liebert M, Washington R, Stein J, Wedemeyer G, Grossman H B: Expression of the VLA β 1 integrin family in bladder cancer. *Am J Pathol* 1994, 144: 1016-1022
104. Liebert M, Washington R, Wedemeyer G, Carey T E, Grossman H B: Loss of co-localization of α 6 β 4 integrin and collagen VII in bladder cancer. *Am J Pathol* 1994, 144: 787-795
105. Natali P G, Nicotra M R, Botti C, Mottolese M, Bigotti A, Segatto O: Changes in expression of α 6/ β 4 integrin heterodimer in primary and metastatic breast cancer. *Br J Cancer* 1992, 66: 318-322
106. Mechtersheimer G, Munk M, Barth T, Koretz K, Möller P: Expression of β 1 integrins in non-neoplastic mammary epithelium, fibroadenoma and carcinoma of the breast. *Virchows Arch A Pathol Anat* 1993, 422: 203-210
107. Pignatelli M, Rosaria Cardillo M, Hanby A, Stamp G W H: Integrins and their accessory adhesion molecules in mammary carcinomas: Loss of polarization in poorly differentiated tumors. *Hum Pathol* 1992, 23: 1159-1166
108. Pignatelli M, Smith M E F, Bodmer W F: Low expression of collagen receptors in moderate and poorly differentiated colorectal adenocarcinomas. *Br J Cancer* 1990, 61: 636-638
109. Stallmach A, von Lampe B, Matthes H, Bornhöft G, Riecken E O: Diminished expression of integrin adhesion molecules on human colonic epithelial cells during the benign to malign tumour transformation. *Gut* 1992, 33: 342-346
110. Koukoulis G K, Virtanen I, Moll R, Quaranta V, Gould V E: Immunolocalization of integrins in the normal and neoplastic colonic epithelium. *Virchow Archiv B Cell Pathol* 1993, 63: 373-383
111. Nigam A K, Savage F J, Boulos P B, Stamp G W H, Liu D, Pignatelli M: Loss of cell-cell and cell-matrix adhesion molecules in colorectal cancer. *Br J Cancer* 1993, 68: 507-514
112. Mechtersheimer G, Barth T, Quentmeier A, Möller P: Differential expression of β 1, β 3, and β 4 integrin subunits in nonneoplastic neural cells of the peripheral and autonomic nervous system and in tumors derived from these cells. *Lab Invest* 1994, 70: 740-752
113. Danen E H J, Van Muijen G N P, Ruiter D J: Role of integrins as signal transducing cell adhesion molecules in human cutaneous melanoma. *Cancer Surv* 1995, 24: 43-65
114. Carico E, French D, Bucci B, Falcioni R, Vecchione A, Mariani-Constantini R: Integrin β 4 expression in the neoplastic progression of cervical epithelium. *Gynecol Oncol* 1993, 49: 61-66
115. Wolf G T, Carey T E, Schmaltz S P, McClatchey K D, Poore J, Glaser L, Hayashida D J S, Hsu S: Altered antigen expression predicts outcome in squamous cell carcinoma of the head and neck. *J Natl Cancer Inst* 1990, 82: 1566-1572
116. Van Waes C, Kozarsky K F, Warren A B, Kidd L, Paugh D, Liebert M, Carey T E: The A9 antigen is associated with aggressive human squamous carcinoma is structurally and functionally similar to the newly defined integrin α 6 β 4. *Cancer Res* 1991, 51: 2395-2402

117. Cortesina G, Sacchi M, Bussi M, Panizzut B, Ferro S, Carlevato M T, Marchisio P C: Integrin expression in head and neck cancers. *Acta Oto-Laryngologica* 1995, 115: 328-330
118. Vitale M, Bassi V, Illario M, Fenzi G F, Casamassima A, Rossi G: Loss of polarity and de novo expression of the $\beta 1$ family of integrins in thyroid tumors. *Int J Cancer* 1994, 59: 185-190
119. Peringa J, Molenaar W M, Timens W: Integrins and extracellular matrix-proteins in the different components of the Wilms' tumour. *Virchows Archiv Int J Pathol* 1994, 425: 113-119
120. Murray J C, Liotta L, Rennard S I, Martin G R: Adhesion characteristics of murine metastatic and nonmetastatic tumor cells in vitro. *Cancer Res* 1980, 40: 347-351
121. Terranova V P, Liotta L A, Russo R G, Martin G R: Role of laminin in the attachment and metastasis of murine tumor cells. *Cancer Res* 1982, 42: 2265-2269
122. Barsky S H, Rao C N, Williams J E, Liotta L: Laminin molecular domains which alter metastasis in a murine model. *J Clin Invest* 1984, 74: 843-848
123. Yamada K M, Kennedy D W, Yamada S S, Gralnick H, Chen W T, Akiyama S K: Monoclonal antibody and synthetic peptide inhibitors of human tumor cell migration. *Cancer Res* 1990, 50: 4485-4496
124. Gehlsen K R, Argraves W S, Pierschbacher M D, Ruoslahti E: Inhibition of in vitro tumor cell invasion by Arg-Gly-Asp-containing synthetic peptides. *J Cell Biol* 1988, 106: 925-930
125. Humphries M J, Olden K, Yamada K M: A synthetic peptide from fibronectin inhibits experimental metastasis of murine melanoma cells. *Science* 1986, 233: 467-470
126. Giancotti F G, Ruoslahti E: Elevated levels of the alpha 5 beta 1 fibronectin receptor suppress the transformed phenotype of Chinese hamster ovary cells. *Cell* 1990, 60: 849-859
127. Schreiner C, Fisher M, Hussein S, Juliano R L: Increased tumorigenicity of fibronectin receptor deficient Chinese hamster ovary cell variants. *Cancer Res* 1991, 51: 1738-1740
128. Felding-Habermann B, Mueller B M, Romerdahl C A, Cheresch D A: Involvement of integrin αV gene expression in human melanoma tumorigenicity. *J Clin Invest* 1992, 89: 2018-2022
129. Marx J: Cell death studies yield cancer clues. *Science* 1993, 259: 760-761
130. Reed J C: Bcl-2 and the regulation of programmed cell death. *J Cell Biol* 1994, 124: 1-6
131. Sutherland R M: Importance of critical metabolites and cellular interactions in the biology of microregions of tumors. *Cancer* 1986, 58: 1668-1680
132. Sutherland R M: Cell and environment interactions in tumor microregions: the multicell spheroid model. *Science* 1988, 240: 177-184
133. Ruoslahti E, Reed J C: Anchorage dependence, integrins, and apoptosis. *Cell* 1994, 77: 477-478
134. Frisch S M, Francis H: Disruption of epithelial cell-matrix interactions induces apoptosis. *J Cell Biol* 1994, 124: 619-626

135. Montgomery A M P, Reisfeld R A, Cheresch D A: Integrin $\alpha_v\beta_3$ rescues melanoma cells from apoptosis in three-dimensional dermal collagen. *Proc Natl Acad Sci USA* 1994, 91: 8856-8860
136. Qian F, Vaux D L, Weissman I L: Expression of the integrin $\alpha_4\beta_1$ on melanoma cells can inhibit the invasive stage of metastasis formation. *Cell* 1994, 77: 335-347
137. Chan B M C, Matsuura N, Takada Y, Zetter B R, Hemler M E: In vitro and in vivo consequences of VLA-2 expression on rhabdomyosarcoma cells. *Science* 1991, 151: 1600-1602
138. Juliano R L, Varner J A: Adhesion molecules in cancer: The role of integrins. *Curr Opin Cell Biol* 1993, 5: 812-818
139. Schwartz M A: Signalling by integrins: Implications for tumorigenesis. *Cancer Res* 1993, 53: 1503-1506
140. Carlos T M, Harlan J M: Leukocyte-endothelial adhesion molecules. *Blood* 1994, 84: 2068-2101
141. Herlyn M, Malkowicz S B: Regulatory pathways in tumor growth and invasion. *Lab Invest* 1991, 65: 262-271
142. Oosterhuis J W, Looijenga L H J: The biology of human germ cell tumours: Retrospective speculations and new prospectives. *Eur Urol* 1993, 23: 245-250

Chapter 2.2

**THE TUMOR MICROENVIRONMENT: POSSIBLE ROLE
OF INTEGRINS AND THE EXTRACELLULAR MATRIX
IN TUMOR BIOLOGICAL BEHAVIOR OF
INTRATUBULAR GERM CELL NEOPLASIA AND
TESTICULAR SEMINOMAS**

Albertus Timmer¹, J. Wolter Oosterhuis², Heimen Schraffordt Koops³, Dirk Th. Sleijfer⁴,
Ben G Szabo⁵, Wim Timens¹.

Departments of Pathology¹, Surgical Oncology³, Internal Medicine⁴ and Radiotherapy⁵,
University Hospital, Groningen. Dr. Daniel den Hoed Cancer Center², Rotterdam,
The Netherlands

ABSTRACT

In the present, study we examined the distribution of integrin subunits and extracellular matrix proteins in normal testis, intratubular germ cell neoplasia (ITGCN), and primary and metastatic seminomas. Compared to normal testis in ITGCN, Sertoli cells showed increased expression of $\alpha 3$, $\alpha 6$ and $\beta 1$ integrin subunits. Malignant intratubular germ cells stained for $\alpha 3$, $\alpha 6$, and $\beta 1$ integrin subunits. Progression of ITGCN to invasive seminoma was associated with loss of $\alpha 3$ integrin subunit expression by tumor cells. Consequent to this loss, it can be speculated that the strong expression on ITGCN may be related to the noninvasive character of the lesion as is also known from other noninvasive tumors. All tumors showed a strong expression of $\alpha 6$ and $\beta 1$ integrin subunits. The $\alpha 5$ integrin subunit was weakly expressed in primary seminomas in all stages. No differences were observed in integrin expression between primary and metastatic tumors. The distribution of extracellular matrix proteins was heterogeneous and revealed clear architectural differences between seminomas that may reflect different stages of tumor stroma formation. To our knowledge, the results presented in this study provide the first information on the possible role of tumor-extracellular matrix interactions in the biological behavior of ITGCN and testicular seminomas.

INTRODUCTION

Integrins are integral membrane proteins, involved in cell-cell and cell-matrix interactions, that play a crucial role in numerous physiological and pathological processes including embryogenesis, wound healing and biological behavior of malignant tumors. They consist of related noncovalently linked α and β chain heterodimers. The extracellular domain of integrins functions as the ligand binding site and both α and β subunits contribute to ligand binding¹⁻⁴. The cytoplasmatic domain is linked to the cytoskeleton⁵ and is supposed to generate signals essential for cell function and tissue processes¹. Receptor avidity and activity are supposed to be under control of other cell-membrane associated molecules⁶ and conversely integrins may function as co-receptors in certain cellular processes¹. The specificity of ligand binding is cell type dependent⁷.

The classification of integrins is complex (see Table 1), caused by association of several α subunits with one particular β subunit, association of one α subunit with more than one β subunit, and alternative splicing of α and β subunits^{1,8,9}. Further, individual integrins can often bind to more than one ligand, and individual ligands are recognized by more than one integrin¹⁻⁴.

The conformation-dependent recognition site for several of the integrins is the amino-acid sequence arginine-glycine-aspartic acid (RGD) present in many, but not all, extracellular matrix (ECM) proteins. Other integrins recognize different sequences in ECM proteins or bind to cellular membrane proteins involved in cell-cell interactions^{10,11}.

The ECM constitutes basement membranes (BMs) and the interstitial matrix. It is responsible for tissue integrity, and by interaction with integrin and nonintegrin receptors, ECM proteins can direct gene expression¹²⁻¹⁴ and modulate proliferation, differentiation and migration of cells¹⁵.

Malignant tumors are characterized by abnormal proliferation and differentiation¹⁶. Moreover, tissue integrity is lost by protease-activity of tumor and/or host cells, making it possible for tumor cells to invade BMs and the surrounding interstitial matrix¹⁷⁻²⁰. Compared to normal tissues, this invasion is, at least partially, due to abnormal function and expression of integrins on tumor cells²¹⁻²⁶ and qualitative and quantitative changes of the surrounding ECM^{27,28}. However, it must be emphasized that tumor cell invasion and development of metastasis is highly regulated and that the mechanisms used by tumor cells to break down mechanical barriers and migrate are analogous to the ones used by normal cells during physiological processes^{17,20}.

Intratubular germ cell neoplasia (ITGCN) of the testis represent the precursor lesion of nearly all adult testicular germ cell tumors and is found adjacent to these tumors in a high frequency²⁹⁻³¹. In untreated patients, ITGCN has been demonstrated to evolve in an invasive tumor, e.g., seminoma (SE) and/or nonseminoma³⁰.

Until now, little attention has been paid to the role of tumor-host interactions in invasion and metastasis of testicular SE. Therefore, we have analyzed the expression of integrin subunits and their ligands in the different stages of the metastatic cascade of testicular SE to determine whether the expression of integrin subunits and distribution of ECM proteins was correlated to invasion and/or development of metastases.

Table 1 The VLA-integrin family.

Receptor	CD	Other names	Mr	Ligands	Main cellular distribution
$\alpha 1\beta 1$	CD49a/CD29	VLA-1	210,130	Coll(I,IV), Ln	F,M,BM,activated T and B-ly, Mus
$\alpha 2\beta 1$	CD49b/CD29	VLA-2	170,130	Coll(I-III,IV)Ln	Pl,F,EN,Ep,activated T-Ly
$\alpha 3\beta 1$	CD49c/CD29	VLA-3	130/25,130	Coll(1),Ln,Fn,Epil	Ep,F,BM,B-ly
$\alpha 4\beta 1$	CD49d/CD29	VLA-4,LPAM2	150,130	Fn,VCAM-1,ICAM-2	M,Eo,Ly,F,NC,NK,Th
$\alpha 5\beta 1$	CD49e/CD29	VLA-5	135/25,130	Fn, Inv	Th,T-Ly,F,Ep,EN,Pl,PMN,M Mus
$\alpha 6\beta 1$	CD49f/CD29	VLA-6	120/30,130	Ln, Inv	Pl,T-ly,Ep,Th,M
$\alpha 6\beta 4$	CD49f/-	Tsp180	-	Ln	Ep

VLA, very late activation antigen; *CD*, cluster of differentiation; *Coll*, collagen; *Epil*, Epiligrin; *Fn*, fibronectin; *ICAM*, intercellular adhesion molecule; *Inv*, invasin; *Ln*, laminin; *LPAM*, lymphocyte Peyer's patch specific adhesion molecule; *Tsp*, trombospondin; *VCAM*, vascular cell adhesion molecule.

Distribution: *BM*, basement membrane associated; *EN*, endothelial cells; *Eo*, eosinophils; *Ep*, epithelial cells; *F*, fibroblasts; *Ly*, lymphocytes; *M*, monocytes/macrophages; *Mus*, muscle; *NC*, neural crest cells, melanocytes; *NK*, natural killer cells; *Pl*, platelets; *PMN*, polymorphonuclear cell (neutrophil); *Th*, thymocytes.

MATERIALS AND METHODS

Tissue. Ten histological normal testes, ten testes containing placental alkaline phosphatase positive (PLAP) intratubular germ cell neoplasia, 13 primary testicular SEs presenting in stage I (tumor confined to the testis), 12 primary testicular SEs presenting in stage II (tumor with regional lymphatic metastasis), one stage III primary testicular SE (tumor with mediastinal and/or supraclavicular metastases) and eight metastases of primary testicular SEs were included in this study. Frozen tissue was randomly selected from our files from cases in which sufficient tissue was available.

Antibodies. Rabbit antiserum directed against PLAP (catalog # A 268) was obtained from DAKO (Glostrup, Denmark). Goat antisera directed against collagen type I (catalog # 1310-01) and collagen type IV (catalog # 1340-01) were purchased from Southern Biotechnology Associates (Birmingham, UK). Rabbit antisera directed against laminin (catalog # A105), fibronectin (catalog # A101), and vitronectin (catalog # A104) and monoclonal antibodies directed against fibronectin (catalog # A002, clone II) were obtained from Telios (San Diego, USA). Details of the antibodies directed against the integrin subunits are given in Table 2. Peroxidase-conjugated second and third step antisera were obtained from DAKO.

Table 2. Anti-integrin antibodies used.

Antibody; clone; catalog #	Subunit	CD	Source/references
TS2/16	β 1	29	Springer ⁶⁴
A-1A5	β 1	29	Hemler ⁶⁵
3E1; A054	β 4		Telios, San Diego, USA ⁶⁶
TS2/7	α 1	49a	Hemler ⁶⁴
CLB Tromb/4	α 2	49b	Sonnenberg ⁶⁷
J143	α 3	49c	Old ⁶⁸
PIB5; A043	α 3	49c	Telios, San Diego, USA ⁶⁹
B5G10	α 4	49d	Hemler ⁷⁰
HP2/1	α 4	49d	Sanchez-Madrid ⁷¹
BIIG2	α 5	49e	Damsky ⁷²
PID6; A045	α 5	49e	Telios, San Diego, USA ⁶⁹
G0H3	α 6	49f	Sonnenberg ⁷³

CD, cluster of differentiation.

Immunohistochemistry. Immunohistochemistry was carried out on 4- μ m frozen tissue sections fixed in acetone for 10 minutes at room temperature. The sections were washed for 5 minutes in phosphate-buffered saline after each incubation step. The sections were incubated with optimal dilutions of the antibodies, as determined previously. To decrease nonspecific binding, the final second and third step antibody dilutions contained 1% normal human AB serum. The localization of peroxidase label was visualized using 3-amino-9-ethylcarbazol together with H₂O₂ as a reagent, giving a reddish brown

precipitate. The slides were counterstained with hematoxylin and mounted with Kaisers glycerol-gelatin (Merck, Darmstadt, Germany). Controls included sections on which the application of the primary antibody was omitted or replaced by nonrelevant antibodies.

RESULTS

Expression of integrin subunits in normal testis, ITGCN, primary SE and metastases of SE.

Normal testes, ITGCN, primary SEs and metastases of SEs showed a variable immunohistochemical expression of integrin subunits, summarized in Tables 3 and 4. The $\alpha 3$ subunit was expressed by Sertoli cells and a subset of intratubular germ cells. A remarkable feature was the localized $\alpha 6$ integrin subunit expression at the basal side of intratubular cells (Figure 1A). In atrophic tubules and ITGCN containing tubules, the expression of both subunits on Sertoli cells was increased (Figure 1A). The distribution of the $\beta 1$ subunit was concordant with the distribution of the α integrin subunits. PLAP positive malignant intratubular germ cells showed a strong nonpolarized expression of the $\alpha 3$ and $\alpha 6$ integrin subunits (Figure 1B and C). The $\beta 1$ integrin subunit was weakly expressed.

Table 3. Integrin subunit distribution in normal testes and testes with intratubular germ cell neoplasia.

Integrin subunit	$\alpha 1$	$\alpha 2$	$\alpha 3$	$\alpha 4$	$\alpha 5$	$\alpha 6$	$\beta 1$	$\beta 4$
vascular system								
endothelium	+/-	±	+	±	+	+	+	+
smooth muscle	+	-	+	-	-	-	+	-
Leydig cells	±/-	-	±/-	-	-	±/-	±	-
lamina propria	±	-	±	-	±	±	+	-
Sertoli cells	-	-	±/+ ^b	-	-	±/+ ^{b,d}	±	-
spermatogenesis	-	-	± ^c	-	-	+ ^d	+	-
ITGCN ^a	-	-	+	-	-	+	+	±/-

Expression of integrin subunits: (-), negative; (±/-), equivocal; (±), weak; (+), positive. ^a Intratubular germ cell neoplasia. ^b increased expression of the $\alpha 3$ integrin subunit on Sertoli cells in atrophic and ITGCN containing testis. ^c $\alpha 3$ integrin subunit expression on a subset of intratubular germ cells. ^d Localized $\alpha 6$ integrin subunit expression at the basal side of intratubular cells.

In primary SEs, the $\alpha 3$ (three out of 25) and $\alpha 5$ (11 out of 25) integrin subunits were weakly expressed in all stages. All tumors showed a strong expression of $\alpha 6$ (Figure 2A) and $\beta 1$ integrin subunits. No significant differences were observed in the integrin expression between primary and metastatic lesions. The expression of the $\alpha 5$ integrin subunit on metastatic SE cells is shown in Figure 2B. In one metastasis, seminoma cells

Table 4. Expression of integrin subunits in primary testicular seminomas and metastases of primary testicular seminomas.

Integrin subunit	$\alpha 1$	$\alpha 2$	$\alpha 3$	$\alpha 4$	$\alpha 5$	$\alpha 6$	$\beta 1$	$\beta 4$
SE stage I	-	-	$\pm 2/12$	-	$\pm 4/12$	$+ 12/12$	$+ 12/12$	$\pm 1-4/13$
SE stage II/III	-	-	$\pm 1/13$	-	$\pm 7/13$	$+ 12/12$	$+ 12/12$	$\pm 1-2/13$
metastases	-	-	$+ / \pm 2/8$	-	$\pm 4/8$	$+ 8/8$	$+ 8/8$	$\pm 1/8$

SE: seminoma. Expression of integrin subunits: (-), negative; (\pm /-), equivocal; (\pm), weak; (+), positive.

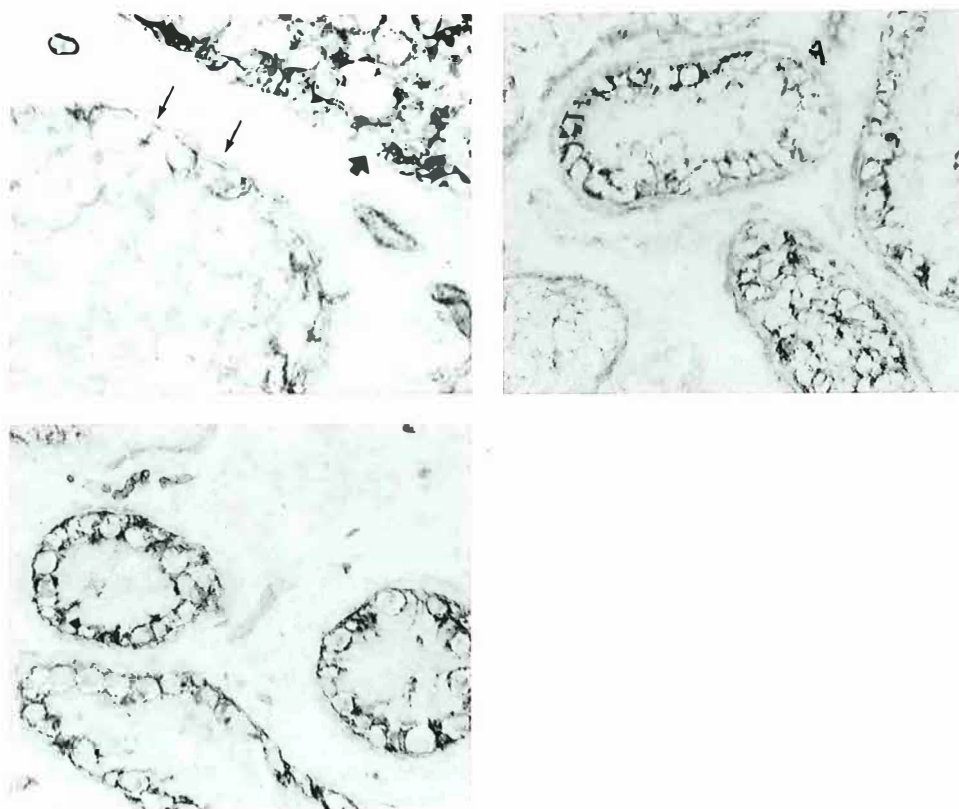


Figure 1. A, top left: Expression of the $\alpha 6$ integrin subunit in normal testis; increased expression of the $\alpha 6$ integrin subunit at the basal side of intratubular cells (small arrows); increased expression of the $\alpha 6$ integrin subunit on Sertoli cells in a atrophic tubule (large arrow) (immunoperoxidase, x 350). Nonpolarized expression of $\alpha 3$ (B, top right) and $\alpha 6$ (C, bottom left) integrin subunits on ITGCN (immunoperoxidase, x 140).

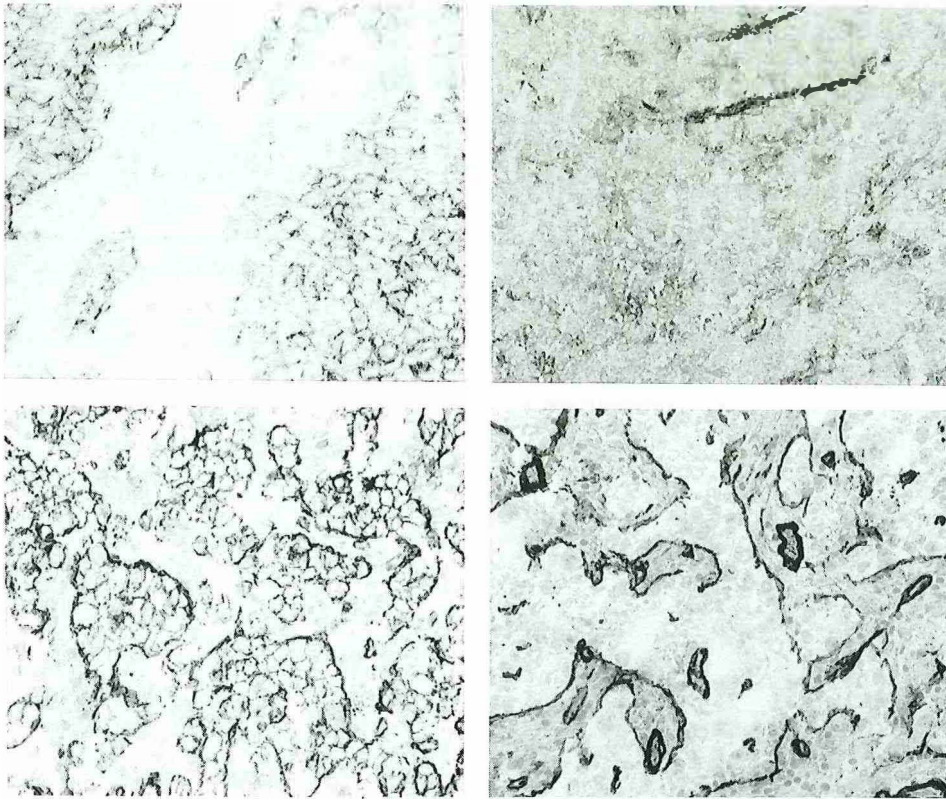


Figure 2. Nonpolarized expression of the $\alpha 6$ integrin subunit on SE cells in a primary SE (A, top left). Weak expression of the $\alpha 5$ integrin subunit on SE cells in a metastasis of a primary SE (B, top right). At the tumor-stroma border $\alpha 6$ (C, bottom left) and $\beta 4$ (D, bottom right) integrin subunits show increased expression on SE cells in a metastasis of a primary SE (immunoperoxidase, x 140).

showed expression of the $\alpha 6$, $\beta 1$, and $\beta 4$ integrin subunits with increased density at the tumor-stroma border (Figure 2C and D).

Composition of the ECM in normal testes, ITGCN, primary SE and metastases of SE.

The lamina propria and the tubular BM were composed of laminin, collagen type IV, collagen type I, fibronectin, and vitronectin. In atrophic and ITGCN containing tubules, the lamina propria and tubular BM were thickened and the BM invaginated into the tubular lumen. In some tubules, staining for ECM proteins revealed double tracking of the tubular wall (Figure 3A). Although the BM was generally thickened, local interruptions of the testicular BM were also observed (Figure 3A). Weak staining for vitronectin was seen in some tubules containing ITGCN and intratubular SE. In one case, tubular structures composed of laminin, collagen type IV, collagen type I,

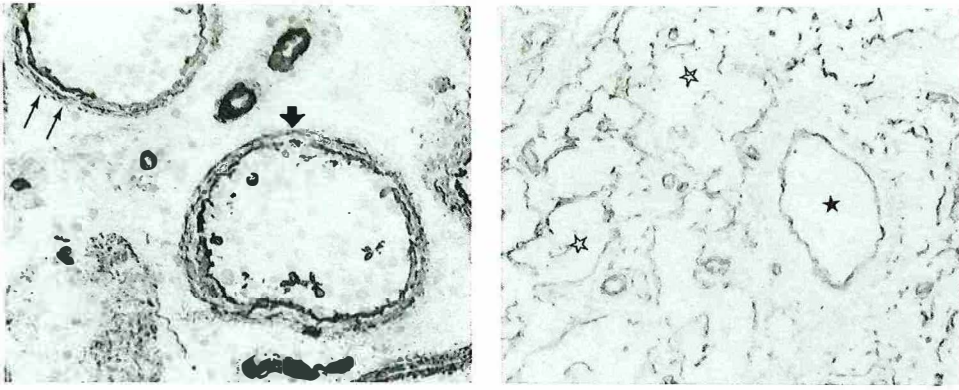


Figure 3. Distribution of laminin in ITGCN containing testis with double tracking of the tubular wall (small arrows). The BM is irregular with invaginations into the tubular lumen. Interruptions of the BM are locally present (large arrow) (A, left). Tubular structures stained for laminin in tumor nodules (open stars) adjacent to a preexistent tubule (black star) (B, right) (immunoperoxidase, x 140).

fibronectin and vitronectin were seen in tumor nodules adjacent to preexistent tubules (Figure 3B).

Based on the distribution of collagen type I, three types of stromal reaction could be recognized (Figure 4A, B and C). In two tumors the stroma was composed of relatively small fibrovascular septa, which showed a regular distribution in the tumors (stromal reaction type I). Large fibrous bands giving the tumor tissue a nodular appearance were seen in 11 tumors (stromal reaction type III). The other 13 tumors showed a stromal reaction of the intermediate type with small fibrovascular septa as well as large fibrous bands (stromal reaction type II). The differences between the three types of stromal reaction were relative but reproducible, as typing of the stromal staining pattern by two independent observers (including repeated typing with time interval) gave almost identical results.

The fibrovascular septa showed a diffuse weak staining of laminin and collagen type IV, and strong staining of collagen type I, fibronectin and vitronectin. Small band-like structures resembling basement membranes (BMs), composed of laminin, collagen type I, collagen type IV, fibronectin, and vitronectin, were randomly distributed in all primary SE. In addition to these structures, in seven SE a linear BM was present at the interface of tumor cells and stroma (Figure 5B). Codistribution of ECM proteins was not always evident (Figure 5C and D).

In metastases of SE the composition of the ECM was similar to that in primary SE. All but one metastases showed a type III stromal reaction. In one metastasis, tumor cells were separated from the stroma by a linear BM, whereas in the other seven metastases the distribution of BMs was similar to that found in primary SE.

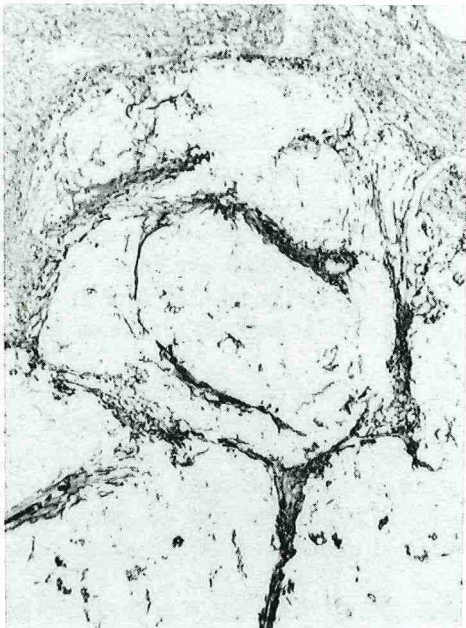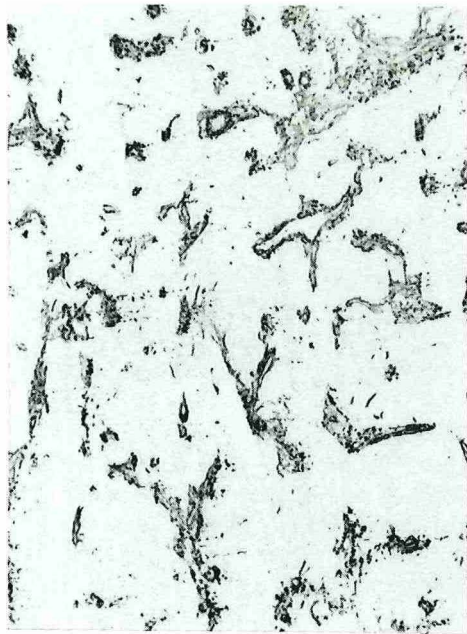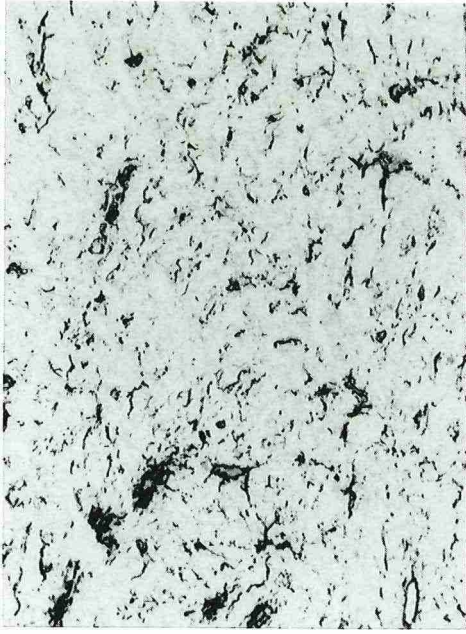


Figure 4. Three types of stromal reaction shown by the distribution of collagen type I. Stromal reaction type I: small fibrovascular septa regularly distributed (A, top left); stromal reaction type II: small fibrovascular septa and large fibrous bands (B, top right); stromal reaction type III: large fibrous bands giving the tumor an nodular appearance (C, bottom left) (immunoperoxidase, x 35).

DISCUSSION

Invasive growth and the development of metastasis is dependent on a repeated sequence of events, first described by Liotta as the three-step hypothesis of invasion¹⁷⁻¹⁹. The first step comprises the adhesion of tumor cells to BMs, mediated by integrin and nonintegrin receptors. This adhesion elicits proteinase mediated degradation of BM components like laminin and collagen type IV at the leading edge of tumor cells. Locomotion of tumor cells through the localized zone of BM-lysis is the final step. This multistep process is highly regulated, and the outcome in invasive tumors is the result of an imbalance between positive and negative regulatory factors, which are operative in physiological processes as well^{17,20}.

It is evident that the interaction of tumor cells with ECM proteins, mediated in part via integrins, plays a crucial role in biological behavior of malignant tumors. Experimental studies with $\alpha 5\beta 1$ integrin receptor deficient or overexpressing variants of Chinese hamster ovary cells, and human rhabdomyosarcoma cells transfected with DNA coding for the $\alpha 2$ integrin subunit suggest that changes in integrin expression explain, at least in part, some of the characteristics of transformed cells, including their migratory, invasive and metastatic behavior²³⁻²⁶.

Although not consistently and dependent on the cell type, malignant cells often express an altered pattern of integrins compared with their nontumorigenic benign counterparts³³⁻³⁵. Furthermore (in contrast to an often localized pattern on the membrane of normal cells), in malignancy, integrins are diffusely distributed over the cell surface^{23,36}, and their function is supposed to be changed^{24,37}. The expression of integrin subunits on intratubular germ cells, malignant intratubular germ cells, and invasive SEs is concordant with these observations. Progression of ITGCN to invasive SE is associated with loss of $\alpha 3$ integrin subunit expression. Because invasive SE cells show no or weak expression of the $\alpha 3$ integrin subunit, the strong expression on ITGCN may be related to the noninvasive character of the lesion. Similarly, a high expression of $\alpha 2$ and $\alpha 3$ integrin subunits has been suggested to account for the indolent nature of basal cell carcinoma³⁸.

The $\alpha 5\beta 1$ and $\alpha 6\beta 1$ integrin receptors function as receptors for fibronectin^{39,40} and laminin⁴¹, respectively. The nonpolarized expression of these integrin subunits in invasive primary and metastatic SE is compatible with previous studies, suggesting a prominent role for adhesion of tumor cells to fibronectin and laminin in invasion and metastasis^{19,23-25,42-44}. Whereas the $\alpha 6\beta 1$ integrin receptor is implicated in promoting invasion of tumor cells⁴³, transfection studies with Chinese hamster ovary cells rather point to a suppressor role of the $\alpha 5\beta 1$ integrin receptor in invasion and metastasis^{24,45}. Future studies, especially those with SE cell lines, will have to elucidate the function of $\alpha 5$, $\alpha 6$, and $\beta 1$ integrin subunits on SE cells and reveal if the mechanisms used to survive, proliferate, and migrate are analogous to the ones used by their nontumorigenic precursors and counterparts, eg., primordial germ cells and gonocytes, respectively.

Invasion of tumor cells is not only dependent on changes in the expression or function of integrins, but also on qualitative and quantitative changes in the composition of the ECM^{27,28}. Regulated degradation of ECM proteins at the leading edge of invasive tumor cells is the result of a local imbalance of proteolytic enzymes and their inhibitors and is a prerequisite for invasion^{17,20}. In an ultrastructural study describing ITGCN, Schulze found intact tubular BMs⁴⁶. However, similar as in invasion of other malignant tumors, BM degradation probably is a step in invasion of malignant intratubular germ

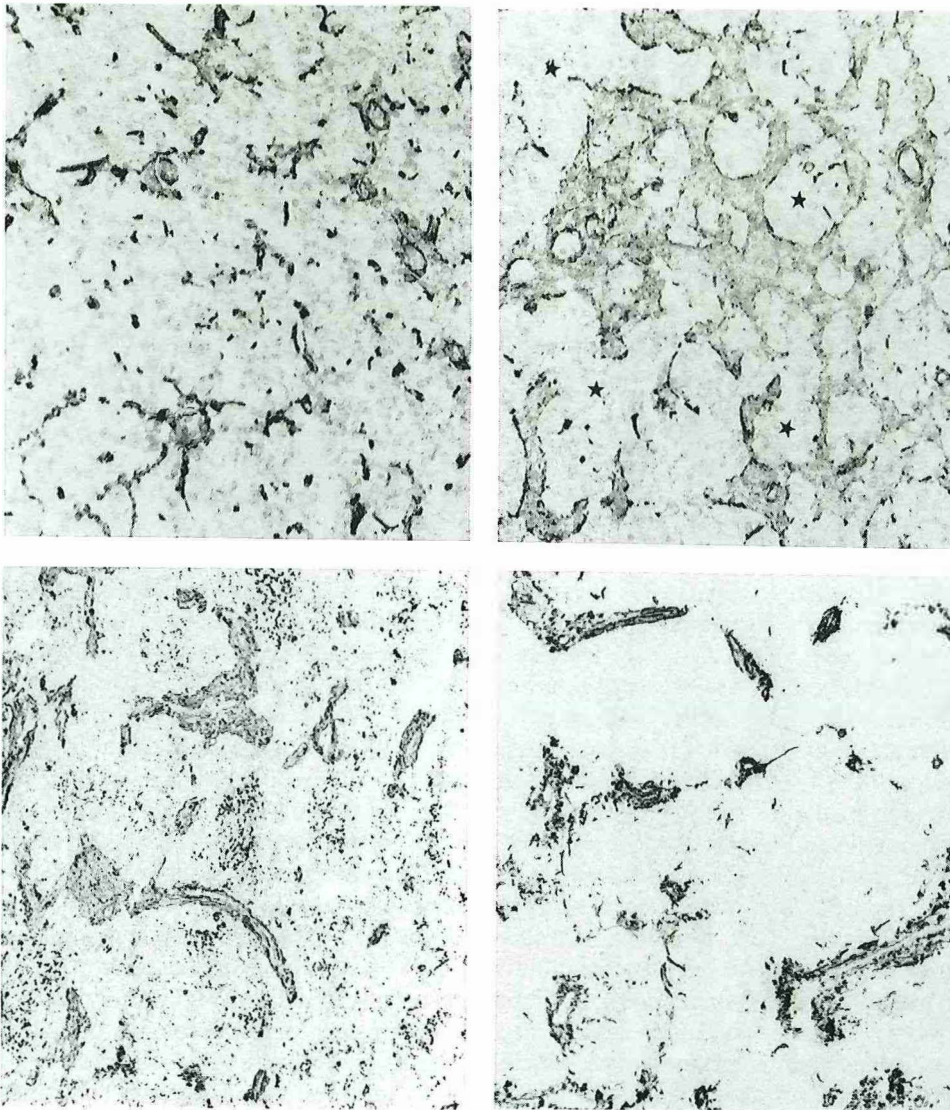


Figure 5. A, top left: Randomly distributed small band-like structures stained for collagen type IV in a primary SE. B, top right: Fibrovascular septa and SE cells (indicated by stars) separated by a linear BM as revealed by staining for collagen type IV in a primary SE (immunoperoxidase, x 140). The distribution of vitronectin (C, bottom left) is more extensive than collagen type I in the same primary tumor (D, bottom right) (immunoperoxidase, x 56).

cells, as microinvasive SE with destruction of the tubular wall has been reported ³², whereas in our study in ITGCN, the tubular BM revealed gaps besides thickened and irregular parts. Changes involving increased ECM production in tubules containing ITGCN may in fact be related to a dysregulation of testicular homeostasis, rather than to

the presence of malignant intratubular germ cells per se, as cryptorchid testes⁴⁷ and testes with Sertoli cell only syndrome⁴⁸ reveal the same tubular abnormalities, including double tracking and thickening of the lamina propria and tubular BM. The BM-like structures diffusely distributed in invasive SE may well represent tubular remnants, not degraded by proteolytic enzymes. However, as Schulze suggested, BM-like structures in invasive SE may as well be newly deposited⁴⁶, as illustrated by the linear distribution of BM proteins at the interface of SE cells and stroma. This deposition is ineffective because BMs in malignant tumors, including testicular SEs, often reveal (ultrastructural) abnormalities⁴⁹⁻⁵². Whatever the origin of these structures and analogous to the adhesion of Sertoli cells and spermatogenic cells to the tubular BM⁵³, adhesion of SE cells to BM structures and/or the interstitial matrix may hamper their migration and bear on the development of metastasis.

It is supposed that after tumor cells have invaded the surrounding tissue, they elicit the formation of a primitive stroma. This stroma consists of plasma derived cross-linked fibrin and fibronectin⁵⁴⁻⁵⁶. Like fibronectin, vitronectin is found in the circulation and might be trapped in the fibrin-fibronectin gel as well⁵⁷. The fibrin-fibronectin gel serves as a provisional matrix that facilitates and regulates influx of endothelial cells, fibroblasts, and other host cells^{56,58}. Subsequently, by deposition of tumor or host cell derived collagen type III and I, the provisional matrix is replaced by mature stroma⁵⁴⁻⁵⁶.

In SEs, the mature stroma, composed of collagen type I, fibronectin and vitronectin, was differentially distributed between different tumors; three types of stromal reaction could be recognized. Since differences between the three types of stromal reaction were partly relative, they may represent different stages in the ongoing process of fibrovascular stroma formation. In this context, the tumors with a nodular appearance (type III stromal reaction) are supposed to represent the more progressed seminomas⁵⁹.

It is evident that the stroma functions as a mechanical scaffold that defines tissue boundaries. However, by modulating cell function, the stroma may have also an active role in numerous physiological and pathological processes^{51,60}. As constituents of the stroma, fibroblasts⁶¹, ECM proteins⁶² and lymphocytes⁶³ have been reported to modulate tumor cell function, including proliferation. The coincident finding of low proliferative activity and fibrotic tissue in SE is in line with this observation⁵⁹.

The results presented in this study provide information on the possible role of tumor-ECM interactions in the biological behavior of ITGCN and testicular SE. More specifically, our results demonstrate that SE are heterogeneous with respect to integrin subunit expression and composition of the ECM. Moreover, the dynamic interplay between tumor cells and their surrounding interstitial matrix is illustrated. It is evident that further studies will have to be undertaken to determine the significance of our observations with respect to tumor growth, invasion and metastasis.

Acknowledgements

Monoclonal antibodies TS2/16 and TS2/7 were kindly provided by Dr. TA Springer (Center for Blood Research, Harvard Medical School, Boston, MA), CLB Thromb/4 and G0H3 by Dr. A Sonnenberg (CLB, Amsterdam, The Netherlands), J143 by Dr. LJ Old (Memorial Sloan-Kettering Cancer Center, New York, NY), A-1A5 and

B5G10 by Dr. ME Hemler (Dana-Farber Cancer Institute, Harvard Medical School, Boston, MA), HP2/1 by Dr. F Sánchez-Madrid (Seccion De Inmunologia, Hospital de la Princesa, Madrid, Spain) and BIIG2 by Dr. C Damsky (University of California, San Francisco, CA). Thanks are due to the Departments of Surgical Oncology, Clinical Oncology, and Radiotherapy for their cooperation, to Ms. Alie Krikken and Mr. Mark Coenen for technical assistance, and Mr. Hilbrand Wierenga for help in the preparation of the microphotographs.

This study was supported by the Dutch Cancer Society Grant GUKC 88-11 and the J.K. De Cock Foundation Groningen.

REFERENCES

1. Hynes R O: Integrins: Versatility, modulation, and signaling in cell adhesion. *Cell* 1992, 69: 11-25.
2. Hemler M E: VLA proteins in the integrin family: structures, functions, and their role on leukocytes. *Annu Rev Immunol* 1990, 8: 365-400.
3. Hynes R O: Integrins: a family of cell surface receptors. *Cell* 1987, 48: 549-554.
4. Ruoslahti E, Pierschbacher M D: New perspectives in cell adhesion: RGD and integrins. *Science* 1987, 238: 491-497.
5. Burridge K, Fath K, Nuckolls G, Turner C: Focal adhesions: transmembrane junctions between the extracellular matrix and the cytoskeleton. *Ann Rev Cell Biol* 1988, 4: 487-525.
6. Pignatelli M, Durbin H, Bodmer W F: Carcinoembryonic antigen functions as an accessory adhesion molecule mediating colon epithelial cell collagen interactions. *Proc Natl Acad Sci USA* 1990, 87: 1541-1545.
7. Hemler M E, Elices M J, Chan B M C, Zetter B, Matsuura N, Takada Y: Multiple ligand binding functions for VLA-2 ($\alpha 2\beta 1$) and VLA-3 ($\alpha 3\beta 1$) in the integrin family. *Cell Diff and Develop* 1990, 32: 229-238.
8. Languino L R, Ruoslahti E: An alternative form of the integrin $\beta 1$ subunit with a variant cytoplasmic domain. *J Biol Chem* 1992, 267: 7116-7120.
9. Tamura R N, Cooper H M, Collo G, Quaranta V: Cell type-specific integrin variants with alternative α chain cytoplasmatic domains. *Dev Biol* 1991, 88: 10183-10187.
10. Humphries M J: Peptide recognition motifs involved in the binding of integrins to their ligands. *Kidney Int* 1992, 41: 645-649.
11. Yamada Y, Kleinman H K: Functional domains of cell adhesion molecules. *Curr Opin Cell Biol* 1992, 4: 819-823.
12. Werb Z, Tremble P M, Behrendtsen O, Crowley E, Damsky C H: Signal transduction through the fibronectin receptor induces collagenase and stromelysin gene expression. *J Cell Biol* 1989, 109: 877-889.

13. Juliano R L, Haskill S: Signal transduction from the extracellular matrix. *J Cell Biol* 1993, 120: 577-585.
14. Streuli C H, Schmidhauser C, Kobrin M, Bissell M J, Derynck R: Extracellular matrix regulates expression of the TGF- β 1 gene. *J Cell Biol* 1993, 120: 253-260.
15. Bissell M J, Hall H G, Parry G: How does the extracellular matrix direct gene expression? *J Theor Biol* 1982, 99: 31-68.
16. Cross M, Dexter T M: Growth factors in development, transformation, and tumorigenesis. *Cell* 1991, 64: 271-280.
17. Liotta L A, Steeg P S, Stetler-Stevenson W G: Cancer metastasis and angiogenesis: an imbalance of positive and negative regulation. *Cell* 1991, 64: 327-336.
18. Liotta L A, Rao C N, Barsky H: Tumor invasion and the extracellular matrix. *Lab Invest* 1983, 49: 636-649.
19. Liotta L A: Tumor invasion and metastases-role of the extracellular matrix. *Cancer Res* 1986, 46: 1-7.
20. Herlyn M, Malkowicz S B: Regulatory pathways in tumor growth and invasion. *Lab Invest* 1991, 65: 262-271.
21. Juliano R L: Membrane receptors for extracellular matrix molecules: relationship to cell adhesion and tumor metastasis. *Biochim Biophys Acta* 1987, 907: 261-278.
22. Cassiman J J: The involvement of the cell matrix receptors, or VLA integrins, in the morphogenetic behaviour of normal and malignant cells is gradually being uncovered. *Cancer Genet Cytogenet* 1989, 41: 19-32.
23. Schreiner C, Fisher M, Hussein S, Juliano R L: Increased tumorigenicity of fibronectin receptor deficient Chinese hamster ovary cell variants. *Cancer Res* 1991, 51: 1738-1740.
24. Giancotti F G, Ruoslahti E: Elevated levels of the alpha 5 beta 1 fibronectin receptor suppress the transformed phenotype of Chinese hamster ovary cells. *Cell* 1990, 60: 849-859.
25. Bauer J S, Schreiner C L, Giancotti F G, Ruoslahti E, Juliano R L: Motility of fibronectin receptor-deficient cells on fibronectin and vitronectin: Collaborative interactions among integrins. *J Cell Biol* 1992, 116: 477-487.
26. Chan B M C, Matsuura N, Takada Y, Zetter B R, Hemler M E: In vitro and in vivo consequences of VLA-2 expression on rhabdomyosarcoma cells. *Science* 1991, 151: 1600-1602.
27. Iozzo R V: Proteoglycans: structure, function, and role in neoplasia. *Lab Invest* 1985, 53: 373-396.
28. Pauli B U, Knudson W: Tumor invasion: a consequence of destructive and compositional matrix alterations. *Hum Pathol* 1988, 19: 628-639.

29. Skakkebæk N E, Berthelsen J G, Giwercman A, Müller J: Carcinoma in situ of the testis: possible origin from gonocytes and precursor of all types of germ cell tumours except spermatocytoma. *Int J Androl* 1987, 10: 19-27.
30. Jørgensen N, Müller J, Giwercman A, Skakkebæk N E: Clinical and biological significance of carcinoma in situ of the testis. *Cancer Surv* 1990, 9: 287-301.
31. Jacobsen G K, Henriksen O B, v der Maase H: Carcinoma in situ of testicular tissue adjacent to malignant germ-cell tumors: a study of 105 cases. *Cancer* 1981, 47: 2660-2662.
32. Mikulowski P, Oldbring J: Microinvasive germ cell neoplasia of the testis. *Cancer* 1992; 70: 659-664.
33. Dedhar S, Saulnier R: Alterations in integrin receptor expression on chemically transformed human cells: specific enhancement of laminin and collagen receptor complexes. *J Cell Biol* 1990, 110: 481-489.
34. Plantefaber L C, Hynes R O: Changes in integrin receptors on oncogenetically transformed cells. *Cell* 1989, 56: 281-290.
35. Albelda S M: Role of integrins and other cell adhesion molecules in tumor progression and metastasis. *Lab Invest* 1993, 68: 4-17.
36. Kimmel K A, Carey T E: Altered expression in squamous carcinoma cells of an orientation restricted epithelial antigen detected by monoclonal antibody A9. *Cancer Res* 1986, 46: 3614-3623.
37. Hirst R, Horwitz A, Buck C, Rohrschneider L: Phosphorylation of the fibronectin receptor complex in cells transformed by oncogenes that encode tyrosine kinases. *Proc Natl Acad Sci USA* 1986, 83: 6470-6474.
38. Stamp G W H, Pignatelli M: Distribution of $\beta 1$, $\alpha 1$, $\alpha 2$ and $\alpha 3$ integrin chains in basal cell carcinomas. *J Pathol* 1991, 163: 307-313.
39. Argraves W S, Suzuki S, Arai H, Thompson K, Pierschbacher M D, Ruoslahti E: Amino acid sequence of the human fibronectin receptor. *J Cell Biol* 1987, 105: 1183-1190.
40. Pytela R, Pierschbacher M D, Ruoslahti E: Identification and isolation of a 140 kd cell surface glycoprotein with properties expected of a fibronectin receptor. *Cell* 1985, 40: 191-198.
41. Sonnenberg A, Modderman P W, Hogervorst F: Laminin receptor on platelets is the integrin VLA-6. *Nature* 1988, 336: 487-489.
42. McCarthy J B, Skubitz A P N, Palm S L: Metastasis inhibition of different tumor types by purified laminin fragments and a heparin-binding fragment of fibronectin. *J Natl Cancer Inst* 1988, 80: 108-116.
43. Honn K V, Tang D G: Adhesion molecules and tumor cell interaction with endothelium and subendothelial matrix. *Cancer Metastasis Rev* 1992, 11: 353-375.

44. Pignatelli M, Rosaria Cardillo M, Hanby A, Stamp G W H: Integrins and their accessory adhesion molecules in mammary carcinomas: Loss of polarization in poorly differentiated tumors. *Hum Pathol* 1992, 23: 1159-1166.
45. Schwartz M A: Signaling by integrins: Implications for tumorigenesis. *Cancer Res* 1993, 53: 1503-1506.
46. Schulze C, Holstein A F: On the histology of human seminoma. Development of the solid tumor from intratubular seminoma cells. *Cancer* 1977, 39: 1090-1100.
47. Santamaria L, Martinez-Onsurbe P, Paniagua R, Nistal M: Laminin, type IV collagen, and fibronectin in normal and cryptorchid human testes. *Int J Androl* 1990, 13: 135-146.
48. Pollanen P P, Kallajoki M, Risteli L, Risteli J, Suominen J J: Laminin and type IV collagen in the human testis. *Int J Androl* 1985, 8: 337-347.
49. Barsky S H, Siegal G P, Jannotta F, Liotta L A: Loss of basement membrane components by invasive tumors but not by their benign counterparts. *Lab Invest* 1983, 49: 140-147.
50. Pierce G B: Ultrastructure of human testicular tumors. *Cancer* 1966, 19: 1963-1983.
51. Bosman F T, Havenith M G, Visser R, Cleutjens J P M: Basement membranes in neoplasia. *Progr Histochem Cytochem* 1992, 24: 1-92.
52. Havenith M G, Dingemans K P, Cleutjens J P M, Wagenaar S S, Bosman F T: Basement membranes in bronchogenic squamous cell carcinoma: an immunohistochemical and ultrastructural study. *Ultrastruc Pathol* 1990, 14: 51-63.
53. Enders G C, Henson J H, Millette C F: Sertoli cell binding to isolated testicular basement membrane. *J Cell Biol* 1986, 103: 1109-1119.
54. Dvorak H F: Tumors: wounds that do not heal. Similarities between tumor stroma generation and wound healing. *N Engl J Med* 1986, 315: 1650-1659.
55. Dvorak H F, Form D M, Manseau E J, Smith B D: Pathogenesis of desmoplasia. I. Immunofluorescence identification and localization of some structural proteins of line 1 and line 10 guinea pig tumors and of healing wounds. *J Natl Cancer Inst* 1984, 73: 1195-1205.
56. Nagy J A, Brown L F, Senger D R, Lanir N, Van de Water L, Dvorak A M, Dvorak H F: Pathogenesis of tumor stroma generation: a critical role for leaky blood vessels and fibrin deposition. *Biochim Biophys Acta* 1989, 948: 305-326.
57. Tomasini B R, Mosher D F: Vitronectin. *Prog Hemost Thromb* 1991, 10: 269-305.
58. Brown L F, Lanir N, McDonagh J, Tognazzi K, Dvorak A M, Dvorak H F: Fibroblast migration in fibrin gel matrices. *Am J Pathol* 1993, 142: 273-283.
59. Rabes H M, Schmeller N, Hartmann A, Rattenhuber U, Carl P, Staehler G: Analysis of proliferative compartments in human tumors. II. Seminoma. *Cancer* 1985, 55: 1758-1769.

60. van den Hooff A: Stromal involvement in malignant growth. *Adv Cancer Res* 1988, 50: 159-196.
61. Cornil I, Theodorescu D, Man S, Herlyn M, Jambrosic J: Fibroblast cell interactions with human melanoma cells affect tumor cell growth as a function of tumor progression. *Proc Natl Acad Sci USA* 1991, 88: 6028-6032.
62. Cooper S, Pera M F: Vitronectin production by human yolk sac carcinoma cells resembling parietal endoderm. *Development* 1988, 104: 565-574.
63. Fidler I J: In vitro studies of cellular-mediated immunostimulation of growth. *J Natl Cancer Inst* 1973, 50: 1307-1312.
64. Hemler M E, Sanchez-Madrid F, Flotte T J, Krensky A M, Burakoff S J, Bhan A K, Springer T A, Strominger J L: Glycoproteins of 210,000 and 130,000 m.w. on activated T cells: cell distribution and antigenic relation to components on resting cells and T cell lines. *J Immunol* 1984, 132: 3011-3018.
65. Hemler M E, Ware C F, Strominger J L: Characterization of a novel differentiation antigen complex recognize by a monoclonal antibody (A-1A5): unique activation-specific molecular forms on stimulated T cells. *J Immunol* 1983, 131: 334-340.
66. Hesse H, Sakai L Y, Hollister D W, Burgeson R E, Engvall E: Basement membrane diversity detected by monoclonal antibodies. *Differentiation* 1984, 26: 49-54.
67. Giltay J C, Brinkman H J, Modderman P W, von den Borne A E, van Mourik J A: Human vascular endothelial cells express a membrane protein complex immunochemically indistinguishable from the platelet VLA-2 (glycoprotein Ia-IIa) complex. *Blood* 1989, 73: 1235-1241.
68. Fradet Y, Cordon-Cardo C, Thomson T, Daly M E, Whitmore W F, Jr., Lloyd K O, Melamed M R, Old L J: Cell surface antigens of human bladder cancer defined by mouse monoclonal antibodies. *Proc Natl Acad Sci U S A* 1984, 81: 224-228.
69. Wayner E A, Carter W G, Piotrowicz R S, Kunicki T J: The function of multiple extracellular matrix receptors in mediating cell adhesion to extracellular matrix: preparation of monoclonal antibodies to the fibronectin receptor that specifically inhibit cell adhesion to fibronectin and react with platelet glycoproteins Ic-IIa. *J Cell Biol* 1988, 107: 1881-1891.
70. Hemler M E, Huang C, Takada Y, Schwarz L, Strominger J L, Clabby M L: Characterization of the cell surface heterodimer VLA-4 and related peptides. *J Biol Chem* 1987, 262: 11478-11485.
71. Sanchez-Madrid F, De Landazuri M O, Morago G, Cebrian M, Acevedo A, Bernabeu C: VLA-3: a novel polypeptide association within the VLA molecular complex: cell distribution and biochemical characterization. *Eur J Immunol* 1986, 16: 1343-1349.
72. Brown D L, Phillips D R, Damsky C H, Charo I F: Synthesis and expression of the fibroblast fibronectin receptor in human monocytes. *J Clin Invest* 1989, 84: 366-370.

73. Sonnenberg A, Janssen H, Hogervorst F, Calafat J, Hilgers J: A complex of platelet glycoproteins Ic and IIa identified by a rat monoclonal antibody. *J Biol Chem* 1987, 262: 10376-10383.

Chapter 2.3

INTEGRIN SUBUNITS AND EXTRACELLULAR MATRIX PROTEINS IN TESTICULAR NONSEMINOMAS

Albertus Timmer¹, J. Wolter Oosterhuis², Heimen Schraffordt Koops³, Dirk Th Sleijfer⁴,
Elisabeth G.E. de Vries⁴, Wim Timens¹

Departments of Pathology¹, Surgical Oncology³ and Internal Medicine⁴, University Hospital,
Groningen. Dr. Daniel den Hoed Cancer Center², Rotterdam, The Netherlands

ABSTRACT

In the present study the composition of the extracellular matrix (ECM) and the distribution of integrin subunits was studied by immunohistochemistry in different components of 34 testicular nonseminomas (NS) to determine whether the composition of ECM and distribution of integrin subunits was correlated to differentiation into the embryonal (embryonal carcinoma: EC; teratoma: TE) or extraembryonal (yolk sac tumor: YST; choriocarcinoma: CH) direction. EC demonstrated variable expression of $\alpha 1$, $\alpha 2$, $\alpha 3$, $\alpha 5$, $\alpha 6$, $\beta 1$ and $\beta 4$ integrin subunits. The different tissues in TE demonstrated characteristic integrin profiles (epithelia: $\alpha 1$), $\alpha 2$, $\alpha 3$, ($\alpha 5$), $\alpha 6$, $\beta 1$, $\beta 4$; cartilage: $\alpha 3$, $\alpha 5$, $\alpha 6$, $\beta 1$; smooth muscle: $\alpha 1$, $\alpha 3$, $\alpha 5$, $\alpha 6$, $\beta 1$). YST showed expression of $\alpha 3$, $\alpha 5$, $\alpha 6$ and $\beta 1$ integrin subunits. In CH integrin subunits were heterogeneously expressed. Subpopulations of cytotrophoblastic cells (CTC) could be identified by their integrin profile. CTC were characterized by $\beta 4$ integrin subunit expression, not present on syncytiotrophoblastic giant cells. The differences in distribution of ECM proteins between EC, TE, YST and CH were relative. In conclusion, our study demonstrates the heterogeneity of testicular nonseminomas with respect to integrin subunit expression and composition of the ECM suggestive to be related to differentiation and biological behavior. Future studies will have to further elucidate the relationship of this heterogeneity to differentiation lineage, tumor progression or both.

INTRODUCTION

Integrins are integral membrane proteins that mediate cell-cell as well as cell-matrix interactions. These proteins consist of related non-covalently linked α and β chain heterodimers and are divided into at least eight subfamilies, each defined by a common β subunit. The extracellular domain of integrins functions as the ligand binding site and both α and β subunits contribute to ligand binding. The cytoplasmatic domain is linked to the cytoskeleton and is supposed to generate signals essential for cell function and tissue processes ^{1,2}. The complexity of the integrin family is enormous, due to promiscuity of α and β chains to associate with more than one subunit ¹, alternative splicing of cytoplasmatic domains ³, redundancies in their ligand binding preferences ¹, and the existence of multiple affinity states for many integrins ⁴. Integrins are supposed to be under control of other cell-membrane associated molecules and vice versa integrins may function as co-receptors in certain cellular processes ^{1,5}. It is supposed that changes in integrins, triggered by ligand binding, activate cellular signal transduction pathways, and induce rearrangement of the cytoskeletal network leading to changes in gene expression that are essential to cell survival, proliferation, differentiation and migration ⁶⁻⁸.

The process of tumor cell invasion and metastasis is highly complex and composed of a sequence of events of which adhesion to and penetration of epithelial basement membranes (BMs) is one of the most important. It is supposed that transition from the in situ to the invasive stage is achieved by loosening cell-cell and cell-matrix contacts and degradation of BM components like laminin and collagen type IV by tumor and/or host cell derived proteinases at the leading edge of tumor cells ⁹⁻¹¹. Vice versa, by binding to tumor cells (partially degraded) ECM proteins can modulate the secretion of proteolytic enzymes ¹², stimulate chemotaxis and haptotaxis of tumor cells ¹³, and modulate the expression of their own receptors ¹⁴, thereby stimulating the invasive process. The final step is the integrin mediated locomotion of tumor cells through the zone of BM lysis that may be regulated by tumor cell derived cytokines and/or host organ-derived chemoattractants ¹¹. Once tumor cells have invaded the surrounding tissue they elicit the formation of a primitive stroma that subsequently is replaced by mature stroma ^{15,16}.

Intratubular germ cell neoplasia (ITGCN) is the precursor lesion of nearly all testicular germ cell tumors (TGCTs) and is found adjacent to these tumors in a high frequency ¹⁷⁻¹⁹. In untreated patients ITGCN has been demonstrated to evolve in a invasive tumor eg. seminoma (SE) and/or nonseminoma (NS) ¹⁸. In a previous study the transition from noninvasive ITGCN to invasive SE was found to be accompanied by loss of $\alpha 3$ integrin subunit expression, whereas the $\alpha 5$ integrin was de novo expressed in 11 out of 25 primary SE studied. Moreover, the ECM demonstrated significant differences between SE that might be related to biological behavior ²⁰. In testicular nonseminomas (NS) expression of integrin subunits has not yet been studied, whereas data on the distribution of ECM proteins and their relevance to tumor biological behavior are rather scarce ²¹⁻²⁴. To extend previous studies, in the present study we analyzed the expression of integrin subunits and distribution of ECM proteins in testicular NS and discuss the results in relation to differentiation and tumor biological behavior.

MATERIALS AND METHODS

Tissue. Thirty-four testicular NS composed of different histological subtypes were included in this study. The histological composition of the tumors is given in Table 1. Frozen tissue was randomly selected from our files from cases of which sufficient material was available.

Table 1. Histology of testicular germ cell tumors and components used.

histological composition	number
EC	7
TE	4
YST	3
EC+SE	4
EC+TE	3
EC+YST	2
TE+YST	1
TE+CH	1
EC+TE+YST	4
EC+TE+CH	1
EC+YST+CH	1
EC+TE+YST+CH	2
SE+EC+TE+YST+CH	1
	34

SE, seminoma. EC, embryonal carcinoma. TE, teratoma. YST, yolk sac tumor. CH, choriocarcinoma.

Antibodies. Goat antisera directed against collagen type I (catalog # 1310-01) and collagen type IV (catalog # 1340-01) were purchased from Southern Biotechnology Associates (Birmingham, UK). Rabbit antisera directed against laminin (catalog # A105), and fibronectin (catalog # A101) were obtained from Telios (San Diego, USA). Details on the antibodies directed against the integrin subunits are given in Tables 2 and 3^{25,26}. Peroxidase-conjugated second and third step antisera were obtained from DAKO (Glostrup, Denmark).

Immunohistochemistry. Immunohistochemistry was carried out on 4 μ m frozen tissue sections fixed in acetone for 10 minutes at room temperature. The sections were washed for 5 minutes in phosphate-buffered saline after each incubation step. The sections were incubated with optimal dilutions of the antibodies, as determined previously. To decrease non-specific binding the final second and third step antibody dilutions contained 1% normal human AB serum. The localization of peroxidase label was visualized using 3-amino-9-ethylcarbazol together with H₂O₂ as a reagent giving a reddish brown precipitate. The slides were counterstained with hematoxylin and mounted with Kaisers glycerol-gelatin (Merck, Darmstadt, Germany). Controls included sections on which the application of the primary antibody was omitted or replaced by non-relevant antibodies.

Table 2. The $\beta 1$ and $\beta 4$ integrin family.

Receptor	CD	Other names	Mr	Ligands	Main cellular distribution
$\alpha 1\beta 1$	CD49a/CD29	VLA-1	210,130	Coll(I,IV), Ln	F,M,BM,activated T and B-ly, Mus
$\alpha 2\beta 1$	CD49b/CD29	VLA-2	170,130	Coll(I-III,IV)Ln	Pl,F,EN,Ep,activated T-Ly
$\alpha 3\beta 1$	CD49c/CD29	VLA-3	130/25,130	Coll(1),Ln,Fn,Epil	Ep,F,BM,B-ly
$\alpha 4\beta 1$	CD49d/CD29	VLA-4,LPAM2	150,130	Fn,VCAM-1,ICAM-2	M,Eo,Ly,F,NC,NK,Th
$\alpha 5\beta 1$	CD49e/CD29	VLA-5	135/25,130	Fn, Inv	Th,T-Ly,F,Ep,EN,PL,PMN,M Mus
$\alpha 6\beta 1$	CD49f/CD29	VLA-6	120/30,130	Ln, Inv	Pl,T-ly,Ep,Th,M
$\alpha 7\beta 1$	-/CD29	VLA-7	100,130	Ln	Mus
$\alpha 8\beta 1$	-/CD29	VLA-8	160	?	?
$\alpha v\beta 1$	CD51/CD29	altFnR	125/24,130	Fn	NC,F
$\alpha 6\beta 4$	CD49f/CD104	Tsp180	120-130, 210	Ln	Ep

VLA, very late activation antigen; *CD*, cluster of differentiation; *Coll*, collagen; *Epil*, Epiligrin; *Fn*, fibronectin; *ICAM*, intercellular adhesion molecule; *Inv*, invasin; *Ln*, laminin; *LPAM*, lymphocyte Peyer's patch specific adhesion molecule; *Tsp*, trombospondin; *VCAM*, vascular cell adhesion molecule.

Distribution: *BM*, basement membrane associated; *EN*, endothelial cells; *Eo*, eosinophils; *Ep*, epithelial cells; *F*, fibroblasts; *Ly*, lymphocytes; *M*, monocytes/macrophages; *Mus*, muscle; *NC*, neural crest cells, melanocytes; *NK*, natural killer cells; *PL*, platelets; *PMN*, polymorphonuclear cell (neutrophil); *Th*, thymocytes.

Table 3. Anti-integrin antibodies used.

Antibody clone; catalog #	subunit	CD	source
TS2/16	$\beta 1$	29	Springer
A-1A5	$\beta 1$	29	Hemler
3E1; A054	$\beta 4$	104	Telios, San Diego, USA
TS2/7	$\alpha 1$	49a	Hemler
CLB Tromb/4	$\alpha 2$	49b	Sonnenberg
J143	$\alpha 3$	49c	Old
P1B5; A043	$\alpha 3$	49c	Telios, San Diego, USA
B5G10	$\alpha 4$	49d	Hemler
HP2/1	$\alpha 4$	49d	Sanchez-Madrid
BIIG2	$\alpha 5$	49e	Damsky
P1D6; A045	$\alpha 5$	49e	Telios, San Diego, USA
G0H3	$\alpha 6$	49f	Sonnenberg

CD, cluster of differentiation.

RESULTS

Expression of integrin subunits

Details on the distribution of integrin subunits in different components of testicular NS is given in Tables 4 and 5. EC showed a variable expression of $\alpha 1$, $\alpha 2$, $\alpha 3$, $\alpha 5$, $\alpha 6$, $\beta 1$ and $\beta 4$ integrin subunits. All tumors stained for $\alpha 6$ and $\beta 1$ integrin subunits. Moreover, there was a variably increased density of the $\alpha 6$ integrin subunit at the tumor-stroma border in all tumors, as demonstrated in Figure 1A and B. The expression of the other integrin subunits in solid EC was generally weak and the polarization of the integrin subunits towards the tumor stroma border was generally absent or less pronounced. However, in EC with papillary and tubular differentiation the staining of $\alpha 2$, $\alpha 3$ and $\alpha 5$ integrin subunits was more intense, and in some cases analogous to the staining pattern of the $\alpha 6$ integrin subunit, increased at the tumor-stroma border (Figure 1C and D).

The morphologically recognizable tissues in teratomas (TE) demonstrated characteristic distribution patterns of integrin subunits. Mucinous and squamous epithelia showed strong differential expression of the $\alpha 2$, $\alpha 3$, $\alpha 6$, $\beta 1$ and $\beta 4$ integrin subunits, mostly restricted to the basal cells of the epithelium (Figure 2A - D). Weak staining of the $\alpha 1$ integrin subunit was additionally seen in mucinous epithelia. In simple epithelia $\alpha 1$ and $\alpha 5$ integrin subunits were present in addition to the integrin subunits found in complex epithelia. Smooth muscle stained for $\alpha 1$, $\alpha 3$, $\alpha 5$, $\alpha 6$ and $\beta 1$ integrin subunits. Cartilage showed expression of $\alpha 3$, $\alpha 5$, $\alpha 6$ and $\beta 1$ integrin subunits.

Five out of 7 YST expressed $\alpha 3$, $\alpha 5$, $\alpha 6$ and $\beta 1$ integrin subunits. The distribution of integrin subunits was generally diffuse. Focally, increased staining of integrin subunits at the tumor-stroma border was observed (Figure 3A - C).

Table 4. Distribution of integrin subunits in embryonal carcinoma.

	$\alpha 1$	$\alpha 2$	$\alpha 3$	$\alpha 4$	$\alpha 5$	$\alpha 6$	$\beta 1$	$\beta 4$
I	-	\pm	+	-	+	+	+	+
II	-	+	+	-	+	\pm	\pm	-
III	\pm	+	+	-	+	+	+	\pm
IV	-	-	-	-	$\pm/-$	+	+	-
V	-	\pm	$\pm/-$	-	-	+	+	-
VI	-	+	+	ND	+	+	+	-
VII	-	+	+	-	+	+	+	\pm
VIII	-	\pm	-	-	ND	+	+	-
IX	$\pm/-$	-	-	-	-	\pm	+	-
X	-	-	-	-	+	+	+	-
XI	-	\pm	-	-	-	+	+	-
XII	-	-	-	-	$\pm/-$	+	+	-
XIII	-	-	\pm	-	-	+	+	-
XIV	\pm	\pm	-	-	-	+	+	-
XV	-	$\pm/-$	-	-	$\pm/-$	+	+	-
XVI	-	-	-	-	-	+	+	-
XVII	-	-	-	-	$\pm/-$	+	+	-
XVIII	-	-	-	-	-	+	+	-
XIX	-	\pm	-	-	-	+	+	-

(-), negative; ($\pm/-$), equivocal; (\pm), weak; (+), positive staining. EC, embryonal carcinoma. ND, not done.

The distribution of integrin subunits on syncytiotrophoblastic giant cells (STGC) and cytotrophoblastic cells (CTC) of choriocarcinomas (CH) was heterogeneous. STGC as well as CTC demonstrated a complex integrin phenotype. Most of the integrin subunits were shared by STGC and CTC, although differences in staining intensity were observed between both cell populations. Moreover, CTC were characterized by $\beta 4$ integrin subunit expression, not present on STGC. Integrin subunits stained diverse populations of CTC. Roughly, $\alpha 1$, $\alpha 5$, $\alpha 6$, $\beta 1$ and $\beta 4$ integrin subunits were codistributed (Figure 3D - H), although inter-tumoral as well as intra-tumoral variation in the staining intensity and distribution could be observed. The $\alpha 2$ and $\alpha 3$ integrin subunits, demonstrated a restricted distribution pattern with a tendency to positive staining of CTC at the invasive front (Figure 3E).

The stroma surrounding tumor nodules in all tumors stained uniformly for $\alpha 1$, $\alpha 5$ and $\beta 1$ integrin subunits. Focally, stromal cells showed weak equivocal staining of $\alpha 2$, $\alpha 3$ and $\alpha 6$ integrin subunits.

Composition of the extracellular matrix (ECM)

In EC the stroma surrounding tumor nodules was intensely stained by collagen type I and fibronectin, but less extensive by collagen type IV and laminin. In solid EC, staining of laminin at the interface of tumor cells and stroma was variable and paralleled

the distribution of the $\alpha 6$ integrin subunit. The distribution of the $\alpha 6$ integrin subunit and laminin in the same tumor area is shown in Figure 4A and B. In papillary and tubular components of EC continuous staining of laminin at the tumor stroma border, with additional staining of collagen type IV was pronounced. Cytoplasmic staining of laminin was present in 9 out of 19 EC.

Table 5. Expression of integrin subunits in teratoma, yolk sac tumor and choriocarcinoma.

Integrin subunit	$\alpha 1$	$\alpha 2$	$\alpha 3$	$\alpha 4$	$\alpha 5$	$\alpha 6$	$\beta 1$	$\beta 4$
TE	+	+	+	\pm^*	+	+	+	+
	8/9	9/9	9/9	8/8	8/9	8/9	9/9	9/9
mucinous epithelia	\pm	+	+	-	-	+	+	+
squamous epithelia	-	+	+	-	-	+	+	+
simple epithelia	\pm	+	+	-	\pm	+	+	+
smooth muscle	+	-	+/ \pm	-	+	\pm	+	-
cartilage	-	-	+	-	+	+	+	-
YST	-	-	+/ \pm	-	+	+	+	-
			5/7		6/7	7/7	7/7	
STGC	+/ \pm	\pm /-	\pm	-	+/ \pm	\pm	+	-
	5/5	1/5	2/5		5/5	3/5	5/5	
CTC	+/ \pm	+	+/ \pm	-	+/ \pm	+/ \pm	+	+/ \pm
	4/5	3/5	4/5		5/5	5/5	5/5	4/4

(-), negative; (\pm /-), equivocal; (\pm), weak; (+): positive staining. TE, teratoma; YST, yolk sac tumor; CH, choriocarcinoma; STGC, syncytiotrophoblastic giant cells; CTC, cytotrophoblastic cells. * The $\alpha 4$ integrin subunit positive staining in TE concerned especially infiltrating leukocytes.

In TE collagen type IV and laminin were generally present in BMs underlining epithelial structures. Collagen type I and fibronectin were codistributed although fibronectin was accentuated in BMs and smooth muscle (Figure 4C - F).

In both YST and CH there was an extensive presence of ECM proteins. Intracellular as well as intercellular staining was noticed, often arranged in BM-like structures (Figure 4G and H). In YST and CH ECM proteins were either diffusely distributed between tumor cells or as (dis)continuous BMs at the interface of tumor cells and stroma. Focally, ECM proteins demonstrated a punctated pattern that surrounded individual CTC. In some but not all CTC cytoplasmic staining could be observed of laminin, collagen type IV and fibronectin.

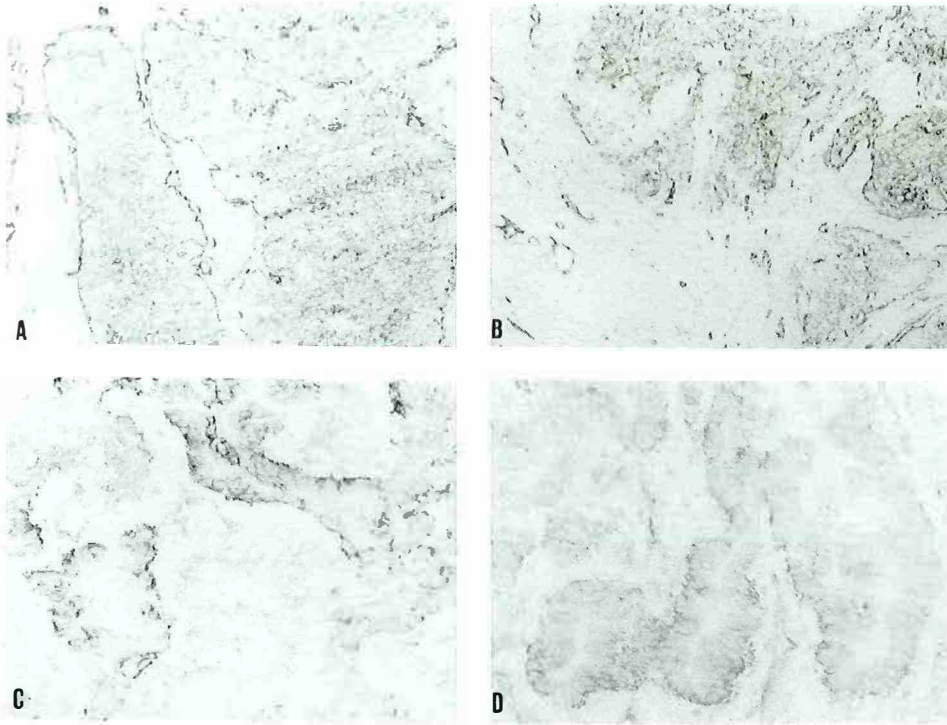


Figure 1. A: Embryonal carcinoma: positive staining of the $\alpha 6$ integrin subunit with increased staining intensity at the tumor-stroma border (56x). B: Embryonal carcinoma: nonpolarized staining of tumor cells for the $\alpha 6$ integrin subunit, focally increased staining intensity at the tumor-stroma border (56x). Embryonal carcinoma with papillary and tubular differentiation: polarized staining of $\alpha 3$ (C) and $\alpha 5$ (D) integrin subunits (140x). Immunoperoxidase staining.

DISCUSSION

Over the past years our understanding on the pathogenesis and biology of TGCTs has increased enormously. It is now well accepted that nearly all TGCTs of adolescents and adults with the possible exception of spermatocytic SE, pass through an in situ stage, known as intratubular germ cell neoplasia (ITGCN)²⁷. Moreover, morphological, immunohistochemical, ploidy and chromosome studies²⁸⁻³² indicate that SE and NS are histogenetically related and that progression of ITGCN to SE and/or NS is accompanied by significant changes in ploidy and karyotype^{29,30,33}.

Recent data suggest that in NS differentiation in the embryonal or extraembryonal direction not necessarily seems to be dependent on gross chromosomal changes. In fact, one and the same tumor may contain a noninvasive and nonmetastatic TE component and a highly metastatic CH component, with identical modal karyotype of both components³⁴. Apart from lineage related differences in genetic basic programming, the biology of the

two components may be determined by additional (epigenetic) factors. Of these factors cytokines, vitamins, hormones, cell-cell contacts and ECM proteins can be supposed to be the most important ³⁵.

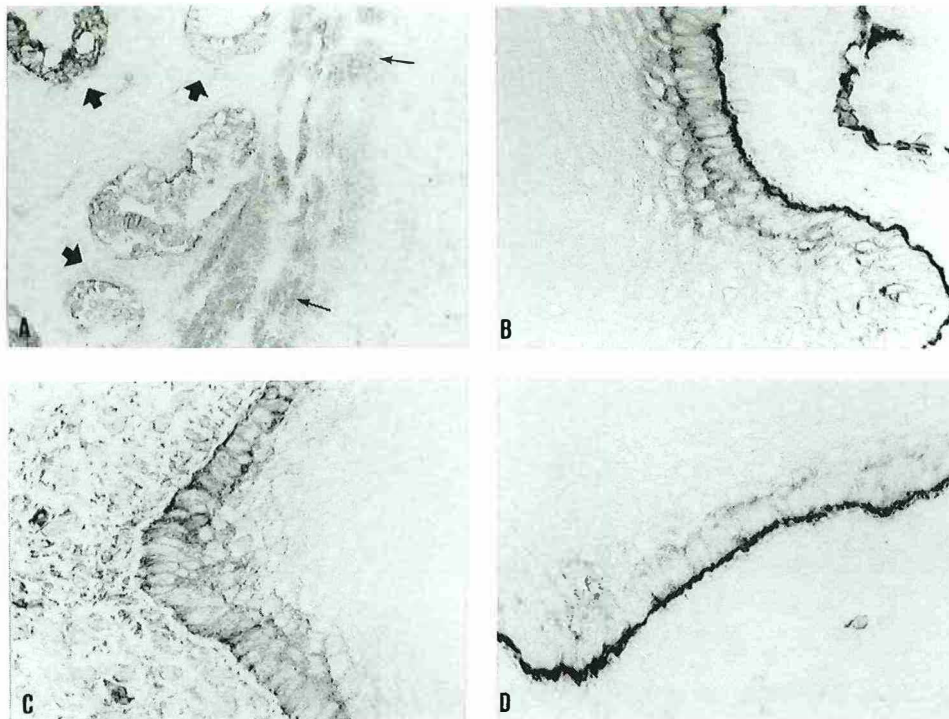


Figure 2. A: Teratoma: $\alpha 3$ integrin subunit expression on epithelia (large arrow) and smooth muscle (small arrow) (140x). Teratoma: strong differential expression of $\alpha 6$ (B), $\beta 1$ (C) and $\beta 4$ (D) integrin subunits on squamous epithelium. The expression of integrin subunits is limited to the basal layers of the epithelium and both $\alpha 6$ and $\beta 4$ integrin subunits show polarization of integrin subunits towards the underlining basement membrane (350x). Immunoperoxidase staining.

It is evident that the interaction of tumor cells with the ECM is a highly regulated, dynamic process in which tumor and non malignant host cells act concomitantly. This process not only involves degradation of the preexistent ECM, but also degradation and deposition of newly synthesized ECM proteins ³⁶. In this way, a local microenvironment is created that permits and promotes the survival, proliferation and migration of tumor cells. In a previous study we examined the distribution of ECM proteins in testicular SE ²⁰. A characteristic feature was the random distribution of BM-like structures between SE cells. In EC, deposition of laminin was variably present at the interface of EC cells and stroma, but intercellular staining of ECM proteins was absent or

only faintly developed compared to SE. The different patterns in SE and EC may be due to a higher proteolytic activity of EC cells than SE cells in keeping with a linear progression model, or be due to inherently different profiles of ECM synthesis by these cells or, most likely, a combination of the two. Indeed, variable *in vitro* synthesis of ECM proteins by TGCTs^{28,37-39} suggests an in part lineage dependent tumor cell origin of ECM proteins *in vivo*.

Table 6. Integrin subunits in normal and malignant cytotrophoblastic cells.

Integrin subunits	$\alpha 1$	$\alpha 2$	$\alpha 3$	$\alpha 4$	$\alpha 5$	$\alpha 6$	$\beta 1$	$\beta 4$
Placenta (first trimester)								
Villous CTC	-	-	\pm	-	-	+	\pm	+
Columnar CTC	-	-	-	-	+	\pm	+	\pm
Placental bed CTC	+	-	-	-	+	-	+	-
Testicular choriocarcinoma								
CTC	+/ \pm	+	+/ \pm	-	+/ \pm	+/ \pm	+	+/ \pm

Data on distribution of integrin subunits in normal (first trimester) placenta according to references⁵¹⁻⁵³: (-), negative; (\pm), weak; (+), positive staining. CTC, cytotrophoblastic cells.

Despite compelling evidence^{10,25,40-43} for a role of integrin-ECM interactions in many steps of the metastatic cascade, the interpretation of integrin expression patterns in malignant tumors is rather complex. In solid tumors integrins show characteristic cell-lineage dependent distribution patterns that may be a useful tool in histopathological classification⁴⁴. For example, the results on integrin expression in TE are consistent with previous reports on the distribution of integrins in their normal counterparts⁴⁴⁻⁴⁶ and its relatively benign biological behavior^{47,48}. In view of this indolent behavior in TE integrins may be considered as suppressors of invasion as these tumors are in fact malignant and composed of cytologically atypical cells with a aneuploid DNA content and gross chromosomal changes^{34,49}.

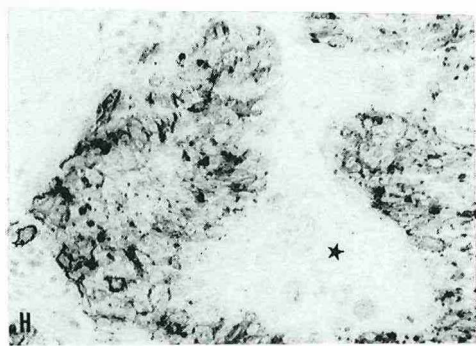
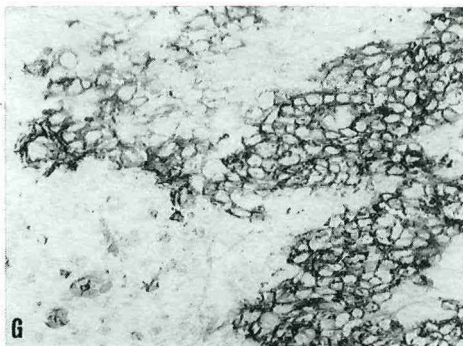
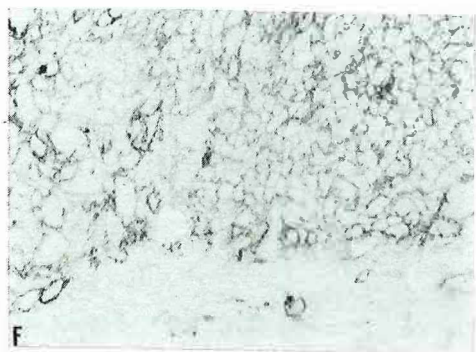
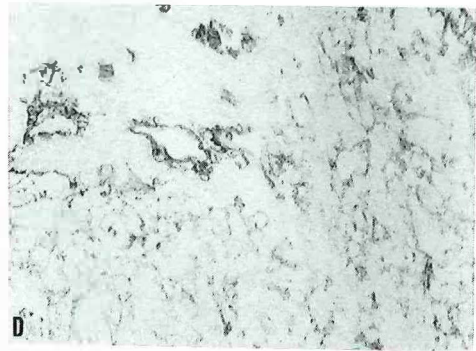
On the other hand, although not consistently and dependent on the cell type, malignant cells often express an altered pattern of integrins compared with their nontumorigenic counterparts^{10,42}. Malignant epithelial tumors show a tendency to express reduced levels of integrins, particularly those integrins that have affinity to BM components like laminin and collagen type IV ($\alpha 2\beta 1$, $\alpha 3\beta 1$, $\alpha 6\beta 1$, $\alpha 6\beta 4$), whereas in some other tumors specific integrins are upregulated and supposed to be positively associated with the malignant phenotype (for example upregulation of $\alpha v\beta 3$ in malignant melanoma)^{10,42,50}. Herein loss of integrins may decrease the adhesiveness of tumor cells in their local microenvironment and render them refractory to growth regulatory (inhibitory) signals^{42,43}, whereas *de novo* expression of integrins may stimulate motility and adhesiveness of tumor cells to foreign matrices and heterologous cells⁹. In normal placental development subtypes of CTC with different biological properties can be

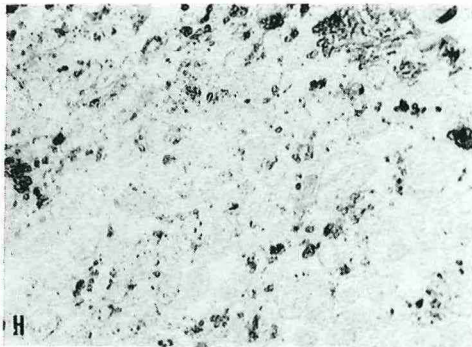
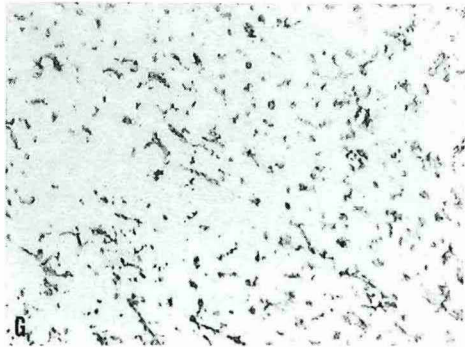

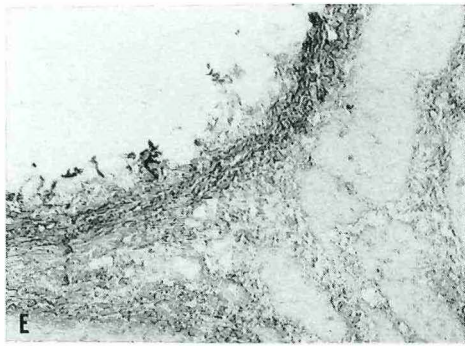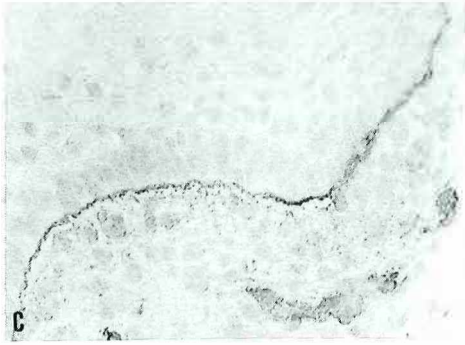
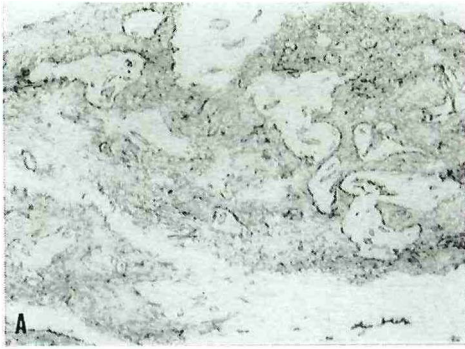recognized by their integrin profiles. First trimester noninvasive villous CTC are characterized by $\alpha 6$ and $\beta 4$ integrin subunit expression, whereas downregulation of these integrin subunits and upregulation of $\alpha 1$, $\alpha 5$ and $\beta 1$ integrin subunits is associated with the development of invasive placental bed CTC^{51,52}. In CH integrin subunits are heterogeneously expressed. Analogous to normal placental development subpopulations of CTC with hypothetically different biological properties can be recognized by their integrin profiles. However, in contrast to normal placental development, in some CH loss of polarization, and aberrant (co)expression of integrin subunits ($\alpha 1$, $\alpha 2$, $\alpha 3$, $\alpha 5$, $\alpha 6$, $\beta 4$) is noticed (Table 6). It is supposed that invasion of normal first trimester CTC is in part regulated by the balance between ECM-CTC interactions that promote (laminin, collagen - $\alpha 1\beta 1$ integrin interaction) and those that inhibit (fibronectin - $\alpha 5\beta 1$ integrin interaction) the invasiveness of CTC⁵³. The aberrant (co)expression of integrin subunits on malignant CTC might disrupt this balance and be related to the aggressive behavior of CH^{47,48}.

Particularly in EC, cell-lineage dependent distribution patterns and transformation/progression related patterns could mix up. It is difficult to determine whether the expression of a particular integrin subunit on EC is related to differentiation towards the embryonal or extraembryonal direction, reflects progression of ITGCN to SE and/or EC, or most likely reflects a combination of both options. In individual cases of EC, integrin subunits may be indicative about the direction and level of differentiation. EC can be considered as epithelial tumors as evidenced by the expression of keratins³¹ and desmosomal plaque proteins⁵⁴. Consistent with their epithelial nature, in our study some EC express epithelial integrin subunits as $\alpha 2$ and $\alpha 3$. Furthermore, the expression of integrin subunits, (in particular the $\alpha 6$ integrin subunit) and laminin is increased at the tumor stroma border. These results are in line with previous studies on the distribution of integrins and ECM proteins in normal epithelia and carcinomas in which the expression of BM proteins paralleled the expression of BM protein binding integrins. From these

Figure 3, page 91. Yolk sac tumor: expression of $\alpha 3$ (A, 56x), $\alpha 5$ (B, 140x) and $\alpha 6$ (C, 56x) integrin subunits. Note that the $\alpha 5$ integrin subunit is expressed by stromal cells as well as tumor cells (Figure B, star). Choriocarcinoma: expression of $\alpha 1$ (D), $\alpha 2$ (E), $\alpha 5$ (F), $\alpha 6$ (G) and $\beta 4$ (H) integrin subunits. The staining of cytotrophoblastic cells is heterogeneous. The $\alpha 2$ integrin subunit demonstrates a limited distribution pattern, in which cytotrophoblastic cells at the invasive front show positive staining whereas the centrally located tumor cells are not stained or only weakly (Figure E, arrow). The distribution of $\alpha 1$, $\alpha 5$, $\alpha 6$ and $\beta 4$ integrin subunits is extensive. Cytotrophoblastic cells show strong expression of the $\beta 4$ integrin subunit, not present of syncytiotrophoblastic giant cells (Figure H, star) (140x). Immunoperoxidase staining.

Figure 4, page 92. Embryonal carcinoma: colocalization of the $\alpha 6$ integrin subunit (A) and laminin (B) at the interface of tumor cells and the stroma. Teratoma: continuous staining of laminin (C) and collagen type IV (D) in squamous epithelium (350x). Teratoma: differential staining of collagen type I (Figure E, 140x) and fibronectin (Figure F, 56x). Yolk sac tumor: extensive distribution of fibronectin (G, 140x). Choriocarcinoma: extensive distribution of laminin (H, 350x). Immunoperoxidase staining.





studies it became evident that the more invasive tumors lacked intact BMs, whereas BM protein binding integrins showed a decreased expression and lacked the normal spatial organization with a diffuse distribution over the cell surface^{10,42}. Analogously to other epithelial tumors and in line with the low metastatic potential of somatically differentiated cells in TGCTs^{47,48}, EC with features of ongoing epithelial differentiation as demonstrated by our study can be supposed to have a less aggressive biological behavior.

Finally, it must be emphasized that tumor cell invasion is highly regulated^{11,55}, and the mechanisms used by tumor cells to break down mechanical barriers and to migrate are analogous to the ones used by normal cells^{9,11}. In other words the biology of malignant tumors is in part related to differentiation lineage and the properties of their normal counterparts as is nicely illustrated in testicular NS^{47,48}. However, analogous to other solid cancers, in testicular NS clonal evolution will result in tumor progression and genotypic and phenotypic heterogeneity. In this process clones will evolve with growth advantage and an enhanced invasive and metastatic potential^{35,56}. The results of our study are compatible with both interrelated processes. Future studies will have to elucidate whether in testicular NS integrin expression and distribution of ECM proteins are related to differentiation lineage, tumor progression, or both.

Acknowledgements

Monoclonal antibodies TS2/16 and TS2/7 were kindly provided by Dr. TA Springer (Center for Blood Research, Harvard Medical School, Boston, USA, MA), CLB Thromb/4 and GOH3 by Dr. A Sonnenberg (CLB, Amsterdam, The Netherlands), J143 by Dr. LJ Old (Memorial Sloan-Kettering Cancer Center, New York, USA, NY), A-1A5 and B5G10 by Dr. ME Hemler (Dana-Farber Cancer Institute, Harvard Medical School, Boston, USA, MA), HP2/1 by Dr. F Sánchez-Madrid (Seccion De Inmunologia, Hospital de la Princesa, Madrid, Spain) and BIIG2 by Dr. C Damsky (University of California, San Francisco, USA, CA). The authors thank Fraukje Kas, MSc for technical assistance and Hilbrand Wierenga for help in the preparation of the microphotographs. This study was supported by the Dutch Cancer Society Grant GUKC 88-11 and the J.K. De Cock Foundation Groningen.

REFERENCES

1. Hynes R O: Integrins: Versatility, modulation, and signaling in cell adhesion. *Cell* 1992, 69: 11-25
2. Hemler M E: VLA proteins in the integrin family: structures, functions, and their role on leukocytes. *Annu Rev Immunol* 1990, 8: 365-400
3. Tamura R N, Cooper H M, Collo G, Quaranta V: Cell type-specific integrin variants with alternative α chain cytoplasmatic domains. *Dev Biol* 1991, 88: 10183-10187
4. Ginsberg M H, Du X, Plow E F: Inside-out integrin signalling. *Curr Opin Cell Biol* 1992, 4: 766-771

5. Damsky C H, Werb Z: Signal transduction by integrin receptors for extracellular matrix: cooperative processing of extracellular information. *Curr Opin Cell Biol* 1992, 4: 772-781
6. Werb Z, Tremble P M, Behrendtsen O, Crowley E, Damsky C H: Signal transduction through the fibronectin receptor induces collagenase and stromelysin gene expression. *J Cell Biol* 1989, 109: 877-889
7. Bissell M J, Hall H G, Parry G: How does the extracellular matrix direct gene expression? *J Theor Biol* 1982, 99: 31-68
8. Juliano R L, Haskill S: Signal transduction from the extracellular matrix. *J Cell Biol* 1993, 120: 577-585
9. Hynes R O, Lander A D: Contact and adhesive specificities in the associations, migrations and targeting of cells and axons. *Cell* 1992, 68: 303-322
10. Albelda S M: Role of integrins and other cell adhesion molecules in tumor progression and metastasis. *Lab Invest* 1993, 68: 4-17
11. Liotta L A, Steeg P S, Stetler-Stevenson W G: Cancer metastasis and angiogenesis: an imbalance of positive and negative regulation. *Cell* 1991, 64: 327-336
12. Emonard H, Christiane Y, Smet M, Grimaud J A, Foidart J M: Type IV and interstitial collagenolytic activities in normal and malignant trophoblastic cells are specifically regulated by the extracellular matrix. *Invasion Metastasis* 1990, 10: 170-177
13. Aznavoorian S, Stracke M L, Krutzsch H, Schiffmann E, Liotta L A: Signal transduction for chemotaxis and haptotaxis by matrix molecules in tumor cells. *J Cell Biol* 1990, 110: 1427-1438
14. Blood C H, Zetter B R: Laminin regulates a tumor cell chemotaxis receptor through the laminin-binding integrin subunit α_6 . *Cancer Res* 1993, 53: 2661-2666
15. Dvorak H F, Nagy J A, Berse B, Brown L F, Yeo K -T, Yeo T -K, Dvorak A M, van de Water L, Sioussat T M, Senger D R: Vascular permeability factor, fibrin, and the pathogenesis of tumor stroma formation. *Ann NY Acad Sci* 1992, 667: 101-111
16. Nagy J A, Brown L F, Senger D R, Lanir N, Van de Water L, Dvorak A M, Dvorak H F: Pathogenesis of tumor stroma generation: a critical role for leaky blood vessels and fibrin deposition. *Biochim Biophys Acta* 1989, 948: 305-326
17. Skakkebaek N E, Berthelsen J G, Giwercman A, Müller J: Carcinoma in situ of the testis: possible origin from gonocytes and precursor of all types of germ cell tumours except spermatocytoma. *Int J Androl* 1987, 10: 19-27
18. Jørgensen N, Müller J, Giwercman A, Skakkebaek N E: Clinical and biological significance of carcinoma in situ of the testis. *Cancer Surv* 1990, 9: 287-301
19. Jacobsen G K, Henriksen O B, v der Maase H: Carcinoma in situ of testicular tissue adjacent to malignant germ-cell tumors: a study of 105 cases. *Cancer* 1981, 47: 2660-2662

20. Timmer A, Oosterhuis J W, Schraffordt Koops H, Sleijfer D Th, Szabo B G, Timens W: The tumor microenvironment: possible role of integrins and the extracellular matrix in tumor biological behavior of intratubular germ cell neoplasia and testicular seminomas. *Am J Pathol* 1994, 144: 1035-1044
21. Bosman F T, Havenith M G, Visser R, Cleutjens J P M: Basement membranes in neoplasia. *Progress in Histochemistry and Cytochemistry* 1992, 24: 1-92
22. Ulbright T M, Roth L M, Brodhecker C A: Yolk sac differentiation in germ cell tumors. A morphologic study of 50 cases with emphasis on hepatic, enteric, and parietal yolk sac features. *Am J Surg Pathol* 1986, 10: 151-164
23. Jacobsen G K: Laminin in testicular germ cell tumours. An immunohistochemical study. *APMIS* 1990, 98: 875-880
24. Bartkova J, Rejthar A, Bartek J, Kovarik J: Differentiation patterns of testicular germ-cell tumours as revealed by a panel of monoclonal antibodies. *Tumour Biol* 1987, 8: 45-56
25. Timens W: Cell adhesive molecule expression and homing of hematologic malignancies. *Crit Rev Oncol Hematol* 1995, 19: 111-129
26. Anonymous leucocyte typing V: white cell differentiation antigens. Oxford University Press 1994, (in press)
27. Damjanov I: Pathogenesis of testicular germ cell tumours. *Eur Urol* 1993, 23: 2-7
28. Damjanov I, Horvat B, Gibas Z: Retinoic acid-induced differentiation of the developmentally pluripotent human germ cell tumor-derived cell line, NCCIT. *Lab Invest* 1993, 68: 220-232
29. de Jong B, Oosterhuis J W, Castedo S M, Vos A, Te Meerman G J: Pathogenesis of adult testicular germ cell tumors. A cytogenetic model. *Cancer Genet Cytogenet* 1990, 48: 143-167
30. Oosterhuis J W, Castedo S M M, de Jong B, Cornelisse C J, Dam A, Sleijfer D Th, Schraffordt Koops H: Ploidy of primary germ cell tumors of the testis. Pathogenetic and clinical relevance. *Lab Invest* 1989, 60: 14-21
31. Lifschitz-Mercer B, Fogel M, Moll R, Jacob N, Kushnir I, Livoff A, Waldherr R, Franke W W, Czernobilsky B: Intermediate filament protein profiles of human testicular non-seminomatous germ cell tumors: correlation of cytokeratin synthesis to cell differentiation. *Differentiation* 1991, 48: 191-198
32. Fogel M, Lifschitz-Mercer B, Moll R, Kushnir I, Jacob N, Waldherr R, Livoff A, Franke W W, Czernobilsky B: Heterogeneity of intermediate filament expression in human testicular seminomas. *Differentiation* 1990, 45: 242-249
33. de Graaff W E, Oosterhuis J W, de Jong B, Dam A, van Putten W L, Castedo S M, Sleijfer D T, Schraffordt Koops H: Ploidy of testicular carcinoma in situ. *Lab Invest* 1992, 66: 166-168

34. de Graaff W E, Oosterhuis J W, de Jong B, van Echten-Arends J, Wiersema-Buist J, Schraffordt Koops H, Sleijfer D T: Cytogenetic analysis of the mature teratoma and the choriocarcinoma component of a testicular mixed nonseminomatous germ cell tumor. *Cancer Genet Cytogenet* 1992, 61: 67-73
35. Nicolson G L: Tumor cell instability, diversification, and progression to the metastatic phenotype: from oncogene to oncofetal expression. *Cancer Res* 1987, 47: 1473-1487
36. Pauli B U, Knudson W: Tumor invasion: a consequence of destructive and compositional matrix alterations. *Hum Pathol* 1988, 19: 628-639
37. Pera M F, Roach S, Elliss C: Comparative biology of mouse and human embryonal carcinoma. *Cancer Surv* 1990, 9: 243-262
38. Cooper S, Pera M F: Vitronectin production by human yolk sac carcinoma cells resembling parietal endoderm. *Development* 1988, 104: 565-574
39. McIlhinney R A, Patel S: Characterization of the fibronectin synthesized by human germ cell tumors. *Cancer Res* 1983, 43: 1282-1288
40. Giancotti F G, Ruoslahti E: Elevated levels of the alpha 5 beta 1 fibronectin receptor suppress the transformed phenotype of Chinese hamster ovary cells. *Cell* 1990, 60: 849-859
41. Qian F, Vaux D L, Weissmann I L: Expression of the integrin $\alpha 4 \beta 1$ on melanoma cells can inhibit the invasive stage of metastasis formation. *Cell* 1994, 77:335-347
42. Juliano R L, Varner J A: Adhesion molecules in cancer: the role of integrins. *Curr Opin Cell Biol* 1993, 5: 812-818
43. Schwartz M A: Signaling by integrins: implications for tumorigenesis. *Cancer Res* 1993, 53: 1503-1506
44. Miettinen M, Castello R, Wayner E, Schwarting R: Distribution of VLA integrins in solid tumors. *Am J Pathol* 1993, 142: 1009-1018
45. Choy M -Y, Richman P I, Horton M A, MacDonald T T: Expression of the VLA family of integrins in human intestine. *J Pathol* 1990, 160: 35-40
46. Salter D M, Hughes D E, Simpson R, Gardner D L: Integrin expression by human articular chondrocytes. *Br J Rheumatol* 1992, 31: 231-234
47. Oosterhuis JW. The metastasis of human teratomas. In: Damjanov I, Knowles B, Solter D, eds. *The human teratomas*. Clifton New Jersey: Humana Press, 1983: 137-171.
48. de Graaff W E, Oosterhuis J W, van der Linden S, Homan van der Heide J N, Schraffordt Koops H, Sleijfer D T: Residual mature teratoma after chemotherapy for nonseminomatous germ cell tumors of the testis occurs significantly less often in lung than in retroperitoneal lymph node metastasis. *J Urogen Pathol* 1991, 1: 75-81
49. Ulbright T M: Germ cell neoplasms of the testis. *Am J Surg Pathol* 1993, 17: 1075-1091

50. Albelda S M, Mette S A, Elder D E, Stewart R M, Damjanovich L, Herlyn M, Buck C A: Integrin distribution in malignant melanoma: association of the $\beta 3$ subunit with tumor progression. *Cancer Res* 1990, 50: 6757-6764
51. Damsky C H, Fitzgerald M L, Fisher S J: Distribution patterns of extracellular matrix components and adhesion receptors are intricately modulated during first trimester cytotrophoblast differentiation along the invasive pathway, in vivo. *J Clin Invest* 1992, 89: 210-222
52. Korhonen M, Yläne J, Laitinen L, Cooper H M, Quaranta V, Virtanen I: Distribution of the $\alpha 1$ - $\alpha 6$ integrin subunits in human developing and term placenta. *Lab Invest* 1991, 65: 347-356
53. Damsky C, Sutherland A, Fisher S: Extracellular matrix 5: Adhesive interactions in early mammalian embryogenesis, implantation, and placentation. *FASEB J* 1993, 7: 1320-1329
54. Denk H, Moll R, Weybora W, Lackinger E, Vennigerholz F, Beham A, Franke W W: Intermediate filament and desmosomal plaque proteins in testicular seminomas and non-seminomatous germ cell tumors as revealed by immunohistochemistry. *Virchows Arch A Pathol Anat* 1987, 410: 295-307
55. Herlyn M, Malkowicz S B: Regulatory pathways in tumor growth and invasion. *Lab Invest* 1991, 65: 262-271
56. Oosterhuis J W, Looijenga L H J: The biology of human germ cell tumours: retrospective speculations and new perspectives. *Eur Urol* 1993, 23: 245-250

Chapter 3

RETINOIC ACID AND CISDIAMMINEDICHLOROPLATINUM IN THE TREATMENT OF MURINE TERATOCARCINOMAS IN VIVO IN A NULLIPOTENT MODEL

Siep Wouda¹, Albertus Timmer¹, Nanno H. Mulder², Anke Dam¹, Jan Koudstaal¹,
J. Wolter Oosterhuis³

Department of Pathology¹, Division of Medical Oncology, Department of Internal Medicine²,
University Hospital, Groningen. Dr. Daniel den Hoed Cancer Center³, Rotterdam,
The Netherlands.

ABSTRACT

Induction of differentiation as a treatment modality for nonseminomatous germ cell tumors (NSGCTs) may promote the development of residual mature teratoma (RMT), which is usually associated with primary tumors that are capable of spontaneous somatic differentiation. Therefore, we studied the combination of a cytotoxic drug and a differentiation inducing agent in vivo in three murine teratocarcinoma models with different levels of spontaneous somatic differentiation: E86-379 (moderate differentiation); NF-1 (poor differentiation); MH-15 (no differentiation). We used retinoic acid (RA) as differentiation inducing agent and cisdiamminedichloroplatinum (CDDP) as cytotoxic drug, plus a combination of both. In four separate experiments, the combination of RA and CDDP gave a significant further reduction of the tumor size as compared to treatment with either RA or CDDP alone. Morphologically intact tumor after treatment with combined RA-CDDP contained a smaller proportion of undifferentiated tissue (embryonal carcinoma) than after CDDP alone. However, somatic differentiation was not induced in the tumor model lacking spontaneous somatic differentiation. Toxicity was reflected in loss of body weight and death of some animals and closely paralleled the degree of tumor reduction in all experiments.

INTRODUCTION

The majority of the chemotherapeutic agents are cytotoxic. Tumor cell kill is attained at the cost of toxic side effects. Although chemotherapy of cancer (in particular childhood cancer) has shown substantial progress in the last decades, it appears that the rate of progress is leveling off (1). This is also true for chemotherapy of nonseminomatous germ cell tumors (NSGCTs) of the testis. A substantial minority of the patients (about 20 % (2)) cannot be cured with the current chemotherapy regimens; the main cause of failure is development of drug resistance.

A new, promising approach might be the induction of terminal differentiation in cancer cells (3). The well documented spontaneous cures in neuroblastoma IV-S (4) - which has an aneuploid DNA content (5) - leaving residual, terminally differentiated ganglioneuromas, lend credibility to the concept of cancer treatment by induction of differentiation. A large number of compounds have been shown to induce differentiation *in vitro* and *in vivo* in animal models. Most clinical trials have not provided any conclusive evidence for a therapeutic benefit so far, but relatively few trials have been carried out (6-9). Recently, it was reported that promyelocytic leukemia can be treated successfully by retinoic acid (RA) alone (10). Resistance to therapy with RA is the result of progressive reduction in plasma drug concentration, rather than the development of resistance of the leukemia cells to the differentiating activity of RA (11). On the other hand, RA-refractory HL-60 myeloid leukemia cells contained altered retinoic acid receptor- α (RAR- α) (12). The human embryonal carcinoma cell line NTera/2D1 was made refractory to RA by mutagenization (Dmitrovsky E, personal communication). Because in solid tumors probably not all the tumor cells are responsive to differentiation inducers, such inducers should probably be combined with cytotoxic agents to get the best therapeutic results. However, induction of differentiation as a treatment modality for NSGCTs of the testis might carry the risk of promoting the development of residual mature teratoma (RMT). RMT is apparently relatively resistant to chemotherapy since it is often the only residual tissue after multiple-drug chemotherapy of disseminated NSGCT of the testis. Usually, it is associated with primary tumors with the capacity of spontaneous somatic differentiation, apparent from a teratoma component (13). Induction of differentiation might promote the development of RMT in patients whose primary tumors lack the capacity for spontaneous somatic differentiation.

We have studied the effect of RA, a differentiation-inducing agent, the cytotoxic drug cisdiamminedichloroplatinum (CDDP), and the combination of both on tumor reduction and histology of murine teratocarcinoma. The treatment regimens were tested in teratocarcinomas with different levels of spontaneous somatic differentiation. In addition to tumor response, toxicity of the various regimens was determined.

MATERIALS AND METHODS

The following murine transplantable embryo derived teratocarcinomas were used: E86-379, with moderate somatic differentiation (50% of the tumor tissue is differentiated); the NF-1 murine teratocarcinoma (14) with poor somatic differentiation (25%); and the MH-15 murine teratocarcinoma without somatic differentiation (<1%).

Tumors were produced by transplanting pieces of tumor (approximately 2 mm in diameter) *i.m.* into the left thigh of earmarked female BALB/c mice aged 12 weeks and of

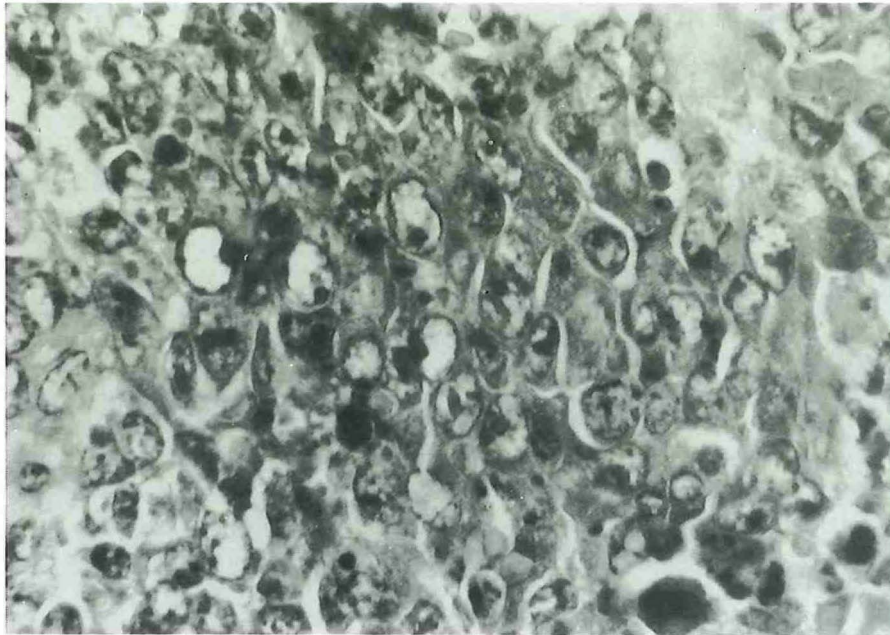


Figure 1. Untreated NF-1 teratocarcinoma showing embryonal carcinoma cells. (hematoxylin and eosin, x 128).

about 21 g body weight. The mice were randomized over four treatment groups: solvents only; RA only; CDDP only; RA + CDDP. Treatments were started when the tumors had a diameter of approximately 10 mm, about 15 days after tumor implantation. Platinol (Bristol Myers, Madrid, Spain) containing 0.5 mg CDDP/ml and all-trans retinoic acid (Eastman Kodak, Rochester N. Y., U.S.A.) dissolved in corn oil (RA: corn oil, 0.2 mg/0.1 ml). The RA solution was freshly made every day immediately before injection. The maximal dosages of RA and CDDP tolerated by healthy animals in pilot experiments were a daily i.p. in a dosage of RA, 30 mg/kg and CDDP, 2 mg/kg (unpublished data).

Four separate experiments were carried out. In three experiments the drugs were given in daily doses of RA, 30 mg/kg body weight, and CDDP, 2 mg/kg body weight already mentioned. In one experiment, with the MH-15 tumor, CDDP, 1 mg/kg body weight was given, instead of 2 mg/kg body weight. In the control group, only solvents were injected, i.p., in the same amounts as in the combination treatment (RA + CDDP).

When the body weight of a mouse decreased below 16 g, CDDP, 1 mg/kg body weight, was given instead of 2 mg/kg body weight; when the body weight decreased below 14.5 g, CDDP was replaced by saline (0.9% NaCl).

Toxicity was monitored by daily measurement of body weight; anti tumor activity by daily measurement of the two largest perpendicular diameters of the tumors (a and b) with calipers. The tumors were measured prior to injection of the drugs. For practical reasons, the same person did the measurements and the injection of the drugs in one session. However, he did not know the results of previous measurements. Tumor size is expressed

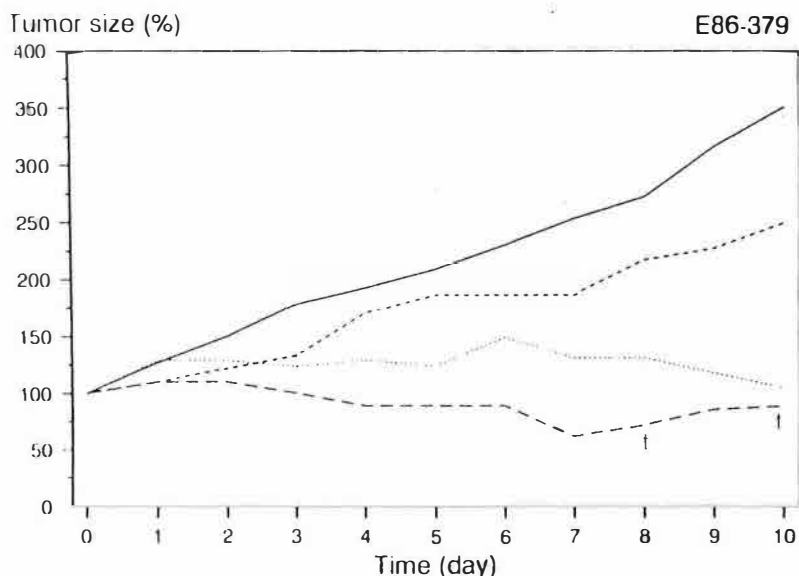


Figure 2. Median size of the E86-379 (moderately differentiating teratocarcinoma) tumors in four treatment arms: solvents only (—), RA (-----), CDDP (·····), and RA-CDDP (- - -). Dose reduction of CDDP in the combination group started on day 3, marked by the vertical line. RA alone did not significantly reduce tumor size as compared with the controls. CDDP alone significantly reduced tumor size ($p < 0.05$) from day 2 to day 10. RA-CDDP caused a significant further reduction of the tumor size as compared with CDDP alone ($p < 0.025$ on day 6); however, on CDDP dose reduction after day 6, this effect is lost. Each cross indicates the death of one mouse.

as a x b (15). Statistical analysis was done by the Mann Whitney U test (16). To allow a comparative histological examination of the tumors, all mice were killed on the tenth day of the treatment. The tumors were removed from the left thigh and fixed in formalin. From paraffin-embedded blocks of tumor tissue, 2 μ m histological slides were cut. The ratio of differentiated and undifferentiated viable tumor tissue was determined morphometrically on hematoxylin-eosin-stained slides by point counting. The slides were examined under code.

Undifferentiated tumor tissue consists of embryonal carcinoma (EC), composed of solid sheets of uniform, polygonal cells with an epithelioid appearance and basophilic cytoplasm, large nuclei, and prominent nucleoli (Figure 1). The earliest sign of differentiation is a decrease of nuclear size and loss of the prominent nucleoli. On differentiation, the morphology of the cytoplasm and the character of the intercellular matrix depend on the differentiation lineages, which can be very heterogeneous with different kinds of neural, epithelial, and mesenchymal tissues. Whatever has non-EC morphology is regarded as differentiated tissue.

In murine retransplantable teratocarcinomas, spontaneous necrosis due to circulation disturbances is an early phenomenon interfering with the measurement of necrosis due to the

treatment. Therefore, we did not morphometrically quantitate the amount of necrosis in the tumors.

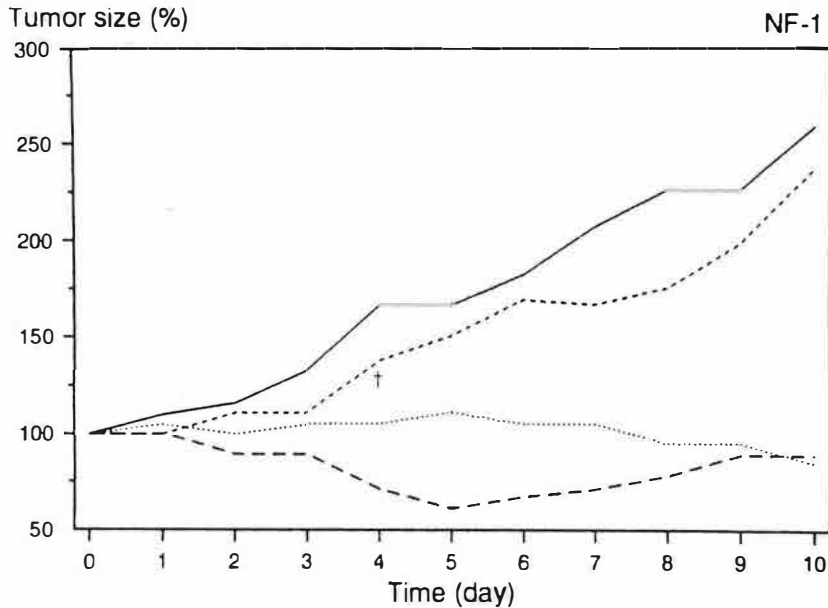


Figure 3. Median size of the NF-1 (poorly differentiating teratocarcinoma) tumors in four treatment arms: solvents only (—), RA (-----), CDDP (·····), and RA-CDDP (— — —). Dose reduction of CDDP in the combination group started on day 5, marked by the vertical line. RA alone had no significant effect on tumor size. CDDP significantly reduced tumor size as compared with the controls ($p < 0.05$ on days 3 and to 10). RA-CDDP significantly further reduced tumor size as compared with CDDP alone ($p < 0.05$) on days 4 and 5; on CDDP dose reduction after day 5, the difference is lost.

RESULTS

Tumor response.

Tumor response to the various treatments in the four experiments is shown in the Figures. 2-5. In all four experiments, tumor size is expressed as a percentage of the size of the tumor at the beginning of the treatment, which for each treatment arm was arbitrarily set at 100%. The tumor diameters at the beginning of the treatment varied from 9 - 13 mm. The untreated tumors grew progressively in the four experiments. RA alone resulted in some reduction of tumor growth, which was statistically significant in the both MH-15 experiments on days 8, 9 and 10 ($p < 0.05$). CDDP alone prevented tumor growth, resulting in a significantly smaller tumor size as compared with the control mice in all experiments on days 2 to 10 ($p < 0.05$). Tumor reduction as compared with initial tumor size was only achieved by the combination RA-CDDP. The tumors treated with the combination RA-CDDP were

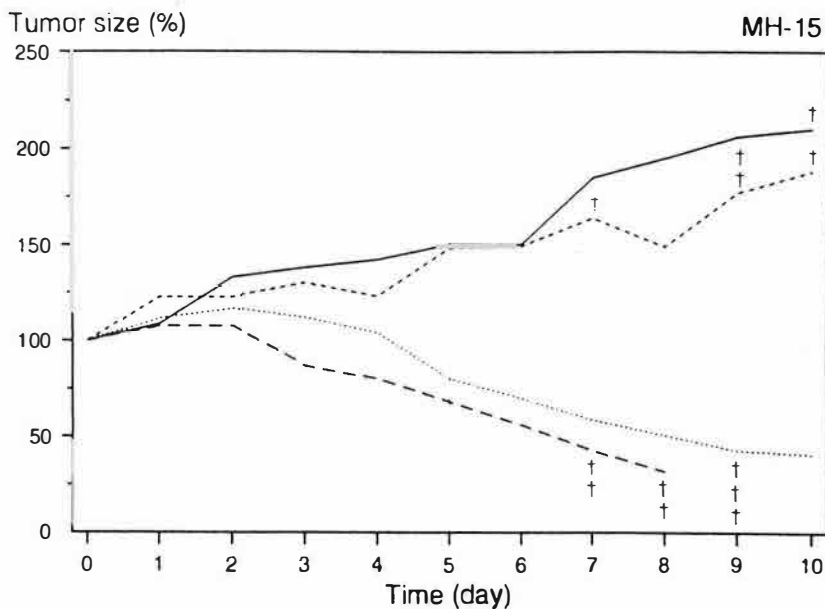


Figure 4. Median size of the MH-15 (undifferentiated teratocarcinoma) tumors in the four treatment arms: solvents only (—), RA (----), CDDP (.....), and RA-CDDP (— — —). Dose reduction of CDDP in the combination group started on day 5, marked by the vertical line. RA significantly reduced tumor size as compared to the controls on days 2 to 10 ($p < 0.05$). CDDP significantly reduced tumor size as compared with the controls on days 7 to 10 ($p < 0.05$ on days 7 and 8; $p < 0.025$ on days 9 and 10); on dose reduction after day 5, the difference gradually disappeared.

TABLE 1. Morphometric analysis of proportion of somatic tissue in embryo-derived tumors with different levels of spontaneous somatic differentiation after treatment with RA, CDDP, or both

Tumor	Somatic differentiation	Control	RA	CDDP	CDDP-RA
		% Range	% Range	% Range	% Range
E86-379	Moderate	44 23-72	82 65-87	45 9-88	85 0-90
NF-1	Low	20 8-35	88 67-89	0	82 79-86
MH-15	Absent	0	0	0	0
MH-15 (low-dose CDDP)		0	0	0	0

Values are median percentages (with ranges) of viable tissue with somatic differentiation. Mann Whitney U test in E86-379 and NF-1 experiments: control vs. RA and CDDP vs. RA-CDDP: $p < 0.05$.

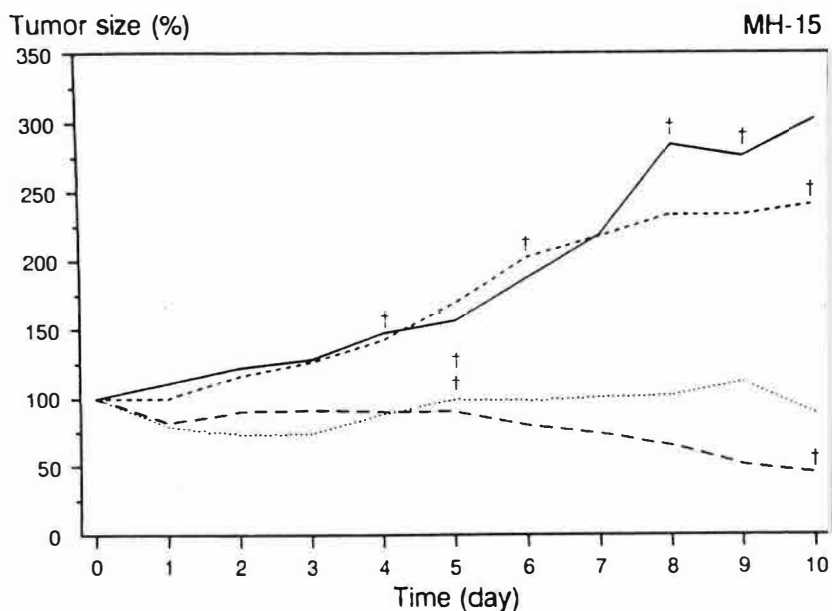


Figure 5. Median size of MH-15 (undifferentiated teratocarcinoma) tumors in four treatment arms: solvents only (—), RA (----), low dose CDDP (.....), and RA with low dose CDDP (- - -). Dose reduction of CDDP was not necessary. RA alone significantly reduced tumor size as compared with controls on days 9 and 10 ($p < 0.05$). CDDP alone significantly reduced tumor size as compared with controls on days 2 to 10 ($p < 0.01$). RA-CDDP significantly further reduced tumor size as compared with CDDP alone on days 9 ($p < 0.05$) and 10 ($p < 0.01$).

significantly smaller than those in the control and the RA-alone groups on days 2 to 10 in all experiments. RA-CDDP gave a further reduction of tumor size compared with CDDP alone in the E86-379 experiment on day 6 ($p < 0.025$); in the NF-1 experiment on days 4 and 5 ($p < 0.05$); in the MH-15 experiment on days 3 and 4 ($p < 0.05$) and day 5 ($p < 0.025$) and in the MH-15 experiment treated with the low dose CDDP on days 9 ($p < 0.05$) and 10 ($p < 0.01$). Reduction of the dose of CDDP after 3 days in the experiments with E86-379, and after 5 days in the experiments with NF-1 and with MH-15, led to increased tumor size; at day 10, the size of the tumors in the combination arm equaled that of the tumors treated with CDDP alone.

Tumor histology.

The percentage of differentiated tissue, defined as tumor tissue with non-EC morphology in the viable tumor tissue, is shown in Table I. In the experiments with E86-379 and NF-1 (tumors with capacity for spontaneous somatic differentiation), the tumors in the treatment arms containing RA showed a significant increase of the amount of differentiated

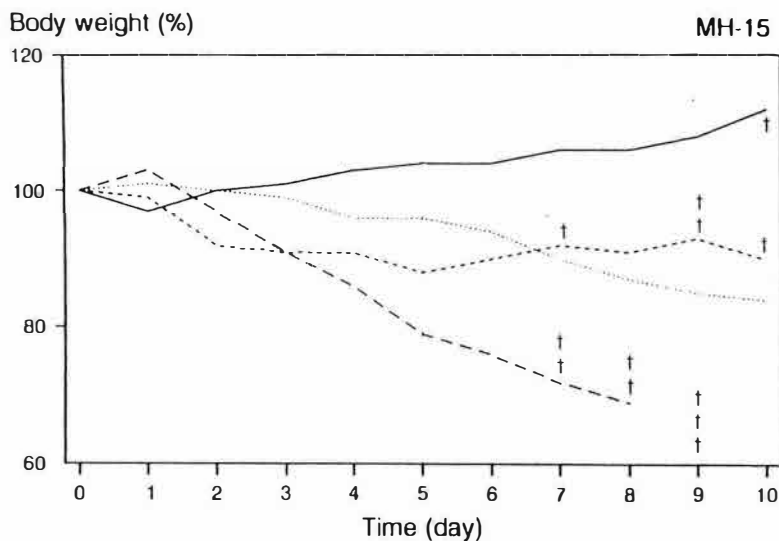


Figure 6. Median body weight of mice of the experiment shown in Fig. 4. The mice were treated in four arms: solvents only (—), RA (-----), CDDP (·····), and RA-CDDP (— — —). Dose reduction of CDDP in the combination group was started on day 5, marked by the vertical line. Loss of body weight is seen in the RA and CDDP groups. RA-CDDP is particularly toxic, as apparent from the severe loss of body weight, and the death of 7 out of 10 mice after day 6.

tissue as compared to the tumors treated with CDDP alone, which tended to reduce the percentage of differentiated tissue, although not significantly. However, in MH-15 tumors (the model lacking spontaneous somatic differentiation), differentiation was not induced by RA alone, or RA-CDDP.

Toxicity.

Toxicity was severe, as shown by the loss of body weight and the death of animals observed in all four experiments, particularly in the treatment arm combining RA and CDDP. The data shown for experiment MH-15 with high dose CDDP (Fig. 6) are representative of the other experiments.

DISCUSSION

Induction of differentiation as a treatment modality for NSGCTs might increase the risk of developing RMT (13), which necessitates surgery for the achievement of a complete remission (17). With cytotoxic drug use, RMT is associated with primary tumors with an

inherent capacity for spontaneous somatic differentiation apparent from a teratoma component. Induction of differentiation might cause RMT to occur also in association with primary tumors lacking spontaneous differentiation, without a teratoma component, as a side effect.

In the present study, we have shown in murine models that the use of RA as differentiation inducing agent indeed increases the percentage of differentiated residual tissue, but only in tumors with the capacity for spontaneous somatic differentiation (NF-1 and E86-379). The nullipotent MH-15 tumor was not induced to differentiate and thus did not give rise to RMT. Rather than having an adverse effect, it turned out that RA alone tended to reduce tumor growth in all models-however, only significantly in the MH-15 tumors (Figs. 4 and 5). In combination with CDDP, RA caused a significant further reduction of tumor growth as compared with CDDP alone. Data on the combination of RA and CDDP are scarce, but our findings are in agreement with those of Nakagawa et al. (18), who found a synergistic effect of CDDP and a retinoid when treating mice with P338 leukemia. In the treatment of two murine models of solid tumors, Ca 755 spontaneous mammary carcinoma and 3 LL Lewis lung carcinoma, vitamin A did not enhance the effect of CDDP (19). The synergistic effect shown by Nakagawa et al (18) in a murine leukemia model is paralleled by the effective induction of differentiation in human hematopoietic malignancies (7,10,11,20).

The additive effect of CDDP and RA in our murine teratoma models is in keeping with studies showing effective induction of differentiation by retinoids in murine embryonal carcinoma *in vitro* (21-23) and *in vivo* (24-26).

In the present experiment, the combination treatment was very toxic, as shown by the severe loss of body weight. We did not analyze the factors contributing to the toxicity in this study, as our goal was to study the effects of induction of differentiation on the development of RMT. Obviously, before expanding these experiments, toxicity should be studied in more detail. In addition, new synthetic retinoids (27) and other differentiation inducers that are less toxic and more effective have to be studied. Conceivably, these new agents can be combined with a lower dose of CDDP (28). Once the problem of the toxicity of the combination therapy in mice has been addressed, Phase I studies may be carried out in humans. Likely candidates for combination treatment with differentiation inducers and chemotherapy are certain embryonal tumors, germ cell tumors, and leukemias.

Acknowledgements

This study was supported by the Dutch Cancer Foundation, Grant GUKC 88-11.

REFERENCES

1. Reiss M, Gamba-Vitalo C, Sartorelli A C. Induction of tumor cell differentiation as a therapeutic approach: preclinical models for hematopoietic and solid neoplasms. *Cancer Treat Rep* 1986;70:201-218.
2. Vugrin D, Chen A, Feigl P, Laszlo J. Embryonal carcinoma of the testis. *Cancer* 1988;61:2348-2352.

3. Pierce G B, Speers W C. Tumors as caricatures of the process of tissue renewal: prospects for therapy by directing differentiation. *Cancer Res* 1988;48:1996-2004.
4. Evans A E, Chatten J, D'Angio G J, Gerson J M, Robinson J, Schnauffer L. A review of 17 IV-S neuroblastoma patients at the children's hospital of Philadelphia. *Cancer* 1980;45:833-839.
5. Look A T, Hayes F A, Nitschke R, McWilliams N B, Green A A. Cellular DNA content as a predictor of response to chemotherapy in infants with unresectable neuroblastoma. *New Engl J Med* 1984;311:231-235.
6. Freshney R I. Induction of differentiation in neoplastic cells. *Anticancer Res* 1985;5:111-130.
7. Gold E J, Mertelsmann R H, Itri L M, et al. Phase I clinical trial of 13-cis-retinoic acid in myelodysplastic syndromes. *Cancer Treat Rep* 1983;67:981-986.
8. Rowinsky E K, Ettinger D S, Grochow L B, Brundrett R B, Cates A E, Donehower R C. Phase I and pharmacologic study of hexamethylene bisacetamide in patients with advanced cancer. *J Clin Oncol* 1986;12:1835-1844.
9. Hassan H T, Rees J. Differentiation induction therapy of myelodysplastic syndromes. *Leuk Res* 1989;13:633-677.
10. Warrell R P, Frankel S R, Miller W H. Differentiation therapy of acute promyelocytic leukemia with tretinoin (all-trans retinoic acid). *N Engl J Med* 1991;324:1485-1493.
11. Muindi J, Frankel SR, Miller WH Jr, Jakubowski A, Scheinberg DA, Young CW, Dmitrovsky E, Warrell RP Jr. Continuous treatment with all-trans retinoic acid causes a progressive reduction in plasma drug concentrations: implications for relapse and retinoid "resistance" in patients with acute promyelocytic leukemia. *Blood* 1992;79:299-303.
12. Collins S J, Robertson K A, Mueller L. Retinoic acid-induced granulocytic differentiation of HL-60 myeloid leukemia cells is mediated directly through the retinoic acid receptor (RAR- α). *Mol Cell Biol* 1990;10:2154-2163.
13. Oosterhuis J W, Suurmeyer A JH, Sleijfer D Th, Schraffordt Koops H, Oldhoff J, Fleuren G J. Effects of multiple-drug chemotherapy (cis-diammine-dichloroplatinum, bleomycine, and vincristine) on the maturation of retroperitoneal lymph node metastases of nonseminomatous germ cell tumors of the testis. No evidence for de novo induction of differentiation. *Cancer* 1983;51:408-416.
14. Oosterhuis JW, Solter D, Knowles BB. Metastasis of teratomas. In: Damjanov I, ed. *The Human Teratomas*. Clifton: Humana Press, 1983:137.
15. Tomayko M M, Reynolds C P. Determination of subcutaneous tumor size in athymic (nude) mice. *Cancer Chemother Pharmacol* 1989;24:148-154.
16. Downie NH, Heath RW. *Basic Statistical Methods*. New York:Harper & Row, 1974.
17. Ulbright T M, Loehrer P J, Roth L M, Einhorn L H, Williams S D, Clark S A. The development of non-germ cell malignancies within germ cell tumors. *Cancer* 1983;54:1824-1833.

18. Nakagawa M, Yamaguchi T, Ueda H, et al. Potentiation by vitamin A of the action of anticancer agents against murine tumors. *Jpn J Cancer Res* 1985;76:887-894.
19. Cattani A, Bresson M L. Vitamin A: failure to demonstrate in mice an anti-tumour effect, whether combined with cytotoxic drugs or not. *Bull Cancer (Paris)* 1986;73:201-206.
20. Picozzi V J, Swanson G F, Morgan R, Hecht F, Greenberg P L. 13-cis retinoic acid treatment for myelodysplastic syndromes. *J Clin Oncol* 1986;4:589-595.
21. Strickland S, Mahdavi V. The induction of differentiation in teratocarcinoma stem cells by retinoic acid. *Cell* 1978;15:393-403.
22. Speers R C. Conversion of malignant murine embryonal carcinomas to benign teratomas. I. Chemical induction of differentiation in vivo. *Cancer Res* 1982;42:1943-1949.
23. Sherman M I, Paternoster M L, Taketo M. Effects of carotinoids upon murine embryonal carcinoma cells. *Cancer Res* 1983;43:4283-4290.
24. Speers W C, Altmann M. Malignant neoplasms of differentiated cells occurring after retinoic acid treatment of murine embryonal carcinomas in vivo. *Cancer Res* 1984;44:2136-2143.
25. McCue P A, Thomas R S, Schroeder D, Gubler M L, Sherman M I. Effects of dietary retinoids upon growth and differentiation of tumors derived from several murine embryonal carcinoma cell lines. *Cancer Res* 1988;48:3772-3779.
26. Jones-Villeneuve E M V, McBurney M W, Rogers K A, Kalnins V I. Retinoic acid induces embryonal carcinoma cells to differentiate into neurons and glial cells. *J Cell Biol* 1982;94:253-262.
27. Hixson E J, Dennine E P. Comparative subacute toxicity of all-trans- and 13-cis- retinoic acid in Swiss mice. *Toxicol Appl Pharmacol* 1978;44:29-40.
28. Ho A D, Martin H, Knauf W, Reichardt P, Trumper L, Hunstein W. Combination of low-dose cytarabine and 13-cis retinoic acid in the treatment of myelodysplastic syndromes. *Leuk Res* 1987;11:1041-1044.

Chapter 4.1

CIS-DIAMMINEDICHLOROPLATINUM(II) RESISTANCE IN VITRO AND IN VIVO IN HUMAN EMBRYONAL CARCINOMA CELLS

Hetty Timmer-Bosscha¹, Albertus Timmer², Coby Meijer¹,
Elisabeth G. E. de Vries¹, Bauke de Jong³, J. Wolter Oosterhuis⁴, Nanno H. Mulder¹

Division of Medical Oncology, Department of Internal Medicine¹, Department of Pathology²,
Department of Medical Genetics³, University Hospital, Groningen. Dr. Daniel den Hoed Cancer
Center, Rotterdam⁴, The Netherlands

ABSTRACT

In the embryonal carcinoma cell line Tera and its 3.7-fold cis-diamminedichloroplatinum(II) (CDDP) resistant subline, Tera-CP, parameters were studied that might have changed in relation to induction of CDDP resistance. Phenotypes of both lines were embryonal carcinoma. Karyotypes were related with a decreased mean number of chromosomes and less copies of the short arm of chromosome 12 in Tera-CP. Tera-CP showed cross resistance for melphalan and 4-hydroperoxycyclophosphamide, had an 1.4-fold increased glutathione (GSH) level, a 1.5-fold increased glutathione S-transferase (GST) activity and a 1.4-fold increased GST π expression compared to Tera. Tera-CP was cross resistant to 5-fluorouracil but thymidilate synthase activity was not increased. Topoisomerase I and II activities and c-myc RNA and protein expression were the same in both lines. Platinum (Pt) accumulation was equal in both lines, Pt-DNA binding was lower in Tera-CP compared to Tera. Both cell lines were xenografted into nude mice and tumours showed marked differentiation. Tera-CP tumours were 2.8-fold resistant to CDDP compared to Tera tumours. In new cell lines derived from xenografts of Tera and Tera-CP sensitivity to CDDP, GST activity, GSH level corresponded with their sensitive and resistant origin. Tera-CP is a model of in vitro and in vivo CDDP resistance with the GSH/GST detoxifying system as an important mechanism. CDDP resistance could be induced without a concomitant increase in differentiation.

INTRODUCTION

Teratocarcinoma, a variant of germ cell tumour of the testis, is the most common form of cancer in young adult men (1). It consists of two histologic components namely embryonal carcinoma (EC) and teratoma (1). EC cells are the stem cells from which the teratoma component derives (2). Clinically EC is highly malignant with a tendency to early metastatic spread, but also a good responder to cis-diamminedichloroplatinum(II) (CDDP) containing chemotherapy (3). In vitro, EC cell lines are known to be more sensitive to CDDP than their more differentiated counterparts (4). Patients with teratocarcinomas treated with CDDP containing chemotherapy regimens, have cure rates of 70-80% (5). However, in the remaining patients, the tumour becomes untreatable due to development of drug resistance.

Resistance to CDDP can be due to a variety of mechanisms. These include, reduced drug accumulation and increased detoxification of CDDP in the cellular cytoplasm. In the cell nucleus decreased DNA accessibility and increased DNA repair may play a role (6,7). The latter accompanied by increased amounts of repair enzymes (7,8). Also changes in the thymidine triphosphate synthesis might be an indication for increased DNA repair, as this process requires a source of deoxynucleotides (8). The net effect of all these systems is reduced DNA platination (Pt-DNA), and thus decreased cytotoxicity, as the Pt-DNA interactions are considered to be the main cytotoxic lesions induced by CDDP (9). However mechanisms of CDDP resistance are not uniform and vary among different cell lines.

In this study we describe a CDDP resistant subline (Tera-CP) of NT2/D1 (Tera, 10) an EC cell line with the capacity to differentiate in vitro. This model enabled us not only to study mechanisms underlying CDDP resistance in extremely sensitive cells, but also to study the effect of serial CDDP incubations on the EC phenotype of the cells. In addition Tera cells in a xenograft in nude mice show a marked differentiation (10), while in contrast Tera in vitro, is mainly composed of EC cells. To investigate the effects of this differentiation on CDDP resistance, Tera and Tera-CP were xenografted into nude mice and tumour sensitivity for CDDP was determined. In new cell lines, derived from the CDDP treated sensitive and resistant xenografts, parameters thought to be relevant for resistance in the primary cell lines were measured, in order to confirm their role in CDDP resistance.

MATERIALS AND METHODS

Chemicals. CDDP and teniposide were obtained from Bristol Myers (Weesp, The Netherlands), doxorubicin from Farmitalia Carlo Erba (Milano, Italy), vincristine from Eli Lilly (St. Cloud, France), melphalan from Wellcome (London, U.K.) bleomycin from Lundbeck (Amsterdam, The Netherlands), and 5-fluorouracil (5-FU) from Hoffman-La Roche (Mijdrecht, The Netherlands). 4-Hydroperoxy-cyclophosphamide (4-HPC) was a gift from ASTA Medica (Frankfurt, Germany). RPMI 1640 medium and fetal calf serum (FCS) were obtained from Life Technologies (Paisley, U.K.), cadmium chloride and 3-(4,5-dimethylthiazol-2-yl)-2,5-diphenyltetrazolium bromide (MTT) from Sigma (St. Louis, MO). Antibodies directed against cytokeratin (CK) 4 (6B10), CK 7 (RCK105), CK 10 (RKSE60), CK 13 (1C7), CK 18 (RGE 53), neurofilaments and vimentin were obtained from Eurodiagnostics (Apeldoorn, The Netherlands), the antibodies AE1/AE3 against a broad spectrum of CKs from Boehringer Mannheim (Mannheim, Germany), and those against

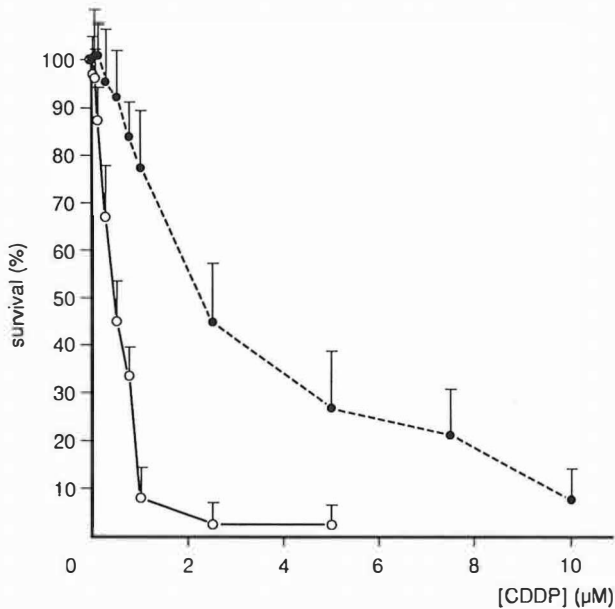


Figure 1. Survival of Tera (o-o) and Tera-CP (●-●) after continuous incubation with CDDP measured by microculture tetrazolium assay ($n = 3$, bars = SD). Survival of Tera and Tera-CP is significantly different from 0.1 to 5 μM CDDP.

desmin and glial fibrillar acidic protein (GFAP) from DAKO (Glostrup, Denmark). The antibodies against CK 5 and 8 (M102) and CK 8, 18 and 19 (M5D3) were a gift from F. Raemakers (University of Maastricht, The Netherlands). The c-myc antibody OM-11-908 was purchased from Cambridge Research Biochemicals (Northwich, U.K.). The Bio-Rad Immuno-blot assay kit was obtained from Bio-Rad (Richmond, CA) and Tissue-Tek II O.C.T. compound from Miles Laboratories (Naperville, Ill).

Cell lines and production of resistance. Tera, kindly provided by P. W. Andrews, is an EC clone of a teratocarcinoma cell line, with the capacity to differentiate *in vitro* as well as *in vivo* (10). *In vitro* it consists of nearly homogeneous EC populations when kept at high cell density (a minimum of 1.5×10^6 cells in a 25 cm² flask) (10). Cells are growing as a monolayer in RPMI 1640 medium supplemented with 10 % FCS in a humidified atmosphere with 5 % CO₂ at 37°C. For production of the CDDP resistant subline, Tera-CP, cells were incubated with CDDP for one hour and subsequently resuspended in fresh medium. This was repeated after cell recovery, (determined by light microscopic observation), with stepwise increasing doses of CDDP. Every CDDP dose was added three times. Each cell recovery took about three to four weeks. The first dose of CDDP was 12.5 μM , the CDDP concentration inducing 90 % kill in the Tera line after a one hour incubation. The final dose, after 11 months was 100 μM CDDP.

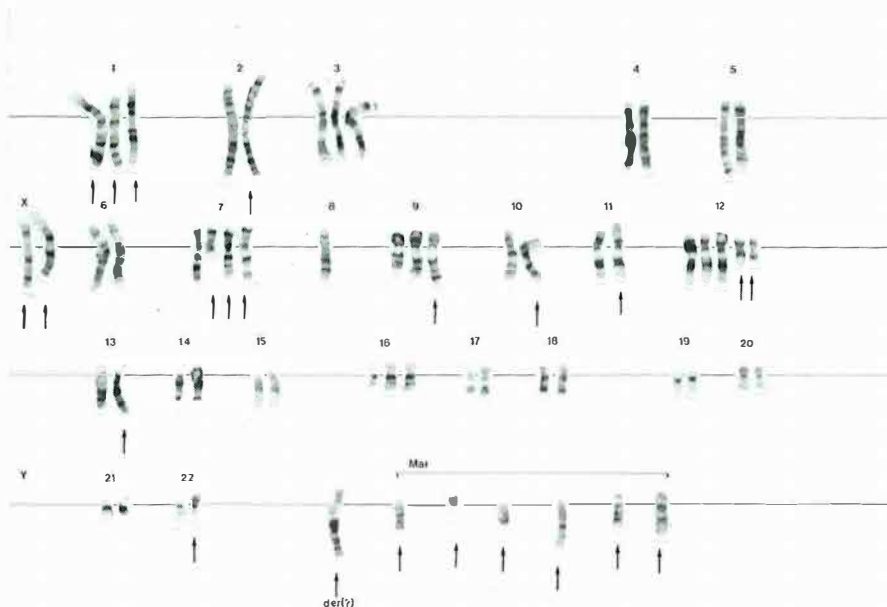


Figure 2. Representative karyotype of Tera. Description: 61, add(X)(q23), -Y, +der(X)t(x;1)(p11;p22), del(1)(p36), der(1)t(X;1)(p11;p13), +i(1)(p10), add(2)(p16), +3, del(7)(q11), +der7, add(7)(p21)t(1;7)(q25;q11.2), +der(7)t(7;17)(q22;q12), -8, +add(9)(q22), add(10)(p12), add(11)(p11), +12, +i12(p10)x2, add(13)(q21), +16, add(22)(p12), +der(?)t(?;2)(?:q14), +6mar.

Cell cycle distribution was determined by screening bromodeoxyuridine incorporation and propidium iodine intensity as described by Preisler et al.(11) with a FACS-tar flow cytometer (Becton Dickinson, Sunnyvale, CA).

Karyotype. To cells of Tera and Tera-CP in logarithmic phase of growth 0.05 μ g colcemid /ml culture medium was added, two hours before harvesting. Chromosomes were GTG banded. From Tera five and from Tera-CP seven metaphases were karyotyped.

The differentiation state of Tera and Tera-CP was determined by cellular antigen expression using immunocytochemistry. For these determinations the antibodies anti-SSEA-1 (12), anti-SSEA-3 (13), TRA-1-60 and TRA-1-81 (14), anti-vimentin, anti-desmin, anti-neurofilaments, anti-GFAP as well as antibodies against CKs (obtained as described in the chemical section) were used. Experiments were repeated at least three times.

Cytotoxicity. For cytotoxicity measurements the microculture tetrazolium assay was used (15). For Tera and Tera-CP 10,000 cells per well were incubated continuously with CDDP, doxorubicin, vincristine, melphalan, bleomycin, teniposide, cadmium chloride, and 4-HPC. After a four day culture period MTT was added and after 3 hours and 45 min incubation at 37°C formazan production was measured. Cross resistance, for the drugs mentioned above was indicated by a resistance factor (RF, the ratio IC₅₀ Tera-CP over IC₅₀ Tera; ID 50 = drug concentration reducing cell survival by 50 %). The mean ID 50 \pm SD was determined in three independent experiments each performed in quadruplicate.

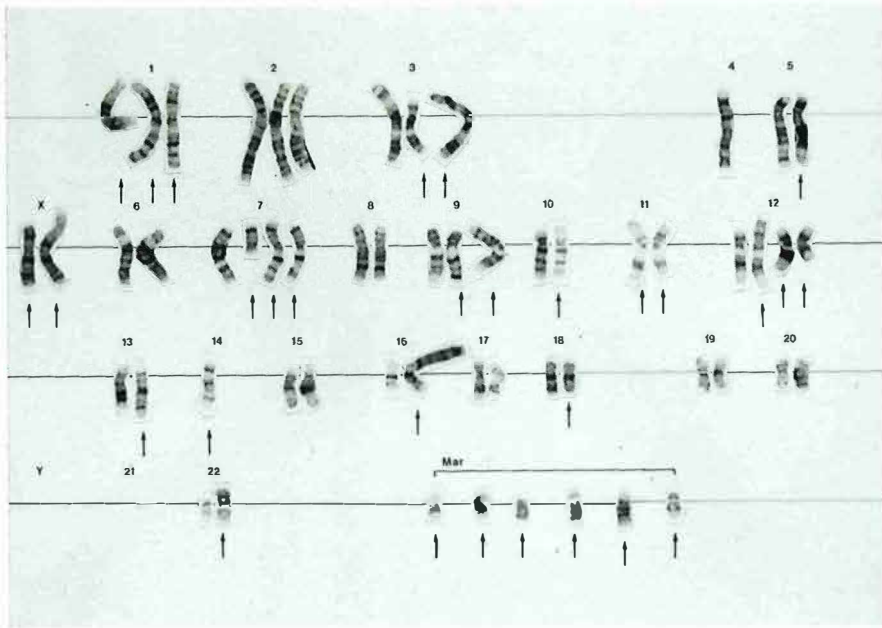


Figure 3. Representative karyotype of Tera-CP. Description: 56,add(X)(q23),-Y, +der(X)t(X;1)(p11;p22),add(1)(q11);del(1)(p36),+der(1)t(X;1)(p11;p13)add(X)(p22), +2,der(3)add(3)(p11)del(3)(q21q23),+der(3)(3qter→3q11::?:3q11→3p24::?), -4,del(5)(q33),del(7)(q11),der(7)add(7)(p21)t(1;7)(q25;q11.2),+der(7)t(7;17)(q22;q12),add(9)(q22), der(9)t(9;14)(p11;q11),add(10)(p12),add(11)(p11),add(11)(q14),add(12)(p11),+del(12)(q14q21), +i(12)(p10),add(13)(q22),-14, add(14)(p10),der(16)t(4;16)(q12;p13.3),del(18)(q22),-21,-21,add(22)(p12),+6mar.

Detoxifying system. The conditions and measurements for glutathione (GSH), total sulfhydryl groups (TSH) and glutathione S-transferase (GST) in the cell lines were as described before (16). The GST π isoenzyme was measured in Tera and Tera-CP using SDS-polyacrylamide gel electrophoresis (SDS-PAGE) followed by Western blotting and subsequent incubation with a monoclonal antibody raised against GST π (17). Reported values are the mean of three independent cell protein extracts.

Thymidilate synthase. In Tera and Tera-CP the catalytic activity of thymidilate synthase and the binding of 5-fluoro-2'-deoxyuridine 5'-monophosphate (FdUMP) to thymidilate synthase were determined as previously published (18, 19). Measurements were repeated three times in independent cell protein extracts.

c-Myc. Tera and Tera-CP were screened for c-myc amplification by Southern blot and for c-myc expression at RNA level by northern blot, using a 1.2 kb SacI fragment from the second exon of human c-myc as a probe (20). For c-myc protein expression SDS-PAGE was performed (21) followed by Western blotting, after transfer of proteins by semi dry-blot, c-myc was detected with OM-11-908 and the Bio-Rad Immuno-blot assay kit for visualization.

DNA topoisomerases. The topoisomerase II catalytic activity in 0.35 M NaCl nuclear extracts of cells in logarithmic phase of growth was measured by the decatenation of

kinetoplast DNA networks (22). Topoisomerase I activity in the same extracts was assayed by relaxation of supercoiled pBR322 DNA (22).

Table 1. Cellular characteristics of Tera and Tera-CP expressed as mean \pm SD (n \geq 3)

		Tera	Tera-CP	p-value ^a
Population doubling time (h)		14 \pm 0.6	14 \pm 1.1	ns ^b
Cell cycle distribution (%)	G0/G1	33.3 \pm 2.1	38.2 \pm 6.6	ns
	S	47.1 \pm 5.0	45.5 \pm 3.6	ns
	G2/M	15.1 \pm 3.9	10.1 \pm 3.3	ns
Cellular protein (mg/10 ⁷ cells)		2.33 \pm 0.62	2.41 \pm 0.65	ns
Nuclear protein (μ g/10 ⁶ nuclei)		27.4 \pm 2.6	34.0 \pm 7.6	ns
DNA (μ g/10 ⁶ nuclei)		17.5 \pm 2.0	13.0 \pm 3.0	p < 0.01

^a mean Tera versus mean Tera-CP. ^b ns: not significant

Table 2. Sensitivity measured by microculture tetrazolium assay after continuous drug incubation of Tera and Tera-CP for various drugs expressed as IC50 \pm SD (n = 3-5)

Drugs	IC50 Tera	IC50 Tera-CP	RF	p-value ^a
CDDP (μ M)	0.69 \pm 0.10	2.57 \pm 0.74	3.7	< 0.0005
CdCl ₂ ^b (μ M)	157 \pm 10	151 \pm 19	1.0	ns ^c
Doxorubicin (nM)	12.8 \pm 3.2	16.1 \pm 4.5	1.3	ns
Vincristine (nM)	0.97 \pm 0.16	1.22 \pm 0.07	1.3	< 0.05
4-HPC (μ M)	2.56 \pm 0.70	5.16 \pm 1.80	2.0	< 0.01
Melphalan (μ M)	0.98 \pm 0.30	1.82 \pm 0.42	1.9	< 0.025
Bleomycin (μ g/ml)	0.16 \pm 0.03	0.23 \pm 0.13	1.3	ns
Teniposide (nM)	11.9 \pm 0.6	15.9 \pm 2.3	1.3	< 0.025
5-FU (μ M)	3.8 \pm 0.7	8.7 \pm 1.1	2.3	< 0.0025

^a IC50 Tera versus IC50 Tera-CP. ^b cadmium chloride. ^c ns: not significant

Platinum measurements. For cellular platinum (Pt) determinations 7.5 x 10⁶ cells were incubated with CDDP concentrations ranging from 10 to 67 μ M for two hours, cells were washed with PBS three times at 0°C. Dry pellets were dissolved in concentrated nitric acid and Pt was measured with atomic absorbance spectrophotometry (AAS) as described before (16). For determination of the amount of Pt bound to DNA 5x10⁷ cells were incubated with CDDP concentrations ranging from 16.7 to 67 μ M for 4 hours, cells were washed with PBS three times at 0°C; DNA was isolated, dissolved in 200 μ l of 1 M HCl, the amount of Pt was measured by AAS (detection threshold 2.5 pmol Pt), and the amount of DNA by

extinction at 260 nm as described before (16). The amount of DNA per sample analyzed was 10-20 μg . The reported values are the mean of three independent experiments.

In vivo experiments. In order to xenograft Tera or Tera-CP 5×10^6 cells of either cell line were injected subcutaneously in the left shoulder of male, athymic (nude) mice. Relative tumour size was determined using three-dimensional measurements, length x width x height, in millimetres (23). After the tumours had reached a relative size of 1000, the tumours were excised. For in vivo CDDP treatment tumour fragments of approximately 5 mm^3 of Tera tumours (TeraX) or Tera-CP tumours (Tera-CPX) were inoculated subcutaneously in the shoulder of four mice per tumour type. When again relative tumour size was 1000, CDDP was administered intraperitoneally at a dose of 5 mg/kg body weight to mice either bearing TeraX or Tera-CPX. After CDDP administration tumour size was measured daily with callipers. At the moment the tumour measures were equal at two consecutive days (defined as start of regrowth), tumours were excised, and divided. One part was snap-frozen in Tissue-Tek II O.C.T. compound for cryoembedding, one part embedded in paraffin after formaldehyde fixation and remaining parts were brought into in vitro culture again. In vivo anti-tumour effects were evaluated in terms of decrease in relative tumour size and as the time, expressed in days, between the administration of CDDP and the start of regrowth. The cultures set up from TeraX and Tera-CPX after CDDP treatment were named Teram(n) and Tera-CPm(n) respectively. In these lines CDDP sensitivity, with the microculture tetrazolium assay ($n = 2$, for each cell line), cellular GSH level and GST activity were determined ($n \geq 3$).

For statistical analyses the unpaired Student's t-test was used. Differences were considered significant when p-values were < 0.05 .

RESULTS

The cell line Tera-CP was defined, with a RF of 3.7 for CDDP, after treatment of cells as described in Materials and Methods, with a final induction dose of 100 μM . In order to ensure stable resistance, proved by microculture tetrazolium assay, all experiments were performed within 14 weeks after the last one hour CDDP incubation of Tera-CP. Every 14 weeks a fresh culture of Tera-CP was started from a liquid nitrogen frozen stock.

In Figure 1 the survival curve of Tera and Tera-CP, after continuous incubation with CDDP, is shown. Tera-CP cells, grow as a monolayer. Doubling time, cell cycle distribution, cellular and nuclear protein as well as relative cell size of Tera-CP cells were comparable with Tera cells (Table 1). Tera-CP had a lower DNA content than Tera (Table 1).

Chromosome analysis of Tera and Tera-CP revealed a strongly abnormal chromosomal pattern with a modal chromosome number of 61 (range 60-62) in Tera and of 57 (range 56-61) for Tera-CP. Figure 2 shows one of the karyotypes from Tera (see legend Figure 2 for a description). All abnormalities described are clonal. Also clonal are an add(1)(p13) and der(1)add(1)(q24)del(1)(p36). Figure 3 shows one of the karyotypes of Tera-CP (see legend Figure 3 for a description). Of the described abnormalities the add(14)(p10) and one -21 were not clonal, while der(9),add(9)(q31) add(9)(p11),der(1) t(X;1)(p11;p13) and add(6)(q13) were other clonal abnormalities. In Tera between five and nine copies of 12p while in Tera-CP four to five copies of 12p were found per karyotype.

The differentiation states of Tera and Tera-CP were comparable. Expression of TRA-1-60 and TRA-1-81 was found in all cells, both cell lines were SSEA-3 positive in >90 % of the cells, and SSEA-1 negative in 80 -90% of the cells, indicating an EC phenotype. A weak AE 1/AE 3 reaction was found, and with the more specific monoclonal antibodies M102, RGE53 and M5D3 CKs were characterized as CK 8 and 18. Neither desmin, nor GFAP positive cells, were detected in the lines. In Tera as well as Tera-CP 50-100% of the cells contained vimentin. Neurofilaments were occasionally found in a few cells.

Cross resistance was clearly demonstrated for 4-HPC, melphalan and 5-FU, with RFs of 2.0, 1.9 and 2.3 respectively (Table 2). For the other drugs mentioned in Table 2 minimal or no cross resistance was found.

Cellular GSH and GST activity were increased in Tera-CP compared to Tera (Table 3). Western blot analysis revealed an 1.4-fold increased GST π in Tera-CP compared to Tera. Cellular TSH was comparable in both lines (Table 3). Thymidilate synthase catalytic activity and the FdUMP binding of thymidilate synthase were slightly lower in Tera-CP than in Tera, although not statistically significant (Table 3). Neither c-myc gene amplification nor differences in c-myc expression at RNA or protein level between Tera and Tera-CP were detected. Topoisomerase II activity was comparable for Tera and Tera-CP. In a serial dilution of nuclear extract complete decatenation was still found with 100 ng protein in a lane for both lines while with 50 ng protein no decatenated kinetoplast DNA band was seen. In the topoisomerase I activity assay complete relaxation was still seen with 2.5 ng nuclear protein per lane, 1.25 ng protein gave partial relaxation and with 0.63 ng protein or less no relaxing activity was found for both Tera and Tera-CP.

Table 3. Amount and activity of detoxifying system related and DNA related compounds / enzymes measured as described in reference 21, in Tera and Tera-CP; data are given as mean \pm SD, (n \geq 3)

	Tera	Tera-CP	p-value ^a
GSH (μ g/mg protein)	1.89 \pm 0.16	2.56 \pm 0.39	<0.05
TSH (μ g/mg protein)	65.7 \pm 10.1	60.7 \pm 9.6	ns ^b
GST activity (nmol CDNB/mg protein.min)	95 \pm 8	146 \pm 8	<0.0025
GST π (relative expression)	1	1.4	
Thymidilate synthase:			
-binding (fmol/mg protein)	3677 \pm 2259	2284 \pm 1252	ns
-activity at 1 μ M substrate (pmol/mg prot.h)	741 \pm 167	552 \pm 121	ns
-activity at 10 μ M substrate (pmol/mg prot.h)	3842 \pm 1515	3293 \pm 688	ns

^a mean Tera versus mean Tera-CP. ^b ns: not significant

Cellular Pt accumulation after 2h CDDP incubation was equal in both lines (Figure 4A). Pt bound to DNA, shown in Figure 4B, after 4 hours CDDP incubation was decreased in Tera-CP compared to Tera (33 μ M and 67 μ M, p < 0.025).

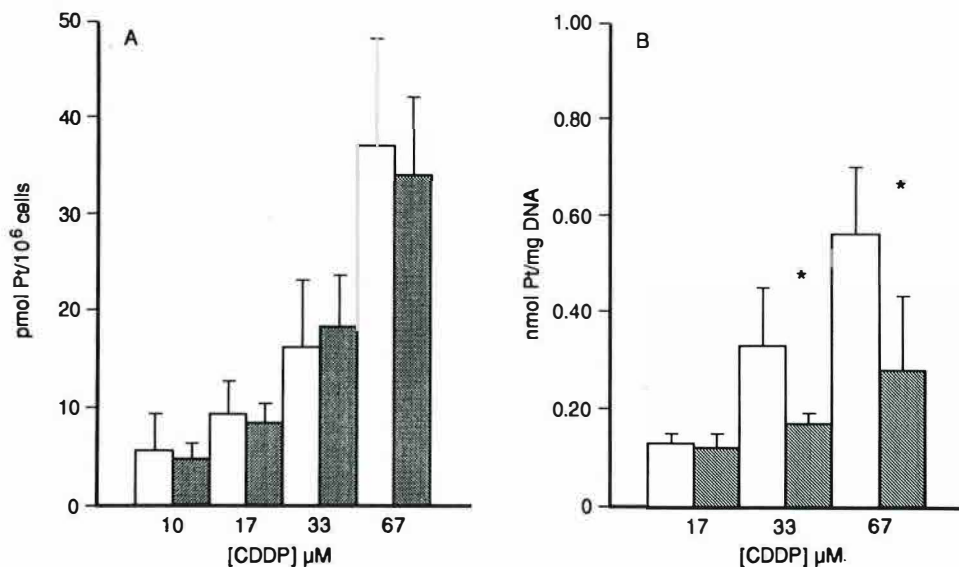


Figure 4. Cellular Pt accumulation after 2 hours CDDP incubation (A) and total Pt bound to DNA after 4 hours CDDP incubation (B) of Tera and Tera-CP, as measured by AAS. $n = 3$ (A), $n = 5$ (B), bars = SD. * = difference at 33 and 67 μM is significant ($p < 0.025$).

In vivo CDDP sensitivity parameters, tumour measurements and time to the start of regrowth, are shown in Figure 5A and 5B. After a single dose of CDDP the mean percentage tumour reduction for TeraX was $73 \pm 13\%$ ($n = 3$) and $26 \pm 15\%$ for Tera-CPX ($n = 4$), TeraX vs. Tera-CPX: $p < 0.005$). The time passing until tumour regrowth was 10.7 ± 3.1 days for TeraX ($n = 3$) and 5.5 ± 0.8 for Tera-CPX ($n = 4$, TeraX vs. Tera-CPX: $p < 0.025$).

From three mice with TeraX cell lines Teram2, Teram3, Teram4, and from four mice with Tera-CPX cell lines Tera-CPm1, Tera-CPm2, Tera-CPm3, Tera-CPm4 were set up. CDDP sensitivity of these cell lines reflected the sensitivity of Tera and Tera-CP respectively (Figure 6). Cellular GSH levels of Teram's and Tera-CPm's as well as their respective GST activities are shown in Figure 7. The mean amounts of GSH were 1.6 ± 0.6 ($n=10$) and 2.1 ± 0.5 ($n=14$) $\mu\text{g}/\text{mg}$ protein in the Teram-group and the Tera-CPm-group, respectively (Teram vs. Tera-CPm: $p < 0.05$). GST activity was significantly increased ($p < 0.0025$) in the Tera-CPm-group compared to the Teram-group, means were 192 ± 59 ($n=9$) and 120 ± 27 ($n=13$) $\text{nmol CDNB}/\text{min}.\text{mg}$ protein, respectively.

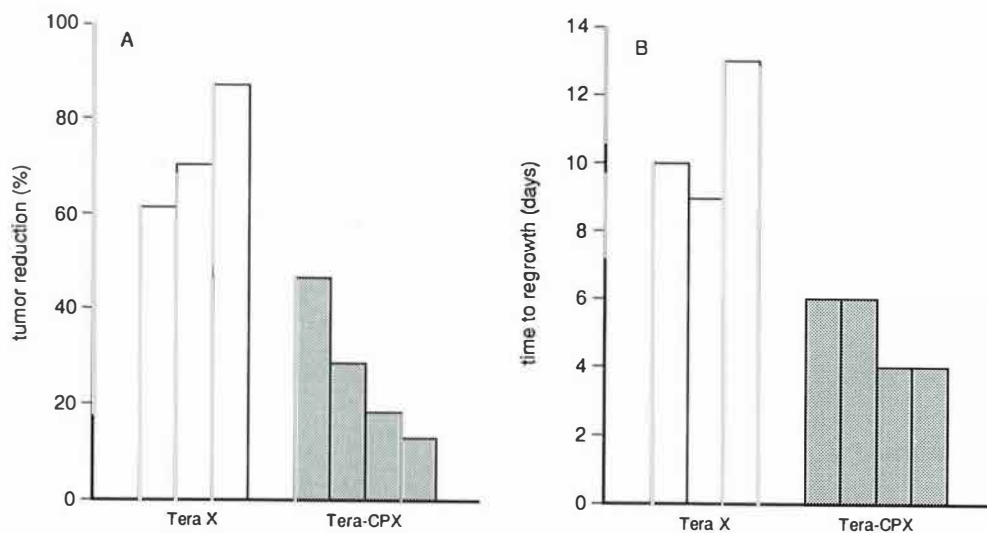


Figure 5. Maximal tumour reduction as a percentage of the tumour volume at day one (A) and the time passing to regrowth (B) of TeraX and TeraCPX after a single dose of 5 mg/kg CDDP i.p. at day one. Differences between the group of sensitive and resistant tumours are significant (tumour reduction, A, $p < 0.005$; regrowth, B, $p < 0.025$).b

DISCUSSION

The development of resistance to CDDP, a drug exquisitely effective in teratocarcinomas, has severe clinical consequences. Since the understanding of the mechanisms underlying this resistance may lead to determination of ways to prevent or to circumvent resistance induction, the development of models that permit such studies is relevant. In this report we present an EC cell line with a level of CDDP resistance that is comparable with that found in other human cell lines with an in vitro acquired resistance (7, 16, 24).

Cytogenetic analysis of Tera and Tera-CP revealed a strongly abnormal chromosomal pattern with a lower chromosome number in Tera-CP than in Tera. The two cell lines had 13 chromosomal abnormalities in common, pointing to their relationship. In addition Tera has five and Tera-CP 13 unique structural abnormalities. The chromosome number of both cell lines is in the range of primary testicular germ cell tumours, the number of abnormalities of the cell lines is higher¹. Both Tera and Tera-CP showed the i(12p), found in about 80% of all testicular germ cell tumours (25). In addition Tera-CP showed a del(12) (q14q21). Allelic deletions in this region are frequently observed, 12q13 and 12q22 might be the chromosomal location of a tumour suppressor gene (26). All karyotyped cells of Tera showed

¹J.van Echten, Submitted

besides three normal copies of chromosome 12, one (3 x), two and three copies of the i(12p), so between five and nine copies of 12p. The seven karyotyped cells of Tera-CP showed one or two normal chromosomes 12 and one copy of i(12p). In all seven cells the del(12)(q14q21) was found and in four cells the add(12) (p11.2). So the number of 12p copies in Tera-CP is either three or four. Bosl et al. (27) found in male germ cell tumours the presence of three or more additional copies of 12p associated with a greater likelihood of treatment failure. As both cell lines show three or more additional 12p copies, in this in vitro model no evidence for a positive correlation between CDDP resistance and number of copies of 12p is found.

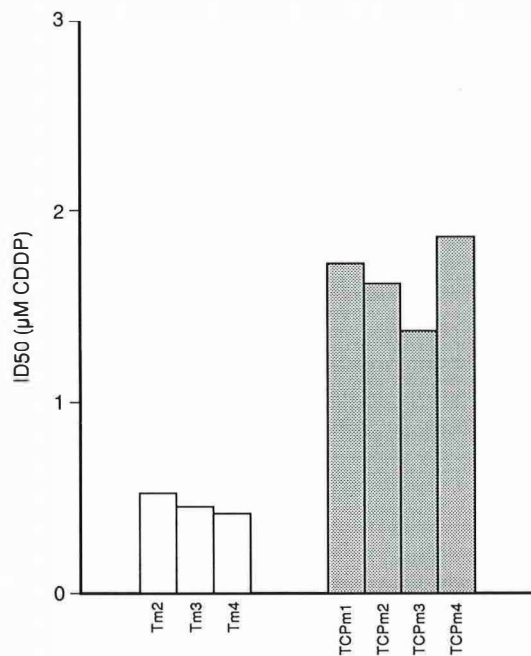


Figure 6. The IC50s for CDDP, measured by microculture tetrazolium assay after continuous incubation of the cell lines derived from Tera xenografts, T(era)m2, -m3, -m4 and of the lines derived from Tera-CP xenografts, T(era)-CPm1, -m2, -m3, -m4. Each bar represents 2 independent determinations, SD's were $\leq 15\%$. Difference in IC50 between the group of sensitive and the group of resistant cell lines was significant ($p < 0.0005$).

Immunocytochemistry demonstrated that both cell lines mainly consisted of EC. The amount of SSEA-1 positive cells was higher than data reported in the literature (10). This is probably due to the long time during which cells were cultured in vitro, in order to keep their passage number comparable with that of Tera-CP, combined with the tendency to differentiation shown by the cell line. The expression of neurofilaments in both lines suggests an early neuro-epithelial differentiation in some cells. The relevance of the presence of

vimentin in cultured cells as a parameter of differentiation *in vitro* is uncertain as it is described to vary with culture conditions (28). Differentiated germ cell tumour cells are found to be more resistant to CDDP than EC cells (4). But in Tera-CP resistance to CDDP in EC cells was induced without a concomitant increase in differentiation. In addition the marked differentiation of TeraX and Tera-CPX (determined by morphometry of tumour slides, data not shown) shows that differentiation of the cells, in the *in vivo* model, does not influence their degree of resistance (*in vivo* RF = 2.8, based on differences in tumour reduction). This close correlation of *in vitro* and *in vivo* degree of resistance also excludes a role for *in vivo* active, tumour associated, factors that influence the pharmacokinetics of CDDP in this nude mice model, a phenomenon described for a model with *in vivo* acquired resistance (29).

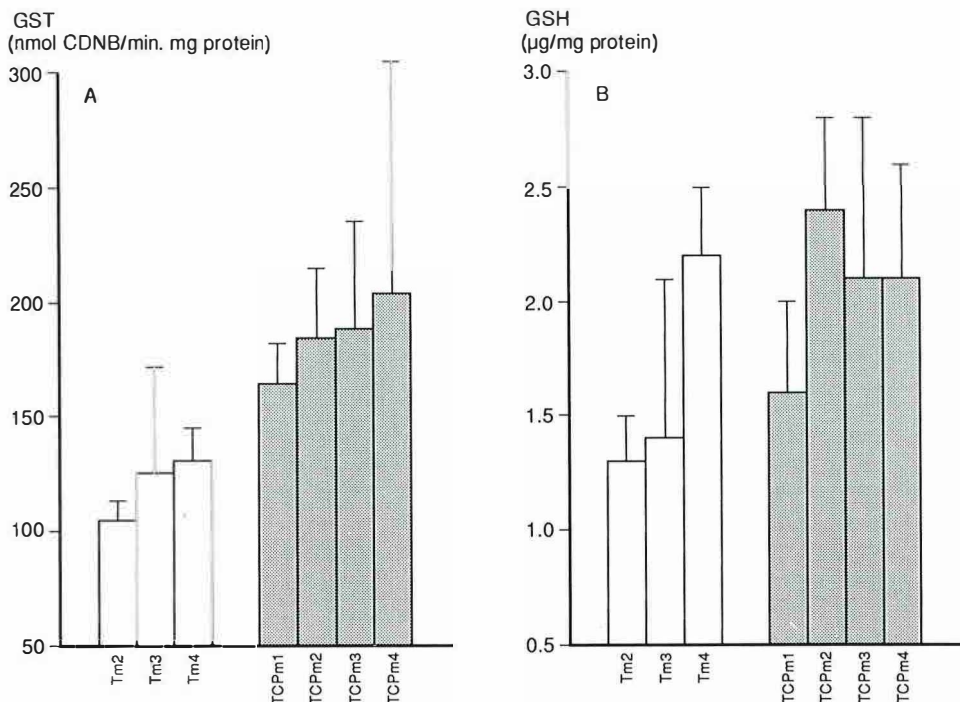


Figure 7. Cellular GST activity (A) and the cellular amount of GSH (B) of the cell lines derived from Tera xenografts, T(era)m2, -m3, -m4 and of the cell lines derived from Tera-CP xenografts, T(era)-CPm1, -m2, -m3, -m4. Bars = SD, n = 3-4 (GST), or n = 3-5 (GSH). Differences between the group of sensitive and the group of resistant cell lines were significant (GST: $p < 0.0025$; GSH $p < 0.05$).

There were no differences in cellular TSH level between Tera and Tera-CP and no cross resistance for cadmium chloride was observed. This indirectly indicates that cellular methallothionein content, does not play a role in this model, although a role for these proteins

is described in an other CDDP resistant germ cell tumour cell line (24). Elevated GSH levels are found to be part of the CDDP resistant phenotype in several studies but not all (30). Also depletion of GSH in resistant cells did not always lead to sensitization to CDDP (30). A causative role of GSH in CDDP resistance therefore remains unclear. In Tera-CP GSH levels were increased, which is compatible with the cross resistance of Tera-CP to melphalan (31) and 4-HPC (32). It was demonstrated that Tera-CP could be sensitized to CDDP by depletion of cellular GSH with D,L,-buthionine-S,R-sulfoximine upto 50 % reduction in RF (33). As GSH seemed to be a possible mechanism of resistance in Tera-CP, it was measured in the cell lines Teram and Tera-CPm created after passage through mice. In Teram4, although CDDP sensitivity was comparable with the other Teram lines, GSH level was comparable with that of the Tera-CPm lines. This increase in GSH without a concomitant decrease of sensitivity, indicates that an increased amount of GSH alone does not necessarily predict for drug resistance. Other mechanisms that influence CDDP sensitivity but that were not determined here might play a role.

GST activity was elevated in Tera-CP. It was also consistently high and low in respectively the resistant, Tera-CPm, and the sensitive, Teram, lines. This together with a report about the low activity of GST in testicular germ cell tumour samples compared with adjacent normal testicular tissue (34), indicates that GST activity could be an important marker of tumour cell CDDP sensitivity in germ cell tumours. The role of the GST isoenzyme GST π is controversial in CDDP resistance. Low levels in small cell lung cancer cells correlated with sensitivity to CDDP (35). In CDDP resistant sublines of Chinese hamster ovary cells the observed increased mRNA and protein expression of GST π were normalized in a revertant subline (36). But transfection of the GST π gene into NIH3T3 and MCF7 cells did not decrease CDDP sensitivity of these cells (35, 37), and in two CDDP resistant small cell lung cancer cell lines GST π mRNA overexpression was found in only one of the two cell lines (38). In our model GST was especially present as the isoenzyme GST π , which is in accordance with the relatively high amount of GST π found by Strohmeyer et al. (34) in germ cell tumours compared to normal testicular tissue. Immunohistochemistry of other germ cell tumours also demonstrated that GST π was the predominant isoenzyme in EC cells, but did not correlate with response to therapy (39).

In contrast to a CDDP resistant germ cell tumour cell line described by Kelland et al. (24) accumulation defects did not seem to play a role in Tera-CP. The observed decreased binding of Pt to DNA might therefore be due to an increased efficacy of the detoxifying system, leading to increased scavenging of reactive CDDP metabolites in the cellular cytosol. On the other hand an effect of GSH on Pt-DNA adduct formation and/or repair has been described (40, 41). Out of many indicators of DNA repair and handling topoisomerase I and II were studied because of their potential role in CDDP resistance. While in other CDDP resistant cell lines increased topoisomerase I (42) and II (43) activities have been reported, we could not demonstrate an altered activity of the DNA topoisomerases in the resistant line. Although cross resistance for 5-FU could be an indication for an increased thymidine metabolism in the resistant cell line (44), the FdUMP binding capacity and the activity of thymidilate synthase found in Tera-CP, however, showed a tendency to be decreased. The cross-resistance to 5-FU could be due to an alteration in cellular reduced folate levels in Tera-CP, as the complexation of the 5-FU metabolite FdUMP to thymidilate synthase is stabilized by such reduced folates.

Tera and Tera-CP are a good model for in vitro and in vivo CDDP resistance. The total binding of Pt to DNA was reduced probably due to an increased efficacy of the

detoxifying system. Induction of CDDP resistance did not affect the EC phenotype of Tera-CP. The model can be used for testing modulators of CDDP sensitivity and for studying the correlation between CDDP resistance and phenotype of germ cell tumours.

Acknowledgements

The authors wish to thank Dr. W.H.M.Peters (Nijmegen, The Netherlands) and J.Prins for Western blots of GST π and c-myc, respectively and T.K.P. Le for technical assistance. This study was supported by grants GUKC 88-11 and 90-18 from the Dutch Cancer Foundation.

REFERENCES

1. Mostofi, F.K. Testicular tumours: epidemiologic, etiologic and pathologic features. *Cancer* 32: 1186-1201, 1973.
2. Damjanov, I. Teratocarcinoma stem cells. *Cancer Surv.* 9: 303-320, 1990.
3. Vugrin, D., Chen, A., Feigl, P., and Laszlo, J. Embryonal carcinoma of the testis. *Cancer* 61: 2348-2352, 1988.
4. Oosterhuis, J.W., Andrews, P.W., Knowles, B.B., and Damjanov, I. Effects of cis-platinum on embryonal carcinoma cell lines in vitro. *Int.J.Cancer* 34: 133-139, 1984.
5. Loehrer, P.J., and Einhorn, L.H. Cisplatin. *Ann.Intern.Med.* 100: 704-713, 1984.
6. Andrews, P.A., and Howell, S.B. Cellular pharmacology of cisplatin: Perspectives on mechanisms of acquired resistance. *Cancer Cells* 2: 35-43, 1990.
7. Kelly, S.L., and Rozenzweig, M. Resistance to platinum compounds: Mechanisms and beyond. *Eur.J.Cancer Clin.Oncol.* 25: 1135-1140, 1989.
8. Scanlon, K.J., Kashani-Sabet, M., Miyachi, H., Sowers, L.C., and Rossi, J. Molecular basis of cisplatin resistance in human carcinomas: model systems and patients. *Anticancer Res.* 9: 1301-1312, 1989.
9. Roberts, J.J., and Friedlos, F. Quantitative estimation of cisplatin-induced DNA interstrand cross-links and their repair in mammalian cells: relationship to toxicity. *Pharmac.Ther.* 34: 215-246, 1987.
10. Andrews, P.W., Damjanov, I., Simon, D., Banting, G.S., Carlin, C., Dracopoli, N.C., and Føgh, J. Pluripotent embryonal carcinoma clones derived from the human teratocarcinoma cell line Tera-2. Differentiation in vivo and in vitro. *Lab.Invest.* 50: 147-162, 1984.
11. Preisler, H.D., Gopal, V., Banavali, S.D., Finke, D., and Bokari, S.A.J. Multiparameter assessment of the cell cycle effects of bioactive and cytotoxic agents. *Cancer Res.* 52: 4090-4095, 1992.

12. Solter, D., and Knowles, B.B. Monoclonal antibody defining a stage-specific mouse embryonic antigen (SSEA-1). *Proc.Natl.Acad.Sci.USA* 75: 5565-5569, 1978.
13. Shevinsky, L.H., Knowles, B.B., Damjanov, I., and Solter, D. Monoclonal antibody to murine embryos defines a stage-specific embryonic antigen expressed on mouse embryos and human teratocarcinoma cells. *Cell* 30: 697-705, 1982.
14. Andrews, P.W., Banting, G.S., Damjanov, I., Arnaud, D., and Auner, P. Three monoclonal antibodies defining distinct differentiation antigens associated with different high molecular weight polypeptides on the surface of human embryonal carcinoma cells. *Hybridoma* 3: 347- 361, 1984.
15. Timmer-Bosscha, H., Hospers, G.A.P., Meijer, C., Mulder, N.H., Muskiet, F.A.J., Martini, I.A., Uges, D.R.A., and de Vries, E.G.E. Influence of docosahexaenoic acid on cisplatin resistance in a human small cell lung carcinoma cell line. *J.Natl.Cancer Inst.* 81: 1069-1075, 1989.
16. Hospers, G.A.P., Mulder, N.H., de Jong, B., de Leij, L., Uges, D.R.A., Fichtinger-Schepman, A.M.J., Scheper, R.J., and de Vries, E.G.E. Characterization of a human small cell lung carcinoma cell line with acquired resistance to cis-diamminedichloroplatinum(II) in vitro. *Cancer Res.* 48: 6803-6807, 1988.
17. Peters, W.H.M., Nagengast, F.M., and Wobbes, T., Glutathione S-transferases in normal and cancerous human colon tissue. *Carcinogenesis* 12: 2371-2374, 1989.
18. Peters, G.J., Laurensse, E., Leyva, A., Lankelma, J., and Pinedo, H.M. Sensitivity of human, murine, and rat cells to 5-fluorouracil and 5'-deoxy-5-fluorouridine in relation to drug-metabolizing enzymes. *Cancer Res.* 46: 20-28, 1986.
19. Spears, C.P., Shahinon, A.H., Moran, R.G., Heidelberger, C., and Corbett, T.H. In vivo kinetics of thymidilate synthase inhibition in 5-fluorouracil-sensitive and -resistant murine colon adenocarcinomas. *Cancer Res.* 42: 450-456, 1982
20. Kok, K., Osinga, J., Schotanus, D.C., Berendsen, H.H., de Ley, L.F.M.H., and Buys, C.H.C.M. Amplification and expression of different myc family genes in a tumour specimen and 3 cell lines derived from one small-cell lung cancer patient during longitudinal follow-up. *Int.J.Cancer* 44: 75-78, 1989.
21. Laemmli U.K. Cleavage of structural proteins during the assembly of the head of bacteriophage T4. *Nature* 227: 680-685, 1970.
22. de Jong, S., Zijlstra, J.G., de Vries, E.G.E., and Mulder, N.H. Reduced DNA topoisomerase II activity and drug-induced DNA cleavage activity in an adriamycin-resistant human small cell lung carcinoma cell line. *Cancer Res.* 50: 304-309, 1990.
23. Tomayko, M.M., and Reynolds, C.P. Determination of subcutaneous tumour size in athymic (nude) mice. *Cancer Chemother.Pharmacol.* 24: 148-154, 1989.
24. Kelland, L.R., Mistry, P., Abel, G., Freidlos, F., Loh, S.Y., Roberts, J.J., and Harrap, K.R. Establishment and characterization of an in vitro model of acquired resistance to cisplatin in a human testicular nonseminomatous germ cell line. *Cancer Res.* 52: 1710-1716, 1992.

25. Castedo, S. M. M. J., de Jong, B., Oosterhuis, J.W., Seruca, R., Idenburg, V.J., Buist, J., and Sleijfer, D.Th. i(12p)-Negative testicular germ cell tumours. A different group? *Cancer Genet. Cytogenet.* 35: 171-178, 1988.
26. Murty, V.V.V.S., Houldsworth, J., Baldwin, S., Reuter, V., Hunziker, W., Besmer, P., Bosl, G., and Chaganti R.S.K. Allelic deletions in the long arm of chromosome 12 identify sites of candidate tumour suppressor genes in male germ cell tumours. *Proc.Natl.Acad.Sci.* 89: 11006-11010, 1992.
27. Bosl, G.J., Dimitrovsky, E., Reuter, V.E., Samaniego, F., Rodriguez, E., Geller, N.L., and Chaganti, R.S.K. Isochromosome of chromosome 12: Clinical useful marker for male germ cell tumours. *J.Natl.Cancer Inst.* 81: 1874-1878, 1989.
28. Ben Ze'ev, A. Differential control of cytokeratins and vimentin synthesis by cell-cell contact and cell spreading in cultured epithelial cells. *J.Cell.Biol.* 99: 1424-1433, 1984.
29. Teicher, B.A., Herman, T.S., Holden, S.A., Wang, Y., Pfeffer, M.R., Crawford, J.W., and Frei (III), E. Tumour resistance to alkylating agents conferred by mechanisms operative only in vivo. *Science* 247: 1457-1461, 1990.
30. Meijer, C., Mulder, N.H., and de Vries, E.G.E. The role of detoxifying systems in resistance of tumour cells to cisplatin and adriamycin. *Cancer Treat.Rev.* 17: 389-407, 1990.
31. Hamilton, T.C., Winker, M.A., Kouie, K.G., Batist, G., Behrens, B.C., Tsuruo, T., Grotzinger, K.R., McKoy, W.M., Young, R.C., and Ozols, R.F. Augmentation of adriamycin, melphalan and cisplatin cytotoxicity in drug resistant and -sensitive human ovarian carcinoma cell lines by buthionine sulfoximine mediated glutathione depletion. *Biochem.Pharmacol.* 34: 2583-2586, 1985.
32. Lee, F.Y., Flannery, D.J., and Siemann, D.W. Prediction of tumour sensitivity to 4-hydroperoxycyclophosphamide by a glutathione-targeted assay. *Br.J.Cancer* 63: 217-222, 1991.
33. Meijer, C., Mulder, N.H., Timmer-Bosscha, H., Sluiter, W.J., Meersma, G.J., and de Vries, E.G.E. Relationship of cellular glutathione to the cytotoxicity and resistance of seven platinum compounds. *Cancer Res.* 52: 6885-6889, 1992.
34. Strohmeyer, T., Klöne, A., Wagner, G., Hartmann, M., and Sies, H. Glutathione S-transferase in human testicular germ cell tumours: changes of expression and activity. *J.Urol.* 147: 1424-1428, 1992.
35. Nakagawa, K., Saijo, N., Tsuchida, S., Sakai, M., Tsunokawa, Y., Yokota, J., Muramatsu, M., Sato, K., Terada, M., and Tew, K.D. Glutathione S-transferase π as a determinant of drug resistance in transfectant cell lines. *J.Biol.Chem.* 265: 4296-4301, 1990.
36. Saburi, Y., Nakagawa, M., Ono, M., Sakai, M., Muramatsu, M., Kohno, K., and Kuwano, M. Increased expression of glutathione S-transferase gene in cis-diamminedichloroplatinum(II)-resistant variants of a Chinese hamster ovary cell line. *Cancer Res.* 49: 7020-7025, 1989.
37. Moscow, J.A., Townsend, A.J., and Cowan, K.H. Elevation of π class glutathione S-transferase activity in human breast cancer cells by transfection of the GST π gene and its effect on sensitivity to toxins. *Mol.Pharmacol.* 36:22-28, 1989.

38. Kasahara, K., Fujiwara, Y., Nishio, K., Ohmori, T., Sugimoto, Y., Komiya, K., Matsuda, T., and Saijo, N. Metallothionein content correlates with the sensitivity of human small cell lung cancer cell lines to cisplatin. *Cancer Res* 51: 3237-3242, 1991.
39. Klys, H.S., Whillis, D., Howard, G., and Harrison, D.J. Glutathione S-transferase expression in the human testis and testicular germ cell neoplasia. *Br. J. Cancer* 66: 589-593, 1992.
40. Lai, G-M., Ozols, R.F., Young, R.C., and Hamilton, T.C. Effect of glutathione on DNA repair in cisplatin-resistant human ovarian cancer cell lines. *J.Natl.Cancer Inst.* 81: 535-539, 1989.
41. Meijer, C., Mulder, N.H., Hospers, G.A.P., Uges, D.R.A., and de Vries, E.G.E. The role of glutathione in resistance to cisplatin in a human small cell lung cancer cell line. *Br.J.Cancer* 62: 72-77, 1990.
42. Katz, E.J., Andrews, P.A., and Howell, S.B. The effect of polymerase inhibitors on the cytotoxicity of cisplatin in human ovarian carcinoma cells. *Cancer Comm.* 2: 159-164, 1990.
43. de Jong, S., Timmer-Bosscha, H., de Vries, E.G.E., and Mulder, N.H. Effect of novobiocin on cisplatin cytotoxicity and DNA interstrand cross-link formation in a cisplatin-resistant small-cell lung carcinoma cell line. *Int.J.Cancer* 53: 110-117, 1993.
44. Scanlon, K.J., Lu, Y., Kashani-Sabet, M., Ma, J.X., and Newman, E.M. Mechanisms for cisplatin-FUra synergism and cisplatin resistance in human ovarian cells both in vitro and in vivo. In: *Advances in experimental medicine and biology*, pp. 127-135. Plenum Press, New York, 1967.

Chapter 4.2

COMBINATION OF CISPLATIN AND 13-CIS RETINOIC ACID FOR THE TREATMENT OF CISPLATIN-SENSITIVE AND -RESISTANT HUMAN EMBRYONAL CARCINOMA XENOGRAFTS IN MICE

Albertus Timmer¹, Hetty Timmer-Bosscha², Elisabeth GE de Vries², Wim Timens¹, Siep Wouda¹,
J Wolter Oosterhuis³, Nanno H Mulder².

Department of Pathology¹, Division of Medical Oncology, Department of Internal Medicine²,
University Hospital, Groningen. Dr. Daniel den Hoed Cancer Center³, Rotterdam,
The Netherlands.

ABSTRACT

Residual mature teratoma following chemotherapy of germ cell tumours, associated with primary tumours with the capacity of spontaneous somatic differentiation, is the result of an inherent chemotherapy resistance of teratoma cells, and is not prognostically unfavourable. About 20 to 30% of patients with disseminated germ cell tumours become unresponsive to cis-diamminedichloroplatinum(II) (CDDP)-containing regimens due to development of drug resistance. In the present study a differentiation inducing agent, 13-cis retinoic acid (cRA), combined with CDDP treatment is tested for its potential to improve treatment of tumour cells with inherent and acquired CDDP resistance. The human embryonal carcinoma cell line NTera2/D1 (Tera) and its CDDP resistant subline Tera-CP, both with an inherent capacity to differentiate in vivo, were transplanted into nude mice. Treatment consisted of cRA on 5 consecutive days (30 mg/kg), or CDDP in a single dose (7 mg/kg), or CDDP followed or preceded by cRA. To study tumour histology all mice were sacrificed at day 12. Toxicity, evaluated with loss of body weight, was acceptable in all treatment arms. cRA alone reduced the size of Tera-CP but not of Tera tumours. CDDP reduced tumour size in Tera tumours to 20%, and Tera-CP tumours to 70% of control values (day 1). In Tera-CP, but not in Tera, regrowth was found. In Tera and Tera-CP tumours, cRA before or after CDDP did not affect CDDP anti-tumour activity. Somatic differentiation, in controls, after CDDP alone, and after combined treatments, was more extensive in Tera than in Tera-CP, while addition of cRA to CDDP treatment increased differentiation in Tera-CP but not in Tera. In conclusion, CDDP combined with cRA was as active as CDDP alone, but induced more differentiation in Tera-CP. cRA pre-treatment did not reduce the CDDP-sensitivity of the tumour cells, while somatically differentiated cells seemed more resistant to CDDP.

INTRODUCTION

Cis-diamminedichloroplatinum(II)(CDDP)-containing regimens cure 70 to 80% of the patients with disseminated germ cell tumours (Loehrer & Einhorn, 1984). In the remaining group the tumour becomes unresponsive to therapy due to development of drug resistance, leading to progressive, metastatic disease. On the other hand, residual mature teratoma following chemotherapy, associated with primary tumours capable of spontaneous somatic differentiation, is the result of an inherent chemotherapy resistance of teratoma cells (Oosterhuis et al., 1983). Residual mature teratoma, when surgically removed, is not prognostically unfavourable. The use of differentiation inducing agents, such as retinoids in combination with CDDP-chemotherapy, could be a way to force embryonal carcinoma (EC) cells with an acquired CDDP resistance into a more differentiated, less proliferative, less invasive state.

Retinoids have important regulatory roles in particular in cell growth and differentiation. Only in the last two decades their potential role in prevention and therapy of malignancies was explored. The natural, bio-active metabolites of retinol are all-trans retinoic acid (RA) and 13-cis retinoic acid (cRA). The effects of both RA and cRA are thought to be mediated by the nuclear retinoic acid receptors. These have a lower affinity for cRA than for RA. On the other hand, pharmacokinetic studies in patients showed a longer half life and higher peak plasma levels for cRA than for RA (for review: Smith et al., 1992). Moreover, plasma levels remained predictable and dose dependent for cRA after extended administration, while for RA this led to reduced plasma levels and a loss of effects (for review: Smith et al., 1992). The induction of differentiation by RA was demonstrated in murine (Strickland & Mahdavi, 1978; Guchelaar et al., 1993) and human (Oosterhuis et al., 1986) EC cells in vitro, as well as in murine EC cells transplanted in syngeneic hosts (Speers, 1982; McCue et al., 1988). Also, cRA-induced differentiation of murine EC cells in vitro has been described (Strickland et al., 1980). Based on the more favourable in vivo pharmacokinetics and the expectation of biologically comparable results in the present study cRA was used as a differentiation inducing agent.

The present study was undertaken to test the potential of the addition of differentiation induction to CDDP chemotherapy. The human EC cell line Tera and its CDDP-resistant subline Tera-CP, both with an inherent capacity to differentiate in vivo (Andrews et al., 1984; Timmer-Bosscha et al., 1993), were transplanted into nude mice. These mice were treated with cRA, CDDP, and combinations of both agents. Toxicity of the treatments, tumour reduction, and differentiation induction were monitored.

MATERIALS AND METHODS

Chemicals. CDDP was obtained from Bristol-Myers Squibb (Weesp, The Netherlands). cRA was generously provided by Hoffman La Roche (Mijdrecht, The Netherlands) and stored in liquid nitrogen.

Tumour production. All experiments were conducted with tumours derived from the human EC cell lines NTera2/D1 (Tera) and its in vitro 3.7-fold CDDP-resistant subline Tera-CP (Timmer-Bosscha, et al., 1993). The characteristics of both cell lines were described previously. Both cell lines mainly consisted of EC. Cell size and doubling time of both cell lines were comparable. Karyotypes revealed a decreased mean number of chromosomes and

Table 1. Treatment schedules of the various groups.

Treatment group	solvent of cRA	cRA (30mg/kg body weight)	solvent of CDDP	CDDP (7mg/kg body weight)
A	days 3 - 7		day 1	
B		days 3 - 7	day 1	
C	days 3 - 7			day 1
D		days 3 - 7		day 1
E		days 1 - 5		day 7

less copies of the short arm of chromosome 12 in Tera-CP (Timmer-Bosscha et al., 1993). Male Balb/c nu/nu mice were kept under standard laboratory conditions according to the guidelines of our institute. Approval for the experiments was obtained from the Medical Committee for Animal Experiments. Mice were maintained in sterilized cages with sterilized bedding, sterilized food (RMH-B #21001, Hope Farms, Woerden, The Netherlands) and sterilized and acidified water. In order to xenograft Tera or Tera-CP, 5×10^6 cells of either cell line were injected subcutaneously in the right shoulder. After outgrowth to solid tumour nodules, experiments were conducted with secondary tumours produced by transplanting pieces of tumour of Tera or Tera-CP (approximately 2 mm in diameter) subcutaneously in the right shoulder of earmarked, 8 to 9 weeks old mice. The mice were randomized over five treatments groups: solvents only (A); cRA only (B); CDDP only (C); CDDP followed by cRA (D); CDDP preceded by cRA (E).

Treatment was started when the tumours had a diameter of approximately 8 mm. This was 59 ± 18 days and 42 ± 24 days after tumour implantation for Tera and Tera-CP tumours, respectively. All solutions were administered intraperitoneally. The solvent for CDDP was 9 mg/ml NaCl. For cRA solvent consisted of sodium hydroxide in 9 mg/ml NaCl solution. In contrast to the formulation advised by Guchelaar et al. (Guchelaar et al., 1992), 0.38 mg/ml sodium hydroxide was used instead of 3 mg/ml. In control animals, solvents were administered instead of the respective agents, according to the scheme in Table 1. CDDP (0.5 mg/ml) was administered at a dose of 7 mg/kg body weight at day 1 or day 7, according to the scheme in Table 1. The dose of 7 mg /kg CDDP was chosen based on pilot experiments. This dose reduced Tera tumours to just palpable size at day 6, and Tera-CP tumours to about 70% of day 1 values, at day 6. It was therefore considered to be a suitable dose to study effects of cRA/CDDP combination in Tera-CP. cRA (2.5 mg/ml) was administered at days 3-7 or days 1-5, according to the scheme in Table 1, at a dose of 30 mg/kg body weight. This dose was well tolerated in pilot experiments, while 40 mg cRA/kg of body weight induced significant weight loss. The cRA solution was freshly made every day immediately before injection and filtered through a 0.2- μ m filter to ensure aseptic solutions.

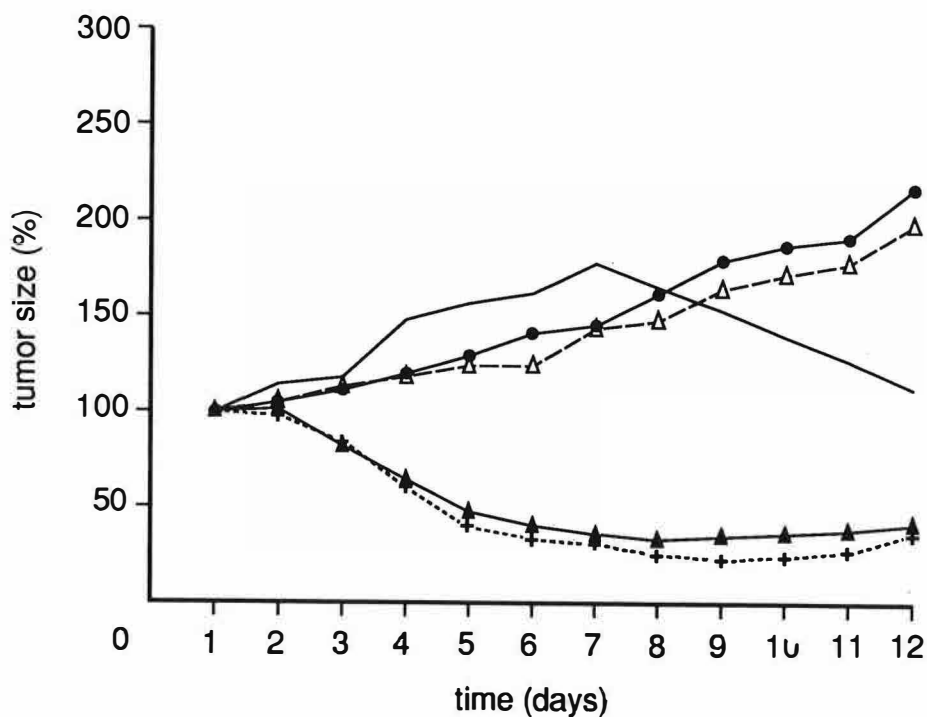


Figure 1. The median size of Tera tumours, relative to median tumour measurements at day 1, in 5 treatment arms: Solvents only (●-●), cRA (Δ--Δ), CDDP (▲-▲), CDDP followed by cRA (+--+), and CDDP preceded by cRA (-). Compared with controls, cRA alone did not reduce tumour size, and CDDP alone reduced tumour size from day 3 ($p < 0.05$) to day 12 (days 4-12, $p < 0.005$). Compared with CDDP alone, CDDP followed by cRA did not reduce tumour size.

Table 2. Differentiation state of the Tera tumours in each treatment arm, semiquantitatively scored on hematoxylin-eosin-stained slides.

group A (n = 5) solvents only	group B (n = 5) cRA only	group C (n = 7) CDDP only	group D (n = 7) CDDP followed by cRA	group E (n = 5) CDDP preceded by cRA
+++ ^a	++	+++	+++	+++
++	++	+++	+++	+++++
++	+	+++	+++	++
+	+	+++	++	±
±	±	+++	++	NE
		+	++	
		NE	++	

^a (±): < 5% differentiated tumour tissue, (+): 5 - 10% differentiated tumour tissue, (++) : 10 - 50% differentiated tumour tissue, (+++): 50 - 100% differentiated tumour tissue, NE: not evaluable.

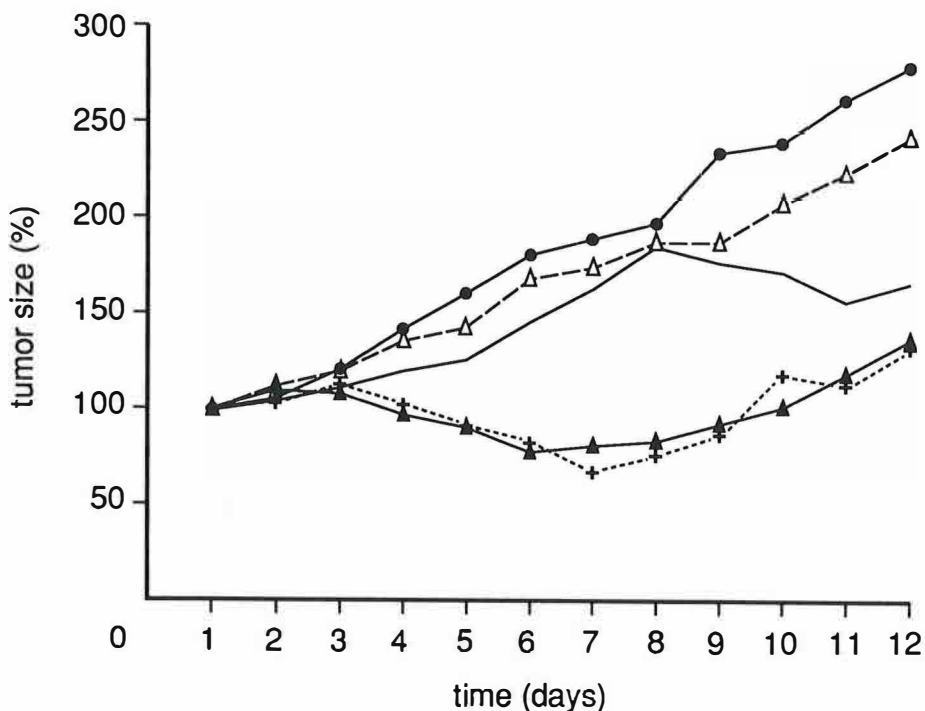


Figure 2. The median size of Tera-CP tumours, relative to median tumour measurements at day 1, in 5 treatment arms: Solvents only (●-●), cRA (Δ-Δ), CDDP (▲-▲), CDDP followed by cRA (+--+), and CDDP preceded by cRA (-). Compared with controls, cRA alone reduced tumour size at day 9 ($p < 0.05$) and day 12 ($p < 0.05$), and CDDP alone reduced tumour size from day 4 ($p < 0.01$) to day 12 (days 5-12, $p < 0.005$). Compared with CDDP alone, CDDP followed by cRA did not reduce tumour size.

Table 3. Differentiation state of the Tera-CP tumours in each treatment arm, semiquantitatively scored on hematoxylin-eosin-stained slides.

group A (n = 5) solvents only	group B (n = 5) cRA only	group C (n = 7) CDDP only	group D (n = 7) CDDP followed by cRA	group E (n = 5) CDDP preceded by cRA
++ ^a	++	++	++	++
+	++	++	++	++
+	+	+	++	++
±	±	+	++	++
±	±	+	+	+
		+	±	
		+	NE	

^a for legend: see table 2.

Tumour size. For evaluation of tumour response, tumour size was determined daily with calipers using three-dimensional measurements, length (l), width (w), and height (h), and expressed as l x h x w (Tomayko & Reynolds, 1989). Toxicity was monitored by daily measurements of body weight.

Tumour histology. To allow comparative histological examination of the tumours, all mice were sacrificed on day 12. At this day the tumours were excised. Of each tumour, one part was fixed in formalin and one part was snap frozen in liquid nitrogen. From paraffin-embedded blocks of tumour tissue, 2- μ m histological slides were cut. The ratio of differentiated and undifferentiated, viable tumour tissue was semiquantitatively scored on hematoxylin-eosin-stained slides ($\pm < 5\%$; + 5-10%; ++ 10-50%; +++ 50-100% viable, differentiated tumour tissue). Undifferentiated tumour tissue consisted of EC composed of solid sheets of uniform polygonal cells with large nuclei with prominent nucleoli. The cytoplasm was relatively scanty and appeared clear to basophilic in hematoxylin-eosin-stained slides. Focally EC cells demonstrated a tubulo-papillary growth pattern. The earliest sign of differentiation is a decrease of nuclear size and loss of prominent nucleoli. On differentiation, the morphology of the cytoplasm and the character of the intercellular matrix depend on differentiation lineages with different kinds of neural, epithelial, and mesenchymal tissues. All cells that had a non-EC morphology were regarded as differentiated.

Statistics. For statistical analysis the one-sided Wilcoxon rank sum test for unpaired data was used. Differences were considered significant when p-values were ≤ 0.05 .

RESULTS

Toxicity

Treatment toxicity was apparent from the loss of body weight of mice. Maximal loss of body weight was 7% in the mice treated with cRA or CDDP only, and 12% in the mice treated with cRA followed by CDDP. In mice treated with CDDP followed by cRA the most severe (13-17%) body weight reduction was found at day 6, with a recovery up to day 12.

Tumor response

Tumour response to the various treatments in the two experiments, defined as a statistically significant reduction of tumour size, is shown in Figures 1 and 2. Tumour size is expressed as percentage of the size of the tumour at the beginning of treatment, which for each treatment was arbitrarily set at 100%. Absolute values for tumour size at the start of treatment were 452 ± 26 (n = 29) for Tera and 458 ± 36 (n = 29) for Tera-CP tumours. Untreated tumours of Tera and Tera-CP grew progressively during the time of the experiments, although Tera tumours were significantly smaller than untreated Tera-CP tumours, from day 4 to day 12 (days 5,12, $p \leq 0.05$; days 4,6,9,10, $p = 0.025$; days 7,8,11, $p = 0.01$). Compared with their respective, untreated controls, treatment of Tera tumours with cRA alone did not reduce tumour size while, in Tera-CP tumours, cRA alone reduced tumour size to about 80% at days 9 ($p < 0.05$) and 12 ($p = 0.05$). Treatment with CDDP alone decreased the size of Tera tumours from day 3 ($p < 0.05$) to day 12 (days 4 to 12, $p < 0.005$), and of Tera-CP tumours from day 4 ($p < 0.01$) to day 12 (days 5 to 12, $p < 0.005$). However, Tera tumours treated with only CDDP were smaller than Tera-CP

tumours treated with only CDDP, from day 4 ($p < 0.01$) to day 12 (days 5 to 12, $p < 0.005$). For Tera as well as for Tera-CP treatment with CDDP followed by cRA did not further reduce tumour sizes compared with treatment with CDDP alone. The percentage of tumour reduction from day 2 (first measurement after CDDP administration) to day 6 of tumours treated with CDDP alone was not different from the percentage tumour reduction from day 8 (first measurement after CDDP administration) to day 12 of tumours treated with cRA before CDDP.

Tumor histology

Histological differentiation state of the tumours excised at day 12 after the various treatments is shown in Tables 2 and 3, and illustrated in Figures 3 and 4. Without any treatment Tera tumours showed a higher degree of differentiation than Tera-CP tumours. After CDDP treatment the highest relative amount of differentiated tissue was found in Tera tumours. In line with the higher differentiation state of Tera tumours are the tubular epithelial structures frequently observed in all Tera tumour slides. After CDDP treatment also in Tera-CP tumours tubular epithelial structures were frequently found. This might indicate an increased differentiation in these tumours, although no increased percentage differentiated tissue was observed (Table 3). Addition of cRA to CDDP treatment of Tera-CP tumours led to an increased percentage of differentiated tissue in these tumours. On the other hand in Tera tumours treatment with the combination of cRA and CDDP seemed to reduce the differentiation state of the tumours. Although the percentage of differentiated tissue seemed to be decreased, the absolute amount of differentiated tumour will probably be unaltered, as sizes of the CDDP treated tumours were generally much smaller than those of tumours treated with CDDP preceded by cRA (Figure 2). Histological examination revealed that, after CDDP treatment, in all Tera tumours, but less frequently in Tera-CP tumours, giant cells with hyperchromatic nuclei, prominent nucleoli, and a clear cytoplasm were found. In most tumours the percentage of necrosis was less than 5%.

DISCUSSION

This *in vivo* study addressed the potential of the combination of cRA and CDDP treatment, in comparison to each drug alone. Activity was measured as tumour response. Tumour response was defined as reduction of tumour size and the duration of this reduction. As a model tumours grown from Tera and Tera-CP, human EC cell lines, were used as representatives of teratocarcinomas with inherent and acquired CDDP resistance, respectively.

The toxicity of cRA is influenced by the vehicle of the drug. The retinoid cRA was given intraperitoneally in an alkaline solution. This was described to be a preferable formulation, especially for small laboratory animals (Guchelaar et al., 1992). However, sodium hydroxide concentration had to be reduced several fold (from 3 mg/ml to 0.38 mg/ml) as in a pilot experiment with the same concentration of cRA in a 3 mg/ml alkaline solution, mice died of acute toxicity (data not shown). The toxicity of the CDDP-cRA combination in the mice described in this study is not due to the alkaline solution as it was also given to the mice in the control-groups without signs of toxicity. Loss of body weight was minor after monotherapy with CDDP or cRA, but seemed to be at least additive with the

combination. However, it recovered rapidly after the final cRA injections. Overall, the combination of a single, high dose CDDP injection with cRA used here was much less toxic than the scheme with RA and sequential low dose CDDP injections used by Wouda et al. (Wouda et al., 1993).

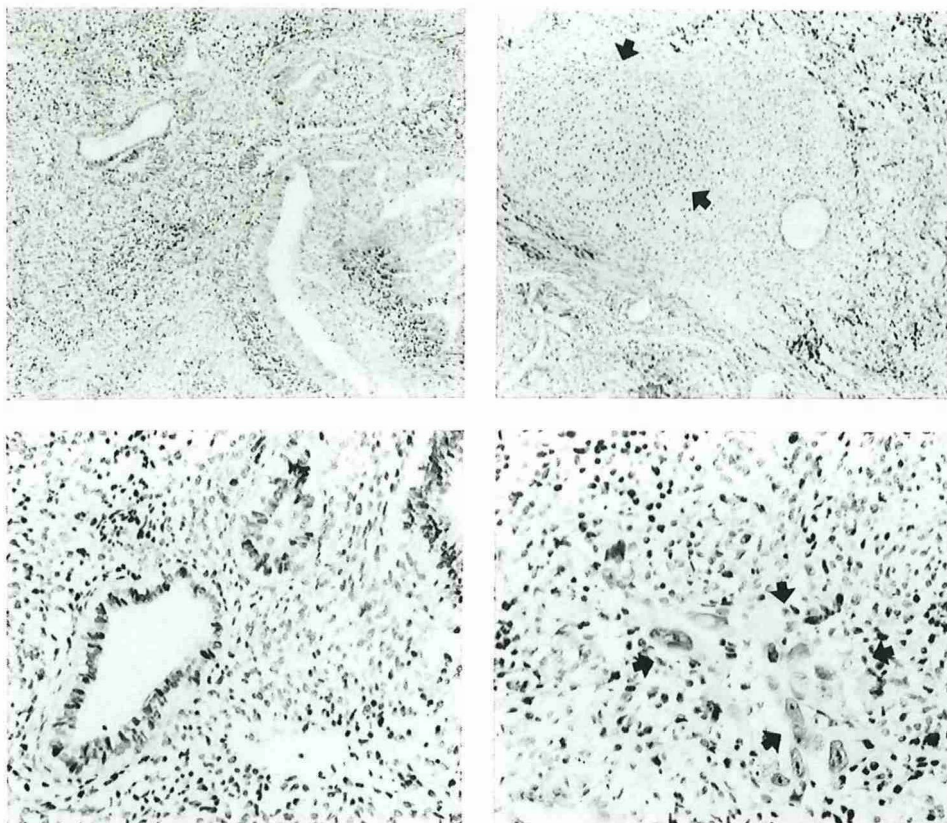


Figure 3. A, top left: Tera treated with solvents only. The majority of tumour tissue consists of (im)mature teratoma with areas of EC in a tubulo-papillary growth pattern (56x); B, top right: Tera treated with CDDP followed by cRA. (Im)mature teratoma with primitive cartilage (arrow) and areas of EC (56x); C, bottom left: Tera treated with CDDP followed by cRA. Extensive (im)mature differentiation with tubulo-epithelial structures (140x); D, bottom right: Tera treated with CDDP followed by cRA. The majority of the tissue consists of (im)mature teratoma. Focally, giant cells with hyperchromatic nuclei, prominent nucleoli and a clear cytoplasm (arrow)(140x) (hematoxylin-eosin).

The effect of cRA on tumour size of Tera-CP occurred relatively late as it started on day 9. This postponed effect was also seen in the report by Wouda et al. (Wouda et al., 1993), in which effects of RA were found 8 to 10 days after the start of daily RA injections. In that study statistically significant tumour reduction by RA alone was only found in tumours incapable of differentiation and not in the tumours with the capacity to differentiate (Wouda et al., 1993). This indicated that this reduction was probably more a result of RA-induced growth inhibition than an effect of differentiation induction. This effect was to a certain

degree also found in the present study, as Tera-CP tumours were significantly reduced compared to untreated controls by cRA, but the Tera tumours, with a higher propensity for spontaneous differentiation were not.

No increased tumour reduction was observed in mice treated with CDDP followed by cRA compared to the mice treated with CDDP alone, in both Tera and Tera-CP tumours. This was in contrast with the *in vivo* potentiation of CDDP cytotoxicity by RA in tumours of murine ECs with an inherent capacity to differentiate (Wouda et al., 1993). This discrepancy could not be due to a complete lack of cRA-effect, as in the Tera-CP tumours with only cRA a tumour reduction of 20% was achieved. A likely explanation is that cRA and CDDP have to be administered simultaneously to achieve this effect. In the experiments by Wouda et al. the tumours started to regrow when the dose of CDDP had to be reduced due to unacceptable toxicity (Wouda et al., 1993). This resulted in the disappearance of the difference between the tumours treated with CDDP alone and those treated with RA and CDDP. Similarly, in the present experiments cRA could not prevent the regrowth of the Tera-CP tumours when the effect of CDDP had vanished (Figure 2). In future experiments the simultaneous administration of the two drugs should be tested in the Tera and Tera-CP tumours.

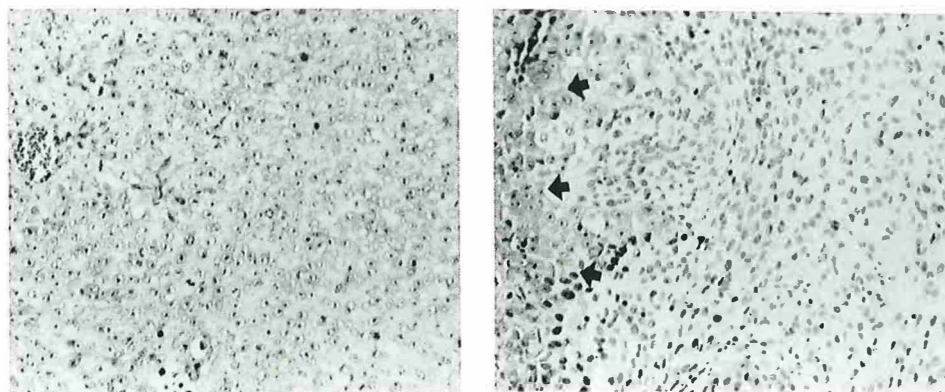


Figure 4. A, left: Tera-CP treated with solvents only. EC with focal necrosis; B, right: Tera-CP treated with CDDP followed by cRA. EC (arrow) and (im)mature teratoma (hematoxylin-eosin, 140x).

In our study, cRA treatment before CDDP did not affect the tumour response. This is in contrast with the *in vitro* loss of CDDP sensitivity in Tera and Tera-CP (Timmer-Bosscha, manuscript in preparation) after differentiation induction by RA. However, in culture Tera and Tera-CP not exposed to RA or cRA were maintained as embryonal cell cultures, while in xenografts not exposed to RA or cRA always a certain degree of spontaneous differentiation occurred (Timmer-Bosscha et al., 1993). Previously, this difference between *in vitro* and *in vivo* differentiation state was shown not to influence their relative CDDP sensitivity as the resistance factor *in vitro* and *in vivo* were comparable (Timmer-Bosscha et al., 1993). It is conceivable that the difference in environmental

conditions might lead to another cellular response to retinoids, as was previously suggested by the species and tissue specific retinoid responses in cancer prevention studies in laboratory animals (Hill & Grubbs, 1992). As *in vitro* interaction with other tissues and their excretion products is impossible, this effect on retinoid treatment might be negligible in that setting.

In the present study, Tera-CP tumours grew faster than Tera tumours, while *in vitro* no difference in doubling time was found. Since differentiation generally is inversely related to proliferation (Cross & Dexter, 1991; Pierce & Speers, 1988) the higher percentage of differentiated cells in Tera tumours compared to Tera-CP tumours may offer an explanation for the differences in tumour growth. However, *in vitro* Tera and Tera-CP demonstrated comparable propensity to differentiate. This suggests, apart from differences in genetic programming, a role for epigenetic factors in differentiation and growth of these tumours *in vivo*.

Differentiation after CDDP alone, and after treatment with the combinations, was more extensive in Tera than in Tera-CP. The tubular epithelial structures observed in all Tera tumours are considered to be part of the higher differentiation state of the Tera tumours. Their presence in the Tera-CP tumours after CDDP treatment indicated an increased differentiation level in these tumours also. The high degree of differentiation, especially in Tera after CDDP treatment, was probably the result of extensive tumour reduction combined with a selective survival of pre-existent differentiated cells as was previously shown by Oosterhuis et al. (Oosterhuis et al., 1986). Tera-CP tumours treated with CDDP preceded or followed by cRA showed a strong tendency to increased differentiation compared to tumours treated with CDDP alone, whereas the response of Tera-CP tumours with respect to tumour size was comparable in all three treatment groups. Future studies will have to elucidate whether the therapy-related increase in differentiation is related to additive or synergistic effects of cRA and CDDP.

Finally, the giant cells present in especially Tera tumours after CDDP treatment are probably a histological sign of toxicity since enlarged cells with extensive cytoplasmic vacuolization, bizarre nuclei and nucleoli could be observed in EC cultures after exposure to CDDP (Oosterhuis et al., 1984).

Summarizing, treatment with CDDP followed by cRA was as active as CDDP alone in CDDP-sensitive and -resistant tumours, which also showed that CDDP sensitivity of tumour cells *in vivo* was not negatively influenced by treatment with cRA. In the CDDP sensitive Tera tumours with the more extensive differentiation, differentiated cells with inherent resistance to CDDP seemed to survive treatment selectively. Tera tumours, therefore, produce clinically favourable residual mature teratoma. In the Tera-CP tumours with acquired CDDP resistance, with the lesser spontaneous somatic differentiation, not only differentiated cells but also EC cells were present after treatment. The latter gave rise to regrowth of the tumour. Thus Tera and Tera-CP tumours in the present experiment showed similarities to inherent and acquired CDDP resistance which is encountered in the clinical situation. In Tera-CP, addition of cRA to CDDP treatment increased differentiation of post-therapy residual tumour cells, thus reducing the invasive and metastatic capacity of this tumour residue. As a differentiation inducing agent cRA must be preferred to RA as toxicity was low. In order to improve anti-tumour activity, simultaneous addition of cRA and CDDP could be considered for future studies.

Acknowledgements

The authors thank Mr. Hilbrand Wierenga for help in the preparation of the microphotographs. This study was supported by grants GUKC 88-11 and 90-18 from the Dutch Cancer Foundation and a grant from the J.K. de Cock Foundation, Groningen.

REFERENCES

Andrews, P.W., Damjanov, I., Simon, D., Banting, G.S., Carlin, C., Dracopoli, N.C. & Føgh, J. (1984). Pluripotent embryonal carcinoma clones derived from the human teratocarcinoma cell line Tera-2. Differentiation in vivo and in vitro. *Lab.Invest.*, 50, 147-162.

Cross, M. & Dexter, T.M. (1991). Growth factors in development, transformation, and tumorigenesis. *Cell*, 64, 271-280.

Guchelaar, H.J., Wouda, S., Beukeveld, G.J.J., Mulder, N.H. & Oosterhuis, J.W. (1992). Pharmacokinetics of parenteral 13-cis-retinoic acid formulations in rats. *J.Pharm.Sci.*, 81, 432-435.

Guchelaar, H.-J., Timmer-Bosscha, H., Dam-Meiring, A., Uges, D.R.A., Oosterhuis, J.W., De Vries, E.G.E. & Mulder, N.H. (1993). Enhancement of cisplatin and etoposide cytotoxicity after all-trans retinoic-acid-induced cellular differentiation of a murine embryonal carcinoma cell line. *Int.J.Cancer*, 55, 442-447.

Hill, D.L. & Grubbs, C.J. (1992). Retinoids and cancer prevention. *Ann.Rev.Nutr.*, 12, 161-181.

Loehrer, P.J. & Einhorn, L.H. (1984). Cisplatin. *Ann.Intern.Med.*, 100, 704-713.

McCue, P.A., Thomas, R.S., Schroeder, D., Gubler, M.L. & Sherman, M.I. (1988). Effects of dietary retinoids upon growth and differentiation of tumors derived from several murine embryonal carcinoma cell lines. *Cancer Res.*, 48, 3772-3779.

Oosterhuis, J.W., Suurmeyer, A.J.H., Sleijfer, D.Th., Schrafford Koops, H., Oldhoff, J. & Fleuren, G. (1983). Effects of multiple-drug chemotherapy (cis-diamminedichloroplatinum, bleomycin, and vinblastine) on the maturation of retroperitoneal lymphnode metastases of nonseminomatous germ cell tumors of the testis. *Cancer*, 51, 408-416.

Oosterhuis, J.W., Andrews, P.W., Knowles, B.B. & Damjanov, I. (1984). Effects of cis-platinum on embryonal carcinoma cell lines in vitro. *Int.J.Cancer*, 34, 133-139.

Oosterhuis, J.W., Andrews, P.W. & de Jong, B. (1986). Mechanisms of therapy-related differentiation in testicular germ cell tumours. In *Biochemical mechanisms of platinum antitumour drugs*. McBrien, D.C.H. and Slater, T.F. (eds) pp.65-89. IRL Press Ltd., Oxford.

Pierce, G.B. & Speers, W.C. (1988). Tumors as caricatures of the process of tissue renewal: prospects for therapy by directing differentiation. *Cancer Res.*, 48, 1996-2004.

Smith, M.A., Parkinson, D.R., Cheson, B.D. & Friedman, M.A. (1992). Retinoids in cancer therapy. *J.Clin.Oncol.*, 10, 839-864.

Speers, W.C. (1982). Conversion of malignant murine embryonal carcinomas to benign teratomas by chemical induction of differentiation in vivo. *Cancer Res.*, 42, 1843-1849.

Strickland, S. & Mahdavi, V. (1978). The induction of differentiation in teratocarcinoma stem cells by retinoic acid. *Cell*, 15, 393-403.

Strickland, S. & Sawey, M.J. (1980). Studies on the effect of retinoids on the differentiation of teratocarcinoma stem cells in vitro and in vivo. *Dev.Biol.*, 78, 76-85.

Timmer-Bosscha, H., Timmer, A., Meijer, C., De Vries, E.G.E., de Jong, B., Oosterhuis, J.W. & Mulder, N.H. (1993). Cis-diamminedichloroplatinum(II) resistance in vitro and in vivo in human embryonal carcinoma cells. *Cancer Res.*, 53, 5707-5713.

Tomayko, M.M. & Reynolds, C.P. (1989). Determination of subcutaneous tumor size in athymic (nude) mice. *Cancer Chemother.Pharmacol.*, 24, 148-154.

Wouda, S., Timmer, B., Mulder, N.H., Dam, A., Koudstaal, J. & Oosterhuis, J.W. (1993). Retinoic acid and cisdiamminedichloroplatinum in the treatment of murine teratocarcinomas in vivo in a nullipotent model. *J.Immunother.*, 13, 261-266.

Chapter 4.3

EXPRESSION OF INTEGRIN SUBUNITS IN THE HUMAN EMBRYONAL CARCINOMA CELL LINE TERA AND ITS CISPLATIN RESISTANT SUBLINE TERA-CP

Albertus Timmer¹, Andre E Alfenaar¹, Hetty Timmer-Bosscha², Nanno H Mulder²,
Elisabeth GE de Vries², Wim Timens¹

Department of Pathology¹, Division of Medical Oncology, Department of Internal Medicine²,
University Hospital, Groningen, The Netherlands

ABSTRACT

In the present study we examined the expression of integrin (subunits) in the human embryonal carcinoma cell line NTera/2D1 (Tera) and its 3.7 fold cisplatin resistant subline Tera-CP by immunohistochemistry on cytopins. The aim of this study was to investigate if differences in integrin phenotype might offer an explanation for the observed differences in growth and differentiation of both cell lines in vivo. As changes in integrin expression might account for the anticancer action of all-trans retinoic acid we also examined the expression of integrin (subunits) in both cell lines after 96 hours treatment with this retinoid. The $\alpha 1$ and $\alpha 3$ integrin subunits were weakly expressed in less than 5% of the tumor cells. Both cell lines showed uniform expression of $\alpha 5$, $\alpha 6$, αv , and $\beta 1$ integrin subunits. The $\alpha v \beta 5$ integrin was expressed by nearly all tumor cells. Neither in Tera nor in Tera-CP $\alpha 2$, $\alpha 4$, $\beta 3$, and $\beta 4$ integrin subunits could be detected. Upon application of all-trans retinoic acid the $\alpha 4$ integrin subunit was de novo expressed in less than 5% of the tumor cells. Compared to untreated cells, increased staining intensity was noticed for the $\alpha 5$ integrin subunit in Tera as well as in Tera-CP. In conclusion, in vitro treatment of both cell lines with all-trans retinoic acid for 96 hours resulted in changes in integrin expression that may be related to differentiation of embryonal carcinoma cells. No differences were observed in integrin (subunit) expression that might account for differences in growth and differentiation observed in vivo. Future studies will have to elucidate whether changes in integrin subunit expression are a reflection of the process of differentiation itself (inside-out signalling), or whether differentiation is affected by the pattern of integrin expression (outside-in signalling).

INTRODUCTION

By interacting with cell adhesion molecules, extracellular matrix (ECM) proteins may have a profound influence on the morphology, behavior, and function of cells¹. Among the different cell adhesion molecules that have affinity for ECM proteins, integrins are the most widely studied (Chapter 2.1, Table 1). Integrins are heterodimeric transmembrane proteins that mediate cell-cell as well as cell-matrix interactions². Via a chain of linking proteins, integrins are physically associated with the cytoskeleton³. Upon ligand binding, integrins may transduce signals into the cell that modify gene expression either by activation of intracellular signal transduction pathways or by rearrangement of the integrin associated cytoskeletal network (outside-in signalling). Conversely, the affinity and specificity of integrins may be modulated by signals from inside the cell (inside-out signalling)²⁻⁵. Both ways of signal transduction act in concert with signals transduced by other cell surface receptors²⁻⁶.

Upon malignant transformation marked changes occur with respect to the level and pattern of integrin expression^{7,8}. Moreover, experimentally induced changes in the expression of integrins has been shown to correlate with growth, invasiveness, and metastatic competence of tumor cells *in vivo*⁹⁻¹².

In the present study we examined the *in vitro* expression of integrin (subunits) in the human embryonal carcinoma cell line N_Tera/2D1 (Tera) and its 3.7 fold cisplatin resistant subline Tera-CP¹³. This subline acquired its cisplatin resistance *in vitro*. Although *in vitro* both cell lines showed similar growth characteristics¹³, *in vivo* tumors derived from the parental cell line Tera appeared less tumorigenic than tumors derived from the resistant cell line Tera-CP (Chapter 4.2).

The aim of this study was to investigate if differences in integrin phenotype might offer an explanation to the observed differences in growth and differentiation of both cell lines *in vivo*. As changes in integrin expression might account for the anticancer action of all-trans retinoic acid¹⁴⁻¹⁶, we also examined the expression of integrin (subunits) in both cell lines after 96 hours treatment with this retinoid.

MATERIALS AND METHODS

Cell lines. The embryonal carcinoma cell line Tera and its 3.7 fold cisplatin resistant subline Tera-CP were grown at high cell density (a minimum of 1.5×10^6 in a 25-cm² flask) as a monolayer in RPMI 1640 medium supplemented with 10% fetal calf serum in a humidified atmosphere with 5% CO₂ at 37°C. Incubation of both cell lines with 10⁻⁷M all-trans retinoic acid was performed for 96 hours with a renewal of culture medium and all-trans retinoic acid after 48 hours.

Immunohistochemistry. Immunohistochemistry was carried out on cytospin preparations fixed in acetone for 10 minutes at room temperature (20°C). The sections were washed for 5 minutes in phosphate-buffered saline (PBS) after each incubation step. The sections were incubated with optimal dilutions of the antibodies, as determined previously. To decrease non-specific binding the final second and third step antibody dilutions contained 1% normal human AB serum. The localization of the peroxidase label was visualized using 3-amino-9-ethylcarbazol together with H₂O₂ as a reagent giving a reddish brown precipitate. The slides were counterstained with hematoxylin and mounted

with Kaisers glycerol-gelatin. Controls included sections on which the application of the primary antibody was omitted or replaced by nonrelevant antibodies.

Table 1. Anti-integrin antibodies used.

Antibody clone; catalog #	subunit	CD	source
TS2/16	$\beta 1$	29	Springer, Boston, USA
CLB Tromb/1	$\beta 3$	61	van Lier, Amsterdam, The Netherlands
3E1; A054	$\beta 4$	104	Telios, San Diego, USA
TS2/7	$\alpha 1$	49a	Hemler, Boston, USA
CLB Tromb/4	$\alpha 2$	49b	Sonnenberg, Amsterdam, The Netherlands
P1B5; A043	$\alpha 3$	49c	Telios, San Diego, USA
B5G10	$\alpha 4$	49d	Hemler, Boston, USA
NKI-SAM1	$\alpha 5$	49e	Monosan, Uden, Netherlands
G0H3	$\alpha 6$	49f	Sonnenberg, Amsterdam, The Netherlands
VNR147; A09	αv	51	Telios, San Diego, USA
P1F6; A035	$\alpha v \beta 5$	51/-	Telios, San Diego, USA

CD, cluster of differentiation.

Chemicals. RPMI 1640 medium and fetal calf serum were obtained from Life Technologies (Paisly, United Kingdom). All-trans retinoic acid was purchased from Sigma Chemical Co. (St Louis, USA). Details on the used antibodies directed against integrin (subunits) are given in Table 1. Peroxidase conjugated second and third step antisera were purchased from DAKO (Glostrup, Denmark). Kaisers glycerol-gelatin was obtained from Merck (Darmstadt, Germany).

RESULTS

The results are summarized in Table 2. In Tera and Tera-CP, $\alpha 1$ and $\alpha 3$ integrin subunit were weakly expressed in less than 5% of the cells. Both cell lines showed uniform strong expression of $\alpha 5$, $\alpha 6$, αv , and $\beta 1$ integrin subunits. The majority of cells in Tera and Tera-CP stained positively with a monoclonal antibody directed against the $\alpha v \beta 5$ integrin. Neither in Tera nor in Tera-CP $\alpha 2$, $\alpha 4$, $\beta 3$ and $\beta 4$ integrin subunits could be detected. After incubation with all-trans retinoic acid the $\alpha 4$ integrin subunit was de novo expressed in less than 5% of the tumor cells (Figure 1A and B). Moreover, compared to untreated cells, increased staining intensity was noticed for the $\alpha 5$ integrin subunit in Tera as well as in Tera-CP (Figure 1C and D).

Table 2. Expression of integrin subunits in TERA and TERA-CP before and after 96 hour treatment with all trans retinoic acid.

Integrin subunit	Tera	Tera-CP	all-trans retinoic acid
$\beta 1$	++++	++++	++++
$\beta 3$	-	-	-
$\beta 4$	-	-	-
$\alpha 1$	+	+	+
$\alpha 2$	-	-	-
$\alpha 3$	+	+	+
$\alpha 4$	-	-	+
$\alpha 5$	++++	++++	++++'
$\alpha 6$	++++	++++	++++
αv	++++	++++	++++
$\alpha v\beta 5$	++++	++++	++++

Percentage of positive cells: (-), no positive cells; (+), < 5% positive cells; (++) , 5-10% positive cells; (+++), 10-50% positive cells; (++++), 50-100% positive cells. ' increased staining intensity of the $\alpha 5$ integrin subunit upon treatment of TERA and TERA-CP for 96 hours with all trans retinoic acid.

DISCUSSION

Recent studies suggest that the phenotype of malignant tumors is in part dependent on the microenvironment in which tumor cells reside. As part of the microenvironment ECM proteins may exert their action by binding to members of the integrin family of cell adhesion molecules. Upon ligand binding integrins may generate signals that interfere with the growth of malignant tumors, either by a direct effect on proliferation or by preventing a apoptotic cell response that evolves after disruption of cell-cell and cell-matrix interactions^{9,10,17,18}. In addition, by promoting differentiation integrins, may indirectly influence the growth of malignant tumors¹⁹.

In the present study we investigated the expression of integrin subunits in the human embryonal carcinoma cell line Tera and its cisplatin resistant subline Tera-CP. Integrins expressed by both cell lines are likely to play an active role in the establishment of an anchorage dependent growth pattern. Although human embryonal carcinoma cells do synthesize ECM proteins, the amount deposited is not sufficient to enable attachment. Instead, the growth of human embryonal carcinoma cells seems to be dependent on attachment factors present in the serum²⁰. More specifically, it appeared that human embryonal carcinoma cells use the $\alpha v\beta 3$ integrin for attachment to vitronectin²⁰. As Tera and Tera-CP do not express the $\alpha v\beta 3$ integrin, one might speculate that the $\alpha v\beta 5$ integrin may be used as an alternative vitronectin receptor. Alternatively, anchorage dependent growth may be mediated by $\alpha 5\beta 1$ -fibronectin interactions. In a previous study fibronectin was shown to be essential to the growth of murine embryonal carcinoma cells but not for the growth of human embryonal carcinoma cells²⁰. Thus, the type of cell-matrix interaction essential to anchorage dependent growth of Tera and Tera-CP remains to be

resolved.

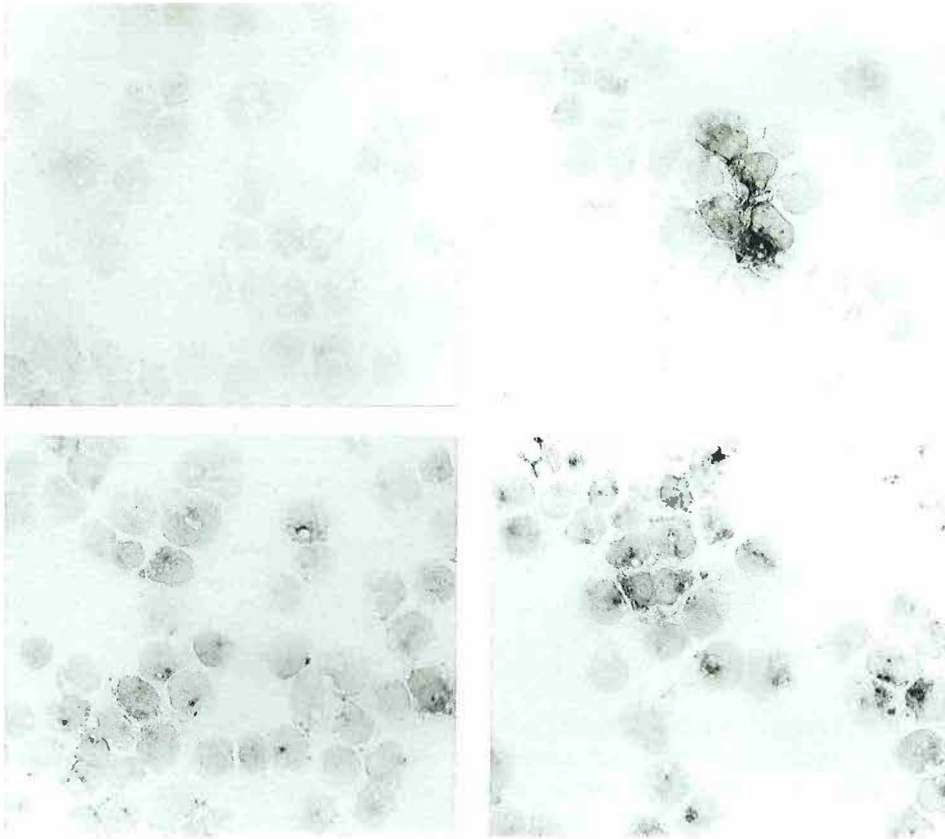


Figure 1. $\alpha 4$ integrin subunit expression in Tera, before (A, top left) and after (B, top right) treatment with all-trans retinoic acid for 96 hours. $\alpha 5$ integrin subunit expression in Tera, before (C, bottom left) and after (D, bottom right) treatment with all-trans retinoic acid for 96 hours (immunoperoxidase, 400x).

In vitro, doubling time and cell cycle distribution were comparable in both cell lines¹³. Moreover, upon application of 10^{-7} M all-trans retinoic acid Tera and Tera-CP showed a similar propensity to differentiate (own observations). In vivo, tumors derived from Tera appeared less tumorigenic than tumors derived from Tera-CP. This may in part be related to the higher percentage of differentiated cells in Tera (Chapter 4.2). Although differences in tumor biology between related cell lines have been linked to differences in integrin expression⁹⁻¹², our study did not reveal differences in integrin expression between Tera and Tera-CP that can explain differences in biology observed in vivo. Loss or gain of genes essential to growth and differentiation may offer a genetic rather than an epigenetic explanation for in vivo differences between Tera and Tera-CP. In line with this

suggestion is the observation that both cell lines show marked numerical and structural differences in karyotype¹³. However, epigenetic and genetic factors are likely to act in concert as full phenotypic expression becomes only apparent after subcutaneous injection of tumor cells in nude mice (Chapter 4.2).

Retinoids have important regulatory roles in particular in cell growth and differentiation. Only in the last two decades their potential role in prevention and therapy of malignancies was explored. The effects of retinoids are thought to be mediated by nuclear receptors that belong to the supergene family of steroid hormone receptors. The biological active metabolites all-trans retinoic acid and 9-cis retinoic acid bind to retinoic acid receptors (RAR) and retinoid X receptors (RXR). Upon (hetero)dimerization of RARs and RXRs the complex acts as a transcription factor by binding to hormone responsive elements in the promotor region of target genes²¹. Both all-trans retinoic acid and 9-cis retinoic acid have been shown to induce a differentiated phenotype in human embryonal carcinoma cells²², and this effect seems to be at least in part mediated by RARgamma²³.

Within 24 hours after treatment with all-trans retinoic acid the level of expression of many retinoid-responsive genes is altered, and most of them encode transcription factors²⁴. After 48-72 hours genes are activated that encode proteins that characterize a more differentiated phenotype. Among these are proteins that have a role in cell-matrix interactions, and it has been suggested that retinoids exert their action at least in part through modulation of cell-matrix interactions^{14-16,24}. Concordantly, de novo expression of the $\alpha 4$ integrin subunit and upregulation of the $\alpha 5$ integrin subunit in Tera and Tera-CP may be used as markers of retinoid-induced embryonal carcinoma cell differentiation. Expression of other integrin subunits was unchanged. Modulation of integrin affinity and specificity through phosphorylation and/or alternative splicing of integrin subunits (not detected by immunohistochemistry) may be an additional way by which all-trans retinoic acid exerts its action in (human) embryonal carcinoma cells^{25,26}. Future studies will have to elucidate whether changes in integrin expression, and function are related to some of the anticancer actions of retinoids in human embryonal carcinoma cells, as may be supposed from studies using all-trans retinoic acid pretreated murine F9 embryonal carcinoma cells^{15,27}.

Normal tissues show characteristic cell-lineage dependent integrin distribution patterns that may be conserved in their malignant counterparts²⁸. Upon application of all-trans retinoic acid Tera and Tera-CP showed differentiation into the neuronal lineage (own observations). Using the same human embryonal carcinoma cell line, Pleasure et al demonstrated that neurons derived from Tera embryonal carcinoma cells have features of central nervous system (CNS) neurons²⁹. In contrast to neurons of the peripheral nervous system³⁰, CNS neurons do not express the $\beta 4$ integrin subunit³¹. Therefore, absence of the $\beta 4$ integrin subunit in Tera and Tera-CP may be indicative of the CNS character of Tera and Tera-CP derived neuronal cells.

Integrin subunits expressed by both cell lines have been implicated in the interaction of developing neurons with the ECM³². The derivation of terminally differentiated neurons after prolonged culture on Matrigel (basement membrane extract containing collagen, laminin, and nidogen) out of retinoid-induced human embryonal carcinoma cells suggests that integrin-ECM interactions are essential to (neuronal) differentiation of human embryonal carcinoma cells too²⁹. Based on our data however, it is difficult to discern if expression of integrin subunits in Tera and Tera-CP is simply a

tissue culture induced phenomenon, or alternatively reflects the degree of malignancy of the cell, and could be related to the degree and lineage of differentiation.

In summary, (based on the literature) integrins are likely to play an active role in growth and differentiation of Tera and Tera-CP human embryonal carcinoma cells. De novo expression of the $\alpha 4$ integrin subunit and upregulation of the $\alpha 5$ integrin subunit may be used as markers of retinoid-induced differentiation. Absence of $\beta 4$ integrin subunit expression may be indicative of the CNS character of embryonal carcinoma cell derived neuronal cells. No differences were observed in integrin expression that might account for differences in growth and differentiation observed in vivo. Moreover, it seems likely that integrins do not play a major role in cell functions operational in resistance to cisplatin. Future studies will have to elucidate whether retinoid-induced changes in integrin subunit expression are a reflection of the process of differentiation itself (inside-out signalling), or whether differentiation is affected by the pattern of integrin expression (outside-in signalling).

Acknowledgments

The authors thank Miss Nadia Jacobs for technical assistance, and Mr. Siep Noorman for help in the preparation of microphotographs. This study was supported by the Dutch Cancer Society Grant GUKC 88-11 and the J.K. De Cock Foundation Groningen.

REFERENCES

1. Bissell M J, Hall H G, Parry G: How does the extracellular matrix direct gene expression J Theor Biol 1982, 99: 31-68
2. Hynes R O: Integrins: Versatility, modulation, and signalling in cell adhesion. Cell 1992, 69: 11-25
3. Sastry S K, Horwitz A F: Integrin cytoplasmic domains: Mediators of cytoskeletal linkages and extra- and intracellular initiated transmembrane signalling. Curr Opin Cell Biol 1993, 5: 819-831
4. Damsky C H, Werb Z: Signal transduction by integrin receptors for extracellular matrix: Cooperative processing of extracellular information. Curr Opin Cell Biol 1992, 4: 772-781
5. Ginsberg M H, Du X, Plow E F: Inside-out integrin signalling. Curr Opin Cell Biol 1992, 4: 766-771
6. Juliano R L, Haskill S: Signal transduction from the extracellular matrix. J Cell Biol 1993, 120: 577-585
7. Albelda S M: Role of integrins and other cell adhesion molecules in tumor progression and metastasis. Lab Invest 1993, 68: 4-17
8. Juliano R L, Varner J A: Adhesion molecules in cancer: The role of integrins. Curr Opin Cell Biol 1993, 5: 812-818

9. Giancotti F G, Ruoslahti E: Elevated levels of the alpha 5 beta 1 fibronectin receptor suppress the transformed phenotype of Chinese hamster ovary cells. *Cell* 1990, 60: 849-859
10. Felding-Habermann B, Mueller B M, Romerdahl C A, Cheresch D A: Involvement of integrin α V gene expression in human melanoma tumorigenicity. *J Clin Invest* 1992, 89: 2018-2022
11. Chan B M C, Matsuura N, Takada Y, Zetter B R, Hemler M E: In vitro and in vivo consequences of VLA-2 expression on rhabdomyosarcoma cells. *Science* 1991, 151: 1600-1602
12. Qian F, Vaux D L, Weissman I L: Expression of the integrin α 4 β 1 on melanoma cells can inhibit the invasive stage of metastasis formation. *Cell* 1994, 77: 335-347
13. Timmer-Bosscha H, Timmer A, Meijer C, De Vries E G E, de Jong B, Oosterhuis J W, Mulder N H: cis-diamminedichloroplatinum(II) resistance in vitro and in vivo in human embryonal carcinoma cells. *Cancer Res* 1993, 53: 5707-5713
14. Gaetano C, Melchiori A, Albin A, Benelli R, Falcioni R, Modesti A, Modica A, Scarpa S, Sacchi A: Retinoic acid negatively regulates β 4 integrin expression and suppresses the malignant phenotype in a Lewis lung carcinoma cell line. *Clin Exp Metastasis* 1994, 12: 63-72
15. Ross S A, Ahrens R A, De Luca L M: Retinoic acid enhances adhesiveness, laminin and integrin β 1 synthesis, and retinoic acid receptor expression in F9 teratocarcinoma cells. *J Cell Phys* 1994, 159: 263-273
16. Dedhar S, Robertson K, Gray V: Induction of expression of the alpha v beta 1 and alpha v beta 3 integrin heterodimers during retinoic acid-induced neuronal differentiation of murine embryonal carcinoma cells. *J Biol Chem* 1991, 266: 21846-21852
17. Bates R C, Buret A, van Helden D F, Horton M A, Burns G F: Apoptosis induced by inhibition of intercellular contact. *J Cell Biol* 1994, 125: 403-415
18. Montgomery A M P, Reisfeld R A, Cheresch D A: Integrin α v β 3 rescues melanoma cells from apoptosis in three-dimensional dermal collagen. *Proc Natl Acad Sci USA* 1994, 91: 8856-8860
19. Hay E D: Extracellular matrix alters epithelial differentiation. *Curr Opin Cell Biol* 1993, 5: 1029-1035
20. Pera M F, Roach S, Elliss C: Comparative biology of mouse and human embryonal carcinoma. *Cancer Surv* 1990, 9: 243-262
21. Giguère V: Retinoic acid receptors and cellular retinoid binding proteins: Complex interplay in retinoid signaling. *Endocrine Rev* 1994, 15: 61-79
22. Kurie J M, Buck J, Eppinger T M, Moy D, Dmitrovsky E: 9-cis and all-trans retinoic acid induce a similar phenotype in human teratocarcinoma cells. *Differentiation* 1993, 54: 123-129
23. Moasser M M, DeBlasio A, Dmitrovsky E: Response and resistance to retinoic acid are mediated through the retinoic acid nuclear receptor gamma in human teratocarcinomas. *Oncogene* 1994, 9: 833-840

24. Love J M, Gudas L J: Vitamin A, differentiation and cancer. *Curr Opin Cell Biol* 1994, 6: 825-831
25. Dahl S C, Gabel L B: Integrin phosphorylation is modulated during the differentiation of F9 teratocarcinoma stem cells. *J Cell Biol* 1989, 108: 183-190
26. Hierck BP, Thorsteindottir S, Niessen CM, Freund E, Iperen LV, Feyen A, Hogervorst F, Poelman RE, Mummery CL, Sonnenberg A: Variants of the alpha 6 beta 1 laminin receptor in early murine development: distribution, molecular cloning and chromosomal localization of the mouse integrin alpha 6 subunit. *Cell Adhes Commun* 1993, 1: 33-53
27. Rusciano D, Lorenzoni P, Burger MM: The role of both specific cellular adhesion and growth promotion in liver colonization by F9 embryonal carcinoma cells. *Int J Cancer* 1991, 48: 450-456
28. Miettinen M, Castello R, Wayner E, Schwarting R: Distribution of VLA integrins in solid tumors. *Am J Pathol* 1993, 142: 1009-1018
29. Pleasure S J, Page C, Lee V M -Y: Pure, postmitotic, polarized human neurons derived from NTera 2 cells provide a system for expressing exogenous proteins in terminally differentiated neurons. *J Neurosci* 1992, 12: 1802-1815
30. Mechtersheimer G, Barth T, Quentmeier A, Möller P: Differential expression of $\beta 1$, $\beta 3$, and $\beta 4$ integrin subunits in nonneoplastic neural cells of the peripheral and autonomic nervous system and in tumors derived from these cells. *Lab Invest* 1994, 70: 740-752
31. Paulus W, Baur I, Schuppan D, Roggendorf W: Characterization of integrin receptors in normal and neoplastic human brain. *Am J Pathol* 1993, 143: 154-163
32. Letourneau P C, Condic M L, Snow D M: Interactions of developing neurons with the extracellular matrix. *J Neurosci* 1994, 14: 915-928

Chapter 5

**SUMMARY, GENERAL DISCUSSION,
AND FUTURE PROSPECTS**

TESTICULAR GERM CELL TUMORS

As reviewed in **Chapter 1**, testicular germ cell tumors can be divided into seminomas, composed of neoplastic gonocytes, and nonseminomas, pluripotent tumors which can be considered as the neoplastic counterpart of early embryos. The germ cell origin of these tumors is firmly established, and current concepts consider intratubular germ cell neoplasia as the preinvasive stage of all adult testicular germ cell tumors with the possible exception of spermatocytic seminoma. Evidence is emerging that seminomas and nonseminomas are histogenetically related and represent stages in tumor progression of testicular germ cell tumors. Progression of intratubular germ cell neoplasia to seminoma and/or nonseminoma is accompanied by significant changes in ploidy and karyotype. The inherent aggressiveness of the histological subtypes largely determines the heterogeneity of testicular germ cell tumors with respect to clinical presentation and reaction to therapy. Yet, (epigenetic) factors that control phenotypic expression, and thus the biology of the histological subtypes, are largely undefined. The choice of therapy in testicular germ cell tumors depends on the histology of the primary tumor (seminoma versus nonseminoma), clinical stage, and the anticipated biological stage. The latter may be extrapolated from clinical, pathological, biological, and genetic parameters. Although testicular germ cell tumors have become a model for curable cancer, presently about 20% of all patients with a testicular germ cell malignancy will succumb due to the growth of residual tumor resistant to chemotherapeutic drugs.

INTEGRINS AND EXTRACELLULAR MATRIX PROTEINS IN THE BIOLOGY OF TESTICULAR GERM CELL TUMORS

Normal testis and testis with intratubular germ cell neoplasia

In **Paragraph 2.1.2** a review is given on the presence and function of extracellular matrix (ECM) proteins in the developing and mature testis. Similar to morphogenetic processes in other organ systems it appears that ECM proteins play a pivotal role in testicular development. For example, the selective distribution of fibronectin along the migration pathway of primordial germ cells suggests that migration of primordial germ cells is at least in part dependent on their interaction with fibronectin. The onset of testicular cord formation is associated with marked changes in the distribution of ECM proteins. However, presently it is not yet clear whether cell-matrix interactions provide the initial signal that activates the morphogenetic cascade or whether initially soluble factors are involved. The coordinated interaction of both myoid cells and Sertoli cells is essential for the formation of the basement membrane (BM) that surrounds testicular cords and, later on, the seminiferous tubules. Conversely, in the adult testis normal seminiferous tubule function including spermatogenesis seems to be dependent on the cooperative action of Sertoli and myoid cells, in which the tubular BM plays an essential role. In atrophic tubules and in intratubular germ cell neoplasia the lamina propria and tubular BM were thickened with invaginations of the BM into the tubular lumen (**Chapter 2.2**). This increase in the deposition of ECM proteins suggests that the balance between production and degradation of BM constituents is lost, either by increased deposition or by decreased degradation of BM components. Yet, at this moment it is impossible to determine whether the impaired spermatogenesis is the trigger that leads

to increased deposition of ECM proteins or that the impaired spermatogenesis is secondary to the changes that occur in the tubular BM. In tubules containing intratubular germ cell neoplasia these changes may be related to a dysregulation of testicular homeostasis, rather than to the presence of malignant intratubular germ cells per se, as similar abnormalities are observed in a variety of local and systemic pathological conditions that lead to tubular atrophy and hyalinization. Finally, in tubules with impaired spermatogenesis, Sertoli cells have been described to coexpress vimentin and keratin ¹, a feature that is characteristic for immature prepubertal Sertoli cells ². By comparing the integrin profile of foetal and prepubertal Sertoli cells with Sertoli cells in atrophic and intratubular germ cell neoplasia containing tubules, one might elucidate whether increased expression of $\alpha 3$ and $\alpha 6$ integrin subunits on Sertoli cells in these abnormal tubules is a sign of immaturity.

Integrins in the biology of malignant tumors

The role of the integrin-matrix interactions in the biology of malignant tumors in general is discussed in **Paragraph 2.1.3**. Upon malignant transformation and subsequent tumor progression the pattern of integrin expression changes and becomes disorganized. However, lineage specific integrin distribution patterns may be conserved in malignant tumors, and occasionally reexpression of embryonic integrins may be observed. Compared to their nontumorigenic counterparts malignant tumors in general show a tendency to express reduced levels of integrins, although in some tumors integrins may be upregulated, or expressed de novo. Functionally, integrins may have inhibitory as well stimulatory effects on tumor cell growth, that in part may be related to conferral of resistance to anoikis (apoptotic cell response after detachment of cells from the ECM) or rescue from programmed cell death by ECM-mediated ligation of integrins present on the tumor cell surface. Furthermore, integrins may inhibit as well as promote the formation of metastases, and can play different roles at different metastatic stages. In line with current concepts on metastasis formation it appears that the effects of integrins on tumor growth and metastasis formation are not necessarily linked. Thus, although the redundancy in integrin-ligand interactions is enormous, experimental data point to different roles for specific integrins at different stages of the metastatic cascade. The association of specific integrin subunits with grade, stage, disease-free survival and overall-survival supports the view that integrins may be used as biological parameters that aid in the evaluation of the risk for metastasis formation and the choice of adequate therapy.

Seminoma

Data on the expression of integrin subunits and distribution of ECM proteins in intratubular germ cell neoplasia, seminoma and nonseminoma (**Chapters 2.2 and 2.3**) are concordant with data reviewed in Paragraph 2.1.3. Malignant intratubular germ cells showed a strong, nonpolarized expression of the $\alpha 3$, and $\alpha 6$ integrin subunits, and a weak expression of the $\beta 1$ integrin subunit. Progression of intratubular germ cell neoplasia to invasive seminoma was associated with loss of $\alpha 3$ integrin subunit expression. In primary seminomas the $\alpha 5$ integrin subunit was weakly expressed in all stages. All tumors showed a strong expression of $\alpha 6$ and $\beta 1$ integrin subunits. Compatible with degradation of BM components, in intratubular germ cell neoplasia the tubular BM revealed gaps besides thickened and irregular parts. Based on the distribution of collagen type I, 3 types of stromal reaction could

be recognized. Since differences between the three types of stromal reaction were partly relative, they may represent different stages in the ongoing process of fibrovascular stroma formation. Small band-like structures resembling BMs were randomly distributed in all primary seminomas and metastases of primary seminomas. These structures may well represent tubular remnants, not degraded by proteolytic enzymes. However, the linear distribution of BM components at the interface of tumor cells and stroma, and the presence of these structures in metastatic lesions suggests that BM components in seminomas may also be newly deposited.

The heterogeneity in integrin subunit expression and distribution of ECM proteins suggest a dynamic interplay between seminoma cells and host cells. However, the contribution of both cell populations to the formation of the ECM has to be determined. It seems likely that seminoma cells themselves do not contribute significantly to the formation of the ECM as cytoplasmic staining for ECM proteins is not evident (unpublished observations, ³). Whatever the origin of the ECM in seminomas, the interaction of seminoma cells with the microenvironment is likely to interfere with processes such as cell survival, proliferation, and migration. The observation that seminoma cells enter an apoptotic pathway, when kept *in vitro* in the absence of a specific matrix ⁴, is in line with this hypothesis, and future studies will have to elucidate whether this response can be viewed as anoikis. In contrast to the former, integrin-matrix interactions may also have an adverse effect on the invasiveness and metastatic competence of seminoma cells. Experimental studies suggest that the adhesiveness of primordial germ cells to fibronectin in part determines the motility of these cells. E.g., the switch from nonmigratory to migratory stages of primordial germ cell migration coincides with a decreased adhesion of primordial germ cells to fibronectin (Paragraph 2.1.1). Similarly, and analogous to the adhesion of intratubular cells to the tubular BM, adhesion of seminoma cells to BM-like structures and the interstitial matrix may hamper their migration and bear on the development of metastases. Interestingly, malignant intratubular germ cells and invasive seminomas express the same integrins ($\alpha 3$, $\alpha 5$, $\alpha 6$, and $\beta 1$) as nonmigratory murine primordial germ cells. As primordial germ cell migration is a highly conserved process in different species (Paragraph 2.1.1) one might speculate that human primordial germ cells use the same set of integrins as their murine counterparts. Future studies will have to elucidate whether the (adhesive) mechanisms used by malignant intratubular germ cells and seminoma cells to survive, proliferate and migrate, are analogous to the ones used by their nontumorigenic precursors and counterparts, e.g., human primordial germ cells and gonocytes respectively. Of special interest is the role of c-kit-stem cell factor interactions as c-kit is expressed by human primordial germ cells as well as malignant intratubular germ cells and seminoma cells ^{5,6}, and has been shown to modulate the (integrin-mediated) adhesiveness of hematopoietic cells to substrates coated with ECM proteins ^{7,8}. Similarly, one might speculate that binding of stem cell factor to c-kit on malignant intratubular germ cells and seminoma cells may modulate the expression and function of integrins on the tumor cell surface.

Nonseminoma

In **Chapter 2.3** results are presented on the expression of integrin subunits and distribution of ECM proteins in 34 testicular nonseminomas. In line with the epithelial nature of embryonal carcinoma cells are the weak expression of epithelial $\alpha 2$ and $\alpha 3$ integrin subunits, and the variable increased density of the $\alpha 6$ integrin subunit at the interface of

tumor cells and the stroma. Putatively, embryonal carcinomas with features of ongoing epithelial differentiation may behave differently, e.g., are associated with less malignant properties. Support for this case can be found from studies in which testicular germ cell tumors with an inherent capacity for somatic differentiation, apparent from a teratoma component, are associated with a better prognosis (Chapter 1). In contrast to highly invasive embryonal carcinoma, mature teratomas are supposed to be noninvasive and nonmetastatic. Concordantly, mature teratomas are composed of a variety of highly differentiated tissues derived from all three germ layers. Despite this benign phenotype, teratomas are in fact malignant as illustrated by the presence of marked genetic abnormalities, and the ability of residual mature teratoma to grow and progress to a non-germ cell malignancy (Chapter 1). Similar to their nonneoplastic counterparts, in teratoma each tissue has its own characteristic integrin profile, suggesting that in teratoma conserved presence of integrins may contribute to the high degree of differentiation and in this way to the indolent biological behavior of this histological subtype. Like teratomas, yolk sac tumors may also be composed of different histological subtypes⁹. Yet, in our study the number of yolk sac tumors was too limited to draw conclusions on the relation of integrin subunit expression and histological subtype. In choriocarcinomas syncytiotrophoblastic giant cells as well as cytotrophoblastic cells demonstrated a complex integrin phenotype. Most of the integrin subunits were shared by both cell types, although differences in staining intensity were observed. Compared to normal placental cytotrophoblastic cells, in choriocarcinoma cytotrophoblastic cells showed aberrant expression of integrin subunits, putatively leading to a disbalance between cell-matrix interactions that promote invasion (collagen/laminin- α 1 β 1 integrin interactions) and those that restrain invasion (fibronectin- α 5 β 1 interactions) of normal cytotrophoblastic cells. The differences in distribution of ECM proteins between the different histological subtypes were relative. Variable *in vitro* synthesis of ECM proteins by different histological subtypes suggests an in part lineage dependent tumor cell origin of ECM proteins *in vivo*¹⁰⁻¹³. Investigation of ECM protein isoform distribution, for example by using antibodies directed against the different chains of the laminin molecule¹⁴, may reveal in addition to quantitative differences, qualitative differences in distribution of ECM proteins, that can be expected to be relevant to the biology of these tumors^{15,16}. Interestingly, *in vitro* growth of embryonal carcinoma cells can be supported by ECM proteins secreted by yolk sac tumors¹². Similarly, and analogous to paracrine support of neighboring cells during the early stages of embryogenesis¹¹ one might hypothesize that paracrine support of one particular germ cell tumor to another is relevant to the biology of testicular germ cell tumors as well.

Of particular interest is the remaining question how differentiation in testicular germ cell tumors is regulated. Based on several studies, a prominent role for genetic factors can be recognized as several tumor suppressor genes and oncogenes show a histological subtype restricted expression pattern, that may be determined by tumor progression related loss or gain of genes essential to growth and differentiation^{17,18}. The imprinting status of the genome in testicular germ cell tumors is supposed to be dependent on the maturation stage of the primordial germ cell at the time of initiation. In fact, by regulating which part of the genome will be transcribed, genomic imprinting may determine whether in testicular germ cell tumors differentiation proceeds along the germinal, embryonal, or extraembryonal lineage (Chapter 1). The extensive differentiation of human embryonal carcinoma cells after subcutaneous injection of nude mice (Chapters 4.1 and 4.2), and the derivation of distinct cell types upon application of different differentiation inducers^{19,20} suggest that the phenotype of human testicular germ cell tumors is dependent on the cooperative action of multiple factors present

in the microenvironment. Indeed, the heterogeneity of testicular germ cell tumors with respect to integrin subunit expression suggests that cell-matrix interactions are involved in differentiation of these tumors. Yet, whether integrins contribute actively to differentiation by inducing and/or repressing histological subtype specific gene expression (outside-in signalling), or whether expression of integrins is a reflection of the process of differentiation itself (inside-out signalling) is to be determined. In a recent study, morphological differentiation of murine F9 embryonal carcinoma cells was shown to be prevented by abrogation of $\beta 1$ integrin-ECM interactions²¹. Analogously, one might hypothesize that the morphological changes that coincide with tumor progression of intratubular germ neoplasia to invasive nonseminoma are integrin mediated as well. Obviously, to confirm this hypothesis, seminoma cell lines are needed in which seminoma cells can be reprogrammed to pluripotency. Besides cell-matrix interactions other epigenetic factors may contribute to testicular germ cell tumor differentiation. Among these growth factors/cytokines, hormones, vitamins, and cell-cell interactions can be considered to be the most important. Intratumoral variation of these factors, and of metabolic substrates, PH and oxygenation, gives a selective pressure that may lead to heterogeneity, and further contributes to differentiation of these tumors²²⁻²⁴.

In conclusion, the developmental potential of testicular germ cell tumors seems to be restricted by the (tumor progression related) genetic make up of the tumor and the imprinting status of the genome. Yet, to express the differentiated phenotype microenvironmental factors are needed. This regulatory model assumes that differentiation in testicular germ cell tumors is highly regulated, and therefore susceptible to the differentiation inducing activity of agents like retinoids.

DIFFERENTIATION INDUCTION AS PART OF ANTI-CANCER THERAPY IN MURINE AND HUMAN TERATOCARCINOMAS

A major challenge in the treatment of patients with testicular germ cell tumors is the cure of patients with tumors that are inherently resistant or have become resistant to chemotherapeutic drugs. Salvage therapies have been developed and are under investigation. At the worst still 20% of patients with advanced nonseminomas can not be cured. Potentially retinoids might play a role in better treatment results in these groups. Combination of chemotherapy and induction of (terminal) differentiation by means of retinoids might theoretically be fruitful as the mechanisms of action are quite different: tumor cell kill and in addition reversion of malignant phenotype of (chemotherapy resistant) tumor cells into terminally differentiated nonproliferating, noninvasive cells.

Murine teratocarcinoma

In **Chapter 3** the combination of a cytotoxic drug and a differentiation inducing agent in vivo in three murine teratocarcinoma models with different levels of spontaneous somatic differentiation (E86-379 (moderate differentiation); NF-1 (poor differentiation); MH-15 (no differentiation)) is discussed. Cisdiamminedichloroplatinum(II) (CDDP) was used as a cytotoxic drug and all-trans retinoic acid was used as differentiation inducing agent. The untreated tumors grew progressively. CDDP alone prevented tumor growth. The combination

of all-trans retinoic acid and CDDP gave a significant further reduction of tumor size as compared with either all-trans retinoic acid or CDDP alone. All-trans retinoic acid as differentiation inducing agent increased the percentage of differentiated residual tissue, but only in tumors with the capacity of spontaneous somatic differentiation (NF-1 and E86-379). The nullipotent MH-15 tumor was not induced to differentiate, and thus did not give rise to residual mature teratoma. Rather than having an adverse effect, it turned out that all-trans retinoic acid alone tended to reduce tumor growth in all models, however, only significant reduction was found in the MH-15 tumors. This indicates that, similar to the effect of 13-cis retinoic in xenografts of Tera-CP (Chapter 4.2), the effect of all-trans retinoic acid in MH-15 tumors probably was more a result of retinoid-induced growth inhibition than a effect of induction of differentiation. Thus, in murine teratocarcinomas the use of all-trans retinoic acid as a differentiation inducing agent indeed increases the percentage of differentiated residual tumor, but only in tumors with the capacity of spontaneous somatic differentiation.

Human teratocarcinoma

Acquired resistance to CDDP is one of the major problems encountered in the therapy of testicular germ cell tumors. The mechanisms contributing to CDDP resistance are diverse, and include reduced drug accumulation and increased detoxification in the cytoplasm. In the cell nucleus, decreased DNA accessibility and DNA repair may play a role^{25,26}. Chapter 4.1 describes a 3.7 fold CDDP-resistant subline (Tera-CP) of N_{Tera}/2D1 (Tera), an human embryonal carcinoma cell line with the capacity to differentiate in vitro as well as in vivo. In vitro both cell lines mainly consisted of embryonal carcinoma cells. For this reason, in Tera-CP CDDP-resistance seems not to be due to a selection of somatically differentiated cells, as is observed in residual lesions of patients treated for a testicular nonseminoma with an inherent capacity for somatic differentiation apparent from a teratoma component (Chapter 1). Tera-CP showed an 1.4-fold increased glutathione (GSH) level, a 1.5-fold increased glutathione S-transferase (GST) activity, and a 1.4-fold increased GST- π expression compared to Tera. The decreased binding of CDDP to DNA in Tera-CP may, in the absence of accumulation defects and in the presence of normal activity of DNA repair enzymes (thymidilate synthase, topoisomerase I and II) be due to an increased efficiency of the detoxifying system. Based on the response of Tera and Tera-CP to a single intraperitoneal dose of 5 mg/kg body weight, an in vivo resistance factor of 2.8 could be calculated. In new cell lines derived from xenografts of Tera and Tera-CP, CDDP sensitivity, GST activity and GSH level corresponded with their sensitivity and resistant origin. Thus, Tera-CP is a model of in vitro and in vivo CDDP resistance with the GSH/GST detoxifying system as an important mechanism. The close correlation of in vitro and in vivo degree of resistance excludes a role for in vivo active, tumor associated factors that influence the pharmacokinetics of CDDP in this nude mouse model, a phenomenon described for a model with in vivo acquired resistance²⁷. Generally, in vitro selection of sublines resistant to chemotherapeutic drugs is accompanied by a decrease in malignant potential, and this phenomenon is referred to as "reverse transformation"²⁸. However, compared to the CDDP sensitive parental cell line Tera, the CDDP-resistant subline Tera-CP demonstrated an increased tumorigenicity (Chapter 4.2). Although in vitro both cell lines showed the same propensity to differentiate²⁹, in vivo the percentage of differentiated tissue in Tera is higher than in Tera-CP, and this difference may explain at least in part the increased tumorigenicity of Tera-CP cells.

In **Chapter 4.2** data are presented on the potential of the combination of a differentiation inducing agent and CDDP treatment, in comparison to each drug alone in xenografts derived from Tera and Tera-CP. Based on the more favorable in vivo pharmacokinetics and the expectation of biologically comparable results, in the present study 13-cis retinoic acid was used as a differentiation inducing agent instead of all-trans retinoic acid. CDDP sensitivity of tumor cells in vivo was not negatively influenced by (pre)treatment with 13-cis retinoic acid. Neither in Tera nor in Tera-CP an increased tumor reduction could be observed in mice treated with CDDP followed by 13-cis retinoic acid compared to the mice treated with CDDP alone. This was in contrast with in vivo potentiation of CDDP cytotoxicity by all-trans retinoic acid in tumors of murine embryonal carcinoma cells with an inherent capacity to differentiate (Chapter 3). This discrepancy could not be due to a complete lack of 13-cis retinoic acid-effect, as in the Tera-CP tumors with only 13-cis retinoic acid a tumor reduction of 20% was achieved. Analogous to the development of clinically favorable residual mature teratoma after chemotherapy for testicular germ cell tumors with an inherent capacity for somatic differentiation (Chapter 1), in the CDDP sensitive Tera tumors with the more extensive differentiation, differentiated cells with inherent resistance to CDDP seemed to survive treatment selectively. In the Tera-CP tumors with acquired CDDP resistance, with less spontaneous somatic differentiation, not only differentiated cells but also embryonal carcinoma cells were present after treatment. The latter gave rise to regrowth of the tumor. Thus, residual lesions of Tera and Tera-CP tumors after treatment with CDDP showed similarities to inherent (CDDP resistant somatically differentiated tumor cells) and acquired CDDP resistance (CDDP resistant undifferentiated embryonal carcinoma cells), as is encountered in the clinical situation. In Tera-CP, addition of 13-cis retinoic acid to CDDP treatment increased differentiation of post-therapy residual tumor cells, thus reducing the invasiveness and metastatic competence of this tumor residue. However, in Tera and Tera-CP differentiation was incomplete and immature. As in vitro embryonal carcinoma cells can be induced to differentiate terminally into nonmitotic neuronal cells ³⁰, one might speculate that the treatment schedule used in our experiment was inappropriate. In order to improve antitumor activity, simultaneous administration of 13-cis retinoic acid and CDDP should be considered for future studies. Regrowth of murine teratocarcinomas after the dose reduction of CDDP (Chapter 3), and the inability of 13-cis retinoic acid to prevent regrowth of Tera-CP tumors when the effect of CDDP had vanished are further arguments for simultaneous administration of CDDP and 13-cis retinoic acid. Finally, enhancement of the effect of 13-cis retinoic acid can be reached by adding cytokines, or other biological response modifiers to the treatment regimen ^{31,32}. Future studies will have to reveal if these alternatives increase the response of embryonal carcinoma cells to retinoids. Finally, our recent data differ from earlier results ²⁹, as in vitro pretreatment of Tera and Tera-CP with all-trans retinoic acid (and 13-cis retinoic acid, H. Timmer-Bosscha, personal communication) for 96 hours strongly prevented cytotoxicity induced by CDDP. Apparently, the response of both cell lines to retinoids is modulated by the microenvironment in which embryonal carcinoma cells reside.

The expression of many genes is altered after treatment with retinoids. Among these are genes that encode proteins that play a role in cell-matrix interactions (Chapter 1). In **Chapter 4.3** the expression of integrin (subunits) in the human embryonal carcinoma cell line Tera and its 3.7 fold CDDP resistant subline Tera-CP is discussed before and after treatment with 10^{-7} M all-trans retinoic acid for 96 hours. The $\alpha 1$ and $\alpha 3$ integrin subunits were weakly

expressed in less than 5% of the tumor cells. Both cell lines showed uniform expression of $\alpha 5$, $\alpha 6$, αv , and $\beta 1$ integrin subunits. The $\alpha v \beta 5$ integrin was expressed by nearly all tumor cells. Neither in Tera nor in Tera-CP $\alpha 2$, $\alpha 4$, $\beta 3$, and $\beta 4$ integrin subunits could be detected. Although integrins expressed by Tera and Tera-CP are likely to play an active role in growth and differentiation, it is difficult to discern whether expression of integrin subunits simply is a tissue culture induced phenomenon, or alternatively reflects the degree of malignancy of the cell, and could be related to the degree and lineage of differentiation. No differences were observed in integrin (subunit) expression that might account for differences in growth and differentiation observed in vivo (Chapter 4.2). Moreover, it seems likely that integrins do not play a major role in cell functions operational in resistance to CDDP. However, the extensive differentiation observed in xenografts of Tera as well Tera-CP (Chapters 4.1 and 4.2) suggests that differentiation in both cell lines is dependent on multiple factors, present in the microenvironment. Hypothetically, the dissimilarity in genetic make up between Tera and Tera-CP may result in differences in cellular signal transduction pathways that only becomes apparent after engagement of the proper microenvironment. Upon application of all-trans retinoic acid the $\alpha 4$ integrin subunit was expressed de novo in less than 5% of the tumor cells, whereas increased staining intensity was noticed for the $\alpha 5$ integrin subunit, suggesting that in Tera and Tera-CP all-trans retinoic acid may exert its action by modulation of cell-matrix interactions. In vitro pretreatment of murine F9 embryonal carcinoma cells with all-trans retinoic acid resulted in a decreased tumorigenicity and a different pattern of metastasis formation of tail vein injected tumor cells³³, that at least in part may depend on modulation of the growth response of tumor cells to the local microenvironment, and changes in the ($\beta 1$ integrin mediated) adhesiveness of tumor cells^{34,35}. Future studies will have to elucidate whether, similar to the effects of all-trans retinoic acid on murine F9 embryonal carcinoma cells, in Tera and Tera-CP retinoid-induced changes in integrin expression are related directly to modulation of growth, invasiveness, and metastatic competence of tumor cells.

CONCLUSIONS AND FUTURE PROSPECTS

It is conceivable to assume that parallels can be drawn between tumors cells and their nonneoplastic counterparts, as tumors can be considered as caricatures of normal tissue renewal and early embryogenesis^{36,37}. Concordantly, compared to their nonneoplastic counterparts, in testicular germ cell tumors a partially conserved expression of integrin subunits was noticed, suggestive to be related to differentiation lineage and biological behavior (Chapters 2.2 and 2.3). However, processes such as invasion and development of metastases are highly regulated, and multiple factors are likely to contribute to the invasiveness and metastatic competence of tumor cells. The dysregulation of multiple regulatory mechanisms operative during physiological processes determines the aggressiveness of a tumor^{38,39}. From this point of view, the role of integrins in the biology of testicular germ cell tumors can only be fully understood if the relation between integrin-dependent and nonintegrin-dependent signal transduction pathways is elucidated.

In order to grow, invade, and metastasize, tumor cells have to elicit their own microenvironment or must become, to a certain degree, independent from their specific microenvironment. In agreement with this, in testicular germ cell tumors ECM protein distribution was heterogeneous, and suggestive to be related to the biology of seminomas as well as nonseminomas. However, the mechanisms responsible for this heterogeneity have to

be elucidated. Do host cells and tumor cells both contribute to the formation of a (differentiation lineage specific) ECM? How is the synthesis and deposition of ECM proteins regulated? To get insight in the role of cell-matrix interactions in biological behavior of these tumors, additional ECM proteins should be studied⁴⁰. Knowledge of the composition of the ECM in testicular germ cell tumors is essential for the development of in vitro models mimicking the in vivo situation. This might especially warranted for seminomas as these tumors, despite recent advances, are difficult to maintain in culture⁴. The balance between ECM protein deposition by tumor and/or host cells and ECM protein degradation, regulated by proteolytic enzymes and their inhibitors, determines the amount of matrix present⁴¹. From this, it is clear that regulation of the expression of these proteinases and anti-proteinases should be subject of future studies. Study of regulatory pathways involved in the regulation of ECM protein synthesis, deposition and degradation enables further insight in the biology of testicular germ cell tumors. Moreover, the disbalance of these and other regulatory pathways as for example revealed by disorganized expression of integrins, irregular deposition of BM proteins and increased expression of proteolytic enzymes, may define an aggressive phenotype that aids in the evaluation of the risk of metastatic spread and in the choice of adequate therapy (Chapter 1).

It is obvious that for patients who belong to the poor risk category, new treatment strategies have to be developed, which not necessarily need to be based on enhancement of the cytotoxic activity of chemotherapeutic drugs⁴². As differentiation in testicular germ cell tumors is supposed to be highly regulated, one might speculate that these alternative treatment strategies may include retinoid-induced terminal differentiation of tumor cells resistant to chemotherapeutic drugs. Treatment of murine and human teratocarcinomas with retinoids indeed did increase the percentage of differentiated cells in murine as well as in human teratocarcinomas, both used as a model for the study of testicular nonseminomas. Moreover, treatment of tumors with retinoids did not interfere with the cytotoxic activity of CDDP (Chapters 3 and 4.2), as might be expected from data on the treatment of patients with disseminated testicular germ cell tumors with an inherent capacity for somatic differentiation (Chapter 1). Future studies should reveal whether in patients with testicular germ cell tumors, retinoids, alone or in combination with chemotherapeutic drugs and/or other biological response modifiers, are as effective as the models suggest. The negative results with all-trans retinoic acid and 13-cis retinoic acid in two Phase II trials (Chapter 1) warrants further study on the clinical efficacy of alternative retinoids.

In order to study the effects of retinoids on differentiation more sensitive parameters should be used, of which determination of platelet-derived growth factor α -receptor transcripts seems one of the most promising⁴³. Evaluation of the response to retinoids should be extended beyond that of differentiation, as retinoids may have pleiotropic effects on malignant tumors (Chapter 1). For example, in vitro the percentage of embryonal carcinoma cells entering a apoptotic pathway is increased after application of all-trans retinoic acid²⁹. Future studies are necessary to evaluate whether retinoids also induce programmed cell death in vivo, and whether the induction of this cell response contributes to the decreased growth of testicular germ cell tumors. Finally, in human embryonal carcinoma cells all-trans retinoic acid exerts its action by means of the retinoic acid receptor gamma⁴⁴. Reduced expression of this receptor confers resistance to the differentiation inducing activity of all-trans retinoic acid. At least in some testicular germ cell tumors, the long arm of chromosome 12 including the region 12q13 is deleted⁴⁵. As the retinoic acid receptor gamma is mapped at this region⁴⁶ one might hypothesize that in testicular germ cell tumors with a deletion of 12q13, the

receptor that mediates the effect of all-trans retinoic acid is also deleted, resulting in an inherent resistance to the anti-cancer action of retinoids. Putatively, and analogous to our data described in Chapter 3, the patients who fail to respond to the differentiation inducing activity of retinoids might be characterized by a nullipotent tumor in which the expression of the retinoic acid receptor gamma is reduced or absent. Therefore, determination of retinoic acid receptor gamma expression in testicular germ cell tumors may identify patients that truly benefit from retinoid-induced modulation of testicular germ cell tumor biology.

REFERENCES

1. Bergmann M, Kliesch S: The distribution pattern of cytokeratin and vimentin immunoreactivity in testicular biopsies of infertile men. *Anat Embryol* 1994, 190: 515-520
2. Stosiek P, Kasper M, Karsten U: Expression of cytokeratins 8 and 18 in human Sertoli cells of immature and atrophic seminiferous tubules. *Differentiation* 1990, 43: 66-70
3. Jacobsen G K: Laminin in testicular germ cell tumours. An immunohistochemical study. *APMIS* 1990, 98: 875-880
4. Olie R A, Looijenga L H J, Dekker M C, de Jong F H, van Dissel-Emiliani F M F, de Rooij D G, van der Holt B, Oosterhuis J W: Heterogeneity in the in vitro survival and proliferation of human seminoma cells. *Br J Cancer* 1995, 71: 13-17
5. Jørgensen N, Rajpert-De Meyts E, Græm N, Müller J, Giwercman A, Skakkebaek N E: Expression of immunohistochemical markers for testicular carcinoma in situ by normal human fetal germ cells. *Lab Invest* 1995, 72: 223-231
6. Rajpert-De Meyts E, Skakkebaek N E: Expression of the c-kit protein product in carcinoma-in-situ and invasive testicular germ cell tumours. *Int J Androl* 1994, 17: 85-92
7. Kinashi T, Springer T A: Steel factor and c-kit regulate cell-matrix adhesion. *Blood* 1994, 83: 1033-1038
8. Kovach N L, Lin N, Yednock T, Harlan J M, Broudy V C: Stem cell factor modulates avidity of $\alpha 4\beta 1$ and $\alpha 5\beta 1$ integrins expressed on hematopoietic cell lines. *Blood* 1995, 85: 159-167
9. Ulbright T M: Germ cell neoplasms of the testis. *Am J Surg Pathol* 1993, 17: 1075-1091
10. Damjanov I, Horvat B, Gibas Z: Retinoic acid-induced differentiation of the developmentally pluripotent human germ cell tumor-derived cell line, NCCIT. *Lab Invest* 1993, 68: 220-232
11. Pera M F, Roach S, Elliss C: Comparative biology of mouse and human embryonal carcinoma. *Cancer Surv* 1990, 9: 243-262
12. Cooper S, Pera M F: Vitronectin production by human yolk sac carcinoma cells resembling parietal endoderm. *Development* 1988, 104: 565-574
13. McIlhinney R A, Patel S: Characterization of the fibronectin synthesized by human germ cell tumors. *Cancer Res* 1983, 43: 1282-1288

14. Timpl R, Brown J C: The laminins. *Matrix* 1994, 14: 275-281
15. Sollberg S, Peltonen J, Uitto J: Differential expression of laminin isoforms and $\beta 4$ integrin epitopes in the basement membrane zone of normal human skin and basal cell carcinomas. *J Invest Dermatol* 1992, 98: 864-870
16. Pyke C, Romer J, Kallunki P, Lund L R, Ralfkiær E, Dano K, Tryggvason K: The gamma2 chain of kalinin/laminin 5 is preferentially expressed in invading malignant cells in human cancers. *Am J Pathol* 1994, 145: 782-791
17. Strohmeier T G, Slamon D J: Proto-oncogenes and tumor suppressor genes in human urological malignancies. *J Urol* 1994, 151: 1479-1497
18. Looijenga L H J. Pathobiology of germ cell tumors of the adult testis: views and news. Thesis, Erasmus Universiteit, Rotterdam 1994
19. Andrews P W, Gonczol E, Plotkin S A, Dignazio M, Oosterhuis J W: Differentiation of TERA-2 human embryonal carcinoma cells into neurons and HCMV permissive cells. Induction by agents other than retinoic acid. *Differentiation* 1986, 31: 119-126
20. Andrews P W, Damjanov I, Berends J, Kumpf S, Zappavigna V, Mavilio F, Sampath K: Inhibition of proliferation and induction of differentiation of pluripotent human embryonal carcinoma cells by osteogenic protein-1 (or bone morphogenetic protein-7). *Lab Invest* 1994, 71: 243-251
21. Stephens L E, Sonne J E, Fitzgerald M L, Damsky C H: Targeted deletion of $\beta 1$ integrins in F9 embryonal carcinoma cells affects morphological differentiation but not tissue-specific gene expression. *J Cell Biol* 1993, 123: 1607-1620
22. Nicolson G L: Tumor cell instability, diversification, and progression to the metastatic phenotype: from oncogene to oncofetal expression. *Cancer Res* 1987, 47: 1473-1487
23. Sutherland R M: Importance of critical metabolites and cellular interactions in the biology of microregions of tumors. *Cancer* 1986, 58: 1668-1680
24. Sutherland R M: Cell and environment interactions in tumor microregions: the multicell spheroid model. *Science* 1988, 240: 177-184
25. Andrews P A, Howell S B: Cellular pharmacology of cisplatin: perspectives on mechanisms of acquired resistance. *Cancer Cells (Cold Spring Harbor)* 1990, 2: 35-43
26. Kelly S L, Rozenzweig M: Resistance to platinum compounds: mechanisms and beyond. *Eur J Cancer Clin Oncol* 1989, 25: 1135-1140
27. Teicher B A, Herman T S, Holden S A, Wang Y, Pfeffer M R, Crawford J W, Frei E: Tumor resistance to alkylating agents conferred by mechanisms operative only in vivo. *Science* 1990, 247: 1457-1461
28. Kerbel R S, Kobayashi H, Graham C H: Intrinsic or acquired drug resistance and metastasis: Are they linked phenotypes. *J Cell Biochem* 1994, 56: 37-47

29. Timmer-Bosscha H. Cisplatin resistance: models, mechanisms, and modulation. Thesis, Rijksuniversiteit Groningen, Groningen 1995
30. Pleasure S J, Page C, Lee V M -Y: Pure, postmitotic, polarized human neurons derived from NTera 2 cells provide a system for expressing exogenous proteins in terminally differentiated neurons. *J Neurosci* 1992, 12: 1802-1815
31. Eisenhauer E A, Lippman S M, Kavanagh J J, Parades-Espinoza M, Arnold A, Hong W K, Massimini G, Schleuniger U, Bollag W, Holdener E E, Krakoff I: Combination 13-cis-retinoic acid and interferon 2 α in the therapy of solid tumors. *Leukemia* 1994, 8: 1622-1625
32. Bollag W: Experimental basis of cancer combination chemotherapy with retinoids, cytokines, 1,25-dihydroxyvitamin D₃, and analogs. *J Cell Biochem* 1994, 56: 427-435
33. Leoncini L, Pacenti L, Rusciano D, Burroni D, Garbisa S, Cintorino M, Terrana B: Correlation between differentiation and lung colonization by retinoic acid-treated F9 cells as revealed by the expression pattern of extracellular matrix and cell surface antigens. *Am J Pathol* 1988, 130: 505-514
34. Rusciano D, Lorenzoni P, Burger M M: The role of both specific cellular adhesion and growth promotion in liver colonization by F9 embryonal carcinoma cells. *Int J Cancer* 1991, 48: 450-456
35. Ross S A, Ahrens R A, De Luca L M: Retinoic acid enhances adhesiveness, laminin and integrin β 1 synthesis, and retinoic acid receptor expression in F9 teratocarcinoma cells. *J Cell Physiol* 1994, 159: 263-273
36. Pierce G B, Speers W C: Tumors as caricatures of the process of tissue renewal: prospects for therapy by directing differentiation. *Cancer Res* 1988, 48: 1996-2004
37. Sell S, Pierce G B: Maturation arrest of stem cell differentiation is a common pathway for the cellular origin of teratocarcinomas and epithelial cancers. *Lab Invest* 1994, 70: 6-22
38. Liotta L A, Steeg P S, Stetler-Stevenson W G: Cancer metastasis and angiogenesis: an imbalance of positive and negative regulation. *Cell* 1991, 64: 327-336
39. Herlyn M, Malkowicz S B: Regulatory pathways in tumor growth and invasion. *Lab Invest* 1991, 65: 262-271
40. Iozzo, R V: Tumor stroma as a regulator of neoplastic behavior. Agonistic and antagonistic elements embedded in the same connective tissue. *Lab Invest* 1995, 73: 157-160
41. van den Hooff A: Stromal involvement in malignant growth. *Adv Cancer Res* 1988, 50: 159-196
42. Fauve R M: Metastases. *Res Immunol* 1994, 145: 229-312
43. Mosselman S, Claesson-Welsh L, Kamphuis J S, van Zoelen E J J: Developmentally regulated expression of two novel platelet-derived growth factor α -receptor transcripts in human teratocarcinoma cells. *Cancer Res* 1994, 54: 220-225
44. Moasser M M, DeBlasio A, Dmitrovsky E: Response and resistance to retinoic acid are mediated through the retinoic acid nuclear receptor gamma in human teratocarcinomas. *Oncogene* 1994, 9: 833-840

45. Murty V S, Houldsworth J, Baldwin S, Reuter V, Hunziker W, Besmer P, Bosl G, Chaganti R S K: Allelic deletions in the long arm of chromosome 12 identify sites of candidate tumor suppressor genes in male germ cell tumors. *Proc Natl Acad Sci USA* 1992, 89: 11006-11010

46. Giguère V: Retinoic acid receptors and cellular retinoid binding proteins: complex interplay in retinoid signalling. *Endocrine Rev* 1994, 15: 61-79

Chapter 6

NEDERLANDSE SAMENVATTING

TESTICULAIRE KIEMCELTUMOREN

Kiemceltumoren van de zaadballen (testiculaire kiemceltumoren) zijn zeldzaam. Bij de man vormen zij 1-2% van alle kwaadaardige tumoren. Omgerekend betekent dit dat in een huisartsenpraktijk waarin 1500 mannen gemiddeld één testiculaire kiemceltumor per 30 jaar wordt gediagnostiseerd. Meestal wordt deze tumor aangetroffen bij mannen tussen de 15 en 45 jaar. Ondanks hun zeldzaamheid zijn testiculaire kiemceltumoren in deze leeftijdsgroep de meest voorkomende kwaadaardige tumor. Kiemceltumoren komen echter ook voor in de vrouwelijke geslachtsklier (eierstok) en op andere lokaties in het lichaam. Behalve in de mannelijke en vrouwelijke geslachtsklieren kunnen deze tumoren ontstaan in de regio van het staart- en heiligbeen, het achter het buikvlies, tegen en naast de wervelkolom gelegen weefsel, het centraal in de borstholte, tussen de longen gelegen weefsel, het hoofd-hals gebied en in de middellijn van de hersenen. Uit het bovenstaande blijkt dat deze tumoren een heterogene groep vormen. Geslacht, leeftijd, lokalisatie en microscopische anatomie van de weefsels waaruit de tumor is opgebouwd (histologie) zijn dan ook mede bepalend voor de wijze waarop de tumor zich manifesteert en reageert op therapie.

Testiculaire kiemceltumoren kunnen worden onderverdeeld in seminomen en nonseminomen. De seminomen zijn opgebouwd uit kwaadaardig ontaarde kiemcellen, die tijdens de vroege ontwikkeling van het embryo de voorloper cellen vormen van de in de zaadbuisjes aanwezige zaadcellen. De nonseminomen kunnen worden beschouwd als een karikatuur van de vroege ontwikkeling van het embryo aangezien zij zijn opgebouwd uit in meer of mindere mate uitgerijpte (gedifferentieerde) weefsels welke ontstaan uit de ongedifferentieerde embryonale carcinoom cel. Daaruit volgt dat naast het ongedifferentieerde embryonaal carcinoom in nonseminomen gedifferentieerde weefsels kunnen worden aangetroffen zoals teratoom, dooierzaktumor en choriocarcinoom. De in de zaadbuisjes aanwezige intratubulaire kiemcelmaligniteit wordt gezien als het niet-infiltrerende, tot de zaadbuisjes beperkte, voorloper stadium van zowel seminomen als nonseminomen. Dit voorloper stadium is evenals het seminoom opgebouwd uit kwaadaardig ontaarde kiemcellen. Door toename van genetische afwijkingen (tumor progressie) krijgen de tumor cellen waaruit de intratubulaire kiemcelmaligniteit is opgebouwd meer kwaadaardige kenmerken waardoor zij dan wel als seminoom dan wel als nonseminoom het omringende testis weefsel kunnen infiltreren.

De intrinsieke agressiviteit van de verschillende histologische subtypen waaruit een testiculaire kiemceltumor is opgebouwd bepaalt in grote mate het gedrag van deze tumoren. De therapie keuze (radiotherapie versus chemotherapie) is dan ook in de eerste plaats afhankelijk van de histologie van de primaire tumor (seminoom versus nonseminoom). Daarnaast wordt de therapie keuze bepaald door het klinische stadium (al dan niet aanwezig zijn van en de uitgebreidheid van uitzaaiingen ten tijde van het stellen van de diagnose testiculaire kiemceltumor) en het te verwachten biologisch stadium (het te verwachten klinisch stadium nadat ten tijde van het stellen van de diagnose testiculaire kiemceltumor, zeer kleine niet detecteerbare uitzaaiingen zichtbaar zijn geworden). Het biologisch stadium kan worden ingeschat aan de hand van klinische, pathologische, biologische en genetische parameters.

INTEGRINES EN EXTRACELLULAIRE MATRIX EIWITTEN IN TESTICULAIRE KIEMCELTUMOREN

De wijze waarop testiculaire kiemceltumoren ontstaan heeft de laatste jaren centraal gestaan in het wetenschappelijk onderzoek. Het is momenteel nog onduidelijk over welke eigenschappen tumor cellen moeten beschikken willen ze het testis weefsel kunnen infiltreren en vervolgens uitzaaien. Een van de factoren die wordt geacht van groot belang te zijn voor de agressiviteit van een kwaadaardige tumor is de directe omgeving (microomgeving) van de tumor cel. Deze microomgeving bepaalt (in combinatie met genetische factoren) het gedrag van een tumor. Extracellulaire matrix (ECM) eiwitten vormen een belangrijk onderdeel van de microomgeving. ECM eiwitten worden door cellen gemaakt en uitgescheiden. Door onderlinge interactie vormen zij een mechanisch netwerk waarin cellen zich "nestelen". Bovendien kunnen ECM eiwitten het gedrag van cellen direct beïnvloeden door binding aan op de celmembraan aanwezige integrines. Het ontstaan van kanker is in vele gevallen geassocieerd met een veranderde interactie van tumor cellen met de hun omgevende ECM eiwitten. Deze verandering is een gevolg van een veranderde expressie en/of functie van integrines en/of een veranderde samenstelling van de ECM die er toe bijdraagt dat de groei en infiltratie van tumor cellen vergemakkelijkt wordt. Bestudering van de expressie van integrines en distributie van ECM eiwitten in testiculaire kiemceltumoren zou informatie kunnen geven over een van de mechanismen die betrokken is bij de groei, differentiatie, infiltratie en uitzaaiing van deze tumoren. Bovendien zouden integrines en ECM eiwitten gebruikt kunnen worden als biologische parameters welke het gedrag van deze tumoren kunnen voorspellen.

In Hoofdstuk 2 staat de door integrines gemedieerde interactie van cellen met ECM eiwitten centraal. In Paragraaf 2.1.1 worden in het kort de ECM eiwitten en integrines geïntroduceerd. Dat de (non) integrine gemedieerde interactie van cellen met de ECM effecten heeft op de vorm, het gedrag en de functie van cellen wordt geïllustreerd in Paragraaf 2.1.2. Net als bij de ontwikkeling van andere organen lijken ECM eiwitten en integrines een essentiële rol te spelen bij de ontwikkeling van de zaadbal. Daarnaast blijkt dat een intacte basaal membraan (gespecialiseerde structuur die cellen van verschillende origine van elkaar scheidt en is opgebouwd uit ECM eiwitten) van groot belang is voor de vorm, gedrag en functie van de cellen waaruit de wand van zaadbuisjes (myoïde cellen en Sertoli cellen van elkaar gescheiden door een basaal membraan) is opgebouwd. Indirect betekent dit dat een intacte basaal membraan ook essentieel is voor het in stand houden van een normale spermatogenese. Bij een verstoring van de spermatogenese zoals kan worden gezien bij patiënten met een intratubulaire kiemcelmaligniteit kunnen dan ook afwijkingen aan de basaal membraan worden gezien. Momenteel is niet aan te geven of de veranderingen in de basaal membraan de oorzaak of het gevolg zijn van de verstoorde spermatogenese en/of het aanwezig zijn van kwaadaardige intratubulaire kiemcellen. Dat integrines en ECM eiwitten niet alleen van belang zijn voor de vorm, gedrag en functie van goedaardige cellen wordt geïllustreerd in Paragraaf 2.1.3. In Hoofdstuk 2.2 en 2.3 wordt de expressie van integrines en distributie van ECM eiwitten beschreven in testiculaire kiemceltumoren. Overeenkomend met de gegevens uit de literatuur blijkt het integrine expressie patroon van seminomen en nonseminomen (en de verschillende histologische subtypen waaruit het nonseminoom is opgebouwd) overeenkomsten te tonen met dat van hun goedaardige tegenhangers. Aangezien kwaadaardige tumoren kunnen worden beschouwd als karikaturen van normale weefselvernieuwing en de vroege

ontwikkeling van het embryo lijkt het redelijk te veronderstellen dat deze overeenkomsten in integrine expressie patroon van belang zijn voor het biologisch gedrag van testiculaire kiemceltumoren.

Interessant blijft de vraag op welke wijze differentiatie in testiculaire kiemceltumoren wordt gereguleerd. Op basis van verschillende studies lijkt er een prominente rol te zijn weggelegd voor genetische factoren aangezien de verschillende oncogenen en tumor suppressor genen (genen die een rol spelen bij de groei en differentiatie van normale weefsels) een (mogelijk tumor progressie gerelateerd) histologisch subtype specifieke expressie tonen. Daarnaast wordt verondersteld dat de differentiatie richting (seminoom, nonseminoom) in testiculaire kiemceltumoren ten dele wordt bepaald door "genomic imprinting" daar dit regulatie mechanisme bepaalt welk deel van het genetisch materiaal wordt afgelezen en uiteindelijk wordt omgezet in functionele eiwitten die een rol spelen bij de regulatie van groei en differentiatie. Tenslotte zouden vele factoren welke aanwezig zijn in de microomgeving van tumor cellen een bijdrage kunnen leveren aan differentiatie. De overeenkomsten in het integrine expressie patroon van de diverse histologische subtypen met hun normale tegenhanger suggereert dat integrine gemedieerde cel-ECM interacties betrokken zijn bij de differentiatie van deze tumoren. Het zal nader moeten worden onderzocht of integrines actief betrokken zijn bij het in gang zetten van differentiatie dan wel een reflectie zijn van het differentiatie proces op zich. Naast cel-ECM interacties kunnen andere (epigenetische) factoren welke eveneens in de microomgeving van de tumor cel aanwezig zijn een bijdrage leveren aan differentiatie. Selectie druk welke ontstaat door intratumorale variatie van deze epigenetische factoren, stofwisselings producten, zuurgraad (pH) en zuurstof verzadiging (oxygenatie) kan leiden tot heterogeniteit en verdergaande differentiatie. Concluderend, differentiatie in testiculaire kiemceltumoren lijkt bepaald te worden door de (tumor progressie gerelateerde) genetische samenstelling van de tumor en "genomic imprinting". Voor de ontwikkeling van de gedifferentieerde verschijningsvorm zijn wel bepaalde factoren nodig welke aanwezig zijn in de microomgeving. Het bovenstaande model verondersteld dat differentiatie in testiculaire kiemceltumoren onder invloed staat van regulatoire factoren welke aanwezig zijn in de microomgeving. Daarmee worden deze tumoren verondersteld gevoelig te zijn voor de differentiatie inducerende werking van stoffen zoals retinoïden.

INDUCTIE VAN DIFFERENTIATIE ALS ANTIKANKER THERAPIE IN TERATOCARCINOMEN

Ongevoeligheid voor chemotherapeutische stoffen is een groot probleem bij patiënten die behandeld worden voor een gemetastaseerde testiculaire kiemceltumor. Deze ongevoeligheid kan vanaf het begin van de behandeling aanwezig zijn (intrinsieke ongevoeligheid) of tijdens de behandeling optreden (geïnduceerde ongevoeligheid). Ofschoon testiculaire kiemceltumoren in essentie zeer gevoelig zijn voor chemotherapeutische stoffen leidt het ontstaan van ongevoeligheid er toe dat circa 20% van de patiënten met een uitgezaaide vorm van deze maligniteit niet geneest. Het is dan ook duidelijk dat voor patiënten met een slechte prognose nieuwe behandelingsstrategieën nodig zijn welke niet noodzakelijkerwijze gebaseerd dienen te zijn op vergroting van de cel dodende werking van chemotherapeutische stoffen. Inductie van terminale

differentiatie in ongevoelige tumor cellen zou een mogelijk alternatief kunnen zijn, temeer daar terminaal gedifferentieerde cellen zich gedragen als "goedaardige" niet-groeiende en niet-infiltrerende cellen. Van vele stoffen is bekend dat zij differentiatie kunnen induceren. Slechts enkele van deze stoffen worden in de kliniek toegepast. De meest bekende zijn wel het all-trans retinoic acid en het 13-cis retinoic acid. Beide stoffen behoren tot de familie der retinoïden welke zowel de natuurlijke als synthetische analoga van vitamine A omvatten.

In Hoofdstuk 3 worden de effecten besproken van een combinatie van de cel dodende stof cisplatine en de differentiatie inducerende stof all-trans retinoic acid. De effecten van cisplatine en all-trans retinoic acid werden onderzocht in drie muizen teratocarcinomen (tumoren samengesteld uit embryonaal carcinoom en teratoom) elk met een verschillend percentage gedifferentieerd weefsel: E86-379 (matig gedifferentieerd); NF-1 (slecht gedifferentieerd); MH-15 (niet gedifferentieerd). Behandeling met all-trans retinoic acid leidde alleen in muize teratocarcinomen met het vermogen tot spontane differentiatie (E86-379 en NF-1) tot een verhoging van het percentage gedifferentieerd weefsel welke niet gepaard ging met een verminderde gevoeligheid voor cisplatine.

Ofschoon muize teratocarcinomen gebruikt worden als model voor de bestudering van testiculaire nonseminomen, verschillen zij in een aantal opzichten van hun humane tegenhangers. Het is daarom gewenst resultaten welke in muize teratocarcinomen zijn verkregen bevestigd te zien in klinisch relevante humane modellen. In Hoofdstuk 4.1 wordt de ontwikkeling van een voor cisplatine ongevoelige sublijn (Tera-CP) van NTera/2D1 (Tera) beschreven. De ongevoelige cellijn Tera-CP liet een verlaagde binding van cisplatine aan het in de celkern aanwezige genetisch materiaal (DNA) zien die mogelijk het gevolg is van een verhoogd vermogen van de Tera-CP cellen om cisplatine onschadelijk te maken. De van getransplanteerde cellijnen afkomstige Tera en Tera-CP tumoren toonden in naakte muizen (muizen met een sterk verminderde afweer waardoor "vreemde" weefsels niet afgestoten worden en blijven groeien na transplantatie) een vergelijkbare gevoeligheid voor cisplatine als de oorspronkelijke cellijnen welke groeiden in kweekflacons.

Zowel in de gevoelige als ongevoelige cellijn werd noch een potentiërend noch een nadelig effect gezien van 13-cis retinoic acid op de door cisplatine geïnduceerde celdood (Hoofdstuk 4.2). Dit contrasteert met de effecten van all-trans retinoic acid in muize teratocarcinomen met het vermogen tot spontane differentiatie in welke een potentiërend effect van all-trans retinoic acid op cisplatine geïnduceerde celdood werd gezien (Hoofdstuk 3). De discrepantie tussen beide experimenten is niet te wijten aan het ontbreken van een door 13-cis retinoic acid geïnduceerd effect, aangezien Tera-CP tumoren welke alleen met dit retinoïd werden behandeld een tumor reductie van 20% werd gezien. In de Tera tumoren werd na behandeling met cisplatine een toegenomen percentage gedifferentieerd weefsel gezien. Deze toename in het percentage gedifferentieerd weefsel is vergelijkbaar met het ontstaan van een terminaal gedifferentieerde tumorrest (residuaal matuur teratoom) na chemotherapie bij patiënten met een uitgezaaide testiculaire kiemceltumor. De toegenomen differentiatie berust vermoedelijk op selectie van gedifferentieerde cellen welke intrinsiek ongevoelig zijn voor de cel dodende werking van cisplatine. Na behandeling met cisplatine werden in de Tera-CP tumoren niet alleen gedifferentieerde cellen aangetroffen maar ook ongedifferentieerde embryonale carcinoom cellen. Deze laatste cellen gaven vermoedelijk aanleiding tot hergroei van de tumor. Dus het lijkt erop dat ongevoeligheid voor cisplatine in tumoren

van Tera en Tera-CP gelijkenis toont met de intrinsieke (teratoom) en verworven (embryonaal carcinoom) ongevoeligheid welke wordt waargenomen bij patiënten die chemotherapeutisch behandeld worden. 13-cis retinoic acid leidde tot een verhoogd percentage gedifferentieerde cellen in residuale lesies van Tera-CP tumoren. Echter volledige differentiatie werd niet waargenomen. Aangezien in vitro terminaal gedifferentieerde zenuwcellen verkregen kunnen worden uit ongedifferentieerde embryonale carcinoom cellen zou men kunnen veronderstellen dat het gebruikte therapie schema inadequaat was. Ten einde de effecten van 13-cis retinoic acid en cisplatine te verbeteren zou men kunnen overwegen om deze gelijktijdig toe te dienen. Combinatie therapie van retinoïden met cytokines (kleine eiwitten die door binding aan cellen het gedrag van een cel kunnen beïnvloeden) en andere biologisch werkzame stoffen zou het differentiatie inducerend effect van retinoïden eveneens kunnen verhogen.

Vele genen staan direct of indirect onder invloed van retinoïden. Daaronder zijn ook genen die coderen voor eiwitten die betrokken zijn bij cel-matrix interacties. Zo is bekend dat de retinoïd geïnduceerde verandering in de expressie en functie van integrines kan leiden tot een verandering in het gedrag van cellen. In Hoofdstuk 4.3 wordt de in vitro expressie van integrines in Tera en Tera-CP besproken voor en na behandeling met all-trans retinoic acid. Op grond van de literatuur mag verondersteld worden dat integrines een belangrijk zijn voor de groei en differentiatie van Tera en Tera-CP. Het is bekend dat de expressie van integrines onder invloed van kweekomstandigheden aanmerkelijke veranderingen kan ondergaan. Het is daarom niet uit te sluiten dat het integrine expressie in Tera en Tera-CP ten dele geïnduceerd is door de (standaard) kweekomstandigheden. Daarnaast zou het integrine expressie patroon een intrinsieke eigenschap van Tera en Tera-CP kunnen zijn die gerelateerd is aan de mate van kwaadaardigheid en het nivo en de richting van differentiatie. Het percentage gedifferentieerde cellen is in Tera-CP tumoren lager dan in Tera, hetgeen een mogelijke verklaring zou kunnen zijn voor de snellere groei van Tera-CP tumoren. Ofschoon cel-ECM interacties betrokken zijn bij de regulatie van groei en differentiatie in zowel goedaardige als kwaadaardige cellen werden in het Tera/Tera-CP model geen verschillen gevonden in integrine expressie die een verklaring zouden kunnen geven voor de gevonden in vivo verschillen tussen beide cellijnen. De toegenomen differentiatie van beide cellen na transplantatie in naakte muizen (in de kweekflacon bestaan beide cellijnen voornamelijk uit embryonale carcinoom cellen) suggereert echter wel dat differentiatie in beide cellijnen in sterke mate afhankelijk is van de omgeving waarin de tumor cellen zich bevinden. Genetische verschillen tussen beide cellijnen kunnen de basis vormen voor verschillen in intracellulaire signaal transductie systemen waarvan de expressie bepaald wordt door de microomgeving waarin de embryonale carcinoom cel zich bevindt. Veranderingen in de expressie van integrines na toediening van all-trans retinoic acid suggereert dat in Tera en Tera-CP all-trans retinoic acid zijn werking, althans ten dele, uitoefent door modulatie van cel-matrix interacties. Toekomstige studies zullen moeten uitwijzen of in Tera en Tera-CP retinoïd geïnduceerde veranderingen in integrine expressie gerelateerd zijn aan modulatie van groei, infiltratie, en uitzaaiing van tumor cellen.

CONCLUSIES EN VOORUITBLIK

De microomgeving waarin tumor cellen zich bevinden wordt verondersteld van groot belang te zijn voor de verschijningsvorm van tumoren. Aangezien tumoren kunnen worden beschouwd als karikaturen van normale weefselvernieuwing en de vroege ontwikkeling van het embryo lijkt het redelijk te veronderstellen dat er overeenkomsten bestaan tussen tumor cellen en hun goedaardige tegenhangers. De overeenkomsten in het integrine expressie patroon tussen de verschillende weefsels in testiculaire kiemceltumoren en hun goedaardige tegenhangers suggereert dat integrine expressie in deze tumoren geassocieerd is met groei, differentiatie, infiltratie en het ontstaan van uitzaaiingen. Infiltratie en het ontstaan van uitzaaiingen zijn echter complexe gebeurtenissen welke onder invloed staan van meerdere regulatoire factoren. De disregulatie van deze in fysiologische omstandigheden werkzame factoren bepaalt de agressiviteit van kwaadaardige tumoren. Vanuit dit gezichtspunt kan het belang van integrines voor het biologisch gedrag van testiculaire kiemceltumoren alleen op juiste waarde geschat worden indien de relatie tussen integrine afhankelijke- en onafhankelijke signaal transductie systemen is opgelost. Een tumor maakt niet alleen passief gebruik van zijn microomgeving. Integendeel, tumor cellen induceren en conditioneren hun microomgeving in hoge mate zelf, hetgeen van groot belang is voor het gedrag van de tumor cel. Het heterogene distributie patroon van ECM eiwitten in de diverse histologische subtypen suggereert dat er een dynamische interactie bestaat tussen tumor cellen en hun omgeving. De mechanismen welke verantwoordelijk zijn voor deze heterogeniteit in ECM eiwit distributie dienen nader te worden onderzocht.

In vivo behandeling van muize en humane teratocarcinomen met retinoïden leidt tot een hoger percentage gedifferentieerd weefsel. Bovendien lijkt het zo te zijn dat retinoïden niet interfereren met de cel dodende activiteit van cisplatine. Verdere studies moeten uitwijzen of retinoïden ook in patiënten met een testiculaire kiemceltumor werkzaam zijn. Om de effecten van retinoïden op differentiatie te bestuderen moeten meer gevoelige (andere dan histologische) parameters gebruikt worden. Ook andere aspecten van retinoïden moeten echter worden bekeken, aangezien retinoïden meerdere effecten hebben op kwaadaardige tumoren, waaronder inductie van geprogrammeerde celdood (apoptosis). Tot slot, in humane embryonale carcinoom cellen wordt de respons van cellen op retinoïden gemedieerd door de retinoïc acid receptor gamma welke aanwezig is in de cel kern. Verlaagde expressie van deze receptor leidt er toe dat de tumor cel ongevoelig wordt voor de differentiatie inducerende activiteit van retinoïden. In testiculaire kiemceltumoren kan verlies optreden van de lange arm van chromosoom 12. Daar de retinoïc acid receptor gamma gelokaliseerd is op de lange arm van chromosoom 12 zou het mogelijk kunnen zijn dat tumoren met een (gedeeltelijk) verlies van de lange arm van chromosoom 12 ongevoelig zijn voor de activiteit van retinoïden. Daarom zou bepaling van retinoïc acid gamma receptor expressie er toe kunnen bij dragen om te bepalen welke patiënten daadwerkelijk baat hebben bij retinoïd geïnduceerde modulatie van het biologisch gedrag van testiculaire kiemceltumoren.

DANKWOORD

De afgelopen 5 jaar is de afdeling Pathologie van het Academisch Ziekenhuis Groningen (hoofd: Prof. Dr. J.D. Elema, huidig hoofd: Prof. Dr. S. Poppema) mijn werkplek geweest. Het onderzoek beschreven in dit proefschrift werd verricht binnen de werkgroep Oncologie (werkgroep leider: Dr. H. Hollema). Nu het "boekje" bijna klaar is, komen de gedachten tot rust en is er tijd om het een en ander te overdenken. Je beseft dat je de afgelopen weken (en maanden) in een wereld hebt geleefd waarin nauwelijks ruimte was voor anderen, één ding was belangrijk: de voltooiing van het proefschrift. Nu het zover is heerst er grote tevredenheid, maar is ook het besef aanwezig dat zonder hulp van anderen dit "boekje" niet tot stand zou zijn gekomen.

Allereerst wil ik mijn promotor Prof. Dr. W. Timens bedanken. Beste Wim, het is moeilijk om in een paar zinnen aan te geven wat je de laatste 5 jaar voor mij betekend hebt. Het feit dat je mij liet zwemmen, maar nooit uit het oog verloor, heb ik zeer gewaardeerd. Naar jouw idee en ook de mijne is dit inderdaad de beste manier waarop je tot ontplooiing komt. Je kennis en gedrevenheid zijn een grote bron van inspiratie geweest. Ik ben je echter nog het meest dankbaar voor het feit dat je ondanks je drukke werkzaamheden precies aanvoelde wanneer ik een duwtje in de rug nodig had en dan ook de tijd nam om me dat duwtje te geven.

Mijn tweede promotor Prof. Dr. N.H. Mulder dank ik voor de snelle en zorgvuldige wijze waarop hij mijn manuscripten van commentaar voorzag. De maandelijkse werkbesprekingen op uw kamer heb ik als zeer inspirerend ervaren. De vragen "wat heb je nu bereikt?" en "hoe ga je verder?" staan in mijn geheugen gegrift.

Prof. Dr. J. W. Oosterhuis heeft mij kennis laten maken met het wetenschappelijk onderzoek. Het vertrouwen dat u mij schonk waardeer ik zeer. Het verheugt mij dan ook dat het werk dat ik indertijd onder uw directe begeleiding heb verricht een plaats heeft gevonden in dit boekje.

Dr. E.G.E. de Vries. Beste Liesbeth, hartelijk dank je voor de enthousiaste en zorgvuldige wijze waarop je de manuscripten van commentaar voorzag. Hetgeen me echter het meest is bij gebleven is het etentje na afloop van het minisymposium. De persoonlijke dingen die we toen besproken hebben, en het begrip dat je toonde zijn van grote invloed geweest op mijn beslissing om te trachten het onderzoek op korte termijn af te ronden.

Zoals ook blijkt uit de namen van mijn promotores en referent berust het tot stand komen van dit proefschrift op een samenwerkingsverband tussen de afdelingen Pathologie en Medische Oncologie (Interne Geneeskunde) van het AZG en het Laboratorium Experimentele Patho-Oncologie van de Dr. Daniel den Hoed Kliniek. Tezamen met mijn inmiddels gepromoveerde onderzoeks-partner Dr. Hetty Timmer-Bosscha (Medische Oncologie) werd het praktisch werk dat beschreven wordt in de hoofdstukken 4.1, 4.2 en 4.3 verricht. Beste Hetty, onze samenwerking heb ik zeer plezierig gevonden. Het feit dat we een verschillende achtergrond hebben is geen handicap gebleken. Integendeel, ik heb er veel van geleerd.

Ook Dr. Coby Meijer van de afdeling Medische Oncologie moet ik bedanken. Beste Coby, de keren dat je voor Hetty en mij de honneurs op het Centraal Dieren Laboratorium (CDL) hebt waargenomen zijn talrijk. Ik ben je voor de vrije weekenden en vakanties zeer erkentelijk.

Anke Dam, Alie Krikken, Thea Rozeboom, Mieke Smith en Janneke Wiersema dank ik voor de analytische ondersteuning.

Ook André Alfenaar, Mark Coenen, Natali Jacobs, Froukje Kas, en Gonnie Meijer ben ik dank verschuldigd. Zij allen hebben meegewerkt aan het tot stand komen van delen van dit boekje.

De dierexperimenten werden verricht in de stal van de afdeling Pathologie en op het CDL. Zeker in het begin, als niet bioloog zijnde en niet gespeend van enige kennis, kon ik altijd met vragen bij Pieter Klok (Pathologie) en Wiebe Hofstra (CDL) terecht. Ik heb aan onze samenwerking prettige herinneringen overgehouden.

De foto's werden gemaakt door Hilbrand Wierenga en Siep Noorman. Hartelijk dank voor jullie vakwerk.

Dr J. Koudstaal, Dr. P.G.J. Nikkels (Hoofdstuk 2.1), Dr. D.Th. Sleijfer, Prof. Dr. H. Schraffordt Koops en Prof Dr. B.G. Szabo ben ik zeer erkentelijk voor het corrigeren van de manuscripten en hun actieve bijdrage betreffende de verkrijging en verwerking van (patienten) gegevens.

Prof. Dr. P. Herrlich, Prof. Dr. B. de Jong en Prof. Dr. G. Stoter, allen lid van de promotiecommissie, ben ik dankbaar voor het kritisch beoordelen van het manuscript. Prof. Herrlich, I'am honoured that you were willing to judge my Thesis. I look forward to your visit November 29th.

Aan mijn ex-kamergenoten Dr. Wilco Coers, Dr. Wim de Graaff en Dr. Henk-Jan Guchelaar bewaar ik goede herinneringen. De vele relevante en niet-relevante discussies hebben mijn denken als onderzoeker zeker beïnvloed.

Feike, Freek, Gerard, Leo, Nathalie, Nelly, (Dr.) Nynke en Vines, ik waardeer het zeer dat jullie mij de ruimte hebben gegeven om het proefschrift af te maken. Met name in de laatste fase zijn jullie van onschatbare waarde geweest. Wanneer het rode knopje weer eens brandde waren jullie altijd aanwezig om het alarm uit te schakelen.

Dr. Jan de Graaf en Siep Wouda dank ik voor hun bereidwilligheid om als paranimf op te treden. Beste Jan, ik ben inderdaad de volgende. Het feit dat we kamergenoten waren en onderzoek deden bij dezelfde "baas" heeft geleid tot een sterke band. Bedankt voor alles. Beste Siep, zoals je laatst al eens terecht opmerkte hebben we veel aan elkaar te danken. Ik heb prettige herinneringen overgehouden aan onze wetenschappelijke samenwerking. Ook aan de periode waarin we collega AGIO's waren bewaar ik goede herinneringen. Ik hoop je niet uit het oog te verliezen.

Mijn ouders hebben altijd in mij geloofd. Lieve papa, de avonden dat je mij aan de tafel zat te overhoren zijn niet voor niets geweest. Als je eens wist hoe dankbaar ik je daarvoor ben. Jullie motto "als je iets wilt dan kun je het ook" draag ik met me mee.

Lieve Jolanda, slechts degenen die het meegemaakt hebben weten wat voor opofferingen de partner van een promovendus zich moet getroosten. Je hebt het huishouden en mij draaiende gehouden. Altijd stond je klaar om mij op te vangen als het weer eens tegen zat. Blij was je als de zaken zich ten goede keerden. Zonder jou was er geen proefschrift geweest. Het feit dat ik jou en Anneleen door de promotie perikelen tekort heb gedaan kan ik niet meer terug draaien. Ik kan alleen zeggen, de toekomst is aan ons.