

University of Groningen

The organization of the central control of micturition in cats and humans

Blok, Bertil Feddo Maarten

IMPORTANT NOTE: You are advised to consult the publisher's version (publisher's PDF) if you wish to cite from it. Please check the document version below.

Document Version

Publisher's PDF, also known as Version of record

Publication date:

1998

[Link to publication in University of Groningen/UMCG research database](#)

Citation for published version (APA):

Blok, B. F. M. (1998). *The organization of the central control of micturition in cats and humans: anatomical and physiological investigations*. s.n.

Copyright

Other than for strictly personal use, it is not permitted to download or to forward/distribute the text or part of it without the consent of the author(s) and/or copyright holder(s), unless the work is under an open content license (like Creative Commons).

The publication may also be distributed here under the terms of Article 25fa of the Dutch Copyright Act, indicated by the "Taverne" license. More information can be found on the University of Groningen website: <https://www.rug.nl/library/open-access/self-archiving-pure/taverne-amendment>.

Take-down policy

If you believe that this document breaches copyright please contact us providing details, and we will remove access to the work immediately and investigate your claim.

Downloaded from the University of Groningen/UMCG research database (Pure): <http://www.rug.nl/research/portal>. For technical reasons the number of authors shown on this cover page is limited to 10 maximum.

Chapter 9

A PET Study on Cortical and Subcortical Control of Pelvic Floor Musculature in Women

Bertil F.M. Blok, Leontien M. Sturms, and Gert Holstege

J. Comp. Neurol. 389:535-544 (1997)

ABSTRACT

The pelvic floor musculature plays an important role in many behaviors, such as defecation, micturition, mating behavior, and vomiting. A recent positron emission tomography (PET) study revealed that structures belonging to the emotional motor system are involved in the control of the pelvic floor during micturition. However, there also exist brain structures involved in the voluntary motor control of the pelvic floor and the present PET study was designed to identify these structures.

Six adult female volunteers were scanned with the bolus injection of $H_2^{15}O$ during the following four conditions: (1) rest; (2) repetitive pelvic floor straining; (3) sustained pelvic floor straining; (4) sustained abdominal straining.

The results revealed that the superomedial precentral gyrus, the most medial portion of the motor cortex, is activated during pelvic floor contraction and the superolateral precentral gyrus during contraction of the abdominal musculature. In these conditions significant activations were also found in the cerebellum and thalamus. No activations were found in subcortical structures belonging to the emotional motor system.

INTRODUCTION

In humans the motor cortex is crucial in voluntary motor control, but other areas in the brain are involved in motor activities related to emotional behavior. These areas form the so-called emotional motor system (Holstege, 1997).

An example of a motor activity which is strongly influenced by the emotional motor system is micturition (Blok and Holstege, 1996). During micturition the coordination of the smooth detrusor muscle of the bladder and its external striated muscle sphincter does not take place in the sacral spinal cord or in the cerebral cortex but in the so-called pontine micturition center (PMC) in the pons (in the cat Barrington, 1925; De Groat, 1975; Holstege et al., 1986; in humans Blok et al., 1997). The PMC, in turn, is not under control of the motor cortex but of structures belonging to the emotional motor

system, such as the periaqueductal gray (in the cat Blok and Holstege, 1994; Blok et al., 1995; in humans Blok et al., 1997) and the dorsolateral part of the preoptic area of the hypothalamus (in the cat Holstege, 1987; in humans Blok et al., 1997). The striated muscle of the bladder sphincter is one of a group of muscles forming the pelvic floor. The pelvic floor not only takes part in micturition and defecation, but also in mating behavior, another component of the emotional motor system (Van der Horst and Holstege, 1995). However, the pelvic floor can also be activated voluntarily, for example during voluntary abdominal or pelvic straining "on command". In our search to the supraspinal organization of the pelvic floor in general, in a study using Positron Emission Tomography (PET) scanning, in human subjects the brain regions were identified that were activated

during voluntary contraction of the pelvic floor.

PET scanning is a non-invasive technique, which is used to identify sites of locally increased blood flow (Fox and Minton, 1989). The regional cerebral blood flow (rCBF) is used as an index for the presynaptic activity in the area under consideration during various physiological conditions (Jueptner and Weiller, 1995).

Since the pelvic floor is often used in combination with abdominal muscles, for example during abdominal straining, the volunteers were also asked to use their abdominal muscles in a separate condition. The results not demonstrate which brain areas are active during voluntary control of the pelvic floor, but also show the differences between these pelvic areas and regions involved in the voluntary control of the abdominal muscles.

MATERIALS AND METHODS

Subjects

The 6 volunteers were females between 21 and 24 years of age. They all completed a general health questionnaire. Volunteers, who reported a history of any neurologic, psychiatric or gastroenterologic illness, were excluded from the study. All subjects were right-handed, and gave their written informed consent, according to the declaration of Helsinki. The protocol of the study was approved by the research ethics committee of the University Hospital of Groningen. During each scan the lights were dimmed, the subjects had their eyes closed and they did not move. Each scanning session consisted of four measurements and lasted 1.5 hours in total.

Experimental protocol and training

Acquisition of scanning data was planned during the following 4 conditions:

Condition 1. Rest, no task was given,

Condition 2. Repetitive pelvic floor straining,

Condition 3. Sustained pelvic floor straining,

Condition 4. Sustained abdominal straining.

It is important to realize that for each volunteer an unbiased sequence of conditions was determined using a randomized number generator. Prior to a scanning session the volunteers were instructed about this sequence. Twenty three seconds before the beginning of scans 2, 3 and 4 the volunteers received a verbal command to start the task. Prior to the rest condition no assignment was given.

Before the scanning session, all the volunteers had practiced the tasks. For each volunteer this was done in two sessions: one session at the subjects' home under the guidance of one of the authors (L.M.S.), and another session prior to the scanning procedure at the PET center in Groningen. For the pelvic floor straining conditions, the volunteers were asked to contract their pelvic floor or their anal sphincter. For the abdominal straining condition the volunteers were asked to contract their abdominal muscles as if they would begin to defecate. They were explicitly asked to breath normally and not to move their legs, thighs, glutei muscles, and, during the pelvic floor conditions, their abdominal muscles. During the session at the subjects home the whole procedure was extensively explained and after the scanning session the volunteers reported that they had no problems to contract their anal sphincter. The muscle activity during rest, pelvic and abdominal straining was recorded continuously with bipolar surface electromyographic (EMG) electrodes. The left and right abdominal electrodes were placed 3 cm from the midline and 3 cm below the costal margin. The pelvic floor electrodes were placed 2 cm lateral from the anal orifice. The EMG signals were processed using an ambulatory differential voltage amplifier UPS 2020 (Medical Measure-

ment Systems, The Netherlands), bandwidth 10-1000 Hz. The signal was, after amplification, full-wave rectified and averaged.

PET scans

The subjects were placed in a horizontal position in the PET camera (Siemens-CTI 951/31, Knoxville, TN, USA) parallel to and 7 cm below the orbitomeatal line as determined by external examination. Because of the technical characteristics of the PET camera, the most caudal limit of the scanned area was the midbrain, and the most rostral limit included the total cerebral cortex. This resulted in images extending between -20 mm below and 76 mm above the intercommissural plane. This implied that the caudal cerebellum and brainstem regions as pons and medulla were not part of the investigated brain areas.

An individually constructed head mold was used to minimize head movement between sessions. First, a transmission scan of 20 minutes was made for attenuation correction of the emission scans. Subsequently, the four scans were carried out. Before each scan, the subjects were given 1.85 GBq of $H_2^{15}O$ diluted in saline. The $H_2^{15}O$ bolus was injected in the right brachial vein, followed by 40 ml saline from an automatic pump. Data acquisition continued during 90 seconds, and was initiated 23 seconds after the beginning of the injection, at which time the peak in radioactivity was assumed to reach the cerebral blood flow. To allow the radiation to reach background levels, there was a 15 minutes interval between the injections.

Data analysis

The data of each scan were summated and the resulting images were centered to prevent loss of information during sampling. Prior to the statistical procedure the data were sampled to a voxel size of 2.2 x 2.2 x

2.4 mm. The data were further analyzed using the Statistical Parametric Mapping procedure (SPM96 from the Wellcome Department of Cognitive Neurology, London, UK) implemented in Matlab (Mathworks Inc. Sherborn MA, USA) on a SPARC workstation (Sun Microsystems Inc., Surrey, UK). The SPM96 software was used for the anatomical realignment, normalization, smoothing and statistical analysis.

Anatomical realignment

The rCBF was reconstructed for each scan, using an attenuation correction based on the transmission scan. Movement-related components between scans were corrected during the realignment, using the first recorded scan of each subject as a reference.

Normalization

Following realignment all images were transformed into a stereotactic standard space (Talairach and Tournoux, 1988). This normalizing spatial transformation matches each scan to a reference or template image that conforms to the standard space (Friston et al., 1991a). Stereotactic normalization of PET images allows comparison of scan data in identical pixels across different subjects and scans.

Smoothing

Prior to the statistical analysis the scans were smoothed in order to increase signal to noise ratio and to suppress effects due to residual differences in functional and gyral anatomy between subjects during inter-subject averaging. During smoothing a Gaussian filter of 12 x 12 x 12 mm was used (full width, half maximum in the x, y and z axes, respectively).

Statistical analysis

Differences in global activity within and between subjects were removed by analysis of covariance on a pixel-by-pixel basis with global counts as covariate. This was

Table 1 Areas with Significant Increased rCBF

		x, y, z peak			Z-score
Repetitive pelvic floor straining - rest					
<i>Motor related areas</i>					
Superolateral precentral gyrus (4)	right	+30	-20	+66	2.9
Superomedial precentral gyrus (4)	midline	+2	-32	+66	3.1
Superomedial precentral gyrus (4)	midline	-6	-26	+74	3.3
Thalamus	left	-10	-4	+4	3.2
Cerebellum	midline	-6	-52	-12	3.9
<i>Other areas</i>					
Superior frontal gyrus (8)	right	+16	+30	+54	3.7
Medial frontal gyrus (mfg; 9)	right	+24	+16	+32	3.7
Temporal lobe (39)	right	+36	-52	+20	3.1
Ant. cingulate (32) & mfg (10)	right	+16	+50	+14	2.8
Sustained pelvic floor straining - rest					
<i>Motor related areas</i>					
Superolateral precentral gyrus (4)	right	+30	-20	+66	3.9
Superomedial precentral gyrus (4)	midline	+2	-26	+68	3.5
Thalamus	left	-10	0	+2	2.4
Cerebellum	midline	-6	-52	-12	3.7
<i>Other areas</i>					
Superior frontal gyrus (8)	right	+16	+24	+54	2.9
Medial frontal gyrus (9)	right	+24	+16	+32	3.6
Anterior cingulate (32) & mfg (10)	right	+14	+52	+12	3.4
Sustained abdominal straining - rest					
<i>Motor related areas</i>					
Superolateral precentral gyrus (4)	right	+30	-22	+66	5.1
Superolateral precentral gyrus (4)	left	-28	-24	+66	2.7
Superomedial precentral gyrus (4)	midline	0	-30	+62	3.2
Supplementary motor area (6)	right	+2	-4	+64	2.7
Cerebellum	midline	0	-42	-16	2.9
Thalamus	left	-12	+2	0	2.6
<i>Other areas</i>					
Superior frontal gyrus (8)	right	+16	+24	+54	3.7
Sust. abdom. straining - repetit. pelvic straining					
Superolateral precentral gyrus (4)	right	+30	-22	+66	3.4
Superolateral precentral gyrus (4)	left	-20	-24	+72	2.9
Medial & Superior frontal gyrus (6)	midline	4	10	+72	3.7

The location of the peak activations is indicated in millimeters by the coordinates x, y and z according to the atlas of Talarach and Tournoux (1988). Coordinates in standard stereotactic space: x is distance to right (+) or left (-) of the midsagittal line; y is distance anterior (+) or posterior (-) to vertical plane through the anterior commissure; z is the distance superior (+) or inferior (-) to the intercommissural (AC-PC) line. The Brodmann area is given (where appropriate) in parentheses. Significant activations include Z-scores of 3.0 ($P < 0.001$) or larger, trends in activation include Z-scores between 2.6 and 3.0.

done because inter- and intra-subject differences in global activity may obscure regional alterations in activity following cognitive processes (Friston et al., 1990). For each pixel in the stereotactic space the analysis of covariance (ANCOVA) generated a condition-specific adjusted mean rCBF value (normalized to 50 ml/dl/min) and an associated adjusted error variance. A repeated-measures ANCOVA was used for the comparison of the straining conditions with the rest condition, each subject being studied under all conditions. The ANCOVA allows comparison of the means across conditions using the t statistic. The resulting set of t values constitutes a statistical parametric map (SPM{t}) (Friston et al., 1991b). An uncorrected P-value of 0.001 ($Z=3.0$) was used. This (omnibus) approach can be used when the location of the area, in which activation is expected, is known (Friston et al., 1991b). Trends in activation are reported when they reach a significance level of $P<0.005$ ($Z=2.6$). This level of significance protects sufficiently against false positives (Warburton et al., 1996).

RESULTS

Subjects comments

Before the scanning the volunteers confirmed that they had an empty bladder and rectum. During scanning they were awake with their eyes closed and were in no discomfort. After the scanning session all volunteers were confident that the tasks were well performed.

EMG pattern of muscle contraction

The EMG records of the rectus abdominis and external anal sphincter muscles of one volunteer during the various tasks and scanning are shown in Fig. 1. EMG recorded from the abdominal musculature during rest showed respiratory activity. The strongest amplitude was observed during abdominal straining, but the signal

was also increased during sustained pelvic floor contraction. The abdominal EMG signal during repetitive pelvic straining differed only slightly from the abdominal EMG signal during rest. The EMG signal from the external anal sphincter was always increased during all three conditions (repetitive and sustained pelvic floor, and abdominal straining) in comparison to the rest condition.

Regional cerebral blood flow

Repetitive pelvic floor contraction versus rest condition

The strongest significant activation (uncorrected $P<0.001$) was found in the vermis of the cerebellum (Table 1; Figure 2). Significant focal activity was also found in the superomedial precentral gyrus, possibly representing activation in the primary motor cortex (M1), the superior frontal gyrus and left anterior thalamus. Trends in increased rCBF ($0.001<P<0.005$) were found in the right anterior cingulate gyrus and superolateral precentral gyrus.

Sustained pelvic floor contraction versus rest condition

The strongest significant activation (uncorrected $P<0.001$) was found in superolateral precentral gyrus and the vermis of the cerebellum (Table 1). Other significant activated areas were the superomedial precentral gyrus, superior frontal gyrus, and the right anterior cingulate gyrus. The rCBF increase in the left anterior thalamus was only slight ($0.005<P<0.01$; Table 1).

Sustained abdominal straining versus rest condition

The strongest significant increase in rCBF was found the right superolateral precentral gyrus (Figure 3). Furthermore, significantly increased rCBF was found in the superior frontal gyrus and frontal areas just rostral from the primary motor cortex. The latter areas possibly represent premotor

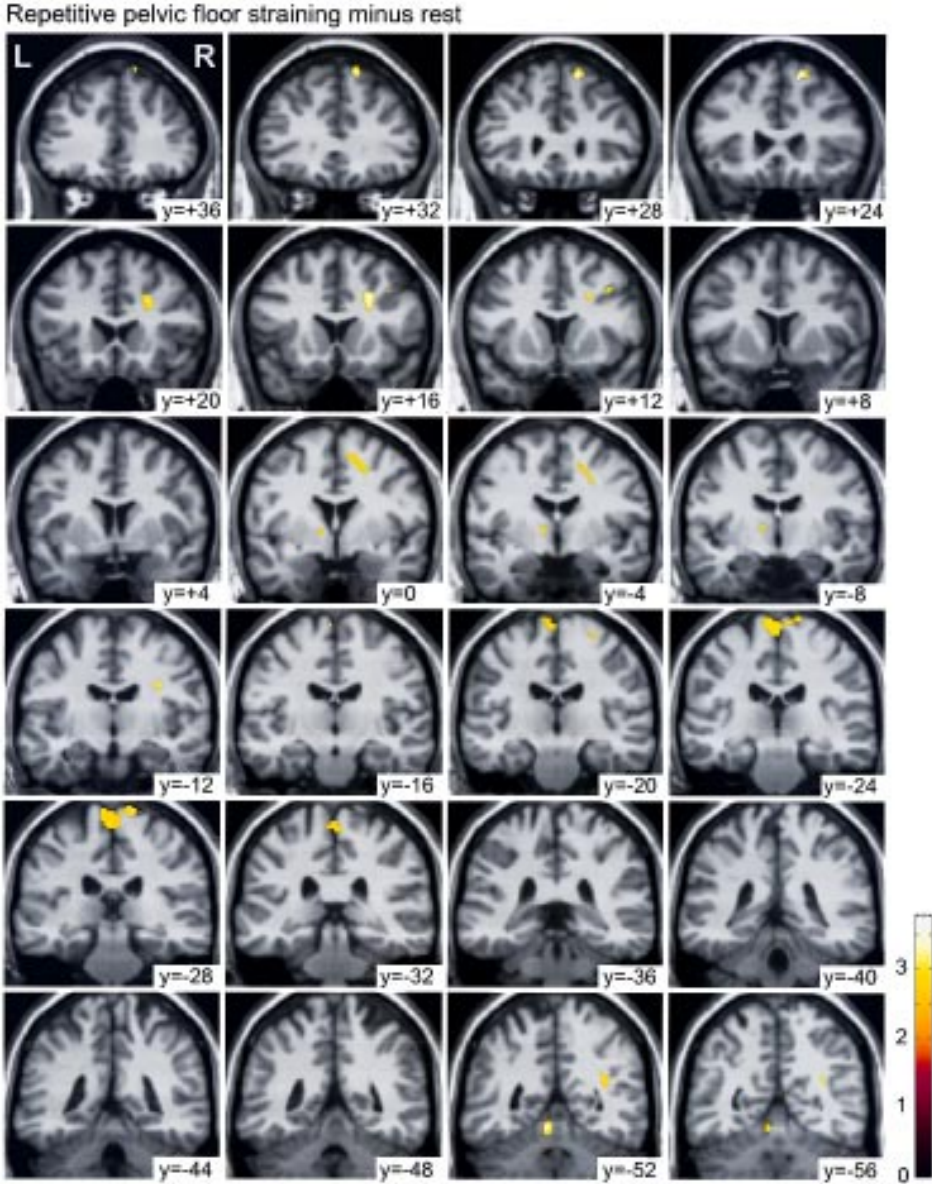


Fig. 1. Significant differences in regional cerebral blood flow (rCBF) for the comparison repetitive pelvic floor straining minus rest projected on coronal slices. Pixels are displayed at a threshold of an uncorrected $P < 0.005$. The numbers on the slices refer to the distance in millimeters relative to the vertical plane through the anterior commissure. The numbers on the colour scale refer to the corresponding Z-scores. Note the activations in the primary motor cortex in -20 to -32, the left thalamus in 0 to -8, and the cerebellum in -52 and -56.

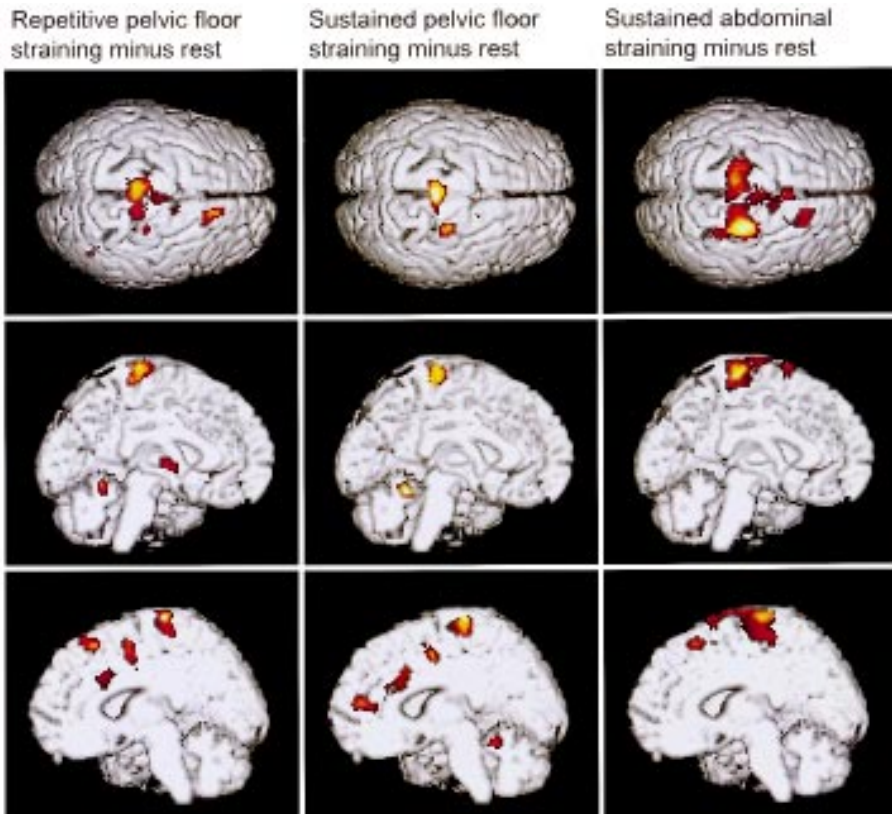


Fig. 2. Significant differences in regional cerebral blood flow (rCBF) for the comparisons between the 3 straining conditions and rest, projected on the superior surface of the brain (top), the medial surface of the left hemisphere (middle), and the medial surface of the right hemisphere (bottom). The shown differences include all activations located 5 mm in front of the shown surface of the brain, and 20 mm behind this surface.

and supplementary motor areas. Trends in increased rCBF ($0.001 < P < 0.005$) were observed in the left anterior thalamus and in the vermis of the cerebellum. No increase in rCBF was found in the anterior cingulate gyrus.

Abdominal straining versus pelvic floor straining

In order to find the exact location of the part of the primary motor cortex involved in abdominal muscle control a compari-

son was made between the conditions during abdominal straining and pelvic straining. The abdominal straining condition minus the pelvic floor straining revealed that a significant increase was found bilaterally in the right and left primary motor cortex (M1) 3 cm lateral to the midline (Figure 4).

studies have reported that the superolateral precentral gyrus is involved in the control of respiration (Colebatch et al., 1991; Ramsay et al., 1993).

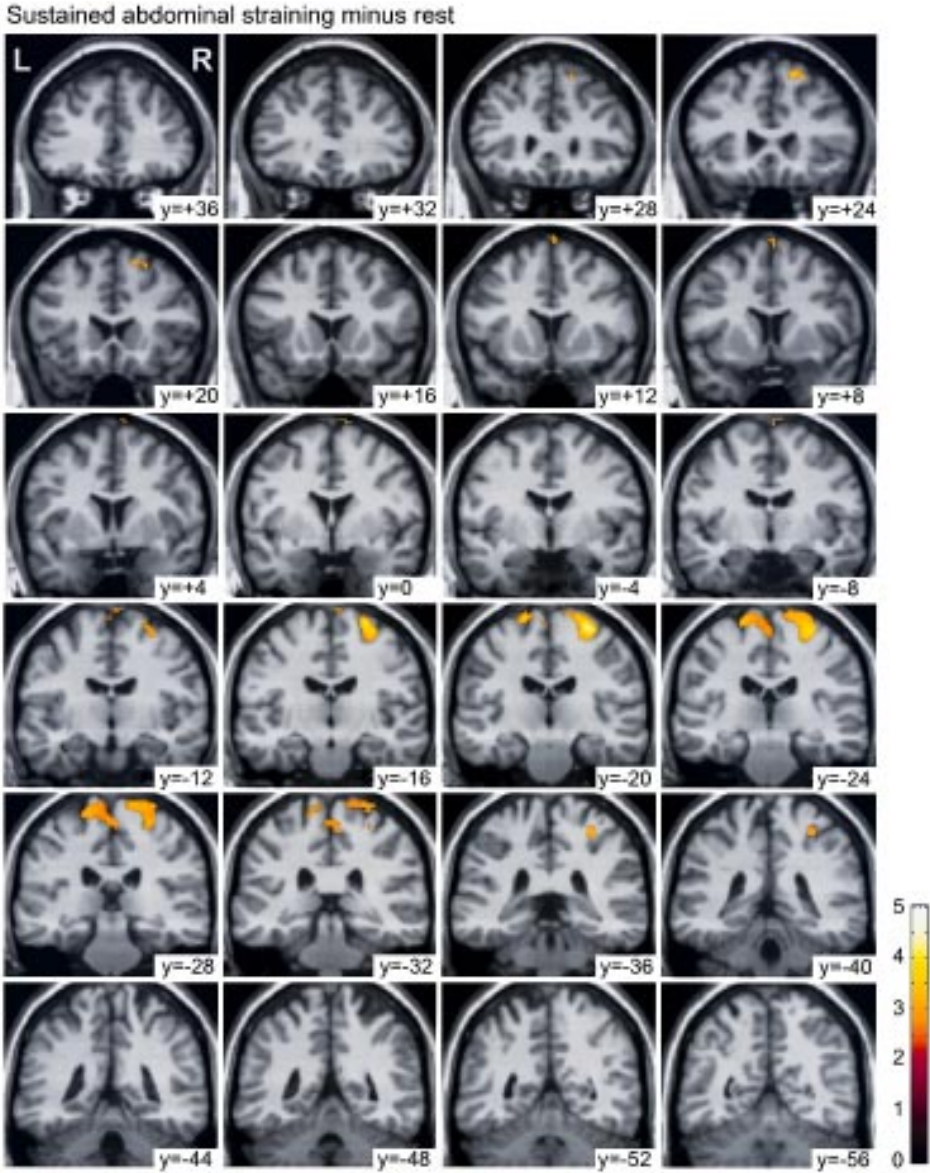


Fig. 3. Differences in rCBF for the comparison sustained abdominal straining minus rest projected on coronal slices. Note that the activations in the primary motor cortex in planes -12 to -32 extend much more laterally than in Figure 1.

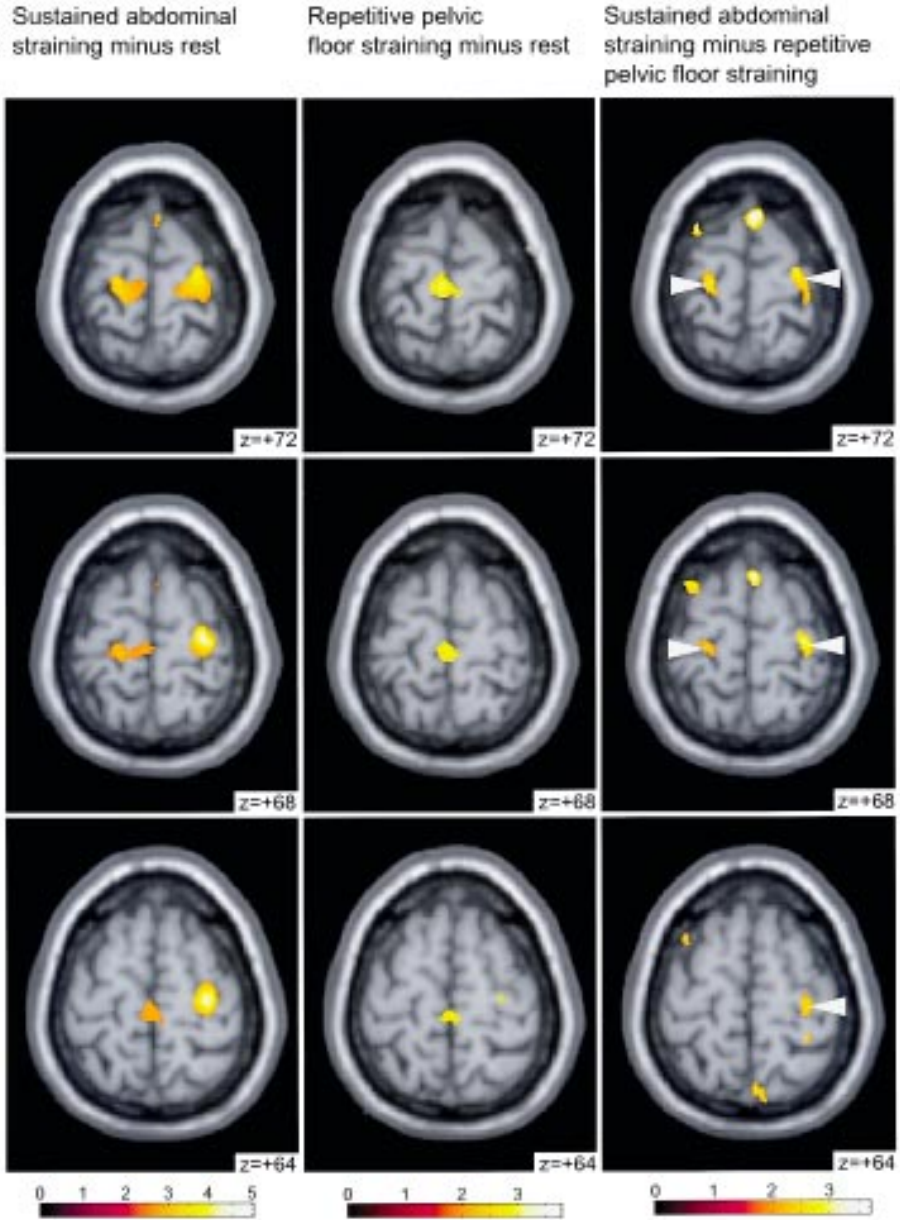


Fig. 4. Significant activations in the precentral gyrus for the comparisons sustained abdominal wall straining minus rest (left), repetitive pelvic floor straining minus rest (middle), and sustained abdominal wall straining minus repetitive pelvic floor (right) projected on horizontal slices. The arrows in the planes of the right column indicate the bilateral difference in the superolateral precentral gyrus, which is related to abdominal straining.

DISCUSSION

The pelvic floor consists of striatal muscles that play a role in voluntary as well as in autonomic motor activities. Examples of the latter are micturition and sexual behavior. In a previous PET-scan study (Blok et al., 1997) it was found that during micturition in human males the same brainstem regions were active as in cats. In that study, the voluntary control of the pelvic floor was not studied. It is possible, albeit difficult, to voluntarily interrupt micturition by contracting the pelvic floor. Also in other circumstances voluntary contraction of the pelvic floor is possible, for example during activities related to abdominal straining. The present PET-scan study investigated which brain areas are activated during voluntary contraction of the pelvic floor.

Technical aspects

Due to the technical limitations of the camera used in this study, it was necessary to pool data from different subjects and use stereotactic normalization of brain shape in order to detect significant increases resulting from the experiments. Inevitably, such normalization results in some loss of resolution of the specific sites of increased rCBF, but it was very well possible to identify significant local differences in rCBF.

Primary motor cortex activations

Abdominal motor area in the superolateral precentral gyrus

The present PET results found increased rCBF during abdominal straining bilaterally in the superolateral precentral gyrus about 3 cm lateral to the midline. Woolsey et al. (1979) localized their 'abdominal motor area' in the same region, 2 cm from the midline. According to Krause (1911) and Foerster (1936) is the abdominal muscle area located between the arm and leg areas of the primary motor cortex, and electrical stimulation in this area in lightly

or locally anesthetized humans evoked abdominal straining. Focal magnetic brain stimulation on the scalp over the same region elicited a strong response of the rectus abdominis (Carr et al., 1994). Other PET studies have reported that the superolateral precentral gyrus is involved in the control of respiration (Colebatch et al., 1991; Ramsay et al., 1993).

Pelvic floor motor area in the superomedial precentral gyrus

The present results point to this part of the primary motor, but the classical electrical stimulation studies on the localization of the human motor cortex failed to report a motor cortex area specifically related to the pelvic floor motor (Krause, 1911; Foerster, 1936; Penfield and Boldrey, 1937; Woolsey et al., 1979). The reason for this failure might be quite simple. The superomedial precentral gyrus in humans is located on the medial surface of the cortex, against which the sagittal sinus with its veins is located in the longitudinal fissure. This makes electrical stimulation in this medial cortical area rather difficult (Penfield and Boldrey, 1937). Another difficulty in determining the pelvic floor region of the human motor cortex is that the much larger leg motor area in this region seems to vary considerably among individuals (Penfield and Boldrey, 1937; Woolsey et al., 1979). On the other hand, animal experiments leave no doubt that a pelvic floor motor cortex exists. Focal electrical stimulation of the dog's medial sigmoid gyrus evoked contraction of the anal and bladder sphincters (Franck, 1887; Von Bechterew and Meyer, 1893). Stimulation of the upper part of the precentral gyrus of the monkey (Sherrington, 1892; Vogt and Vogt, 1907) and chimpanzee (Grünbaum and Sherrington, 1904) resulted in protrusion of the anal canal and closure of the anal sphincter.

Clinical studies on World War I injured

soldiers suggested that in humans a cortical pelvic floor motor area was located close to the 'hip motor area' between the arm and leg motor areas in the superior precentral gyrus. It would control the external sphincter muscle during conscious withholding of urine and interruption of micturition (Pfeifer, 1918). Bilateral destruction of this area was accompanied by urine retention due to a hyperreflexia of the pelvic floor musculature, causing inability of the bladder to relax. Usually this condition was combined with a bilateral spastic paralysis of the lower limbs, which combination is known as the paracentral lobule syndrome (Nathan, 1976). Non-invasive transcranial electrical stimulation of the primary motor cortex detected the optimal response of the external anal sphincter after stimulation in the midline of the skull (Merton, 1985; Ertekin et al., 1990). No rCBF differences during the muscle contraction tasks in comparison with the rest condition were observed in the area deeper in the medial motor cortex, i.e. just superior to the cingulate gyrus. This is important because this region has been implicated in the control of the bladder and rectum (Foerster, 1936).

Activations in other motor related areas

Significant activation during sustained and repetitive pelvic floor straining, and non significantly, during abdominal straining, was found in the thalamus and cerebellum. Given the resolution of the scanner, it was not possible unequivocally to determine which thalamic nuclei are activated, although the impression was gained that the peak activation was in the ventrolateral nucleus. In other PET studies these same regions in cerebellum and thalamus were found to be activated during motor related activities, as respiration (Colebatch et al., 1991; Ramsay et al., 1993), movements of the arm (Fox et al., 1985; Colebatch et

al., 1991; Grafton), and leg movements (Fink et al., 1995).

Especially during abdominal straining an area was activated rostral to the activated area in the superomedial precentral gyrus. It probably represents the part of Brodmann's area 6, that is called the supplementary motor area (SMA), or, more precisely, SMA proper. This region is thought to be involved in the execution of "simple" tasks (Picard and Strick, 1996), of which the straining tasks of the present study might be an example.

Activation in the right anterior cingulate gyrus

This area was significantly activated during repetitive and sustained pelvic floor straining, but not during abdominal straining. Usually, the pelvic floor is tonically contracted, and the individual is unaware of this. This might be the reason that voluntary contraction of the pelvic floor on the top of this tonical contraction is more difficult than voluntary contraction of the abdominal wall. The anterior cingulate gyrus has been implicated in many motor behaviors, but especially when it concerns a novel and difficult task (Jenkins et al., 1994). The anterior cingulate gyrus has also been implicated in attention to body parts (Pardo et al., 1991). An example is the bladder. Andrew and Nathan (1964) reported that lesions in the anterior cingulate gyrus and the adjacent superior prefrontal cortex can cause urge incontinence. According to our PET study (Blok et al., 1997) the same part of the anterior cingulate gyrus as indicated by Andrew and Nathan plays a role in micturition. The same study, however, indicated that the anterior cingulate gyrus is not specifically involved in micturition control, but in more general control mechanisms, like goal directed attention and alertness. Thus, urge incontinence due to lesions in the anterior cingulate gyrus is the result of a general

indifference of the patients, including indifference to a full bladder.

Voluntary and involuntary pelvic floor control and micturition

Although it can be concluded that the superomedial part of the precentral gyrus is involved in the control of the pelvic floor musculature, it should be emphasized that this cortical area is important for the **conscious** withholding of urine and subsequent suppression of the micturition reflex. This voluntary control mechanism is not involved in the control of micturition itself, because the micturition reflex is under involuntary control of structures belonging to the emotional motor system (Holstege, 1997). The previous PET study on micturition in human males has shown that the preoptic area of the hypothalamus and the periaqueductal gray (PAG) are activated during micturition (Blok et al., 1997). The same PET study demonstrated that another brain structure in the caudal brainstem, the so-called L-region or pontine storage center, is activated during involuntary and possibly also tonic con-

traction of the pelvic floor (Blok et al., 1997).

Motor cortex involvement in micturition control

Foerster (1936) reported that electrical stimulation of the pre- and postcentral gyrus just superior to the cingulate gyrus in humans resulted in an effect on the muscles of the bladder and rectum. One year later, Penfield and Boldrey (1937) found that electrical stimulation in the postcentral gyrus close to the cingulate gyrus evoked sensations of the genitalia, rectum, and buttock, but they could not evoke bladder or rectal contractions after stimulation in the corresponding precentral motor area. It seems that the cortical area close to the cingulate gyrus is primarily concerned with sensory information of the pelvic organs. This might explain why lesions in this area can result in urge incontinence (Kleist, 1918; Adler, 1919), since patients are not aware of a filled bladder or rectum. However, the micturition reflex itself is still intact in these patients.