

University of Groningen

## Idiopathic cord herniation (letter)

Groen, R.J.; Middel, B.

*Published in:*  
Journal of Neurosurgery: Spine

**IMPORTANT NOTE: You are advised to consult the publisher's version (publisher's PDF) if you wish to cite from it. Please check the document version below.**

*Document Version*  
Publisher's PDF, also known as Version of record

*Publication date:*  
2010

[Link to publication in University of Groningen/UMCG research database](#)

*Citation for published version (APA):*  
Groen, R. J., & Middel, B. (2010). Idiopathic cord herniation (letter). *Journal of Neurosurgery: Spine*, 12(5), 714-716.

### Copyright

Other than for strictly personal use, it is not permitted to download or to forward/distribute the text or part of it without the consent of the author(s) and/or copyright holder(s), unless the work is under an open content license (like Creative Commons).

The publication may also be distributed here under the terms of Article 25fa of the Dutch Copyright Act, indicated by the "Taverne" license. More information can be found on the University of Groningen website: <https://www.rug.nl/library/open-access/self-archiving-pure/taverne-amendment>.

### Take-down policy

If you believe that this document breaches copyright please contact us providing details, and we will remove access to the work immediately and investigate your claim.

*Downloaded from the University of Groningen/UMCG research database (Pure): <http://www.rug.nl/research/portal>. For technical reasons the number of authors shown on this cover page is limited to 10 maximum.*

### Idiopathic cord herniation

TO THE EDITOR: With interest we read the recently published study by Imagama et al. (Imagama S, Matsuyama Y, Sakai Y, et al: Image classification of idiopathic spinal cord herniation based on symptom severity and surgical outcome: a multicenter study. *J Neurosurg Spine* 11:310–319, 2009), in which they provide “the first evidence for image classification of idiopathic spinal cord herniation (ISCH)” based on their experience in 12 cases, collected retrospectively from the databases of 7 orthopedic institutes. The severity of cord herniation and cord displacement (based on MR images and/or CT myelography) in the sagittal plane was classified as: a kink type (Type K), when showing an obvious spinal kink toward the ventral region; a discontinuous type (Type D), if the spinal cord completely disappears at a herniated site; and a protrusion type (Type P), in which the subarachnoid space of the anterior spinal cord disappears with almost no kink in the posterior spinal cord. On axial images, the location of cord herniation was classified into either central (Type C) or lateral (Type L). Classification of laterality of the herniated spinal cord is based on correspondence (same side as: Type S) or noncorrespondence (opposite side as: Type O) with the hiatus location. In addition, the presence (+) or absence (–) of a bone defect in the vertebral body was scored. This all resulted in a 4-point-construct-score, which represents the image classification for each individual patient. With this classification, the authors started to analyze statistically a number of patient characteristics, preoperative neurological data, and postoperative outcome scores. Dr. Imagama et al. concluded that “Patients with Type P herniation had a good postoperative recovery, and those with a Type C location had significant severe preoperative lower-extremity paralysis and a significant poor postoperative recovery. Patients with a bone defect had a significantly severe preoperative myelopathy, but showed no difference in postoperative recovery.” The authors stated that, “... the results show that a Type C classification and a bone defect have strong relationships with severity of symptoms and surgical outcome and are important imaging and clinical features for ISCH. These findings may allow surgeons to determine the severity of preoperative symptoms and the probable surgical outcome from imaging.”

The authors described a rare and, most probably, underdiagnosed disorder. Therefore, clinical experience is limited, and as a result, treatment strategies are based on individual cases and on small series reported in the literature. We wish to commend Dr. Imagama and colleagues on their attempt to correlate preoperative imaging findings with both the severity of the neurological

deficit and postoperative results. However, we feel that a number of limitations in this article warrant further scrutiny and comment.

First, the authors use the abbreviation ISCH (idiopathic spinal cord herniation). However, this denomination seems inaccurate, as the patients the authors report on all meet the criteria of the so-called anterior thoracic spinal cord herniation (ATSCH). In the literature, different terminology is used for the same entity (idiopathic spinal cord herniation, thoracic idiopathic spinal cord herniation, spontaneous spinal cord herniation, spontaneous thoracic spinal cord herniation). Because the cause of cord herniation remains unknown (despite many speculations concerning the etiology), in our opinion, it is more appropriate to use the term ATSCH since this term comprises the radiological features that all these cases have in common (that is, the anterior herniation of the thoracic spinal cord through a ventral dural defect).<sup>5</sup> Second, the image classification designed by the authors is interesting, but the rationale for such a complex classification, composed of 4 different variables, remains obscure to the readership. For the differentiation of the severity of cord herniation and cord displacement in the sagittal plane, the authors distinguish 3 types and employed the following order of severity: 1) Type K (kink), 2) Type D (discontinuous), and 3) Type P (protrusion). In our opinion, it seems more plausible to start this ordinal scale with: 1) Type P (which seems to be similar to the “forme fruste” of ATSCH), followed by 2) kinking of the spinal cord (Type K), and finally ending with 3) complete herniation/protrusion of the spinal cord (Type D). This is in line with a publication by Ewald and Hasler<sup>3</sup> who reported on the evolution of the MR imaging findings in a patient with progressive thoracic myelopathy 6 months, 18 months, and 24 months after onset of the symptoms; finally this patient underwent surgery and ATSCH was confirmed.<sup>3</sup> From a recent review of the literature, we know that the diagnosis of ATSCH is likely to be long delayed, with an average of 5 years from the onset of symptoms.<sup>5</sup> Magnetic resonance imaging abnormalities, in the early stage of the disorder, may be very subtle, showing only slight anterior displacement of the thoracic spinal cord, compatible with the Imagama Type P. Consequently, one may assume that this type of herniation is associated with a mild neurological deficit compared with a more profound cord herniation seen on Type K and Type D images. Unfortunately such a clear theoretical basis for the design of the image classification is missing in their paper.

Third, the authors have not developed a standardized scoring protocol, and apparently both MR imaging and CT myelography can be used, both simultaneously or (in the absence of one of the imaging modalities) separately.

Interrater reliability (do the blinded observers measure what they purport to measure?) was not tested, which makes this classification system invalid.

Recently, we reported the results of an individual patient data (IPD) meta-analysis using data derived from 126 case reports with ATSCH.<sup>5</sup> After statistical analysis of the data, it appeared that Brown-Séquard syndrome is a strong independent factor associated with postoperative motor function improvement ( $p = 0.033$ ). Also, operative results after cord release and subsequent widening of the dural defect were significantly better than those in patients who received an anterior dural patch to cover the dural defect after cord release ( $p = 0.036$ ). At the time of manuscript preparation, we did not analyze imaging findings. As a result, associations between imaging characteristics and preoperative neurological deficit or postoperative results were not calculated. To test the image classification system described by Imagama et al., for the purpose of this letter, we have used the data of our IPD meta-analysis,<sup>5</sup> supplemented with 29 new cases recently reported by Akaza et al.,<sup>1</sup> Ghostine et al.,<sup>4</sup> Hassler et al.<sup>6</sup> (it appeared to us that Case 1 and Case 3 have been published before by one of the authors in 2001 [see Ewald and Hassler<sup>3</sup>] and were already included in our IPD meta-analysis), Ishida et al.,<sup>7</sup> Sai Kiran et al.,<sup>8</sup> Uhl et al.,<sup>11</sup> Olivieri et al.,<sup>12</sup> Chaichana et al.,<sup>2</sup> Imagama et al.,<sup>9</sup> Sasani et al.,<sup>9</sup> and Selviaridis et al.<sup>10</sup> For the classification of the severity of herniation and cord displacement, we employed the method of Imagama et al. on sagittal images (Types P, K, and D). In this updated series (now comprising a total of 158 reported cases) no statistically significant associations were found between the severity of herniation/cord displacement as classified by Imagama et al. and preoperative neurological deficits (Brown-Séquard syndrome, paraparesis, sensory deficit, and pain). However, for sensory deficit and pain, these analyses showed a violation of statistical assumptions by empty table cells and frequencies less than 5. To check whether the results were affected by this violation, only the cases with Brown-Séquard syndrome and the cases with paraparesis were used (Table 1). This association also appeared to be not statistically significant ( $p = 0.17$ ).

The proportions of cases with Brown-Séquard syndrome and paraparesis among individuals in whom no imaging was available did not differ from those classified as Type P, Type K, or Type D (difference of proportions test). Controlling for widening of the dural defect (WDD), Brown-Séquard syndrome and paraparesis remained statistically nonsignificant associated with the extent of herniation ( $p > 0.05$ , chi-square). Also we made an attempt to compare imaging type with postoperative results, taking into account only a selected subgroup of cases in which surgery involved a spinal cord release together with widening of the dural defect (all cases in this subgroup were operated in the same way [cord release and WDD] as the patients described by Imagama et al.). There were no statistically significant associations between WDD and Type P ( $p = 0.09$ , Fisher exact test), Type K ( $p = 0.06$ , Fisher exact test), and Type D ( $p = 0.22$ , Fisher exact test) cord herniation.

We are aware that our present analysis also has a

**TABLE 1: Differences in prevalence of Brown-Séquard syndrome and paraparesis, stratified by types of severity of herniation/cord displacement on sagittal images, as classified by Imagama et al.\***

| Neurological Deficit   | Imaging Findings (%) |           |           |           | Total |
|------------------------|----------------------|-----------|-----------|-----------|-------|
|                        | Type D               | Type K    | Type P    | Unknown   |       |
| Brown-Séquard syndrome | 15 (68.2)            | 30 (66.7) | 46 (74.2) | 10 (47.6) | 101   |
| paraparesis            | 7 (31.8)             | 15 (33.3) | 16 (25.8) | 11 (52.4) | 49    |
| total                  | 22 (100)             | 45 (100)  | 62 (100)  | 21 (100)  | 150   |

\*  $\chi^2 = 5.05$ ;  $df = 3$ ;  $p = 0.17$ . Type D = discontinuous-type cord herniation; Type K = kinking-type cord herniation; Type P = protrusion-type cord herniation.

number of limitations: 1) data used from publications may have induced information bias because only 1 or 2 images selected by the authors of a particular case report were available; 2) in such cases standardized scoring is not possible; and 3) discrimination between Type K and Type D sometimes is difficult. Nevertheless, the number of cases collected (158 overall) allows for a bivariate analysis to test the hypothesized association between preoperative imaging findings and neurological deficit, and we calculated that such an analysis has sufficient statistical power. This does not apply for the series reported by Imagama et al., which is too small to allow for any statistical analysis at all. Imagama and colleagues have brought up an interesting issue, by focusing the readership on the characteristics of imaging studies in ATSCH. However, as we have shown above, and in contrast to what is stated in their abstract, there is no statistically significant association between imaging characteristics and neurological deficit or operative results.

Clinical experience with ATSCH within a single institution is very limited. Currently, treatment strategies are based on individual cases and on reports in the literature, or they result from ad hoc decisions made during operative exploration of preoperatively unrecognized cases. Standardization of case reports would allow for better comparison of individual cases. Clinicians should be encouraged to report new cases and to describe all the details that are discussed in the recent reviews. Only this will help to better understand the pathophysiology, and the pre- and postoperative findings, and to identify factors that determine outcomes of this rare and very intriguing disorder.

ROB J. M. GROEN, M.D., PH.D.

BERRIE MIDDEL, PH.D.

University Medical Center Groningen  
University of Groningen  
Groningen, The Netherlands

#### References

1. Akaza M, Tsunemi T, Hotate M, Toru S, Mizusawa H: Spinal cord herniation which manifested stepwise deterioration. *Intern Med* 46:537-538, 2007
2. Chaichana KL, Sciubba DM, Li KW, Gokaslan ZL: Surgical

- management of thoracic spinal cord herniation: technical consideration. **J Spinal Disord Tech** 22:67–72, 2009
3. Ewald C, Hassler WE: [Spontaneous herniation of the thoracic spinal cord as the etiology of progressive Brown-Sequard syndrome. A description of 3 cases.] **Nervenarzt** 72:441–444, 2001 (Ger)
  4. Ghostine S, Baron EM, Perri B, Jacobson P, Morsette D, Hsu FP: Thoracic cord herniation through a dural defect: description of a case and review of the literature. **Surg Neurol** 71:362–367, 2009
  5. Groen RJ, Middel B, Meilof JF, de Vos-van de Biezenbos JB, Enting RH, Coppes MH, et al: Operative treatment of anterior thoracic spinal cord herniation: three new cases and an individual patient data meta-analysis of 126 case reports. **Neurosurgery** 64 (3 Suppl):145–160, 2009
  6. Hassler W, Al-Kahlout E, Schick U: Spontaneous herniation of the spinal cord: operative technique and follow-up in 10 cases. **J Neurosurg Spine** 9:438–443, 2008
  7. Ishida M, Maeda M, Kasai Y, Uchida A, Takeda K: Idiopathic spinal cord herniation through the inner layer of duplicated anterior dura: evaluation with high-resolution 3D MRI. **J Clin Neurosci** 15:933–937, 2008
  8. Sai Kiran NA, Vaishya S, Kasliwal MK, Kale SS, Sharma BS: Spontaneous thoracic spinal cord herniation presenting as tethered cord syndrome. **Neurol India** 57:221–222, 2009
  9. Sasani M, Ozer AF, Vural M, Sarioglu AC: Idiopathic spinal cord herniation: case report and review of the literature. **J Spinal Cord Med** 32:86–94, 2009
  10. Selviaridis P, Balogiannis I, Foroglou N, Hatzisotiriou A, Patsalas I: Spontaneous spinal cord herniation: recurrence after 10 years. **Spine J** 9:e17–e19, 2009
  11. Uhl E, Holtmannspötter M, Tonn JC: Improvement of Brown-Sequard syndrome after surgical repair of an idiopathic thoracic spinal cord herniation. **J Neurol** 255:125–126, 2008
  12. Ulivieri S, Olivieri G, Petrini C, D'Elia F, Cuneo GL, Cerese A: Thoracic spinal cord herniation: case report and technical note. **Neurol Neurochir Pol** 43:86–89, 2009

RESPONSE: I appreciate the interest in our article expressed Drs. Groen and Middel in their letter. I also read the published meta-analysis by Groen and colleagues,<sup>1</sup> which was a nice piece of work and represents a great effort on their part. I was disappointed, however, that in their letter they did not appear to understand our image classification for ISCH. I would therefore like the opportunity to describe this further.

#### *Sagittal Image Classification*

Regarding our sagittal image classification, it would be impossible to evaluate this classification based on only 1 or 2 formerly reported cases. First, I would like to discuss Groen and Middel's evaluation of the sagittal images in Table 1 because this is the most important point of contention in their letter. I wonder why they referred only to our sagittal image classification, even though we evaluated both sagittal and axial images, which were then subcategorized into 3 groups for further assessment in our paper. They reviewed more than 150 cases from former case reports, but the reported cases had only sagittal images. Thus, they could not confirm or classify images from the other 3 categories.

Although they deemed our classification as “complex” or “obscure,” we attempted to simplify the classification as much as possible from the outset. When we

initiated this study, we first attempted to classify the sagittal images by subcategorizing them into Groups P, K, and D. Because the sagittal images enabled us to easily observe the status of spinal cord herniation, and many case reports had adopted sagittal images, we attempted to classify these based on the sagittal images, a process described as “classified according to the severity of hernia and displacement (Fig. 1)” in the *Methods* section of our paper. However, because the condition of spinal cord herniation varied in practice, it was found that such a simple classification method based only on sagittal images was meaningless and could clarify nothing, as described in the *Discussion* of our paper.

As mentioned in our paper, axial image classification was a better indication of preoperative symptoms and surgical outcomes. Axial images could provide rich information because spinal disorders, which are judged by the position of the hiatus, the location of the protruded spinal cord and degree of spinal cord displacement, and the presence or absence of the spinal cord herniation into a bone defect, are of great importance. Thus, classification of sagittal images alone may be simple but inadequate to properly account for spinal cord herniation. However, because the analysis reported by Groen and colleagues<sup>1</sup> only used sagittal images, axial images have rarely been studied to date. Thus, reviewing only previously conducted studies did not provide sufficient data to assess our axial image classification. However, we still included the sagittal image classification because sagittal images have some advantages in terms of spinal cord herniations. Thus, a larger amount of information, including both axial and sagittal images, is needed to properly classify images of spinal cord herniation.

As Groen and colleagues mentioned in the “Limitation” in their review,<sup>1</sup> the weakest point of their claim is that while they investigated sagittal images obtained in more than 150 patients, they could never evaluate *all* the images: in reviewing the case reports, in general, one slice was selected in most cases, which was the best for diagnosing hernia but would never be suitable for classifying images, as the authors would not have been aware of any such image classification. Thus, it was necessary to conduct the image classification in Table 7 of our paper based on only a limited number of reports that were usable for image classification. To be precise, in Table 1 of Groen and colleagues' report, many of the Type P cases could actually be considered to be Type K (Fig. 1 in this response), and the Type D and the Type K cases were barely distinguishable. True Type P herniations should exhibit little kinking of the spinal cord and the symptoms must be mild. Therefore, the presence of a great number of Type P cases in their Table 1 further indicates the ambiguity of their evaluation of sagittal images. On the other hand, we have evaluated all of the sagittal and axial images for every slice of MR imaging and CT myelography studies obtained in 12 cases, which is the largest number of patients to date and required time to ascertain the condition of spinal cord herniation. Therefore, I can say that the sagittal image classification in their Table 1 is not at all reliable for the evaluation.

Considering that Groen and colleagues discussed

their opinions in the *Results* of their case review, I am afraid that they classified the images of spinal cord herniation without consideration. Simply reviewing the classification of our sagittal images alone, which is only one of 4 classification categories, and collecting only 1 image from each case, one cannot conclude that our classification scheme is meaningless. Based on my experience of detailed evaluation of the images, I emphasize again that axial images are essential for evaluating symptoms, treatment regimens, and surgical outcomes. Because a spinal cord herniation exhibits only a slight alteration, many lesions could have gone undetected. Although there is no consistent consensus at present as to whether sagittal images are important, this issue will eventually be determined when we are able to conduct a study that enables detailed evaluation of sagittal images.

At this time, I sincerely thank Groen and Middel for raising this issue and providing me with the opportunity to explain this further, as it was not possible to fully discuss the issue due to the space constraints of a normal journal publication.

The following is my detailed response to their critiques of our paper.

*The Terminology of This Entity*

Regarding the terminology of this entity, I agree that there is confusion in the descriptions used in the literature. However, the thoracic spinal cord was never herniated in the posterior direction, but rather in the anterior direction. Therefore, I do not believe that we need to describe herniations all as “anterior.” The possible origins of spinal cord herniation include congenital anomaly, slight trauma,

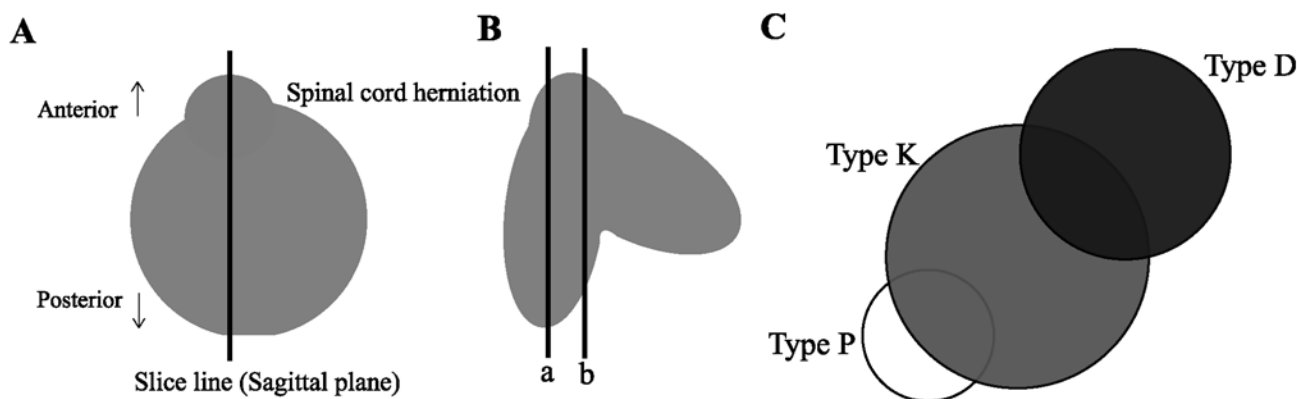
and so on. Therefore, “idiopathic spinal cord herniation” might more appropriately capture this entity. If the classification in the axial plane becomes useful, a better way to describe this clinical condition and surgical outcome might be the following: “Idiopathic (thoracic) spinal cord herniation: anterior (or central) type” or “Idiopathic (thoracic) spinal cord herniation: anterolateral type.”

*Our Classification is Composed of 4 Different Variables*

I agree with the notion that a simple classification is easy to understand and utilize. However, in order to account for the pathological condition of spinal cord herniation, the 4 variables we used are indispensable. I believe that the axial images are more important than the others. Examining sagittal images alone is meaningless when evaluating the laterality of motor paralysis of the lower extremities and determining operative approaches. In our study, when we found no relationship between the sagittal images and the clinical findings, we attempted to exclude sagittal images to simplify the classification. However, we recognized that the displacement of the spinal cord on the sagittal and axial images was not necessarily consistent, and thus examining axial images alone could not substitute for the information obtained from examining both vantages. Therefore, I believe all 4 of the categories are necessary at present for classification.

*The Order of Severity in the Sagittal Plane*

Our description might be misinterpreted. We expressed “classified according to the severity of hernia and displacement (Fig. 1)” in the *Methods* section of our paper and described in the order of Types K, D, and P. However,



**FIG. 1.** Images from case reports alone are insufficient for establishing a sagittal image classification. **A:** Schema of axial spinal cord images. A typical Type P herniation has very little kink in the posterior spinal cord with only a forward protrusion. **B:** Some axial slices can be determined to be Type P (Line a), Type K, or even Type D (Line b). It is unknown as to which sagittal slices were selected in previous case reports; such cases should be classified as Type K or Type D but not Type P. Furthermore, only one axial slice could not help us distinguish between Type K and Type D herniation because of lateral displacement and the fact that the degree of displacement in the craniocaudal direction of the spinal cord was important for the assessment. This point is also one of the reasons that we could not completely exclude the need for sagittal image classification. When the degree of spinal cord displacement became higher in the craniocaudal or lateral direction in Type K lesions, the case was considered to be aggravated and was classified as Type D. **C:** Regarding sagittal image classification, when images with different extents of spinal cord displacement are equivocal, the case should be considered to represent a more severe herniation in order to avoid missing displacement of a higher-degree lesion. For example, when a Type P–like image and a Type K–like image yield equivocal results at the location of herniation, the case should be determined as Type K, and when a Type K–like image and a Type D–like image are similarly mixed, the case should be determined to represent a Type D herniation.

the order was based on the frequency of cases, not “the order of severity.” As described in the *Discussion* section of our paper, we never believed that the severity of symptoms was in this order, but rather in the order of Type P, Type K, and Type D, with Type P being the mildest, which is consistent with their opinion. However, because we assumed that only a few patients with Type P herniation (that is, mild) would visit the hospital, as there was only one case of Type P in our cases, we avoided placing Type P first. I would like to emphasize that although we initially attempted to use sagittal image classification to predict “the severity of herniation” in a simple manner, we later found that sagittal images could not account for the complicated pathological condition and that the axial images were better in this respect, as described in the *Discussion* section of our paper. Thus, the order of Types K, D, and P in our study is not intended in any way to indicate the severity of symptoms.

Regarding “a clear theoretical basis for the design of the image classification,” I agree with this statement, of course. However, since there was only one case of Type P herniation, and there was no relationship between the sagittal image classification and preoperative or postoperative factors in our 12 cases, we determined that it would be better to simply mention the pathology of the sagittal image classification, rather than to claim our unconfirmed assumption regarding sagittal image classification. A claim in this respect could be reasonable, and further investigation is necessary to examine the utility of sagittal image classification by investigating many cases, which would enable evaluation of all images, not just a limited number, as noted previously.

#### *Magnetic Resonance Imaging or CT Myelography*

Thanks to the recent emergence of high-resolution MR imaging, the need for CT myelography has decreased. Magnetic resonance imaging, which is a noninvasive procedure, may also be a better choice due to the recent availability of dynamic MR imaging. However, the important point is that we are able to obtain sufficient information about the hernia, regardless of whether it is through MR imaging or CT myelography. At present, we initially use MR imaging to evaluate herniation in detail and then move on to CT myelography when more detailed images are needed or when it is difficult to assess a bone lesion using MR images alone. Although the more images we can obtain, the more information we can collect and the more useful it becomes, both MR imaging and CT myelography are not always required when considering the burden for patients. Only when something is unclear do I consider the need for both modalities.

#### *Reliability of Image Evaluation*

Evaluation of images should of course be conducted in a blinded manner, in terms of symptoms. As mentioned in the *Acknowledgments* of our paper, Dr. Nakamura, one of the coauthors, investigated the images and symptoms, I generated the classification system, and 2 doctors classified the images and were blinded in terms of symptoms. I subsequently checked the image classifications, symptoms, and so on.

#### *Conclusions*

Lastly, I would like to express my greatest appreciation to all of the doctors who read this article and who have expressed an interest in our study.

Of course, the number of cases (12) was not sufficient to completely justify our classification system. However, prior to this, there had been only case reports, and none had suggested any system of image classification. Furthermore, no attention had been paid to axial images. Thus, it is regrettably difficult to evaluate image classification systems in conventional reviews based on images from the limited number of previously conducted case reports and it will be important to obtain detailed images in all future cases to resolve this issue. I would be very pleased if our classification design were to be used to evaluate images and report on this rare disease in the future. While images and neurological symptoms are sometimes inconsistent in spinal diseases, I hope to establish an image classification system that enables the evaluation of images, prognosis of symptoms, and early determination of therapeutic regimens for spinal cord herniation, which will be beneficial in the clinical setting.

I again would like to thank Drs. Groen and Middel who expressed their interest in our image classification design and have provided me with the opportunity to discuss these issues. It is my hope that we will all be able to contribute to further clarification of spinal cord herniation, which is poorly understood at present. (DOI: 10.3171/2009.10.SPINE09829)

SHIRO IMAGAMA, M.D.

Nagoya University Graduate School of Medicine  
Nagoya, Japan

#### **Reference**

1. Groen RJ, Middel B, Meilof JF, de Vos-van de Biezenbos JB, Enting RH, Coppes MH, et al: Operative treatment of anterior thoracic spinal cord herniation: three new cases and an individual patient data meta-analysis of 126 case reports. *Neurosurgery* **64** (3 Suppl):145–160, 2009