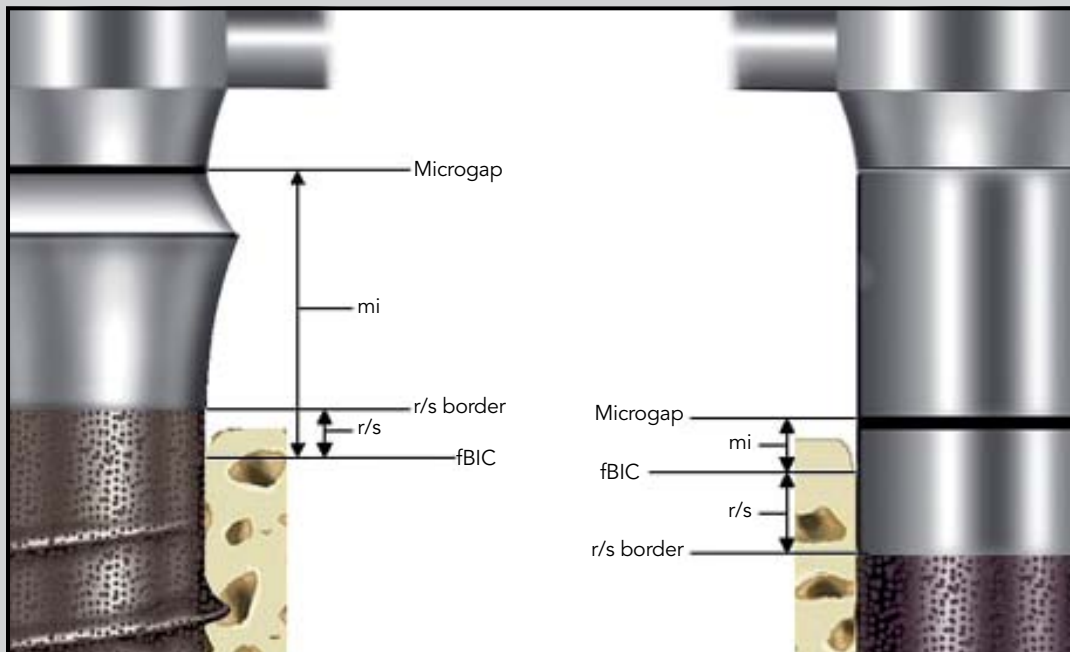

Changes in Crestal Bone Around Endosseous Implants During Functional Loading: A Radiographic Evaluation in Edentulous Patients Comparing Different Implant Designs



Nynke Tymstra, DDS, PhD*

Henny J.A. Meijer, DDS, PhD**

Gerry M. Raghoebar, MD, DDS, PhD***

Arjan Vissink, MD, DDS, PhD***

Marginal bone changes around titanium plasma-sprayed implants (n = 240) placed in the mandibular interforaminal regions of 120 edentulous patients were assessed over 5 years of follow-up, with emphasis on the influence of the locations of the microgap and rough/smooth border. Marginal bone changes were measured on standardized radiographs. Locations of the microgap and the rough/smooth border were both shown not to be major contributing factors in determining the marginal bone level around implants. (Int J Periodontics Restorative Dent 2012;32;677–686.)

*Researcher, Department of Oral and Maxillofacial Surgery, University Medical Center Groningen, University of Groningen, Groningen, The Netherlands.

**Professor, Department of Oral and Maxillofacial Surgery and Department of Prosthetic Dentistry, Dental School, University Medical Center Groningen, University of Groningen, Groningen, The Netherlands.

***Professor, Department of Oral and Maxillofacial Surgery, University Medical Center Groningen, University of Groningen, Groningen, The Netherlands.

Correspondence to: Dr Nynke Tymstra, Department of Oral and Maxillofacial Surgery, University Medical Center Groningen, University of Groningen, PO Box 30.001, NL-9700 RB Groningen, The Netherlands; fax: + 31 50 3611136; email: h.j.a.meijer@umcg.nl.

Marginal peri-implant bone loss is considered a factor in predicting long-term success of an implant regarding implant survival, peri-implant health, and esthetic outcome. The occurrence and extent of this bone loss have been thought to be related to implant design, density of bone, surgical trauma at implant insertion and stage-two surgery, occlusal overload of the implant, apical migration of the crevicular epithelium in an attempt to isolate bacterial-induced infection or to establish a biologic width, interruption of the blood supply, and development of a pathogenic bacterial biofilm.¹

The state of the implant surface (smooth versus rough) and the location of the rough/smooth border have been considered major factors in determining the marginal bone level around implants.²⁻⁴ This has been studied in detail during the initial healing phase but infrequently during the subsequent period of functional loading of the implant. It was concluded in several animal and human studies that the rough/smooth border of

nonsubmerged single-piece implants determined the level of the first bone-to-implant contact during the initial healing phase.⁵⁻⁷ However, no long-term data were available on the effects during functional loading.

Several animal studies have placed emphasis on the location of the implant-abutment microgap in relation to the marginal bone level.^{1,4,7-9} Hermann et al⁴ observed that the microgap, when located at or below the alveolar crest, determined the magnitude of crestal bone resorption during the initial healing phase. Other authors confirmed this observation.^{1,8,10} In contrast, Todescan et al⁹ did not observe additional bone loss when placing the microgap deeper in the bone.

Most human studies concluded that bone loss around implants was most pronounced during the initial healing phase, ie, during the first 6 to 12 months after implant placement.^{2,3,11,12} Moreover, in both human and animal studies, bone loss was not related to remodeling during the initial healing phase but occurred later after implant placement, and factors influencing this bone loss have not been studied with great detail. Therefore, the aim of this radiographic study was to assess crestal bone changes around implants used to support a mandibular overdenture during 5 years of functional loading. Special attention was paid to the impact of the locations of the rough/smooth border and the microgap at the crestal bone level.

Method and materials

Standardized intraoral radiographs¹³ taken of patients who had been treated with implant-supported mandibular overdentures at fixed intervals after implant placement were used. Patients had participated in previous prospective studies performed by the authors' group^{14,15} and were selected based on the following inclusion criteria: presence of a severely resorbed mandible (Class V or VI¹⁶ with reduced stability and insufficient retention of the mandibular denture), edentulous at least 2 years, no history of radiotherapy to the head or neck region, and no history of preprosthetic surgery or previous oral implants. Patients were informed of the different treatment options, and written informed consent was obtained from all participants.

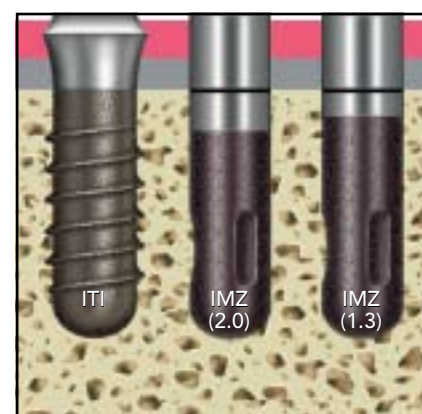
To assess the impact of the locations of the rough/smooth border and the microgap, implant systems were chosen in which the microgap and rough/smooth border lie on different levels in relation to the marginal bone level at implant placement. The following groups were formed (all patients of the previous prospective studies^{14,15} were included in the present study): ITI group = 50 patients who received two ITI implants (single-stage, 4.1-mm-diameter solid-screw implants, titanium plasma-sprayed [TPS] coating with a 3.8-mm smooth machined titanium surface at the coronal portion; Straumann), IMZ (2.0) group = 40 patients who

Table 1 Patient characteristics at baseline

	ITI (n = 50)	IMZ (2.0) (n = 40)	IMZ (1.3) (n = 30)
Mean age in y (range)	55.2 (34–74)	58.1 (42–79)	53.6 (38–77)
Sex (male/female)	17/33	21/19	9/21
Mean edentulous period for mandible in y (SD)	20.4 (9.9)	25.7 (12.0)	20.8 (9.0)
Mean mandibular bone height in mm (SD)	16.0 (2.0)	16.6 (2.7)	15.6 (2.0)
Mean bone quality (score 1 to 4)	2.6	2.8	3.0

SD = standard deviation.

Fig 1 Schematic drawing of the implants in each experimental group at time of implant placement in relation to the bone crest. Pink = epithelium; gray = connective tissue.



received two IMZ implants (two-stage, 4-mm-diameter cylindrical implants, TPS coating with a 2-mm smooth machined titanium surface at the coronal portion; Friatec), and IMZ (1.3) group = 30 patients who received two IMZ implants (two-stage, 4-mm-diameter cylindrical implants, TPS coating with a 1.3-mm smooth machined titanium surface at the coronal portion; Friatec).

Patient characteristics for each group are listed in Table 1. Bone height was measured using a lateral cephalometric radiograph with correction for distortion. Bone

quality was determined according to Lekholm and Zarb using a lateral cephalometric radiograph.¹⁷

Data collection for all patients was performed at 6, 12, 18, 30, 42, 54, and 66 months after implant placement. For the purposes of this radiographic study, data collection was initiated approximately 6 months after implant placement (at the start of functional loading) since it was not possible to take standardized radiographs immediately after implant placement because an aiming device was used connected to the bar.¹³

Treatment procedures

All patients received an implant in the right and left canine regions of the mandible under local anesthesia. One maxillofacial surgeon placed all implants according to a standard surgical protocol.^{14,15} ITI implants were placed nonsubmerged with the rough/smooth border level with the bone crest, and thus the top of the implant was located 3.8 mm above the crest (Fig 1). The IMZ implants were placed in a way that the top of the implant was aligned with the level

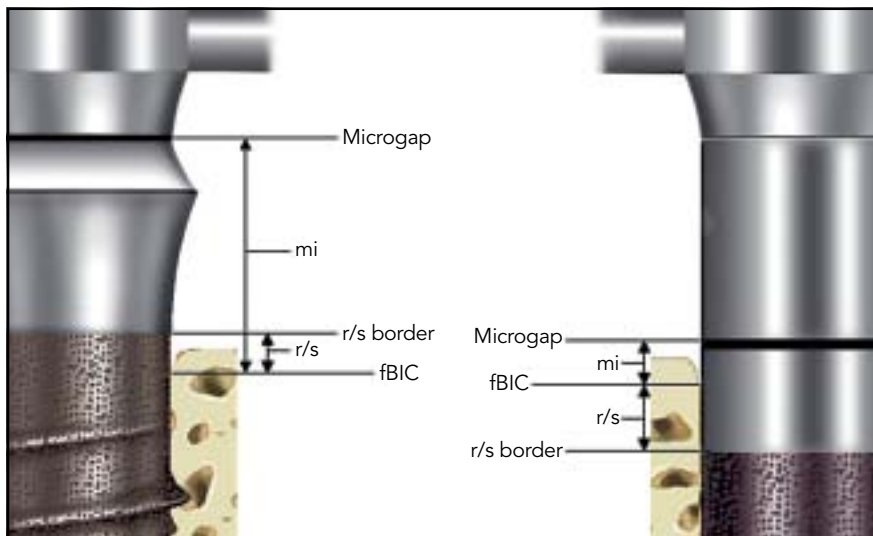


Fig 2 Schematic drawing of the radiographic evaluation with the following measurements: distance (mi) from the microgap of the implant to the first bone-to-implant contact (fBIC) and distance (r/s) from the rough/smooth border (r/s border) to the fBIC at ITI (left) and IMZ (right) implants. Figure not drawn to scale.

of the bone crest, thereby placing the microgap level with the bone crest. As a result, the rough/smooth border was located 2.0 and 1.3 mm under the bone crest in the IMZ (2.0) and IMZ (1.3) groups, respectively (Fig 1).

Three months after implant placement, stage-two surgery (thinning of the mucosa and abutment connection) was performed by the same oral surgeon in patients who had undergone submerged treatment. In the IMZ groups, 4-mm titanium connectors were used. Two weeks later, fabrication of a new maxillary denture and mandibular overdenture was initiated.

The prosthetic procedure began 3 months after implant placement in the ITI group. A uniform prosthetic treatment procedure was performed for all patients by two experienced prosthodontists. A bar with subsequent clip attachment supported the overdentures. A balanced occlusion and monoplane articulation concept with porcelain teeth was used for prosthesis fabrication. With regard to the ITI implants, the bar was placed in such a way that the microgap was located at the top of the implant and not at the lower end of the bevel, thus resulting in a microgap 3.8 mm above the alveolar crest (Fig 2).

Radiographic outcome measures

Intraoral standardized radiographs were obtained using the long-cone technique with an aiming device.¹³ The following measurements were taken using a digital caliper (Digital SI, Tesa) at each side of the implant¹⁸: distance between the top of the implant (microgap) and the first bone-to-implant contact and distance between the rough/smooth border and the first bone-to-implant contact (Fig 2).

All measurements were performed twice by the same observer within a 2-week interval and averaged since it has been shown that

the reproducibility is more consistent when one experienced observer performs the measurements twice than when two observers perform the measurements once.¹⁹

Data analysis

The Kruskal-Wallis test was used to evaluate possible significant differences between groups. A significance level of .05 was chosen. As in earlier implant literature, it was assumed that two implants placed in the same patient were statistically independent.^{14,19-21}

Results

Table 2 shows the number of patients and implant sides that could be assessed during the various evaluation times. Reasons for not attending a follow-up were mainly related to patient sickness or because patients had moved or passed away ($n = 5$). In addition, in a small number of patients, it was not possible to take a standardized radiograph of one or both implants because of anatomical restrictions or other patient-related factors.

In total, three implants were lost during the 5-year follow-up. Two implants were lost during the first 6 months (one IMZ [2.0] and one IMZ [1.3]) and were successfully replaced. After 18 months, a second IMZ (2.0) implant was lost. Because the patient died shortly after the implant was lost, the implant could not be replaced.

Figures 3 and 4 depict the mean distance between the top of the implant and the location of the first bone-to-implant contact and the mean distance between the rough/smooth border and the first bone-to-implant contact, respectively, as a function of the length of follow-up. Figure 3 shows that at functional loading, the mean marginal bone levels of IMZ implants were within 2 mm of the microgap. Subsequently, bone loss progressed to a mean level of approximately 2 mm below the microgap at the 66-month follow-up. Moreover, at the start of functional loading, the mean marginal bone levels of the IMZ implants were at the height of the smooth surface (Fig 4), coronal to the rough/smooth border. In addition, over time, bone loss did not stop when the rough/smooth border was reached.

Table 3 shows the percentage of implant sides with a marginal bone level at the height of the smooth surface and within 1.0, 1.3, and 2.0 mm of the microgap. At the time of loading, one-third of the ITI implant sides had a marginal bone level at the height of the smooth machined surface. Furthermore, the marginal bone level in the majority of IMZ (2.0) and IMZ (1.3) implant sides was found to be at the smooth machined surface and within 2 mm of the microgap at the start of functional loading.

Figure 5 shows the progress of mean marginal bone loss from 6 (start of functional loading) to 66 months after implant placement. The mean marginal bone loss

Table 2 No. of patients and proximal implant sides available for evaluation at 6, 12, 18, 30, 42,

	6 mo			12 mo			18 mo		
	ITI	IMZ (2.0)	IMZ (1.3)	ITI	IMZ (2.0)	IMZ (1.3)	ITI	IMZ (2.0)	IMZ (1.3)
No. of patients	49	38	30	48	36	30	48	38	30
No. of implant sides	190	152	120	186	144	116	186	148	120
No. of photographs absent (left, right, both)	4 (1, 2, 1)	2 (0, 0, 2)	0 (0, 0, 0)	4 (1, 2, 1)	4 (0, 0, 4)	2 (1, 1, 0)	4 (1, 2, 1)	4 (1, 1, 2)	0 (0, 0, 0)

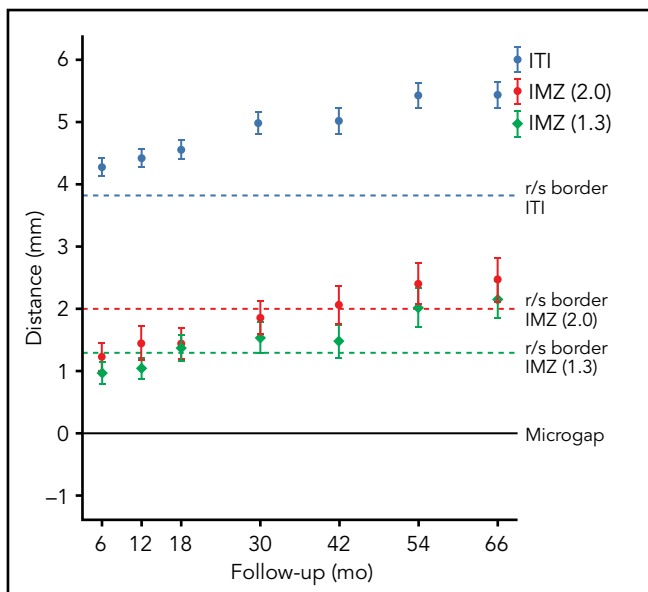


Fig 3 Mean distance between the marginal bone level and the microgap for the ITI, IMZ (2.0), and IMZ (1.3) groups over 66 months after implant placement (error bars show 95% confidence intervals of the mean). Functional loading of the implants was initiated 6 months after placement.

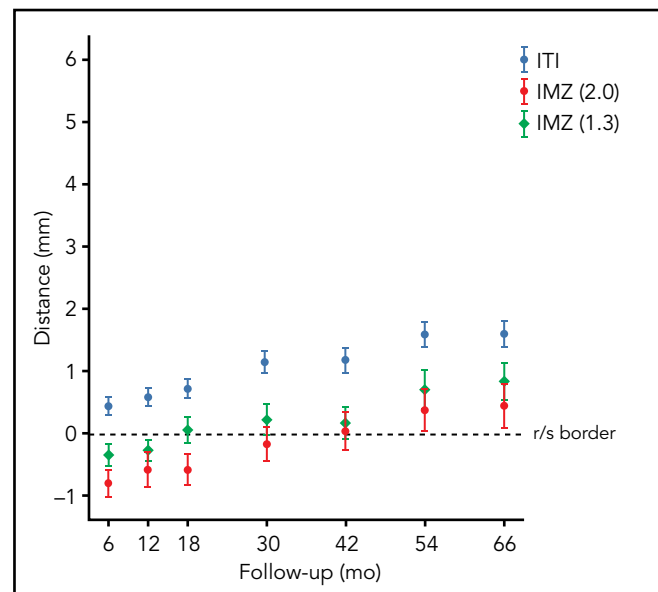


Fig 4 Mean distance between the marginal bone level and the rough/smooth border of the implants for the ITI, IMZ (2.0), and IMZ (1.3) groups over 66 months after implant placement (error bars show 95% confidence intervals of the mean). Functional loading of the implants was initiated 6 months after placement.

around all implant systems continued gradually over the 5 years of follow-up. No significant differences in bone loss were observed between groups.

Discussion

This study revealed that the locations of the rough/smooth border and the microgap do not have to

be considered as major factors in determining the marginal bone level after implant placement in edentulous subjects during the first 5 years of functional loading.

54, and 66 months after implant placement

30 mo		42 mo		54 mo		66 mo					
ITI	IMZ (2.0)	IMZ (1.3)	ITI	IMZ (2.0)	IMZ (1.3)	ITI	IMZ (2.0)	IMZ (1.3)	ITI	IMZ (2.0)	IMZ (1.3)
48	37	30	47	37	28	45	35	30	45	35	30
186	146	118	176	146	112	170	138	120	170	138	120
4 (1, 2, 1)	3 (0, 1, 2)	1 (0, 1, 0)	5 (1, 2, 2)	3 (0, 1, 2)	0 (0, 0, 0)	7 (1, 2, 4)	4 (0, 1, 3)	0 (0, 0, 0)	7 (1, 2, 4)	4 (0, 1, 3)	0 (0, 0, 0)

Table 3 Percentage of implant sides next to which the marginal bone level was at the height of the smooth surface and within 2.0, 1.3, or 1.0 mm of the microgap between the implant and abutment

Group	Marginal bone level	6 mo*	12 mo	18 mo	30 mo	42 mo	54 mo	66 mo
ITI	Smooth surface	33.2	29.6	26.3	18.8	21.6	4.1	8.2
	< 2.0 mm below microgap	NA	NA	NA	NA	NA	NA	NA
	< 1.3 mm below microgap	NA	NA	NA	NA	NA	NA	NA
	< 1.0 mm below microgap	NA	NA	NA	NA	NA	NA	NA
IMZ (2.0)	Smooth surface	78.9	75.7	74.3	63.7	58.2	55.1	55.1
	< 2.0 mm below microgap	78.9	75.7	74.3	63.7	58.2	55.1	55.1
	< 1.3 mm below microgap	67.1	61.1	61.5	52.1	44.5	47.1	43.5
	< 1.0 mm below microgap	55.9	51.4	51.4	39.7	37.0	36.2	35.5
IMZ (1.3)	Smooth surface	70.0	66.4	55.0	50.0	47.3	41.7	30.8
	< 2.0 mm below microgap	91.7	94.0	85.0	73.7	74.1	60.0	58.3
	< 1.3 mm below microgap	70.0	66.4	55.0	50.0	47.3	41.7	30.8
	< 1.0 mm below microgap	43.3	37.1	35.0	33.9	32.1	23.3	22.5

NA = not applicable.

*Functional loading of the implants was initiated 6 months after placement.

ITI implants were used to study the impact of a rough/smooth border on the marginal bone level because an ITI implant is a single-piece implant without a microgap

in the vicinity of the marginal bone. When placing these implants with the rough/smooth border in alignment with the bone crest, one would expect the marginal bone

level to be at or below the level of the rough/smooth border 6 months after implant placement. However, in one-third of implants, the marginal bone level was still located

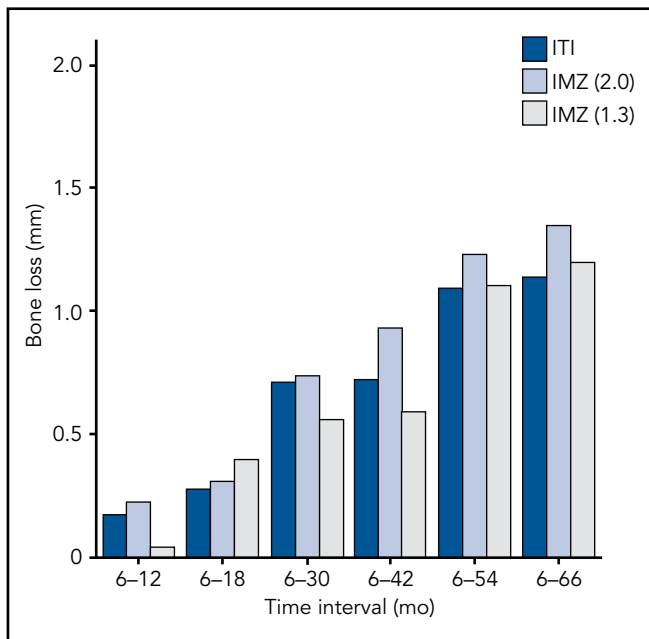


Fig 5 Mean radiographic marginal bone loss for the ITI, IMZ (2.0), IMZ (1.3) groups over a period of 6 to 66 months after implant placement. Functional loading of the implants was initiated 6 months after placement.

above the rough/smooth border, ie, at the height of the smooth surface. This might be related to the surgical technique applied. When inserting the implants with the rough/smooth border in alignment with the lower buccal bone level, the approximal sides of a certain number of ITI implants will be placed with the smooth surface subcrestal. In particular, this positioning might occur in mandibles with a small buccolingual dimension. Even then, based on the results of prior animal studies evaluating bone remodeling during the initial healing phase, the marginal bone level was not expected to be above the rough/smooth border at the start of functional loading. Several animal studies, including that of Hermann et al,⁴ showed that the first bone-to-implant contact for single-piece implants is determined by the rough/smooth border, re-

sulting in a first bone-to-implant contact at the height of the rough surface. Hermann et al⁴ indicated that the rough/smooth border is an important landmark for bone loss, but their study design did not permit prediction of bone loss after the initial remodeling phase. Hämmerle et al⁵ and Hartman and Cochran³ concluded that subcrestal positioning of the rough/smooth border resulted in a significantly higher marginal bone loss in the first year after implant placement. However, in this human study, the marginal bone level was found well above the rough/smooth border in approximately one-third of patients at loading. In addition, bone loss continued after the marginal bone level had reached the rough surface. Thus, the authors propose that the state of the surface (rough versus smooth) has no major impact on the

marginal bone level in the edentulous mandible during functional loading.

In IMZ implants, both the rough/smooth interface and the microgap could affect marginal bone changes. The implants were placed with the smooth portion of the implant neck subcrestal and the microgap at the level of the bone crest. In contrast to other studies reported in the literature,^{3,4} the marginal bone level was not at the rough/smooth border after initial bone remodeling at implant loading but still in the area between the microgap and the rough/smooth border, thus at the smooth surface. In addition, there were no significant differences measured for bone loss between the two IMZ groups. Moreover, the mean bone loss continued after crossing the rough/smooth border in both IMZ groups.

These observations indicate that the location of the rough/smooth border is not a major factor in determining the extent of peri-implant bone loss in humans during functional loading.

In previous animal studies, it was concluded that the microgap determines the first bone-to-implant contact in two-piece implants.^{1,4,8} A contaminated microgap would be isolated by apical migration of the epithelium beyond the microgap and its bacteria. Migration of the epithelium and its subsequent response to re-establish the dimension of the biologic width has been proposed to be responsible for the approximate 2 mm that was present apical to the microgap in those experiments after initial bone remodeling.^{8,22} The results of the IMZ implants demonstrated that a marginal bone level within 2 mm or even within 1 mm of the microgap is not an exception 6 months after placement at the start of functional loading. Moreover, in spite of the different locations of the microgap after implant placement for the various implant designs studied, there were no significant differences in mean bone loss between the IMZ and ITI groups, other than a larger variation in bone levels around IMZ implants than around ITI implants. This observation might indicate that marginal bone changes around IMZ implants are less predictable and more prone to patient factors. In addition, these results seem to indicate that the location of the microgap has no major impact on the marginal bone level in humans.

An important observation was that neither implant group (ITI, IMZ) reached a steady bone state, which would be expected from modern implant designs. The peri-implant bone loss in the three implant groups was more extended in comparison with the studies of Hämmerle et al⁵ and others^{23,24} who evaluated implant-supported overdentures. However, the bone loss was still acceptable since it was within the limits of a yearly bone loss of 0.2 mm, described by Albrektsson et al.²⁵ The authors are not sure as to how to explain this continuing bone loss. A possible explanation might be that TPS-coated implants were used. Implants with TPS coatings seem to show more marginal bone loss than, for example, a sandblasted and acid-etched implant surface.^{26,27} On the other hand, Hämmerle et al⁵ and Hartman and Cochran³ also evaluated TPS-coated implants. However, instead of edentulous patients like those included in this study, only partially edentulous patients were included in their studies. Moreover, because the study was performed on severely resorbed edentulous mandibles, the observations do not have to reflect the peri-implant bone changes that might be observed in implants placed in partially edentulous patients. Another precaution that has to be considered when comparing the results of this human study with that of animal studies is that the observations were based on radiographic findings, while in animal studies, histologic data were also avail-

able. Hermann et al²⁸ showed that reliable standardized radiography reflected peri-implant crestal bone levels similar to those determined by histometric analysis.

Conclusions

The locations of the rough/smooth border and the microgap do not have to be considered as major factors in determining the marginal bone level around implants in the severely resorbed human mandible during functional loading of TPS-coated implants. In addition, marginal bone loss continued to progress gradually over time. An important observation was that the intermediate (5-year) effects of the implant designs studied on marginal bone loss in humans were not in accordance with the bone loss around implants expected from the results of previous animal studies. Moreover, this study showed that there still are a lot of uncertainties regarding the behavior of marginal bone around implants in humans since most current implant designs are based on results of animal studies. Further clinical research is needed to verify these results over longer time periods.

Acknowledgments

The authors express their gratitude to Dr R.H.K. Batenburg and Dr K. Heydenrijk for their work in the initial studies.

References

1. Assenza B, Scarano A, Petrone G, et al. Crestal bone remodeling in loaded and unloaded implants and the microgap: A histologic study. *Implant Dent* 2003; 12:235–241.
2. Hänggi MP, Hänggi DC, Schoolfield JD, Meyer J, Cochran DL, Hermann JS. Crestal bone changes around titanium implants. Part I: A retrospective radiographic evaluation in humans comparing two non-submerged implant designs with different machined collar lengths. *J Periodontol* 2005;76:791–802.
3. Hartman GA, Cochran DL. Initial implant position determines the magnitude of crestal bone remodeling. *J Periodontol* 2004;75:572–577.
4. Hermann JS, Buser D, Schenk RK, Cochran DL. Crestal bone changes around titanium implants. A histometric evaluation of unloaded non-submerged and submerged implants in the canine mandible. *J Periodontol* 2000;71:1412–1424.
5. Hämmerle CH, Brägger U, Bürgin W, Lang NP. The effect of subcrestal placement of the polished surface of ITI implants on marginal soft and hard tissues. *Clin Oral Implants Res* 1996;7:111–119.
6. Hermann JS, Schoolfield JD, Schenk RK, Buser D, Cochran DL. Influence of the size of the microgap on crestal bone changes around titanium implants. A histometric evaluation of unloaded non-submerged implants in the canine mandible. *J Periodontol* 2001;72:1372–1383.
7. King GN, Hermann JS, Schoolfield JD, Buser D, Cochran DL. Influence of the size of the microgap on crestal bone levels in non-submerged dental implants: A radiographic study in the canine mandible. *J Periodontol* 2002;73:1111–1117.
8. Piattelli A, Vrespa G, Petrone G, Iezzi G, Annibali S, Scarano A. Role of the microgap between implant and abutment: A retrospective histologic evaluation in monkeys. *J Periodontol* 2003;74:346–352.
9. Todescan FF, Pustiglioni FE, Imbrunio AV, Albrektsson T, Gioso M. Influence of the microgap in the peri-implant hard and soft tissues: A histomorphometric study in dogs. *Int J Oral Maxillofac Implants* 2002;17:467–472.
10. Alomrani AN, Hermann JS, Jones AA, Buser D, Schoolfield J, Cochran DL. The effect of a machined collar on coronal hard tissue around titanium implants: A radiographic study in the canine mandible. *Int J Oral Maxillofac Implants* 2005; 20:677–686.
11. Chou CT, Morris HF, Ochi S, Walker L, DesRosiers D. AICRG, Part II: Crestal bone loss associated with the Ankylos implant: Loading to 36 months. *J Oral Implantol* 2004;30:134–143.
12. Weber HP, Crohin CC, Fiorellini JP. A 5-year prospective clinical and radiographic study of non-submerged dental implants. *Clin Oral Implants Res* 2000; 11:144–153.
13. Meijer HJ, Steen WH, Bosman F. Standardized radiographs of the alveolar crest around implants in the mandible. *J Prosthet Dent* 1992;68:318–321.
14. Heydenrijk K, Raghoobar GM, Meijer HJ, Stegenga B. Clinical and radiologic evaluation of 2-stage IMZ implants placed in a single-stage procedure: 2-year results of a prospective comparative study. *Int J Oral Maxillofac Implants* 2003;18: 424–432.
15. Batenburg RH, Meijer HJ, Raghoobar GM, Van Oort RP, Boering G. Mandibular overdentures supported by two Brånemark, IMZ or ITI implants. A prospective comparative preliminary study: One-year results. *Clin Oral Implants Res* 1998;9: 374–383.
16. Cawood JI, Howell RA. A classification of the edentulous jaws. *Int J Oral Maxillofac Surg* 1988;17:232–236.
17. Lekholm U, Zarb GA. Patient selection and preparation. In: Brånemark PI, Zarb GA, Albrektsson T (eds). *Tissue-Integrated Prostheses: Osseointegration in Clinical Dentistry*, ed 1. Chicago: Quintessence, 1985:199–209.
18. Meijer HJ, Steen WH, Bosman F. A comparison of methods to assess marginal bone height around endosseous implants. *J Clin Periodontol* 1993;20:250–253.
19. Batenburg RH, Meijer HJ, Geraets WG, van der Stelt PF. Radiographic assessment of changes in marginal bone around endosseous implants supporting mandibular overdentures. *Dentomaxillofac Radiol* 1998;27:221–224.
20. Stellingsma K, Raghoobar GM, Meijer HJ, Stegenga B. The extremely resorbed mandible: A comparative prospective study of 2-year results with 3 treatment strategies. *Int J Oral Maxillofac Implants* 2004;19:563–577.
21. Boerrigter EM, Geertman ME, Van Oort RP, et al. Patient satisfaction with implant-retained mandibular overdentures. A comparison with new complete dentures not retained by implants—A multicentre randomized clinical trial. *Br J Oral Maxillofac Surg* 1995;33:282–288.
22. Hermann JS, Buser D, Schenk RK, Schoolfield JD, Cochran DL. Biologic Width around one- and two-piece titanium implants. *Clin Oral Implants Res* 2001; 12:559–571.
23. Lindquist LW, Carlsson GE, Jemt T. A prospective 15-year follow-up study of mandibular fixed prostheses supported by osseointegrated implants. Clinical results and marginal bone loss. *Clin Oral Implants Res* 1996;7:329–336.
24. Quirynen M, Naert I, van Steenberghe D, Teerlinck J, Dekeyser C, Theuniers G. Periodontal aspects of osseointegrated fixtures supporting an overdenture. A 4-year retrospective study. *J Clin Periodontol* 1991;18:719–728.
25. Albrektsson T, Zarb G, Worthington P, Eriksson AR. The long-term efficacy of currently used dental implants: A review and proposed criteria of success. *Int J Oral Maxillofac Implants* 1986;1:11–25.
26. Cochran DL, Nummikoski PV, Higginbottom FL, Hermann JS, Makins SR, Buser D. Evaluation of an endosseous titanium implant with a sandblasted and acid-etched surface in the canine mandible: Radiographic results. *Clin Oral Implants Res* 1996;7:240–252.
27. Rocuzzo M, Bunino M, Prioglio F, Bianchi SD. Early loading of sandblasted and acid-etched (SLA) implants: A prospective split-mouth comparative study. *Clin Oral Implants Res* 2001;12:572–578.
28. Hermann JS, Schoolfield JD, Nummikoski PV, Buser D, Schenk RK, Cochran DL. Crestal bone changes around titanium implants: A methodologic study comparing linear radiographic with histometric measurements. *Int J Oral Maxillofac Implants* 2001;16:475–485.