

University of Groningen

Body composition of patients with neuroblastoma using computed tomography

Ijpma, Irene; Lequin, Maarten H.; Nievelstein, Rutger A.J.; Fiocco, Marta; Tissing, Wim J.E.

Published in:
Pediatric Blood and Cancer

DOI:
[10.1002/pbc.29337](https://doi.org/10.1002/pbc.29337)

IMPORTANT NOTE: You are advised to consult the publisher's version (publisher's PDF) if you wish to cite from it. Please check the document version below.

Document Version
Publisher's PDF, also known as Version of record

Publication date:
2021

[Link to publication in University of Groningen/UMCG research database](#)

Citation for published version (APA):

Ijpma, I., Lequin, M. H., Nievelstein, R. A. J., Fiocco, M., & Tissing, W. J. E. (2021). Body composition of patients with neuroblastoma using computed tomography. *Pediatric Blood and Cancer*, *68*(12), [e29337]. <https://doi.org/10.1002/pbc.29337>

Copyright

Other than for strictly personal use, it is not permitted to download or to forward/distribute the text or part of it without the consent of the author(s) and/or copyright holder(s), unless the work is under an open content license (like Creative Commons).

The publication may also be distributed here under the terms of Article 25fa of the Dutch Copyright Act, indicated by the "Taverne" license. More information can be found on the University of Groningen website: <https://www.rug.nl/library/open-access/self-archiving-pure/taverne-amendment>.

Take-down policy

If you believe that this document breaches copyright please contact us providing details, and we will remove access to the work immediately and investigate your claim.

Downloaded from the University of Groningen/UMCG research database (Pure): <http://www.rug.nl/research/portal>. For technical reasons the number of authors shown on this cover page is limited to 10 maximum.

PSYCHOSOCIAL AND SUPPORTIVE CARE:
RESEARCH ARTICLE

Body composition of patients with neuroblastoma using computed tomography

Irene IJpma¹ | Maarten H. Lequin^{1,2} | Rutger A. J. Nievelstein^{1,2} | Marta Fiocco^{3,4,5} | Wim J. E. Tissing^{1,6}¹ Princess Máxima Center for Pediatric Oncology, Utrecht, The Netherlands² Division Imaging & Oncology, Department of Radiology & Nuclear Medicine, University Medical Center Utrecht, Utrecht, The Netherlands³ Department of Biomedical Data Science, Leiden University Medical Center, Leiden, The Netherlands⁴ Mathematical Institute, Leiden University, Leiden, The Netherlands⁵ Trial Data Center, Princess Máxima Center for Pediatric Oncology, Utrecht, The Netherlands⁶ Department of Pediatric Oncology and Hematology, University of Groningen, University Medical Center Groningen, Groningen, The Netherlands**Correspondence**

Wim Tissing, Princess Máxima Center for Pediatric Oncology, PO Box 113, 3720 AC Bilthoven, The Netherlands.

Email: w.j.e.tissing@prinsesmaximacentrum.nl**Abstract****Background:** Computed tomography (CT) is often used to investigate muscle and fat mass in adult patients with cancer. However, this method has rarely been used in the pediatric cancer population. The present retrospective study aimed to investigate changes in body composition using CT during treatment in children with neuroblastoma.**Procedure:** CT images of 29 patients with high-risk neuroblastoma were retrospectively analyzed at diagnosis and longitudinally during treatment. The cross-sectional area of skeletal muscle, intermuscular adipose tissue (IMAT), visceral adipose tissue (VAT), and subcutaneous adipose tissue (SAT) and skeletal muscle density at the level of the third lumbar vertebra were examined. To correct for height, cross-sectional areas were divided by height in meters squared. A linear mixed model was estimated to investigate changes in body composition over time.**Results:** A small increase in skeletal muscle ($p = .029$), skeletal muscle density ($p = .002$), and IMAT ($p < .001$) was found. Furthermore, a rapid increase in VAT ($p < .001$) and SAT ($p = .001$) was seen early during treatment with the highest volumes after six cycles of chemotherapy.**Conclusions:** CT scans obtained during standard care provide insight into the direction and timing of changes in skeletal muscle and different types of adipose tissue in childhood cancer patients. Future research is needed regarding the consequences of the rapid increase of VAT and SAT early during treatment.**KEYWORDS**

body composition, computed tomography, neuroblastoma, pediatric cancer

Abbreviations: ASCT, autologous stem cell transplantation; BIA, bioelectrical impedance analyses; BMI, body mass index; CT, computed tomography; FFM, fat-free mass; FM, fat mass; HU, Hounsfield units; IMAT, intermuscular adipose tissue; L3, third lumbar vertebra; MIBG, metaiodobenzylguanidine; MRI, magnetic resonance imaging; SAT, subcutaneous adipose tissue; SDS, standard deviation score; TAT, total adipose tissue; VAT, visceral adipose tissue.This is an open access article under the terms of the [Creative Commons Attribution-NonCommercial](https://creativecommons.org/licenses/by-nc/4.0/) License, which permits use, distribution and reproduction in any medium, provided the original work is properly cited and is not used for commercial purposes.© 2021 The Authors. *Pediatric Blood & Cancer* published by Wiley Periodicals LLC

1 | INTRODUCTION

Malnutrition has been associated with complications during and after childhood cancer treatment. During treatment, under- and overnutrition can result in a reduced tolerance to treatment, increased risk of infections, and a lower quality of life.^{1–3} After treatment, overnutrition is one of the risk factors for obesity, metabolic syndrome, cardiovascular disease, and type 2 diabetes mellitus.^{4–6} Both obesity and a decreased body mass index (BMI) have been linked to a lower survival in childhood cancer patients.^{3,7}

Bodyweight, height, and BMI are most commonly used to determine nutritional status. However, these measurements do not distinguish between fat mass (FM) and fat-free mass (FFM). Patients with cancer can be undernourished based on a low BMI and/or low FFM, or can be overnourished based on a high BMI and/or a high FM. Both criteria do not necessarily occur simultaneously, which can result in misclassification of nutritional status if only weight and height are measured. Therefore, the measurement of body composition is crucial to identify under- and overnourished patients.

Studies regarding body composition in children with cancer during treatment are scarce. A longitudinal study in 133 newly diagnosed pediatric patients with a hematological, solid, or brain malignancy (63 males; median age 8.1 years) investigated the BMI and body composition at 0, 3, 6, and 12 months after diagnosis.⁸ Body composition was determined by bioelectrical impedance analyses (BIA). The BMI of patients with a brain malignancy increased directly after diagnosis, whereas the BMI of patients with a hematological or solid malignancy initially decreased at the beginning of treatment, but increased within 3 months after diagnosis. In all patients, FFM was low at diagnosis and remained low during treatment. The FM increased almost immediately after diagnosis and continued to increase during treatment. The nature of this increased FM (either intermuscular, visceral, or subcutaneous) in children with cancer cannot be measured using BIA. As visceral fat is strongly correlated with cardiovascular disease and type 2 diabetes,⁹ the distinction between different types of fat tissue seems important for childhood cancer patients.

Several methods can be used to assess body composition, including circumferences, skinfold measurements, BIA, dual-energy X-ray absorptiometry (DEXA), air displacement plethysmography (ADP), magnetic resonance imaging (MRI), and computed tomography (CT). Unlike other methods, CT and MRI have the benefit that a distinction can be made between skeletal muscle, intermuscular adipose tissue (IMAT), visceral adipose tissue (VAT), and subcutaneous adipose tissue (SAT). Single-slice abdominal cross-sectional areas at the level of the third lumbar vertebra (L3) are strongly correlated with whole-body FM and FFM in healthy and cancer adult populations.^{10,11} A recent study in 39 pediatric patients with a solid tumor (18 males, median age 11.0 years) used CT scans at the level of T12-L1 to assess body composition at diagnosis and during follow-up at 6–14 weeks.¹² Scans at the level of L3 were also available for 22 of these patients. A decrease in skeletal muscle was found both at the level of T12-L1 and L3. Furthermore, a trend toward a significantly increased VAT was only found at the level of T12-L1. No study has investigated body composition using

CT in children with neuroblastoma, so far. Patients with neuroblastoma are generally younger at diagnosis, receive more aggressive treatment, and are more likely to have significant metastatic disease compared to children with other solid tumors. Further knowledge regarding the timing of changes in skeletal muscle and the different types of adipose tissue is needed to develop intervention studies aiming to prevent possible detrimental changes in body composition during cancer treatment.

The present retrospective study aimed to investigate changes in body composition using CT scans made during standard care of children with high-risk neuroblastoma at diagnosis and during follow-up. Data on weight, height, and BMI were examined as well.

2 | METHODS

2.1 | Study population

Patients diagnosed with high-risk neuroblastoma between 2014 and 2018 and treated at the Princess Máxima Center for pediatric oncology in Utrecht were randomly selected. Patients were treated or were still on treatment according to the DCOG NBL 2009 protocol, including chemotherapy, autologous stem cell transplantation (ASCT), surgery, radiotherapy, and immunotherapy. All patients received dexamethasone to prevent chemotherapy-induced nausea and vomiting. Eligible patients were 0–18 years of age and had at least two CT scans at the level of the L3 vertebra at any time during treatment.

2.2 | Methods

Low-dose CT scans, which were part of metaiodobenzylguanidine (MIBG) scans, were used. The MIBG scans were made during the standard care of patients with neuroblastoma at diagnosis and during follow-up. CT scans were selected at the following time points: at diagnosis (T0), after six cycles of chemotherapy (T1), after ASCT (T2), after three cycles of immunotherapy (T3), and at the end of immunotherapy (T4). Data on age, gender, weight, and height were derived from medical records.

2.3 | Body composition

The cross-sectional area (cm²) of skeletal muscle, IMAT, VAT, and SAT was assessed using CT images at the level of the L3 vertebra by a single trained researcher (Irene I. Jpma) using Slice-O-Matic 5.0 (Tomovision, Montreal, Canada). Standard density thresholds (Hounsfield units [HU]) were used to define skeletal muscle (–29 to +150 HU), IMAT (–190 to –30 HU), VAT (–150 to –50 HU), and SAT (–190 to –30 HU).¹⁰ Skeletal muscle density was measured as the mean density (HU) of the total skeletal muscle cross-sectional area. Total adipose tissue (TAT) was derived by summing the areas of IMAT, VAT, and SAT. To correct for height, all cross-sectional areas in square centimeters were divided by height in squared meters. The

TABLE 1 Baseline characteristics of patients with high-risk neuroblastoma

	Patients (N = 29)
Age (years), median (IQR)	3.0 (2.0–4.5)
Gender boy, N (%)	19 (65.5)
Weight-for-age (SDS), median (IQR)	−0.5 (−1.4 to 0.3)
Height-for-age (SDS), median (IQR)	−0.3 (−0.8 to −0.5)
Nutritional status, N (%)	
Undernutrition (BMI < −2SDS)	4 (13.8)
Normal	25 (86.2)
Overnutrition (BMI > +SDS)	0
Time between first and last CT scan (months), median (IQR)	13.0 (7.0–17.5)

Abbreviations: BMI, body mass index; CT, computed tomography; IQR, interquartile range; SDS, standard deviation score.

VAT-to-SAT ratio, muscle-to-VAT ratio, and muscle-to-TAT ratio were calculated.

2.4 | Anthropometry

Anthropometric data were expressed as standard deviation scores (SDSs) calculated from Dutch reference standards.^{13,14} These Dutch reference standards are based on the third nationwide growth study for data on weight-for-age¹³ and based on the fifth nationwide growth study for data on height-for-age and BMI-for-age.¹⁴ The SDSs reflect how patients relate to healthy age- and gender-matched Dutch children.

2.5 | Statistical analysis

Descriptive statistics are presented as median with interquartile range (IQR) or percentage. A linear mixed model was estimated to investigate the effect of skeletal muscle, IMAT, VAT, SAT, VAT-to-SAT ratio, muscle-to-VAT ratio, muscle-to-TAT ratio, weight-for-age, height-for-age, and BMI-for-age over time. An unstructured covariance type was used to model the covariance structure among repeated measures. Time point was entered as fixed effect in the model (T0 as baseline). Statistical analyses were performed using SPSS, version 22 (IBM SPSS Inc., Chicago, IL).

3 | RESULTS

3.1 | Study population

A sample of 29 patients was selected to analyze body composition. Patient characteristics are shown in Table 1. Two to five CT scans were available per patient at the defined time points, resulting in a total of 99 analyzed scans. Two patients had no CT scan at baseline. Five patients died within the study period (after T1: N = 1; after T2: N = 3; after T3: N = 1). Other reasons for missing CT scans were unusable scan (e.g., no

L3 included, movement; N = 9), scan made in another hospital (N = 5), no scan made at selected time point (N = 5), and insufficient follow-up time (N = 15).

3.2 | Body composition

Figure 1 shows the changes in body composition over time. A small increase in skeletal muscle, skeletal muscle density, and IMAT was found ($p = .029$, $.002$, and $<.001$, respectively). Furthermore, a rapid increase in VAT ($p < .001$) and SAT ($p = .001$) was seen early during treatment, with the highest volumes after six cycles of chemotherapy (T1). The changes in body composition over time without adjustment for height showed comparable results (Table S1). No significant change in VAT-to-SAT ratio was found over time ($p = .090$). A significant decrease was found in muscle-to-VAT and muscle-to-TAT ratio ($p < .001$ and $.040$, respectively) (Figure S1). Figure 2 shows an example of the analyzed CT scans of a patient at each time point.

3.3 | Anthropometry

Figure 3 illustrates the changes in weight, height, and BMI over time. Weight-for-age, height-for-age, and BMI-for-age decreased over time ($p = .001$, $<.001$, and $.001$, respectively). The SDSs for weight-for-age and BMI-for-age were closest to zero after six cycles of chemotherapy (T1).

4 | DISCUSSION

The present study provides for the first time, insight into changes of different types of adipose tissue in children with high-risk neuroblastoma throughout treatment. A rapid increase in VAT and SAT was found early during treatment with the highest volumes after six cycles of chemotherapy. Furthermore, a small increase in skeletal muscle and IMAT was seen during treatment.

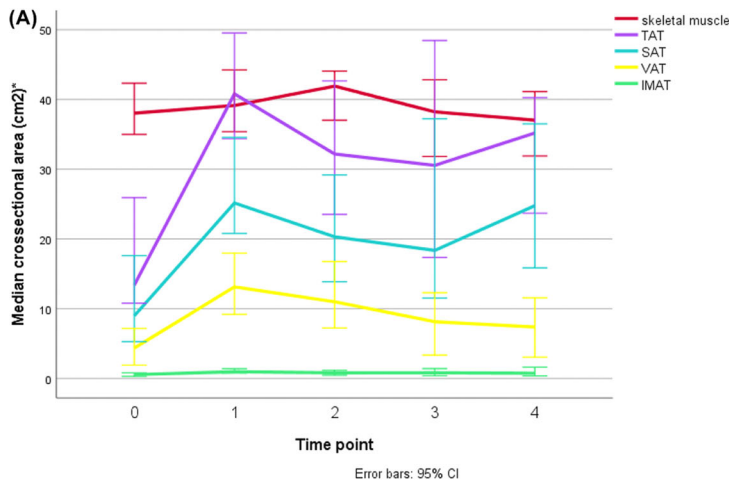


FIGURE 1 (A) Changes in body composition (median [95% CI]) of patients with neuroblastoma over time.

*Cross-sectional areas (cm²) divided by height in squared meters. T0: N = 27; T1: N = 24; T2: N = 24; T3: N = 14; T4: N = 10. TAT, total adipose tissue; SAT, subcutaneous adipose tissue; VAT, visceral subcutaneous adipose tissue; IMAT, intermuscular adipose tissue. Skeletal muscle: $p = .029$; TAT: $p < .001$; SAT: $p = .001$; VAT: $p < .001$; IMAT: $p < .001$. (B) Changes in skeletal muscle density (median [95% CI]) of patients with neuroblastoma over time, $p = .002$. Error bars: 95% CI

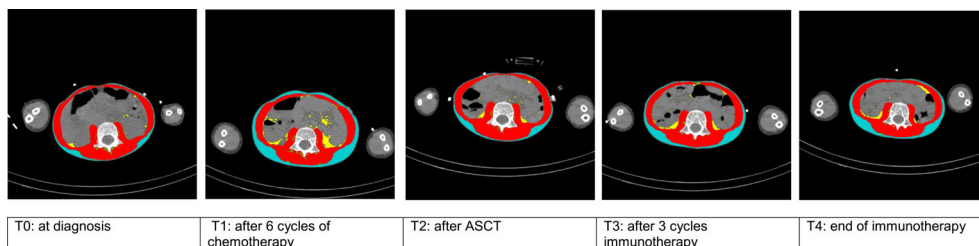
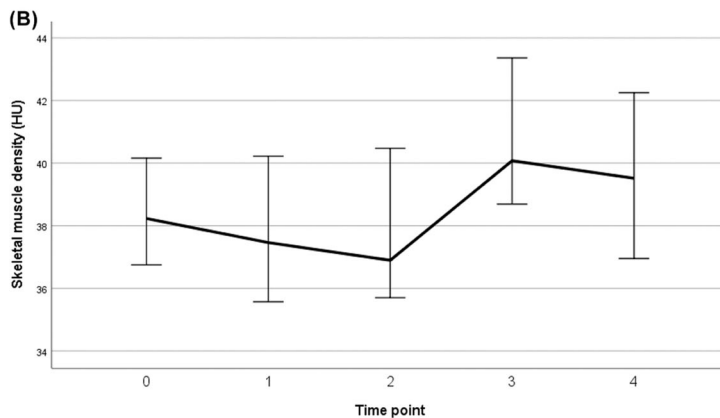
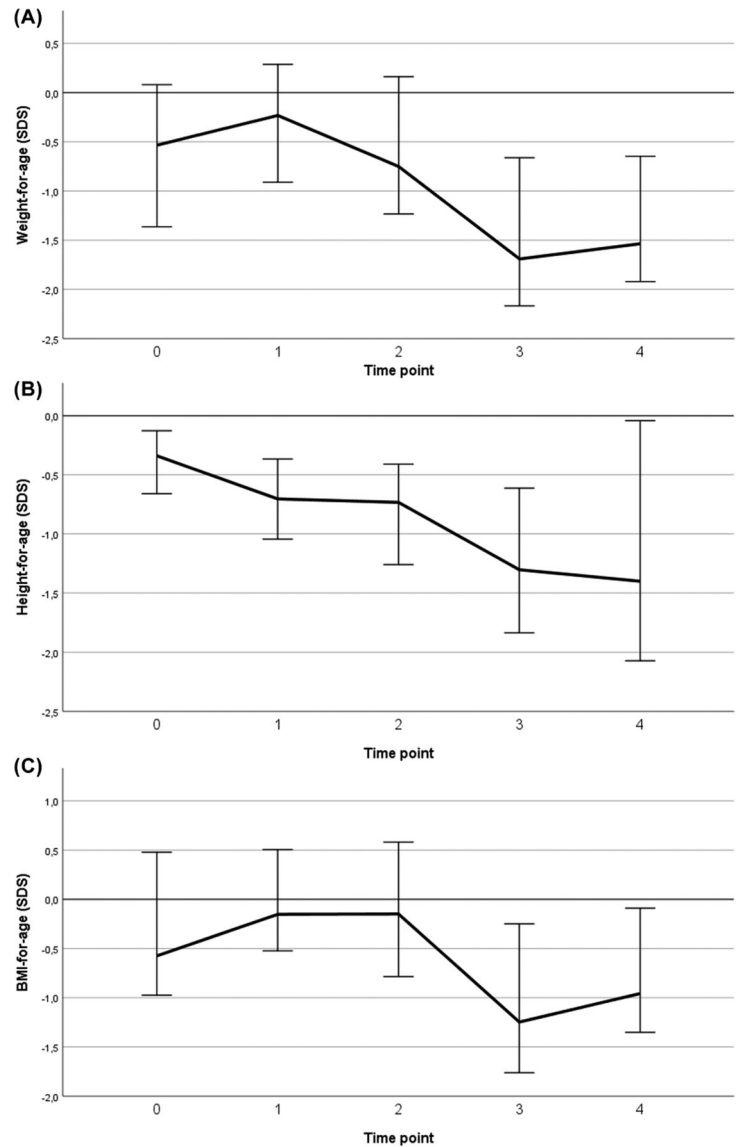


FIGURE 2 Example of analyzed CT scans of a patient with neuroblastoma. Red = skeletal muscle; green = intermuscular adipose tissue (IMAT); yellow = visceral subcutaneous adipose tissue (VAT); blue = subcutaneous adipose tissue (SAT). ASCT, autologous stem cell transplantation

The increase in body fat is in line with a longitudinal study in 133 newly diagnosed pediatric patients with a hematological, solid, or brain malignancy,⁸ in which BIA was used to assess whole-body FM.⁸ BIA provides only information regarding total FM, whereas a distinction between different types of adipose tissue can be made by using CT. A study in 39 pediatric patients with a solid tumor used CT to assess body composition and found a trend toward an increased VAT at the T12-L1 level 6–14 weeks after diagnosis ($p = .052$).¹² Although a strong correlation between body composition variables at L3 and T12-L1 was found ($r = .93-.98$), no change in VAT was found at the L3 level ($N = 22$). Furthermore, no changes in SAT were found in that study. Possibly, significant increases in VAT and SAT were not yet

reached just after 6–14 weeks of follow-up, whereas these increases were more distinct after six cycles of chemotherapy in the present study. Moreover, the patients with neuroblastoma in the present study were more likely to have significant metastatic disease than the other study population including children with rhabdomyosarcoma, Wilms tumor, Ewing sarcoma or osteosarcoma, which may explain the contrasting findings. Nevertheless, more research with a larger sample size and a longer follow-up time is needed to confirm this. A longer follow-up time is needed to understand the timeframe of posttreatment changes in body composition and the relation with long-term consequences. These data can be used to investigate the relation between body composition and survival. A retrospective study of 129

FIGURE 3 Changes in anthropometrics (median [95% CI]) of patients with neuroblastoma over time. T0: $N = 27$; T1: $N = 24$; T2: $N = 24$; T3: $N = 14$; T4: $N = 10$. SDS, standard deviation score. (A) Weight-for-age; $p = .001$. (B) Height-for-age; $p < .001$. (C) BMI-for-age; $p = .001$. Error bars: 95% CI



patients with neuroblastoma showed that disease stage at diagnosis was a predictor for survival but no relation between BMI and survival was found.¹⁵ Whether skeletal muscle and different types of adipose tissue of patients with neuroblastoma play a role in the survival of these patients remains to be elucidated. Moreover, a larger sample size will enable subanalyses to investigate possible associations of body composition changes with treatment response.

Although skeletal muscle mass changed significantly over time, the differences were small. Moreover, minor changes of IMAT and skeletal muscle density were observed, suggesting little change in muscle quality. This study suggests that cancer treatment seems not to have much impact on the skeletal muscle mass and muscle quality of patients with neuroblastoma. In accordance with the findings regarding muscle quality, the previously mentioned study in pediatric patients with a solid tumor using CT to assess body composition found no changes in IMAT and skeletal muscle density.¹² In contrast, that study found a decrease

in skeletal muscle both at the level of T12-L1 and L3. The older patients had more muscle loss compared to the younger patients. The contradictory finding regarding muscle loss may be explained by the difference in age between that study (median age 11.0 years) and the present study (median age 3.0 years). Another explanation may be that the muscle mass was already low before diagnosis and remained low during treatment in the patients with high-risk neuroblastoma of the present study. Therefore, a possible decrease in muscle mass before diagnosis may have been missed. The previously mentioned study in 133 children with cancer using BIA for body composition assessment found a low FFM at diagnosis, which remained low during treatment.⁸ Unfortunately, suitable reference data for body composition using CT are lacking for the pediatric population precluding classification of patients with a low muscle mass (or high FM).

The SDSs for weight-for-age and BMI-for-age were closest to zero early during treatment, reflecting a higher similarity with age- and

gender-matched healthy children. These SDSs suggest a good nutritional status of the patients with neuroblastoma. However, the assessment of body composition using CT revealed that the SDSs close to zero were mainly explained by an increase in FM. Although more research is needed regarding the consequences of the rapid increase of VAT and SAT, these results suggest that interventions to prevent these changes in body composition have to start early, preferably at the start of the treatment. Promoting a healthy lifestyle with attention to both exercise and diet can be an effective intervention strategy to reduce the short- and long-term complications of childhood cancer treatment. Lifestyle interventions introduced early during childhood cancer treatment are both safe and feasible,¹⁶ but further research is needed to investigate the effect of combined diet and exercise interventions on body composition in children with cancer and the sustainability of intervention effects over long-term.

Body composition analysis in the pediatric population is complicated due to the rapid period of growth. To account for differences in height within and between patients, the cross-sectional areas of skeletal muscle, IMAT, VAT, and SAT were divided by height in squared meters. This way of correction is comparable with body composition analysis in adult populations.¹⁰ However, correlations of body composition with height may vary by age and gender during childhood,¹⁷ making changes of body composition in children over time difficult to interpret. Therefore, the correction of the division by height in squared meters might not be optimal for the pediatric population, but the best available option to adjust for changes in body composition due to changes in age and height over time, and to longitudinally investigate the effect of cancer and/or treatment on body composition. Nevertheless, the influence of growth on the changes in body composition over time was probably minimal in the present study, as changes in body composition over time without adjustment for height showed comparable results. This may be explained by the stunted growth of the patients with neuroblastoma.

A strength of the present study is the use of low-dose CT scans, which are routinely used at diagnosis and during follow-up in clinical practice, to assess skeletal muscle and different types of adipose tissue. This method has rarely been used to measure body composition in children with cancer. CT scans provide detailed information regarding body composition as a reflection of the nutritional status of children with cancer. Moreover, patients do not have to undergo additional measurements, which is of great advantage in pediatric care, especially for young children. Another strength is the analysis of multiple scans per patient, providing data of body composition of patients with neuroblastoma throughout the whole treatment period. A limitation of the study is the lack of suitable reference data, precluding classification of patients with a low muscle mass or high FM not yet possible. The current lack of reference data limits the application of CT analysis in clinical practice. Furthermore, data were not available at all time points for all patients. Moreover, data on dietary intake and nutritional support were unavailable for this retrospective study.

To conclude, the use of CT scans obtained during standard care provides insight into the direction and timing of changes in skeletal muscle

and different types of adipose tissue. Future research is needed regarding the consequences of the rapid increase of VAT and SAT early during treatment.

ACKNOWLEDGMENT

We would like to thank Harm van Baar for his insightful suggestions and careful reading of the manuscript.

CONFLICT OF INTEREST

The authors declare that there is no conflict of interest.

AUTHOR CONTRIBUTIONS

All authors read and approved the final version of the manuscript.

DATA AVAILABILITY STATEMENT

Data that support the findings of this study are available from the corresponding author upon reasonable request.

REFERENCES

1. Andrassy RJ, Chwals WJ. Nutritional support of the pediatric oncology patient. *Nutrition*. 1998;14:124-129.
2. Brinksma A, Sanderma R, Roodbol PF, et al. Malnutrition is associated with worse health-related quality of life in children with cancer. *Support Care Cancer*. 2015;23:3043-3052.
3. Loeffen EA, Brinksma A, Miedema KG, de Bock GH, Tissing WJ. Clinical implications of malnutrition in childhood cancer patients - infections and mortality. *Support Care Cancer*. 2015;23:143-150.
4. Bizzarri C, Bottaro G, Pinto RM, Cappa M. Metabolic syndrome and diabetes mellitus in childhood cancer survivors. *Pediatr Endocrinol Rev*. 2014;11:365-373.
5. Carneiro Teixeira JF, Maia-Lemos PDS, Cypriano MDS, Pellegrini Pisani L. Obesity in survivors of childhood cancer: a review. *Pediatr Endocrinol Rev*. 2017;15:33-39.
6. Scholz-Kreisel P, Spix C, Blettner M, et al. Prevalence of cardiovascular late sequelae in long-term survivors of childhood cancer: a systematic review and meta-analysis. *Pediatr Blood Cancer*. 2017;64(7):e26428.
7. Ethier MC, Alexander S, Ablu O, Green G, Lam R, Sung L. Association between obesity at diagnosis and weight change during induction and survival in pediatric acute lymphoblastic leukemia. *Leuk Lymphoma*. 2012;53:1677-1681.
8. Brinksma A, Roodbol PF, Sulkers E, et al. Changes in nutritional status in childhood cancer patients: a prospective cohort study. *Clin Nutr*. 2015;34:66-73.
9. Montague CT, O'Rahilly S. The perils of portliness: causes and consequences of visceral adiposity. *Diabetes*. 2000;49:883-888.
10. Mourtzakis M, Prado CM, Lieffers JR, Reiman T, McCargar LJ, Baracos VE. A practical and precise approach to quantification of body composition in cancer patients using computed tomography images acquired during routine care. *Appl Physiol Nutr Metab*. 2008;33:997-1006.
11. Shen W, Punyanitya M, Wang Z, et al. Total body skeletal muscle and adipose tissue volumes: estimation from a single abdominal cross-sectional image. *J Appl Physiol (1985)*. 2004;97:2333-2338.
12. Joffe L, Shen W, Shadid G, Jin Z, Ladas EJ. Skeletal muscle and adipose tissue changes in the first phase of treatment of pediatric solid tumors. *Cancer Med*. 2021;10:15-22.

13. Roede MJ, Van Wieringen JC. *Growth Diagrams 1980: Netherlands Third Nation-Wide Survey*. Tijl tijdschriften; 1985.
14. Schönbeck Y, van Buuren S. *Resultaten Vijfde Landelijke Groeistudie*. TNO; 2010.
15. Small AG, Thwe LM, Byrne JA, et al. Neuroblastoma, body mass index, and survival: a retrospective analysis. *Medicine (Baltimore)*. 2015;94:e713.
16. Zhang FF, Kelly MJ, Must A. Early nutrition and physical activity interventions in childhood cancer survivors. *Curr Obes Rep*. 2017;6:168-177.
17. Wang Z, Zhang J, Ying Z, Heymsfield SB. New insights into scaling of fat-free mass to height across children and adults. *Am J Hum Biol*. 2012;24:648-653.

SUPPORTING INFORMATION

Additional supporting information may be found in the online version of the article at the publisher's website.

How to cite this article: Ijpma I, Lequin MH, Nieuvelstein RAJ, Fiocco M, Tissing WJE. Body composition of patients with neuroblastoma using computed tomography. *Pediatr Blood Cancer*. 2021;68:e29337 <https://doi.org/10.1002/pbc.29337>.