

University of Groningen

## Aesthetic Outcomes of Perineal Reconstruction with the Lotus Petal Flap

Hellinga, Joke; Fleer, Joke; van der Lei, Berend; Werker, Paul M N; van Etten, Boudewijn; Stenekes, Martin W

*Published in:*  
Plastic and Reconstructive Surgery. Global Open

*DOI:*  
[10.1097/GOX.0000000000003621](https://doi.org/10.1097/GOX.0000000000003621)

**IMPORTANT NOTE: You are advised to consult the publisher's version (publisher's PDF) if you wish to cite from it. Please check the document version below.**

*Document Version*  
Publisher's PDF, also known as Version of record

*Publication date:*  
2021

[Link to publication in University of Groningen/UMCG research database](#)

*Citation for published version (APA):*

Hellinga, J., Fleer, J., van der Lei, B., Werker, P. M. N., van Etten, B., & Stenekes, M. W. (2021). Aesthetic Outcomes of Perineal Reconstruction with the Lotus Petal Flap. *Plastic and Reconstructive Surgery. Global Open*, 9(6), [3621]. <https://doi.org/10.1097/GOX.0000000000003621>

### Copyright

Other than for strictly personal use, it is not permitted to download or to forward/distribute the text or part of it without the consent of the author(s) and/or copyright holder(s), unless the work is under an open content license (like Creative Commons).

The publication may also be distributed here under the terms of Article 25fa of the Dutch Copyright Act, indicated by the "Taverne" license. More information can be found on the University of Groningen website: <https://www.rug.nl/library/open-access/self-archiving-pure/taverne-amendment>.

### Take-down policy

If you believe that this document breaches copyright please contact us providing details, and we will remove access to the work immediately and investigate your claim.

*Downloaded from the University of Groningen/UMCG research database (Pure): <http://www.rug.nl/research/portal>. For technical reasons the number of authors shown on this cover page is limited to 10 maximum.*

# Aesthetic Outcomes of Perineal Reconstruction with the Lotus Petal Flap

Joke Hellinga, MD\*

Joke Fleer, PhD†

Berend van der Lei, MD, PhD\*

Paul M.N. Werker, MD, PhD\*

Boudewijn van Etten, MD, PhD‡

Martin W. Stenekes, MD, PhD\*

**Background:** The lotus petal flap can be applied for reconstruction of extensive defects in the vulvoperineal area. Studies on aesthetic outcomes are lacking. This study aimed to fill this gap.

**Methods:** All patients who underwent lotus petal flap reconstruction between October 2011 and December 2015 were asked permission to have their photographs used. Two questionnaires were used: (1) the Strasser score to assess the overall aesthetic results (range 0–15) and (2) the Patient and Observer Scar Assessment Scale (POSAS; range 6–60). Six plastic surgeons and 6 laymen filled in the Strasser score and the Observer scale of the POSAS. Patients filled in the Strasser score, the Patient scale of the POSAS and scored their overall satisfaction with the aesthetic results on a Likert scale (0–10).

**Results:** The photographs of 11 patients were included. The median Strasser score of all observers of 11.9 (range 0.0–75.0) indicated a mediocre aesthetic result. The median total POSAS score of 15.6 (range 6.0–41.0) indicated an aesthetically acceptable scar. Strasser and POSAS scores of the plastic surgeons and laymen did not differ significantly from the patients' scores. The patient satisfaction score with the aesthetic result was a median of 6.0 of 10.

**Conclusions:** The findings indicate that, overall, patients were moderately satisfied with the aesthetic results of their lotus petal flap reconstructions, as were the plastic surgeons and laymen. For clinical practice, it is important that the plastic surgeon manages expectations carefully before surgery, as it is possible that patients might experience a rather low aesthetic outcome after perineal reconstruction. (*Plast Reconstr Surg Glob Open* 2021;9:e3621; doi: [10.1097/GOX.0000000000003621](https://doi.org/10.1097/GOX.0000000000003621); Published online 10 June 2021.)

## INTRODUCTION

The lotus petal flap (LPF) is our workhorse for the reconstruction of vulvar and perineal defects, especially after extensive resection (ie, abdominoperineal excision) of malignant lesions in the perineal region.<sup>1,2</sup> The LPF is a fasciocutaneous flap based on the rich network of perforating vessels of the internal and external pudendal arteries. The name is derived from the fact

that all different options for petals together resemble the petals of the lotus flower.<sup>1,2</sup> Figure 1 shows the operative steps of perineal reconstruction with the LPF technique. Over the last decades, resections in this area seem to have become more extensive and often include resection of part of the levator ani muscle or part of the perineum and vagina. This has significantly improved the oncological outcomes, as indicated by lower local recurrence rates.<sup>3,4</sup> Because of the improved oncological outcomes, along with the earlier diagnosis, patients after treatment of malignant lesions in the perineal area live longer.

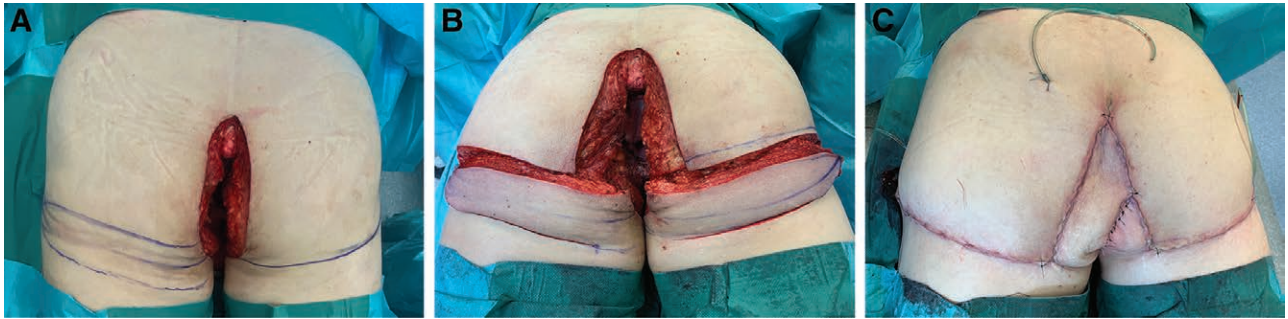
Insights regarding the impact of LPF reconstruction on quality of life are crucial to optimize implementation of the reconstruction technique, but data concerning this aspect are scarce.<sup>5</sup> Recently, the first results on quality of life and sexual functioning following vulvar reconstruction with the LPF technique were published by our group.<sup>6</sup> This study showed a lower quality of life following reconstruction compared with healthy women and, although patients experienced more pain during

From the \*Department of Plastic Surgery, University Medical Center Groningen, University of Groningen, Groningen, the Netherlands; †Department of Health Psychology, University Medical Center Groningen, University of Groningen, Groningen, the Netherlands; ‡Department of Surgical Oncology, University Medical Center Groningen, University of Groningen, Groningen, the Netherlands. Received for publication February 12, 2021; accepted April 13, 2021.

Copyright © 2021 The Authors. Published by Wolters Kluwer Health, Inc. on behalf of The American Society of Plastic Surgeons. This is an open-access article distributed under the terms of the [Creative Commons Attribution-Non Commercial-No Derivatives License 4.0 \(CCBY-NC-ND\)](https://creativecommons.org/licenses/by-nc-nd/4.0/), where it is permissible to download and share the work provided it is properly cited. The work cannot be changed in any way or used commercially without permission from the journal.

DOI: [10.1097/GOX.0000000000003621](https://doi.org/10.1097/GOX.0000000000003621)

**Disclosure:** All the authors have no financial interest in relation to the content of this article.



**Fig. 1.** Photographs of a 56-year-old male patient on the operating table in prone position. A, The perineal defect following resection of a perineal tumor with the lotus petal flap (LPF) marked in the left gluteal fold and the gluteal fold marked on the right side. B, Harvest of bilateral LPFs. C, Direct postreconstruction result. Please note that 1 flap was partially deepithelialized.

sexual activity following reconstruction, they reported to be satisfied with their sexual functioning. Another study of our team on perineal reconstruction with the LPF technique indicated that the quality of life of this patient population was not impaired by reconstruction with the LPF, but their sexual and physical functioning were.<sup>7</sup> Interestingly, even though sexual and physical functioning scored lower, this did not influence the general patient satisfaction with their LPF reconstruction. The ideal perineal reconstruction, however, should not only result in a functionally satisfying result, but should also be aesthetically satisfying.<sup>8</sup> In reconstructive surgery, the aesthetic result is an important aspect in patient satisfaction and in improving the self-image of the patient. Moreover, a good aesthetic result can positively influence the quality of life.<sup>9,10</sup> Providing information on the aesthetic result and its possible influence on patient satisfaction and self-image are important when obtaining informed consent in the preoperative setting.

The aim of this study was to investigate the aesthetic outcomes following reconstruction with the LPF from the perspective of the patients, laymen, and plastic surgeons and to investigate patient satisfaction with the aesthetic outcomes. To our knowledge, we are the first group to report data regarding the aesthetic outcome following reconstruction of the perineal area with the LPF technique. Because no specific scoring instruments are available for scoring of the aesthetic results in the perineal area, we used general scoring questionnaires to study the aesthetic outcomes and patient satisfaction. Next to evaluation of the aesthetic results after LPF reconstruction in the perineal region judged by the patients, we also evaluated the aesthetic outcomes judged by plastic surgeons and laymen. The plastic surgeons use their professional view to judge the aesthetic results. Their experience is used during preoperative counseling; therefore, it is important for plastic surgeons to know how their own opinion relates to the patients' opinion on the aesthetic outcome. The laymen have the most objective opinion on the aesthetic outcomes; they are not biased by their personal experience or their professional experience and knowledge, as such giving the best impression of how the general population observes the aesthetic outcomes of LPF reconstruction.

## METHODS

### Participants and Procedure

Patients who were eligible as subjects for this cross-sectional study on aesthetic outcomes underwent an extensive perineal resection necessitating an LPF procedure for reconstruction between October 2011 and December 2015 at the University Medical Center Groningen (UMCG). Exclusion criteria were: no knowledge of the Dutch language, cognitive impairment, and known recurrence of the disease. Participants were sent an information letter, an informed consent form, and the questionnaires. They were also invited to have photographs taken of their LPF reconstruction by our medical photographer (Fig. 2). Only patients who gave written informed consent were included in the study.

Six plastic surgeons from the UMCG (3 women and 3 men; mean age of 44.2 years (SD 7.1)), experienced in the LPF procedure, were asked to give their opinion on the aesthetic results. These plastic surgeons also performed the LPF procedure of the patients in the patient group. Six nonmedically trained persons, matched on gender and age (mean age of 44.0 years (SD 12.1)) with the plastic surgeons, were asked to participate in the layman group. All plastic surgeons and laymen gave oral informed consent. The medical ethical committee of the UMCG decided that formal ethical approval for this study was unnecessary (M17.206526).

Six photographs of each patient were taken while standing: a frontal view, a back view, a view of each side, a lithotomy position view, and a standing view while bending over (Fig. 3). The photographs were anonymized and collated into a powerpoint presentation in random order per patient to be assessed by the plastic surgeon and layman group. Every plastic surgeon and layman scored every patient based on the six photographs per patient. A participant in the patients group only judged him or herself (without the photographs).

### Scales

An overview of the assessment tools is provided in Figure 2. The aesthetic results of the reconstruction were objectified using the Strasser questionnaire and the Patient and Observer Scar Assessment Scale (POSAS).<sup>11,12</sup>

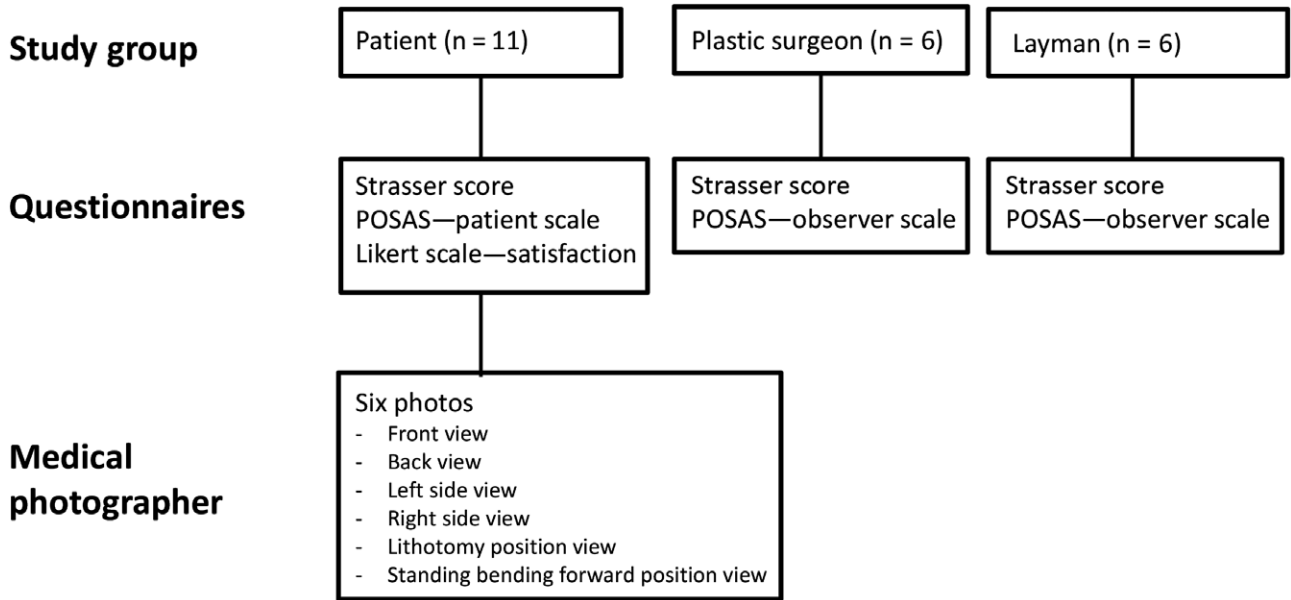


Fig. 2. Overview of assessment tools.

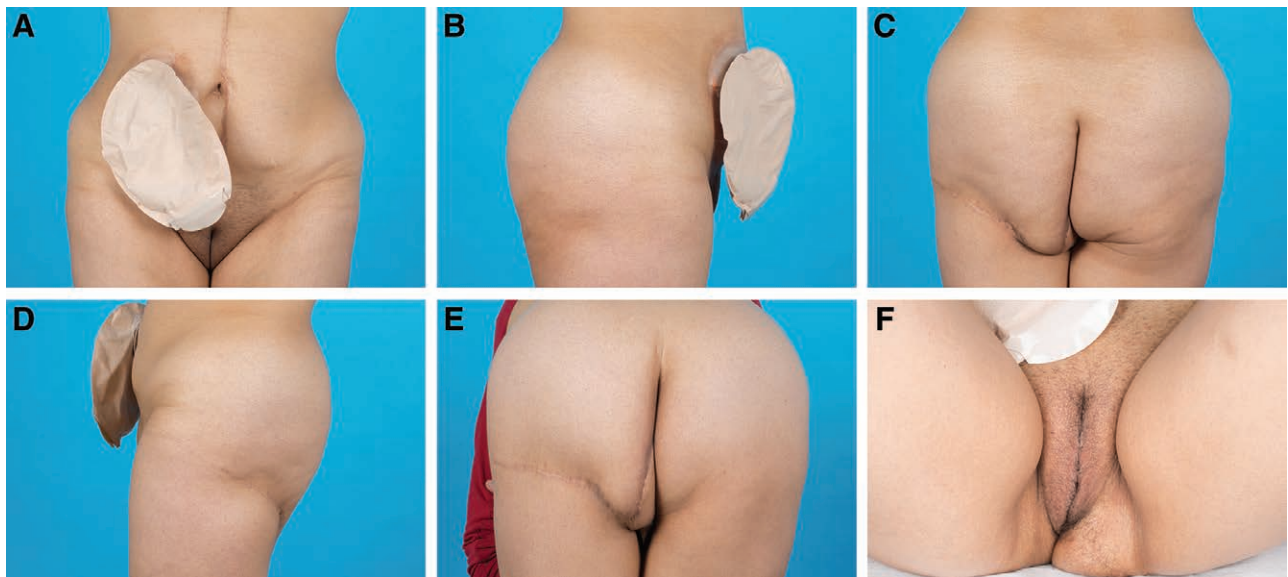


Fig. 3. Photographs of a patient 41 months postoperatively. A, Frontal view. B, Right side view. C, Back view. D, left side view. E, Standing view while bending over. F, lithotomy position view.

The Strasser questionnaire was used to grade the aesthetic surgical results based on 5 flaws or deficiencies: malposition, distortion, asymmetry, contour deformity, and the scar. They can each be scored as “perfect” (0 points), “noticeable” (1 point), “obvious” (5 points), or “obvious and deforming” (15 points). The total score is the sum of all 5 scores. Zero points means an excellent aesthetic result, 1–4 points is a good aesthetic result, 5–14 points a mediocre aesthetic result, and 15 points and up is a poor aesthetic result.

POSAS was used to assess the aesthetic result of the scars resulting from reconstruction with the LPF. The POSAS has 2 parts: a Patient scale and an Observer scale.

The Patient scale has 6 items: pain, itching, color, pliability, thickness, and relief of the scar. The Observer scale also has 6 items: vascularity, pigmentation, pliability, thickness, relief, and surface of the scar. Each item is scored from 1 (normal skin) to 10 (worst imaginable scar). The total score of all 6 items together ranges from 6 to 60. The overall opinion is scored with an item ranging from 1 to 10. A low score indicates a scar result close to normal skin. No difference is made between the scar of the donor site and acceptor site.

The overall patient satisfaction with the aesthetic result of their LPF reconstruction was measured using a 10-point Likert scale ranging from low satisfaction (0) to

high satisfaction (10). Data on patient demographics and reconstruction characteristics were collected using their medical files.

#### Data Analysis

Data analysis was performed using IBM Statistical Package for the Social Sciences, version 23 (IBM Corp., Armonk, N.Y.).

Categorical data were described as number (%), and continuous data as mean (SD) in case of normal distribution and median (range) for non-normal distributed data. Results of the questionnaires and the Likert scale were described as median (range), because of the small sample size. In case of 1 missing item score, the mean imputation method was applied to calculate the total score. For comparison of the results of the questionnaires between the patient, plastic surgeon, and layman group the Kruskal Wallis test was applied. The influence of the aesthetic outcome, scored on the questionnaires, on the satisfaction with the aesthetic result, scored on the Likert scale, was tested with the Spearman correlation coefficient.  $P < 0.05$  was considered significant.

## RESULTS

#### Participant Characteristics

Between October 2011 and December 2015, 35 patients underwent perineal reconstruction with the LPF at the UMCG. Eleven patients had died at the time of this study. Twenty-four questionnaires were sent out, and 21 patients responded (87.5%). Six patients did not want to participate in the study, 1 patient did not understand the Dutch language, 2 patients had a known recurrence of the disease, and 1 patient was unable to fill out the questionnaire due to cognitive impairment. The remaining eleven patients were included in this study, 3 women and 8 men (Fig. 4). The mean age at time of study was 56.6 years old (SD 13.7) and the median time from reconstruction was 2.6 years (range 1.4–5.4). Most patients ( $n = 9$ ; 81.8%) had a rectal carcinoma, and the other 2 (18.2%) an anal carcinoma.

All patients but 1 (90.9%) received neoadjuvant chemoradiotherapy. This patient (9.1%) received postoperative radiotherapy only. A biological mesh was applied to reconstruct the pelvic floor in 8 (72.7%) patients, and an omentoplasty in 10 (90.9%) patients. Reconstruction was performed with a unilateral (54.5%) or bilateral (45.5%) LPF. No comparison analysis is performed between the unilateral and bilateral group because of the small sample size. Complications of the donor site occurred in 5 (45.5%) patients. These were all minor complications (Clavien Dindo grade I or II).<sup>13</sup> Complications of the recipient site occurred in 7 (63.6%) patients. In 5 (45.5%) patients, these were minor complications (Clavien Dindo grade I), but in 2 (18.2%) patients major complications (Clavien Dindo grade IIIb), necessitating surgical debridement in the OR.

#### Aesthetic Result Scored by the Strasser Questionnaire

The patient, the plastic surgeon, and the layman group had a median score of respectively 7 (0–75), 12.2 (8–32),

and 14.7 (10–23). The scores in all 3 groups were categorized as a mediocre result. The results per case are shown in Table 1. At groups level, there were no significant differences between the scores of the 3 groups ( $P = 0.325$ ).

#### Result of the POSAS Questionnaire

The patient group scored a median total score of 14 (6–41) of 60. On the Observer scale of the POSAS questionnaire, the plastic surgeon and layman group scored a median total score of respectively 13.6 (10–22) and 19.5 (12–25) of 60. Those results indicate a scar “relatively close to normal skin,” since a score of 6 of 60 is seen as normal skin. The results of each case are shown in Table 2. There were no significant differences between the 3 groups concerning the total scores of the POSAS questionnaire ( $P = 0.506$ ).

Besides the total score, the overall opinion item score of the POSAS questionnaire was given by all 3 groups. On the Patient scale of the POSAS questionnaire, the patient group gave their overall appearance a median score of 5 (1–8) of 10. On the Observer scale of the POSAS questionnaire, the plastic surgeon and layman group gave the overall appearance a median score of respectively 2.5 (2–3) and 3.6 (2–4) out of 10. The results of each case are shown in Table 3. Although the patient overall appearance score was higher than the score of the plastic surgeon and layman group, this difference was not significant ( $P = 0.286$ ).

#### Patient Satisfaction with the Aesthetic Result

The patients' satisfaction with the aesthetic result was scored using a Likert scale. The patient group scored a median of 6.0 (range 0.5–10.0) of 10. There was no significant correlation between the patient satisfaction and the patient score on the Strasser score ( $r = -0.255$ ;  $P = 0.449$ ), POSAS total score ( $r = -0.213$ ;  $P = 0.529$ ), and the POSAS overall opinion item score ( $r = -0.333$ ;  $P = 0.316$ ), indicating that patient satisfaction with the aesthetic result was independent of the grading of the aesthetic surgical result and the scar.

## DISCUSSION

This study evaluated the aesthetic outcome of 11 major perineal reconstructions with the LPF flap, seen through the eyes of 3 stakeholders: the patient, the plastic surgeon, and the layman. The aesthetic surgical result as judged by the patients using Strasser was mediocre; however, the aesthetic result of specifically the scars using POSAS was “relatively close to normal skin.” Also, the results clearly demonstrate a moderate overall patient satisfaction, indicating that the patient satisfaction with the aesthetic result does not depend on the grading of the aesthetic surgical result. Patients' scores of both questionnaires did not differ significantly from those of the plastic surgeons and laymen, indicating that the opinion of all groups are comparable.

To date, only 1 study reported results on the aesthetic outcomes following perineal reconstruction, for which the inferior gluteal artery musculocutaneous transposition

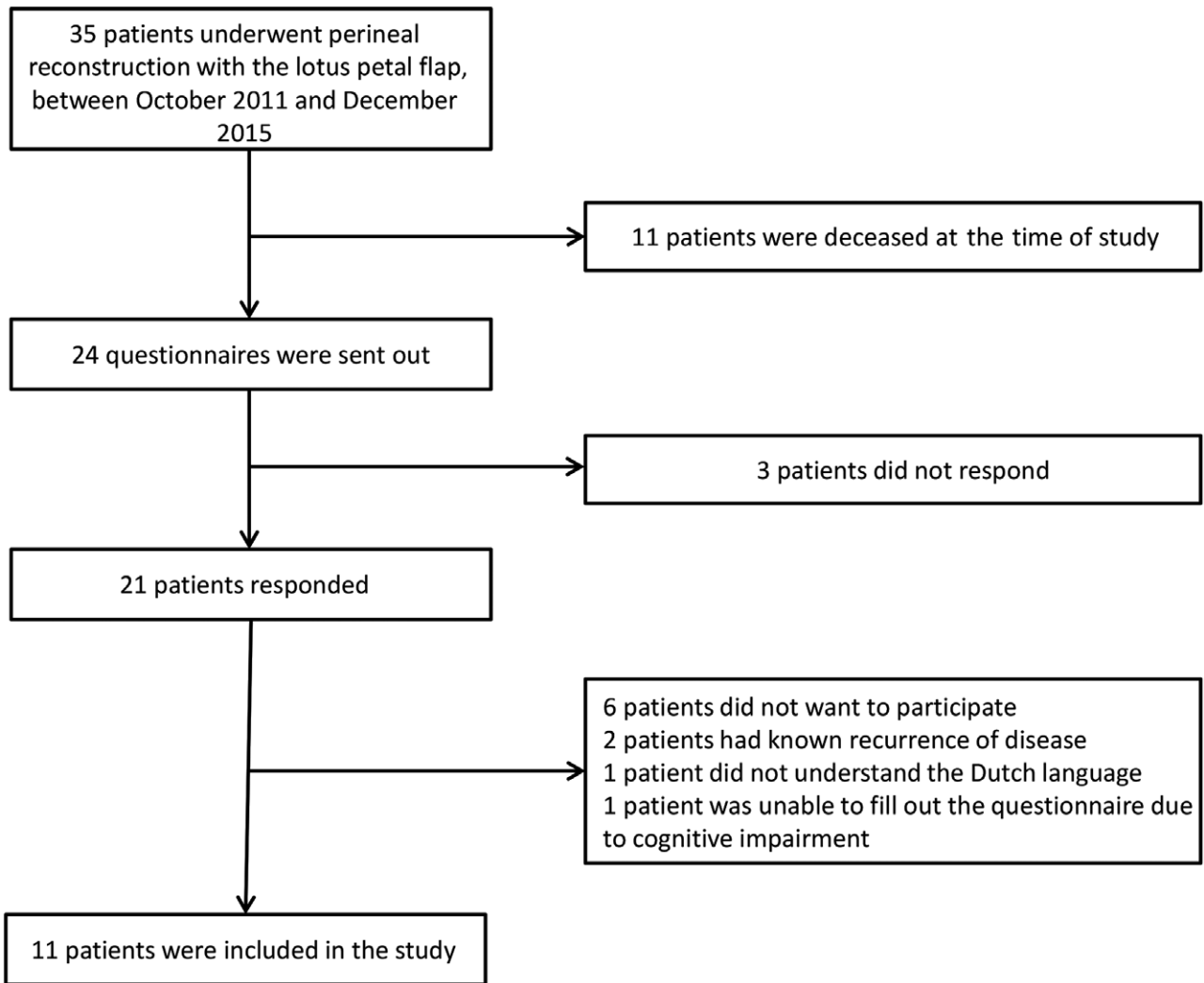


Fig. 4. Flow chart of the study population.

Table 1. Strasser Scores per Group

Case No.	Patient		Surgeon		Layman	
	Score	Category	Median (Range)	Category	Median (Range)	Category
1	0	Excellent	19.0 (4–31)	Poor	9.0 (3–17)	Mediocre
2	2	Good	10.5 (1–25)	Mediocre	17.0 (9–37)	Poor
3	5	Mediocre	31.5 (8–61)	Poor	19.0 (4–31)	Poor
4	7	Mediocre	18.5 (13–55)	Poor	30.0 (8–55)	Poor
5	75	Poor	13.0 (3–55)	Mediocre	20.5 (9–55)	Poor
6	9	Mediocre	5.0 (1–17)	Mediocre	6.0 (4–41)	Mediocre
7	25	Poor	15.0 (4–35)	Poor	19.0 (2–61)	Poor
8	16	Poor	15.0 (5–45)	Poor	13.0 (2–21)	Mediocre
9	31	Poor	9.0 (3–21)	Mediocre	5.0 (4–17)	Mediocre
10	1	Good	2.5 (0–21)	Good	5.0 (0–21)	Mediocre
11	5	Mediocre	6.0 (2–45)	Mediocre	7.0 (3–31)	Mediocre
Total	7 (0–75)*	Mediocre	12.2 (8–32)	Mediocre	14.7 (10–23)	Mediocre

\*Median (range).

A low score indicates an excellent aesthetic surgical result.

Categories: 0 points: excellent result; 1–4 points: good result; 5–14 points: mediocre result; 15 points and up: poor result.

flap was applied. In this study, patients were asked for their opinion about the aesthetic results of their reconstruction. Upon subjective questioning, they rated their outcomes as good.<sup>3</sup> It should be noted that in literature the POSAS

questionnaire has mostly been applied for the evaluation of smaller reconstructions. The Strasser questionnaire is mainly applied following facial and breast reconstruction.<sup>14,15</sup> The extent of the defect, in which LPF is applied,

**Table 2. POSAS Total Score per Group**

Case No.	Patient	Surgeon	Layman
	Score	Median (Range)	Median (Range)
1	6	14.5 (13–17)	20.5 (11–27)
2	14	17.0 (13–37)	25.5 (18–33)
3	10	12.0 (9–20)	15.5 (7–31)
4	22	14.0 (7–15)	22.0 (7–35)
5	26	19.0 (9–34)	34.5 (17–40)
6	12	9.5 (6–12)	10.0 (6–20)
7	30	15.5 (11–24)	14.0 (12–27)
8	20	13.0 (9–17)	16.5 (12–27)
9	6	14.0 (6–48)	15.5 (12–25)
10	8	14.0 (6–32)	17.0 (6–31)
11	41	8.5 (6–12)	12.5 (6–27)
Total	14 (6–41)*	13.6 (10–22)	19.5 (12–25)

\*Median (range).

A lower score indicates a result close to normal skin

**Table 3. POSAS Overall Opinion Item Score Per Group**

Case No.	Patient	Surgeon	Layman
	Score	Median (Range)	Median (Range)
1	2	3.0 (1–3)	3.5 (2–7)
2	3	3.0 (2–4)	5.0 (3–7)
3	5	2.0 (1–4)	4.0 (1–7)
4	8	2.5 (2–4)	4.5 (1–6)
5	8	4.0 (2–6)	6.0 (3–7)
6	6	2.0 (1–2)	1.5 (1–3)
7	5	2.0 (2–3)	2.5 (2–5)
8	1	2.0 (2–3)	3.0 (2–5)
9	2	2.5 (1–7)	2.5 (2–4)
10	1	2.5 (1–5)	2.5 (1–5)
11	7	1.5 (1–2)	2.0 (1–4)
Total	5 (1–8)*	2.5 (2–3)	3.6 (2–4)

\*Median (range).

A lower score indicates a result close to normal skin.

is much larger. A dedicated validated questionnaire for aesthetic outcome following extensive reconstruction, as is the case with an LPF reconstruction, unfortunately is currently not available. Besides, earlier studies also showed that, although the Strasser questionnaire was the best available option, it is, especially in larger reconstructions, unable to discriminate between clinically clearly different aesthetic results. The scoring system is very stringent and a small flaw already leads to a poor or mediocre aesthetic result.<sup>16</sup>

Patient satisfaction is an important factor for determining treatment success. Creating realistic expectations beforehand is of great importance for a high satisfaction afterwards.<sup>8,17</sup> Only studying the opinion of surgeons regarding the aesthetic outcome of a reconstruction will ignore aspects that are of importance to patients.<sup>17</sup> The patient’s opinion not only extends beyond cosmetics, the experience during the whole treatment influences their satisfaction.<sup>18</sup> Despite the rather mediocre aesthetic surgical result following LPF reconstruction as judged by all assessors using the questionnaires, it stands that most patients were overall moderately satisfied with the aesthetic outcome. The patient’s satisfaction with the aesthetic outcome seemed to be independent of the aesthetic surgical result as scored by the questionnaires. The Strasser and POSAS questionnaires are mostly used following smaller

reconstructions, in which small flaws may be less conspicuous, while a major resection and a flap by definition causes a major flaw in aesthetic result, which will significantly lower the score of the questionnaire. Patients probably take the extent of the reconstruction into account while grading their satisfaction with the aesthetic result. This could be the reason that the patients’ satisfaction with the aesthetic result is higher compared with the scores on the questionnaires.

Our study did not find a significant difference between the scores regarding the aesthetic outcomes of plastic surgeons and the scores of the patients, probably due to the small simple size. In 2 previous studies, patients and surgeons were asked to score their satisfaction with the aesthetic outcome of respectively nasal and breast reconstruction in a slightly larger study population. Both studies showed that patients were more satisfied with the aesthetic outcomes when compared with the surgeons.<sup>8,17</sup> In our study we did not score the overall satisfaction of the plastic surgeons with the aesthetic outcomes, but we rather asked them to evaluate the aesthetic surgical result and the scars of the LPF reconstruction using the questionnaires. This evaluation does not reflect an overall satisfaction with the aesthetic outcome. This is affirmed by the result that we found no significant correlation between patient satisfaction and the scores of the patients on the questionnaires.

Patients have to deal with the reactions of their (intimate) environment regarding the aesthetic outcome of plastic surgery.<sup>8</sup> In general, laymen tend to be more positive about the aesthetic outcome compared with patients and surgeons.<sup>19,20</sup> In our study, however, this difference was not found to be statistically significant possibly due to our small sample size. Other than the facial and breast reconstruction in previous studies, the location of the reconstruction site in our study has a limited visibility. The intimate location of the reconstruction site or the extensiveness of the reconstruction could also play a role in the judgment of the laymen.

**Strength and Limitations**

A strength of this pilot study is the provision of a structured impression on the aesthetic outcomes following LPF reconstruction from the point of view of the patients, plastic surgeons and laymen. Aesthetic outcomes after LPF reconstructions of the perineal area have never been reported before. An important limitation of the study is that the questionnaires we used were not specifically tailored for evaluation after perineal reconstruction, but better alternatives are currently lacking. Another shortcoming of this study is the limited number of patients due to the low incidence of the procedure and the low survival rate in our patient group because of the extensiveness of the disease. This may also lead to the broad range seen in the results of the questionnaires and the Likert scale. Lastly, the plastic surgeons were all surgeons performing the LPF procedure themselves. This may have limited their objectiveness; however, the advantage is that they were all familiar with the procedure itself and the possible reconstructive outcomes.

## CONCLUSIONS

This study illustrates that patients score the aesthetic surgical results of their perineal reconstruction with the LPF as rather low, but the scars as fairly good. However, those results are independent of the overall patient satisfaction, which is considered reasonable following LPF reconstruction. No differences between the grading of the aesthetic outcome among patients, plastic surgeons, and laymen were found.

Further studies should focus on developing a better standardized questionnaire for evaluating the aesthetic outcome after perineal reconstruction. This will enable us to compare the results of different reconstruction techniques and possibly give better insight regarding the experienced and observed aesthetic outcomes. For clinical practice, it is important that the plastic surgeon manages expectations carefully before surgery, as it is possible that patients might experience a rather low aesthetic outcome after perineal reconstruction.

**Martin W. Stenekes, MD, PhD**

Department of Plastic and Reconstructive Surgery  
University Medical Center Groningen  
Groningen, The Netherlands  
HPC BB81, PO Box 30.001, Hanzeplein 1  
9700 RB Groningen  
The Netherlands  
E-mail: m.w.stenekes@umcg.nl

## REFERENCES

1. Yii NW, Niranjana NS. Lotus petal flaps in vulvo-vaginal reconstruction. *Br J Plast Surg*. 1996;49:547–554.
2. Hellinga J, Khoe PC, van Etten B, et al. Fasciocutaneous lotus petal flap for perineal wound reconstruction after extralevator abdominoperineal excision: Application for reconstruction of the pelvic floor and creation of a neovagina. *Ann Surg Oncol*. 2016;23:4073–4079.
3. Boccola MA, Rozen WM, Ek EW, et al. Reconstruction of the irradiated extended abdominoperineal excision (APE) defect for locally advanced colorectal cancer. *J Gastrointest Cancer*. 2011;42:26–33.
4. West NP, Finan PJ, Anderin C, et al. Evidence of the oncologic superiority of cylindrical abdominoperineal excision for low rectal cancer. *J Clin Oncol*. 2008;26:3517–3522.
5. Mughal M, Baker RJ, Muneer A, et al. Reconstruction of perineal defects. *Ann R Coll Surg Engl*. 2013;95:539–544.
6. Hellinga J, Te Grootenhuis NC, Werker PMN, et al. Quality of life and sexual functioning after vulvar reconstruction with the lotus petal flap. *Int J Gynecol Cancer*. 2018;28:1728–1736.
7. Hellinga J, Stenekes MW, Werker PMN, et al. Quality of life, sexual functioning, and physical functioning following perineal reconstruction with the lotus petal flap. *Ann Surg Oncol*. 2020;27:5279–5285.
8. Moolenburgh SE, Mureau MA, Hofer SO. Aesthetic outcome after nasal reconstruction: Patient versus panel perception. *J Plast Reconstr Aesthet Surg*. 2008;61:1459–1464.
9. Dikmans REG, Nene LEH, Bouman MB, et al. The aesthetic items scale: A tool for the evaluation of aesthetic outcome after breast reconstruction. *Plast Reconstr Surg Glob Open*. 2017;5:e1254.
10. Eltahir Y, Werners LLCH, Dreise MM, et al. Quality-of-life outcomes between mastectomy alone and breast reconstruction: Comparison of patient-reported BREAST-Q and other health-related quality-of-life measures. *Plast Reconstr Surg*. 2013;132:201e–209e.
11. Strasser EJ. An objective grading system for the evaluation of cosmetic surgical results. *Plast Reconstr Surg*. 1999;104:2282–2285.
12. Draaijers LJ, Tempelman FR, Botman YA, et al. The patient and observer scar assessment scale: A reliable and feasible tool for scar evaluation. *Plast Reconstr Surg*. 2004;113:1960–1967.
13. Clavien PA, Barkun J, de Oliveira ML, et al. The Clavien-Dindo classification of surgical complications: Five-year experience. *Ann Surg*. 2009;250:187–196.
14. Bae SH, Bae YC. Analysis of frequency of use of different scar assessment scales based on the scar condition and treatment method. *Arch Plast Surg*. 2014;41:111–115.
15. Ching S, Thoma A, McCabe RE, et al. Measuring outcomes in aesthetic surgery: A comprehensive review of the literature. *Plast Reconstr Surg*. 2003;111:469–80; discussion 481.
16. Eltahir Y, Bosma E, Teixeira N, et al. Satisfaction with cosmetic outcomes of breast reconstruction: Investigations into the correlation between the patients' Breast-Q outcome and the judgment of panels. *JPRAS Open*. 2020;24:60–70.
17. Wachter T, Edlinger M, Foerg C, et al. Differences between patients and medical professionals in the evaluation of aesthetic outcome following breast reconstruction with implants. *J Plast Reconstr Aesthet Surg*. 2014;67:1111–1117.
18. Beesley H, Ullmer H, Holcombe C, et al. How patients evaluate breast reconstruction after mastectomy, and why their evaluation often differs from that of their clinicians. *J Plast Reconstr Aesthet Surg*. 2012;65:1064–1071.
19. Groen JW, Piatkowski AA, Sawor JH, et al. Autologous Fat transfer after augmentation and reconstruction of the female breast: An international, cross-sectional photo-comparison study among different physician and laymen study groups. *Surg Innov*. 2018;25:594–601.
20. Smittenberg MN, Marsman M, Veeger NJGM, et al. Comparison of cartilage-scoring and cartilage-sparing otoplasty: A retrospective analysis of complications and aesthetic outcome of 1060 ears. *Plast Reconstr Surg*. 2018;141:500e–506e.