

University of Groningen

Abdominal Wall Transplantation: Indications and Outcomes

Honeyman, Calum; Dolan, Roisin ; Stark, Helen ; Fries, Charles Anton ; Reddy, Srikanth; Allan, Philip ; Vrakas, Giorgios ; Vaidya, Anil; Dijkstra, G.; Hofker, Sijbrand H.

Published in:
Current Transplantation Reports

DOI:
[10.1007/s40472-020-00308-9](https://doi.org/10.1007/s40472-020-00308-9)

IMPORTANT NOTE: You are advised to consult the publisher's version (publisher's PDF) if you wish to cite from it. Please check the document version below.

Document Version
Publisher's PDF, also known as Version of record

Publication date:
2020

[Link to publication in University of Groningen/UMCG research database](#)

Citation for published version (APA):

Honeyman, C., Dolan, R., Stark, H., Fries, C. A., Reddy, S., Allan, P., Vrakas, G., Vaidya, A., Dijkstra, G., Hofker, S. H., Tempelman, T., Werker, P. M. N., Erdmann, D., Ravindra, K., Sudan, D., Friend, P. J., & Giele, H. (2020). Abdominal Wall Transplantation: Indications and Outcomes. *Current Transplantation Reports*, 7, 279-290. <https://doi.org/10.1007/s40472-020-00308-9>

Copyright

Other than for strictly personal use, it is not permitted to download or to forward/distribute the text or part of it without the consent of the author(s) and/or copyright holder(s), unless the work is under an open content license (like Creative Commons).

The publication may also be distributed here under the terms of Article 25fa of the Dutch Copyright Act, indicated by the "Taverne" license. More information can be found on the University of Groningen website: <https://www.rug.nl/library/open-access/self-archiving-pure/taverne-amendment>.

Take-down policy

If you believe that this document breaches copyright please contact us providing details, and we will remove access to the work immediately and investigate your claim.

Downloaded from the University of Groningen/UMCG research database (Pure): <http://www.rug.nl/research/portal>. For technical reasons the number of authors shown on this cover page is limited to 10 maximum.



Abdominal Wall Transplantation: Indications and Outcomes

Calum Honeyman¹ · Roisin Dolan² · Helen Stark^{3,4} · Charles Anton Fries⁴ · Srikanth Reddy⁵ · Philip Allan⁵ · Giorgios Vrakas⁶ · Anil Vaidya^{7,8} · Gerard Dijkstra⁹ · Sijbrand Hofker⁹ · Tallechien Tempelman¹⁰ · Paul Werker¹⁰ · Detlev Erdmann¹¹ · Kadiyala Ravindra¹¹ · Debra Sudan¹¹ · Peter Friend^{3,5} · Henk Giele^{3,4,5} 

Accepted: 15 October 2020 / Published online: 7 November 2020
© The Author(s) 2020

Abstract

Purpose of Review This article aims to review published outcomes associated with full-thickness vascularized abdominal wall transplantation, with particular emphasis on advances in the field in the last 3 years.

Recent Findings Forty-six full-thickness vascularized abdominal wall transplants have been performed in 44 patients worldwide. Approximately 35% of abdominal wall transplant recipients will experience at least one episode of acute rejection in the first year after transplant, compared with rejection rates of 87.8% and 72.7% for hand and face transplant respectively. Recent evidence suggests that combining a skin containing abdominal wall transplant with an intestinal transplant does not appear to increase sensitization or de novo donor-specific antibody formation.

Summary Published data suggests that abdominal wall transplantation is an effective safe solution to achieve primary closure of the abdomen after intestinal or multivisceral transplant. However, better data is needed to confirm observations made and to determine long-term outcomes, requiring standardized data collection and reporting and collaboration between the small number of active transplant centres around the world.

Keywords Abdominal wall transplant · Intestinal transplant · Multivisceral transplant · Vascularized composite allograft

Introduction

Abdominal wall transplantation is principally indicated to achieve expansion of the abdominal domain and abdominal wall closure after intestinal transplantation. Closure of the

abdominal wall after intestinal transplant (ITx) or multivisceral transplant (MVT) is an essential element in preventing complications and preserving transplant function. An open abdomen after ITx or MVT may lead to sepsis and fistula formation, whilst closure under excessive tension risks

This article is part of the Topical Collection on *Vascularized Composite Allografts*

✉ Henk Giele
henk.giele@nds.ox.ac.uk

- ¹ Canniesburn Plastic Surgery and Burns Unit, Glasgow Royal Infirmary, Glasgow, Scotland, UK
- ² Department of Plastic and Reconstructive Surgery, St Vincent's University Hospital, Dublin, Ireland
- ³ Nuffield Department of Surgical Sciences, University of Oxford, John Radcliffe Hospital, Oxford, UK
- ⁴ Department of Plastic and Reconstructive Surgery, Oxford University Hospitals NHS Foundation Trust, John Radcliffe Hospital, Oxford, UK
- ⁵ Department of Transplant Surgery, Oxford University Hospitals and University of Oxford, Oxford, UK

- ⁶ Department of Transplant Surgery, University of Maryland School of Medicine, 29 S. Greene Street, Suite 200, Baltimore, MD 2120, USA
- ⁷ Apollo Hospitals, 21 Greams Road, Chennai, Tamil Nadu 600001, India
- ⁸ Transplant Center, The Cleveland Clinic, 9500 Euclid Avenue A 100, Cleveland, OH 44195, USA
- ⁹ Department of Gastroenterology and Hepatology, University Medical Center Groningen, University of Groningen, Hanzeplein 1, 9713, GZ Groningen, The Netherlands
- ¹⁰ Department of Plastic Surgery, University Medical Center Groningen, University of Groningen, Hanzeplein 1, 9713, GZ Groningen, The Netherlands
- ¹¹ Department of Surgery, Duke University Medical Center, Durham, NC, USA

abdominal compartment syndrome, bowel ischemia and respiratory compromise [1•, 2]. Inability to achieve primary closure after transplantation occurs in approximately 20–40% of cases. This is commonly a result of loss of abdominal domain due to a combination of extensive intra-abdominal scarring (multiple preceding laparotomies and enterocutaneous fistulae) and post-transplant bowel oedema [1•, 3].

Several reconstructive options have been described to augment closure in these complex cases, including component separation, tissue expansion, use of absorbable and non-absorbable mesh, acellular dermal matrices, pedicled thigh flaps and vascularized or non-vascularized rectus fascia grafts [4•, 5–9]. However, in malnourished, total parenteral nutrition (TPN)-dependent patients undergoing transplantation, many of these options carry significant additional morbidity. In 2001, Levi et al reported vascularized, full-thickness abdominal wall transplants (AW-VCA) as an alternative solution for abdominal wall closure after ITx [1•]. Retrieving the entire anterior abdominal wall, as part of multiorgan procurement, allowed ‘like-for-like’ reconstruction, with no donor site morbidity for the recipient. Crucially, this early report was not associated with increased immunosuppression requirements when compared to ITx in isolation, encouraging further development of the technique.

The aim of this article is to review the published literature on abdominal wall transplantation, with particular emphasis on outcomes and advances in the field of AW-VCA over the last 3 years. We have excluded cases of abdominal fascial transplantation performed in-continuity with the liver, as these were not separate transplants and did not include muscle or skin components.

The data presented in this article is from a comprehensive literature search of the PubMed and EMBASE electronic databases on the 4th of April 2020. Search terms included ‘abdominal wall transplant’, ‘vascularized composite allotransplantation’, ‘VCA’ and ‘intestinal transplant’. Only articles relating to full-thickness vascularized AW-VCA, with sufficient data to facilitate comparative analysis, were included.

Updated International Experience with AW-VCA

Over the last two decades, 46 full-thickness AW-VCA have been performed in 44 patients. Seven international units in five countries have now performed AW-VCA, with Duke the most recent new unit to perform an AW-VCA in 2018. There are many units advertising AW-VCA capability who are yet to perform AW-VCA, which is indicative of the interest in the technique. An updated summary of the international experience of AW-VCA can be seen in Table 1.

Indications for AW-VCA

AW-VCA is principally indicated when candidates for intestinal transplantation have loss of the abdominal domain due to (1) multiple previous laparotomies, perforations and subsequent adhesions; (2) extensive enterocutaneous fistulae (e.g. secondary to Crohn’s disease or due to surgical complications); (3) abdominal wall fibrosis and scarring preventing wall expansion, e.g. following previous abdominal wall radiotherapy, or healing by secondary intention; and (4) resection of the abdominal wall due to tumour involvement (desmoid/pseudomyxoma peritonei (PMP)) (Fig. 1). AW-VCA may also be indicated as a technique to reconstruct massive herniation when no other techniques are possible, or have previously failed, especially for patients that already have a transplant and are immunosuppressed.

A summary of the indications for ITx can be seen in Table 2. Difficulty in abdominal wall closure after intestinal transplantation occurs in 40% of recipients [2, 21]. Difficulties, and hence indications that are more likely to require AW-VCA, commonly occur after a significant period of intestinal failure and cachexia. The resulting short gut syndrome following significant intestinal resection leaves a scaphoid abdomen with little abdominal domain, especially against a background of multiple abdominal wall scars from previous procedures, stomas and/or fistulae. By contrast, patients with PMP often have expanded abdominal cavities and do not need AW-VCA unless there has been significant abdominal wall resection required for tumour involvement.

The indications for AW-VCA is an ongoing area of controversy. Many centres feel that non-transplant methods of abdominal wall reconstruction are adequate, and may avoid the additional morbidity and complexity AW-VCA adds to an already complex procedure. These centres either reduce the quantity of intestinal graft transplanted, restrict donors to smaller sizes or lower BMIs or use techniques such as staged closure, expansion, component separation, flaps, grafts or implants such as biological or prosthetic supplementary closure, despite the associated increased risks of these techniques.

Against these known risks are balanced the relatively unknown risks of adding an AW-VCA to an ITx. Traditional immunological teaching and understanding has always been that skin is the most immunogenic organ in the body. As such, the main fear was that by transplanting skin in addition to a visceral transplant, there would be an increased risk of immunological rejection, an increase in immunosuppression requirements and an increased risk of sensitizing the patient to produce anti-donor antibodies, prompting chronic rejection and fibrosis, or leading to graft versus host disease (GVHD) due to the large quantities of immunologically active cells in skin. There were also fears that AW-VCA would lead to extended operative times and stress, potentially endangering the patient and increasing the ischaemia reperfusion burden.

Table 1 Updated international experience of AW-VCA (includes unpublished data verified by personal communication)

Relevant publications (First author, date published)	Units	AW-VCA Since	No. of patients	No. of AW-VCA grafts	Immediate or delayed	Technique	Sex (M:F)	Age range (years)	Maximum recorded follow-up
Erdmann (2019) [10•]	Duke, USA	2018	1	1	Immediate	Macrovascular	M	37	8 weeks
Trentadue (2020) [11•]	Groningen	2015	2	2	Immediate	Microvascular	F	24	1 year
Haveman (2016) [12]	Netherlands						F		
Unpublished communication with senior author H.G.	Chennai, India	2015	3	3	NR	Microvascular	NR	NR	NR
Schimmelpfennig (2013) [13]	Indiana, USA	2013	1	1	Delayed (<i>n</i> = 1 case)	Macrovascular	F	17	NR
Weissenbacher (2017) [14•]	Oxford, UK	2011	23	24	Immediate	Microvascular	11:7	26–69	8 years
Gerlach (2016) [15]									
Giele (2014) [16]									
Allin (2013) [17]									
Selvaggi (2009) [18]	Bologna, Italy	2005	3	3	Immediate	Microvascular	2:1	33–38	7.1 years
Cipriani (2007) [19]									
Selvaggi (2009) [18]	Miami, USA	2001	11	12	Delayed (<i>n</i> = 2 cases)	Macrovascular	6:5	1–53	7.1 years
Selvaggi (2004) [20]									
Levi (2003) [1]									

AW-VCA abdominal wall vascularized composite allotransplant, NC North Carolina, NR not recorded, UK United Kingdom, USA United States of America

More controversy exists when considering AW-VCA transplantation in patients with a history of malignancy, due to concerns that immunosuppression may lead to cancer recurrence. However, a number of cases have now been reported [22–24]. Despite initial technical successes reported in these VCA recipients, long-term outcomes relating to cancer recurrence are not available. It remains unknown whether an additional AW-VCA transplant increases the risk of malignancy compared to ITx alone. There are a number of case reports of mortalities resulting from overwhelming new or recurrent malignancies following facial transplantation [25, 26]. However, to-date, this has not been the case in AW-VCA, with follow-up extending beyond 4 years.

Future Indications for AW-VCA

Oxford have performed one isolated AW-VCA for reconstruction of a massive hernia in a patient with an existing functional kidney transplant. As the patient was already immunosuppressed, the ethical debate about non-life saving transplantation was avoided, though there was debate regarding risk to the kidney transplant. Two units from the USA have now performed penis VCAs that included varying amounts of abdominal wall within the transplant [27•, 28]. This new combined VCA, without associated visceral organ transplantation, offers hope for many war veterans who have sustained composite genitourinary and abdominal wall injuries.

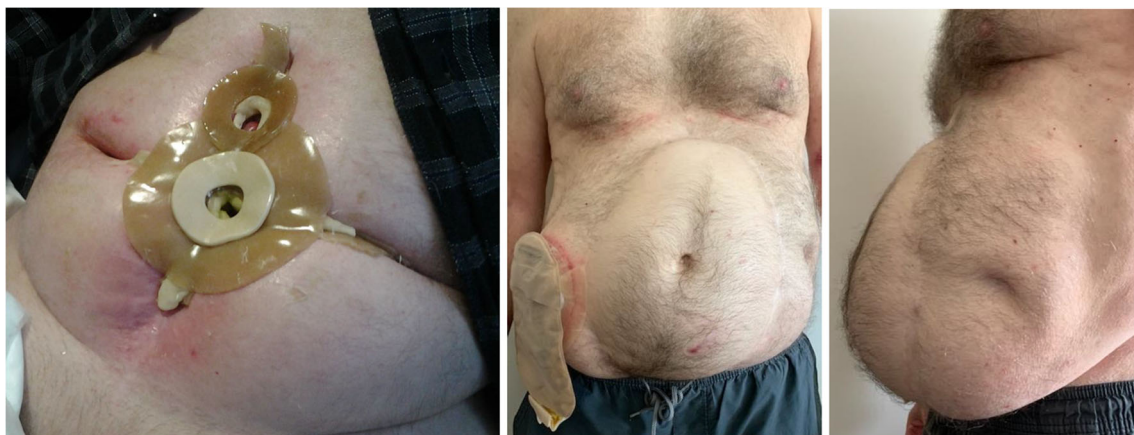

Fig. 1 A 66-year-old male. Clinical photographs taken 6 6 years and 9 months after combined AW-VCA and ITx due to Crohn’s Disease. Left - pre-transplant state: TPN dependent, multiple preceding laparotomies,

residual 250 250 cm of fistulated jejunum and multiple enterocutaneous fistulae. Middle - AP image post-transplant at most recent follow-up. Right - lateral image post-transplant at most recent follow-up

Table 2 Indications for combined AW-VCA and ITx, MVT or MMVT

Indication	Number of patients	Notes
Neoplasia other than PNP	8	Desmoid tumours secondary to Gardner syndrome
Inflammatory bowel disease (IBD)	7	Multiple small bowel resections +/- perforations >> short-bowel syndrome with involvement of abdominal wall
Intestinal motility disorder	1	Miami (Hirschsprung's disease, $n = 3$) Bologna ($n = 1$): Chronic intestinal pseudo obstruction Oxford ($n = 1$)
Pseudomyxoma Peritonei	6	Oxford (combined MMVT and AW-VCA)
Enteritis/enterocolitis other than IBD	3	Oxford
Trauma	3	Miami (^a may be overlap with multiple adhesions described in 'other')
Mesenteric thrombosis	2	Oxford and Bologna
Visceral neuropathy	2	Oxford
Gastroschisis	1	Miami ($n = 2$) Oxford ($n = 1$)
Vasculitis	1	Churg Strauss Vasculitis
Other	2	Indiana ($n = 1$). Juvenile dermatomyositis >> Duodenal perforation >> intestinal failure and multiple enterocutaneous fistulae Duke ($n = 1$). Multiple adhesions >> short bowel syndrome and multiple high output enterocutaneous fistulae (NB: multiple failed attempts at fistula takedown and ventral hernia repair using component separation and biological mesh)
Vasculitis	1	Churg Strauss Vasculitis

AW-VCA abdominal wall vascularized composite allotransplant, IBD inflammatory bowel disease, ITx intestinal transplant, MVT multivisceral transplant, MMVT modified multivisceral transplant (without liver), PNP pseudomyxoma peritonei

^a Chennai ($n = 3$) not included due to lack of published outcomes

These examples raise the possibility of AW-VCA transplantation as a reconstructive option for patients with massive abdominal wall defects that cannot be reconstructed by other methods. The need for AW-VCA will need to be balanced against the risks of immunosuppression.

Technical Considerations

Work-Up for Combined AW-VCA and ITx/MVT/MMVT

Standard pre-operative protocols for ITx, MVT or modified multivisceral transplant (MMVT) are followed, with no additional requirements for simultaneous AW-VCA. ABO matching of donors and recipients is routinely performed and the HLA status of the patient is known. Consent for AW-VCA is obtained from donor families and recipients, including counselling for possible skin tone mismatch. A pre-transplant computed tomography scan gives an indication of recipient abdominal capacity and also images the inferior epigastric, deep circumflex iliac and internal mammary vessels, as potential recipient vessels for AW-VCA.

Venous drainage is a frequent issue for these patients due to multiple, and prolonged venous access for parenteral nutrition. However, inferior vena cava and iliac vein thrombosis

and occlusions are not contraindications to AW-VCA as in our experience, despite IVC occlusion, drainage via patent inferior epigastric veins somehow bypasses the occlusion. In the absence of inferior epigastric veins, alternative veins can be used as described later.

No additional procurement criteria are raised that might restrict offers or procurement such as skin tone, sex, size, or other matching characteristics as occurs in VCA hand and face transplantation.

AW-VCA Retrieval

The donor AW-VCA is retrieved as part of routine multiorgan transplant procurement. Most commonly, the AW-VCA and intestinal or multivisceral graft originate from the same donor. However, three cases of delayed AW-VCA, from different donors have also been reported [1, 13]. Full thickness AW-VCA comprises peritoneum, posterior rectus sheath, both rectus abdominis muscles, anterior rectus sheath, overlying fat, skin and parts of the internal and external obliques and transversus abdominis. The AW-VCA is most commonly retrieved using a longitudinal elliptical incision over both rectus abdominis muscles, permitting direct closure of the donor defect. Though this limits the width of the skin component to a few centimetres lateral to the linea semilunaris, the

musculoaponeurotic component can include the obliques and transversalis laterally to the costal margins and iliac crests. Contrary to the experimental studies performed by Light et al in 2017, it is our experience that these lateral muscles extending to their origins and a near-total anterior abdominal wall can be successfully vascularized on the inferior epigastric supply alone [29].

Vascular Anastomosis

AW-VCA can be performed using a macroscopic or microscopic approach. In the macroscopic approach, larger calibre iliac vessels as a cuff or conduit to the inferior epigastric vessels are used for anastomosis to the recipient iliac or femoral arteries. However, this method may not be possible in the setting of liver retrieval, where the iliac vessels are also retrieved for the purpose of liver inset [4••]. The microscopic approach uses the donor and recipient inferior epigastric vessels, anastomosed in an end-end fashion (Fig. 2).

In order to minimize ischaemia reperfusion injury and cold ischaemia time, and to reduce operative time in fragile patients, Giele et al. described immediate, temporary revascularization of AW-VCA grafts onto the recipients' ulnar or radial arteries [16]. This technique is performed simultaneously alongside ITx or MMVT. Following completion of visceral transplantation, the patient's physiological status and recipient vessel status are assessed. If the patient remains physiologically stable and vessels are identified, then direct microsurgical anastomosis is performed, and the recipient forearm vessels are repaired. If the patient is unstable, then the AW-VCA remains perfused by the forearm vessels and is pedicled to allow closure of abdominal wall. At a 4–6-week interval, the pedicle from the forearm can be divided, the flap having established a vascular supply from the adjacent native abdominal wall. If there is doubt regarding AW-VCA vascularity,

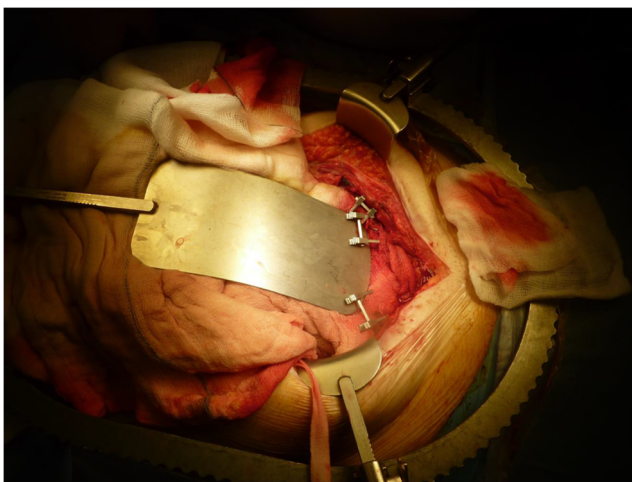


Fig. 2 Intra-operative photograph of the preparation of the inferior epigastric vessels for AW-VCA inset

this can be augmented with a microsurgical anastomosis to the inferior epigastric or internal mammary vessels as required. This technique can also be used when the inferior epigastric vessels are of poor quality. Alternative recipient vessels are the deep circumflex iliac that we, and the unit in Bologna, have used with success. We suggest an additional iliac crest incision to approach these vessels rather than accessing them through the midline laparotomy. We have also revascularized the AW-VCA through the intestinal transplant graft using arterial grafts to the superior mesenteric artery stump with venous drainage via vein grafts to the transplanted splenic vein on one side and a gonadal vein on the other.

Erdmann et al. describe an alternative approach for synchronous revascularization of ITx and AW-VCA. They create bilateral arteriovenous (AV) fistulae, by dissecting the saphenous veins, at the level of the mid-thigh, and rotating them through 180°, before performing end-to-side anastomosis with the common femoral arteries. The left AV fistula is transected and an end-to-end anastomosis with the donor inferior epigastric artery and vein is performed using 7-0 Prolene sutures. After adequate perfusion is achieved, the AW-VCA is temporarily secured to the thigh until ITx is completed. Subsequently, revascularization of the right side is then performed and the AW-VCA inset [10•, 30].

As mentioned earlier, venous drainage is often more troublesome than the arterial input due to long-term venous access issues. In addition to the strategies already mentioned, in the event of occlusion or deficient inferior epigastric veins, we have on occasion drained the AW-VCA via the deep circumflex iliac vessels or via the mesenteric veins through the intestinal transplant.

Postoperative Monitoring for Rejection

All units employ routine endoscopic intestinal biopsies as part of local intestinal transplant monitoring. The previous Oxford protocol included protocol-driven endoscopies and mucosal biopsies, performed three times a week for the first 3 months, then twice a week for the next 3 months and subsequently at an interval of one endoscopy every 2 weeks until stoma closure, and then once a year for routine check-ups. However, current protocols due in part to the useful presence of the abdominal wall skin no longer includes protocol biopsies but relies on monitoring of stoma output and serum citrulline levels as well as skin monitoring. In addition, intestinal endoscopies are performed in response to episodes of suspected rejection [15]. ITx biopsies are reported in accordance with universally recognized histological rejection criteria [31].

Follow-up for AW-VCA in Oxford comprises of visual inspection of colour, warmth and capillary refill. Skin biopsies are only taken if there is a clinical suspicion of AW-VCA such as erythema, rash or oedema, or if there is suspected or biopsy proven intestinal transplant rejection. AW-VCA skin biopsy

results are reported in accordance with the Banff 2007 working classification of skin-containing composite tissue allograft pathology [32].

Clinical Outcomes for AW-VCA

The following clinical outcomes are from published studies. Thirteen publications yielded data for 37 AW-VCA grafts in 35 patients, performed between 2001 and 2020 [1•, 10•, 11, 12, 14•, 18]. Three cases from Chennai, and the five most recent cases performed in Oxford, were excluded as they are currently unpublished. Limited data exists for the single case report from Indiana. Four original articles detailing clinical experience with AW-VCA have been published over the last 3 years [10•, 11, 12, 14•]. Clinical outcomes and complications relating to AW-VCA are summarized in Tables 1, 2, 3 and 4.

Operative Outcomes

The aim of AW-VCA is to expand the abdominal domain to accommodate the intestinal transplant and to permit primary closure thus avoiding associated complications. The outcomes regarding the period spent in intensive care, return to theatre, time to wound healing, abdominal compartment pressures or its surrogate glomerular filtration rate (GFR), or duration of hospital stay are poorly recorded. What is published suggests that the primary aim of expanding the abdominal domain and achieving primary closure was achieved in all cases. There does not seem to be a need to innervate the abdominal musculature as the rate of herniation or bulging seems low, with three reports of patients being able to contract their abdominal muscles following AW-VCA [15, 18].

Improved recording of events is needed to determine if AW-VCA achieves the additional goals of reducing complications, return to theatre and length of stay.

Table 3 Immunosuppression protocols used by different units

Unit	Induction immunosuppression	Maintenance immunosuppression	Rescue immunosuppression
Duke, USA	Thymoglobulin (1.5 mg/kg × 4 doses)	Tacrolimus, MMF, prednisolone (dosages not specified)	5-day steroid pulse (type and dose not specified)
Groningen, Netherlands	Methylprednisolone (500 mg) Anti-thymocyte globulin (9 @mg/kg)	Tacrolimus (13–17 ng/mL), MMF (2–4 mg/L), prednisolone (starting at 2 mg/kg/day IV and weaning to 0.1 mg/kg/day orally by 4–6 months) MMF stopped on day 14 due to pancytopenia Recurrent AW-VCA ACR required initiation of Vedolizumab. Initially 300 mg on weeks 0, 2 and 6 (induction), and every 8 weeks thereafter (maintenance) Tacrolimus was continued with trough levels between 17.8–24.5 ng/mL during induction and 6.5–19.5 ng/mL during maintenance	Tacrolimus dose increased 3-day boost of IV methyl-prednisolone Addition of ATG (T cell depleting agent)
Chennai, India	No published data	No published data	No published data
Indiana, USA	No published data	Tacrolimus and Prednisolone	No published data
Oxford, UK	Alemtuzumab (30 mg) 6 hours after reperfusion and 24 hours later	Tacrolimus (trough level 8–10 ng/mL)	Methylprednisolone (500 mg/day) Tacrolimus increased If AW-VCA ACR–Tacrolimus ointment (0.1%) BD used for 2/52 or until resolution
Bologna, Italy	Alemtuzumab (0.3 mg/kg) immediately pre-op and post-op and days 3 and 7	Tacrolimus (trough level 10 ng/mL)	IV corticosteroids and PO steroid weaning regimen (type and dose not specified)
Miami, USA	Alemtuzumab (0.3 mg/kg) immediately pre-op and post-op and days 3 and 7	Tacrolimus (trough level 10 ng/mL)	IV corticosteroids and PO steroid weaning regimen (type and dose not specified)

ATG Anti-thymocyte globulin, BD twice daily, IV intravenous, MMF Mycophenolate mofetil, PO per oral

Table 4 Summary of the published complications of AW-VCA at different units

Unit, no. of reported cases	Complications
Duke, USA <i>n</i> = 1 case	None reported
Groningen, Netherlands <i>n</i> = 1 case	Pancytopenia, <i>n</i> = 1 episode (GSF given, MMF stopped) Astrovirus infection (day 254)—cleared uneventfully Primary CMV infection (days 316 to 337 post-transplant)—cleared uneventfully
Chennai, India	No published data
Indiana, USA	No published data
Oxford, UK <i>n</i> = 18 cases (*published data currently available for 18/24 cases)	AW-VCA graft loss, <i>n</i> = 1 graft Wound infection, <i>n</i> = 3 patients Sepsis, <i>n</i> = 2 patients GVHD, <i>n</i> = 2 patients
Bologna, Italy <i>n</i> = 3 cases	PTLD, <i>n</i> = 1 patient
Miami, USA <i>n</i> = 11 cases	AW-VCA graft loss, <i>n</i> = 2 grafts Wound infection, <i>n</i> = 7 patients

ACR acute cellular rejection, AW-VCA abdominal wall vascularized composite allotransplant, CR chronic rejection, GVHD graft versus host disease, PTLD post-transplant lymphoproliferative disease

Patient Survival

Patient survival data for publications relating to AW-VCA is challenging to interpret and compare. No studies present survival data as standard 30 day, 1-, 3- or 5-year survival figures, or as Kaplan-Meier survival curves. Oxford reported 33% deaths in 18 patients with AW-VCA and ITx, and Miami and Bologna combined their figures and reported 64% deaths in their 15 grafts in 14 patients. With that in mind, our best estimate is that at least 53% of patients who received AW-VCA with ITx or MVT/MMVT were still alive at the time of publication (mean follow-up range 6 to 85 months). Cause of death for all units included: sepsis (*n* = 4); recalcitrant acute rejection (*n* = 1); CMV enteritis (*n* = 1); cerebral oedema/hyperammonaemia (*n* = 1); GVHD (*n* = 1); upper gastrointestinal bleed (*n* = 1), transplant pancreatitis (*n* = 1); primary non-function of the transplanted intestine (*n* = 1); PTLD (*n* = 1). This is comparable to non-VCA visceral transplant recipients [14•]. All AW-VCA were reported to be functioning at the time of death and no patients died secondary to complications from the AW-VCA. Our estimated survival figures appear to reflect published 1- and 3-year survival figures for corresponding intestinal transplants [33].

AW-VCA Loss

AW-VCA losses can be considered as those that occur immediately postoperatively due to poor perfusion and later losses due to chronic rejection or explantation for other reasons.

Immediate postoperative losses for all units is currently 4.3% (2/46). The Miami Group lost two AW-VCA in the early postoperative period. The first was lost due to venous outflow obstruction and graft thrombosis at day 6 after transplantation, with eventual healing due to secondary intention. The second graft was lost on day 1 post-transplant due to primary non-function of the intestinal graft and associated hypoperfusion of the AW-VCA, requiring removal of both transplants. Late losses represent 2.5%, or a risk of 3% of grafts that survive. Gerlach et al. from Oxford report explanation of one AW-VCA and ITx after 30 months due to chronic rejection of the AW-VCA and ITx. The patient ultimately underwent retransplantation [15]. The rate and risk of losses of AW-VCA compare favourably to other VCAs and to solid organ transplants [34].

Visceral Graft Loss After Combined AW-VCA and ITx, MVT or MMVT

ITx graft loss is closely associated with death. Weissenbacher et al. report 1- and 3-year intestinal graft survival rates of 94% and 57% respectively. This compares to 1- and 3-year intestinal graft survival rates of 78% and 70% (*p* = 0.67) in patients with ITx/MMVT alone [14•]. Miami reported 2/12 intestinal graft losses due to post-op perfusion problems and recalcitrant rejection, but with less than 33 months follow-up of the remainder. There does not seem to be an increased rate of patient or intestinal graft loss associated with AW-VCA.

Immunological Outcomes

Immunosuppression Protocols

Individual induction, maintenance and rescue immunosuppression protocols between units are summarized in Table 3. Miami, Oxford, Chennai and Bologna use induction with intravenous alemtuzumab (anti-CD52 monoclonal antibody) followed by tacrolimus monotherapy for long-term maintenance. The other units used thymoglobulin induction and triple therapy maintenance using tacrolimus, mycophenolate mofetil (MMF) and steroids. Indiana excluded the MMF. Rescue therapy consists of IV corticosteroids in a weaning protocol. Most cases of AW-VCA and ITx acute cellular rejection (ACR) were successfully managed with intravenous corticosteroids.

Trentadue et al. from Groningen in the Netherlands have also described the successful use of the humanized mouse anti-a4b7 monoclonal antibody Vedolizumab in the management of recurrent recalcitrant ACR in an AW-VCA patient [11•].

Donor-Specific Antibodies

Measurement of donor-specific antibodies (DSAs) and non-DSAs forms part of routine pre-transplant work-up. It is possible for transplant recipients to be pre-sensitized by alloantigens after pregnancy, previous transfusions or previous transplants. However, the majority of DSAs develop after transplantation has occurred [35, 36]. The development and management of pre-sensitized VCA recipients has now been reported [37]. The clinical significance of DSAs in VCA remains poorly defined, and even a recent multicentre study in hand transplant recipients was unable to highlight a strong statistical correlation between DSA and hand allograft survival and function. However, trends appear to support poorer outcomes after the development of DSAs (especially after HLA class 2 mismatch) [35].

Weissenbacher et al. investigated the role of de novo DSAs (dnDSA) following combined ITx and AW-VCA, and found that the addition of a VCA to the ITx did not appear to increase sensitization or dnDSA formation, when compared to ITx alone [14•]. This finding was of particular interest as it goes against traditional concepts regarding the high antigenicity of skin compared to other tissue types.

Episodes of Acute Cellular Rejection

At least one episode of biopsy proven ACR affected 35% (13/37) of AW-VCA grafts, and 22% (8/37) of ITx grafts in the first post-transplant year. These results compare favourably with hand and face VCA skin ACR rates of 87.8% and 72.7% respectively, in the first post-transplant year [34].

Intestinal transplant rejection rates are reported at 30–50%, indicating that the addition of an AW-VCA does not appear to increase the risk of ITx rejection.

When interpreting rates of ACR in published literature, one must pay close attention to the denominator. For example, the Miami Group lost two AW-VCA grafts in two patients in the very early postoperative period. In subsequent combined publications with Bologna, both patients were included in the denominator of calculations relating to AW-VCA ACR, when they had little time to develop ACR, and as such likely leads an under estimation of ACR rates.

To date, Oxford have reported no cases of ITx ACR without preceding, or simultaneous AW-VCA skin ACR. This demonstrates uni-directional concordant rejection between skin and intestine when intestine rejected, but discordant rejection on most occasions when skin rejected as the intestine did not reject at that time. This may have been because the skin rejection was detected and treated early in the immunological process before intestinal rejection manifested.

Oxford reported 37% (7/19) of AW-VCA grafts had at least one biopsy confirmed ACR event presenting as a visible skin rash. Three of these seven patients had associated intestinal transplant rejection at presentation or within a few days, confirmed by biopsy. There were no intestinal rejection events without skin rejection. This 17% (3/18) rate of intestinal ACR compares favourably against the rejection incidence of 36% (5/14) in patients who received only an intestinal transplant and no AW-VCA. There was no evidence that the presence of a VCA increased the frequency of intestinal rejection episodes ($p = 0.23$) or overall rejection events [14•]. This goes some way to alleviating the concern that the addition of an AW-VCA would increase rejection events or immunosuppressive requirements either in maintenance dosing or rejection treatment dosing. In their case report, Erdmann et al. from Duke did not correlate their single episode of AW-VCA ACR with biopsy confirmed ITx rejection [10•].

In contrast, in the 14 cases reported by Miami and Bologna, AW-VCA rejection was seen in 4/13 patients. They also reported intestinal rejection in two patients, but AW-VCA and intestinal rejections did not occur together and were always discordant. This series has limited follow-up of between 1 and 33 months. It is worth considering that in two of the four patients who suffered rejection of the AW-VCA, the AW-VCA were from different donors to the visceral transplant. Furthermore, the absence of AW-VCA rejection in the presence of intestinal rejection was assessed clinically rather than by biopsy [18, 19]. In Groningen, they reported intestinal biopsy proven rejection occurring at day 6 after transplantation, preceding skin biopsy changes by 15 days [11•]. The authors are aware that the skin of the AW-VCA showed erythema on the day of the intestinal rejection but the biopsy reported at that time showed only mild non-specific inflammatory changes, not diagnostic of rejection. Skin biopsies

only became diagnostically positive for rejection 15 days later. That this episode of rejection occurred so rapidly after administration of the induction agent anti-thymocyte globulin (ATG) raises the possibility that ATG has a disproportionate effect on AW-VCA skin.

VCA skin as an immune monitor in intestinal transplantation

The findings detailed above may indicate that signs of ACR on the AW-VCA skin (rash, erythema, oedema) may allow early detection and treatment of ACR, prior to detectable rejection in the intestine [15]. In Oxford, this finding has facilitated a reduction in endoscopies and permits remote monitoring and follow-up of combined AW-VCA and ITx recipients via telemedicine [38]. However, it seems that discordant intestinal rejection can occur so the utility of skin as a diagnostic tool for intestinal rejection remains to be assessed and verified. The sensitivity, specificity and positive and negative predictive values also need to be determined. The difficulty in doing so is that there is no gold standard diagnostic tool for intestinal rejection and that it is unethical to observe skin rejection and withhold treatment to see whether the intestine will subsequently reject. Furthermore, treatment of the skin rejection naturally prevents intestinal rejection from occurring so comparing the skin with the gold standard diagnostic test is not possible. Instead, future studies will have to rely on surrogates such as comparative numbers of rejection episodes.

Gerlach et al. from Oxford also highlighted the utility of the skin component of the AW-VCA in patients presenting with intestinal dysfunction of indeterminate cause [15]. They found that in a cohort of 28 patients (of which 13 had an AW-VCA), 11 patients that presented with intestinal dysfunction, but with no associated skin changes, suffered infection related intestinal dysfunction. On initial presentation, this is a challenging diagnosis to make, and in retrospect Oxford mistreated 7/11 patients as having acute rejection. In 5/11 patients that had no AW-VCA, and 2/11 with AW-VCA, prednisolone was administered after biopsy of the intestine but before final results were available. The problem of course being that to get microbiological or virological confirmation of infection sometimes takes days. However, these patients failed to respond to Methylprednisolone and later investigations revealed the infectious cause. Given this experience, they subsequently felt that in the absence of skin changes in any intestinal dysfunction, it should be approached cautiously with respect to increasing immunosuppression, perhaps delaying immunosuppressive treatment until the diagnosis was confirmed as either infection or rejection. This approach was tested on the remaining four patients with intestinal dysfunction and no AW-VCA changes, and subsequent positive infectious agent investigation results verified this approach.

Possible Protective Effect of Combined AW-VCA and ITx or MVT/MMVT

It is documented that rates of ACR are lower in combination transplants when compared to single organ transplants [39, 40]. The degree to which this occurs and the mechanisms are still poorly defined. The same phenomenon may also hold true for combined AW-VCA and ITx or MVT/MMVT. Weissenbacher et al. present a 16.8% (3/18) ITx ACR rate when combined with AW-VCA, compared to 35.7% for isolated ITx or MMVT. Although not reaching statistical significance, this trend highlights a possible protective effect of combination VCA and SOT transplant. An AW-VCA rejection rate of 38.9% in combined AW-VCA and intestinal transplant seems reduced compared to reported hand and face VCA skin ACR rates of 87.8% and 72.7%, respectively in the first post-transplant year [34]. There is a need for robust long-term outcomes reporting and immunological investigation to determine the extent of this effect and its mechanism.

Episodes of chronic rejection

To date, Oxford are the only unit to present a case of chronic rejection (CR) of both AW-VCA and ITx, making the current CR rate for AW-VCA 2%. The Oxford case presented as tissue fibrosis, including vascular fibrosis, leading to obstruction and necrosis. Global estimates for CR for all types of VCA is approximately 6% (13/205) and 15% for ITx [33, 41]. Limited published long-term patient follow-up, small patient numbers and a lack of standardized diagnosis and reporting of CR in AW-VCA may be leading to an underreporting of cases of CR.

Adverse Outcomes

An updated summary of all reported adverse outcomes in the field of AW-VCA can be seen in Table 4. Taking into account non-standardized reporting of complications and small patient numbers, current complication rates do not appear to be greater than what would be expected for VCA or solid organ transplant (SOT) in isolation. Of particular relevance, there does not appear to be an increased risk of post-transplant lymphoproliferative disease (PTLD) or graft-versus-host disease (GVHD) for skin containing AW-VCA when combined with ITx or MMVT/MVT, compared with SOT outcomes in isolation [14, 15].

Psychosocial and Quality of Life Impact of AW-VCA

There is a need to employ objective, standardized psychosocial and quality of life (QoL) measures across the field of VCA. Numerous studies have now described measures for the assessment and follow-up of face and hand

transplantation, but to date, this has not been investigated for AW-VCA [42, 43]. Ambrose et al. recently showed that QoL improved after ITx including patients with AW-VCA, compared to their pre-transplant intestinal failure state [44]. They employed standardized measures, including EQ-5D, SF36 and the ITx-QOL score at regular time intervals. The effect of the addition of a visible transplant to a normally invisible intestinal transplant has yet to be reported.

Conclusions

AW-VCA fulfills the need to expand the abdominal domain and obtain primary closure after intestinal transplantation, seemingly without increasing the risk to the intestinal transplant or patient. There is some evidence that there may also be additional benefits from AW-VCA in providing additional information regarding immune status for monitoring and diagnosis when intestinal dysfunction occurs, and in perhaps reducing the number of intestinal rejection events by virtue of the combination transplant effect and improved monitoring and earlier treatment. In the future, better data is needed to report on long-term outcomes and verify or refute some of the observations made. There is a need to better define the underlying immunology of the AW-VCA skin component, the effect of multi-component transplantation, ascertain the psychosocial and quality of life impact of AW-VCA on recipients. Given the small numbers of patients, all of these areas will require close collaboration between transplant units.

Acknowledgements C.H. would like to thank the William Rooney Plastic Surgery and Burns Trust for their generous support of his period of research in Oxford. This study/project is funded by Robert McAlpine Foundation and the JP Moulton Charitable Foundation and supported by the NIHR Oxford Biomedical Research Centre. The views expressed are those of the authors and not necessarily those of the NIHR or the Department of Health and Social Care.

Compliance with Ethical Standards

Conflict of Interest The authors declare that they have no conflict of interest.

Human and Animal Rights and Informed Consent This article does not contain any studies with human or animal subjects performed by any of the authors.

Open Access This article is licensed under a Creative Commons Attribution 4.0 International License, which permits use, sharing, adaptation, distribution and reproduction in any medium or format, as long as you give appropriate credit to the original author(s) and the source, provide a link to the Creative Commons licence, and indicate if changes were

made. The images or other third party material in this article are included in the article's Creative Commons licence, unless indicated otherwise in a credit line to the material. If material is not included in the article's Creative Commons licence and your intended use is not permitted by statutory regulation or exceeds the permitted use, you will need to obtain permission directly from the copyright holder. To view a copy of this licence, visit <http://creativecommons.org/licenses/by/4.0/>.

References

Papers of particular interest, published recently, have been highlighted as:

- Of importance
 - Of major importance
1. Levi DM, Tzakis AG, Kato T, et al. Transplantation of the abdominal wall. *Lancet*. 2003;361(9376):2173–6. [https://doi.org/10.1016/S0140-6736\(03\)13769-5](https://doi.org/10.1016/S0140-6736(03)13769-5) **Original publication by Miami group detailing the first eight patients treated using AW-VCA.**
 2. Zanfi C, Cescon M, Lauro A, et al. Incidence and management of abdominal closure-related complications in adult intestinal transplantation. *Transplantation*. 2008;85(11):1607–9. <https://doi.org/10.1097/TP.0b013e318174db6f>.
 3. Todo S, Reyes J, Furukawa H, et al. Outcome analysis of 71 clinical intestinal transplantations. *Ann Surg*. 1995;222(3):270–80 discussion 280–2.
 4. Giele H, Vaidya A, Reddy S, Vrakas G, Friend P. Current state of abdominal wall transplantation. *Curr Opin Organ Transplant*. 2016;21(2):159–64. <https://doi.org/10.1097/MOT.0000000000000276> **Previous review article by the senior author H.G. This article gives a concise summary of vascularised AW-VCA up to 2016. It also provides a summary of non-vascularized abdominal wall grafts, not covered in this review.**
 5. Patel NG, Ratanshi I, Buchel EW. The Best of Abdominal Wall Reconstruction. *Plast Reconstr Surg*. 2018;141(1):113e–36e. <https://doi.org/10.1097/PRS.00000000000003976>.
 6. Berli JU, Broyles JM, Lough D, et al. Current concepts and systematic review of vascularized composite allotransplantation of the abdominal wall. *Clin Transpl*. 2013;27(6):781–9. <https://doi.org/10.1111/ctr.12243>.
 7. Drosou A, Kirsner RS, Kato T, et al. Use of a bioengineered skin equivalent for the management of difficult skin defects after pediatric multivisceral transplantation. *J Am Acad Dermatol*. 2005;52(5):854–8. <https://doi.org/10.1016/j.jaad.2004.11.069>.
 8. Weiner J, Wu J, Martinez M, et al. The use of bi-planar tissue expanders to augment abdominal domain in a pediatric intestinal transplant recipient. *Pediatr Transplant*. 2014;18(5):E174–9. <https://doi.org/10.1111/ptr.12282>.
 9. Gondolesi G, Selvaggi G, Tzakis A, et al. Use of the abdominal rectus fascia as a nonvascularized allograft for abdominal wall closure after liver, intestinal, and multivisceral transplantation. *Transplantation*. 2009;87(12):1884–8. <https://doi.org/10.1097/TP.0b013e3181a7697a>.
 10. Erdmann D, Atia A, Phillips BT, et al. Small bowel and abdominal wall transplantation: A novel technique for synchronous revascularization. *Am J Transplant*. 2019;19(7):2122–6. <https://doi.org/10.1111/ajt.15370> **Early clinical report of the first AW-VCA**

- performed by the team at Duke, USA, including details of their novel revascularization technique using bilateral arteriovenous loupes.**
11. Trentadue G, Kats-Ugurlu G, Blokzijl T, et al. Safe and successful treatment of acute cellular rejection of an intestine and abdominal wall transplant with vedolizumab. *Trans Direct*. 2020;6(2):e527. <https://doi.org/10.1097/txd.0000000000000973> **Early experience from Groningen, Netherlands of their first AW-VCA and the novel use of Vedolizumab to treat refractory acute cellular rejection.**
 12. Haveman JW, Tempelman T, Hofker HS, Khoe PC, Dijkstra G, Werker PM. First combined intestinal and abdominal wall transplantation in the Netherlands. *Ned Tijdschr Geneesk*. 2016;160:A7988.
 13. Schimmelpfennig R, Kritzmire S. [NM-290] Multivisceral and abdominal wall transplantation after gastrointestinal perforation in juvenile dermatomyositis: a case report. <http://www2.pedsanesthesia.org/meetings/2013winter/syllabus/submissions/stracts/nonmod/NM-290.pdf>. Accessed Apr 6, 2018.
 14. Weissenbacher A, Vrakas G, Chen M, et al. De novo donor specific HLA antibodies after combined intestinal and vascularised composite allotransplantation. *Transpl Int*. 2018;31(4):398–407. <https://doi.org/10.1111/tri.13096> **Paper from Oxford detailing the significance of de novo donor specific HLA antibodies after combined AW-VCA and intestinal transplant.**
 15. Gerlach UA, Vrakas G, Sawitzki B, et al. Abdominal wall transplantation: skin as a sentinel marker for rejection. *Am J Transplant*. 2016;16(6):1892–900. <https://doi.org/10.1111/ajt.13693>.
 16. Giele H, Bendon C, Reddy S, et al. Remote revascularization of abdominal wall transplants using the forearm. *Am J Transplant*. 2014;14(6):1410–6. <https://doi.org/10.1111/ajt.12724>.
 17. Allin BSRSR, Ceresa CDLDL, Issa F, et al. A single center experience of abdominal wall graft rejection after combined intestinal and abdominal wall transplantation. *Am J Transplant*. 2013;13(8):2211–5. <https://doi.org/10.1111/ajt.12337>.
 18. Selvaggi G, Levi DM, Cipriani R, Sgarzani R, Pinna AD, Tzakis AG. Abdominal wall transplantation: surgical and immunologic aspects. *Transplant Proc*. 2009;41(2):521–2. <https://doi.org/10.1016/j.transproceed.2009.01.020>.
 19. Cipriani R, Contadini F, Santoli M, et al. Abdominal wall transplantation with microsurgical technique. *Am J Transplant*. 2007;7:1304–7.
 20. Selvaggi G, Levi D, Kato T, et al. Expanded use of transplantation techniques: abdominal wall transplantation and intestinal autotransplantation. *Transplant Proc*. 2004;36(5):1561–3. <https://doi.org/10.1016/j.transproceed.2004.05.037>.
 21. Gerlach UA, Pascher A. Technical advances for abdominal wall closure after intestinal and multivisceral transplantation. *Curr Opin Organ Transplant*. 2012;17(3):258–67. <https://doi.org/10.1097/MOT.0b013e3283534d7b>.
 22. Grajek M, Maciejewski A, Giebel S, et al. First complex allotransplantation of neck organs. *Ann Surg*. 2017;266(2):e19–24. <https://doi.org/10.1097/SLA.0000000000002262>.
 23. Selber JC, Chang EI, Clemens MW, et al. Simultaneous scalp, skull, kidney, and pancreas transplant from a single donor. *Plast Reconstr Surg*. 2016;137(6):1851–61. <https://doi.org/10.1097/PRS.00000000000002153>.
 24. Jones TR, Humphrey PA, Brennan DC. Transplantation of vascularized allogeneic skeletal muscle for scalp reconstruction in a renal transplant patient. *Transplantation*. 1998;65(12):1605–1610. <http://www.ncbi.nlm.nih.gov/pubmed/9665077>. Accessed Dec 3, 2017.
 25. Özkan Ö, Özkan Ö, Doğan U, et al. Consideration of difficulties and exit strategies in a case of face allotransplantation resulting in failure. *Microsurgery*. 2017;37(6):661–8. <https://doi.org/10.1002/micr.30137>.
 26. Cavadas PC, Ibez J, Thione A. Surgical aspects of a lower face, mandible, and tongue allotransplantation. *J Reconstr Microsurg*. 2012;28(1):43–7. <https://doi.org/10.1055/s-0031-1284236>.
 27. Redett RJ, Etra JW, Brandacher G, et al. Total penis, scrotum, and lower abdominal wall transplantation. *N Engl J Med*. 2019;381(19):1876–8. <https://doi.org/10.1056/NEJMc1907956> **Case report from Johns Hopkins team detailing combined penis, scrotum and abdominal wall transplant, a new indication for partial or total AW-VCA.**
 28. Cetrulo CL, Li K, Salinas HM, et al. Penis transplantation. *Ann Surg*. 2018;267(5):983–8. <https://doi.org/10.1097/SLA.0000000000002241>.
 29. Light D, Kundu N, Djohan R, et al. Total abdominal wall transplantation: an anatomical study and classification system. In: *Plastic and Reconstructive Surgery*. Vol 139. Lippincott Williams and Wilkins; 2017:1466–1473. <https://doi.org/10.1097/PRS.0000000000003327>.
 30. Atia A, Hollins A, Shammam R, et al. Surgical techniques for Revascularization in abdominal wall transplantation. *J Reconstr Microsurg*. 2020;36(7):522–7. <https://doi.org/10.1055/s-0040-1709481>.
 31. Ruiz P, Bagni A, Brown R, et al. Histological criteria for the identification of acute cellular rejection in human small bowel allografts: Results of the pathology workshop at the VIII International Small Bowel Transplant Symposium. In: *Transplantation Proceedings*, vol. 36; 2004. p. 335–7. <https://doi.org/10.1016/j.transproceed.2004.01.079>.
 32. Cendales LC, Kanitakis J, Schneeberger S, et al. The Banff 2007 Working classification of skin-containing composite tissue allograft pathology. *Am J Transplant*. 2008;8(7):1396–400. <https://doi.org/10.1111/j.1600-6143.2008.02243.x>.
 33. Abu-Elmagd KM, Costa G, Bond GJ, et al. Five hundred intestinal and multivisceral transplantations at a single center. *Trans Meet Am Surg Assoc*. 2009;250(4):567–81. <https://doi.org/10.1097/SLA.0b013e3181b67725>.
 34. Petruzzo P, Sardu C, Lanzetta M, Dubernard JM. Report (2017) of the International Registry on Hand and Composite Tissue Allotransplantation (IRHCTT). *Curr Transplant Rep*. 2017;4(4):294–303. <https://doi.org/10.1007/s40472-017-0168-3>.
 35. Berglund E, Andersen Ljungdahl M, Bogdanović D, et al. Clinical significance of alloantibodies in hand transplantation: a multicenter study. *Transplantation*. 2019;103(10):2173–82. <https://doi.org/10.1097/TP.0000000000002650>.
 36. Duhamel P, Suberbielle C, Grimbert P, et al. Anti-HLA sensitization in extensively burned patients: Extent, associated factors, and reduction in potential access to vascularized composite allotransplantation. *Transpl Int*. 2015;28(5):582–93. <https://doi.org/10.1111/tri.12540>.
 37. Chandraker A, Arscott R, Murphy G, et al. Face transplantation in a highly sensitized recipient. *Mil Med*. 2016;181(5S):221–6. <https://doi.org/10.7205/milmed-d-15-00136>.
 38. Gerlach UA, Vrakas G, Holdaway L, et al. Skype clinics after intestinal transplantation – follow-up beyond post codes. *Clin Transpl*. 2016;30(7). <https://doi.org/10.1111/ctr.12745>.
 39. Pinderski LJ, Kirklín JK, McGiffin D, et al. Multi-organ transplantation: is there a protective effect against acute and chronic rejection? *J Heart Lung Transplant*. 2005;24(11):1828–33. <https://doi.org/10.1016/j.healun.2005.03.015>.

40. Rana A, Robles S, Russo MJ, et al. The combined organ effect. *Ann Surg*. 2008;248(5):871–9. <https://doi.org/10.1097/SLA.0b013e31817fc2b8>.
41. Ng ZY, Lellouch AG, Rosales IA, et al. Graft vasculopathy of vascularized composite allografts in humans: a literature review and retrospective study. *Transpl Int*. 2019;32(8):tri.13421. <https://doi.org/10.1111/tri.13421>.
42. Kumnig M, Jowsey SG, Moreno E, Brandacher G, Azari K, Rumpold G. An overview of psychosocial assessment procedures in reconstructive hand transplantation. *Transpl Int*. 2014;27(5):417–27. <https://doi.org/10.1111/tri.12220>.
43. Coffman KL. Psychological and psychosocial aspects of face transplantation. In: *Psychosocial Care of End-Stage Organ Disease and Transplant Patients*: Springer International Publishing; 2019. p. 353–63. https://doi.org/10.1007/978-3-319-94914-7_34.
44. Ambrose T, Holdaway L, Smith A, et al. The impact of intestinal transplantation on quality of life. *Clin Nutr*. 2019. <https://doi.org/10.1016/j.clnu.2019.08.023>.

Publisher's Note Springer Nature remains neutral with regard to jurisdictional claims in published maps and institutional affiliations.