

University of Groningen

Are there any benefits of using an inlay graft in the treatment of primary hypospadias in children?

Silay, Mesrur Selcuk; 't Hoen, Lisette; Bhatt, Nikita; Quaedackers, Josine; Bogaert, Guy; Dogan, Hasan Serkan; Nijman, Rien J M; Rawashdeh, Yazan; Stein, Raimund; Tekgul, Serdar

Published in:
Journal of Pediatric Urology

DOI:
[10.1016/j.jpurol.2021.02.013](https://doi.org/10.1016/j.jpurol.2021.02.013)

IMPORTANT NOTE: You are advised to consult the publisher's version (publisher's PDF) if you wish to cite from it. Please check the document version below.

Document Version
Publisher's PDF, also known as Version of record

Publication date:
2021

[Link to publication in University of Groningen/UMCG research database](#)

Citation for published version (APA):

Silay, M. S., 't Hoen, L., Bhatt, N., Quaedackers, J., Bogaert, G., Dogan, H. S., Nijman, R. J. M., Rawashdeh, Y., Stein, R., Tekgul, S., & Radmayr, C. (2021). Are there any benefits of using an inlay graft in the treatment of primary hypospadias in children? A systematic review and metanalysis. *Journal of Pediatric Urology*, 17(3), 303-315. <https://doi.org/10.1016/j.jpurol.2021.02.013>

Copyright

Other than for strictly personal use, it is not permitted to download or to forward/distribute the text or part of it without the consent of the author(s) and/or copyright holder(s), unless the work is under an open content license (like Creative Commons).

The publication may also be distributed here under the terms of Article 25fa of the Dutch Copyright Act, indicated by the "Taverne" license. More information can be found on the University of Groningen website: <https://www.rug.nl/library/open-access/self-archiving-pure/taverne-amendment>.

Take-down policy

If you believe that this document breaches copyright please contact us providing details, and we will remove access to the work immediately and investigate your claim.



Review Article

Are there any benefits of using an inlay graft in the treatment of primary hypospadias in children? A systematic review and metanalysis



^aDivision of Pediatric Urology,
Department of Urology, Biruni
University, Istanbul, Turkey

^bErasmus MC, Department of
Urology, Rotterdam, the Netherlands

^cUrology Registrar, East of England
Deanery, Cambridge, United
Kingdom

^dDepartment of Urology and
Pediatric Urology, University Medical
Centre Groningen, University of
Groningen, the Netherlands

^eDepartment of Urology, University
of Leuven, Belgium

^fDivision of Pediatric Urology,
Department of Urology, Hacettepe
University, Ankara, Turkey

^gDepartment of Urology, Aarhus,
Denmark

^hDepartment of Pediatric,
Adolescent and Reconstructive
Urology, University of Medical Center
Mannheim, Medical Faculty
Mannheim, Heidelberg University,
Mannheim, Germany

ⁱDepartment of Urology, Medical
University of Innsbruck, Austria

* Correspondence to: Mesrur
Selcuk Silay, FEBU, FEAPU
Division of Pediatric Urology,
Department of Urology, Biruni
University, 10, Yil Caddesi,
Protokol Yolu, No: 45, 34010,
Topkapi, Istanbul, Turkey.
Office: +90 505 6454005; Fax:
+90 212 4164646
selcuksilay@gmail.com (M.S.
Silay)

Keywords
Hypospadias; Inlay; Graft;
Pediatrics

Received 8 October 2020
Revised 16 January 2021
Accepted 12 February 2021
Available online 19 February
2021

Mesrur Selcuk Silay ^{a,*}, Lisette 't Hoen ^b, Nikita Bhatt ^c,
Josine Quaedackers ^d, Guy Bogaert ^e, Hasan Serkan Dogan ^f,
Rien J.M. Nijman ^d, Yazan Rawashdeh ^g, Raimund Stein ^h,
Serdar Tekgul ^f, Christian Radmayr ⁱ

Summary

Introduction

Dorsal inlay graft urethroplasty (DIGU) has been described as an effective method for hypospadias repair with the proposed advantage of reducing the risk of complications. We aimed to systematically assess whether DIGU has any additional advantages over standard tubularized incised plate urethroplasty (TIPU) repair in children with primary hypospadias.

Materials and methods

This systematic review was performed according to the Preferred Reporting Items for Systematic Reviews and Meta-Analyses (PRISMA) Statement. The a priori protocol is available at the PROSPERO database (CRD42020168305). A literature search was conducted for relevant publications from 1946 until January 10, 2020 in seven different databases. Randomized controlled trials (RCTs), comparative studies (TIPU vs DIGU) and single arm case series (>20 cases) of DIGU were eligible for inclusion. Secondary hypospadias, two-stage repairs, disorders of sex development, significant curvature of >30°,

and a mean or median follow-up of less than 12 months were excluded.

Discussion

A total of 499 articles were screened and 14 studies (3 RCTs, 5 non-randomized studies (NRSs), and 6 case series) with a total of 1753 children (distal: 1334 (76%) and proximal: 419 (24%)) were found eligible. Mean follow-up of the studies was between 16 and 77 months. DIGU was found superior to TIPU in decreasing meatal/neourethral stenosis ($p = 0.02$, 95% CI 0.02–0.78). All other parameters were found comparable including overall complications, fistula and glans dehiscence rates. Success rates were similar among the groups ranging between 48% and 96% for DIGU and 43–96% in the TIPU group. The lack of standardization in the definition of complications and success was the major limitation of this study.

Conclusions

Using an inlay graft during primary hypospadias repair decreases the risk of meatal/neourethral stenosis. However, current evidence does not demonstrate superiority of DIGU over TIPU in terms of treatment success and overall complication rates.

Introduction

Tubularized incised plate urethroplasty (TIPU) has become the most popular technique for repairing distal hypospadias at many institutions over the last two decades. It can also be applied in some cases of proximal hypospadias with minimal chordee where the urethral plate is not transected [1]. Although this technique is easily applicable with good cosmetic results, several complications, including meatal and/or neourethral stenosis, have been reported [1].

Dorsal inlay graft urethroplasty (DIGU), using an inner preputial free graft in the dorsal incision of the standard TIPU technique, has been described as an effective method for hypospadias repair with the proposed advantage of reducing the risk of meatal/neourethral stenosis [2]. DIGU is an addition to standard TIPU technique with the aim of improving the healing process of the incised urethra. The authors hypothesized that leaving a large denuded surface in the neourethra that reepithelializes and scars could be the leading factor for meatal/neourethral

stenosis. With the insertion of a free inlay graft they aimed to preserve the urethral plate and increase the area of the healthy tissue. Since this modification was first reported in 2000, many other studies including randomized controlled trials have been published [2].

In one of the randomized controlled trials (RCT's) by Mouravas et al. fifty consecutive patients with pathology ranging from glanular to proximal penile hypospadias were randomized into two groups, comparable for age and pathology, to be operated on either with standard TIPU or with DIGU procedure [3]. DIGU procedure had a significantly smaller number of unsatisfactory results compared to TIPU procedure. No cases of stenosis were detected after DIGU procedure.

In another non-randomized comparative study by Smitakahara et al. 100 primary hypospadias patients were analyzed [4]. Outcomes of 50 cases with DIGU vs 50 cases with standard TIPU procedure were compared. The stenosis rates were lower in DIGU group compared to TIPU procedure at a mean follow up of 3.6 years.

In contrast, in another recent RCT by Helmy et al., no difference was observed between the two techniques in patients with primary distal hypospadias [5]. There are many other studies published on this topic and a systematic review/metaanalysis (SR/MA) can elucidate whether insertion of an inlay graft is beneficial or not.

With this comprehensive systematic review and meta-analysis we aim to evaluate whether DIGU has an advantage over standard TIPU repair in children with primary hypospadias.

Evidence acquisition

Search strategy

This systematic review was performed according to the Preferred Reporting Items for Systematic Reviews and Meta-Analyses (PRISMA) Statement. The a priori protocol is available at the PROSPERO database (CRD42020168305). A systematic literature search was conducted for relevant publications from 1946 until January 10, 2020 in the following databases: Embase, MEDLINE, Cochrane SRs, Cochrane Central, Cochrane HTA, Clinicaltrial.gov, and World Health Organization (WHO) International Clinical Trials Registry Platform Search Portal. We manually searched the reference lists of included studies and relevant review articles. The complete search strategy is available at the PROSPERO database.

We used the string terms hypospadias AND inlay AND pediatrics or synonyms of this. There was no limitation for publication time and no language limitations. Three authors (JQ, LH, NB) independently screened the titles and abstracts of identified records for eligibility. Full-texts were retrieved for all potentially eligible studies and these were again independently reviewed by three authors (JS, LH, NB). Any disagreement was resolved by an independent fourth party (SS).

Types of study designs

The eligibility criteria and relevant confounders were identified during a consensus meeting of the European

Association of Urology (EAU) Pediatric Urology guidelines panel. RCTs, comparative studies (TIPU vs DIGU) and single arm case series (>20 cases) of DIGU were eligible for inclusion. Systematic and narrative reviews were excluded, but used for the discussion.

Types of participants

Patients had to be children (<18 years of age) with primary hypospadias at any location, surgically corrected by DIGU or in comparative studies by TIPU. Exclusion criteria were: secondary hypospadias, two-stage repairs, disorders of sex development, significant curvature of >30°, mean or median follow-up of less than 12 months.

Types of interventions

Experimental intervention was primary hypospadias repair with inlay graft (DIGU). The type of inlay grafts included were: preputial skin, lingual and buccal mucosa. This intervention was compared to control a group of primary hypospadias repair without inlay graft (TIPU).

Types of outcome measures

The primary outcomes for this study were: success rate (as defined by trialists) of DIGU (benefit) and meatal/neourethral stenosis of DIGU (harm). The secondary outcomes of interest were cosmetics, fistula, glans dehiscence, re-operation rate, other complications including persistent curvature, total breakdown, skin necrosis etc., also compared to TIPU. Two relevant confounders were identified: type of inlay graft (buccal, lingual, preputial) and severity of hypospadias (distal or proximal).

Assessment of risk of bias

Two authors (LH and NB) independently assessed the risk of bias for each included study. For the RCTs the recommended tools in the Cochrane Handbook for Systematic Reviews of Interventions were used [6]. The following was assessed: random sequence generation; allocation concealment; blinding of participants and personnel; blinding of outcome assessment; incomplete outcome data; selective reporting; and other sources of bias. For the comparative studies and case series three issues were considered: the presence of an a priori protocol, was the total eligible population included and recruited consecutively, were the primary harm and benefit outcomes appropriately measured. Finally, for each of the identified confounders we evaluated whether they were considered and if so, if they were controlled for.

Data analysis

The study characteristics are described for continuous data as mean \pm SD and median (range) and for categorical data as counts. The numbers and percentages of treatment success rate and meatal/neourethral stenosis as well as all

secondary outcomes were extracted from the included studies.

A meta-analysis was performed for the following outcomes of the three included RCTs: success rate, meatal/neourethral stenosis, fistula, re-operation rate and glans dehiscence.

A narrative synthesis of the data was performed for the non-RCTs with odds ratios (ORs) for categorical outcomes and mean difference with 95% confidence intervals to report continuous outcomes. The number of total complications was represented in a forest plot without meta-analysis to show a visual result in comparison to the results of the RCTs.

Meta-analysis was intended for the total complication rates. However, due to the lack of this evidence in the RCT's, some of the additional data from Non randomized studies (NRS) have been represented in Forest plots without meta-analysis (due to methodological heterogeneity and the high risk of bias).

Evidence synthesis

Quantity of evidence identified

The PRISMA flow diagram demonstrates our search and selection process (Fig. 1). We screened a total of 499

abstracts and titles, and retrieved 28 articles for full-text screening. We found 14 eligible studies with a total of 1753 children (RCTs: 167, non-randomized studies (NRSs): 908, case series: 678). This included 3 RCTs, 5 NRSs, and 6 case series.

Characteristics of the included studies

The baseline characteristics of all included studies are presented in Table 1. Of the 1753 patients who underwent a primary hypospadias repair, 1334 (76%) were distal and 419 (24%) were proximal. In the intervention group (DIGU), the type of graft was preputial in 12 studies, only one single arm study reported the use of a lingual graft [7] and one NRS study reported a subgroup with buccal mucosal graft [8].

Characteristics of RCT's

There were 3 included RCTs, their comparison parameters are listed in Table 1 [3,5,9]. All three studies used preputial grafts in the intervention group. Two of the studies only included distal hypospadias and one study [3] included 12 patients with proximal hypospadias (one stage repair) that were randomized in equal numbers in the intervention and control groups.

Two studies clearly defined the primary outcome or success [5,9] while one did not report this explicitly and

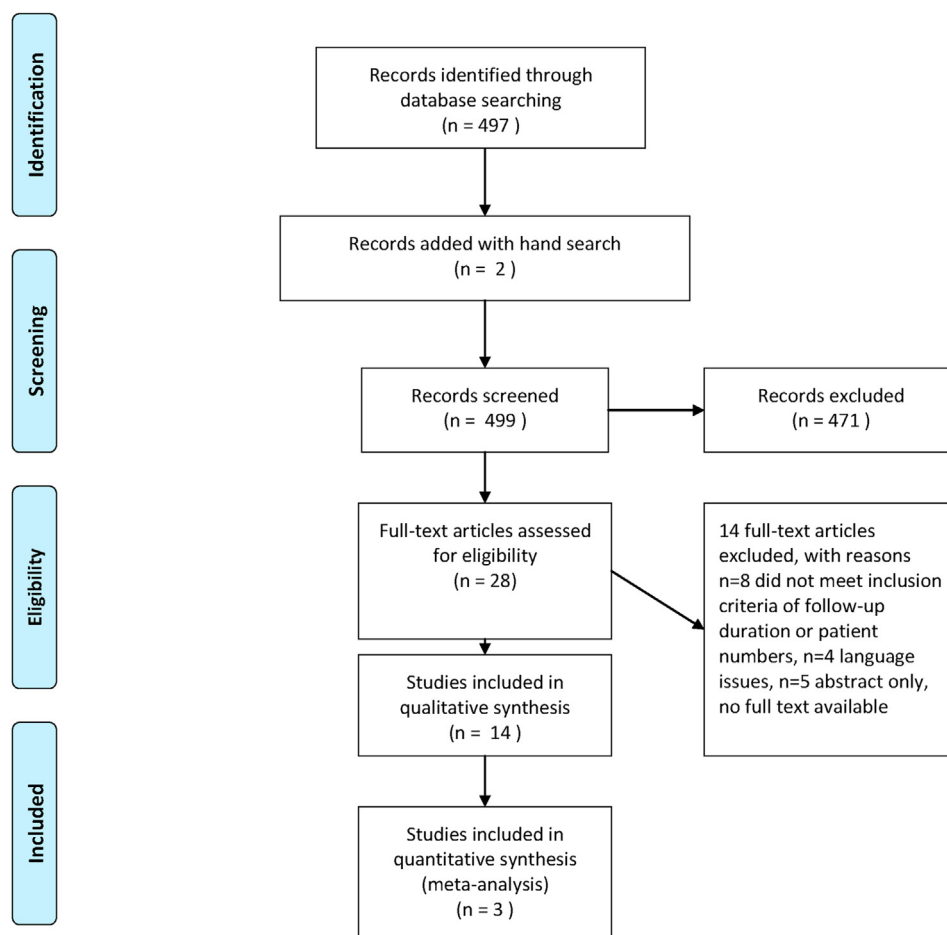


Fig. 1 Prisma flow diagram.

Table 1 Baseline characteristics of all included studies.

Study characteristics		Intervention type	Study criteria		Primary hypospadias type -DIGU		Primary hypospadias type -Control TIPU		Followup period mean (range) months	Age	
Study ID and year	Design	DIGU inlay graft type	Inclusion criteria	Exclusion criteria	Distal (n)	Proximal (n)	Distal (n)	Proximal (n)		Intervention	Control
Ahmed 2015	Prospective single arm	Preputial	Consecutive patients, underwent combined inner preputial inlay graft with TIPU	NR	225	5	0	0	17.5 (5–36)	mean 3.2 (11 month –10 yrs)	
Asanuma 2007	Retrospective single arm	Preputial	Primary hypospadias repair	Deep groove and no severe curvature	19	9	0	0	22 (13–31)	21 months (14 months –4.6 yrs)	
Eldeeb 2020	Prospective RCT	Preputial	Children age 4–24 months, distal penile hypospadias, urethral plate <8 mm, glans width >14 mm before incision, primary non-circumcised	Proximal and midpenile hypospadias, glandular hypospadias, curvature of >30° after penile degloving, shallow urethral plate, history of Testosterone supplementation	30	0	30	0	16 (2–24)	13 (5–24) months	12 (6–24) months
Elsayed 2015	Retrospective single arm	Lingual	Distal hypospadias, with a urethral plate of less than 8 m, 3 had previous hypospadias surgery	NR	23	0	0	0	25.4 (18–36)	mean 2.3 ± 0.5 (range 1–3 yrs)	
Gupta 2016	Prospective single arm	Preputial	Primary hypospadias, minimal FU of 3 months	NR	257	6	0	0	Median 17 (6–22)	15 (11–72) months	
Helmy 2018	Prospective RCT	Preputial	Age <5 yrs, distal hypospadias (subcoronal and distal shaft), primary, uncircumcised, no or mild chordee (<30°)	Recurrent, circumcised, severe chordee, narrow urethral plate (<8 mm)	30	0	30	0	40 ± 15	41.9 ± 16 months	39.1 ± 15 months
Kolon 2007	Retrospective single arm	Preputial	Not specifically reported	NR	11	21	0	0	21 (3–37)	mean 10 (6 months10 yrs)	
Mouravas 2014	Prospective RCT	Preputial	Glanular to proximal primary hypospadias, having their preputial hood intact, no dermatological pathology of the genitalia	Failure to re-examination protocol	18	6	17	6	76.8 (24–60)	3.5 years (10 months9.4 yrs)	3.4 years (9 months-9.6 yrs)
Pippi Salle 2016	Retrospective non randomised comparative	Preputial	all patients with proximal primary hypospadias	One-stage island flap repairs	0	23	0	117	29.6 (6–127)	mean 15.3 months	mean 17.6 months
Rober 1990	Retrospective non randomised comparative	Preputial	All primary hypospadias repairs performed between 1981 and 1988 using a free graft technique	NR	37	Total 34 proximal and 47 distal		44	min 12 (max 240)	10 months - 11 yrs	

Author	Study Design	Intervention	Comparison	Primary Outcome	Secondary Outcome	Number of Patients	Number of Events	Mean Follow-up (yrs)
Seleim 2019	Prospective non randomised comparative	Preputial	Preputial	All consecutive children with distal penile hypospadias in the presence of a narrow urethral plate (defined as <8 mm pre-incision subcoronal plate width)	Non preservable plate (ie significant chordee), circumcised cases, redo cases	81	0	mean 1.08 ± 0.365 yrs
Shuzhu 2016	Retrospective non randomised comparative	Preputial	Preputial	Primary distal hypospadias, who had mild or no chordee and good penile development	NR	89	78	1.2 yrs (6months - 3yrs)
Silay 2012	Retrospective single arm	Buccal	Preputial	Primary distal hypospadias, who had mild or no chordee and good penile development	Proximal hypospadias, severe chordee, micropenis and circumcised penis	101	0	mean 7.26 (1-17) yrs
Singh-Pavithran 2004	Retrospective non randomised comparative	Preputial	Preputial	Primary distal hypospadias	Those with chordee, proximal hypospadias, previous urethroplasty	25	0	3 (2-11) yrs

success was defined as lack of complications [3]. One study reported all the secondary outcomes [3] while two studies did not report reoperation rates [5,9]. One of the RCTs [5] reported on maximum flow rate on postoperative uroflow (Qmax). The baseline characteristics of the RCTs are summarized in Table 1.

Characteristics of NRS’s

A total of 5 NRSs (1 prospective [10] and 4 retrospective studies [8,10-13]) including 908 patients met the inclusion criteria. Two of the studies included distal hypospadias only [10,11], one study included proximal hypospadias [12] only and two included both distal and proximal hypospadias [8,13]. All the NRS studies used preputial grafts with the exception of one study with two intervention groups, one of which included a buccal graft [8]. Four studies did not report a specific definition for success, while one study defined success as lack of complications [8]. All secondary outcomes were reported by 3 NRS while 1 NRS did not report reoperation rate and glans dehiscence [11] and one did not report on re-operation rates [8]. Two studies reported on other complications such as superficial necrosis [11], complete dehiscence and recurrence of ventral curvature [12]. The definitions of success as complications were variable in all studies as well as the inclusion and exclusion criteria that are reported in Tables 1 and 2.

Characteristics of case series

A total of 6 case series (2 prospective [14,15] and 4 retrospective [2,7,16,17]) including 678 patients met the inclusion criteria. All the studies except one included preputial grafts, lingual grafts were used in this study [7]. Four studies included proximal and distal hypospadias [2,14-16] while remaining two studies only included distal hypospadias [7,17]. Three studies did not report a definition for success [2,16,17], one study reported this as cure with no complications as success [7], one reported excellent cosmetic and functional results as success [14] and one study reported this as a HOSE (hypospadias objective scoring evaluation) score of >14 [15]. Four studies reported on all secondary outcomes [2,7,16,17], one study did not report the cosmetic outcome [14] and one did not report the glans dehiscence rates. Other secondary complications such as ventral shaft skin breakdown [2] and complete graft loss and repair disruption after infection [7] were reported by one study each.

Risk of bias summary for the included studies

Fig. 2 demonstrates the risk of bias summary and confounding assessments for the 14 included studies. A low risk of selection bias was present for the three included RCTs, whereas a high risk was present for the remaining studies. A low risk of performance bias and a high risk of detection bias were present for two of the included RCTs. Attrition bias and reporting bias were at low risk in half the studies and unclear risk in the remainder. There was a low risk for confounders overall, with five studies reporting high risk of bias for confounder severity of hypospadias (distal, proximal).

	Random sequence generation (selection bias)	Allocation concealment (selection bias)	Blinding of participants and personnel (performance bias)	Blinding of outcome assessment (detection bias)	Was there an apriori protocol?	Was the total eligible population included and recruited consecutively?	Were the primary harm and benefit outcomes appropriately measured?	Incomplete outcome data (attrition bias)	Selective reporting (reporting bias)	Severity of hypospadias (distal, proximal)	Type of inlay graft (preputial, buccal, lingual etc.)
Ahmed 2015	-	-	-	-	?	+	+	?	?	+	+
Asanuma 2007	-	-	-	-	-	?	+	?	?	-	+
Eldeeb 2020	+	+	+	+	+	+	+	+	+	+	+
Elsayed 2015	-	-	-	-	-	?	+	?	?	+	+
Gupta 2016	-	-	-	-	-	-	?	+	+	?	+
Helmy 2018	+	+	+	-	+	?	?	?	?	+	+
Kolon 2007	-	-	-	-	-	?	+	?	?	-	+
Mouravas 2014	+	-	-	-	+	+	+	+	+	+	+
Pippi Salle 2016	-	-	-	-	+	?	+	+	+	+	+
Rober 1990	-	-	-	-	-	?	+	?	?	+	+
Seleim 2019	-	-	-	-	?	+	+	+	+	-	+
Shuzhu 2016	-	-	-	-	+	+	+	+	+	-	-
Silay 2012	-	-	-	-	+	+	+	+	+	+	+
Singh-Pavithran 2004	-	-	-	-	-	?	+	?	?	-	+

Fig. 2 Risk of bias (RoB) summary for 14 included studies.

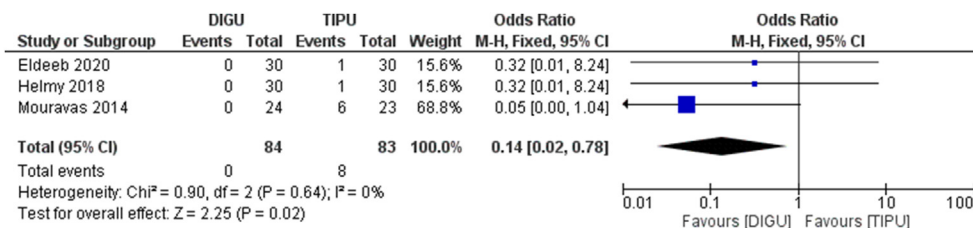


Fig. 3 Forest plot demonstrating meatal/neourethral stenosis.

Outcomes of included studies

The outcome results of 14 studies are summarized and demonstrated in Table 2.

Treatment success

The definition of success in 14 of the included studies was variable and included lack of complications, excellent functional and cosmetic outcome, slit shaped meatus and HOSE score >14. Success rates were between 48% and 96% in

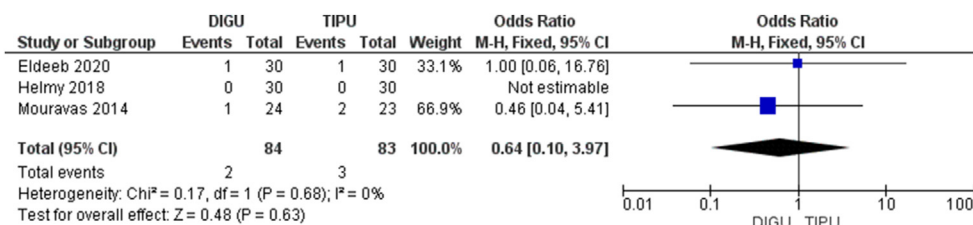


Fig. 4 Forest plot demonstrating fistula.

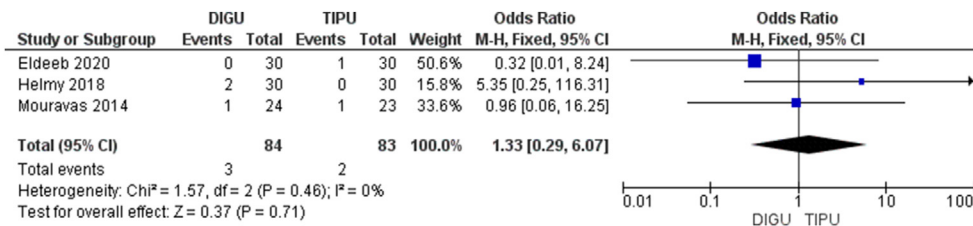


Fig. 5 Forest plot demonstrating glans dehiscence.

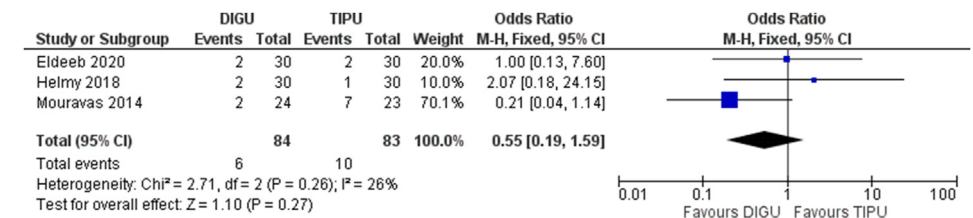


Fig. 6 Forest plot demonstrating overall complications of RCTs.

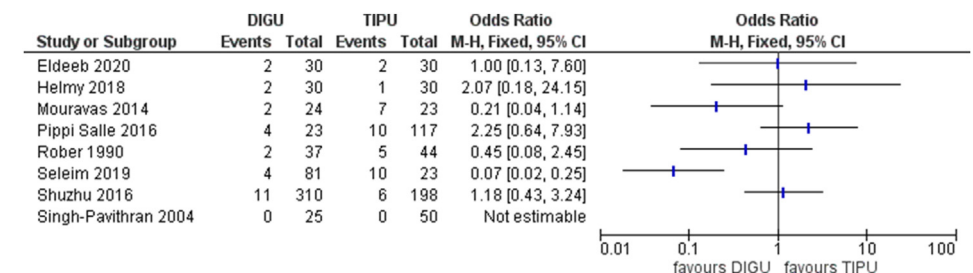


Fig. 7 Forest plot demonstrating overall complications of RCT's and NRS's.

Table 2 Summary of Findings table including all studies.

Study ID and year	Primary Outcomes				Secondary outcomes										Authors conclusion	
	Success rate N (%)		Meatal/neourethral stenosis N (%)		Cosmetics unfavourable N (%)	Fistula N (%)	Glans dehiscence N (%)	Re-operation N (%)	Other complications including persistent curvature, total breakdown, bleeding, skin necrosis etc.							
	Definition for cure or success	Inter-vention	Control	Inter-vention	Control	Inter-vention	Control	Inter-vention	Control	Inter-vention	Control	Inter-vention	Control	Inter-vention	Control	
Ahmed 2015	Excellent cosmetic and functional results	221/230 (96.09%)	N/A	0	N/A	NR	N/A	9/230 (3.9%)	N/A	0	N/A	8/230 (3.5%)	N/A	NR	N/A	Combined inner preputial graft with TIP urethroplasty secures the optimal glanular position of a wide slit-like neomeatus
Asanuma 2007	NR	27 pts had no complications (96.4%)	N/A	0	N/A	0	N/A	1/28 (3.6%)	N/A	0	N/A	1/28 (3.6%)	N/A	0	N/A	DIGU is an effective method for hypospadias repair and leads to good cosmetic outcome with low risk of complications
Eldeeb 2020	No complications	28 pts had no complication (93.3%)	28 pts had no complication (93.3%)	0	1/30 (3.33%)	2/30 (6.7%)	2/30 (6.7%)	1/30 (3.33%)	1/30 (3.33%)	1/30 (3.33%)	0	NR	NR	0	0	Snodgrass is not considered to be superior to Snodgrass regarding the success and occurrence of complications.
Elsayed 2015	Cured with no complications	20/23 (87%)	N/A	0	N/A	0	N/A	3/20 (13%)	N/A	0	N/A	3/20 (13%)	N/A	Complete graft loss: 1 = 4.3%, Repair disruption following infection: 1 = 4.3%	N/A	One-stage lingual graft urethroplasty offers promising outcomes for the repair of distal penile hypospadias with a narrow urethral plate.
Gupta 2016	HOSE score of >14	252/263 (96%)	N/A	1/263 = 0.04%	N/A	11/263 (4%)	N/A	10/263 (3.7%)	N/A	NR	N/A	9/263 (3.4%)	N/A	NR	N/A	The G-TIP repair is a straightforward and feasible technique facilitating reconstruction of an apical neomeatus with an optimum outcome based on HOSE scoring.
Helmy 2018	As slit shaped meatus at the tip of the glans with no stenosis, fistula or diverticulum	28/30 (93.3%)	29/30 (96.7%)	0	1/30 (3.33%)	3/30 (10%)	0	0	0	2/30 (6.7%)	0	NR	NR	Qmax 11.6 ± 3	Qmax 11.2 ± 5	Snodgrass and GTIP techniques for primary distal hypospadias repair have similar outcome.
Kolon 2007	NR	30/32 pts had	N/A	0	N/A	0	N/A	0	N/A	1/32	N/A	2/32 (6.2%)	N/A	1/32 (3.1%)	N/A	

		no complications during follow-up (94%)											ventral shaft skin breakdown			
Mouravas 2014	NR	22/24 pts had no complications (92.67%)	16/23 pts had no complications (70%)	0	6/23 (26%)	0	0	1/24 (4.1%)	2/23 (8.7%)	1/24 (4.1%)	1/23 (4.3%)	1/24 (4.1.7%)	3/23 (13%)	0	0	The G-TIP procedure results in lower complication rates and this outweighs the extra operative time.
Pippi Salle 2016	NR	11/23 pts had no complications (47.90%)	TIP: 22/57 pts had no complications = 38.6%; SR: 37/60 pts had no complications (61.7%)	4/23 (17.3%)	TIP: 9/57 (15.7%); SR: 1/60 (1.6%)	0	0	3/23 (13%)	TIP: 18/57 (31.5%); SR: 7/60 (11.6%)	TIP: 3/57 (5.2%); SR: 7/60 (11.6%)	12/23 (52.10%)	TIP: 30/57 (52.6%); SR: 19/60 (31.6%)	Complete dehiscence 4/23 (17.3%); Recurrence of ventral curvature 4/23 (17.3%)	Complete dehiscence 4/57 (7%); Recurrence of VC 8/57 (14%), Diverticulum 1/57 (1.7%), SR: Complete dehiscence 3/60 (5%), Recurrence of VC 3/60 (5%), Diverticulum 1/60 (1.6%)	Urethro-cutaneous fistulae occur more commonly after TIP repair. TIP and DIG repairs had more meatal and urethral stenosis. (especially after urethral mobilization). Recurrence of ventral curvature after TIP and DIG seems to be a significant complication. Staged repairs resulted in overall better outcomes.	
Rober 1990	NR	18/37 pts had no complications (48.6%)	19/44 pts had no complications (43.2%)	2/37 (5.4%)	5/44 (11.4%)	0	0	17/37 (45.9%)	20/44 (45.5%)	0	0	14/37 (38%)	21/44 (47.7%)	0	0	Long term results with 1-stage repair have been excellent. The end results are a nearly normal functioning and appearing penis.
Seleim 2019	NR	73/81 pts had no complications (90%)	3/23 pts had no complications (13%)	4/81 (4.9%)	10/23 (43.5%)	0	0	2/81 (2.5%)	3/23 (13%)	0	0	4/81 (5%)	10/23 (43.4%)	0	0	4 mm width is the border line of clinical relevance that defines poor urethral plate.
Shuzhu 2016	Presence of complications (a whole list) and loss of a stent	Buccal: 141/150 (94%); Prepuce: 148/160 (92.5%)	186/198 = 93.9%	Buccal: 4/150 (2.7%); Prepuce: 7/160 (4.4%)	6/198 (3%); HOSE Score: 14.28; Prepuce: 14.25	HOSE score: 14.34	HOSE score: 5/150 (3.3%); Prepuce: 5/160 (3.1%)	Buccal: 6/198 (3.0%); Prepuce: 5/160 (3.1%)	0	0	NR, based on all fistulas and stenosis: Buccal: 9/150 (6%); Prepuce: 12/160 (7.5%)	NR based on fistulas and stenosis: Buccal: 9/150 (6%); Prepuce: 12/198 (6.1%)	0	0	0	As the inner foreskin Snodgrass does not appear to be worse than the buccal mucose graft, it is a good method for hypospadias repair, and this method is not inferior to TIP
Silay 2012	NR: lack of complications	92/102 (90.2%)	N/A	0	N/A	0	N/A	10/102 (9.8%)	N/A	0	N/A	10/102 (9.8%)	N/A	0	N/A	No meatal/neourethral stenosis was observed in any patient undergoing the snodgrass procedure.
Singh-Pavithran 2004	NR	NR	NR	0	TIP: 25/25 (100%);	NR	NR	4/25 (16%)	TIP: 5/25 (20%);	NR	NR	0	TIP: 1/25 (4%); TIP2: 1/4/25 (16%)	Superficial necrosis: 5/25 (20%), scrotal	The high incidence of meatal stenosis in TIP group was partly due to technical	

(continued on next page)

Table 2 (continued)

Study ID and year	Primary Outcomes		Secondary outcomes						Authors conclusion		
	Success rate N (%)	Definition for cure or success	Meatal/neourethral stenosis N (%)	Cosmetics unfavourable N (%)	Fistula N (%)	Glans dehiscence N (%)	Re-operation N (%)	Other complications including persistent curvature, total breakdown, bleeding, skin necrosis etc.			
	Inter-vention	Control	Inter-vention	Control	Inter-vention	Control	Inter-vention	Control	Inter-vention	Control	
			TIP2: 0		TIP2: 3/25 (12%)			25 (4%)		hematoma 1/25 (4%); TIP2: superficial necrosis 4/25 (16%)	errors and partly due to contraction of the raw area of the distal urethral plate at the glans apex. Adoption of one of the modifications can effectively prevent meatal stenosis.

NR: Not Recorded; N/A: Not available (in single-arm studies); DIGU: Dorsal Inlay Graft Urethroplasty; TIPU: Tubularized Incised Plate Urethroplasty; G-TIP: Grafted- Tubularized Incised Plate Repair; HOSE: Hypospadias Objective Scoring Evaluation.

the intervention group and ranged from 43 to 96% in the control group. It was not reported in eight of the included studies and lack of complications was taken as definition for success [2,3,10–13,16,17]. The difference in this primary outcome was not significant between DIGU and TIPU based on this. However, due to the variability of definition used and the imprecision in the included studies, the GRADE of this outcome is very low (Appendix 1).

Meatal/neourethral stenosis

Assessment of meatal stenosis in the 14 studies was variable and included either assessment using calibration of neomeatus using a blunt tip 6F bougie [11], feeding tube insertion [17] or 8-10F tiemann catheter [3]. Others used uroflow assessment with $Q_{max} < 10$ ml/min [12] or visual assessment of stream [10,11,15], use of voiding cystourethrography (VCUG) or retrograde urethrogram to assess for stricture [8,16] or simply need for urethral dilatations [7]. Five studies did not record a definition for meatal stenosis or stricture [2,5,9,13,14]. Rate of meatal stenosis ranged from 0 to 18% in the intervention group and 3–100% in control group. The forest plot in Fig. 3 demonstrates this difference was statistically significant in favour of the DIGU intervention group ($p = 0.02$). When only the distal cases are analyzed and the proximal cases are excluded, the outcome is still the same and the stenosis rate is significantly higher for TIPU when compared to DIGU ($p = 0.04$).

Fistula

The fistula assessment was undertaken visually in all studies, one study only included patients requiring further intervention only [8], while others included all fistula patients including those with spontaneous fistula resolution. The fistula rates in the intervention group varied from 0 to 46% and in the control group varied from 0 to 45%. The Forest plot using the three RCTs is displayed in Fig. 4, the difference between the DIGU and TIPU groups was not significant. The GRADE recommendation for this outcome was very low due to high risk of bias in the studies and level of imprecision.

Glans dehiscence

Two studies did not record glans dehiscence rates [11,15]. The rate varied from 0 to 7% in the DIGU group and 0–5% in the TIPU group. The forest plot for the RCTs shows no significant difference between the two groups (Fig. 5). The GRADE recommendation for this outcome was very low.

Cosmetic outcome

The cosmetic outcome was recorded in 12 studies [except 11, 14], it was objectively recorded using the HOSE score in two studies [8,15]. In other studies the evaluation was subjective by the parents and the clinician usually on the basis of a straight penis, external urethral meatus shape (slit/round) and location (apical/glanular) [3,5,9,10]. Some studies specifically defined a good cosmetic outcome as straight penis without dorsal plication of the corpora cavernosa and a slit-like appearance of the neomeatus with an acceptable cosmetic appearance of the penis [16,17]. In some studies this was not defined clearly [2,7,12,13]. The rate of unfavourable cosmetic outcome after DIGU repair ranged from 0 to 10% and in the TIPU group ranged from 0 to

7%. On metaanalysis of the RCTs this difference was not statistically significant on the forest plot. The GRADE recommendation for this outcome was very low due to similar reasons as above outcome.

Re-operation rates

The reoperation rate varied from 0 to 52% in the DIGU group and from 4 to 48% in the TIPU group. Three studies did not record the reoperation rate [5,8,9]. Reoperations included repair of fistula using primary closure, staged repair or flaps; correction of stenosis or stricture using urethral dilatation, internal urethrotomy or staged urethroplasty and correction of glans dehiscence. The forest plot on the RCTs (Fig. 7) shows the difference was not significant between the DIGU and TIPU groups, the GRADE of the recommendation was very low.

Other reported complications

Eleven studies [2,3,7–13,16,17] reported other complications including superficial necrosis, scrotal haematoma, complete dehiscence, recurrence of ventral curvature, diverticulum, complete graft loss and repair disruption after infection. The pooled rate of other complications varied from 0 to 17% in DIGU group and 0–20% in the TIPU group. One study reported the Qmax in both groups as no significant difference between the DIGU and TIPU groups [5]. It was not possible to meta-analyse this outcome as it was not reported by any of the other RCTs.

The overall complications were demonstrated as forest plot figures. The forest plot created using the metaanalysis of RCTs is in Fig. 6 while a forest plot including all RCTs and NRS comparative studies is in Fig. 7 for comparison.

Discussion

Principal findings

Our SR and MA elucidated many unanswered questions regarding the use of inlay graft during primary hypospadias repair.

First, the proposed advantage of DIGU for decreasing the risk of meatal/neourethral stenosis has been confirmed and statistically proven.

Second, the treatment success for both of the groups were found comparable in 3 available RCT's. When NRSs were added to the RCT's, DIGU demonstrated more favourable outcomes as shown in Fig. 7. However due to heterogeneity of the data we did not provide a statistical p value in order to avoid bias.

Third, the other complications including fistula and glans dehiscence were also found comparable for both of the groups.

A SR and MA on this same topic has been published recently [18]. However there are major differences between our article both in the methods and the outcomes as well. Alshafei et al. included 6 articles (2 RCT, 4 NRS) whereas we included 14 articles (3 RCT, 5NRS, 6 case series). In their study, pooled analysis was performed to analyse the postoperative outcomes related to low numbers of included studies. However in our article, we have created forest plots and assessed the odds ratios in order to

achieve more powerful statistical outcomes. Therefore although Alshafei et al. could not find any statistical difference for any of the parameters, we have clearly demonstrated that meatal/neourethral stenosis is lower for DIGU.

Implications for clinical practice

With this SR and MA, DIGU was found beneficial in terms of decreasing the risk of meatal/neourethral stenosis. However, at this stage DIGU was not found superior than TIPU procedure in the treatment of primary hypospadias repair. Treatment success and complication rates were found comparable.

Further research

The first aim of the upcoming researches should be the standardization of the terminology about reporting the outcomes. Needless to say that more high quality randomized controlled trials are required to compare the long term outcomes of using inlay graft and without inlay graft. A recent article has shown that contemporary hypospadias literature are below the suboptimal standards [19]. Although articles published after 2006 and with larger than 100 patients have higher quality, they are still below the standards according to the CONSORT (Consolidated standards of reporting trials) statement checklist. This low standard is also visible in articles published about inlay graft placement.

The type of the inlay graft, measurements of the urethral width, the depth of the incision plate, exact definition of urethral stenosis are some of the important points that require further research.

Limitations and strengths

There are many limitations and strengths of this SR and MA that needs to be taken into account. The major limitation was the heterogeneity of the definitions in included studies. This has led to an increase in the risk of bias (ROB) assessment as seen in Fig. 2.

The second most important limitation is the low numbers of RCT's included in the metaanalysis. Only 3 articles were included and this may lead to potential risk of bias in interpretation of the outcomes. It was not statistically possible to compare the type of the grafts (lingual, buccal, preputial) since the vast majority of the eligible studies included preputial grafts. Moreover it was not possible to perform a subgroup analysis for the position of the meatus (distal vs proximal).

The surgeon experience which is one of the most important predictors of success was not reported and could not be assessed. One might say that the depth of the incision, the width of the urethral plate, the dartos coverage of the tubularized urethra and many other surgical details may vary between the studies which can effect the outcomes directly.

The definition of the meatal/neourethral stenosis is not uniform in the eligible studies. In majority of the studies, the cosmetic outcomes were not reported with validated assessments such as HOSE or HOPE (hypospadias objective penile evaluation) scores.

On the other hand, our study has many strengths which enables the reflection of the best available evidence in the literature. Unlike the previously reported SR, we have included 3 RCT's where the forest plots were prepared from. In addition, we did not use pooled analysis which may lead to misinterpretation of the outcomes. Finally, our study has a priori protocol which was registered to PROSPERO database and the outcomes can guide the future research in this specific field.

Another strength was that, this SR and MA was performed by a group of experts including clinicians and methodologists (EAU Pediatric Urology Guideline Panel) according to PRISMA guidelines, and the results will be incorporated into the 2021 practice guidelines.

Conclusions

According to the contemporary evidence, which is robustly supported by the systematic assessment and meta-analysis, using an inlay graft during primary hypospadias repair decreases the risk of meatal/neourethral stenosis. However, current evidence does not demonstrate superiority of DIGU over TIPU in terms of treatment success and overall complication rates. There is a lack of well designed studies to recommend one technique over the other and therefore until future robust trials are available the choice of grafting is as per surgeon preference.

Conflicts of interest

None.

Acknowledgements

This systematic review was performed under the auspices of European Association of Urology and the European Society for Paediatric Urology, Pediatric Urology Guidelines Panel.

References

- [1] EAU/ESPU Guidelines EAU/ESPU guidelines on Pediatric urology in EAU Guidelines. Edn. Presented at the EAU Annual Congress Copenhagen. 2018. ISBN 978-94-92671-01-1.
- [2] Kolon TF, Gonzales ET. The dorsal inlay graft for hypospadias repair. *J Urol* 2000;194:1–3.
- [3] Mouravas V, et al. Urethral plate grafting improves the results of tubularized incised plate urethroplasty in primary hypospadias. *J Pediatr Urol* 2014;10:463–8.
- [4] Smitakahara, et al. Tubularized incised plate urethroplasty with dorsal inlay graft prevents meatal/neourethral stenosis: a single surgeon's experience. *J Pediatr Surg* 2011;46:2370–2.
- [5] Helmy TE, et al. Does grafted tubularized incised plate improve the outcome after repair of primary distal hypospadias: a prospective randomized study. *J Pediatr Surg* 2018;53:1461–3.
- [6] Deeks JJ, Higgins JPT, Altman DG. Chapter 9: Analysing data and undertaking meta-analyses. In: Higgins JPT, Green S, editors. *Cochrane Handbook for systematic Reviews of interventions* Version 5.1.0 (updated March 2011). The Cochrane Collaboration; 2011. Available from: www.cochrane-handbook.org.
- [7] Elsayed E, Dawod T, Abdalla M, et al. One-stage lingual augmented urethroplasty in repair of distal penile hypospadias. *Afr J Urol* 2015;21:6–9.
- [8] Shuzhu C, Min W, Yidong L, Weijing Y. Selecting the right method for hypospadias repair to achieve optimal results for the primary situation. *SpringerPlus* 2016;5:1624.
- [9] Eldeeb M, Nagla S, Hassan A, Abou-Farha M. Snodgrass versus snodgraft operation to repair the distal hypospadias in the narrow urethral plate. *J Pediatr Urol* 2020;16:165.
- [10] Seleim HM, ElSheemy MS, Abdalazeem Y, et al. Comprehensive evaluation of grafting the preservable narrow plates with consideration of native plate width at primary hypospadias surgery. *J Pediatr Urol* 2019;15:345.
- [11] Singh RB, Pavithran NM. Lessons learnt from Snodgrass tip urethroplasty: a study of 75 cases. *Pediatr Surg Int* 2004;20:204–6.
- [12] Pippi Salle JL, Sayed S, Salle A, et al. Proximal hypospadias: a persistent challenge. Single institution outcome analysis of three surgical techniques over a 10-year period. *J Pediatr Urol* 2016;12:28.
- [13] Rober PE, Perlmutter AD, Reitelman C. Experience with 81, 1-stage hypospadias/chordee repairs with free graft urethroplasties. *J Urol* 1990;144:526–9.
- [14] Ahmed M, Alsaïd A. Is combined inner preputial inlay graft with tubularized incised plate in hypospadias repair worth doing? *J Pediatr Urol* 2016;11:229.
- [15] Gupta V, Yadav SK, Alanzi T, Amer I, Salah M, Ahmed M. Grafted tubularised incised-plate urethroplasty: an objective assessment of outcome with lessons learnt from surgical experience with 263 cases. *Arab J Urol* 2016;14:299–304.
- [16] Asanuma H, Satoh H, Shishido S. Dorsal inlay graft urethroplasty for primary hypospadiac repair. *Int J Urol* 2007;14:43–7.
- [17] Silay MS, Sirin H, Tepeler A, et al. Snodgraft technique for the treatment of primary distal hypospadias: pushing the envelope. *J Urol* 2012;188:938–42.
- [18] Alshafei A, Cascio S, Boland F, O'Shea N, Hickey A, Quinn F. Comparing the outcomes of tubularized incised plate urethroplasty in children with hypospadias: a systematic review and meta-analysis. *J Pediatr Urol* 2020;16:154–61.
- [19] Braga LH, McGrath M, Easterbrook B, Jegatheeswaran K, Mauro L, Lorenzo AJ. Quality of reporting for randomized controlled trials in the hypospadias literature: where do we stand? *J Pediatr Urol* 2017;13:482.

Appendix 1 Dorsal inlay graft urethroplasty (DIGU) compared to Tubularized incised plate urethroplasty (TIPU) in Primary hypospadias: Summary of Findings.

Dorsal inlay graft urethroplasty (DIGU) compared to Tubularized incised plate urethroplasty (TIPU) in Primary hypospadias

Patient or population: Primary hypospadias

Setting:

Intervention: Dorsal inlay graft urethroplasty (DIGU)

Comparison: Tubularized incised plate urethroplasty (TIPU)

Outcomes	Anticipated absolute effects* (95% CI)		Relative effect (95% CI)	№ of participants (studies)	Certainty of the evidence (GRADE)
	Risk with Tubularized incised plate urethroplasty (TIPU)	Risk with Dorsal inlay graft urethroplasty (DIGU)			
Success	Study population 245 per 1000	166 per 1000 (130–210)	RR 0.68 (0.53–0.86)	1750 (3 RCTs, 5 comparative studies)	⊕⊕⊕⊕ VERY LOW ^{1 2}
Fistula	Study population 126 per 1000	115 per 1000 (81–164)	RR 0.91 (0.64–1.30)	1750 (3 RCTs, 5 comparative studies)	⊕⊕⊕⊕ VERY LOW ^{1 3}
Meatal Stenosis	Study population 124 per 1000	46 per 1000 (29–75)	OR 0.34 (0.21–0.57)	1750 (3 RCTs, 5 comparative studies)	⊕⊕⊕⊕ LOW ^{1 3 4}
Cosmetics unfavourable	Study population 4 per 1000	9 per 1000 (2–40)	OR 2.30 (0.50–10.64)	1750 (3 RCTs, 5 comparative studies)	⊕⊕⊕⊕ VERY LOW ^{1 3 5}
Glans dehiscence	Study population 23 per 1000	17 per 1000 (5–55)	OR 0.72 (0.21–2.44)	1750 (3 RCTs, 5 comparative studies)	⊕⊕⊕⊕ VERY LOW ^{1 3 5}
Reoperation rate	Study population 188 per 1000	141 per 1000 (98–200)	OR 0.71 (0.47–1.08)	1750 (13 RCTs, 5 comparative studies)	⊕⊕⊕⊕ VERY LOW ^{1 3 5}
Other complications pooled	Low 0 per 1000	0 per 1000 (0–0)	OR 1.71 (0.80–3.64)	270 (2 observational studies, 2 comparative studies)	⊕⊕⊕⊕ VERY LOW ^{1 5}

CI: Confidence interval; RR: Risk ratio; OR: Odds ratio.

GRADE Working Group grades of evidence.

High certainty: We are very confident that the true effect lies close to that of the estimate of the effect.**Moderate certainty:** We are moderately confident in the effect estimate: The true effect is likely to be close to the estimate of the effect, but there is a possibility that it is substantially different.**Low certainty:** Our confidence in the effect estimate is limited: The true effect may be substantially different from the estimate of the effect.**Very low certainty:** We have very little confidence in the effect estimate: The true effect is likely to be substantially different from the estimate of effect.

* The risk in the intervention group (and its 95% confidence interval) is based on the assumed risk in the comparison group and the relative effect of the intervention (and its 95% CI).

¹ Most studies have high risk bias.² definition of success was ver inconsistent.³ very large confidence intervals.⁴ stenosis not reported in all, inconsistently reported.⁵ not reported in all, inconsistent.