

University of Groningen

Migration After Endovasclar Aneurysm Sealing in Conjunction With Chimney Grafts

Zoethout, Aleksandra C.; Sheriff, Arshad; Zeebregts, Clark J.; Reijnen, Michel M. P. J.; Hill, Andrew; Holden, Andrew

Published in:
Journal of Endovascular Therapy

DOI:
[10.1177/1526602820957279](https://doi.org/10.1177/1526602820957279)

IMPORTANT NOTE: You are advised to consult the publisher's version (publisher's PDF) if you wish to cite from it. Please check the document version below.

Document Version
Publisher's PDF, also known as Version of record

Publication date:
2021

[Link to publication in University of Groningen/UMCG research database](#)

Citation for published version (APA):

Zoethout, A. C., Sheriff, A., Zeebregts, C. J., Reijnen, M. M. P. J., Hill, A., & Holden, A. (2021). Migration After Endovasclar Aneurysm Sealing in Conjunction With Chimney Grafts. *Journal of Endovascular Therapy*, 28(1), 165-172. <https://doi.org/10.1177/1526602820957279>

Copyright

Other than for strictly personal use, it is not permitted to download or to forward/distribute the text or part of it without the consent of the author(s) and/or copyright holder(s), unless the work is under an open content license (like Creative Commons).

The publication may also be distributed here under the terms of Article 25fa of the Dutch Copyright Act, indicated by the "Taverne" license. More information can be found on the University of Groningen website: <https://www.rug.nl/library/open-access/self-archiving-pure/taverne-amendment>.

Take-down policy

If you believe that this document breaches copyright please contact us providing details, and we will remove access to the work immediately and investigate your claim.

Downloaded from the University of Groningen/UMCG research database (Pure): <http://www.rug.nl/research/portal>. For technical reasons the number of authors shown on this cover page is limited to 10 maximum.

Migration After Endovascular Aneurysm Sealing in Conjunction With Chimney Grafts

Journal of Endovascular Therapy
 2021, Vol. 28(1) 165–172
 © The Author(s) 2020



Article reuse guidelines:

sagepub.com/journals-permissions

DOI: 10.1177/1526602820957279

www.jevt.org



Aleksandra C. Zoethout, MD^{1,2,3} , Arshad Sheriff, MBChB, FRANZCR¹,
 Clark J. Zeebregts, MD, PhD², Michel M. P. J. Reijnen, MD, PhD^{3,4} ,
 Andrew Hill, MBChB, FRACS¹, and
 Andrew Holden, MBChB, FRANZCR¹ 

Abstract

Purpose: To assess the incidence of migration after endovascular aneurysm sealing (EVAS) in conjunction with chimney grafts (chEVAS) for repair of abdominal aortic aneurysms (AAAs). **Materials and Methods:** A retrospective, observational cohort study was conducted of 31 patients (mean age 75.7 years; 27 men) treated for juxtarenal AAA between April 2013 and December 2018 at single centers in New Zealand and the Netherlands. The majority of patients received > 1 chimney graft (13 single, 13 double, and 5 triple) during chEVAS. Six patients had only the first postoperative scan, so the migration analysis was based on 25 patients. **Results:** Median seal length assessed on the first postoperative computed tomography scan was 36.5 mm. The assisted technical success rate was 93.5% with 2 technical failures. Median time to final imaging follow-up was 17 months in 25 patients. At the latest follow-up, there were no cases of caudal migration > 10 mm. Freedom from caudal movement of 5 to 9 mm was estimated as 86.1% at 1 year and 73.9% at 2 years; freedom from clinically relevant migration (movement requiring reintervention) was 100% at both time intervals. However, at 3 years there were 2 cases of caudal movement of 5 to 9 mm and a type Ia endoleak warranting reintervention. No correlation between migration and aneurysm growth ($p=0.851$), endoleak ($p=0.562$), or the number of chimney grafts ($p=0.728$) was found. During follow-up, 2 patients (7%) had aneurysm rupture and 10 (33%) had reinterventions. Eight patients (27%) died; 2 were aneurysm-related (7%) and due to the consequences of a reintervention. **Conclusion:** In the 2 years following chEVAS, there was no caudal migration > 10 mm, but nearly a quarter of patients had caudal movement of 5 to 9 mm. A trend was observed toward ongoing migration that required intervention at 3-year follow-up. chEVAS is technically challenging and should be considered only for patients with no viable alternative treatment option.

Keywords

abdominal aortic aneurysm, chimney graft, endoleak, endovascular aneurysm sealing, migration, parallel graft, reintervention, rupture

Introduction

Endovascular aneurysm repair (EVAR) has supplanted open repair as the most common treatment option for abdominal aortic aneurysm (AAA) due to reduced early morbidity and mortality.^{1–4} However, EVAR is associated with long-term modes of failure not seen with open repair, resulting in higher reintervention rates.^{5,6} Since the introduction of EVAR, endograft designs and delivery systems have evolved to respond to these complications and to increase anatomical applicability of the devices.⁷

Endovascular aneurysm sealing (EVAS) was commercially introduced in 2013 and is based on the principle of

¹Department of Interventional Radiology and Vascular Surgery, Auckland City Hospital, Auckland, New Zealand

²Department of Surgery, Division of Vascular Surgery, University Medical Center Groningen, University of Groningen, the Netherlands

³Department of Vascular Surgery, Rijnstate Hospital, Arnhem, the Netherlands

⁴MultiModality Medical Imaging Group, TechMed Centre, University of Twente, Enschede, the Netherlands

Corresponding Author:

Aleksandra C. Zoethout, Department of Surgery, University Medical Center Groningen, Hanzeplein 1, Groningen, 9713 GZ, the Netherlands.
 Email: sandrazoethout@gmail.com

“active sac management” through the use of dual endobags mounted on balloon-expandable endoframes. The Nellix EVAS System (Endologix, Irvine, CA, USA) was designed to achieve complete aneurysm sac exclusion, with the expectation of a low endoleak rate, particularly type II. Initial results of EVAS were positive for the most part,^{8,9} but the occurrence of migration after EVAS was a particular problem, with an incidence ranging between 2% and 17%¹⁰⁻¹² based on diverse definitions of migration. Various factors may contribute to migration, including patient anatomy and suboptimal positioning of the device.¹³ Anatomical features predisposing to migration include hostile infrarenal neck anatomy and a small blood volume within the aneurysm sac, which causes incomplete polymer filling of the endobags, reducing endoframe support and lessening resistance to lateral bending and subsequent migration forces.¹⁴

Hostile infrarenal neck refers to short, wide, conical, or severely angulated necks and those with significant thrombus and/or calcification.⁸ Common endovascular management options for patients with a hostile infrarenal neck include fenestrated EVAR (fEVAR), chimney EVAR (chEVAR), and chimney EVAS (chEVAS). Theoretically, chEVAS should be better than chEVAR because the compliant endobags fill the space between the Nellix stents and the chimney grafts, reducing the incidence of gutter type Ia endoleak. This advantage of chEVAS has been confirmed in bench models^{15,16} and subsequently reported in clinical practice, most notably in the ASCEND Registry.¹⁷

Logically, migration after chEVAS might occur less frequently and to a lesser degree compared to standard EVAS for several reasons. First, the device is sealing into a healthier aortic segment, usually a neck below the superior mesenteric artery (SMA) or celiac trunk. An adequate neck length of at least 20 mm can be achieved using this technique of moving the landing zone up the aorta. Second, the infrarenal EVAS device also achieves fixation by filling the blood lumen within the aneurysm sac and the proximal and distal sealing zones without the assistance of hooks or barbs. Third, the proximal endobag shelf in chEVAS has considerably less cross-sectional area compared to conventional infrarenal EVAS due to the space occupied by the chimney grafts. This could reduce the downward displacement force on the implant.

The current study investigates the incidence of migration and endoleak when the Nellix System is used in conjunction with chimney grafts to determine if the migration is less frequent with the chEVAS configuration than the infrarenal EVAS device.

Materials and Methods

Study Design and Patient Sample

A retrospective, observational study was conducted of chEVAS patients treated electively for asymptomatic

AAAs at 2 active and experienced EVAS centers in New Zealand and the Netherlands between April 2013 and December 2018. Both research sites acquired local ethics committee approval according to national guidelines (New Zealand: HDEC 19/CEN/6; the Netherlands: LHC 2018-1316). The study was conducted according to the principles of the Declaration of Helsinki and in accordance with the applicable guidelines, regulations, and acts. Patients gave informed consent for the procedure and the use of anonymized data in research.

Patients were considered for chEVAS if they were deemed unfit for open surgical repair and for fEVAR. Of 52 chEVAS cases performed during the study period, 16 patients were excluded because the procedure was performed as a reintervention for EVAS, EVAR, or open repair (n=2). Additionally, 2 patients could not be contacted to provide consent, 2 patients were treated for symptomatic intact or ruptured AAA, and 1 patient received the chimney grafts in the internal iliac artery and none proximally. These exclusions left 31 patients (mean age 75.7 years; 27 men) for analysis of migration and endoleak. The majority (n=25) of patients were from the New Zealand center. Baseline clinical and anatomical characteristics are presented in Table 1. The comorbidity profile was typical of an AAA cohort. All aneurysms were juxtarenal and 30 were fusiform. Eight (27%) patients had a maximum sac to lumen diameter ratio >1.40.

Procedure

The conventional EVAS procedure¹⁸ as well as the chEVAS technique¹⁷ have been described previously. For chEVAS, percutaneous or open access was achieved through the femoral arteries for introduction of the Nellix devices, while the chimney grafts were introduced via brachial, axillary, or subclavian artery accesses. Depending on the aneurysm morphology, chimney grafts [typically Advanta V12 (Getinge, Gothenburg, Sweden) and Viabahn (W. L. Gore & Associates Inc, Flagstaff, AZ, USA)] were placed in the renal arteries, SMA, and/or the celiac trunk. Once the Nellix stents and chimney grafts were in position, the Nellix stents were usually deployed first, which facilitated a more parallel course for the chimney grafts during their subsequent deployment. The endobags were pre-filled with saline to verify the calculated volume for the polymer fill, while the delivery balloons were kept inflated in all chimney grafts and Nellix systems. Polymer fill was performed to a pressure of at least 180 mm Hg after aspiration of the prefill. Angiography was performed to confirm aneurysm seal; if necessary, a secondary fill of the endobags was performed.

Aneurysm Morphology and Device Migration

Preoperative and follow-up computed tomography angiography (CTA) scans collected at 1, 6, and 12 months and annually thereafter were assessed for this analysis by an

Table 1. Baseline Clinical and Anatomical Characteristics of the 31 Patients in the Study.^a

Patient characteristics	
Age, y	75.7±6.0
Men	27 (87)
Body mass index, kg/m ²	25.2 (23.0, 29.1)
ASA class	
I	1 (3)
II	7 (23)
III	18 (58)
IV	5 (16)
NIDDM	4 (13)
Smoking	20 (65)
Hypertension	28 (90)
Hyperlipidemia	26 (84)
Cardiac disease	18 (58)
Renal disease	13 (42)
Pulmonary disease	12 (39)
Previous vascular intervention ^b	5 (16)
Peripheral artery disease ^c	9 (19)
Anatomical characteristics	
Juxtarenal aneurysm	31 (100)
Lengths, mm	
Celiac artery to aneurysm	52 (43, 62)
SMA to aneurysm	33 (25, 46)
Lowest renal artery to aneurysm	10 (4, 14)
Diameters, mm	
Aorta at the celiac artery	26 (25, 27)
Aorta at the SMA	25 (23, 26)
Aorta at the RRA	24 (23, 27)
Aorta at the LRA	24 (23, 27)
Maximum AAA sac ^d	61 (57, 65)
Maximum AAA lumen	50 (40, 55)
Aorta at the iliac bifurcation	30 (21, 36)
Maximum RCIA	14 (13, 18)
Maximum LCIA	16 (14, 18)

Abbreviations: AAA, abdominal aortic aneurysm; ASA, American Society of Anesthesiologists; LCIA, left common iliac artery; LRA, left renal artery; NIDDM, non-insulin-dependent diabetes mellitus; RCIA, right common iliac artery; RRA, right renal artery; SMA, superior mesenteric artery.

^aContinuous data are presented as the mean ± standard deviation or median (interquartile range Q1, Q3); categorical data are given as the count (percentage).

^bThree treated for thoracic aortic disease.

^cTwo popliteal and 4 iliac artery aneurysms.

^dOuter to outer diameter.

independent radiologist (A.S.) and independently reviewed (A.Ho.) with the use of 3-dimensional vascular planning software (Syngo.via; Siemens, Erlangen, Germany). Diameters at the level of the celiac artery, SMA, right and left renal arteries, maximum aneurysm, and left and right common iliac arteries were measured perpendicular to the center lumen line from the outer-to-outer walls and directly caudal to the specified vessel. The maximum aneurysm

diameter and maximum aortic flow lumen diameter were used to calculate the aortic diameter ratio. The caudal extent of the aneurysm neck was where the aortic diameter was increased >20% compared with the aortic diameter at the level of the lowest renal artery. Aneurysm neck lengths were measured from the caudal orifice of the celiac trunk, the SMA, and the lowest renal artery to the caudal end of the aneurysm neck. All visceral arteries were checked for stenosis and occlusion.

Seal length was determined as the distance between the top end of the highest Nellix stent-graft and the beginning of the aneurysm on the first postoperative CT. The top 5 mm of the Nellix stent-graft is not covered by endobag, however, for uniformity of measurements, this was included in the seal zone length.

Follow-up imaging recorded the Nellix graft position relative to the caudal orifice of the SMA, with positive values being above the SMA and negative values being below the SMA. Any fracture of the Nellix endoframes or complication of the chimney grafts was reported, including occlusion, stent fracture, evident position change, and compression.

Migration was assessed by comparing the first postoperative CTA to the latest available follow-up imaging. When a CTA at a follow-up window was absent but a CTA on a later follow-up showed no migration, it was assumed there was no migration in the interim. Clinically relevant migration after EVAR is reported as caudal migration ≥10 mm or caudal movement of 5 to 9 mm with the need for reintervention.

Definitions

Comorbidities were scored according to the Society of Vascular Surgery comorbidity grading scale.¹⁹ Hypertension was defined as known history of hypertension or use of antihypertensive medication. Hyperlipidemia was defined as known history or the use of a statin or elevated lipid levels (low-density lipoprotein, total cholesterol, and triglyceride levels above normal limits for age). Renal insufficiency was based on a serum creatinine ≥2.4 mg/dL or dialysis dependency. Smoking included current and prior smoking in the past 10 years.¹⁹ An aneurysm was considered juxtarenal when the infrarenal neck length was <10 mm or when the neck length was 10 to 15 mm but with hostile features (infrarenal diameter >28 mm, infrarenal neck angle >60°, circumferential calcium, or circumferential thrombus).

Technical success was defined as successful introduction and deployment of the device without open conversion, death, type I or III endoleak, or graft limb occlusion within 24 hours after the procedure. The term “assisted technical success” was applied to cases in which unplanned endovascular or surgical procedures were required to successfully exclude the aneurysm during the index chEVAR procedure.²⁰

Endoleaks were defined according to the Society for Vascular Surgery reporting standards of vascular surgery,¹⁹ and type Ia endoleaks were defined as specified by van den Ham et al.²¹ Type 1S1 endoleak is the appearance of contrast between the endobag and the wall of the proximal neck but not reaching the aneurysm sac itself. In a type 1S2 endoleak, the contrast reaches the aneurysm wall and extends into the aneurysm sac. A type 1S3 endoleak refers to contrast between the endobags inside the aneurysm sac.

Mortality was reported as all-cause mortality and as aneurysm-related mortality at 6 months, 1 year, and 2 years. Aneurysm-related mortality included death due to aneurysm rupture or the consequence of a primary or secondary procedure or surgical conversion.

Statistical Analysis

Continuous variables were presented as mean and standard deviation or as median and interquartile range (IQR Q1, Q3) depending on the distribution of data based on Kolmogorov-Smirnov tests and histograms. Categorical variables were presented as counts (percentages). Correlations between migration and aneurysm growth, endoleak, the number of chimney grafts, and the aortic diameter ratio were explored using a 2-sided Pearson chi-square test. The threshold of statistical significance was $p < 0.05$. Kaplan-Meier survival analysis was performed with censoring for patients lost to follow-up. All statistical analyses were performed using IBM SPSS Statistics (version 24.0; IBM Corporation, Armonk, NY, USA).

Results

Procedure Details

All patients had the procedure under general anesthesia, and the majority had bilateral percutaneous accesses (22, 71%). The Advanta V12 was used in 71% of the chimneys, the Viabahn in 19%, and other stents in 10%. Nine of the 13 single chimney procedures (11 left and 2 right renal arteries) were performed before 2016. Eleven of the 13 double chimneys were in the renal arteries. Additionally, 1 patient received a stent in the SMA and right renal artery, and 1 patient had stenting of 2 right renal arteries. Of the 5 triple chimneys, 1 had stents in an accessory renal artery and both main renal arteries; the other 4 patients had chimneys to both renal arteries and the SMA. The median polymer fill volume was 109 mL (IQR 75, 132) at a median pressure of 220 mm Hg (IQR 210, 240). There were 10 secondary fills with a median volume of 10 mL (IQR 8, 14). Additionally, median seal length analyzed on the first postoperative CTA was 36.5 mm (IQR 30.3, 51.3).

Primary technical success was achieved in 20 of 31 patients (64%). Another 9 cases required additional

Table 2. Details of the 31 Procedures.^a

Chimney access type	
Brachial	17 (55)
Axillary	11 (36)
Subclavian	3 (10)
Chimney grafts	
1	13 (42)
2	13 (42)
3	5 (16)
Blood loss, mL	275 (125, 500)
Contrast volume, mL	356 (290, 430)
Procedure duration, min	207 (149, 266)
Intensive care unit stay, d	1 (1, 1)
Hospital stay, d	4 (3, 8)
Technical success	20 (64)
Assisted technical success	29 (93)

^aContinuous data are presented as the median (interquartile range Q1, Q3); categorical data are given as the count (percentage).

unplanned procedures to successfully seal the aneurysm (93% assisted technical success). Four iliac stents were placed for acute angulation, distal endoleak, stenosis, and inadequate distal seal; additional renal stenting for inadequate stent length or dislocation was done in 3. One patient needed an SMA stent because the origin was compromised by the renal artery chimneys. Finally, 1 patient required additional stent placement in the renal artery because of migration and relining of the chimney for common iliac artery rupture after postdilation. Other details of the procedures are given in Table 2.

Of the 2 failures, 1 was due to a small postoperative type Ib endoleak. The second case required conversion to remove the Nellix system because the nosecone could not be retrieved by endovascular means.

Overall Complications

Aneurysm-related complications are reported in Table 3. Of 10 reinterventions (33%) required after the index procedure, 2 were for aneurysm rupture. The first had ongoing sac expansion during follow-up and had a rupture at 3 months. The patient was treated with a Nellix-in-Nellix procedure,²² with a small type Ia endoleak persisting postoperatively. Five days later the patient died, possibly due to cardiac arrest. The second patient had a type Ib endoleak with contained rupture at 8 months, which was treated with open conversion. This was complicated by an acute on chronic kidney insufficiency that resolved during hospitalization.

Additionally, another patient had a Nellix-in-Nellix procedure for aneurysm growth. The other reinterventions were performed for 3 type Ib endoleaks and 2 renal stenoses (1 patient had 2 reinterventions, one for renal stenosis and the other later for a type Ib endoleak).

Table 3. Aneurysm-Related Complications.^a

	30 Days (n=30)	6 Months (n=25)	1 Year (n=20)	2 Years (n=14)	3 Years (n=8)	4 Years (n=4)	Overall (n=30)
Endoleak^{b,c}							
IS1	2 [2 new]	3 [2 new]	2 [0 new]	1 [0 new]	2 [1 new]	0	4
IS2	0	0	0	0	1 [1 new]	0	1
IS3	0	1 [1 new]	0	0	0	0	1
Type Ib	0	2 [2 new]	2 [1 new]	2 [0 new]	1 [0 new]	0	3
Type IIa	0	0	0	0	1 [1 new]	0	1
Total	2 (7)	6 (24)	4 (20)	3 (21)	5 (62)	0	10 (33)
Stent-graft fracture ^d	1 (3)	1 (4)	1 (5)	1 (7)	1 (12)	0	1
Chimney stent complication							
Fracture	1 [1 new]	0	1 [1 new]	0	0	0	1
Stenosis	2 [2 new]	1 [0 new]	1 [0 new]	1 [0 new]	1 [0 new]	0	1 ^e
Occlusion	0	2 ^f	2 [0 new]	1 [0 new]	0	0	2
Compression	2 [2 new]	5 [3 new]	3 [0 new]	3 [0 new]	2 [0 new]	3 [1 new]	6
Total	5 (17)	6 (24)	7 (35)	5 (36)	3 (38)	2 (50)	7 (23)
Aneurysm growth	4 (13) [4 new]	5 (20) [2 new]	2 (10) [1 new]	3 (21) [3 new]	3 (38) [1 new]	3 (75) [2 new]	13 (27)

^aNumber of new cases are reported in brackets and percentages in parentheses.

^bEndoleak was classified according to van den Ham et al.²¹

^cOne patient had a IS1 endoleak at 30 days that progressed into a IS3 at 6 months; this is counted as a IS3 endoleak overall.

^dAll in 1 patient.

^eOne of the cases with stenosis occluded later and is classified as occlusion.

^fBoth these cases had a prior complication (1 stenosis and 1 fracture) with the chimney stent-graft that progressed into occlusion.

Of 8 patients (27%) who died in follow-up, 2 died at 6 months, 4 at 1 year, and 2 at 2 years. There were 2 aneurysm-related deaths as described above. The remaining causes of death were cancer (n=2), trauma (n=1), cardiac (n=1), stroke (n=1), and unknown (n=1).

Migration and Endoleak

Six patients (20%) had only the first postoperative scan, so evaluation of migration was based on 25 patients. The median time to the last follow-up CTA in these patients was 17 months (IQR 6, 35), and the median time to the last clinical follow-up visit was 23 months (IQR 10, 37).

There were no cases of caudal migration >10 mm throughout follow-up (Figure 1), but 7 of the 25 patients (28%) had caudal movement at 2 years (n=5) or beyond (n=2). The maximum observed caudal movement was 8 mm, which occurred at 3 years. Freedom from caudal movement of 5 to 9 mm (Figure 2) was estimated at 86.1% at 1 year and 73.9% at 2 years.

Up to 2 years there was no clinically significant migration (caudal movement and a reintervention). At 3 years, however, 2 cases of caudal movement of 8 and 6 mm, respectively, and type Ia endoleak warranted reintervention. As such, the freedom from clinically significant migration was 76.2% at 3 years (Figure 2). One patient had migration with aneurysm growth and a type IS1 endoleak. This patient

underwent a Nellix-in-Nellix procedure with 3 vessel chimney after 4 years. The other patient had migration with aneurysm growth and a type IS2 endoleak, which required conversion at 3.5 years. Unfortunately, the patient suffered a fatal stroke 7 days after the open procedure. Additionally, 1 patient with caudal movement of 5 to 9 mm from 1 year onward had sac shrinkage from 57 mm preoperatively to 47 mm at 1 year and 44 mm at 3 years. No other complications related to migration or endoleak were observed in the patients who had migration. There was no correlation between migration and aneurysm growth (p=0.851), endoleak (p=0.562), the number of chimney grafts (p=0.728), or the aortic diameter ratio and migration (p=0.402).

Discussion

Chimney EVAS has been a theoretically interesting alternative to other treatment options for patients with hostile neck anatomy, particularly if patients are not suitable for fEVAR, chEVAR, or open repair. Bench models and early clinical experience confirmed a low incidence of gutter type Ia endoleaks, potentially because the compliant endobags successfully fill the spaces between the Nellix stents and chimney grafts.¹⁶⁻¹⁸ In addition, it has been proposed that chEVAS may have better resistance to migration forces compared with conventional infrarenal EVAS. Factors that might contribute to reduced migration forces include friction force

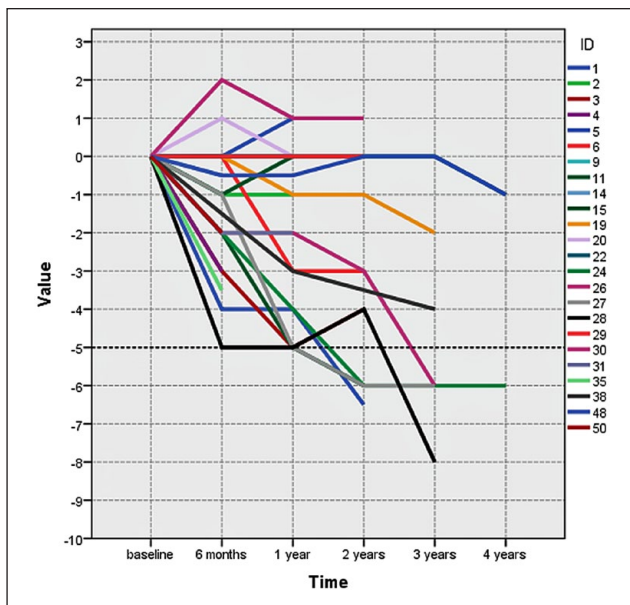


Figure 1. Plot of the maximum amount of migration of at least one of the Nellix stent-grafts over time. Each line represents 1 case. The dotted line indicates the cutoff point of significant (≥ 5 mm) caudal migration.

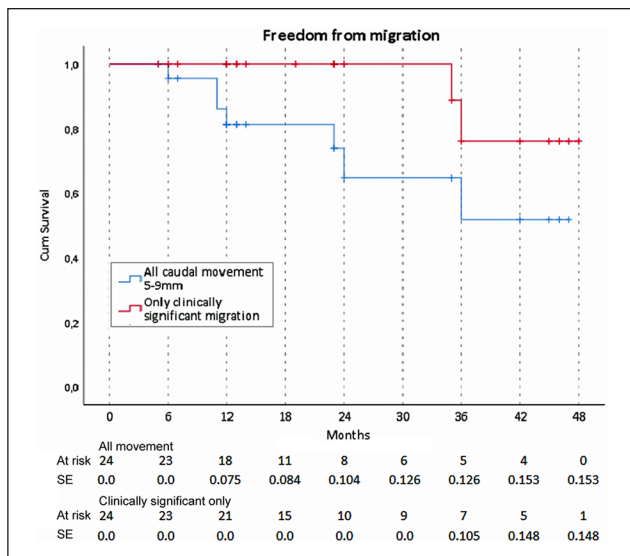


Figure 2. Freedom from caudal movement of 5 to 9 mm and freedom from clinically significant migration. The standard error exceeded 10% at 24 months for the 5- to 9-mm migration and 36 months for the clinically significant migration outcome.

between the Nellix stents, chimney stents, and aortic wall; a healthier aortic sealing zone below the SMA; and a reduced proximal endobag shelf area due to the chimney stents.

A comparison with other studies is complicated by inconsistent definitions of migration. Stenson et al²³ recently published an analysis including 79 cases of chEVAS of which 57

were performed in an elective setting. They reported freedom from migration (≥ 5 mm) of 100% at 1 year and 85.7% at 2 years. Although they had a larger sample and more complex cases, our freedom from caudal movement (≥ 5 mm) was lower at both time points (86.1% at 1 year and 73.9% at 2 years). However, in both our study and Stenson's, migration becomes problematic at or beyond 3 years' follow-up.

The hypothesis of our study, that chEVAS might have lower rates of migration compared to EVAS, was not confirmed. The only cases of clinically significant migration occurred at 3 years, and both required reintervention for a type I endoleak. This 7% migration rate is comparable to migration after standard EVAS. The DEVASS registry¹⁰ showed clinically significant migration of 7.1% at 2 years for EVAS cases treated within the instructions for use (IFU). The EVAS investigational device exemption trial¹³ had a 6.0% migration > 10 mm rate at 3 years. Of course, these rates are based on much larger patient samples than ours. Additionally, differences in aneurysm anatomy make a comparison between chEVAS and EVAS difficult, especially with the added consideration of a relatively challenging patient cohort.

Caudal migration may also occur due to hostile neck anatomy with a conventional endovascular approach, including fEVAR. England et al²⁴ reported an incidence of 21% caudal movement > 4 mm after fEVAR, which is slightly lower compared to the 23% of caudal movement that was observed in the current study. However, all cases described in the current study were considered to have anatomies unsuitable for fEVAR. Unfortunately, no further information was available regarding the specific causes for unsuitability; the decision to perform chEVAS instead of alternative treatment in these cases was based on multiple factors and decided in a physician panel. Although chEVAS is also related to late migration, it might remain a last resort option for patients not fit for open repair and with anatomies not suitable for fEVAR.

Disturbingly, there were 2 patients who had aneurysm rupture after their Nellix procedure, of which one had a fatal outcome after endovascular reintervention. There was one other aneurysm-related death that occurred after open conversion for endoleak. These complications may have occurred due to the learning curve that is related to any new type of device but should not be taken lightly. It indicates the high risk associated with secondary intervention after EVAS and warrants ongoing surveillance.

It has been hypothesized that minimal caudal movement after EVAS may stabilize once the endobags are properly fixated. However, the data in this study indicate that once the stents move caudally, there is a trend toward progressing migration over time, as has been portrayed in Figure 1. A longer follow-up period and a larger number of patients would be needed to confirm this observation.

The low primary technical success rate shows the complexity of the chEVAS procedure, indicating it should be

performed only by physicians with extensive experience in EVAS. Despite the capabilities and experience of the surgeons in our cohort, there were 2 technical failures, one of which led to conversion. This was due to a problem with the device design and resulted in changes to the design of the device. However, a good assisted technical success rate was achieved with additional steps during the index procedure, which suggests that chEVAS is technically challenging but feasible.

To achieve a good-quality seal zone for juxtarenal aneurysms and aneurysms with a hostile neck, the infra-SMA seal zone should be at least 20 mm. This generally involves stenting both renal arteries. However, there were a relatively large number of single chimneys in this study. The majority were in patients treated during the early experience with chEVAS, when a shorter seal zone length was accepted. Even though no correlation was observed between the number of chimney grafts and the occurrence of migration, it is advisable to perform at least a double chimney in order to achieve good seal. The high proportion of single chimneys may have negatively affected the results.

Limitations

It is crucial to acknowledge that this study had a small sample size with a limited follow-up. As such, the study could be underpowered, and results must be interpreted with caution. Stenson et al²³ showed high technical failure rates of chEVAS past 3 years, which was not available in our follow-up. The only 2 cases of clinically significant migration, our primary endpoint, occurred 3 years after the index procedure. Additionally, patients were selected for chEVAS if they were deemed unsuitable for open surgical repair or fEVAR, which produces a challenging cohort of patients. This selection bias must be taken into account. Despite these limitations, these midterm results give more insight into the benefits and drawbacks of chEVAS. Of note, the higher than anticipated midterm migration rate with EVAS prompted refinement of the Nellix IFU in 2016 and led to voluntary restriction of sales in 2019.

Conclusion

The incidence of clinically relevant migration after chEVAS is similar to that reported after EVAS performed inside the IFU at 2 years. Moreover, a trend was observed toward ongoing migration at 3 years that requires intervention. It is advisable to keep patients who underwent chEVAS under surveillance for such complications. Longer follow-up and a larger sample are indicated in order to draw more robust conclusions.

Authors' Note

This study was presented at the 2019 Annual Veith Symposium (November 21, 2019; New York, NY, USA).

Declaration of Conflicting Interests

The author(s) declared the following potential conflicts of interest with respect to the research, authorship, and/or publication of this article: Michel M. P. J. Reijnen and Andrew Holden are members of the Endologix scientific advisory board.


Funding

The author(s) received no financial support for the research, authorship, and/or publication of this article.

ORCID iDs

Aleksandra C. Zoethout  <https://orcid.org/0000-0002-5562-190X>

Michel M. P. J. Reijnen  <https://orcid.org/0000-0002-5021-1768>

Andrew Holden  <https://orcid.org/0000-0002-8170-4960>

References

- Greenhalgh RM, Brown LC, Kwong GP, et al. Comparison of endovascular aneurysm repair with open repair in patients with abdominal aortic aneurysms (EVAR trial 1), 30-day operative mortality results: randomized controlled trial. *Lancet*. 2004;364:843–848.
- Prinssen M, Verhoeven EL, Buth J, et al; Dutch Randomized Endovascular Aneurysm Management (DREAM) Trial Group. A randomized trial comparing conventional and endovascular repair of abdominal aortic aneurysms. *N Engl J Med*. 2004;351:1607–1618.
- Brown LC, Powell JT, Thompson SG, et al. The UK Endovascular Aneurysm Repair (EVAR) trials: randomized trials of EVAR versus standard therapy. *Health Technol Assess*. 2012;16:1–218.
- Albuquerque FC Jr, Tonnessen BH, Noll RE Jr, et al. Paradigm shifts in the treatment of abdominal aortic aneurysm: trends in 721 patients between 1996 and 2008. *J Vasc Surg*. 2010;51:1348–1352.
- Propper BW, Abularrage CJ. Long-term safety and efficacy of endovascular abdominal aortic aneurysm repair. *Vasc Health Risk Manag*. 2013;9:13–41.
- Al-Jubouri M, Comerota AJ, Thakur, et al. Reintervention after EVAR and open surgical repair of AAA: a 15-year experience. *Ann Surg*. 2013;258:652–657.
- van den Ham LH, Zeebregts CJ, de Vries JP, et al. Abdominal aortic aneurysm repair using Nellix endovascular aneurysm sealing. *Surg Technol Int*. 2015;26:226–231.
- Karathanos C, Spanos K, Kouvelos G, et al. Hostility of proximal aortic neck anatomy in relation to abdominal aortic aneurysm size and its impact on the outcome of endovascular repair with the new generation endografts. *J Cardiovasc Surg (Torino)*. 2020;61:60–66.
- Reijnen MMPJ, Holden A. Status of endovascular aneurysm sealing after 5 years of commercial use. *J Endovasc Ther*. 2018;25:201–206.
- Zoethout AC, Boersen JT, Heyligers JMM, et al; DEVASS (Dutch Endovascular Aneurysm Sealing) Group. Two-year outcome of the Nellix endovascular aneurysm sealing system for treatment of abdominal aortic aneurysms. *J Endovasc Ther*. 2016;25:270–281.

11. England A, Torella F, Fisher RK, et al. Migration of the Nellix endoprosthesis. *J Vasc Surg.* 2016;64:306–312.
12. Carpenter JP, Cuff R, Buckley C, et al. One-year pivotal trial outcomes of the Nellix system for endovascular aneurysm sealing. *J Vasc Surg.* 2017;65:330–336.
13. Carpenter JP, Cuff R, Buckley C, et al. Results of the Nellix system investigational device exemption pivotal trial for endovascular aneurysm sealing. *J Vasc Surg.* 2016;63:23–31.
14. Spanos K, Karathanos C, Saleptsis V, et al. Systematic review and meta-analysis of migration after endovascular aortic aneurysm repair. *Vascular.* 2016;24:323–336.
15. Boersen JT, Donselaar EJ, Groot Jebbink E, et al. Benchtop quantification of gutter formation and compression of chimney stent grafts in relation to renal flow in chimney endovascular aneurysm repair and endovascular aneurysm sealing configurations. *J Vasc Surg.* 2017;66:1565–1573.
16. van Schaik TG, Meekel JP, Jongkind V, et al. Secondary fill minimizes gutter size in chimney EVAS configurations in vitro. *J Endovasc Ther.* 2019;26:62–71.
17. Thompson M, Youssef M, Jacob R, et al. Early experience with endovascular aneurysm sealing in combination with chimney grafts for the treatment of complex abdominal aneurysms: The ASCEND registry. *J Endovasc Ther.* 2017;24:764–772.
18. Batagini NC, Hardy D, Clair DG, et al. Nellix EndoVascular Aneurysm Sealing System: device description, technique of implantation, and literature review. *Semin Vasc Surg.* 2016;29:55–60.
19. Chaikof EL, Blankensteijn JD, Harris PL, et al. Reporting standards for endovascular aortic aneurysm repair. *J Vasc Surg.* 2002;35:1048–1060.
20. Stoner MC, Calligaro KD, Chaer FA, et al. Reporting standards of the Society for Vascular Surgery for endovascular treatment of chronic lower extremity peripheral artery disease. *J Vasc Surg.* 2016;64:e1–e21.
21. van den Ham LH, Holden A, Savlovskis J, et al; EVAS Type Ia Endoleak Study Group. Occurrence and classification of proximal type I endoleaks after endovascular aneurysm sealing using the Nellix device. *Eur J Vasc Endovasc Surg.* 2017;54:729–736.
22. Donselaar EJ, Holden A, Zoethout AC, et al. Feasibility and technical aspects of proximal Nellix-in-Nellix extension for late caudal endograft migration. *J Endovasc Ther.* 2017;24:210–217.
23. Stenson KM, de Bruin JL, Loftus IM, et al. Migration and sac expansion as modes of midterm therapeutic failure after endovascular aneurysm sealing. *J Vasc Surg.* 2020;71:457–469.
24. England A, Finana-Garcia M, McWilliams R. Multicenter retrospective investigation into migration of fenestrated aortic stent grafts. *J Vasc Surg.* 2015;62:884–892.