

University of Groningen

Blunt abdominal injury resulting in a belly full of candy after a motocross accident, a case report

Poelmann, Floris B.; IJpma, Frank F. A.

Published in:
BMC Surgery

DOI:
[10.1186/s12893-020-00997-0](https://doi.org/10.1186/s12893-020-00997-0)

IMPORTANT NOTE: You are advised to consult the publisher's version (publisher's PDF) if you wish to cite from it. Please check the document version below.

Document Version
Publisher's PDF, also known as Version of record

Publication date:
2020

[Link to publication in University of Groningen/UMCG research database](#)

Citation for published version (APA):

Poelmann, F. B., & IJpma, F. F. A. (2020). Blunt abdominal injury resulting in a belly full of candy after a motocross accident, a case report. *BMC Surgery*, 20, [325]. <https://doi.org/10.1186/s12893-020-00997-0>

Copyright

Other than for strictly personal use, it is not permitted to download or to forward/distribute the text or part of it without the consent of the author(s) and/or copyright holder(s), unless the work is under an open content license (like Creative Commons).

The publication may also be distributed here under the terms of Article 25fa of the Dutch Copyright Act, indicated by the "Taverne" license. More information can be found on the University of Groningen website: <https://www.rug.nl/library/open-access/self-archiving-pure/taverne-amendment>.

Take-down policy

If you believe that this document breaches copyright please contact us providing details, and we will remove access to the work immediately and investigate your claim.

Downloaded from the University of Groningen/UMCG research database (Pure): <http://www.rug.nl/research/portal>. For technical reasons the number of authors shown on this cover page is limited to 10 maximum.

CASE REPORT

Open Access



Blunt abdominal injury resulting in a belly full of candy after a motocross accident, a case report

Floris B. Poelmann*  and Frank F. A. IJpma

Abstract

Background: Blunt traumatic gastric perforations in children are rare. Delayed diagnosis will lead to abdominal contamination and may result in morbidity and even mortality. We present a case of an adolescent who sustained blunt abdominal injury in a motocross accident and presented with remarkable hyperdense spherical shaped structures on the computed tomography (CT).

Case presentation: A 15-year-old boy arrived at the emergency room with an acute abdomen after a motocross accident. A CT scan of the abdomen demonstrated free air and hyperdense round structures in the stomach, pelvic cavity and right paracolic gutter. During emergency laparotomy a traumatic gastric perforation was sutured, a splenic rupture was treated with a vicryl mesh and multiple spherical food scraps were removed from the abdomen. After surgery, the boy clarified that he had eaten a whole bag of colorful and spherical shaped candy just before the accident.

Conclusions: Traumatic gastric rupture in children is rare but physicians should be aware of this diagnosis in case of blunt abdominal trauma with free air on the CT scan. Gastric contents, in this case candy, can present as hyperdense shaped structures in the abdominal cavity on the CT scan.

Keywords: Abdominal injury, Gastric perforations in children

Background

Blunt traumatic gastric perforations in children are rare [1]. An incidence has been described between 0.02 and 1.7% of all blunt abdominal trauma [2]. Traffic accidents are the most important cause of gastric rupture in case of blunt trauma [3]. Motor vehicle accidents account for approximately 90% of the gastric tears at this young age [1–3]. Delayed diagnosis may lead to abdominal contamination, resulting in morbidity and even mortality [2, 4–8]. We present a case of an adolescent who sustained blunt abdominal injury during a motocross accident and

presented with remarkable hyperdense spherical shaped structures on the CT-abdomen.

Case presentation

A 15-year-old, otherwise healthy, boy arrived at the emergency room after a motocross accident. Trauma screening was performed according to the Advanced Trauma Life Support principles. His airway was free and his cervical spine was immobilized. He had a tachypnoea of 28 breaths per minute, with normal vesicular breathing sounds and a saturation of 100%. He had a tachycardia, with 130 beats per minute, a blood pressure of 160/90 mmHg and a painful abdomen on palpation. His consciousness was slightly decreased with an EMV score of 3–5–4. X-ray of the thorax showed opacification, which was interpreted as a lung contusion. The Focused

*Correspondence: florispoelmann@gmail.com; f.b.poelmann@umcg.nl
Department of Trauma Surgery, University of Groningen, University Medical Center Groningen, Hanzeplein 1, 9713 GZ Groningen, The Netherlands



Assessment with Sonography for Trauma demonstrated free abdominal fluids. CT-angiography showed a grade IV splenic laceration and free air in the abdomen. There was no active bleeding. Also, remarkable hyperdense spherical structures were present in the stomach, pelvic cavity and right paracolic gutter (Fig. 1). Because of the presence of free air in the abdomen an emergency laparotomy was performed. During surgery, two liters of blood mixed with spherical shaped food remains were evacuated from the abdomen. A gastric perforation (diameter 5 cm) was found at the ventral side of the stomach (Fig. 2). This defect was primarily closed with sutures. The splenic rupture was treated with a Lyostipt (topical hemostatic agent). Subsequently, a soluble vicryl mesh was wrapped around the spleen in order to ensure hemostasis by compression. No further injuries were detected in the abdominal cavity (Fig. 3). After surgery, we were still unsure about the nature of the white food debris, which has been removed from the abdomen, so we asked the patient about his last meal. It appeared that he had eaten a whole bag of colorful and spherical shaped candy (Fig. 4) just before the motocross event. The patient recovered uneventfully after the operation.

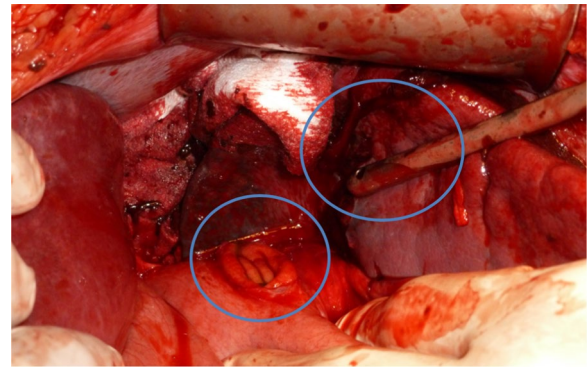


Fig. 2 Intraoperative image of the stomach perforation (center) and a splenic laceration (center, near the tip of the suction device)

Discussion and conclusions

Traumatic gastric ruptures are rare with an estimated incidence of 0.02–1.7% of all blunt abdominal injury [2]. Gastric perforation can occur as a consequence of a high velocity impact involving the epigastric region in post-meal phase [9–11]. This trauma mechanism also applies

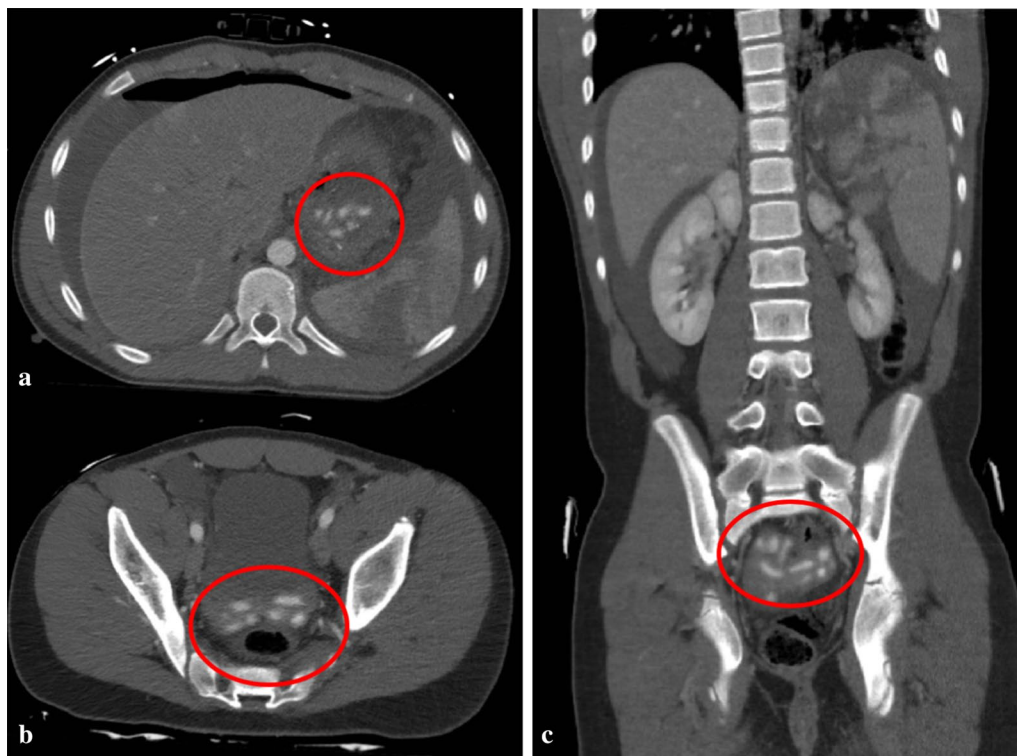


Fig. 1 Computed tomography (CT) of the abdomen after blunt abdominal injury due to a motocross accident. **a** Axial contrast enhanced CT image of the abdomen at the portal venous phase shows free abdominal fluids, free air, a splenic laceration and remarkable spherical shaped corpora aliena in the stomach; **b** axial image, demonstrating the same hyperdense lesions in the pelvic cavity; **c** coronal image, showing a grade 4 splenic rupture as well as hyperdense lesions in the pelvic cavity

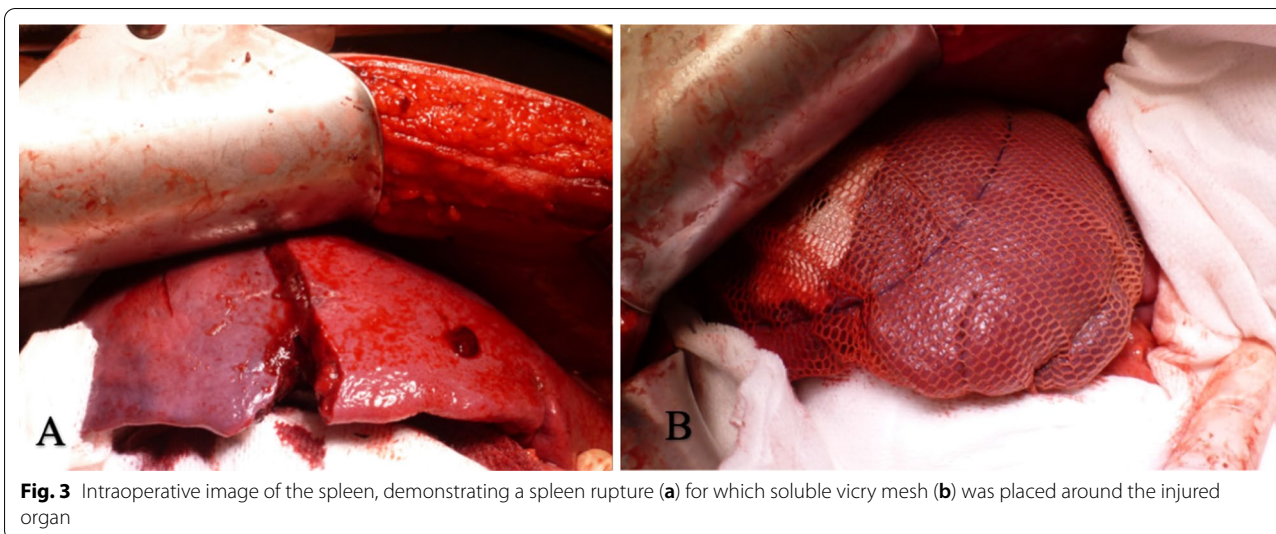


Fig. 3 Intraoperative image of the spleen, demonstrating a spleen rupture (a) for which soluble vicry mesh (b) was placed around the injured organ



Fig. 4 Colorful and spherical shaped candy

to our case. The impact of the handlebar, striking the abdomen during the motocross accident, has probably caused a sudden increase in pressure in the full stomach, causing a gastric perforation and spreading of candy in the abdominal cavity. At the initial assessment of the CT scan, we were not yet aware that the patient had eaten a large quantity of candy. To our best knowledge, no candy-related traumatic gastric ruptures in children have been described. The hyperdense spherical structures on the CT scan, of which the nature was preoperatively unknown, appeared to be candy that entered the abdominal cavity after traumatic gastric perforation.

Conclusion

In conclusion, traumatic gastric rupture in children is rare but physicians should be aware of this diagnosis in case of blunt abdominal trauma with free air on the CT scan. Moreover, certain released stomach contents—in this particular case candy—can present as hyperdense shaped structures at the CT scan.

Abbreviation

CT: Computed tomography.

Acknowledgements

Not applicable.

Authors' contributions

FP and FIJ were involved in in-hospital treatment of this case. FP analyzed and interpreted the patient data. FIJ helped to draft the manuscript. All authors read and approved the final manuscript.

Funding

There are no sources of funding for this case report.

Availability of data and materials

This case report only contains clinical data from the medical records of the patient reported herein. The data will be made available upon request.

Ethics approval and consent to participate

Not applicable.

Consent for publication

Written informed consent was obtained from the patient's parents for publication of this Case report and any accompanying images. A copy of the written consent is available for review by the Editor of this journal.

Competing interests

The authors declare that they have no competing interests.

Received: 10 June 2020 Accepted: 1 December 2020

Published online: 09 December 2020

References

1. Vassy LE, Klecker RL, Koch E, Morse TS. Traumatic gastric perforation in children from blunt trauma. *J Trauma*. 1975;15(3):184–6.
2. Tejerina Alvarez EE, Holanda MS, López-Espadas F, Dominguez MJ, Ots E, Díaz-Regañón J. Gastric rupture from blunt abdominal trauma. *Injury*. 2004;35(3):228–31.
3. Brunsting LA, Morton JH. Gastric rupture from blunt abdominal trauma. *J Trauma*. 1987;27(8):887–91.
4. Rodríguez-Hermosa JI, Roig J, Sirvent JM, Codina-Cazador A, Gironès J, Puig J, et al. Gastric perforations from abdominal trauma. *Dig Surg*. 2008;25(2):109–16.
5. Bruscajin V, Coimbra R, Rasslan S, Abrantes WL, Souza HP, Neto G, et al. Blunt gastric injury. A multicentre experience. *Injury*. 2001;32(10):761–4.
6. Shinkawa H, Yasuhara H, Naka S, Morikane K, Furuya Y, Niwa H, et al. Characteristic features of abdominal organ injuries associated with gastric rupture in blunt abdominal trauma. *Am J Surg*. 2004;187(3):394–7.
7. Allen GS, Moore FA, Cox CS, Wilson JT, Cohn JM, Duke JH. Hollow visceral injury and blunt trauma. *J Trauma - Inj Infect Crit Care*. 1998;45(1):69–78.
8. Talton DS, Craig MH, Hauser CJ, Poole GV. Major gastroenteric injuries from blunt trauma. *Am Surg*. 1995;61(1):69–73.
9. Siemens RA, Fulton RL. Gastric rupture as a result of blunt trauma. *Am Surg*. 1977;43(4):229–33.
10. Takabe K, Ohtani T, Muto I, Takano Y, Miyauchi T, Kato H, et al. Computed tomography (CT) findings of gastric rupture after blunt trauma. *Hepato-gastroenterology*. 2000;47(33):901–3.
11. Lassandro F, Romano S, Rossi G, Muto R, Cappabianca S, Grassi R. Gastric traumatic injuries: CT findings. *Eur J Radiol*. 2006;59(3):349–54.

Publisher's Note

Springer Nature remains neutral with regard to jurisdictional claims in published maps and institutional affiliations.

Ready to submit your research? Choose BMC and benefit from:

- fast, convenient online submission
- thorough peer review by experienced researchers in your field
- rapid publication on acceptance
- support for research data, including large and complex data types
- gold Open Access which fosters wider collaboration and increased citations
- maximum visibility for your research: over 100M website views per year

At BMC, research is always in progress.

Learn more biomedcentral.com/submissions

