

University of Groningen

Accuracy of Patient-Specific 3D-Printed Drill Guides for Pedicle and Lateral Mass Screw Insertion

Pijpker, Peter A J; Kraeima, Joep; Witjes, Max J H; Oterdoom, D L Marinus; Vergeer, Rob A; Coppes, Maarten H; Groen, Rob J M; Kuijlen, Jos M A

Published in:
SPINE

DOI:
[10.1097/BRS.0000000000003747](https://doi.org/10.1097/BRS.0000000000003747)

IMPORTANT NOTE: You are advised to consult the publisher's version (publisher's PDF) if you wish to cite from it. Please check the document version below.

Document Version
Publisher's PDF, also known as Version of record

Publication date:
2021

[Link to publication in University of Groningen/UMCG research database](#)

Citation for published version (APA):

Pijpker, P. A. J., Kraeima, J., Witjes, M. J. H., Oterdoom, D. L. M., Vergeer, R. A., Coppes, M. H., Groen, R. J. M., & Kuijlen, J. M. A. (2021). Accuracy of Patient-Specific 3D-Printed Drill Guides for Pedicle and Lateral Mass Screw Insertion: An Analysis of 76 Cervical and Thoracic Screw Trajectories. *SPINE*, 46(3), 160-168. <https://doi.org/10.1097/BRS.0000000000003747>

Copyright

Other than for strictly personal use, it is not permitted to download or to forward/distribute the text or part of it without the consent of the author(s) and/or copyright holder(s), unless the work is under an open content license (like Creative Commons).

The publication may also be distributed here under the terms of Article 25fa of the Dutch Copyright Act, indicated by the "Taverne" license. More information can be found on the University of Groningen website: <https://www.rug.nl/library/open-access/self-archiving-pure/taverne-amendment>.

Take-down policy

If you believe that this document breaches copyright please contact us providing details, and we will remove access to the work immediately and investigate your claim.

Downloaded from the University of Groningen/UMCG research database (Pure): <http://www.rug.nl/research/portal>. For technical reasons the number of authors shown on this cover page is limited to 10 maximum.

CLINICAL CASE SERIES

OPEN

Accuracy of Patient-Specific 3D-Printed Drill Guides for Pedicle and Lateral Mass Screw Insertion

*An Analysis of 76 Cervical and Thoracic Screw Trajectories*Peter A.J. Pijpker, MSc,^a Joep Kraeima, MSc, PhD,^b Max J.H. Witjes, MD, PhD,^b
D.L. Marinus Oterdoom, MD,^a Rob A. Vergeer, MD,^a Maarten H. Coppes, MD, PhD,^a
Rob J.M. Groen, MD, PhD,^a and Jos M.A. Kuijlen, MD, PhD^a**Study Design.** Single-center retrospective case series.**Objective.** The purpose of this study was to assess the safety and accuracy of three-dimensional (3D)-printed individualized drill guides for pedicle and lateral mass screw insertion in the cervical and upper-thoracic region, by comparing the preoperative 3D surgical plan with the postoperative results.**Summary of Background Data.** Posterior spinal fusion surgery can provide rigid intervertebral fixation but screw misplacement involves a high risk of neurovascular injury. However, modern spine surgeons now have tools such as virtual surgical planning and 3D-printed drill guides to facilitate spinal screw insertion.**Methods.** A total of 15 patients who underwent posterior spinal fusion surgery involving patient-specific 3D-printed drill guides were included in this study. After segmentation of bone and screws, the postoperative models were superimposed onto the preoperative surgical plan. The accuracy of the realized screw trajectories was quantified by measuring the entry point and angular deviation.From the ^aUniversity of Groningen, University Medical Center Groningen, Department of Neurosurgery, Groningen, The Netherlands; and ^bUniversity of Groningen, University Medical Center Groningen, Department of Oral and Maxillofacial Surgery, Groningen, The Netherlands.

Acknowledgment date: February 12, 2020. First revision date: June 8, 2020. Acceptance date: August 13, 2020.

The device(s)/drug(s) that is/are the subject of this manuscript is/are exempt from FDA or corresponding national regulations because it is a custom made device.

The University Medical Center Groningen internal grant (CDO17.0021/2017-2/314) funds were received in support of this work.

No relevant financial activities outside the submitted work.

This is an open-access article distributed under the terms of the Creative Commons Attribution-Non Commercial-No Derivatives License 4.0 (CCBY-NC-ND), where it is permissible to download and share the work provided it is properly cited. The work cannot be changed in any way or used commercially without permission from the journal.

Address correspondence and reprint requests to Peter A.J. Pijpker, MSc, Staff Neurosurgery AB71, Department of Neurosurgery, University Medical Center Groningen, University of Groningen, PO BOX 30.001, 9700 RB Groningen, The Netherlands; E-mail: p.a.j.pijpker@umcg.nl

DOI: 10.1097/BRS.00000000000003747

160 www.spinejournal.com

Results. The 3D deviation analysis showed that the entry point and angular deviation over all 76 screw trajectories were 1.40 ± 0.81 mm and $6.70 \pm 3.77^\circ$, respectively. Angular deviation was significantly higher in the sagittal plane than in the axial plane ($P=0.02$). All screw positions were classified as “safe” (100%), showing no neurovascular injury, facet joint violation, or violation of the pedicle wall.**Conclusion.** 3D virtual planning and 3D-printed patient-specific drill guides appear to be safe and accurate for pedicle and lateral mass screw insertion in the cervical and upper-thoracic spine. The quantitative 3D deviation analyses confirmed that screw positions were accurate with respect to the 3D-surgical plan.**Key words:** 3D surgery, 3D printing, drill guide, guides, lateral mass screw, pedicle screw, rapid prototyping, templates, virtual surgical planning, VSP.**Level of Evidence:** 4**Spine 2021;46:160–168**

Posterior spinal screw fixation is a widely recognized procedure that is extensively used in the treatment of a range of spinal pathologies, including trauma, deformity, degenerative disease, and tumor. Accurate screw insertion is essential for safe and rigid fixation. Misplaced screws may lead to injury to vital structures or failure to achieve spondylodesis.^{1,2} Numerous studies have reported high rates of screw misplacement associated with freehand screw insertion (up to 30% in some cases).^{3–6} Moreover, freehand screw insertion involves the extensive use of fluoroscopy, which poses a risk of high radiation exposure for the surgical team.⁷

The urge for increased safety and reduced malpositioning and complication rates resulted in the development of computer-assisted surgery (CAS) techniques. Although CAS can improve screw insertion accuracy compared with freehand techniques, screw malpositioning and subsequent neurovascular injury still occur; indeed malposition rates of up to 18% have been reported.^{8–10} One of the pitfalls in navigated spinal instrumentation, and a well-known cause

of screw deviation, is the inability to rigidly immobilize the cervical spine, despite the use of cranial clamping. Surgical manipulation in this area may cause a disparity between imaging data and the actual position of the exposed spine, which can inadvertently result in screw malpositioning.

Recent years have seen a significant improvement in medical three-dimensional (3D) planning and printing, also known as 3D Virtual Surgical Planning (VSP) technology. In spinal fixation surgery, VSP can facilitate the precise pre-operative planning of screw trajectories. Individualized 3D-printed drill guides can be used to translate VSP to the operating theater with a high degree of accuracy.¹¹⁻¹³ Unlike CAS, 3D-printed drill guides maintain their accuracy despite the movement of vertebral levels during surgical manipulation, as each guide is designed to fit a specific vertebra.

A variety of spinal drill guides are described in the literature. These include designs for unilateral approaches,¹⁴ for multilevel application,¹⁵ and for use in revision surgery.¹⁶ However, there is no uniform methodology for evaluating accuracy, in terms of entry point- and angular deviation from the 3D-surgical plan. The authors recently proposed a novel method for quantitative 3D deviation analysis, presented a blueprint for the most optimal guide design, and evaluated the VSP workflow in a cadaveric series.¹⁷ In our present paper, we describe the results of a clinical study about the safety and accuracy of the 3D-printed drill guides used for pedicle and lateral mass screw insertion in the cervical and cervico-thoracic spine.

MATERIALS AND METHODS

Study Population

In this study, we selected patients with available postoperative computed tomography (CT) who had previously undergone cervical and/or upper-thoracic spinal fixation surgery involving individualized 3D-printed drill guides. The institutional review board approved the use of guides for spinal procedures. All procedures were performed between February 2017 and January 2019, at the Department of Neurosurgery, University Medical Center Groningen. The institutional review board provided a written statement that the requirements of the Medical Research Involving Human Subjects Act did not apply to this retrospective accuracy study (M17.206624). Since no waiver of approval was obtained, all patients provided written informed consent for use of their clinical data.

Virtual Surgical Planning (VSP)

VSP for the preparation and fabrication of each patient's guide took place prior to this accuracy study and briefly included the next steps. First, the preoperative CT scan was used for the coarse threshold segmentation of bone in Mimics v19 (Materialise, Leuven, Belgium). Using the split mask feature, 3D models were obtained for each individual vertebra. These models were then imported into 3-matic v12 (Materialise, Leuven, Belgium) to define the optimal screw

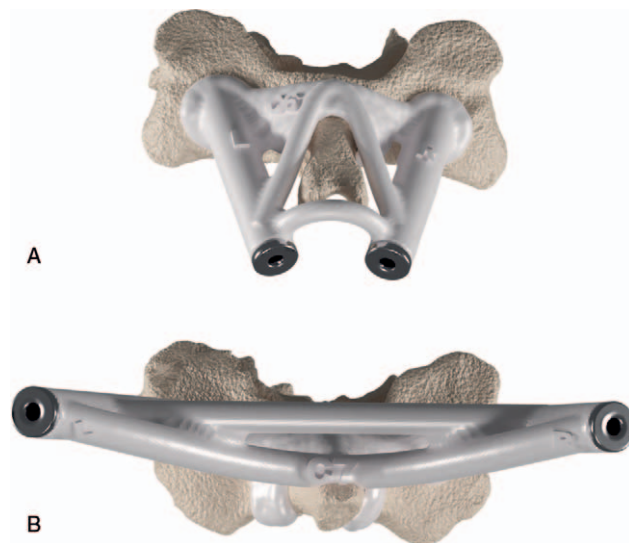

Figure 1. Example of a lateral mass (A) and pedicle (B) drill guide, with reinforcing cross connections, laminar hooks, and metallic inlays.

trajectories and to design drill guides tailored to each patient's spine. These guides included a laminar bone contact area, hooks around the spinous process, cross-connections, and inlay stainless steel sleeves for guidance of the drill bit (Figure 1). The cylindrical shaft was modified to match the length of the intended trajectory. Two illustrative cases are provided (see Results section) to show how guide designs may differ from one patient to another, to allow for variations in individual anatomy.

Surgical Procedure

A posterior midline vertical incision was made to expose the posterior aspect of the spinal column. All soft tissue was meticulously stripped from the laminae and spinous process, to ensure that the guides were in direct contact with the bony surface. After the guide was positioned and an optimal fit was confirmed, it was either held in place manually or fixed to the lamina with micro screws. The trajectories were confirmed radiographically and a 2 mm-wide pilot hole was drilled, corresponding to the predefined trajectory length (over-drilling was prevented by the integrated drill-stop). The resulting pilot hole provided guidance for hand-drilling or probing in the same direction. A pedicle feeler was used to check the integrity of the trajectory, after which self-tapping screws were inserted. The remaining part of the procedure was conducted according to standard practice (see Video 1, <http://links.lww.com/BRS/B655> which demonstrates the key steps of the VSP workflow and the intra-operative use of guides).

Three-Dimensional Deviation Analysis

Postoperative CT scans featuring metal artifact reduction were used to reconstruct 3D models of bone and screws. Using surface-based registration in 3-matic, the postprocedural models were superimposed onto the preoperative models to compare the planned and realized trajectories

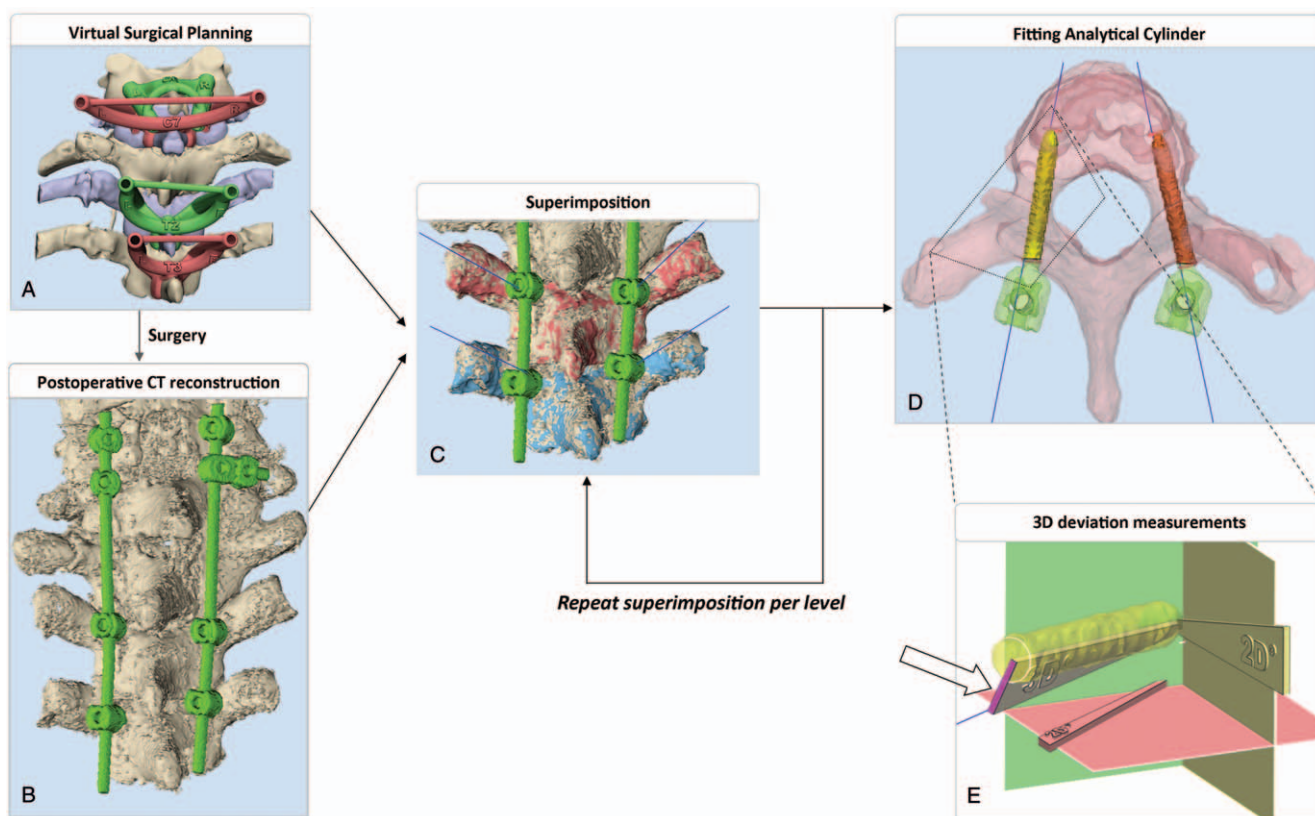


Figure 2. 3D deviation analysis method. The (A) preoperative plan and the (B) postoperative result are (C) fused, level by level, using registration algorithms. (D) The screw shanks are manually separated and an analytical cylinder is auto-fitted. (E) A deviation analysis is performed by measuring the 3D angle, the 2D sagittal (yellow) and axial (red) angles, between corresponding plan and result. The entry point deviation is measured in millimeters, here displayed in purple and pointed out by a black arrow.

(Figure 2A, B). Registration was repeated at each individual level, so these analyses were independent down to the level of individual vertebral alignment (Figure 2C). The screw shank was separated (Figure 2D) to facilitate the auto-fitting of analytical cylinders (Figure 2E). Next, measurements were taken of 3D angular deviation and entry point deviation (the latter being the shortest distance between the realized entry point and the planned trajectory). Although the 3D deviation methodology is supposed to be largely user independent due to the fact that most steps are automated, it was nevertheless decided to measure the methods' reliability, by having a second observer (JK) perform a 3D analysis of a randomly selected sample ($N = 10$) of screws. Screw insertion safety was also assessed, using “in” or “out” classification to assess violation of the pedicle wall.

Statistical Analysis

The statistical analysis was performed using SPSS Statistics For Windows (SPSS Version 23.0 for Windows, IBM, NY.) All accuracy data are presented as descriptive statistics, expressed as mean \pm standard deviation. Accuracy in the axial plane was compared with accuracy in the sagittal plane by means of a Student *t* test, after testing for normality of distribution. A *P* value of <0.05 was considered statistically significant. The intraclass correlation coefficient, the median variation, and the interquartile range (IQR) of the

variation were assessed to quantify the inter-rater reliability of the 3D analysis method (due to the data's non-normal distribution).

CASE ILLUSTRATIONS

Spine configurations vary, due to anatomical variations, degenerative deformities, or complex fractures. This often calls for additional design features, requiring medical engineers to devise novel solutions. We describe the VSP process and the subsequent surgical procedure, using two of the 15 reported cases for purposes of illustration.

The Unfused Spinous Process (Case 1)

A 10-year-old girl with spondylo-epiphysial dysplasia congenita presented with segmental instability (caused by odontoid hypoplasia and subsequent atlantoaxial dislocation) which required fixation surgery. The 3D VSP included meticulous preplanning of screw trajectories, as the patient's underdeveloped spine provided very little bone stock. Partially ossified spinous processes preclude the use of a single bone contact area. The guide design was modified to avoid the unfused spinous process, thus ensuring that the cartilage remained intact. Bilateral contact areas were selected on the lamina, and connected using a centrally located torus (Figure 3A). After being 3D-printed (Figure 3B), the drill guides were sterilized to be used intraoperatively.

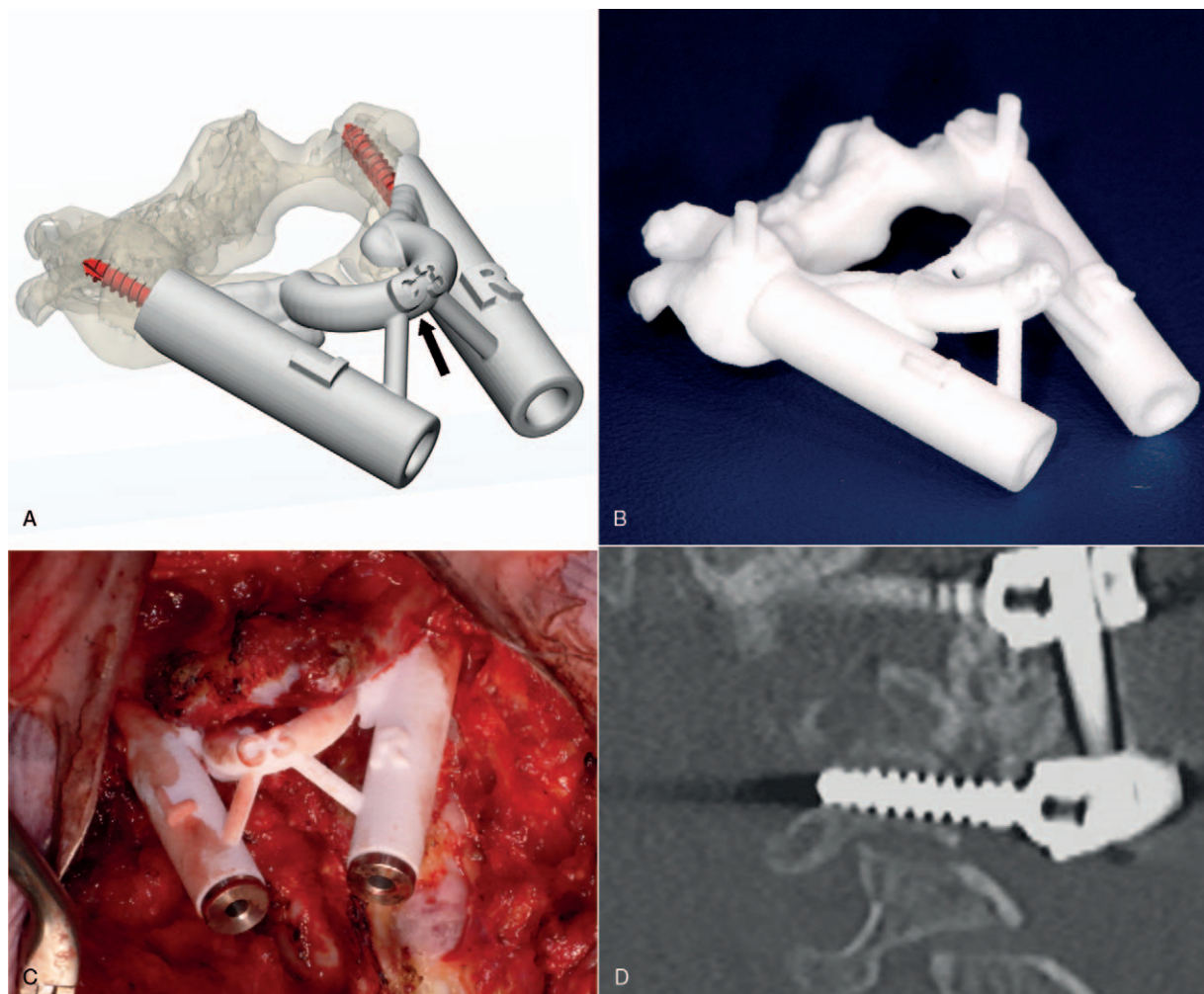


Figure 3. The use of a custom-made drill guide for immature C3 vertebrae, showing (A) the design, featuring a centrally located torus indicated by a black arrow, (B) 3D-print, (C) intraoperative positioning, and (D) postoperative image.

During surgery, the guides were positioned to achieve a precision fit (Figure 3C). The trajectories were drilled under radiographic monitoring, using appropriate drill stops. Self-tapping screws were inserted to the predefined depth, to ensure bicortical purchase. The postoperative phase was uneventful and subsequent imaging showed that the screws had been accurately positioned (Figure 3D).

C1 Lateral Mass Screw Insertion (Case 12)

A 63-year-old woman presented with neck and shoulder pain, due to a type III dens fracture resulting from an accidental fall. Imaging revealed an unstable fracture that required surgical fixation. A 3D VSP strategy was deployed for the challenging C1 lateral mass screw insertion. The original guide design was modified as follows: 1) the drill guide cylinders was positioned just below the C1 arch, and connected by a partial torus primitive (Figure 4A); 2) a modified metallic inlay was manufactured with a halved distal shaft, enabling it to slide beneath the flared section of the arch, thus protecting the C2 nerve root (Figure 4B); 3) hooks (thin enough to allow for deflection) were added

around both sides of the arch, providing a snap-fit attachment; 4) lastly, small holes were made for temporary guide fixation using micro-screws.

During surgery, the cervical spine was exposed subperiosteally from the occiput to C3. Further dissection was carried out along the caudal side of the C1 arch, creating space for the drill sleeve to slide beneath it (Figure 4C, D). The guide was positioned to create a precision fit, and was held in place using a single micro-screw. Next, the drill sleeve was inserted, the pilot trajectories were drilled, and self-tapping partially-threaded screws were inserted. The postoperative phase was uneventful. No postoperative complications were observed.

RESULTS

A total of 18 patients underwent cervical and/or upper-thoracic spinal fixation surgery involving individualized 3D-printed drill guides. Three patients were excluded due to missing postoperative CT, which resulted in a total of 15 patients included in this study. In all, 92 screw trajectories were preoperatively planned by VSP, 76 of which were used

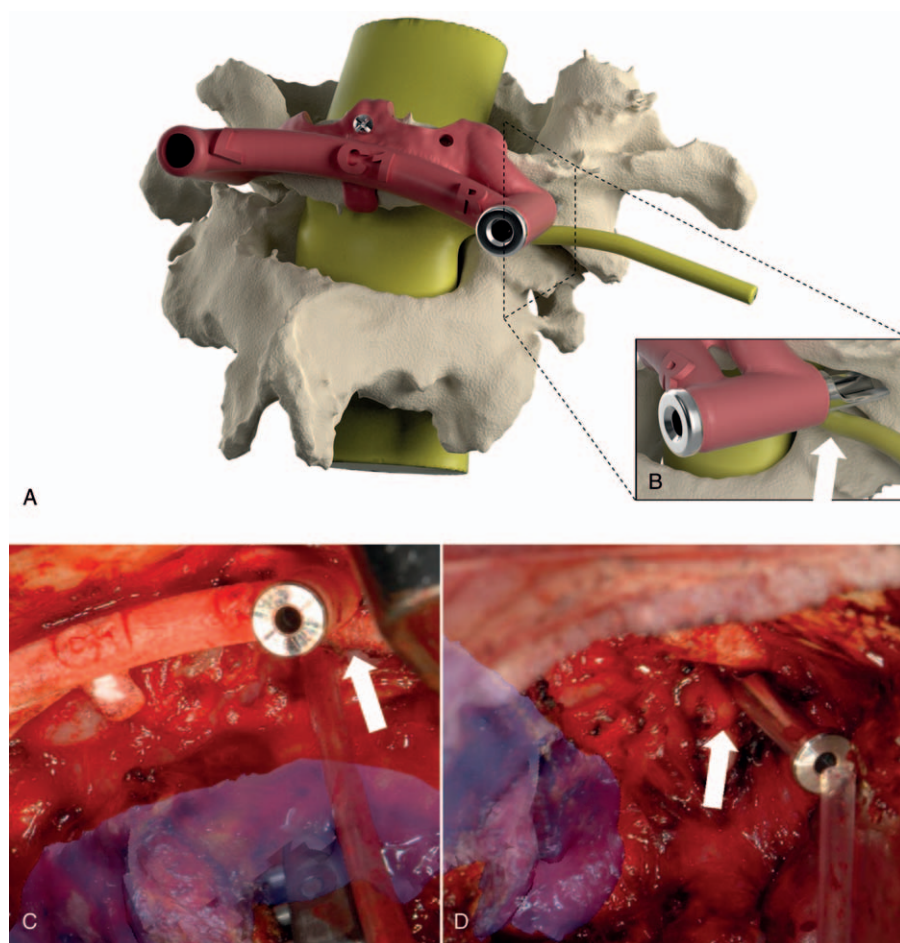


Figure 4. Where no photographs are available, the situation is illustrated using images of a similar case outside this series. (A) Positioning the C1 lateral mass guide, (B) sliding the sleeve underneath the arch, (C) intraoperative view, (D) the tip of the sleeve positioned between the arch and nerve root. The C2 nerve roots are indicated by white arrows.

to insert screws by means of guides. These screws were then subjected to 3D deviation analysis. For 16 trajectories the planned use of the guide was abandoned due to: per-procedural decision to use fewer screws than was envisaged in the preoperative planning ($N=11$); intraoperative conversion to conventional screw insertion, due to a dysfunctional guide design ($N=4$); and an intraoperative screw revision following a pull-out caused by poor bone quality ($N=1$). See Table 1 for a summary of the included patients, the corresponding 3D plan, and screws that were suitable for analysis.

Primary Outcome

The results of the 3D deviation analysis of both the pedicle and lateral mass screw trajectories are given in Table 2. The mean entry point and 3D angular deviation for all trajectories were 1.40 ± 0.81 mm and $6.70 \pm 3.77^\circ$, respectively. With regard to 2D angular accuracy, deviation was significantly higher in the sagittal plane than in the axial plane ($5.00 \pm 3.44^\circ$ vs. $3.75 \pm 3.07^\circ$, $P=0.02$), and the difference increases when the analysis was limited to pedicle screw trajectories alone ($5.74 \pm 3.64^\circ$ vs. $3.13 \pm 1.47^\circ$, $P=0.02$). Lateral mass guides were found to be more accurate than pedicle guides, but the difference was not significant (1.33 ± 0.79 mm vs. 1.73 ± 0.82 mm, $P=0.10$). All screw positions were classified as “safe” (100%) since there was

no neurovascular injury, facet joint violation, or violation of the pedicle wall.

Interobserver Variation











Measurement of a randomly selected sample of screws ($N=10$) by a second observer showed that the 3D analysis methodology has high inter-rater reliability. The intraclass correlation coefficient (two-way random) was 0.99, while the median differences between observers for entry point and angular deviation were 0.03 mm (IQR: 0.00–0.04 mm) and 0.09° (IQR: 0.03 – 0.43°), respectively.





DISCUSSION

This study evaluated the safety and accuracy of 3D-printed, individualized drill guides for 76 pedicle and lateral mass screw trajectories in the cervical and cervico-thoracic spine. All cases involved surgery using guides that were each designed to provide a unique and to guide the drill to a predefined angle and depth. Accuracy was quantitatively analyzed by superimposing the postoperative 3D models onto the 3D VSP. The analyses confirmed that these 3D-printed drill guides provided accurate screw positioning, with no cortical violation.

Traditionally, screw insertion in the cervical and thoracic spine has posed challenges with regard to accuracy and safety. It requires appropriate training and experience, especially

TABLE 1. Patient Characteristics and Corresponding 3D VSP

No.	Age	Sex M/F	No. of Screws	Levels	3D Virtual Surgical Plan
1	70	F	6	C3,C4,C5	
2	12	F	4	C1,C3	
3	75	F	4	C1,C2	
4	49	M	4	C3,C5	
5	66	F	4	C6,C7	
6	72	F	7	C6r, C3,T1,T2	
7	77	F	5	C2l, C3,C4	
8	48	F	4	C4,C5	
9	65	M	4	T2,T3	
10	41	M	1	C7r	
11	48	F	8	C6,C7,T2,T3	

No.	Age	Sex M/F	No. of Screws	Levels	3D Virtual Surgical Plan
12	63	F	4	C1,C2	
13	44	F	8	C3,C4,C5,C6	
14	18	M	7	C3l,C4r,C7l, C5,C6	
15	48	M	6	C5,C6,C7	

when using the freehand technique. However, new technical developments and intraoperative tools are now available to support surgeons during these critical steps of spinal instrumentation. One of these, CAS has been reported to produce fewer screw misplacements, but it has not been widely adopted in spinal instrumentation theaters.¹⁸ This may be due to intraoperative cervical mobility, which impacts accuracy. Accurate screw insertion is, however, particularly important in the cervical spine, due to the proximity of vital structures. A tool that is unaffected by intraoperative vertebral motion, like previously proposed by the authors and clinically assessed in this study, could be invaluable for spinal fixation surgery in this region.

3D VSP, a new tool in the surgeon’s armamentarium, matches the emerging mindset concerning detailed preoperative planning. In spinal surgery, this technique can be used to preoperatively plan screw trajectories and translated to the operating theater by 3D-printed drill guides.^{11,12,14,19} We have previously developed and assessed a VSP workflow through a cadaveric series, and have introduced a 3D deviation analysis approach.¹⁷ The

present paper evaluated clinical use and confirms accurate 3D-guided screw positioning, with no cortical violation. Screw insertion accuracy was greatest in the axial plane, particularly for pedicle screw trajectories. This might be due to the pedicles’ oval shape, which causes the cortical walls to restrict any major axial deviation.²⁰ Another explanation for the sagittal deviation could be that guides, which are mounted on the bone across the width of the lamina, provide less support and stability along the vertebra’s longitudinal axis.

Our past and present studies reported different accuracies, possibly due to different surgical approaches. Unlike the cadaveric study, which focused on drilling accuracy, the present study also measured screw insertion accuracy. Screw insertion may introduce additional inaccuracy, as screws can deviate from the pilot trajectory. Inhomogeneous bone density can exacerbate deviation from the intended course, as found in cases featuring dysplastic pedicles.²¹ Lee *et al*²² stated that the use of cannulated screws may improve accuracy with respect to the pilot trajectory. Moreover, Sugawara *et al*²³ used a 3D

Screw Trajectory	No. Trajectories	Mean ± SD			
		Entry Point Deviation (mm)	3D Angular Deviation (°)	2D Axial Deviation (°)	2D Sagittal Deviation (°)
Pedicle	14	1.73 ± 0.82	6.64 ± 3.44	3.13 ± 1.47	5.74 ± 3.64
Lateral mass	62	1.33 ± 0.79	6.72 ± 3.85	3.89 ± 3.31	4.84 ± 3.37
	76	1.40 ± 0.81	6.70 ± 3.77	3.75 ± 3.07	5.00 ± 3.44

guidance system to create a 3D-guided pilot hole, followed by an additional template to guide actual screw insertion. As yet, there have been no studies to confirm that the use of cannulated screws or a two-step template approach does indeed increase accuracy.

The guides were found to have three limitations. First, a common drawback is the importance of carefully exposing the bony structures. This can be time consuming, particularly in cases with poor bone quality, but accuracy requires that the bone-contact areas be meticulously skeletonized. On the other hand, though not part of this study, it has to be said that time might be saved in case no intraoperative imaging has to be acquired, and therefore suggested to include in future studies. However, it can also be difficult to measure this objectively. Second, the current guide's design has a bone contact area that requires the removal of interspinous ligament. This may be undesirable in cases where there is a risk of developing a junctional kyphosis. However, a full-width bone contact area could use the sharp ridge of the spinous process to facilitate an optimal fit and midline alignment. Several studies have presented guide designs that avoid removal of the ligament, but their use is restricted to the lumbar spine.^{15,24} Thirdly, guides were occasionally found to be dysfunctional. This was generally solved intraoperatively, by removing bone from any adjacent spinous processes that prevented a precise fit. In one case, trajectories created by 3D planning impeded the insertion of the drill bit, rendering the guide dysfunctional. In another case, the guide could not be precisely fitted to the C1 arch so it was decided that the C1 design should be altered, as shown in the illustrative cases.

This study provided quantitative data on the accuracy of 3D-printed guides, in terms of entry point and angular deviation. This data may be valuable for spine surgeons during forthcoming cases that involve VSP and help them select pedicles that are safe for 3D-guided screw insertion. The authors' learning curve prior to clinical implementation suggests that practice may, however, be needed to achieve comparable results. The current study also highlights the additional deviation that is introduced when inserting a screw into 3D-guided pilot holes. The screw insertion accuracy reported here differs from the 3D-guided drilling accuracy that was previously reported, so there may be some margin for improvement. We therefore recommend that studies be carried out to determine whether accuracy might be further improved by the use of cannulated screws or an additional template that guides the actual screw. Future work will involve the use of a similar 3D deviation analysis method to directly compare the accuracy of 3D VSP with CAS.

In conclusion, 3D VSP provides surgeons with new tools to prepare and visualize complex spinal procedures in an accurate and predictable manner. 3D-printed drill guides can ensure safe and accurate pedicle and lateral mass screw insertion. In addition, plans are outlined for a series of studies to compare this technique to CAS and to

determine whether two-step templates can further improve accuracy.

➤ Key Points

- ❑ Screw insertion in the cervical and thoracic spine poses challenges with regard to accuracy and safety.
- ❑ Virtual Surgical Planning—a new tool in the surgeon's armamentarium—can be used to preoperatively plan screw trajectories and translate them to surgery using 3D-printed guides.
- ❑ Screw insertion accuracy was quantitatively analyzed by superimposing the postoperative 3D model onto the 3D VSP.
- ❑ 3D-printed drill guides can be effectively used for safe and accurate pedicle and lateral mass screw insertion.

Supplemental digital content is available for this article. Direct URL citations appearing in the printed text are provided in the HTML and PDF version of this article on the journal's Web site (www.spinejournal.com).

References

1. Esses SI, Sachs BL, Dreyzin V. Complications associated with the technique of pedicle screw fixation. A selected survey of ABS members. *Spine (Phila Pa 1976)* 1993;18:2231–8.
2. Gertzbein SD, Robbins SE. Accuracy of pedicular screw placement in vivo. *Spine (Phila Pa 1976)* 1990;15:11–4.
3. Gaines RW Jr. The use of pedicle-screw internal fixation for the operative treatment of spinal disorders. *J Bone Joint Surg Am* 2000;82:1458–76.
4. Blumenthal S, Gill K. Complications of the wiltse pedicle screw fixation system. *Spine (Phila Pa 1976)* 1993;18:1867–71.
5. Liljenqvist UR, Halm HFH, Link TM. Pedicle screw instrumentation of the thoracic spine in idiopathic scoliosis. *Spine (Phila Pa 1976)* 1997;22:2239–45.
6. Vaccaro AR, Rizzolo SJ, Balderston RA, et al. Placement of pedicle screws in the thoracic spine. Part II: an anatomical and radiographic assessment. *J Bone Joint Surg Am* 1995;77:1200–6.
7. Slomczykowski M, Roberto M, Schneeberger P, et al. Radiation dose for pedicle screw insertion: fluoroscopic method versus computer-assisted surgery. *Spine (Phila Pa 1976)* 1999;24:975–83.
8. Ishikawa Y, Kanemura T, Yoshida G, et al. Intraoperative, full-rotation, three-dimensional image (O-arm)-based navigation system for cervical pedicle screw insertion. *J Neurosurg Spine* 2011;15:472–8.
9. Austin MS, Vaccaro AR, Brislin B, et al. Image-guided spine surgery: a cadaver study comparing conventional open laminoforaminotomy and two image-guided techniques for pedicle screw placement in posterolateral fusion and nonfusion models. *Spine (Phila Pa 1976)* 2002;27:2503–8.
10. Ishikawa Y, Kanemura T, Yoshida G, et al. Clinical accuracy of three-dimensional fluoroscopy-based computer-assisted cervical pedicle screw placement: a retrospective comparative study of conventional versus computer-assisted cervical pedicle screw placement. *J Neurosurg Spine* 2010;13:606–11.
11. Hu Y, Yuan Z, Spiker WR, et al. A comparative study on the accuracy of pedicle screw placement assisted by personalized rapid prototyping template between pre-and post-operation in patients with relatively normal mid-upper thoracic spine. *Eur Spine J* 2016;25:1706.

12. Kaneyama S, Sugawara T, Sumi M. Safe and accurate midcervical pedicle screw insertion procedure with the patient-specific screw guide template system. *Spine (Phila Pa 1976)* 2015;40:E341–8.
13. Lu S, Xu YQ, Zhang YZ, et al. A novel computer-assisted drill guide template for placement of C2 laminar screws. *Eur Spine J* 2009;18:1379–85.
14. Kim SB, Won Y, Yoo HJ, et al. Unilateral spinous process non-covering hook type patient-specific drill template for thoracic pedicle screw fixation. *Spine (Phila Pa 1976)* 2017;42:E1050–7.
15. Merc M, Vogrin M, Recnik G, et al. Error rate of multi-level rapid prototyping trajectories for pedicle screw placement in lumbar and sacral spine. *Chin J Traumatol* 2014;17:261–6.
16. Otsuki B, Takemoto M, Fujibayashi S, et al. Utility of a custom screw insertion guide and a full-scale, color-coded 3D plaster model for guiding safe surgical exposure and screw insertion during spine revision surgery. *J Neurosurg Spine* 2016;25:94–102.
17. Pijpker PAJ, Kraeima J, Witjes MJH, et al. Accuracy assessment of pedicle and lateral mass screw insertion assisted by customized 3D-printed drill guides: a human cadaver study. *Oper Neurosurg (Hagerstown)* 2019;16:94–102.
18. Hartl R, Lam KS, Wang J, et al. Worldwide survey on the use of navigation in spine surgery. *World Neurosurg* 2013;79:162–72.
19. Lu S, Xu YQ, Lu WW, et al. A novel patient-specific navigational template for cervical pedicle screw placement. *Spine (Phila Pa 1976)* 2009;34:E959–66.
20. Ebraheim NA, Xu R, Ahmad M, et al. Projection of the thoracic pedicle and its morphometric analysis. *Spine (Phila Pa 1976)* 1997;22:233–8.
21. Sarwahi V, Sugarman EP, Wollowick AL, et al. Prevalence, distribution, and surgical relevance of abnormal pedicles in spines with adolescent idiopathic scoliosis vs. no deformity: a CT-based study. *JBJS* 2014;96:e92.
22. Lee CK, Chan CYW, Gani SMA, et al. Accuracy of cannulated pedicle screw versus conventional pedicle screw for extra-pedicular screw placement in dysplastic pedicles without cancellous channel in adolescent idiopathic scoliosis: a computerized tomography (CT) analysis. *Eur Spine J* 2017;26:2951–60.
23. Sugawara T, Higashiyama N, Kaneyama S, et al. Multistep pedicle screw insertion procedure with patient-specific lamina fit-and-lock templates for the thoracic spine. *J Neurosurg Spine* 2013;19:185–90.
24. Chen HL, Wu DY, Yang HL, et al. Clinical use of 3D printing guide plate in posterior lumbar pedicle screw fixation. *Med Sci Monit* 2015;21:3948–54.