

University of Groningen

Three-dimensional virtual surgical planning in the oncologic treatment of the mandible

Kraeima, J; Glas, H H; Merema, B J; Vissink, A; Spijkervet, F K L; Witjes, M J H

Published in:
 Oral diseases

DOI:
[10.1111/odi.13631](https://doi.org/10.1111/odi.13631)

IMPORTANT NOTE: You are advised to consult the publisher's version (publisher's PDF) if you wish to cite from it. Please check the document version below.

Document Version
 Publisher's PDF, also known as Version of record

Publication date:
 2021

[Link to publication in University of Groningen/UMCG research database](#)

Citation for published version (APA):

Kraeima, J., Glas, H. H., Merema, B. J., Vissink, A., Spijkervet, F. K. L., & Witjes, M. J. H. (2021). Three-dimensional virtual surgical planning in the oncologic treatment of the mandible. *Oral diseases*, 27(1), 14-20. <https://doi.org/10.1111/odi.13631>

Copyright

Other than for strictly personal use, it is not permitted to download or to forward/distribute the text or part of it without the consent of the author(s) and/or copyright holder(s), unless the work is under an open content license (like Creative Commons).

The publication may also be distributed here under the terms of Article 25fa of the Dutch Copyright Act, indicated by the "Taverne" license. More information can be found on the University of Groningen website: <https://www.rug.nl/library/open-access/self-archiving-pure/taverne-amendment>.

Take-down policy

If you believe that this document breaches copyright please contact us providing details, and we will remove access to the work immediately and investigate your claim.

Downloaded from the University of Groningen/UMCG research database (Pure): <http://www.rug.nl/research/portal>. For technical reasons the number of authors shown on this cover page is limited to 10 maximum.

Three-dimensional virtual surgical planning in the oncologic treatment of the mandible

Joep Kraeima  | Haye H. Glas  | Bram Barteld Jan Merema  | Arjan Vissink  |
Fred K. L. Spijkervet  | Max J. H. Witjes 

Department of Oral and Maxillofacial Surgery, University Medical Center Groningen, University of Groningen, Groningen, The Netherlands

Correspondence

Joep Kraeima, Department of Oral and Maxillofacial Surgery, University of Groningen, University Medical Center Groningen, PO Box 30.001, Groningen NL-9700 RB, The Netherlands.
Email: j.kraeima@umcg.nl

Abstract

Objectives: In case of surgical removal of oral squamous cell carcinomas, a resection of mandibular bone is frequently part of the treatment. Nowadays, such resections frequently include the application of 3D virtual surgical planning (VSP) and guided surgery techniques. In this paper, current methods for 3D VSP leads for optimisation of the workflow, and patient-specific application of guides and implants are reviewed.

Recent findings: Current methods for 3D VSP enable multi-modality fusion of images. This fusion of images is not restricted to a specific software package or workflow. New strategies for 3D VSP in Oral and Maxillofacial Surgery include finite element analysis, deep learning and advanced augmented reality techniques. These strategies aim to improve the treatment in terms of accuracy, predictability and safety.

Conclusions: Application of the discussed novel technologies and strategies will improve the accuracy and safety of mandibular resection and reconstruction planning. Accurate, easy-to-use, safe and efficient three-dimensional VSP can be applied for every patient with malignancies needing resection of the mandible.

KEYWORDS

CAD/CAM, data fusion, head and neck cancer, mandible, optimisation, virtual surgical planning

1 | INTRODUCTION

In case of surgical removal of oral squamous cell carcinomas, a resection of mandibular bone is often part of the treatment. A resection of the mandible with a microscopic free margin of at least 5 mm on both ends of the resected specimen is required according to current clinical guidelines (Dutch online guideline database, 2015). The oncological-surgical challenge is to plan and perform an adequate resection with sufficient margins, based on preoperative clinical and imaging information.

Nowadays, mandibular malignancy resections frequently include the application of 3D virtual surgical planning (VSP) and guided surgery techniques. Currently, VSP is mostly based on

computed tomography (CT) data. Both intra-operative navigation and 3D printed surgical guides have been shown to provide an accurate translation of the 3D VSP to the surgical procedure (Bittermann et al., 2013; Schepers et al., 2016; Wilde et al., 2015; Yu et al., 2013).

For reconstruction of the mandible after a continuity resection and with extra-intraoral communicating wounds, a free vascularised fibular flap is reported as the gold standard (Cordeiro, Disa, Hidalgo, & Hu, 1999). Several studies have reported an accurate and safe workflow for 3D VSP-based fibula reconstruction of mandibular defects, occasionally in combination with a patient-specific reconstruction plate (Essig et al., 2011; Roser et al., 2010; Schepers et al., 2015; Weijs et al., 2016; Weitz, Wolff, Kesting, & Nobis, 2018; Yang et al., 2019; Zhang et al., 2016). This

paper critically reviews current methods for 3D VSP, leads for optimisation of the 3D VSP workflow and patient-specific application of guides and implants.

2 | OPTIMISATION OF VIRTUAL PLANNING—CT AND MRI FUSION

The aim of a bony resection of the mandible is to radically remove the tumour from the mandible or realise sufficient margin in relation to the soft tissue tumour. In general, three methods for image-based planning of such tumour removal are described. The first of which is a basic screen-to-screen interpretation of the extend of the tumour as the surgeon studies both the CT and magnetic resonance imaging (MRI), and occasionally PET scan results before the surgical procedure (Kraeima et al., 2015). Secondly, when, additionally a 3D VSP method is applied, the extend of the tumour can be included in the preoperative plan. This inclusion is usually performed by means of digital delineation on CT data (Schepers et al., 2016; Wilde et al., 2015). In this 3D VSP process, it is not always clear where to virtually plan the resection margins of the mandible. When the surgical margins are not well included in the preoperative plan, an intra-operative exploration or deviation from the 3D VSP may be needed. In addition, intra-operative deviation from planning can result in an inability to use the prepared patient specific guides and reconstruction plate, which leads to suboptimal reconstructions (Ramella et al., 2017). Thus, planning for adequate tumour removal should include detailed bone information as well as tumour characteristics such as localisation, size, shape and extension (Dai et al., 2012). In this respect, as the third alternative, it is a great progress when this information is extracted from multi-modality imaging: CT and MRI together (Dong, Dong, Hu, & Xu, 2011).

It is reported that a fusion of CT and MRI 2D slices combines the sensitivities of both modalities. This fusion provides the surgeon with more accurate information regarding the tumour in

relation to the surrounding structures (Abd El-Hafez et al., 2011; Blatt, Ziebart, Krüger, & Pabst, 2016; Dai et al., 2012; Farrow et al., 2016; Nemeč et al., 2007). The combination of information with regard to localisation, extent, size and shape of the tumour, as provided by CTs and MRIs, is crucial for adequate resection planning (Blatt et al., 2016; Dai et al., 2012; Rana et al., 2012, 2015). Application of this combined CT and MRI workflow has been shown to result in an accurate resection of mandibular tumours with tumour-free bone margins and no per-operative deviation from planning (Kraeima, Dorgelo, et al., 2018; Kraeima, Glas, Witjes, & Schepman, 2018; Kraeima, Glas, Steenbakkers, Spijkervet, Roodenburg, & Witjes, 2018). Figure 1 provides a schematic overview of this method, including the postoperative evaluation. An alternative strategy, the "triple-cut" method, was introduced by Ramella et al., 2017 (Ramella et al., 2017). In this strategy, multiple virtual scenarios for resection and reconstruction are combined in a single set of 3D printed guides. In this study, the bone margin status after resection was not reported, so this outcome cannot be compared with the study by Kraeima et al (Kraeima, Dorgelo, et al., 2018; Kraeima, Glas, et al., 2018; Kraeima, Steenbakkers, et al., 2018).

One could argue that tumour-free bone resections of the mandible with the afore mentioned methods could reflect an overestimation of the required and performed resection. It has been reported for breast cancer that MRI estimates tumour size more accurately compared to CT only, but overestimates the size (Pop et al., 2018). For oral head and neck cancer, it was reported that MRI decreases underestimation of the tumour in comparison with CT (Sarrión Pérez, Bagán, Jiménez, Margaix, & Marzal, 2015). Especially when the MRI shows marrow oedema or suspects peri-neural extension, the exact tumour border delineation is challenging, however still the best preoperative indicator in the 3D VSP workflow (Kolk et al., 2014; Van Cann et al., 2008). Histopathological confirmation of the exact tumour extension in suspected areas of bone is in need of the bony specimen to postoperatively be cut into thin lamellae. These lamellae should be superimposed on to the 3D virtual

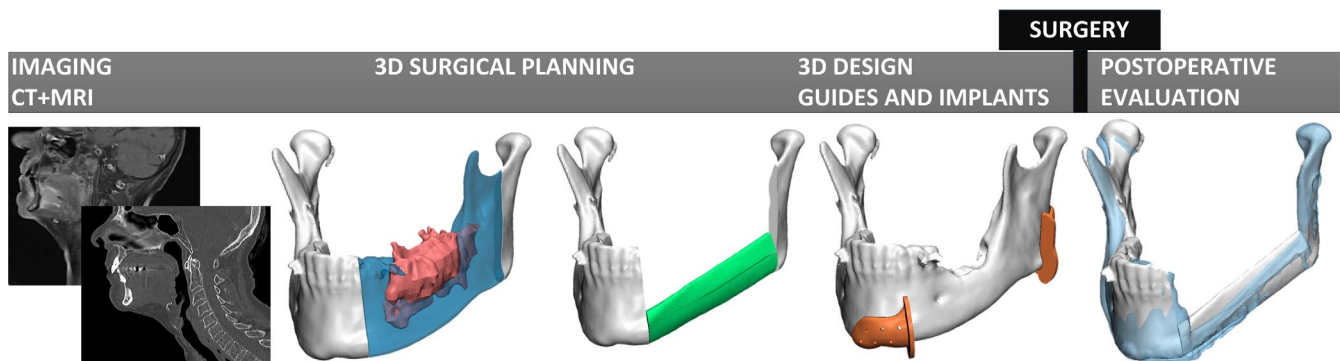


FIGURE 1 Overview of the workflow for 3D VSP in mandibular resection surgery. First the CT and MRI data is fused in order to combine bone and tumour information. After delineation of the tumour the resection is planned, as presented in blue in the second image. The mandible is reconstructed by planning a free vascularised fibular flap (green). In order to translate the procedure towards the actual surgery, patient specific cutting guides (orange) are designed and fabricated. After completion of the surgical procedure again a (CB) CT scan is made for detailed 3D evaluation, as presented in the last image [Colour figure can be viewed at wileyonlinelibrary.com]

model of the 3D resection planning including the tumour and the bone. This superimposition is still under development and not part of current routine, no reports were found with regard to such analysis.

The described 3D VSP workflow requires the availability of hard- and software as well as corresponding technical expertise. This is facilitated by a technical physician as part of the multidisciplinary team. It can be seen as a disadvantage that this expertise and additional hard- and software are not yet widely available in every hospital.

2.1 | Radiation dose visualisation in case of ORN

The use of multi-modality image fusion in 3D-VSP is not only applicable for mandibular resection planning, but also for surgical treatment of osteoradionecrosis (ORN). When a patient develops severe ORN (Marx, 1983; Rice, Polyzois, Ekanayake, Omer, & Stassen, 2015; Spijkervet, Brennan, Peterson, Witjes, & Vissink, 2019), a surgical intervention may be indicated, including removal of affected bone. ORN is defined as bone death following radiotherapy (RT) and is characterised by a non-healing area of exposed bone (Lambade, Lambade, & Goel, 2013; Marx & Johnson, 1987). There is a reported pathophysiological relationship between the occurrence of ORN in the jaw and the cumulative radiation dose to the bone as the radiation dose is reported to be a risk factor for the development of ORN. The risk of developing ORN of mandibular bone is considered to be medium when the bone was exposed to a cumulative dose of 40-60 Gy and high when the bone was exposed to a cumulative dose >60 Gy (Costa et al., 2016; Lyons & Ghazali, 2008; Reuther, Schuster, Mende, & Kübler, 2003; Wong, Wood, & McLean, 1997). When the original radiation dose is added as a visual volume into 3D-VSP, this information can support the decision with regard to resection planning (Kraeima, Dorgelo, et al., 2018; Kraeima, Glas, et al., 2018; Kraeima, Steenbakkens, et al., 2018). Yet, there is no consensus in literature with regard to the exact cut-off for received radiation

dose in case of planning a mandibular resection (Marx, 1983; Rice et al., 2015).

2.2 | Optimisation of image processing - deep learning

Each of the aforementioned 3D VSP applications require a segmented model of the anatomical structures and occurred pathology, of which the 3D models in Figure 1 are an example. In other words, a conversion step in which 2D slices of DICOM data (e.g., CT data) are segmented into a 3D virtual model. This segmentation can be time-consuming and user-dependent. Improvement of the 3D virtual model is achieved by optimisation of segmentation techniques (Minnema et al., 2018; Qiu et al., 2019). The use of a Deep learning image processing strategy could reduce the time and user dependency. Deep learning is a method of machine learning that enables a computer program to learn in a progressive way from its own experience, in order to continuously improve its ability to perform the (3D segmentation) task (Kwang Gi Kim, 2016). Artificial neural networks, which are a type of deep learning architecture, are computing systems that can learn and progressively improve their ability to learn (Schmidhuber, 2015). When applying artificial neural networks to segmentation of anatomical structures in medical image data (e.g., CT or MRI), the segmentation workflow is optimised by automation, decrease of the inter-observer variability and improvement of the accuracy (Neslisah Torosdagli et al., 2017; Zhou, Takayama, Wang, Hara, & Fujita, 2017). As is reported by Minnema et al. (Minnema et al., 2018, 2019), this method is applicable to both CT and ConeBeam CT (CBCT) data sets. Potentially, neural network application would enable accurate and fast segmentation of the required anatomical structures from each modality that the neural network is trained to process (Qiu et al., 2019). Currently, the application in daily practice is depending on the hospitals own engineering facilities and not implemented in widely available commercial software packages. It is expected that within a few years these functionalities are validated and implemented in easy-accessible 3D VSP software applications. This will lead to time saving, less user-dependent 3D VSP workflows.

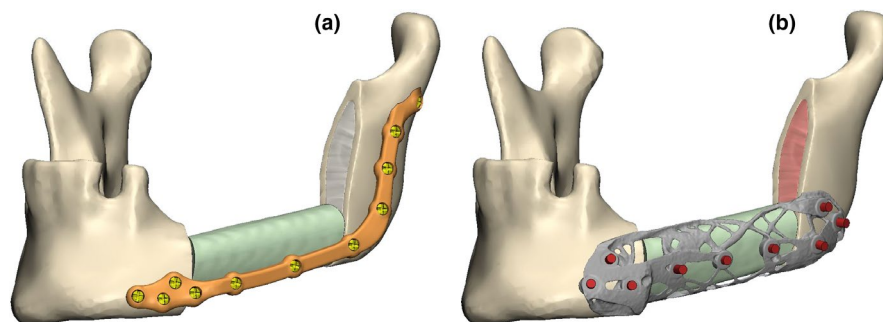


FIGURE 2 (a) An example of a 'conventional' patient specific reconstruction plate, fixing a fibula flap and the remaining segments of the mandible after resection. (b) A minimalistic, topology optimised design of a patient specific reconstruction plate based on finite element analysis. The input requirements in the analysis relate to bone characteristics (e.g., spongy bone in red, cortical bone in yellow), location of the screws and expected load [Colour figure can be viewed at wileyonlinelibrary.com]

2.3 | Optimisation of the 3D implant design—finite element analysis

Once a 3D-VSP is completed and approved by the surgeon, the VSP can be translated towards the patient using patient-specific surgical cutting and drilling guides and osteosynthesis materials, of which examples are presented in Figures 1 and 2a. The shape and fitting of these patient specific attributes is usually tailored to the contour of the bone of the individual case. In addition, the screw location and trajectories are planned, based on the thickness of the (cortical) bone and allowed surgical access. Tailoring of these products is performed in a 3D VSP design software application, based on experiences of the involved surgeons and engineers and starting from conventional off-shelf plate designs. This design process usually lacks a systematic application of biomechanical analysis on an individual patient basis. It is reported that these osteosyntheses can be subject to failure in terms of plate fracture or screw loosening, due to inadequate design adaptations of inhomogeneous loads (van Gemert et al., 2012; Kimura et al., 2006).

The application of biomechanical models to design osteosynthesis materials and implants, using the finite element (FE) method, was reported as a potential solution for failure of the materials (Deshmukh, Kuthe, Chaware, Bagaria, & Ingole, 2012; Kimura et al., 2006; Rodrigues et al., 2018). Finite element models, however, are not uniform and have a variation in required input factors such as constraints, load, mechanical properties of the bone, muscle forces and vectors. The application of a FE model can predict the behaviour, such as load distribution, stress or failure, of, for example osteosynthesis plates or implants. In search of further optimisation of the design of 3D VSP-based osteosynthesis and implants, the output of a FE model should be incorporated in the design process and function as input to a topology optimisation study. Topology optimisation is a mathematical method that, given certain boundary conditions, can optimise the design or layout of an object that match the input requirements. Application of topology optimisation has to be explored in future studies, using a FE model, applied to the design of osteosynthesis and implants and optimal locations for screws in oral and maxillofacial surgery. Figure 2 presents an example of a topology optimised design of a reconstruction plate in the mandible. Not only will this topology optimisation enable the evaluation of different designs, also the use of different materials with different characteristics (e.g., wear rate or stiffness) can be evaluated and adequate load transfer via the implants can be assured based on the FE analysis (Sutradhar, Park, Carrau, & Miller, 2014; Sutradhar et al., 2016).

2.4 | Optimisation of 3D VSP translation during surgery—augmented reality

Once the 3D-VSP is completed and the implant and surgical guides have been designed and produced, the plan must be translated to the actual surgical procedure. This translation is commonly performed

with 3D printed surgical guides, which is time consuming. The use of intra-operative navigation can be used as an alternative to 3D printed guides for translating the 3D VSP into a surgical procedure (Nemec et al., 2007; Yu et al., 2013, 2016; Zinser et al., 2013). Using intra-operative navigation has some drawbacks, however, mainly that the surgeon has to look away from the surgical field to receive feedback from the system (Berger et al., 2017) and the absence of haptic feedback to be received by the surgeon during the cutting or drilling. In case 3D information can be projected onto the surgical field, with good stability and accuracy, such an approach will probably optimise the translation from 3D VSP to the actual surgical procedure. The use of augmented reality via head mounted devices has been reported as a potential technique for translating 3D VSP to the actual surgical procedure (Bosc, Fitoussi, Hersant, Dao, & Meningaud, 2018). The first reports of augmented reality-supported navigation have shown that both speed and accuracy of performing the navigational tasks were significantly improved (Ahn, Choi, Hong, & Hong, 2019; Meulstee et al., 2018).

2.5 | Analysis of postoperative accuracy

A widely reported advantage of using 3D VSP is improvement in accuracy of the mandibular resection and reconstruction. As described, several methods for further optimisation of the 3D VSP workflow are in place or development, mainly to improve the speed and accuracy. To objectify this (improved), accuracy multiple methods are in use. Usually, a postoperative CT or CBCT is made which is aligned with the preoperative 3D VSP (Baan et al., 2016; van Baar, Liberton, Forouzanfar, Winters, & Leusink, 2019; van Eijnatten et al., 2018; Kraeima, Dorgelo, et al., 2018; Kraeima, Glas, et al., 2018; Kraeima, Steenbakkens, et al., 2018; Schepers et al., 2015). As reported by van Baar et al. (van Baar et al., 2019), heterogeneity in evaluation methods limits comparison of postoperative outcomes between studies. Furthermore, the aim for postoperative evaluation differs between studies. For example, outcome measures of evaluation can be the accuracy of the performed resection with regard to oncologic safety, the accuracy of the reconstruction in relation to a fibula graft or osteosynthesis materials, and the postoperative position of the inserted implants with respect to dental rehabilitation. It is important to define the primary outcome measure before defining a method for postoperative evaluation. Although it is not within the scope of this review to provide a guideline for measurement of postoperative accuracy for the different outcome measures, it is important to mention that pre- and postoperative CT or CBCT data are obtained conform a scanning protocol. Subsequently, validated software should be used for the image processing and alignment of the planning with the postoperative result. The definition of accuracy should be defined using anatomical landmarks or regions of interest that are easily recognisable and reproducible for clinicians. In addition, inter-observer variability is advised to be included in the analysis in order to present the user independency of the chosen method. Finally, development of improved software applications (Baan et al., 2016) is expected to reduce the manual steps in current

methods for 3D VSP and postoperative analysis, leading to improved objective and reproducible data describing the accuracy.

3 | CONCLUSION

Current methods for 3D VSP enable multi-modality image fusion and are not restricted to a specific software package or workflow. Image fusion will improve the accuracy and safety in case of mandibular resection and reconstruction planning. New strategies for 3D VSP in oral and maxillofacial surgery include using finite element analysis, deep learning and advanced augmented reality techniques. When applying such strategies, treatment will be improved in terms of accuracy, predictability and safety. The ultimate outcome will be that 3D VSP is applied for every patient in an optimised tailored way.

AUTHOR CONTRIBUTIONS

Joep Kraeima: Conceptualization; Data curation; Formal analysis; Investigation; Methodology; Software; Supervision; Validation; Visualization; Writing-original draft; Writing-review & editing. **Haye H. Glas:** Conceptualization; Data curation; Formal analysis; Investigation; Methodology; Software; Validation; Visualization; Writing-original draft; Writing-review & editing. **Bram Barteld Jan Merema:** Formal analysis; Resources; Software; Visualization; Writing-review & editing. **Arjan Vissink:** Conceptualization; Methodology; Supervision; Writing-original draft; Writing-review & editing. **Fred K.L. Spijkervet:** Conceptualization; Methodology; Supervision; Writing-original draft; Writing-review & editing. **Max Witjes:** Conceptualization; Data curation; Investigation; Methodology; Supervision; Writing-original draft; Writing-review & editing.

PEER REVIEW

The peer review history for this article is available at <https://publons.com/publon/10.1111/odi.13631>.

ORCID

Joep Kraeima  <https://orcid.org/0000-0001-8527-960X>
Haye H. Glas  <https://orcid.org/0000-0002-6641-7568>
Bram Barteld Jan Merema  <https://orcid.org/0000-0003-0994-3104>
Arjan Vissink  <https://orcid.org/0000-0003-2581-4361>
Fred K. L. Spijkervet  <https://orcid.org/0000-0003-0200-2344>
Max J. H. Witjes  <https://orcid.org/0000-0002-4135-3246>

REFERENCES

Abd El-Hafez, Y. G., Chen, C., Ng, S., Lin, C., Wang, H., Chan, S., & Yen, T. (2011). Comparison of PET/CT and MRI for the detection of bone marrow invasion in patients with squamous cell carcinoma of the oral cavity. *Oral Oncology*, 47(4), 288–295.

Ahn, J., Choi, H., Hong, J., & Hong, J. (2019). Tracking accuracy of a stereo camera-based augmented reality navigation system for orthognathic surgery. *Journal of Oral and Maxillofacial Surgery: Official Journal of the American Association of Oral and Maxillofacial Surgeons*, 77(5), 1070.e1–1070.e11.

Baan, F., Liebrechts, J., Xi, T., Schreurs, R., de Koning, M., Berge, S., & Maal, T. (2016). A new 3D tool for assessing the accuracy of bimaxillary surgery: The OrthoGnathicAnalyser. *PLoS One*, 11(2), e0149625. <https://doi.org/10.1371/journal.pone.0149625>

Berger, M., Nova, I., Kallus, S., Ristow, O., Freudlsperger, C., Eisenmann, U., ... Seeberger, R. (2017). Can electromagnetic-navigated maxillary positioning replace occlusional splints in orthognathic surgery? A clinical pilot study. *Journal of Cranio-Maxillofacial Surgery*, 45(10), 1593–1599.

Bittermann, G., Scheifele, C., Prokic, V., Bhatt, V., Henke, M., Grosu, A., ... Metzger, M. C. (2013). Description of a method: Computer generated virtual model for accurate localisation of tumour margins, standardised resection, and planning of radiation treatment in head & neck cancer surgery. *Journal of Cranio-Maxillofacial Surgery*, 41(4), 279–281. <https://doi.org/10.1016/j.jcms.2012.10.011>

Blatt, S., Ziebart, T., Krüger, M., & Pabst, A. M. (2016). Diagnosing oral squamous cell carcinoma: How much imaging do we really need? A review of the current literature. *Journal of Cranio-Maxillofacial Surgery*, 44(5), 538–549. <https://doi.org/10.1016/j.jcms.2016.02.003>

Bosc, R., Fitoussi, A., Hersant, B., Dao, T., & Meningaud, J., (2018). Intraoperative augmented reality with heads-up displays in maxillofacial surgery: A systematic review of the literature and a classification of relevant technologies. *International Journal of Oral and Maxillofacial Surgery*, 48(1), 132–139. <https://doi.org/10.1016/j.ijom.2018.09.010>

Cordeiro, P. G., Disa, J. J., Hidalgo, D. A., & Hu, Q. Y. (1999). Reconstruction of the mandible with osseous free flaps: A 10-year experience with 150 consecutive patients. *Plastic and Reconstructive Surgery*, 104(5), 1314–1320. <https://doi.org/10.1097/00006534-199910000-00011>

Costa, D. A., Costa, T. P., Netto, E. C., Joaquim, N., Ventura, I., Pratas, A. C., ... Moreira, A. R. (2016). New perspectives on the conservative management of osteoradionecrosis of the mandible: A literature review. *Head & Neck*, 38(11), 1708–1716. <https://doi.org/10.1002/hed.24495>

Dai, J., Wang, X., Dong, Y., Yu, H., Yang, D., & Shen, G. (2012). Two- and three-dimensional models for the visualization of jaw tumors based on CT-MRI image fusion. *Journal of Craniofacial Surgery*, 23(2), 502–508. <https://doi.org/10.1097/SCS.0b013e31824cd433>

Deshmukh, T. R., Kuthe, A. M., Chaware, S. M., Bagaria, V., & Ingole, D. S. (2012). A novel rapid prototyping and finite element method-based development of the patient-specific temporomandibular joint implant. *Computer Methods in Biomechanics and Biomedical Engineering*, 15(4), 363–370. <https://doi.org/10.1080/10255842.2010.538385>

Dong, Y., Dong, Y., Hu, G., & Xu, Q. (2011). Three-dimensional reconstruction of extremity tumor regions by CT and MRI image data fusion for subject-specific preoperative assessment and planning. *Computer Aided Surgery: Official Journal of the International Society for Computer Aided Surgery*, 16(5), 220–233. <https://doi.org/10.3109/10929088.2011.602721>

(2015). *Dutch online guideline database*.

Essig, H., Rana, M., Kokemueller, H., von See, C., Ruecker, M., Tavassol, F., & Gellrich, N. C. (2011). Pre-operative planning for mandibular reconstruction – a full digital planning workflow resulting in a patient specific reconstruction. *Head & Neck Oncology*, 3, 45. <https://doi.org/10.1186/1758-3284-3-45>

Farrow, E. S., Boulanger, T., Wojcik, T., Lemaire, A., Raoul, G., & Julieron, M. (2016). Magnetic resonance imaging and computed tomography in the assessment of mandibular invasion by squamous cell carcinoma of the oral cavity. influence on surgical management and post-operative course. *Revue De Stomatologie, De Chirurgie Maxillo-Faciale Et De Chirurgie Orale*, 117, 311–321. <https://doi.org/10.1016/j.revsto.2016.06.004>

Kim, K. G., (2016). *Deep learning*, 1st ed. Cambridge, MA: The MIT Press.

Kimura, A., Nagasao, T., Kaneko, T., Tamaki, T., Miyamoto, J., & Nakajima, T. (2006). Adequate fixation of plates for stability during mandibular reconstruction. *Journal of Cranio-Maxillo-Facial Surgery: Official*

- Publication of the European Association for Cranio-Maxillo-Facial Surgery, 34(4), 193–200. S1010-5182(06)00021-7
- Kolk, A., Schuster, T., Chlebowski, A., Lange, P., Scheidhauer, K., Kesting, M., ... Weitz, J. (2014). Combined SPECT/CT improves detection of initial bone invasion and determination of resection margins in squamous cell carcinoma of the head and neck compared to conventional imaging modalities. *European Journal of Nuclear Medicine and Molecular Imaging*, 41(7), 1363–1374. <https://doi.org/10.1007/s00259-014-2726-6>
- Kraeima, J., Dorgelo, B., Gulbitt, H. A., Steenbakk, R. J. H. M., Schepman, K. P., Roodenburg, J. L. N., & Witjes, M. J. H. (2018). Multi-modality 3D mandibular resection planning in head and neck cancer using CT and MRI data fusion: A clinical series. *European Oral Oncology*, 82, 22–28. <https://doi.org/10.1016/j.oraloncology.2018.03.013>
- Kraeima, J., Glas, H. H., Witjes, M. J. H., & Schepman, K. P. (2018). Patient-specific pre-contouring of osteosynthesis plates for mandibular reconstruction: Using a three-dimensional key printed solution. *Journal of Cranio-Maxillo-Facial Surgery: Official Publication of the European Association for Cranio-Maxillo-Facial Surgery*, 46(6), 1037–1040. S1010-5182(18)30098-2
- Kraeima, J., Schepers, R. H., van Ooijen, P. M. A., Steenbakk, R. J. H. M., Roodenburg, J. L. N., & Witjes, M. J. H. (2015). Integration of oncologic margins in three-dimensional virtual planning for head and neck surgery, including a validation of the software pathway. *Journal of Cranio-Maxillofacial Surgery*, 43(8), 1374–1379. <https://doi.org/10.1016/j.jcms.2015.07.015>
- Kraeima, J., Steenbakk, R. J. H. M., Spijkervet, F. K. L., Roodenburg, J. L. N., & Witjes, M. J. H. (2018). Secondary surgical management of osteoradionecrosis using three-dimensional isodose curve visualization: A report of three cases. *International Journal of Oral and Maxillofacial Surgery*, 47(2), 214–219. S0901-5027(17)31584-9
- Lambade, P. N., Lambade, D., & Goel, M. (2013). Osteoradionecrosis of the mandible: A review. *Oral and Maxillofacial Surgery*, 17(4), 243–249. <https://doi.org/10.1007/s10006-012-0363-4>
- Lyons, A., & Ghazali, N. (2008). Osteoradionecrosis of the jaws: Current understanding of its pathophysiology and treatment. *British Journal of Oral and Maxillofacial Surgery*, 46(8), 653–660. <https://doi.org/10.1016/j.bjoms.2008.04.006>
- Marx, R. E. (1983). A new concept in the treatment of osteoradionecrosis. *Journal of Oral and Maxillofacial Surgery*, 41(6), 351–357. [https://doi.org/10.1016/S0278-2391\(83\)80005-6](https://doi.org/10.1016/S0278-2391(83)80005-6)
- Marx, R. E., & Johnson, R. P. (1987). Studies in the radiobiology of osteoradionecrosis and their clinical significance. *Oral Surgery, Oral Medicine, and Oral Pathology*, 64(4), 379–390. [https://doi.org/10.1016/0030-4220\(87\)90136-8](https://doi.org/10.1016/0030-4220(87)90136-8)
- Meulstee, J. W., Nijsink, J., Schreurs, R., Verhamme, L. M., Xi, T., Delye, H. H. K., ... Maal, T. J. J. (2018). Toward holographic-guided surgery. *Surgical Innovation*, 26(1), 86–94. <https://doi.org/10.1177/1553350618799552>
- Minnema, J., Eijnatten, M., Hendriksen, A. A., Liberton, N., Pelt, D. M., Batenburg, K. J., ... Wolff, J. (2019). Segmentation of dental cone-beam CT scans affected by metal artifacts using a mixed-scale dense convolutional neural network. *Medical Physics*, 46(11), 5027–5035. <https://doi.org/10.1002/mp.13793>
- Minnema, J., van Eijnatten, M., Kouw, W., Diblen, F., Mendrik, A., & Wolff, J. (2018). CT image segmentation of bone for medical additive manufacturing using a convolutional neural network. *Computers in Biology and Medicine*, 103, 130–139. S0010-4825(18)30311-1
- Nemec, S. F., Donat, M. A., Mehra, S., Friedrich, K., Krestan, C., Matula, C., ... Czerny, C. (2007). CT-MR image data fusion for computer assisted navigated neurosurgery of temporal bone tumors. *European Journal of Radiology*, 62(2), 192–198. <https://doi.org/10.1016/j.ejrad.2006.11.029>
- Pop, C.-F., Stanciu-Pop, C., Drisis, S., Radermek, M., Vandemerck, C., Noterman, D., ... Veys, I. (2018). The impact of breast MRI workup on tumor size assessment and surgical planning in patients with early breast cancer. *Breast Journal*, 24(6), 927–933. <https://doi.org/10.1111/tbj.13104>
- Qiu, B., Guo, J., Kraeima, J., Glas, H. H., Borra, R. J. H., Witjes, M. J. H., & van Ooijen, P. M. A. (2019). Automatic segmentation of the mandible from computed tomography scans for 3D virtual surgical planning using the convolutional neural network. *Physics in Medicine and Biology*, 64(17), 175020. <https://doi.org/10.1088/1361-6560/ab2c95>
- Ramella, V., Franchi, A., Bottosso, S., Tirelli, G., Novati, F. C., & Arnez, Z. M. (2017). Triple-cut computer-aided design-computer-aided modeling: More oncologic safety added to precise mandible modeling. *Journal of Oral and Maxillofacial Surgery: Official Journal of the American Association of Oral and Maxillofacial Surgeons*, 75(7), 1567. e1–1567.e6. S0278-2391(17)30346-4
- Rana, M., Essig, H., Eckardt, A. M., Tavassol, F., Ruecker, M., Schramm, A., & Gellrich, N. C. (2012). Advances and innovations in computer-assisted head and neck oncologic surgery. *Journal of Craniofacial Surgery*, 23(1), 272–278. <https://doi.org/10.1097/SCS.0b013e318241bac7>
- Rana, M., Modrow, D., Keuchel, J., Chui, C., Rana, M., Wagner, M., & Gellrich, N. (2015). Development and evaluation of an automatic tumor segmentation tool: A comparison between automatic, semi-automatic and manual segmentation of mandibular odontogenic cysts and tumors. *Journal of Cranio-Maxillofacial Surgery*, 43(3), 355–359. <https://doi.org/10.1016/j.jcms.2014.12.005>
- Reuther, T., Schuster, T., Mende, U., & Kübler, A. (2003). Osteoradionecrosis of the jaws as a side effect of radiotherapy of head and neck tumour patients—a report of a thirty year retrospective review. *International Journal of Oral and Maxillofacial Surgery*, 32(3), 289–295. <https://doi.org/10.1054/ijom.2002.0332>
- Rice, N., Polyzois, I., Ekanayake, K., Omer, O., & Stassen, L. F. A. (2015). The management of osteoradionecrosis of the jaws – A review. *The Surgeon*, 13(2), 101–109. <https://doi.org/10.1016/j.surge.2014.07.003>
- Rodrigues, Y. L., Mathew, M. T., Mercuri, L. G., da Silva, J. S. P., Henriques, B., & Souza, J. C. M. (2018). Biomechanical simulation of temporomandibular joint replacement (TMJR) devices: a scoping review of the finite element method. *International Journal of Oral and Maxillofacial Surgery*, 47(8), 1032–1042. <https://doi.org/10.1016/j.ijom.2018.02.005>
- Roser, S. M., Ramachandra, S., Blair, H., Grist, W., Carlson, G. W., Christensen, A. M., ... Steed, M. B. (2010). The accuracy of virtual surgical planning in free fibula mandibular reconstruction: Comparison of planned and final results. *Journal of Oral and Maxillofacial Surgery: Official Journal of the American Association of Oral and Maxillofacial Surgeons*, 68(11), 2824–2832. <https://doi.org/10.1016/j.joms.2010.06.177>
- Sarrion Pérez, M. G., Bagán, J. V., Jiménez, Y., Margaix, M., & Marzal, C. (2015). Utility of imaging techniques in the diagnosis of oral cancer. *Journal of Cranio-Maxillo-Facial Surgery*, 43(9), 1880–1894.
- Schepers, R. H., Kraeima, J., Vissink, A., Lahoda, L. U., Roodenburg, J. L. N., Reintsema, H., ... Witjes, M. J. (2016). Accuracy of secondary maxillofacial reconstruction with prefabricated fibula grafts using 3D planning and guided reconstruction. *Journal of Cranio-Maxillofacial Surgery*, 44(4), 392–399. <https://doi.org/10.1016/j.jcms.2015.12.008>
- Schepers, R. H., Raghoebar, G. M., Vissink, A., Stenekes, M. W., Kraeima, J., Roodenburg, J. L., ... Witjes, M. J. (2015). Accuracy of fibula reconstruction using patient-specific CAD/CAM reconstruction plates and dental implants: A new modality for functional reconstruction of mandibular defects. *Journal of Cranio-Maxillofacial Surgery*, 43(5), 649–657. <https://doi.org/10.1016/j.jcms.2015.03.015>
- Schmidhuber, J. (2015). Deep learning in neural networks: An overview. *Neural Networks: The Official Journal of the International Neural Network Society*, 61, 85–117. S0893-6080(14)00213-5
- Spijkervet, F. K. L., Brennan, M. T., Peterson, D. E., Witjes, M. J. H., & Vissink, A. (2019). Research frontiers in oral toxicities of cancer

- therapies: Osteoradionecrosis of the jaws. *Journal of the National Cancer Institute. Monographs*, 2019(53), lgz006. <https://doi.org/10.1093/jncimonographs/igz006>
- Sutradhar, A., Park, J., Carrau, D., & Miller, M. J. (2014). Experimental validation of 3D printed patient-specific implants using digital image correlation and finite element analysis. *Computers in Biology and Medicine*, 52, 8–17. <https://doi.org/10.1016/j.compbiomed.2014.06.002>
- Sutradhar, A., Park, J., Carrau, D., Nguyen, T. H., Miller, M. J., & Paulino, G. H. (2016). Designing patient-specific 3D printed craniofacial implants using a novel topology optimization method. *Medical & Biological Engineering & Computing*, 54(7), 1123–1135. <https://doi.org/10.1007/s11517-015-1418-0>
- Torosdagli, N., Liberton, D. K., Verma, P., Lee, P., Pattanaik, S., Bagci, U. (2017). *Robust and fully automated segmentation of mandible from CT scans*. IEEE International Symposium on Biomedical Imaging, (arXiv:1702.07059).
- van Baar, G. J. C., Liberton, N. P. T. J., Forouzanfar, T., Winters, H. A. H., & Leusink, F. K. J. (2019). Accuracy of computer-assisted surgery in mandibular reconstruction: A postoperative evaluation guideline. *Oral Oncology*, 88, 1–8. S1368-8375(18)30422-6
- Van Cann, E. M., Rijpkema, M., Heerschap, A., van der Bilt, A., Koole, R., & Stoelinga, P. J. (2008). Quantitative dynamic contrast-enhanced MRI for the assessment of mandibular invasion by squamous cell carcinoma. *Oral Oncology*, 44(12), 1147–1154. <https://doi.org/10.1016/j.oraloncology.2008.02.009>
- van Eijnatten, M., van Dijk, R., Dobbe, J., Streekstra, G., Koivisto, J., & Wolff, J. (2018). CT image segmentation methods for bone used in medical additive manufacturing. *Medical Engineering & Physics*, 51, 6–16. S1350-4533(17)30263-1
- van Gemert, J. T., van Es, R. J., Rosenberg, A. J., van der Bilt, A., Koole, R., & Van Cann, E. M. (2012). Free vascularized flaps for reconstruction of the mandible: Complications, success, and dental rehabilitation. *Journal of Oral and Maxillofacial Surgery: Official Journal of the American Association of Oral and Maxillofacial Surgeons*, 70(7), 1692–1698. <https://doi.org/10.1016/j.joms.2011.08.024>
- Weijs, W. L., Coppens, C., Schreurs, R., Vreeken, R. D., Verhulst, A. C., Merkx, M. A., ... Maal, T. J. (2016). Accuracy of virtually 3D planned resection templates in mandibular reconstruction. *Journal of Cranio-Maxillo-Facial Surgery: Official Publication of the European Association for Cranio-Maxillo-Facial Surgery*, 44(11), 1828–1832. S1010-5182(16)30203-7
- Weitz, J., Wolff, K. D., Kesting, M. R., & Nobis, C. P. (2018). Development of a novel resection and cutting guide for mandibular reconstruction using free fibula flap. *Journal of Cranio-Maxillo-Facial Surgery: Official Publication of the European Association for Cranio-Maxillo-Facial Surgery*, 46(11), 1975–1978. S1010-5182(18)30461-X
- Wilde, F., Hanken, H., Probst, F., Schramm, A., Heiland, M., & Cornelius, C. (2015). Multicenter study on the use of patient-specific CAD/CAM reconstruction plates for mandibular reconstruction. *International Journal of Computer Assisted Radiology and Surgery*, 10(12), 2035–2051. <https://doi.org/10.1007/s11548-015-1193-2>
- Wong, J. K., Wood, R. E., & McLean, M. (1997). Conservative management of osteoradionecrosis. *Oral Surgery, Oral Medicine, Oral Pathology, Oral Radiology, and Endodontology*, 84(1), 16–21. [https://doi.org/10.1016/S1079-2104\(97\)90287-0](https://doi.org/10.1016/S1079-2104(97)90287-0)
- Yang, W. F., Zhang, C. Y., Choi, W. S., Zhu, W. Y., Li, D. T. S., Chen, X. S., ... Su, Y. X. (2019). A novel 'surgeon-dominated' approach to the design of 3D-printed patient-specific surgical plates in mandibular reconstruction: A proof-of-concept study. *International Journal of Oral and Maxillofacial Surgery*, 49(1), 13–21. S0901-5027(19)31164-6
- Yu, H., Wang, X., Zhang, S., Zhang, L., Xin, P., & Shen, S. G. (2013). Navigation-guided en bloc resection and defect reconstruction of craniomaxillary bony tumours. *International Journal of Oral and Maxillofacial Surgery*, 42(11), 1409–1413. <https://doi.org/10.1016/j.ijom.2013.05.011>
- Yu, Y., Zhang, W., Liu, X., Guo, C., Yu, G., & Peng, X. (2016). Three-dimensional accuracy of virtual planning and surgical navigation for mandibular reconstruction with free fibula flap. *Journal of Oral and Maxillofacial Surgery*, 74(7), 1503.e1–1503.e10. <https://doi.org/10.1016/j.joms.2016.02.020>
- Zhang, W., Yu, Y., Wang, Y., Mao, C., Liu, X., Guo, C., ... Peng, X. (2016). Improving the accuracy of mandibular reconstruction with vascularized iliac crest flap: Role of computer-assisted techniques. *Journal of Cranio-Maxillofacial Surgery*, 44(11), 1819–1827. <https://doi.org/10.1016/j.jcms.2016.08.014>
- Zhou, X., Takayama, R., Wang, S., Hara, T., & Fujita, H. (2017). Deep learning of the sectional appearances of 3D CT images for anatomical structure segmentation based on an FCN voting method. *Medical Physics*, 44(10), 5221–5233. <https://doi.org/10.1002/mp.12480>
- Zinser, M. J., Sailer, H. F., Ritter, L., Braumann, B., Maegele, M., & Zöller, J. E. (2013). A paradigm shift in orthognathic surgery? A comparison of navigation, computer-aided designed/computer-aided manufactured splints, and "Classic" intermaxillary splints to surgical transfer of virtual orthognathic planning. *Journal of Oral and Maxillofacial Surgery*, 71(12), 2151.e1–2151.e21. <https://doi.org/10.1016/j.joms.2013.07.007>

How to cite this article: Kraeima J, Glas HH, Merema BBJ, Vissink A, Spijkervet FKL, Witjes MJH. Three-dimensional virtual surgical planning in the oncologic treatment of the mandible. *Oral Dis*. 2021;27:14–20.

<https://doi.org/10.1111/odi.13631>