

University of Groningen

From Da Vinci Si to Da Vinci Xi

van der Schans, Emma M.; Hiep, Marijn A. J.; Consten, Esther C. J.; Broeders, Ivo A. M. J.

Published in:
Journal of robotic surgery

DOI:
[10.1007/s11701-020-01057-8](https://doi.org/10.1007/s11701-020-01057-8)

IMPORTANT NOTE: You are advised to consult the publisher's version (publisher's PDF) if you wish to cite from it. Please check the document version below.

Document Version
Publisher's PDF, also known as Version of record

Publication date:
2020

[Link to publication in University of Groningen/UMCG research database](#)

Citation for published version (APA):

van der Schans, E. M., Hiep, M. A. J., Consten, E. C. J., & Broeders, I. A. M. J. (2020). From Da Vinci Si to Da Vinci Xi: realistic times in draping and docking the robot. *Journal of robotic surgery*, 14(6), 835-839. <https://doi.org/10.1007/s11701-020-01057-8>

Copyright

Other than for strictly personal use, it is not permitted to download or to forward/distribute the text or part of it without the consent of the author(s) and/or copyright holder(s), unless the work is under an open content license (like Creative Commons).

The publication may also be distributed here under the terms of Article 25fa of the Dutch Copyright Act, indicated by the "Taverne" license. More information can be found on the University of Groningen website: <https://www.rug.nl/library/open-access/self-archiving-pure/taverne-amendment>.

Take-down policy

If you believe that this document breaches copyright please contact us providing details, and we will remove access to the work immediately and investigate your claim.

Downloaded from the University of Groningen/UMCG research database (Pure): <http://www.rug.nl/research/portal>. For technical reasons the number of authors shown on this cover page is limited to 10 maximum.

Identification of Intermediate Cell Types by Keratin Expression in the Developing Human Prostate

Yong Xue,¹ Frank Smedts,² Frans M.J. Debruyne,¹ Jean J.M.C.H. de la Rosette,¹ and Jack A. Schalken^{1*}

¹*Department of Urology, University Hospital Nijmegen, Nijmegen, The Netherlands*

²*Department of Pathology, Foundation of Collaborating Hospitals in East Groningen, Winschoten, The Netherlands*

BACKGROUND. The secretory acini of the adult human prostate contain basal, luminal, and intermediate types of exocrine cells. Intermediate cells are thought to play an important role in normal growth and neoplastic transformation. In this study we investigated whether this cell type is present in early stages of prostate development, using keratin antibodies specific for them.

METHODS. Autoptic tissue from 11 prepubertal and 5 normal adult prostates was immunohistochemically stained with four keratin antibodies capable of specifically detecting basal, luminal, or intermediate cell types.

RESULTS. Morphologically, in fetal prostate cells differentiation was often not evident. However, basally located cells usually displayed a basal-cell keratin-phenotype. Morphologically similar cells with more luminal localization expressed keratins typical of luminal cells, or of intermediate cells.

CONCLUSIONS. 1) In early stages of prostate development, cells with intermediate keratin-phenotype can be identified. 2) Their large numbers comply with a hierarchical pathway of cellular differentiation from basal to luminal cells. 3) The presence of intermediate cells at such an early fetal age may reflect their regulatory function in prostate development. *Prostate* 34:292–301, 1998. © 1998 Wiley-Liss, Inc.

KEY WORDS: intermediate filament; immunohistochemistry; embryology; maturation; benign prostatic hyperplasia; etiology

INTRODUCTION

Although benign prostatic hyperplasia (BPH) is one of the most common conditions in elderly men [1], our knowledge concerning its etiology is fragmentary. The correlation between adult neoplastic growth and fetal prostate development was first hypothesized by McNeal [2]. He emphasized that BPH occurring later in life is the result of a “reawakening” of the embryonic capability in the adult, i.e., of the stromal inductive potential on epithelial growth [2]. Prostatic early development and morphogenesis are dependent on inductive signals originating in the mesenchymal compartment [3]. Furthermore, adult urogenital epithelia maintain the capability to respond to stromal mediators of growth and differentiation, and several peptide

growth factors have been implicated in the development of BPH [4,5]. These studies on the embryology and development of the prostate provide important clues which may elucidate mechanisms of prostatic neoplasia.

In characterizing epithelial cell differentiation, antibodies against keratin (K) components of the cytoskeleton can be instrumental, as the 20 different members of this family are expressed in specific combinations in various types of epithelia. Moreover, their

*Correspondence to: Jack Schalken, Ph.D., Department of Urology, University Hospital Nijmegen, P.O. Box 9101, 6500 HB Nijmegen, The Netherlands. E-mail: j.schalken@uro.azn.nl

Received 3 June 1997; Accepted 6 October 1997

TABLE I. Characteristics of Monoclonal Antibodies Used in this Study

Antibody	Specificity	Localization in prostatic tissue	Dilution	Source	Reference
RCK102	K5 and K8	All epithelial cells	1:10	Dr. G. van Muijen, Nijmegen, Netherlands	20
34 β E12	K1, K5, K10, and K14	Basal cells	1:50	DAKO, Carpinteria, CA	21
RCK103	K5, etc.	Basal and some luminal cells	1:5	Dr. G. van Muijen, Nijmegen, Netherlands	17,18
CK18 (clone DC-10)	K18	Luminal cells	1:40	DAKO, Glostrup, Denmark	16,22

expression is related to specific stages of differentiation (reviewed in Moll et al. [6], Ramaekers et al. [7], and Nagle [8]). Previous keratin expression studies in the fetal prostate showed that of 30–36-week of gestation, only basal-cell keratins are expressed. In the 7-month neonate and 1-year-old infant, distinct changes in keratin expression occur, and a population of cells expressing basal-type keratins is found along with a population expressing luminal-type keratins [9]. However, data concerning the exact keratin-phenotype of these cells and possible transitions in keratin expression during fetal development are not available. At present, the keratin-phenotype for prostate exocrine epithelial cells comprises, among others, keratins 5 and 14, also called complex keratins found in basal cells, while luminal cells contain, among others, keratins 8 and 18, called simple keratins [10,11]. It is thought that during differentiation, basal cells acquire simple keratins (K8 + K18) and lose their basal-cell keratins (K5 + K14).

Based on light and electron microscopic studies in humans and dogs, a third cell type has been identified, having characteristics of both basal and luminal cells [12,13]. In the postnatal rat prostate these cells contain both basal-cell keratins 5 and 15 and luminal-cell keratins 8 and 18 [14]. Bonkhoff et al. [15] observed a subset of basal cells which coexpress basal-cell keratins and PSA (prostatic-specific antigen is usually only expressed in luminal cells). This is considered evidence for the presence of a group of cells with intermediate differentiation [15]. Our own studies confirm the presence of an intermediate cell type in the secretory acini of the normal adult human prostate, in BPH, in prostate carcinoma (PCa), and in involution-regeneration processes in rat prostate [16–18]. We demonstrated that these cells contain keratin 18 and express the basal-keratin antibody RCK103. Based on these observations we proposed that this cell type could be the same as the amplifying cells described in the stem-cell model [19].

Because knowledge concerning intermediate cells

in the developing human prostate is incomplete, we investigated the keratin-phenotype of epithelial cells in the prostate during various stages of human development to see whether cells with an intermediate cell keratin-phenotype could be identified. This may provide more information regarding the similarities between the process of prostate maturation and development of BPH.

MATERIALS AND METHODS

Tissues

Tissue specimens used in this study comprised 11 prepuberal prostates taken during autopsy in 5 fetuses (17, 19, 27, 32, and 38 weeks of gestation), 3 infants (2, 3.5, and 7 months old), and 3 prepubertal males (1 year and 4 months, 1 year and 7 months, and 11 years old). For comparative purposes, prostate tissue from 5 adults (27–49 years old) was also used. Tissue blocks were fixed in 10% phosphate-buffered formalin and processed through paraffin. All patients died of non-prostatically related diseases, and none of them had been hormonally treated. Postmortem delay did not exceed 10 hr (5.6 ± 2.4 hr). From each tissue block at least five consecutive sections were cut. The tissue block in the fetal prostate was a transversal section through the entire prostate. In the adults, a representative section was taken without identifying the anatomic location.

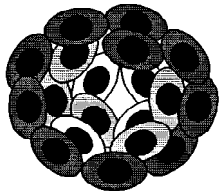
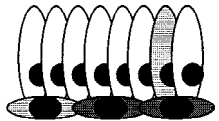
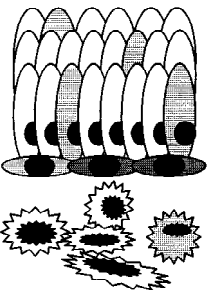
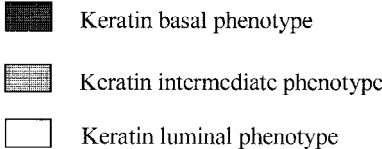
Antibodies

Four monoclonal antibodies were used in this study and are summarized in Table I.

Briefly, RCK102 directed against K5 and K8 is a broadly crossreacting keratin antibody. RCK102 stains most epithelial tissues, while nonepithelial tissues do not react with this antibody. We used RCK102 as a general epithelial marker [20].

Monoclonal antibody 34 β E12 recognizes K1, K5, K10, and K14. As K1 and K10 are characteristic of

TABLE II. Comparison of Intermediate Cell Types Identified by Keratin Phenotyping in the Prostate

	Characteristics of cell types	Morphology
<p>Budding Tip</p> 	<p>Developmental</p> <p>K14⁺/K5⁺/K18⁻</p> <p>K14[±]/K5[±]/K18[±]</p> <p>K14[±]/K5[±]/K18⁺</p> <p>K14⁻/K5⁻/K18⁺</p>	<p>Present data</p> <p>Basally located in budding acini</p> <p>Intermediately located in budding acini</p> <p>Luminally located in budding acini</p> <p>Luminally located in budding acini</p>
<p>Normal Adult Gland</p> 	<p>Normal adult</p> <p>K14⁺/K5⁺/K18⁻</p> <p>K14⁺/K5⁺/PSA⁺</p> <p>K14⁻/K5⁺/K18⁺</p> <p>K14⁻/K5⁻/K18⁺</p>	<p>References 15, 17, 18</p> <p>Spindle-shaped basal cells</p> <p>Spindle-shaped basal cells</p> <p>Tall columnar luminal cells</p> <p>Tall columnar luminal cells</p>
<p>BPH, PCa</p> 	<p>Regenerating, BPH, and PCa</p> <p>K14⁺/K5⁺/K18⁻</p> <p>K14⁻/K5⁺/K18⁻</p> <p>K14⁺/K5⁺/PSA⁺</p> <p>K14⁻/K5⁺/K18⁺</p> <p>K14⁻/K5⁻/K18⁺</p>	<p>References 16–18</p> <p>Spindle-shaped basal cells</p> <p>Basal-cell hyperplasia</p> <p>Spingle-shaped basal cells</p> <p>Luminally-located, and some tumor cells</p> <p>Tall columnar luminal cells, and tumor cells</p>
	<p></p> <p>■ Keratin basal phenotype</p> <p>▨ Keratin intermediate phenotype</p> <p>□ Keratin luminal phenotype</p>	

stratified keratinizing squamous epithelium, which is not found in the prostate, this antibody recognizes K5 and K14 in prostatic tissue [21].

RCK103 recognizes K5 and a number of other keratins that are not yet characterized. In the prostate it reacts with basal cells and intermediate cells, and to identify these last cells they must coexpress K18 [16,17].

CK18 (clone DC-10) recognizes K18. In the prostate this keratin is found in luminal cells, for which it is considered a marker [22].

Immunohistochemistry

Four-micrometer tissue sections were cut from paraffin blocks, mounted on coated slides, and dried overnight. After deparaffination, antigen retrieval was performed: for CK18 (DC-10), microwave heating was performed according to the manufacturer's instructions. For the antibodies RCK102 and RCK103, antigen retrieval was achieved according to a modified protocol [23] by submerging the slides in a 0.5% periodic acid solution and microwave heating for two cycles of

5 min each (180 W). For 34βE12, slides were incubated with 0.1% Pronase XIV solution (P-5147, Sigma Chemical Co.) dissolved in 10 mM Tris, 1 mM EDTA, pH 7.5, at 37°C for 10 min. Sections were incubated with the primary antibodies at 4°C overnight. Biotinylated secondary antibody and ABC complex were used (Elite Vector ABC kit, Amersham, Burlingame, CA). Peroxidase activity was visualized with diaminobenzidine (DAB) as a chromogen. Sections were briefly counterstained in hematoxylin and cover-slipped.

Evaluation of Keratin Immunostaining Results

The number of positively staining cells in the entire section was estimated for the four keratin-antibodies semiquantitatively and independently by two of us (Y.X., F.S.). Any discrepancies were discussed and consensus was reached in all cases. The number of positive staining cells was estimated and recorded as follows: -, no cells stained; +/-, incidental positive cells, <1%; +, between 1–25% of cells; ++, between 26–50% of cells; +++, between 51–75% of cells; and +++++, between 76–100% of cells. Staining intensity

was not separately graded, as it was often heterogeneous within a specimen and between specimens. The pattern of staining, however, was constant. Staining was evaluated separately for the three cell types in the budding tips, also referred to as the distal compartment (see Results), and for the more proximal tubules referred to as the ductal compartments which are directly adjacent to the urethral orifice and which show immature glandular lumens. Positive controls consisted of prostate tissues from surgery specimens, which are known to react strongly with the antisera used [17]. Bovine serum albumin was used instead of the primary antibodies for negative controls.

RESULTS

Light Microscopy

Topographically, prostate epithelial cells could be subdivided into three types, and are illustrated schematically in Table II. First, basally located cells were directly adjacent to the basal membrane, which separated them from the stromal compartment. These cells had no direct contact with glandular lumen. Second, intermediately located cells were found above the basal cells and underneath the lumenally located cells which lined the prostate acinus. In early development, many layers of these suprabasal cells were seen in solid cords in the peripheral zone of prenatal and infantile prostate. Third, lumenally located cells lined the acini. Under them, basally located cells and sometimes intermediately located cells were found. In early development, it was not easy to identify these cells separately.

The epithelial compartment of the 17- and 19-week fetuses consisted of budding solid cords of cells in the peripheral parts of the gland, surrounded by highly cellular stroma (Fig. 1a). The basement membrane was inconspicuous. Cells in the solid cords had relatively large ovoid nuclei and scant cytoplasm. Columnar cells were not recognizable. Luminal differentiation was found in the proximal parts of the tubules. The luminal portion of these ducts was lined by nonciliated low columnar or cuboid cells with underlying multilayered basaloid cells. In the 27-week fetus and in the older fetuses, the branching process started to appear in the peripheral parts of the prostate. It was characterized by increased numbers of solid buds and tubules lined by epithelium, similar to those found in the younger fetus. The ducts in the vicinity of the urethra were sometimes lined by squamous metaplastic epithelium (Fig. 2c).

The prostates from the 4 infants showed a histologic picture different from that of the fetuses. The number of developing solid cords had increased and

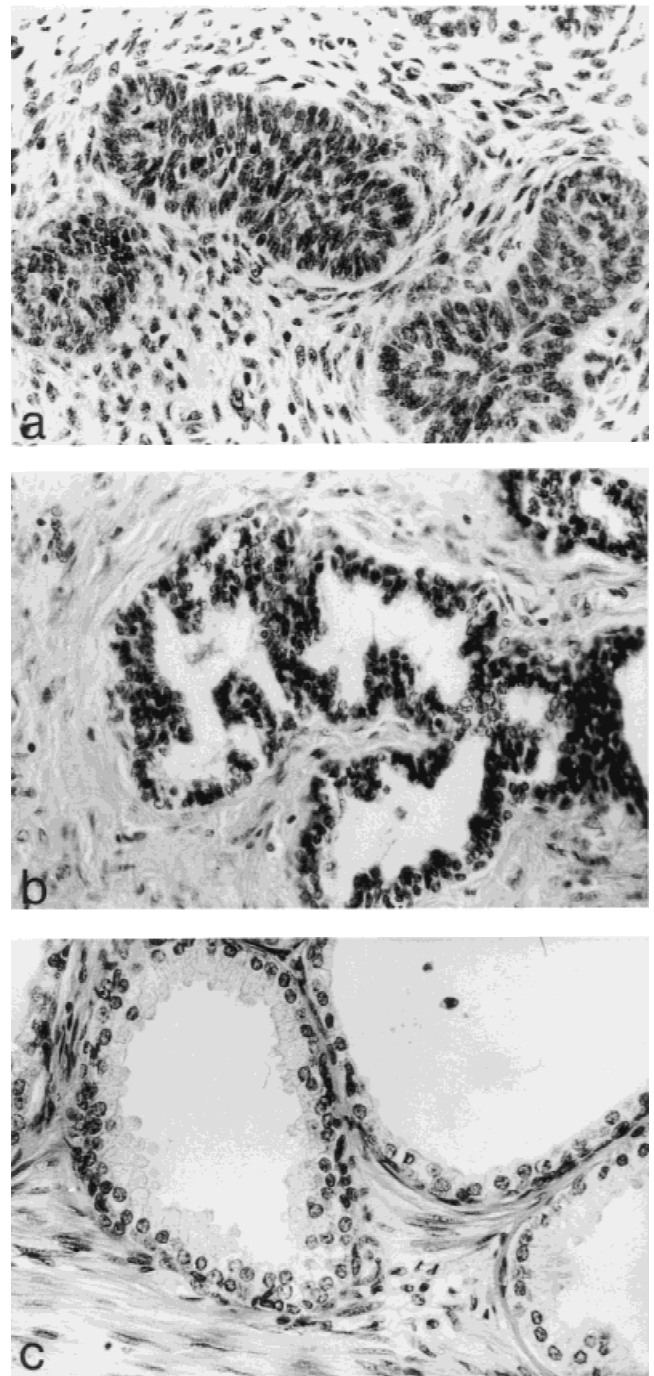


Fig. 1. H&E-stained tissue sections from prostate. **a:** 11-week fetus. **b:** 11-year-old male. **c:** 49-year-old male. Original magnification: objective $\times 40$.

also the number of ducts. The stroma was a little less cellular. The basally located cells were the same as in the fetus, but more cords had lumina lined by columnar cells.

In the two prostates from children, 16 and 19 months old, solid cords of epithelial cells were mostly replaced by arborizing tubules lined by one or more

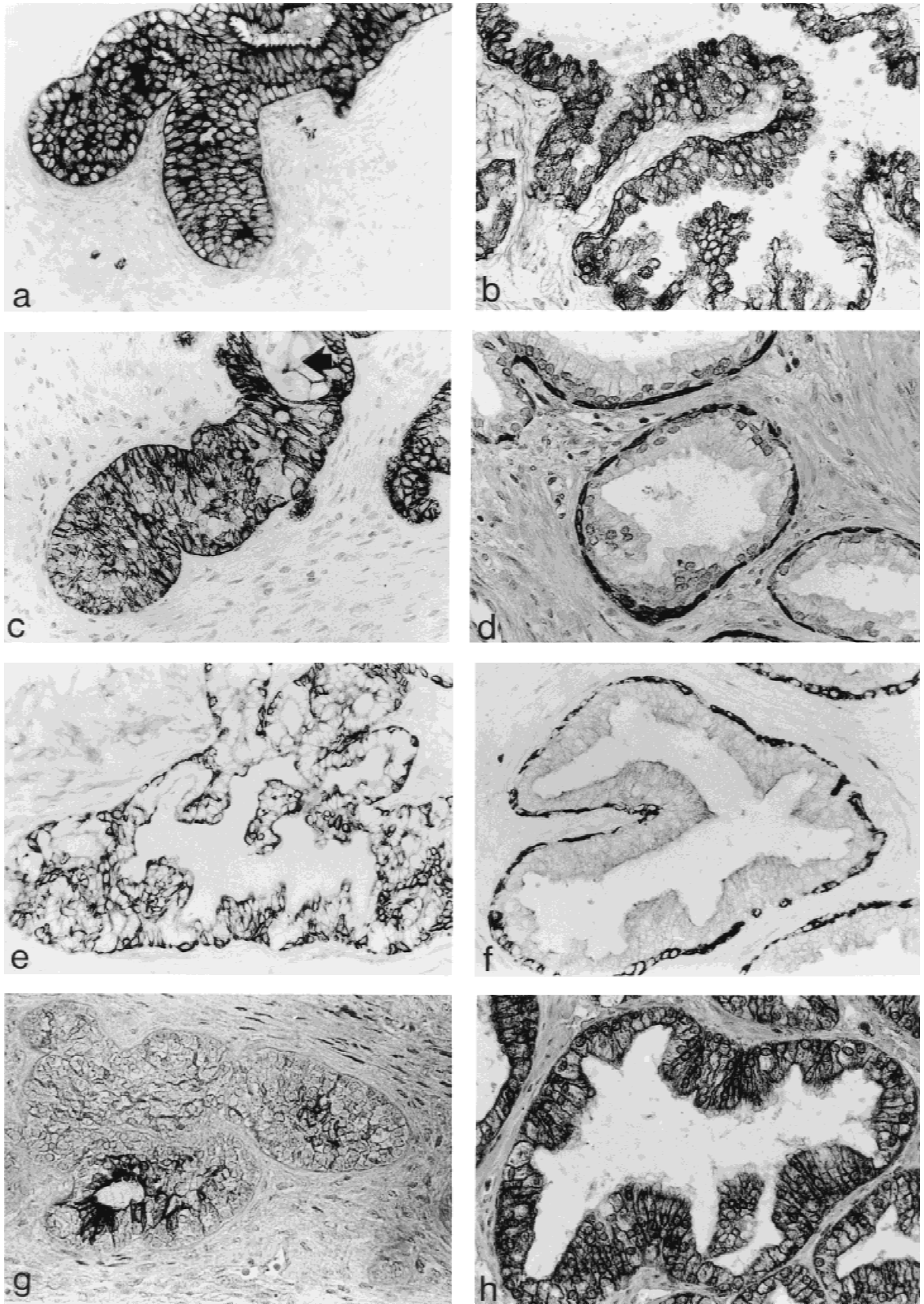


Fig. 2. Immunoperoxidase staining pattern of developing (a,c,e,g) and adult (b,d,f,h) prostate after staining with RCK102 (a,b), 34βE12 (c,d), RCK103 (e,f), and CK18 (g,h). Tissue sections were from prostates of (a) 19-week fetus, (c) 32-week fetus, (e) 11-year-old male, and (g) 32-week fetus. Arrow indicates squamous metaplastic epithelium (c). Original magnification: objective $\times 40$.

TABLE III. Cellular Keratin Phenotype on Budding Tips of Developing Acini and Mature Glands in the Prostate*

















































































































Age	Site	RCK102	34βE12	RCK103	CK18
17 weeks	B	NA		NA	
	I	NA		NA	
	L	NA		NA	
19 weeks	B				
	I				
	L				
27 weeks	B				
	I				
	L				
32 weeks	B				
	I				
	L				
38 weeks	B				
	I				
	L				
2 months	B				
	I				
	L				
3.5 months	B				
	I				
	L				
7 months	B				
	I				
	L				
1 year, 4 months	B				
	I				
	L				
1 year, 7 months	B				
	I				
	L				
11 years	B				
	I				
	L				

TABLE III. Continued

Age	Site	RCK102	34 β E12	RCK103	CK18
Mature gland					
27 years	B				
	L				
39 years	B				
	L				
42 years	B				
	L				
48 years	B				
	L				
49 years	B				
	L				

*A completely solid bar indicates that between 75–100% of cells stained. A $\frac{3}{4}$ solid bar indicates that between 50–75% of cells stained. A $\frac{1}{2}$ solid bar indicates that between 25–50% of cells stained. A $\frac{1}{4}$ solid bar indicates that between 1–25% of cells stained. An open bar indicates that no cells stained. Horizontal lines mean incidental positive in <1% of cells. B, basally located cells; I, intermediately located cells; L, lumenally located cells; NA, not available; F, fetus. For details of scoring, see Materials and Methods.

layers of small cells with relatively large nuclei and scant cytoplasm. Luminal low columnar or cuboidal cells, usually with large central nuclei, were also seen. Polarity and secretory vacuoles in the supranuclear portion were hardly discernible, and often it was difficult to distinguish these cells from adjacent cells with more basaloid features. The prostate of the prepubertal 11-year-old male basically showed the same picture as in the infants, especially in the distal segment of the ductal acini. This was characterized by a more elaborate formation of arborizing irregularly-shaped glands consisting of a single layer of small spindle-shaped basal cells underlying a single layer of tall columnar luminal cells with periapical vacuolation of their cytoplasm. Stroma was still predominant but less cellular in comparison to younger prostates (Fig. 1b). For comparison, the histology of adult prostate acini is shown in Figure 1c.

Keratin Immunophenotyping

Keratin expression was separately evaluated in the distal segment of branching glandular structures or budding tips, and in the proximal ductal compartment associated with the urethra, for the basally-located, intermediately-located, and lumenally-located cells.

Keratin Immunophenotyping in the Developing Prostate (Table III, Fig. 2)

Basally-located cells. In 9 of 11 developing prostates, all basally-located cells were positive for RCK102 and

34 β E12 (Fig. 2a,c). In 2 cases about half of the basally-located cells stained for 34 β E12. Monoclonal antibody RCK103 was intensely immunoreactive with basally located cells in both budding tips and ducts of the developing prostate (Fig. 2e). However, there was some variability in the number of positively staining cells, and in 3 cases approximately 50% of cells stained, and one case was negative. CK18 was not expressed in the basal-cell compartment of any of the cases (Fig. 2g).

Intermediately-located cells. In all but 2 cases, all intermediately located cells stained with the RCK102 antibody (Fig. 2a). 34 β E12, a marker for basal cells, stained 50–75% of cells in the intermediate compartment of 10 cases (Fig. 2c), while in one case only sporadic cells stained. RCK103 stained the cells in this compartment in most cases. However, the percentage of cells staining was considerably lower than that found in the basal compartment (Fig. 2e). In one case, only sporadic cells stained. CK18 was detected in 10 cases in the intermediate compartment. One case was negative. Immunoreactivity was variable, with 4 cases showing positivity in 50% of cells, 2 cases showing positivity in 25% of cells, and 4 cases showing only sporadic staining (Fig. 2g).

Lumenally-located cells. RCK102 was positive in all cases in most cells (Fig. 2a). In 9 cases, between 25–50% of luminal cells stained with 34 β E12 (Fig. 2c). In

one case, only sporadic cells were immunoreactive, and in one case the luminal compartment was negative. The cases with the least reactivity were the infant and the prepubertal prostate. In most cases, RCK103 showed the same or slightly less immunoreactivity than with intermediately-located cells (Fig. 2e). In one case, only sporadic cells stained, and one other case was completely negative. Keratin 18 was detectable in the lumenally-located cells of all cases. However, the percentage of positive cells varied. In 6 cases, virtually all cells in the luminal compartment stained (Fig. 2g), in 3 cases, 75%, in one case, 50%, and in one other case, only 25%. For K18, there seemed to be a trend toward lower levels of immunoreactivity in luminal cells with lower fetal age.

Keratin Immunoreactivity in Ductal Compartments

In general, ductal compartments showed immunoreactivity that paralleled that of the budding tips. Only salient features of keratin phenotyping are described. Differential expression of the various keratin antibodies between basal and luminal cells was often more obvious. Most striking was the focal expression of RCK103 in the luminal cell compartment, with 34 β E12 showing positivity in 2 cases. In the fetuses of 17 and 27 weeks of gestation, ductal structures were not observed in the slides.

Keratin Immunophenotyping in Adult Prostate

Keratin expression in the adult prostate was the same as previously described in frozen sections [17]. Basal cells intensely expressed 34 β E12 and RCK103, while CK18 was not expressed (Fig. 2d,f,h). Luminal cells only expressed CK18. However, 3 cases showed sporadic RCK103 positivity, and one case showed scanty expression of 34 β E12. RCK102 was positive in almost all epithelial cells in the adult prostate (Fig. 2b).

DISCUSSION

Luminal and basal cell types encountered in the adult prostatic epithelium are two distinctly different cellular populations with regard to structure and function [24,25]. Early reports suggested that they originate independently [6,26,27]. More recent studies, however, provide evidence for the existence of a pluripotent progenitor cell type for luminal cells [28]. Ultrastructural studies on human, rat, and dog prostatic tissue suggest that basal cells are actively engaged in growth. They are not highly specialized in a structural sense but resemble undifferentiated secretory epithelial cells [12,13,24]. In the developing prostate, how-

ever, the typical morphologic basal-cell and luminal-cell features could not be readily identified.

Early studies on prostate development were based mainly on light and electron microscopic results. They showed that the prostatic buds appear at about week 12 of amenorrhea. The buds are formed from the mucosa of the urogenital sinus, which protrudes through the basement membrane to colonize the surrounding mesenchyme. Initially they are solid budding tips composed of monotonous cells with basaloid appearance. Ultrastructural studies show that at 13 weeks of gestation, luminal cells with dense secretion granules and nuclear polarization may be identified in the acinar lumen. The other cells present in these acini are less well-differentiated and have been hypothesized to represent the equivalents of basal cells in the adult prostate [29-31].

Antibodies to cytoskeletal proteins of the keratin subclasses have been used as a relatively new tool to study embryonic development, particularly with regard to differentiation [7,26, and references therein]. These studies show that changes in levels of differentiation are accompanied by distinct transitions in expression of individual keratins. In the present report we investigated whether application of a small panel of keratin antibodies could give a more profound insight into prostatic differentiation. And as such, this is an extensive report describing keratin expression in the fetal prostate. Due to the absence of keratin antibodies specific for intermediate cells, they are identified by their coexpression of antibodies RCK103 and CK18, and actually this MAb RCK103 is mainly found in the basal cell compartment. In a previous study we found that epithelial cells in the adult prostate could be characterized into basal cells (K14⁺/K5⁺/K18⁻), luminal cells (K14⁻/K5⁻/K18⁺), and intermediate cells (K14⁻/K5⁺/K18⁺). We have suggested that these cells could well be the missing link between basal and luminal cell types during differentiation, and that they could play a role in neoplastic transformation in the adult prostate [17]. An interesting question is whether this cell type is present in the developing prostate, and if so when may it first be identified?

At 17 weeks of gestation, we observed variable differentiation-specific keratins in the immature prostate. Basally-located cells were positive for both 34 β E12 and RCK103, but negative for CK18. Therefore, their keratin phenotype was K14⁺/K5⁺/K18⁻. This pattern is the same as that of spindle-shaped basal cells in adult prostates [17,18]. Most probably these basally-located cells are the same as adult prostate basal cells, which have proliferative potential [12,32].

The lumenally-located cells were partially positive for 34 β E12 and RCK103, and practically all contained K18. Therefore, their keratin phenotype is

K14⁺/K5⁺/K18⁺. These cells have a keratin phenotype different from that of their adult counterparts (K14⁻/K5⁻/K18⁺). This could be explained by contending that even though they are luminally located they are still not fully differentiated luminal cells, and that they still have basal-cell and intermediate-cell characteristics in terms of their keratin phenotype despite their luminal location, meaning that the morphologic transition of these cells, from basaloid to luminal, is preceded by a transition in keratin-phenotype. In some adult prostatic tissues we also noticed that sporadic cells in the luminal compartment had the basal-cell keratin-phenotype. This is consistent with previous reports and is probably associated with focal basal-cell hyperplasia [18,33]. Furthermore, comparing the intermediate cell type between the human adult prostate and the developing prostate, previous studies never found that intermediate cells express basal-cell keratin 34βE12 in the adult.

The intermediately-located cells displayed a heterogeneous keratin phenotype coexpressing both keratins found in basal and luminal cells (K14⁺/K5⁺/K18⁺). Furthermore, there are cells expressing basal keratins only and a number of cells expressing luminal-cell keratins only. It is possible that this intermingled pattern indicates the underlying gradual switch from basal cells with K14 and K5 phenotype to luminal cells with K18. This would strongly favor the role of these cells as intermediate cells that stemmed from basal cells and that will eventually differentiate into luminal cells. The simultaneous expression of both K_{basal} (K5 + 14) and K_{luminal} (K18) is substantial evidence that these intermediately located cells are truly in an intermediate state of differentiation. In Table II, we summarize the keratin differential expression patterns in comparison with previous results. The identification of the intermediate cell type in the fetal prostate reveals that the hierarchical expanding pathway from basal to luminal cells may be demonstrated in the most early stages of development. The fact that these cells are present in the fetus may indicate that they have a regulatory function in prostate development. Since the same intermediate cell type can be identified in the adult, this potential to transform probably remains throughout life. Pathologic stimulation, e.g., aging hormonal alteration, or disturbance in homeostasis (stromal-epithelial interactions), may reactivate this process, inducing profound changes resulting in abnormal accumulation of specific cell types. For instance, castration induces basal-cell hyperplasia, while luminal cells are either lost entirely or decrease in number [16], indicative of an androgen-independent proliferative function [25,34]. The abnormal accumulation of these specific cell types in the adult may be contributory in the development of BPH or even PCA [35].

We conclude that in the fetal prostate, morphologic cell differentiation is preceded by differential keratin expression. In early stages of prostate development, cells with an intermediate keratin phenotype may be identified. The large numbers of these cells may reflect their position as a link between basal and luminal cells in a differentiation pathway.

ACKNOWLEDGMENTS

The authors thank Dr. E. Ruijter and Dr. E. Schaafsma for assistance in acquiring fetal prostate tissues, and Dr. E. Ruijter for critical comments in the preparation of this manuscript.

REFERENCES

1. Barry M: Epidemiology and natural history of BPH. In Cockett A, Khoury S, Aso Y, Chatelain C, Denis L, Griffiths K, Murphy G (eds): Proceedings: "The Third International Consultation on Benign Prostatic Hyperplasia (BPH)." Paris: Scientific Communication International, 1995:19-50.
2. McNeal JE: Origin and evolution of benign prostatic enlargement. *Invest Urol* 1978;15:340-345.
3. Freeman MR, Chung LWK: Stromal-epithelial interactions: Molecular aspects and relevance to benign prostatic hyperplasia. In Kirby R, McConnell J, Fitzpatrick J, Roehrborn C, Boyle P (eds): "Textbook of Benign Prostatic Hyperplasia." Oxford: ISIS, 1996: 57-84.
4. Cunha GR: Role of mesenchymal-epithelial interactions in normal and abnormal development of the mammary gland and prostate. *Cancer* 1994;74:1030-1044.
5. Griffiths K, Coffey D, Cockett A, Di Sant'Agnes A, Ichikawa T, Krieg M, Lee C, McKeehan W, Schalken J, Sciarra F, Steiner G, Sugimura Y, Yamanaka H: The regulation of prostatic growth. In Cockett ATK, Khoury S, Aso Y, Chatelain C, Denis L, Griffiths K, Murphy G (eds): "Proceedings: The Third International Consultation on Benign Prostatic Hyperplasia (BPH)." Paris: Scientific Communication International, 1995:73-121.
6. Moll R, Franke WW, Schiller DL, Geiger B, Krepler R: The catalog of human cytokeratins: Patterns of expression in normal epithelia, tumors and cultured cells. *Cell* 1982;31:11-24.
7. Ramaekers FCS, Smedts F, Vooijs PG: Keratins as differentiation markers in tumor biology and surgical pathology. In Spandidos D (ed): "Current Perspectives on Molecular and Cellular Oncology," Vol 1. London: JAI Press Ltd., 1992:285-318.
8. Nagle RB: A review of intermediate filament biology and their use in pathologic diagnosis. *Mol Biol Rep* 1994;19:3-21.
9. Sherwood ER, Theyer G, Steiner G, Berg LA, Kozlowski JM, Lee C: Differential expression of specific cytokeratin polypeptides in the basal and luminal epithelia of the human prostate. *Prostate* 1991;18:303-314.
10. Purkis PE, Steel JB, Mackenzie IC, Nathrath WB, Leigh IM, Lane EB: Antibody markers of basal cells in complex epithelia. *J Cell Sci* 1990;97:39-50.
11. Brawer MK, Peehl DM, Stamey TA, Bostwick DG: Keratin immunoreactivity in the benign and neoplastic human prostate. *Cancer Res* 1985;45:3663-3667.
12. Mao P, Angrist A: The fine structure of the basal cell of human prostate. *Lab Invest* 1966;15:1768-1782.
13. Timms BG, Chandler JA, Sinowatz F: The ultrastructure of basal cells of rat and dog prostate. *Cell Tissue Res* 1976;173:543-554.
14. Prins GS, Birch L: The developmental pattern of androgen re-

- ceptor expression in rat prostate lobes is altered after neonatal exposure to estrogen. *Endocrinology* 1995;136:1303–1314.
15. Bonkhoff H, Stein U, Remberger K: Multidirectional differentiation in the normal, hyperplastic, and neoplastic human prostate: Simultaneous demonstration of cell-specific epithelial markers. *Hum Pathol* 1994;25:42–46.
 16. Verhagen AP, Aalders TW, Ramaekers FC, Debruyne FM, Schalken JA: Differential expression of keratins in the basal and luminal compartments of rat prostatic epithelium during degeneration and regeneration. *Prostate* 1988;13:25–38.
 17. Verhagen AP, Ramaekers FC, Aalders TW, Schaafsma HE, Debruyne FM, Schalken JA: Colocalization of basal and luminal cell-type cytokeratins in human prostate cancer. *Cancer Res* 1992;52:6182–6187.
 18. Xue Y, Smedts F, Umbas R, Aalders TW, Debruyne FMJ, de la Rosette JJMCH, Schalken JA: Changes in keratin expression during the development of benign prostatic hyperplasia (BPH). *Eur Urol* 1997;32:332–338.
 19. Isaacs JT, Coffey DS: Etiology and disease process of benign prostatic hyperplasia. *Prostate* 1989;Supp 2:33–50.
 20. Ramaekers F, Huysmans A, Schaart G, Moesker O, Vooijs P: Tissue distribution of keratin 7 as monitored by a monoclonal antibody. *Exp Cell Res* 1987;170:235–249.
 21. van de Voorde W, Baldewijns M, Lauweryns J: Florid basal cell hyperplasia of the prostate. *Histopathology* 1994;24:341–348.
 22. Okada H, Tsubura A, Okamura A, Senzaki H, Naka Y, Komatz Y, Morii S: Keratin profiles in normal/hyperplastic prostates and prostate carcinoma. *Virchows Arch A Pathol Anat Histo-pathol* 1992;421:157–161.
 23. Kwaspen F, Smedts F, Blom J, Pronk A, Kok MJ, van Dijk M, Ramaekers F: Periodic acid as a nonenzymatic enhancement technique for detection of cytokeratin immunoreactivity in routinely processed carcinomas. *Appl Immunohistochem* 1993;1: 143–148.
 24. Ichihara I, Pelliniemi LJ: Ultrastructure of the basal cell and the acinar capsule of rat ventral prostate. *Anat Anz* 1975;138:355–364.
 25. Aumüller G: Morphologic and endocrine aspects of prostatic function. *Prostate* 1983;4:195–214.
 26. Wernert N, Seitz G, Achtstatter T: Immunohistochemical investigation of different cytokeratins and vimentin in the prostate from the fetal period up to adulthood and in prostate carcinoma. *Pathol Res Pract* 1987;182:617–626.
 27. Evans GS, Chandler JA: Cell proliferation studies in the rat prostate: II. The effects of castration and androgen-induced regeneration upon basal and secretory cell proliferation. *Prostate* 1987;11:339–351.
 28. Kinbara H, Cunha GR, Boutin E, Hayashi N, Kawamura J: Evidence of stem cells in the adult prostatic epithelium based upon responsiveness to mesenchymal inductors. *Prostate* 1996;29: 107–116.
 29. Aumüller G: Postnatal development of the prostate. *Bull Assoc Anat (Nancy)* 1991;75:39–42.
 30. Delmas V, Dauge MC: Embryology of the prostate. In Khoury S (ed): “Urology: Prostate Cancer.” Boissy le cutté: FIIS, 1990:65–69.
 31. Kellokumpu Lehtinen P, Santii R, Pelliniemi LJ: Correlation of early cytodifferentiation of the human fetal prostate and Leydig cells. *Anat Rec* 1980;196:263–273.
 32. Bonkhoff H, Stein U, Remberger K: The proliferative function of basal cells in the normal and hyperplastic human prostate. *Prostate* 1994;24:114–118.
 33. Devaraj LT, Bostwick DG: Atypical basal cell hyperplasia of the prostate. Immunophenotypic profile and proposed classification of basal cell proliferations. *Am J Surg Pathol* 1993;17:645–659.
 34. English HF, Santen RJ, Isaacs JT: Response of glandular versus basal rat ventral prostatic epithelial cells to androgen withdrawal and replacement. *Prostate* 1987;11:229–242.
 35. Bonkhoff H, Remberger K: Differentiation pathways and histogenetic aspects of normal and abnormal prostatic growth: A stem cell model. *Prostate* 1996;28:98–106.