

University of Groningen

The use of xenografts to prevent inferior border defects following bilateral sagittal split osteotomies

van der Helm, H. C.; Kraeima, J.; Xi, T.; Jansma, J.; Schepers, R. H.

Published in:
International Journal of Oral and Maxillofacial Surgery

DOI:
[10.1016/j.ijom.2020.01.006](https://doi.org/10.1016/j.ijom.2020.01.006)

IMPORTANT NOTE: You are advised to consult the publisher's version (publisher's PDF) if you wish to cite from it. Please check the document version below.

Document Version
Publisher's PDF, also known as Version of record

Publication date:
2020

[Link to publication in University of Groningen/UMCG research database](#)

Citation for published version (APA):
van der Helm, H. C., Kraeima, J., Xi, T., Jansma, J., & Schepers, R. H. (2020). The use of xenografts to prevent inferior border defects following bilateral sagittal split osteotomies: three-dimensional skeletal analysis using cone beam computed tomography. *International Journal of Oral and Maxillofacial Surgery*, 49(8), 1029-1035. <https://doi.org/10.1016/j.ijom.2020.01.006>

Copyright

Other than for strictly personal use, it is not permitted to download or to forward/distribute the text or part of it without the consent of the author(s) and/or copyright holder(s), unless the work is under an open content license (like Creative Commons).

The publication may also be distributed here under the terms of Article 25fa of the Dutch Copyright Act, indicated by the "Taverne" license. More information can be found on the University of Groningen website: <https://www.rug.nl/library/open-access/self-archiving-pure/taverne-amendment>.

Take-down policy

If you believe that this document breaches copyright please contact us providing details, and we will remove access to the work immediately and investigate your claim.

Downloaded from the University of Groningen/UMCG research database (Pure): <http://www.rug.nl/research/portal>. For technical reasons the number of authors shown on this cover page is limited to 10 maximum.

Research Paper
Orthognathic Surgery

The use of xenografts to prevent inferior border defects following bilateral sagittal split osteotomies: three-dimensional skeletal analysis using cone beam computed tomography

H. C. van der Helm¹, J. Kraeima¹,
T. Xi², J. Jansma¹, R. H. Schepers¹

¹Department of Oral and Maxillofacial Surgery, University Medical Center Groningen and University of Groningen, Groningen, The Netherlands; ²Department of Oral and Maxillofacial Surgery, Radboud University Medical Center, Nijmegen, The Netherlands

H. C. van der Helm, J. Kraeima, T. Xi, J. Jansma, R. H. Schepers: *The use of xenografts to prevent inferior border defects following bilateral sagittal split osteotomies: three-dimensional skeletal analysis using cone beam computed tomography*. Int. J. Oral Maxillofac. Surg. 2020; 49: 1029–1035. © 2020 International Association of Oral and Maxillofacial Surgeons. Published by Elsevier Ltd. All rights reserved.

Abstract. The aim of this retrospective study was to investigate grafting in the osteotomy gap during bilateral sagittal split osteotomy (BSSO), using a xenograft and fibrin glue. Hard tissue defects in the inferior mandibular border were assessed using cone beam computed tomography scans taken 1 week and 1 year postoperatively. The study group of 20 patients underwent bone grafting during BSSO (mean age 26.1 years; mean horizontal displacement 8.5 mm) and the control group of 20 patients did not (mean age 30.2 years; mean horizontal displacement 7.6 mm). The mean height of the mandibular defects was significantly lower in the study group, but there was no significant difference in volume measurements between the groups. Grafting had a negligible effect on large displacements (9.0–15.0 mm), which might have been due to an inadequate amount and/or positioning of the graft, or to poor dimensional stability. This may be resolved by improved graft positioning or by using a different kind of (xeno)graft.

Key words: orthognathic surgery; orthognathic surgical procedures; bilateral sagittal split osteotomy; mandibular inferior border; bone transplantation; three-dimensional imaging.

Accepted for publication 9 January 2020
Available online 24 January 2020

The bilateral sagittal split osteotomy (BSSO) is a surgical procedure of the mandible that is performed to correct dentofacial skeletal abnormalities. The mandible can be

repositioned by displacing the osteotomy segments. Occasionally, large gap formation occurs during bone healing, which can result in an inferior mandibular border defect.

These defects can contribute to various complications, such as malunion and non-union of the osteotomy segments, relapse, and ingrowth of soft tissue^{1,2}. They can also

lead to disappointing aesthetic results or palpable depressions, and thereby to patient complaints. These can be corrected secondarily using a bone graft or an allogeneic implant, but this can cause patient discomfort and iatrogenic damage³. Incidences of mandibular defects, ranging from 7% to 35.5% per operation site, have been described in the literature^{3,4}. The splitting technique, patient age, and amount of rotation, as well as the magnitude of the horizontal displacement, are considered to be risk factors for defect formation^{3,4}. Therefore, Agbaje et al.⁴ suggested that bone grafting is a better option for displacements larger than 10 mm and/or for patients over 30 years of age. The position of the mandibular condyle should be preserved because defects are more likely to occur with severe upward rotation of the proximal segment¹.

Bone grafts can be used to improve bone regeneration at the inferior mandibular border. They create a scaffold that enhances bone healing and reduces soft tissue herniation into the osteotomy defect. Xenografts and allografts have osteoconductive properties and thus no additional surgical procedure is required². Autografts also have osteoinductive properties, but they tend to show less predictable resorption and the amount of bone that can be harvested locally is limited^{5,6}.

The purpose of this retrospective study was to examine the preventative effect of Bio-Oss xenografts (BO) (Geistlich Pharma, Wolhusen, Switzerland), in combination with Tissucol fibrin glue (TC) (Baxter, Deerfield, IL, USA), on hard tissue inferior mandibular border defects in patients undergoing a BSSO. The study group, which received BO and TC, was compared to a control group without any grafting. The hard tissue defects were investigated on cone beam computed tomography (CBCT) scans. The specific aim of this study was to investigate the effect of BO and TC on the hard tissue inferior mandibular border defects by comparing the heights and volumes of the defects. The influence of the amount of horizontal displacement of the osteotomy segments was also investigated. The hypothesis was that the application of BO and TC during a BSSO procedure would improve skeletal volume and that it would be more beneficial for larger horizontal displacements.

Materials and methods

Research design and study sample

The data of patients who underwent a BSSO according to the Hunsuck modification⁷

(occasionally combined with a Le Fort I osteotomy and/or genioplasty) were examined in this retrospective observational cohort study. A total of 80 sagittal splits in 40 patients treated between January 2013 and February 2017 were included. The study group consisted of 14 men and 6 women (mean age 26.1 years; standard deviation (SD) 9.9 years) who had been treated with BO and TC at the University Medical Center Groningen, the Netherlands. Eighteen of the study patients were treated for a class II malocclusion and two for a class III malocclusion, with distinct gap formation between the osteotomy segments. The control group, without any grafting, consisted of 7 men and 13 women (mean age 30.2 years; SD 12.3 years) treated at the Radboud University Medical Center, the Netherlands. All 20 of the control patients were treated for a class II malocclusion. Patients were excluded if one of the required CBCT scans was not available (the first from within 1 month after surgery (T1) and the second from 10–14 months after the first CBCT scan (T2)), and if the mandibular border could not be examined closely (e.g., due to a bad quality CBCT scan or scattering of the low placed miniplates). Once selected, the patients in both groups were divided into subgroups based on the amount of horizontal displacement: group I, 0.0–6.9 mm; group II, 7.0–8.9 mm; group III, 9.0–15.0 mm.

Surgical protocol

The BSSO procedure was executed according to the Hunsuck modification by a maxillofacial surgeon, frequently assisted

by a resident. Both sides of the mandible were permanently fixated with miniplates (study group: 2.0-mm, KLS Martin, Tuttlingen, Germany; control group: Champy 2.0-mm plates, same manufacturer) and care was taken to avoid upward rotation of the proximal segments.

For the study group patients, BO xenograft (granules of 0.25–1 mm) was mixed evenly with the TC fibrin glue using a spatula and subsequently formed manually into two well-mixed blocks (Fig. 1). The volume of BO and TC required to fill the cortical defect in the inferior border of the mandible was evaluated preoperatively, but the volume used was preferably more than the estimated gap size (Fig. 2). Although the quantity depended on the size of the gap, the maximum for each side was 0.25 ml BO and 0.5 ml TC. Each BO and TC block was carefully placed into the osteotomy gap in the inferior mandibular border using a spatula, with the aim of filling this gap and restoring the contour. The mixture does not adhere well to the bone surfaces in the osteotomy gap and therefore a tight fit is important to keep the mixture in place. The mandibular inferior border was then palpated through the skin to check for any irregularity. If there was, the BO and TC block was modified and checked again by extraoral palpation.

The transoral placement of graft material in the inferior border is done with limited direct vision. Verifying correct placement is therefore difficult, but this is important because, if the placement and the osteotomy planes are incorrect, the osteoconductive properties of the xenograft will be affected.

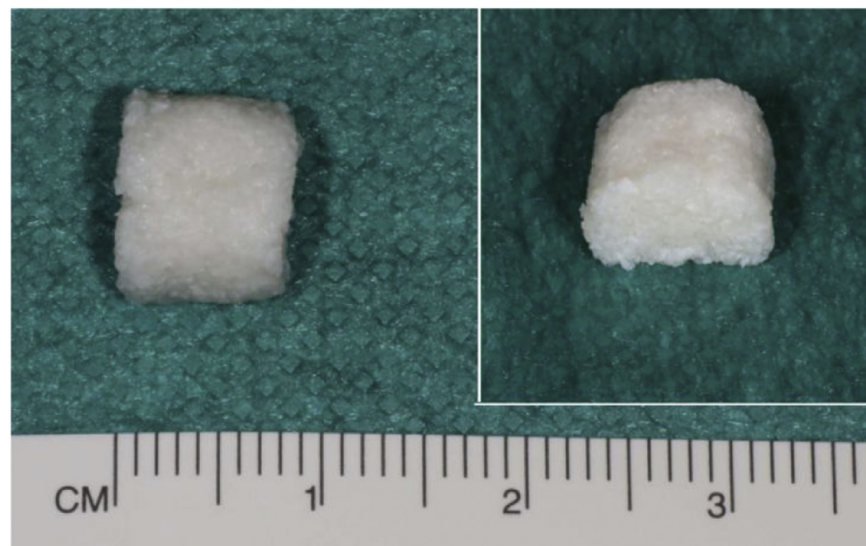


Fig. 1. Mixed xenograft (Bio-Oss) and fibrin glue (Tissucol) block.

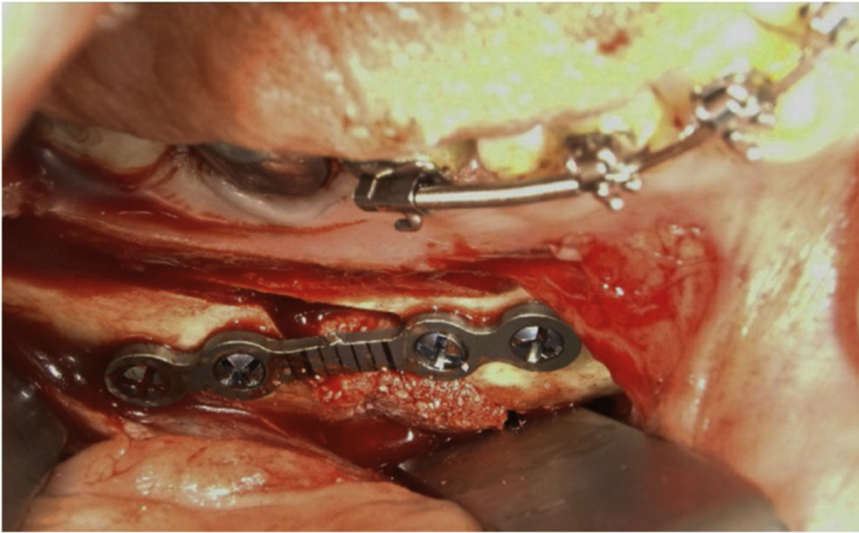


Fig. 2. Intraoperative photo of the applied xenograft–fibrin glue block (Bio-Oss and Tissucol) and the inferior mandibular border.

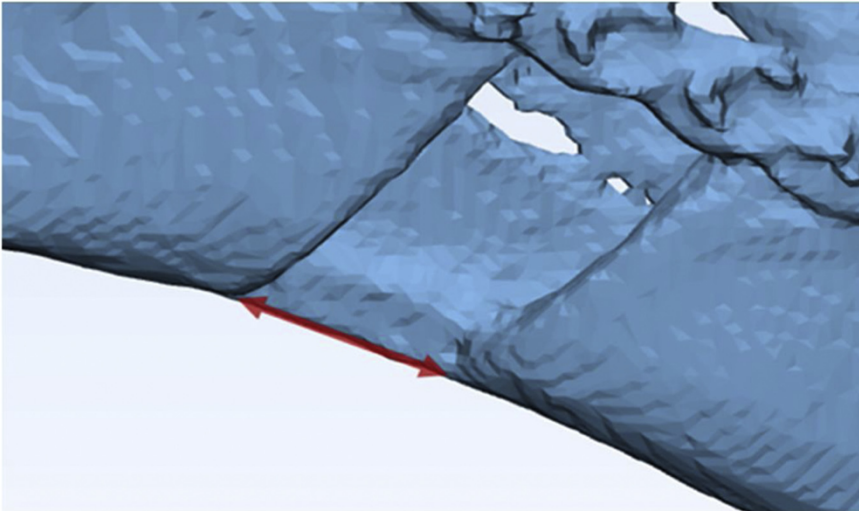


Fig. 3. Horizontal displacement measured between the inferior mandibular borders of the proximal and distal segments.

In all cases, wound closure was performed with a standard running resorbable suture.

Radiographic and three-dimensional analyses

Postoperative CBCT scans were obtained at T1 and T2 as part of the routine follow-up. A Planmeca Pro-Max CBCT system (Planmeca Oy, Helsinki, Finland) was used for the study group patients, with settings of 120 kVp voltage, 5 mA dose, and 5.8 s exposure time. An i-CAT CBCT scanner (Imaging Sciences International, Hatfield, PA, USA) was used for the control group

patients, with settings of 120 kVp voltage, 3–8 mA dose, and 2×20 s exposure time. The same head positioning protocol was applied for all CBCT scans at T1 and T2, giving reproducible data.

The raw image files were segmented using ProPlan CMF v. 3.0 software (Materialise, Leuven, Belgium). The horizontal displacement between the osteotomy segments at the inferior mandibular border was measured for both groups on each three-dimensional (3D) model (Fig. 3). The 3D models from T1 and T2 were then superimposed using a closest point algorithm in Geomagic studio software (3D Systems, Morrisville,

NC, USA). The T2 superimposed models were imported into 3-Matic v. 11.0 (Materialise, Leuven, Belgium) to measure the height of the defect and the volume percentage between the osteotomy segments.

The height of the defect was measured by first drawing a line that crossed the defect at the inferior border (Fig. 4). A second line was then drawn down from the highest indentation point of the osteotomy gap, perpendicular to the first line that crossed the defect; this line was used to measure the height of the defect in millimetres.

The volume percentage of the defect (i.e., volume of the defect) was obtained by measuring the volume of the osteotomy gap at T2 and comparing this with an individualized cubic volume, representing the optimal contour volume (Fig. 5). The volume at T2 was created by measuring the volume of the mandible between the osteotomy lines with an even height of 5 mm from the line that crosses the defect at the inferior border.

The optimal contour volume had the same borders as the volume at T2, but the width was measured from a line between the mesial and distal top width of the volume at T2.

Both volumes were calculated before dividing the volume at T2 by the optimal contour volume to obtain a percentage, which represents the degree of bone regeneration.

In addition, two maxillofacial surgeons (JJ, RS) scored the hard tissue 3D models of both groups by visual evaluation as either a noticeable defect (i.e., distinct contour change in the continuity of the inferior border) or no defect. All of the measurement process steps were executed by one researcher (HH) and were calibrated by the two surgeons (JJ, RS).

Statistical analysis

All border defects were analysed individually because of the large discrepancy between the right and left mandibular borders within the same patient. Differences in characteristics between the two groups in terms of age, horizontal displacement, and period of follow-up were compared using the Mann–Whitney test. Differences in sex distribution between the groups were compared using the χ^2 test.

An independent samples *t*-test was used to compare the height and volume of the defect. The hard tissue models that were scored by the two surgeons were compared with χ^2 tests ($P < 0.05$). The results were processed using IBM SPSS

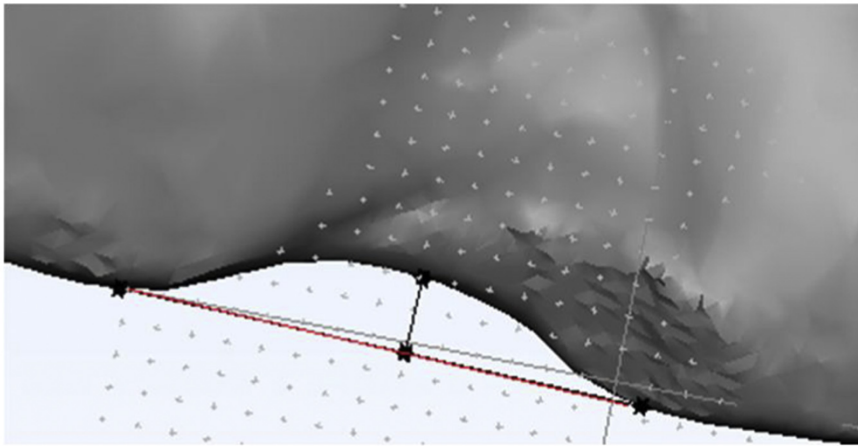


Fig. 4. Measuring the height of the defect at T2. The red line illustrates a reproducible line that crosses the defect; the perpendicular black line shows the height of the defect (For interpretation of the references to colour in this figure legend, the reader is referred to the web version of this article).

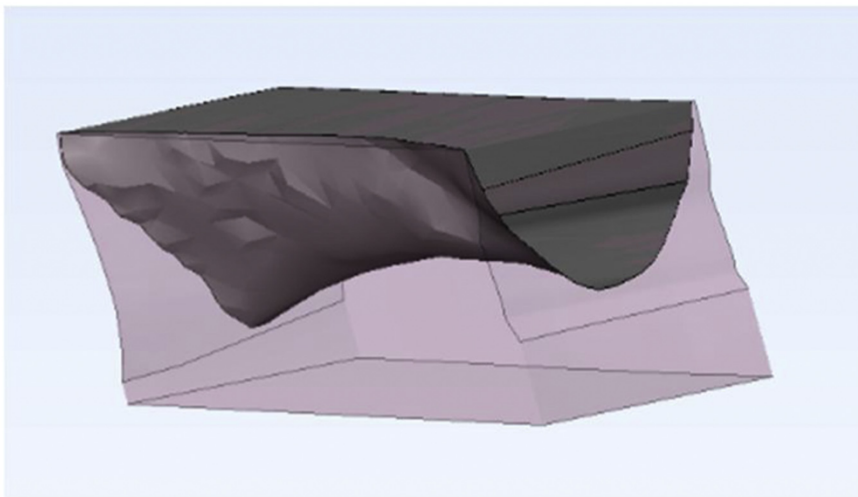


Fig. 5. Cut-out volume. The grey shaded area represents the volume of the osteotomy gap and the pink shaded area represents the optimal contour volume (For interpretation of the references to colour in this figure legend, the reader is referred to the web version of this article).

Statistics version 25.0 (IBM Corp., Armonk, NY, USA).

The effect of the intervention on defect heights and volumes according to the level of horizontal displacement was assessed in the six subgroups using Cohen's *d* effect size. This was done because an effect size calculation, which indicates the effect of

the intervention, is possible with small groups.

Results

The characteristics of the patients in both groups are shown in Tables 1 and 2, and the comparison of measurements in Table

3. The mean height of the defect at T2 was 0.75 mm (SD 1.12 mm) in the study group and 1.38 mm (SD 1.33 mm) in the control group. The mean height of the study group defects was significantly lower than that of the control group defects ($P = 0.024$). There was no significant difference in the volumes of the defects ($P = 0.139$). Regarding the scoring of the hard tissue models, the study group had significantly fewer defects at the mandibular border ($P < 0.001$).

The height and volume parameters of the study and control groups were compared with Cohen's *d* effect size (Table 4). The heights of the defects in group I (0.0–6.9 mm horizontal displacement) showed a small to moderate effect (0.43) and the volumes of the defects showed a small effect (0.32), when compared to the control group. The group II (7.0–8.9 mm horizontal displacement) parameters showed a large effect (height of defect: 1.29; volume of defect: 0.90). Conversely, the group III (9.0–15.0 mm horizontal displacement) parameters demonstrated a negligible effect (height of defect: 0.16; volume of defect: -0.15).

Discussion

The aim of this study was to investigate the effect of BO and TC on mandibular border defects after a BSSO. The results of the study group are positive in terms of lower defect heights ($P = 0.024$) and fewer noticeable inferior defects (compared with the χ -test) ($P = 0.000$), but no significant difference in the volume of the defects was found in comparison to the controls (Table 1).

Studies on bone augmentation at the mandibular border have shown positive results in bone regeneration^{1,2,8}. The results for the patients in the present study group confirm these positive findings regarding the heights of the defects and the numbers of noticeable defects as evaluated by inspection of the hard tissue models, but not regarding the volumes of the defects. Lee et al.¹ studied the use of an allogeneic demineralized bone matrix during BSSO and found a significant increase

Table 1. Patient characteristics: study and control groups.

	Study group (n = 20)	Control group (n = 20)	25 th percentile	Median	75 th percentile	P-value
Male	14	7				0.003
Female	6	13				
Mean age (years) ± SD	26.1 ± 9.9	30.2 ± 12.3	19.0	23.0	36.3	0.142
Mean horizontal displacement (mm) ± SD	8.5 ± 2.8	7.6 ± 2.2	6.1	7.9	9.6	0.348
Mean follow-up (months) ± SD	12.0 ± 0.7	12.1 ± 0.7	11.5	11.8	12.4	0.615

SD, standard deviation.

Table 2. Study group (group 1) and control group (group 2) characteristics and measurements.

Group	Patient number	Sex	Age (years)	Follow-up (months)	Right			Left			
					Displacement (mm)	Height of defect (mm)	Volume of defect (%)	Scored hard tissue defect ^a	Displacement (mm)	Height of defect (mm)	Volume of defect (%)
1	1	M	20	11.7	11.2	0	41.7	7.5	1.71	34.2	+
1	2	M	22	11.5	13.4	1.49	22.9	14.7	0.53	29	+
1	3	M	21	12.4	6.6	0.94	34.1	8.4	0.66	33.2	+
1	4	F	19	12.7	8.8	0.54	49.6	6.8	0.27	32.2	+
1	5	F	31	10.8	14.4	2.84	12.1	13	4.7	11.8	-
1	6	F	18	11.7	7.7	0.88	25.5	7.5	0	63.3	+
1	7	F	34	11.6	9.3	4.95	2.2	9.6	0.86	28.6	-
1	8	M	25	13.4	12.9	1.89	36.8	12.8	0.56	34.1	+
1	9	M	44	11.7	5.1	0	66.9	6.6	0	55.7	+
1	10	M	21	13.1	9.9	0.12	49.2	7.5	0	74.1	+
1	11	M	28	11.3	8.9	0.43	34.5	4.2	0.77	55.5	+
1	12	M	44	11.5	6	0.36	41.2	5.9	0.8	44.1	+
1	13	F	19	11.3	6.4	0.44	43.2	4.1	0.22	52.1	+
1	14	F	29	13.4	7.9	0.41	29.7	7.3	0.22	42.5	+
1	15	M	16	12.4	7	0.25	56.4	4.3	0.41	63.1	+
1	16	M	22	11.7	9.8	0	52	9.6	0.36	62.6	+
1	17	M	19	11.7	7.5	0	58.9	5	0.71	45.7	+
1	18	M	51	11.7	5.9	0.6	32.4	8.4	0.72	41.1	-
1	19	M	19	12.2	12	0	27	10.3	0	57.3	+
1	20	M	19	12.2	7.7	0.37	42.3	6	0	58.8	+
2	1	M	19	12.2	10.5	0	59.1	10.7	0	46	-
2	2	F	47	11.3	9.6	4.53	33.7	9.5	1.97	27.5	-
2	3	F	37	12.7	8.5	3.07	25	7.9	1.92	23.1	-
2	4	F	22	13.4	8.9	1.35	35	7.8	2.28	32	-
2	5	M	17	13.6	8.4	1.38	29	6.5	0.36	36.1	+
2	6	F	20	12	9.2	0.63	38.7	7.5	0	59.7	+
2	7	M	15	11	5	0	64.1	5	0	59.1	+
2	8	F	24	11.4	2.5	0	65.2	9.7	1.88	15.8	-
2	9	M	44	11.3	6.5	0.78	36.5	5.5	1.89	31.7	+
2	10	F	28	11.8	7.3	2.34	21.4	6.2	0	25.3	+
2	11	F	18	11.9	5.9	0	60.8	5.5	0	42.7	+
2	12	F	20	12	7.3	0.54	49.9	8.2	0.58	53.2	+
2	13	M	51	11.7	3	0.37	55.8	4.5	0.94	45.1	-
2	14	M	21	11.6	5.8	1.62	36.6	5.1	1.82	17.8	-
2	15	F	37	12	12.6	0.88	32.7	11.4	1.56	39.4	-
2	16	F	29	11.8	8.7	0.99	46.9	8.6	0.48	30.3	-
2	17	F	29	12.1	9.8	1.23	32.7	7.9	1.45	31.2	-
2	18	F	49	12.6	8.3	2.46	18	8.6	3.49	4.7	-
2	19	M	52	11.5	8.9	6.09	2.3	4.8	1.72	35.8	-
2	20	F	24	13.3	7	1.9	38	9.4	2.78	30.4	-

F, female; M, male; +, is the presence of an inferior border defect; -, is the absence.

^a Hard tissue defects.

Table 3. Comparison of measurements between the study group and control group.

	Study group (n = 20)	Control group (n = 20)	P-value
Mean height of defect (mm) ± SD	0.75 ± 1.12	1.38 ± 1.33	0.024
Mean volume of defect (%), ± SD	41.9 ± 16.0	30.2 ± 12.3	0.139
Scored hard tissue defects (borders)	4.5	13	0.000

SD, standard deviation.

Table 4. Study and control subgroup defect heights and volumes: Cohen's *d* effect sizes^a.

	Height of defect	Volume of defect
Study and control group I	0.43	0.32
Study and control group II	1.29	0.90
Study and control group III	0.16	-0.15
Study and control group total	0.51	0.34

Note: Difference in horizontal displacement: group I, 0.0–6.9 mm; group II, 7.0–8.9 mm; group III, 9.0–15.0 mm (Fig. 3).

^a Cohen's *d* indicates the effect of the intervention. Index interpretation: <0.2 = negligible effect; 0.2–0.5 = small effect; 0.5–0.8 = moderate effect; >0.8 = large effect.

in volume compared to no bone grafting. However, the area measured was more extensive than the volume between the osteotomy segments. Therefore, the change in volume could have been influenced by the results of bone regeneration over the entire osteotomy plane.

There was no significant difference between the study and control groups in terms of age, magnitude of the horizontal displacement, and follow-up period. However, there was a significant difference in sex distribution ($P = 0.003$). Patient age and the amount of horizontal displacement have been described as risk factors for mandibular border defects, but not sex^{3,4}. Therefore, the group parameters are comparable.

The regenerative effect of BO and TC at the inferior mandibular border was expected to increase with larger horizontal displacement, when compared to the control group. However, large displacements (subgroup III, 9.0–15.0 mm) resulted in BO and TC having a negligible effect on the measured height

and volume of the defect. Trevisiol et al.² examined large displacements (mean displacement 11.36 mm) treated with the xenograft

Bio-Oss Collagen (Geistlich Pharma, Wolhusen, Switzerland), and no defect formation was found in all 20 patients included. This difference with our results could be attributed to their use of more grafting material or to the better adherence of the xenograft to the bony recipient site. That study used 0.5–1.5 ml Bio-Oss Collagen compared to 0.25 ml of BO with 0.5 ml of TC fibrin glue applied in our study.

To gain more insight into the finding of a negligible effect of BO and TC in the large displacements, all cases in study subgroup III were examined individually post hoc. The 3D models showed that 11/14 mandibular borders had irregular shaped BO and TC volumes, which already had large defects between the bone graft and bone at T1 (Fig. 6A). If there is no intimate contact between the graft and the native bone surface,

there will be no osteoconduction and therefore no bone regeneration. In this study subgroup, 7/14 mandibular borders were scored to have an inferior border defect at T2, compared to 10/10 in the control subgroup III. However, comparison of the height and volume measurements resulted in a negligible effect of BO and TC between the two groups, which might be attributed to the relatively large outliers in the study group, influencing the Cohen's *d* analysis.

Thus, the reduced effect of BO and TC on the large displacements and/or the volume measurements might have been a logical consequence of applying too little BO and TC or there being insufficient contact or fixation between the osteotomy segments. Therefore, careful application of the BO and TC block so that it comes into close contact with the proximal and distal segments might enhance the results (Fig. 6B). Alternatively, Bio-Oss Collagen or blocks of other types of (xeno)graft material with better dimensional stability and/or osteoinductive capabilities might give better results in these large defects. The use of autografts seems less appropriate because of the unpredictable resorption pattern and the limited amount of bone that can be harvested locally, although the osteoinductive capabilities might enhance bone regeneration. The study subgroup III cases were not excluded from this study because the treatment is technique-sensitive and this would otherwise have led to bias regarding the clinical effect of BO and TC.

In this study, a homologous fibrin glue (TC) was used to adhere the BO xenograft. The choice of BO was based on experience in alveolar ridge augmentation and to avoid an extra donor site. Homologous fibrin glues are known to reduce bone regeneration, whereas autologous platelet-rich fibrin glues significantly enhance bone regeneration^{9,10}. However, applying TC enables a sustainable shape with BO, which is not possible with autologous platelet-rich




Fig. 6. (A) Incorrect alignment of the xenograft–fibrin glue block (Bio-Oss and Tissucol) between the osteotomy segments at T1. (B) Correctly applied xenograft–fibrin glue block between osteotomy segments at T1.

fibrin or BO alone. The TC is expected to resorb within 2 weeks, which for large displacements could be too short for sufficient support for bone regeneration¹¹.

Different splitting techniques have been described that decrease inferior mandibular border defect formation^{4,12}. A splitting technique that only includes the buccal plate is preferred. A split that also includes the lingual plate increases the chance of defect formation⁴. Both splitting techniques were used in this study because, when the cranial cortex is opened, the inferior border splits to the side of the least resistance. Therefore, it is difficult to influence the splitting technique. Another reported technique involves gently splitting the mandibular border using a Piezosurgery device (OT7; Mectron, Carasco, Italy)¹²; this has shown better outcomes, with mandibular border defects prevented when compared to the traditional BSSO. However, a BSSO with bone grafting has been described to be superior to this Piezosurgery technique⁸.

Limitations of this study include the retrospective study design, whereby only a small sample size was available, and the use of different CBCT scanners and settings in the two clinics. The use of non-steroidal anti-inflammatory drugs (NSAIDs) and smoking have been described as risk factors for impaired bone healing^{13,14}. These potential confounders were poorly documented at both clinics and could not be taken into account; nevertheless, they probably had little effect on the outcomes of this study.

This preliminary study confirmed a positive effect of BO and TC on the hard tissues (i.e., a significantly lower defect height and score of the hard tissue), but not on volume measurements (no difference). The use of xenografts can lead to certain complications such as infections, transmission of diseases, or rejection of the graft⁵. One has to consider the effect of the treatment on the hard tissues and the overall effect on the overlying soft tissues. Severe upward rotation of the proximal segment could cause a soft tissue defect.

To determine whether it is worth the risk regarding complications and the extra costs of the material, long-term prospective randomized studies with larger sample sizes are needed. The effect of hard tissue defects on the soft tissue profile should be investigated thoroughly. The patients need to be matched and more information is required such as complete medical history, two- and three-dimensional light photography, and patient satisfaction.

In conclusion, the aim of this study was to examine the effect of BO and TC on the

mandibular border after a BSSO. In this preliminary study on the use of BO and TC, there was significantly better bone regeneration as determined by the comparison of defect heights and hard tissue scores. However, no significant difference in defect volume was found between the two groups. With large displacements (9.0–15.0 mm), the application of BO and TC had a negligible effect, which could be attributed to the inadequate amount, positioning, or adherence capabilities of the BO and TC mixture. We feel that the grafting of large advancements remains indicated, but that the concept of grafting might be improved by using xenograft materials in such a way that they have a better dimensional stability or by using a graft with osteoinductive capabilities.

Funding

None.

Competing interests

None.

Ethical approval

Not required.

Patient consent

Not required.

Acknowledgements. The authors thank J. Siemienski for proofreading the manuscript.

References

- Lee BS, Ohe JY, Kim BK. Differences in bone remodeling using demineralized bone matrix in bilateral sagittal split ramus osteotomy: a study on volumetric analysis using three-dimensional cone-beam computed tomography. *J Oral Maxillofac Surg* 2014;**72**:1151–7.
- Trevisiol L, Nocini PF, Albanese M, Sbarbari A, D'Agostino A. Grafting of large mandibular advancement with a collagen-coated bovine bone (Bio-Oss Collagen) in orthognathic surgery. *J Craniofac Surg* 2012;**23**:1343–8.
- Verweij JP, van Rijssel JG, Fiocco M, Mensink G, Gooris PJJ, van Merkesteyn JPR. Are there risk factors for osseous mandibular inferior border defects after bilateral sagittal split osteotomy? *J Craniofac Surg* 2017;**45**:192–7.
- Agbaje JO, Sun Y, Vrielinck L, Schepers S, Lambrechts I, Politis C. Risk factors for the development of lower border defects after bilateral sagittal split osteotomy. *J Oral Maxillofac Surg* 2013;**71**:588–96.
- Oryan A, Alidadi S, Moshiri A, Maffulli N. Bone regenerative medicine: classic options, novel strategies, and future directions. *J Orthop Surg Res* 2014;**9**:1–27.
- Nandi SK, Roy S, Mukherjee P, Kundu B, De DK, Basu D. Orthopaedic applications of bone graft and graft substitutes: a review. *Indian J Med Res* 2010;**132**:15–30.
- Hunsuck E. A modified intraoral sagittal splitting technic for correction of mandibular prognathism. *J Oral Surg* 1968;**26**:250–3.
- Cifuentes J, Yanine N, Jerez D, Barrera A, Agbaje JO, Politis C. Use of bone grafts or modified bilateral sagittal split osteotomy technique in large mandibular advancements reduces the risk of persisting mandibular inferior border defects. *J Oral Maxillofac Surg* 2018;**76**: 189.e1–189.e6.
- Carmagnola D, Berglundh T, Lindhe J. The effect of a fibrin glue on the integration of Bio-Oss with bone tissue. An experimental study in labrador dogs. *J Clin Periodontol* 2002;**29**:377–83.
- Xuan F, Lee CU, Son JS, Jeong SM, Choi BH. A comparative study of the regenerative effect of sinus bone grafting with platelet-rich fibrin-mixed Bio-Oss and commercial fibrin-mixed Bio-Oss: an experimental study. *J Craniomaxillofac Surg* 2014;**42**:e47–50.
- Tabélé C, Montana M, Curti C, Terme T, Rathelot P, Gensollen S, Vanelle P. Organic glues or fibrin glues from pooled plasma: efficacy, safety and potential as scaffold delivery systems. *J Pharm Pharm Sci* 2012;**15**:124–40.
- Agbaje JO, Gemels B, Salem AS, Anunden D, Vrielinck L, Politis C. Modified mandibular inferior border sagittal split osteotomy reduces postoperative risk for developing inferior border defects. *J Oral Maxillofac Surg* 2016;**74**: 1062.e1–9.
- Geusens P, Emans PJ, De Jong JJA, Van Den Bergh J. NSAIDs and fracture healing. *Curr Opin Rheumatol* 2013;**25**:524–31.
- Patel RA, Wilson RF, Patel PA, Palmer RM. The effect of smoking on bone healing: a systematic review. *Bone Joint Res* 2013;**2**:102–11.

Address:

Hayo C. van der Helm
Department of Oral and Maxillofacial Surgery
PO Box 30.001
9700RB
Groningen
The Netherlands
Tel.: +31 50 361 3844
Fax: +31 50 361 1136
E-mail: h.c.van.der.helm@umcg.nl