

University of Groningen

Primary umbilical endometriosis

Theunissen, Carla I. J. M.; Ijpma, Frank F. A.

Published in:
Journal of surgical case reports

DOI:
[10.1093/jscr/rjv025](https://doi.org/10.1093/jscr/rjv025)

IMPORTANT NOTE: You are advised to consult the publisher's version (publisher's PDF) if you wish to cite from it. Please check the document version below.

Document Version
Publisher's PDF, also known as Version of record

Publication date:
2015

[Link to publication in University of Groningen/UMCG research database](#)

Citation for published version (APA):

Theunissen, C. I. J. M., & Ijpma, F. F. A. (2015). Primary umbilical endometriosis: a cause of a painful umbilical nodule. *Journal of surgical case reports*, (3), 1-3. <https://doi.org/10.1093/jscr/rjv025>

Copyright

Other than for strictly personal use, it is not permitted to download or to forward/distribute the text or part of it without the consent of the author(s) and/or copyright holder(s), unless the work is under an open content license (like Creative Commons).

The publication may also be distributed here under the terms of Article 25fa of the Dutch Copyright Act, indicated by the "Taverne" license. More information can be found on the University of Groningen website: <https://www.rug.nl/library/open-access/self-archiving-pure/taverne-amendment>.

Take-down policy

If you believe that this document breaches copyright please contact us providing details, and we will remove access to the work immediately and investigate your claim.

Downloaded from the University of Groningen/UMCG research database (Pure): <http://www.rug.nl/research/portal>. For technical reasons the number of authors shown on this cover page is limited to 10 maximum.

CASE REPORT

Primary umbilical endometriosis: a cause of a painful umbilical nodule

Carla I.J.M. Theunissen* and Frank F.A. Ijpma

Department of Surgery, Isala Clinics, Zwolle, The Netherlands

*Correspondence address. Department of surgery, Isala Clinics, PO Box 10400, Zwolle 8000 GK, The Netherlands. Tel: +31-38-4245000; E-mail: c.i.j.m.theunissen@isala.nl

Abstract

A female patient presented with a painful swelling in the umbilicus. Ultrasonography demonstrated a hypodense nodule of 1.8 cm. Surgical exploration revealed a subcutaneous, dark discoloured, lobulated swelling at the bottom of the umbilicus, which turned out to be primary umbilical endometriosis (PUE). Primary umbilical endometriosis is a rare and benign disorder, caused by the presence of ectopic endometrial tissue in the umbilicus, which can present as a painful, discoloured swelling in the umbilicus. The clinical distinction between primary umbilical endometrioses and other causes of an umbilical nodule is difficult. Additional imaging modalities do not show any pathognomonic signs for establishing this diagnose. Surgical exploration and excision are a safe and definitive treatment of primary umbilical endometrioses. This case highlights the importance of including PUE in the differential diagnosis of women with a painful umbilical nodule.

INTRODUCTION

Endometriosis is a common benign disease, which is defined by the presence of endometrial tissue outside the uterus that most often affects the pelvic peritoneum [1, 2]. The presence of endometriosis in the umbilicus does rarely occur [3]. Primary umbilical endometriosis (PUE) is often not recognized based on its clinical appearance, and knowledge about the pathophysiology is scarce [2].

We report here a rare case of a painful, livid coloured nodule in the umbilicus, which turned out to be PUE. PUE should be a differential diagnostic consideration in patients with a painful swelling in the umbilicus as is outlined in this report.

CASE REPORT

A 47-year-old healthy female presented with a painful and livid coloured nodule in the umbilicus, which gradually evolved over the past 6 months. She had no symptoms of dysmenorrhoea or

cyclical umbilical pain. At physical examination, she had a soft, painful swelling with a diameter of 2 cm in the umbilicus, which was irreducible by gentle digital pressure (Fig. 1). Ultrasonography revealed a hypodense nodule of 1.8 cm at the umbilicus (Fig. 2). However, a definitive diagnosis could not be established thus far. Under the provisional clinical diagnosis, 'irreducible umbilical hernia with probably strangulated fatty tissue in the hernia sac' surgical exploration of the umbilicus was performed. Under general anaesthesia, a sub-umbilical incision was made. To our surprise, a subcutaneous, lobulated mass was exposed, which was fixated on the bottom of the umbilicus (Fig. 3). The abdominal wall itself was unaffected. The nodule was excised, and histopathological examination revealed connective tissue fragments with irregular tubular formations surrounded by stromal cells. Our patient was treated by excision of the swelling that turned out to be PUE. Two months after the surgery, she visited the outpatient clinic and reported complete recovery of the painful sensation and swelling in the umbilicus.

Received: December 15, 2014. Accepted: February 20, 2015

Published by Oxford University Press and JSCR Publishing Ltd. All rights reserved. © The Author 2015.

This is an Open Access article distributed under the terms of the Creative Commons Attribution Non-Commercial License (<http://creativecommons.org/licenses/by-nc/4.0/>), which permits non-commercial re-use, distribution, and reproduction in any medium, provided the original work is properly cited. For commercial re-use, please contact journals.permissions@oup.com

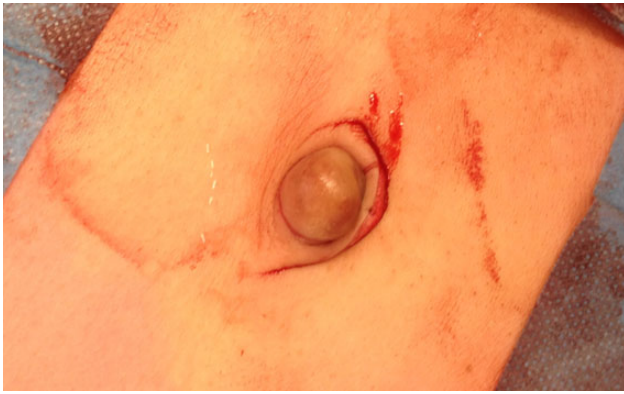

Figure 1: Clinical presentation of a livid, soft, painful swelling in the umbilicus, which could not be reduced by gentle digital pressure.

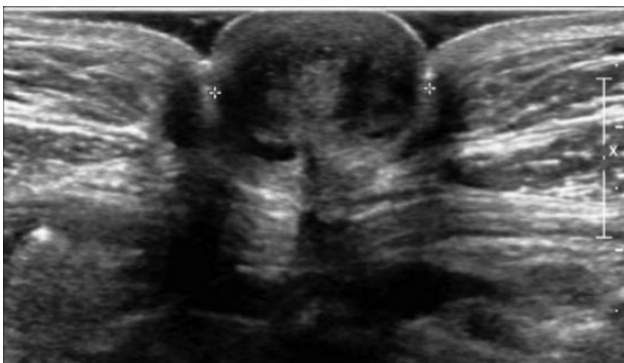

Figure 2: Ultrasonography of the umbilicus demonstrated a hypodense nodule of 1.8 cm in the umbilicus.

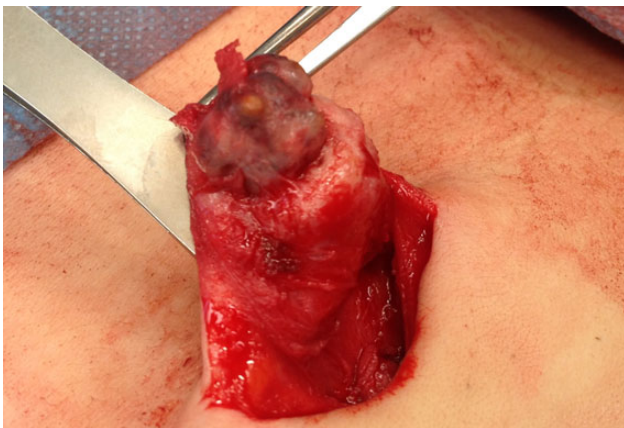


Figure 3: Intraoperative image of dark discoloured, lobulated swelling at the bottom of the umbilicus that turned out to be PUE.

DISCUSSION

Endometriosis is a benign disorder, which affects 6–10% of all women in the reproductive age [1]. The umbilicus could be an extraordinary site of endometriosis and is affected in 0.5–4% of the women with endometriosis. Umbilical endometriosis could have a ‘secondary’ nature, but this disorder can also be spontaneous or ‘primary’ [2]. In the English literature, only 37 cases of PUE have been described. The pathogenesis of PUE is not fully elucidated. Possible explanations for PUE could be the migration of

Table 1 Differential diagnosis of an umbilical nodule.

Benign	Malignant
Cutaneous endometriosis/endosalpingiosis ^a	Sister Mary Joseph node ^b
Haemangioma/vascular malformation	Melanoma
Umbilical hernia/cicatrical hernia	Sarcoma
Sebaceous cyst	Adenocarcinoma
Granuloma	Lymphoma
Lipoma	
Abscess	
Keloid	
Omphalomesenteric or urachus anomaly and/or infection	
Desmoid tumour	

^aEndosalpingiosis: the presence of fallopian tube-like epithelium outside of the fallopian tube.

^bSister Mary Joseph node: palpable nodule bulging into the umbilicus as a result of metastasis of a malignant tumour in the pelvis or abdomen.

endometrial cells to the umbilicus through the abdominal cavity, the lymphatic system or through the embryonic remnants in the umbilical fold such as the urachus and the umbilical vessels [3–5]. Secondary umbilical endometriosis is caused by iatrogenic dissemination of endometrial cells, for instance, after a caesarean section or laparoscopic operation [1, 2, 4]. Other causes of a painful swelling in the umbilicus are shown in Table 1 [3–5].

In the majority of cases, the clinical manifestation of PUE consists of an umbilical nodule. This could be associated with cyclical pain or a bleeding tendency from the umbilicus. Instead of ‘cyclical’ pain, patients could have ‘continuous’ umbilical pain, like in our case. The nodule may have a brown, blue or dark discolouration [3].

Little is known about the sensitivity and specificity of ultrasonography, CT scan and MRI in diagnosing umbilical endometriosis. No pathognomonic signs of PUE have been observed at one of these imaging techniques. Ultrasonography can provide some information about the size of the nodule and its adherence to surrounding tissues [5, 6]. However, in our case, it was not possible to establish a definitive diagnosis with ultrasonography. Furthermore, CT scan and MRI are also of little value in diagnosing intra-abdominal endometriosis [7, 8].

In patients with a symptomatic umbilical nodule due to PUE, surgical exploration and excision of the nodule should be considered. Recurrence of PUE after thoroughly surgical excision is rare [3]. The patient in our case had no symptoms of extensive intra-abdominal endometriosis such as dysmenorrhoea. When patients do have clinical symptoms of intra-abdominal endometriosis, referral to a gynaecologist is mandatory. Treatment of umbilical endometriosis with hormones might be different approach for this condition and can diminish clinical symptoms temporarily. However, after the cessation of hormonal therapy, it is likely that the symptoms will reoccur. Agonist of gonadotropin-releasing hormone and oral contraceptives are most frequently used hormones to treat endometriosis [1, 3].

In conclusion, by increasing the awareness of PUE as a potential diagnose in women with a painful, sometimes discoloured, umbilical swelling, we hope this condition will be recognized and treated optimally.

CONFLICT OF INTEREST STATEMENT

None declared.

REFERENCES

1. Giudice LC, Kao LC. Endometriosis. *Lancet* 2004;**364**:1789–99.
2. Victory R, Diamond MP, Johns DA. Villar's nodule: a case report and systematic literature review of endometriosis externa of the umbilicus. *J Minim Invasive Gynecol* 2007;**14**:23–32.
3. Efremidou EI, Kouklakis G, Mitrakas A, Liratzopoulos N, Polychronidis A. Primary umbilical endometrioma: a rare case of spontaneous abdominal wall endometriosis. *Int J Gen Med* 2012;**5**:999–1002.
4. Fancellu A, Pinna A, Manca A, Capobianco G, Porcu A. Primary umbilical endometriosis. Case report and discussion on management options. *Int J Surg Case Rep* 2013;**4**:1145–8.
5. Hensen JH, Van Breda Vriesman AC, Puylaert JB. Abdominal wall endometriosis: clinical presentation and imaging features with emphasis on sonography. *AJR Am J Roentgenol* 2006;**186**:616–20.
6. Savelli L, Manuzzi L, Di Donato N, Salfi N, Trivella G, Ceccaroni M, et al. Endometriosis of the abdominal wall: ultrasonographic and Doppler characteristics. *Ultrasound Obstet Gynecol* 2012;**39**:336–40.
7. Rousset P, Rousset-Jablonski C, Alifano M, Mansuet-Lupo A, Buy JN, Revel MP. Thoracic endometriosis syndrome: CT and MRI features. *Clin Radiol* 2014;**69**:323–30.
8. Stratton P, Winkel C, Premkumar A, Chow C, Wilson J, Hearn-Stokes R, et al. Diagnostic accuracy of laparoscopy, magnetic resonance imaging, and histopathologic examination for the detection of endometriosis. *Fertil Steril* 2003;**79**:1078–85.