

University of Groningen

Current understanding of fibrosis in genetic cardiomyopathies

Eijgenraam, Tim R; Silljé, Herman H W; de Boer, Rudolf A

Published in:
TRENDS IN CARDIOVASCULAR MEDICINE

DOI:
[10.1016/j.tcm.2019.09.003](https://doi.org/10.1016/j.tcm.2019.09.003)

IMPORTANT NOTE: You are advised to consult the publisher's version (publisher's PDF) if you wish to cite from it. Please check the document version below.

Document Version
Publisher's PDF, also known as Version of record

Publication date:
2020

[Link to publication in University of Groningen/UMCG research database](#)

Citation for published version (APA):

Eijgenraam, T. R., Silljé, H. H. W., & de Boer, R. A. (2020). Current understanding of fibrosis in genetic cardiomyopathies. *TRENDS IN CARDIOVASCULAR MEDICINE*, 30(6), 353-361.
<https://doi.org/10.1016/j.tcm.2019.09.003>

Copyright

Other than for strictly personal use, it is not permitted to download or to forward/distribute the text or part of it without the consent of the author(s) and/or copyright holder(s), unless the work is under an open content license (like Creative Commons).

The publication may also be distributed here under the terms of Article 25fa of the Dutch Copyright Act, indicated by the "Taverne" license. More information can be found on the University of Groningen website: <https://www.rug.nl/library/open-access/self-archiving-pure/taverne-amendment>.

Take-down policy


If you believe that this document breaches copyright please contact us providing details, and we will remove access to the work immediately and investigate your claim.

Downloaded from the University of Groningen/UMCG research database (Pure): <http://www.rug.nl/research/portal>. For technical reasons the number of authors shown on this cover page is limited to 10 maximum.



Contents lists available at ScienceDirect

Trends in Cardiovascular Medicine

journal homepage: www.elsevier.com/locate/tcmCurrent understanding of fibrosis in genetic cardiomyopathies^{☆,☆☆}

Tim R. Eijgenraam, Herman H.W. Silljé, Rudolf A. de Boer*

Department of Cardiology, University Medical Center Groningen, University of Groningen, Antonius Deusinglaan 1, 9713 AV Groningen, the Netherlands



ARTICLE INFO

Keywords:
Fibrosis
Remodeling
Heart failure
Cardiomyopathy
Genetics
Imaging

ABSTRACT

Myocardial fibrosis is the excessive deposition of extracellular matrix proteins, including collagens, in the heart. In cardiomyopathies, the formation of interstitial fibrosis and/or replacement fibrosis is almost always part of the pathological cardiac remodeling process. Different forms of cardiomyopathies show particular patterns of myocardial fibrosis that can be considered as distinctive hallmarks. Although formation of fibrosis is initially aimed to be a reparative mechanism, in the long term, on-going and excessive myocardial fibrosis may lead to arrhythmias and stiffening of the heart wall and subsequently to diastolic dysfunction. Ultimately, adverse remodeling with progressive myocardial fibrosis can lead to heart failure. Not surprisingly, the presence of fibrosis in cardiomyopathies, even when subtle, has consistently been associated with complications and adverse outcomes. In the last decade, non-invasive *in vivo* techniques for visualization of myocardial fibrosis have emerged, and have been increasingly used in research and in the clinic. In this review, we will describe the epidemiology, distribution, and role of myocardial fibrosis in genetic cardiomyopathies, including hypertrophic, dilated, arrhythmogenic, and non-compaction cardiomyopathy, and a few specific forms of genetic cardiomyopathies.

© 2019 The Author(s). Published by Elsevier Inc.

This is an open access article under the CC BY license. (<http://creativecommons.org/licenses/by/4.0/>)

Introduction

Heart failure (HF) is a major cause of morbidity and mortality worldwide and is expected to increase in the next years due to the aging population [1]. HF is defined by an inadequate circulation, due to loss of cardiac pump function, and consequently the inability to provide other tissues with an adequate amount of blood and oxygen [1]. Cardiomyopathies are a group of structural and functional disorders that affect the heart muscle and often lead to HF [2]. A diagnosis of cardiomyopathy implies that no underlying pathophysiology such as (untreated) coronary artery disease, hypertension, valvular disease or congenital heart defect can explain the myocardial remodeling and abnormalities [2].

Cardiomyopathies are categorized based on morphological and pathological characteristics of the heart [2]. The most common types of genetic cardiomyopathies include hypertrophic, dilated, arrhythmogenic, restrictive, and non-compaction cardiomyopathy [2]. In genetic cardiomyopathies, generally changes occur in the structure and function of cardiomyocytes, and this is often associated with formation of fibrosis. Indeed, a hallmark of cardiomyopathies and HF is cardiac fibrosis. In this review, we will discuss the epidemiology, distribution, and role of myocardial fibrosis in hypertrophic, dilated, arrhythmogenic, and non-compaction cardiomyopathy, and forms of cardiomyopathy with a unique pattern of myocardial fibrosis.

Myocardial fibrosis

In the healthy heart, the cardiomyocytes are tightly arranged and coupled for synchronization of electrical conduction and contraction. The architecture of the cardiac muscle is heavily defined by a network of extracellular matrix (ECM) proteins, a non-cellular network that functions as a scaffold, and contains numerous cells, including cardiac fibroblasts (CFs) [3]. The main component of the cardiac ECM is collagen, consisting of approximately 85% type I collagen, which is important for strength, and 11% type III collagen, which is important for elasticity [3]. The ECM has a high turnover of proteins, mainly mediated by the CFs [4]. CFs synthesize the

[☆] Declaration of Competing Interest: The UMCG, which employs the authors, has received research grants and/or fees from AstraZeneca, Abbott, Bristol-Myers Squibb, Novartis, Novo Nordisk, and Roche. Dr. de Boer received personal fees from Abbott, AstraZeneca, MandalMed Inc., and Novartis.

^{☆☆} Funding: This work was supported by the Netherlands Heart Foundation (CVON DOSIS, grant 2014–40) and by a grant from the Leducq Foundation (Cure Phospho-LambdaN induced cardiomyopathy (Cure-PLaN)). Dr. de Boer receives further support from the Netherlands Heart Foundation (CVON SHE-PREDICTS-HF (2017–21), CVON RED-CVD (2017–11) and CVON PREDICT2 (grant 2018–30)), the Innovational Research Incentives Scheme program of the Netherlands Organization for Scientific Research (NWO VIDI, grant 917.13.350), and the European Research Council (ERC CoG 818715, SECRETE-HF).

* Corresponding author.

E-mail address: r.a.de.boer@umcg.nl (R.A. de Boer).

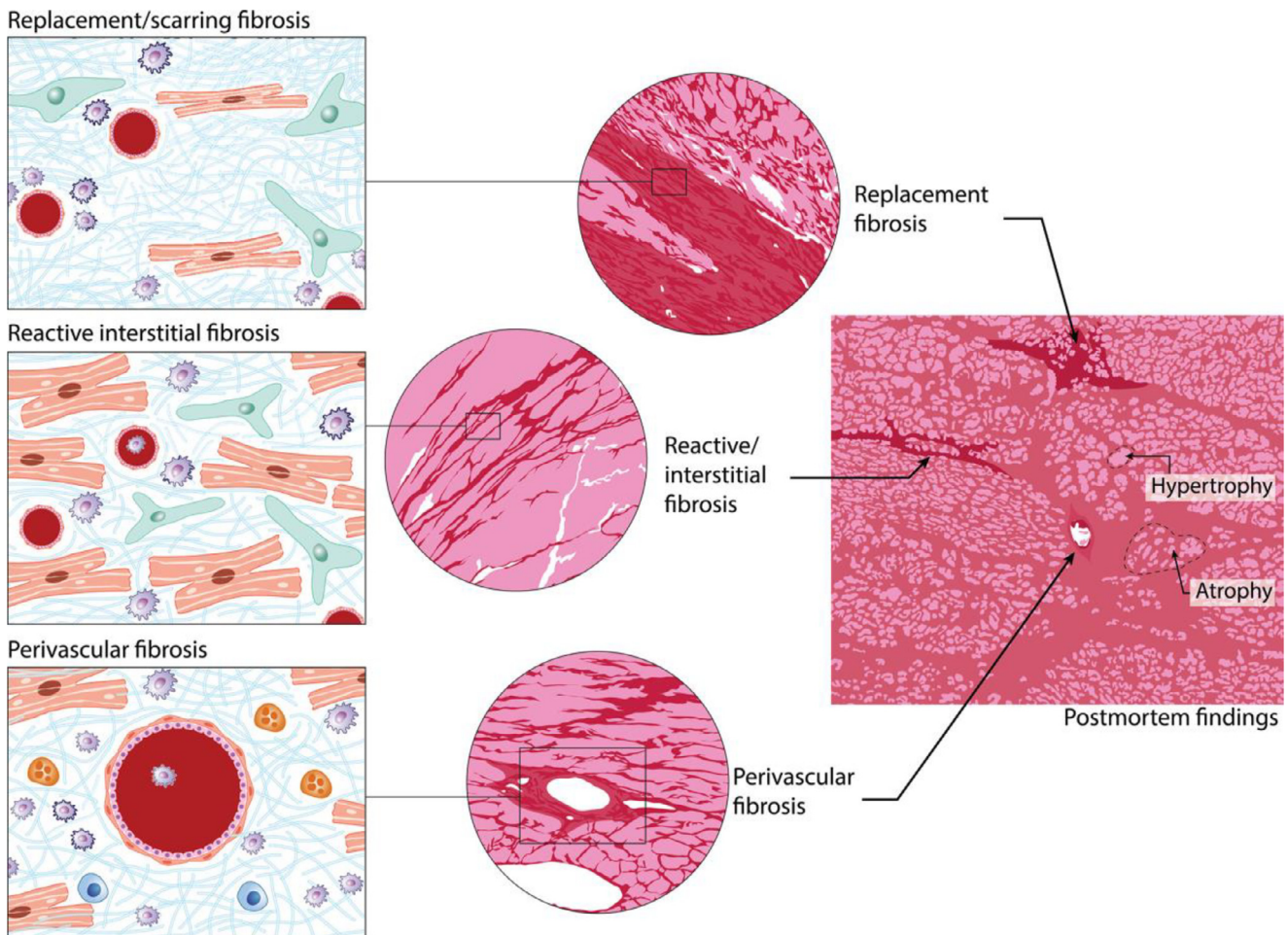


Fig. 1. Myocardial fibrosis can be present as replacement/scarring, reactive interstitial, and perivascular fibrosis, or as a combination. The different cell types that are involved are shown in the panels on the left: fibroblasts (green), inflammatory cells (blue), and cardiomyocytes (red), with fibrillar debris interpositioned. (From: de Boer RA et al. *Eur J Heart Fail* 2019;21(3):272–85 [6]). (For interpretation of the references to colour in this figure legend, the reader is referred to the web version of this article.)

ECM proteins, including collagen, while matrix metalloproteinases (MMPs) break down ECM proteins. MMPs are, in turn, regulated by tissue inhibitors of metalloproteinases (TIMPs) [4]. Indeed, the ECM is not static, but rather a very dynamic structure, with continuous synthesis and degradation at all times.

Fibrosis is a characteristic of many chronic diseases, including cardiac disease and HF. In case of myocardial fibrosis, the balance between synthesis and degradation of ECM proteins is disturbed, leading to excess fibrous connective tissue formation [3]. A main event that occurs is CF activation and differentiation into myofibroblasts, which is primarily triggered by transforming growth factor (TGF- β) [5]. Myofibroblasts secrete higher amounts of ECM proteins, thereby playing a key role in fibrosis formation [4]. Based on the cause and appearance, fibrosis can be divided into different subtypes: reactive interstitial fibrosis, infiltrative perivascular fibrosis, and replacement fibrosis (Fig. 1) [6]. Interstitial fibrosis is characterized by an increase in ECM and collagen deposits between the cells without loss of cardiomyocytes. The fibrosis is diffusely present throughout the myocardium. This type of fibrosis is mostly caused by chronic triggers, such as pressure overload (hypertension), inflammation, and aging [6]. Perivascular fibrosis is characterized by accumulation of collagen fibres in the area surrounding the coronary arteries, and is mainly observed in the setting of hypertension [6]. Replacement fibrosis presents following cardiomyocyte death, and occurs for instance after acute ischemic injury, such as myocardial infarction (MI) (Fig. 2) [6].

In multifactorial forms of HF, generally in older patients or in patients with hypertension, diabetes mellitus (DM), and coronary artery disease (CAD) with MI, the triggers for cardiac remodeling and fibrosis are well known. For instance, chronic pressure overload, such as hypertension and valvular disease, causes activation of TGF- β with a subsequent process of interstitial fibrosis [7]. MI is characterized by substantial cell loss, which necessitates reparative fibrosis [8]. However, the triggers in cardiomyopathies are less well studied, and thus less clear. In hypertrophic cardiomyopathy, we know that the cellular changes and growth at the sites of hypertrophy are uncontrolled, with a typical pattern disarray and cell loss, and patchy replacement fibrosis can be discerned [9]. On the other hand, in dilated cardiomyopathy, stretch of the ventricle due to dilatation causes cardiac remodeling, paracrine signaling of the cardiomyocytes to the CFs, and activation of pro-fibrotic neuro-hormonal systems, most notably the renin-angiotensin-aldosterone system, with myocardial interstitial fibrosis as a result [10]. Other forms of cardiomyopathies are characterized by other triggers, but the exact culprits and sequelae of events are unknown.

As cardiomyocytes have negligible regenerative capacity, severe cardiomyocyte loss cannot be compensated by the generation of new cardiomyocytes. The subsequent loss of tissue will therefore have to be repaired by generation of fibrotic scar tissue [3]. In other words, initially, fibrosis formation often is a reparative reaction to maintain cardiac structural integrity and strength, and may prevent dramatic events such as cardiac rupture. The presence of

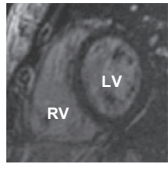

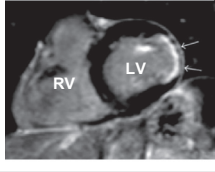

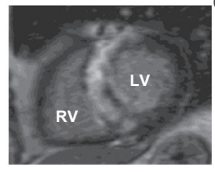

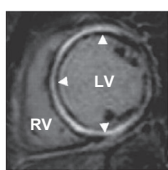
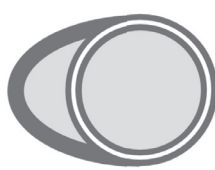
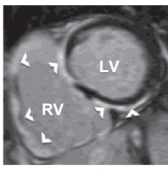
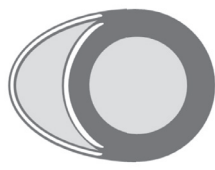
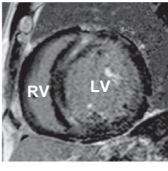

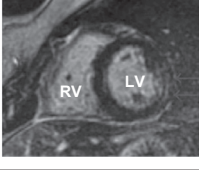

CONDITION	DESCRIPTION	CARDIAC MRI	SCHEMATIC
Healthy	Normal network of extracellular matrix		
MI	Replacement fibrosis in the infarcted area of the LV wall, often endocardial or epicardial, or even transmural, depending on the infarct size		
HCM	Most prominently patches of replacement fibrosis, mainly in the septum, and/or RV and LV insertion points		
DCM	Replacement fibrosis, present throughout the LV midwall		
ARVC	In addition to fibrofatty replacement, myocardial fibrosis in the RV free wall and RV wall of the septum		
LVNC	Myocardial fibrosis, commonly in the compacted but also in the non-compacted wall, mainly in the septum		
PLN-R14del	Extensive interstitial myocardial fibrosis, predominantly in the epicardial layer of the posterolateral LV wall		

Fig. 2. Overview of the different types of cardiomyopathies that were discussed in this review and their distinct types and patterns of myocardial fibrosis. Healthy myocardium is visualized as dark areas without fibrosis, while fibrotic patches are observed as bright areas of LGE. (CMR images from: Posch et al. *Heart Rhythm* 2009;6(4):480–486 [66], Doltra et al. *Biomed Res Int* 2013;2013:676,489 [81], Ismail et al. *Heart* 2014;100(23):1851–1858 [82], Lehrke et al. *Heart* 2011;97(9):727–732 [38], Waterhouse et al. *Br J Sports Med* 2012;46(Suppl 1):69–77 [83], and Szemraj-Rogucka & Majos *OMICS J Radiol* 2017;6:246 [84]).

fibrosis has consistently been associated with worse clinical outcomes. Clearly, this will be confounded by the fact that most severe cardiomyopathy will be accompanied by the most extensive fibrosis. However, the sheer presence of fibrosis, especially when disproportionate to the severity of the disease, may cause specific clinical presentation that is disadvantageous. For instance, myocardial tissue becomes stiff and less compliant when excessive fibrosis forms, resulting in diastolic dysfunction [11]. Further, interstitial or patchy fibrosis is accompanied with electrical events that may cause arrhythmias, such as re-entry circuits and areas of automated automaticity [12].

Visualization of myocardial fibrosis

The gold standard for the investigation of myocardial fibrosis consists of histological analysis of endocardial biopsies (EMB), for example using Masson's trichrome or Sirius red staining [6]. However, since the collection of tissue samples requires an invasive procedure, and explanted tissues are not commonly available for scientific purposes, the data from histological studies are scarce. Furthermore, obtaining EMB is subject to sampling error, as it usually is taken via right-sided heart catheterization from the right ventricular (RV) septal area. In other words, absence of fibrosis in

EMB does not at all rule out the presence of (extensive, patchy) fibrosis elsewhere in the heart. Alternatively, non-invasive techniques have emerged to investigate cardiac fibrosis *in vivo*, most commonly using cardiac magnetic resonance (CMR) imaging. An example is the use of late gadolinium enhancement (LGE) [13]. Gadolinium (Gd) is a chemical element that creates a visible contrast on CMR. By intravenously injecting a bolus of Gd, bound to a carrier molecule that is relatively large and therefore cannot pass the cell membrane, the Gd will rapidly diffuse out of the blood vessels into the tissues, including the heart. In the heart, it cannot invade into intact cardiomyocytes, and will therefore distribute across the extracellular space. Passively accumulated Gd will slowly diffuse out of the tissue and is eventually cleared by the kidneys. In case of damaged cells or fibrosis, there is more extracellular space and therefore a greater amount of Gd, resulting in a delayed wash in and wash out, which can be visualized on CMR [13]. Normal myocardium is visualized as a “dark” area without Gd, and damaged myocardium will be seen as “bright” areas of Gd accumulation. The extent of LGE can be quantified and the accuracy of LGE-CMR to visualize focal myocardial fibrosis has been validated by a close correlation to histologically proven cardiac fibrosis [14].

The major disadvantage of LGE is its limited resolution in the detection of myocardial fibrosis. LGE is an all-or-nothing approach, which is very sensitive to regional Gd accumulation, and is therefore able to visualize focal regions of (replacement) fibrosis but not diffuse interstitial fibrosis [13]. In order to overcome this limitation, new CMR techniques using T1 mapping have been developed. T1 mapping consists of the generation of a pixelated map based on the longitudinal or spin-lattice relaxation of protons that recover towards thermodynamic equilibrium following excitation with the radiofrequency beam [15]. The value of T1 relaxation time varies according to the state of the molecular environment. The native T1 value is a tissue-specific time constant in the absence of an exogenous contrast agent. Tissues generally contain water but pathological processes, including fibrosis, alter the water composition and thereby alter the T1 values. In case of myocardial fibrosis, an increase in native T1 relaxation time will be observed. T1 mapping can also be combined with administration of Gd, which increases proton relaxation, and thus decreases T1 relaxation time [15]. Therefore, in contrast to the native T1 relaxation time, in case of myocardial fibrosis, the post-contrast T1 values will be lower. Native and post-contrast T1 mapping can determine an increase in ECM volume that is not detectable by LGE.

Fibrosis in hypertrophic cardiomyopathy

Hypertrophic cardiomyopathy (HCM) is characterized by left ventricular hypertrophy (LVH), which cannot be explained by abnormal loading conditions (e.g. hypertension) [16]. In the early stages, HCM can present with a non-dilated left ventricle (LV), and a normal LV ejection fraction (EF) or even hypercontractility [16]. In the late phase of the disease, often a dilated LV and diastolic dysfunction are observed [16]. Most commonly, the hypertrophy is asymmetrical and is predominantly located in the interventricular septal (IVS) wall at the basal level, but hypertrophy may also present apical or elsewhere in the heart [16]. Diagnosis of HCM is based on the presence of a diastolic LV wall greater than 15 mm during cardiac imaging [16]. However, in children a Z-score is used to reflect deviation from an age- and sex-matched population [16].

Myocardial fibrosis has been extensively researched in HCM. In a study by Galati et al. [17], 30 hearts that were explanted from end-stage HCM patients due to severe HF were histologically analyzed to quantitatively determine the extent, type and distribution of myocardial fibrosis. All hearts had massive amounts of myocardial fibrosis, ranging from 23% to 56%, with an average amount of

37% [17]. The type of myocardial fibrosis was determined and classified as interstitial or replacement fibrosis, or as a combination [17]. The most prominent type of myocardial fibrosis was replacement fibrosis, which was present in more than half of the cases, followed by a combination of replacement and interstitial fibrosis in a third of the cases [17]. Interstitial fibrosis alone was only seen in one in ten cases [17]. The distribution of myocardial fibrosis was assessed along the three axes, longitudinal (base-to-apex), circumferential (anterior, posterior, lateral and septal), and transmural (epicardial-to-endocardial) [17]. Along the longitudinal axis, the amount of fibrosis was progressively increasing when going from base to apex [17]. Considering the circumferential axis, the LV free wall and the IVS, especially at the LV and RV insertion points, were mostly affected [17]. In contrast, the posterolateral LV wall and RV were least involved [17]. Finally, the epicardial-to-endocardial distribution showed that myocardial fibrosis was mostly present in the mid-ventricular layer [17].

Since the tissues that are available for histological evaluation of myocardial fibrosis are usually derived from end-stage disease, when the amount of fibrosis may have accumulated to extreme amounts, these studies do not provide insight in the development of myocardial fibrosis during disease progression. For this reason and the fact that explanted tissues are scarce, most studies use LGE-CMR. These studies have reported that the majority (42% to 92%) of HCM patients have LGE on CMR, indicating the presence of dense focal scarring [18–23]. Similar to the above mentioned histological findings, the reported amount of myocardial fibrosis was extensive as the extent of LGE went up to 65% of total LV mass, and was mostly present at the IVS and the insertion points of the RV to the LV. Interestingly, the presence and extent of LGE were of great prognostic value since they have been associated with several adverse clinical outcomes, including contractile dysfunction [20,23], cardiac arrhythmias [18–20], and cardiovascular and all-cause mortality [19–22]. Since LGE is only capable of visualizing dense scar tissue, newer studies have used T1-weighted imaging [24–27]. Non-contrast, native T1 relaxation times were increased in HCM patients, indicating the presence of interstitial fibrosis [24–26]. T1 values were higher in segments with LGE than in segments without LGE but were also higher than normal in regions without LGE, meaning that, besides patches of fibrosis, also diffuse interstitial fibrosis was present that was not detected by LGE [24]. Similarly, presence of interstitial fibrosis was demonstrated by shorter post-contrast T1 relaxation times in HCM patients after administration of Gd [25,27]. In line with the findings using LGE, it has been reported that the myocardial T1 times correlated with diastolic function [27]. Together, these studies show that both diffuse interstitial fibrosis and dense focal replacement fibrosis are commonly present in HCM patients and can be visualized by CMR.

In addition to the use of imaging techniques to visualize myocardial fibrosis, a few studies have investigated the utility of serum biomarkers in the assessment of cardiac remodeling in HCM. High sensitivity cardiac troponin T (hs-cTnT) is a marker of cardiomyocyte death as troponin is released from permeabilized, dead cardiomyocytes. Indirectly, hs-cTnT could indicate myocardial fibrosis as cardiomyocyte loss is replaced by fibrosis [28,29]. It has been reported that hs-cTnT serum levels are higher in HCM patients compared to healthy controls, and that increasing levels of hs-cTnT are associated with increasing amounts of myocardial fibrosis [28,30]. A study by Roncarati et al. [31] demonstrated that circulating miRNA-29a, which is produced by fibroblasts, and plays a role in fibrosis by regulating collagen gene expression, was positively correlated with myocardial fibrosis in HCM patients. Also, plasma levels of MMP-9 have been shown to be increased in HCM patients [32]. Interesting results have been found in patients that carry a pathogenic sarcomere mutation but do not have LVH. These genotype positive-phenotype negative (G+P-) patients

were also shown to have myocardial fibrosis, evidenced by presence of LGE and increased T1 relaxation times [33,34]. In addition, Ho et al. [23] demonstrated that serum levels of procollagen I C-terminal propeptide (PICP), a marker of collagen synthesis, were elevated in *G+P-* HCM patients, and even higher in patients with an established phenotype. Moreover, the ratio of PICP to collagen type I C-terminal telopeptide (CITP), which reflects the balance between collagen synthesis and degradation, was unchanged in phenotype negative patients but was higher in patients with overt HCM, suggesting that at first collagen synthesis and degradation are balanced but later collagen synthesis exceeds degradation [23]. Together, these findings suggest that myocardial fibrosis may be an early disease manifestation, independent of LVH and other abnormalities.

In summary, in the majority of HCM patients, often extensive amounts of fibrosis are observed. Typical to HCM, this is most commonly seen as patchy replacement fibrosis, either alone or in combination with interstitial fibrosis, and mostly present at the (basal) IVS and the attachment of the RV and LV (Fig. 2). This can be assessed using LGE and T1 mapping on CMR, but also serum biomarkers have been shown to be useful. The presence and extent of fibrosis have consequences for disease penetration and prognosis.

Fibrosis in dilated cardiomyopathy

On the opposite site of the spectrum of cardiomyopathies is dilated cardiomyopathy (DCM), which is characterized by ventricular dilatation and often progressive contractile dysfunction, resulting in great risk of developing HF [10]. Diagnosis of DCM is based on a LVEF below 45% and an end-diastolic LV diameter greater than 117% during cardiac imaging in the absence of other known causes of myocardial disease [10].

Several studies using LGE-CMR have reported that one third to two thirds (30–66%) of DCM patients have focal myocardial fibrosis [35–38]. Although less extensive than in HCM patients, generally substantial myocardial fibrosis can be determined, up to 36% of total LV mass. LGE distribution is typically indicated as midwall fibrosis, which sets it apart from LGE distribution observed in ischemic heart disease [35–37]. DCM patients with midwall fibrosis have been reported to have greater LV dilatation and worse LVEF than DCM patients without midwall fibrosis [36,38]. Furthermore, the presence and extent of LGE have been associated with adverse clinical outcomes, including cardiac arrhythmias, HF severity, higher rates of cardiac transplantation, implantable cardioverter/defibrillator (ICD) implantation and cardiac resynchronization therapy (CRT), and cardiovascular and all-cause mortality [36–38]. Presence of interstitial fibrosis was also observed, evidenced by increased mean native T1 relaxation times and decreased post-contrast T1 relaxation times in DCM patients, even in the absence of LGE [24,25].

A unique study, performed by Gulati et al. [36], had explanted hearts of 16 DCM patients after heart transplantation or death for histological assessment of myocardial fibrosis together with CMR data. Staining of the explanted hearts validated the findings on CMR studies performed in the same patients prior to their death or transplant, confirming presence of extensive midwall replacement fibrosis in DCM patients [36].

Two studies reported that serum levels of several fibrosis markers, including procollagen type III (PCIII), connective tissue growth factor (CTGF), MMP-2, MMP-9 and TIMP-1, were increased in DCM patients compared to healthy controls [39,40]. Interestingly, only PCIII was even higher in DCM patients with detectable fibrosis than in DCM patients without detectable fibrosis [39].

To summarize, many DCM patients present with substantial amounts of myocardial fibrosis. In these patients, myocardial

fibrosis is mostly observed as replacement fibrosis with a midwall distribution throughout the LV (Fig. 2). Similar to HCM, myocardial fibrosis is related to disease severity in DCM.

Fibrosis in arrhythmogenic cardiomyopathy

Arrhythmogenic right ventricular cardiomyopathy (ARVC) is an inherited form of heart disease and is characterized by ventricular arrhythmias (VAs) and contractile dysfunction with a high risk for sudden cardiac death (SCD), particularly in young patients and athletes [41]. Initially, this type of cardiomyopathy was thought to predominantly affect the right side of the heart but nowadays it is increasingly recognized to involve both ventricles, resulting in the broader term of arrhythmogenic cardiomyopathy (ACM) [41]. The hallmark characteristic of ARVC is the replacement of myocardial tissue, mainly of the RV, by fibrofatty tissue [41]. In addition, degeneration of the myocardium and fibrosis are present [41]. There is no gold standard in the diagnosis of ARVC [41]. Instead, diagnosis is based on a scoring system comprised of multiple aspects such as genetic factors, electrocardiographic and histological abnormalities, arrhythmias, and structural or functional alterations, divided into major and minor criteria based on their association with ARVC [41]. Diagnosis of ARVC is fulfilled when 2 major criteria, 1 major plus 2 minor, or 4 minor criteria from different categories are present [41].

Since the key hallmark of ARVC is cardiac fibrofatty replacement, the use of LGE is not included in the current Task Force criteria for diagnosis of ARVC [42]. Only a few studies have investigated LGE on CMR in ARVC [43–46]. These studies reported the presence of RV LGE in 39%–88% of ARVC patients. The high variability between studies might be explained by the low number of patients ($n=8-23$) that were studied. LGE was most commonly found in the RV outflow tract, RV free wall and RV wall of the IVS (Fig. 2). Regions of LGE were described to show motion abnormalities [43,44]. In two studies EMBs or explanted heart tissues were available from a small number of patients and histological examination confirmed the presence of extensive myocardial fibrosis in the RV wall [43,44]. In a study by Tandri et al., [43] presence of LGE predicted inducibility of ventricular tachycardia (VT) during electrophysiological testing. Moreover, there was a strong association between the extent of LGE and RV dysfunction [43,45]. In addition to RV LGE, two studies reported presence of LGE in the LV in 50% and 33% of ARVC patients, consistent with the increasingly recognized paradigm that ARVC has biventricular involvement [44,46].

There are several limitations that complicate the use of LGE in ARVC. One limitation is the thin RV wall and the pronounced thinning of the RV wall in ARVC [42]. In addition, it is challenging to distinguish myocardial fibrosis from fibrofatty replacement by LGE sequences, introducing great interobserver variability [42]. Three-dimensional (3D) electroanatomic voltage mapping (EVM) is a technique to accurately characterize presence, localization, and extent of so-called low-voltage areas (LVAs) or “electroanatomical scars” [47]. LVAs have been proven to correspond with RV areas of pathological myocardial substrates [47]. Indeed, increasing amounts of RV LGE were associated with the extent of LVAs but EVM has been shown to provide a more accurate measurement of affected myocardium in ARVC patients, evidenced by presence of LVAs in 64–91% of patients [45,46,48]. However, the main disadvantage of EVM is that it is an invasive procedure as it requires cardiac catheterization, whereas LGE can be used noninvasively [45].

In summary, even though ARVC is mainly characterized by fibrofatty replacement, and determination of myocardial fibrosis *in vivo* could be challenging, the presence of focal RV myocardial fibrosis is related to the severity of RV dysfunction and the presence

of VT. Additionally, myocardial fibrosis is not limited to the right side of the heart but may also be observed in the LV.

Fibrosis in non-compaction cardiomyopathy

Left ventricular non-compaction (LVNC) is a very rare form of cardiomyopathy, which is characterized by structural abnormality of the LV myocardium [49]. The etiology of LVNC is unknown but is believed to be genetic in nature, causing failure of the compaction process of the myocardial wall during development [49]. The key hallmark of LVNC is the two-layered structure of the LV myocardium at the apical and lateral sides, consisting of a spongy (non-compacted), trabeculated endocardial layer and a thinner compacted epicardial layer [49]. The ratio of non-compacted to compacted myocardium is the main criterion for diagnosis of LVNC, and is met when the ratio is greater than 2:1 at end-systole using echocardiography or 2.3:1 at end-diastole using CMR [49].

A limited amount of studies have investigated myocardial fibrosis in small numbers ($n=13-47$) of LVNC patients [50–56]. These studies reported the presence of LGE on CMR in 33%–74% of LVNC patients. The average reported amount of LGE was relatively small when compared to the cardiomyopathies that were previously discussed, ranging from 5% to 8% of total LV mass. LGE was present in both compacted and non-compacted myocardial segments but most commonly in the compacted region, and mainly in the IVS [50–53]. LGE was most frequently seen as mid-myocardial [51–54]. Even though the amount of myocardial fibrosis is low, LVNC patients with LGE were demonstrated to have greater LV volume than patients without LGE, and presence and extent of LGE were independently related to LV systolic function [51,53–55]. Moreover, LVNC patients with LGE had a higher risk of developing arrhythmias [53,55]. Mean native T1 relaxation times of the compacted myocardium of LVNC patients were higher than healthy control myocardium [54,56]. Furthermore, LGE-positive patients had higher native T1 values than patients without LGE, and native T1 values showed an inversed correlation with LVEF [54,56]. Nucifora et al. [51] observed presence of LGE in approximately 20% of asymptomatic LVNC patients and LVNC patients with preserved systolic function, which suggests that myocardial fibrosis may be an early disease manifestation.

The study of Szemraj-Rogucka et al. [53] determined the plasma levels of four miRNAs, which are well established in myocardial fibrosis, miRNA-21, miRNA-29a, miRNA-30d and miRNA-133a. They demonstrate that plasma levels of all 4 miRNAs are elevated in LVNC patients as compared to healthy controls. In addition, plasma levels were higher in LVNC patients with LGE as compared to LVNC patients without LGE. The only study in which an EMB sample was available was a case report by Kalavakunta et al., [57] in which histological examination showed a vast amount of replacement fibrosis, similar to the findings with CMR.

To summarize, myocardial fibrosis was mostly present in the compacted myocardium, and most commonly in the IVS (Fig. 2). The presence of patches of myocardial replacement fibrosis, although to a lesser extent than in other forms of cardiomyopathy, correlated with the severity of systolic dysfunction and the risk of arrhythmias in LVNC. Moreover, in these patients, the serum levels of miRNAs related to fibrosis were indicative of myocardial fibrosis severity.

Cardiomyopathies with different disease manifestations and divergent patterns of myocardial fibrosis

The cardiomyopathies described above adhere to common descriptions. There are, however, also additional gene mutations causing cardiomyopathies that cannot be automatically included in

one of these categories, as they exhibit a specific clinical presentation, often also with divergent fibrotic patterns.

Laminopathies are caused by pathogenic variants in the lamin A/C (*LMNA*) gene [58]. The lamin A and C proteins are produced via alternative splicing of this gene, and are components of the nuclear lamina and hence essential in proper nuclear architecture and function. Several autosomal dominant mutations in the *LMNA* gene have been associated with cardiac disease that finally can culminate in a DCM phenotype. This cardiomyopathy is, however, also characterized by early-onset atrioventricular (AV)-block, (supra)ventricular arrhythmias, and SCD even before DCM development [59]. Thus, in contrast to idiopathic DCM, these laminopathies have a higher occurrence of conduction system defects and VAs. Interestingly, the unusual structural abnormalities in laminopathies include fibrosis within the IVS, near the region of the conduction system, as has been revealed by autopsy studies [60]. Several imaging studies using LGE have shown midmyocardial basal and septal fibrosis [61–63]. The basal septal scar also makes catheter ablation of VAs very challenging and this procedure is associated with a poor prognosis in this patient population. [64]. The localized fibrosis in the IVS may be the mechanism behind reduced septal function, AV-block, and VA in lamin A/C mutation-positive subjects. In conclusion, the fibrotic pattern in laminopathy patients appears different from other DCM patients and even has some HCM (septal fibrosis) characteristics.

Another form of cardiomyopathy that is present with specific disease is the phospholamban (PLN) p.Arg14del induced cardiomyopathy. Our group has extensively characterized this form of cardiomyopathy, which interestingly shows a unique pattern of myocardial fibrosis that is different than the other cardiomyopathies that were discussed previously. PLN is a sarcoplasmic reticulum (SR) membrane protein expressed in cardiomyocytes and involved in calcium handling by negatively regulating the SR Ca^{2+} -ATPase (SERCA) protein [65]. This mutation in the *PLN* gene, deleting the arginine on position 14 of the PLN protein, results in a severe form of cardiomyopathy with characteristics of DCM and ARVC [65]. Mutation carriers have a high risk of developing arrhythmias and end-stage HF with high mortality and poor prognosis from late adolescence [65]. This mutation has been found in about 14% of Dutch DCM and ARVC patients and is therefore the most identified mutation in cardiomyopathy patients in the Netherlands [65].

Two studies have demonstrated the presence of focal myocardial fibrosis in PLN-R14del mutation carriers using LGE on CMR, which was mainly observed in the posterolateral LV wall [66,67]. In the study of te Rijdt et al. [67], it was reported that out of 150 PLN-R14del mutation carriers that were enrolled in the PHORECAST study who underwent CMR imaging, 50 mutation carriers (9/10 index patients and 41/140 relatives) showed LGE. The median extent of LGE was 6% of total LV mass and was higher in index patients (18%) than their relatives (5%). Almost all mutation carriers (10/11) with impaired LV systolic function had LGE. The RV only showed LGE in 5% of mutation carriers but these mutation carriers had lower RV function compared to mutation carriers without RV-LGE. LGE was also observed in mutation carriers with preserved LV function, suggesting that fibrosis is an early mutation-related remodeling process that precedes detectable ventricular dysfunction [66,67]. Both studies reported an association between the presence and localization of LGE and low-voltage ECG, a typical characteristic in PLN-R14del mutation carriers, suggesting that myocardial fibrosis is the substrate of these ECG abnormalities [66,67]. Finally, te Rijdt et al. reported that the presence of LGE was independently associated with the occurrence of VA, stressing the clinical importance of fibrosis in this disease [67].

Several studies have performed histological analysis on hearts of patients with the PLN-R14del mutation after autopsy or transplantation, confirming the findings using LGE on CMR [67–70].

Similar to the observed localization of LGE, extensive interstitial myocardial fibrosis was mostly present in the epicardial layer of the posterolateral LV wall and to a lesser extent in the septum and right ventricle [67–70]. The distribution of myocardial fibrosis was not different between patients with a predominantly DCM or ARVC phenotype [68]. Additionally, Sepehrkhoy et al. [70] compared the distribution of myocardial fibrosis in PLN-R14del hearts with hearts with desmosomal, lamin A/C, sarcomeric and desmin mutations. It was demonstrated that together with desminopathy, PLN-R14del hearts had the highest amount of myocardial fibrosis. In addition, the epicardial distribution of fibrosis in the posterolateral LV wall was found to be a distinct pattern in PLN-R14del cardiomyopathy (Fig. 2).

In summary, specific mutations causing cardiomyopathy may give rise to myocardial fibrosis patterns that are distinct from most other types of cardiomyopathy, as exemplified by laminopathies and PLN-R14del cardiomyopathy. These distinct fibrotic patterns are also associated with specific disease characteristics, and therefore the fibrotic pattern recognition has clinical importance.

Can we treat myocardial fibrosis?

Given the importance of myocardial fibrosis for many different types of cardiomyopathies, attempts have been made to inhibit or attenuate fibrosis formation.

TGF- β is the best-known fibrogenic factor in myocardial fibrosis formation. TGF- β expression in the heart is increased with cardiac stress and during myocardial fibrosis, and exerts profibrotic effects amongst others via fibroblast activation and downregulation of TIMPs [71]. There are two FDA-approved drugs, pirfenidone and tranilast, which have an effect on fibrosis by inhibition of the TGF- β signaling pathway. Pirfenidone, initially used for treatment of idiopathic pulmonary fibrosis, has been reported to reduce fibrosis in rats with MI [72]. Tranilast, originally used as an antihistamine in asthma, was found to reduce fibrosis in diabetic rats [73]. However, inhibition of the TGF- β receptors 1 and 2 (TGF β R1 and TGF β R2) has been shown to reduce cardiac fibrosis in mouse models but resulted in increased mortality, suggesting that TGF- β is not only detrimental but is necessary to maintain a normal ECM [74].

The renin-angiotensin-aldosterone system (RAAS) plays a key role in homeostasis of blood pressure and tissue perfusion [75]. When blood pressure is decreased, a homeostatic feedback mechanism is activated in the kidneys, in which angiotensin (Ang) II production is stimulated to restore blood pressure via vasoconstriction and fluid retention [75]. AngII and aldosterone can stimulate collagen synthesis. Additionally, AngII can reduce MMP-1 activity and can induce TGF- β 1 expression via the angiotensin type-I (AT1) receptor in CFs. Together, these effects contribute to increased myocardial fibrosis, and therefore have been proposed as therapeutic targets. The use of aliskiren, a renin inhibitor, has been shown to prevent myocardial collagen deposition in a mouse model of myocardial fibrosis [76]. In addition, angiotensin-converting enzyme (ACE) inhibitors, including captopril, have been reported to reduce arrhythmias and improve cardiac function [77]. Administration of valsartan, an AngII receptor blocker (ARB), was also found to reduce perivascular fibrosis in a pressure overload mouse model [78]. Similarly, the AT1 receptor antagonist losartan was shown to suppress myocardial fibrosis in patients with end-stage renal disease [79]. Finally, inhibition of aldosterone using spironolactone prevented the increase in myocardial collagen in rats [80].

In conclusion, targeting myocardial fibrosis as a therapeutic target in cardiomyopathies seems reasonable, and experimental data are promising. However, it needs to be taken into account that for normal structure and function, the heart depends on a well-balanced ECM, and that shifting the balance towards the other extreme may have detrimental effects as well. Indeed, fibro-

sis formation has several bona fide functions, and interfering with fibrogenesis could be detrimental. Clearly, generation of solid experimental and mechanistic data should precede any clinical trial.

Clinical impact

Currently advocated diagnostic and treatment guidelines do not include the recommendation to visualize or target myocardial fibrosis. Most guidelines made use of cohorts with long-term follow-up, and it has taken 10–20 years to accumulate endpoints based on which prognostic models can be calculated. Since echocardiography has been the imaging tool of choice for a long term, HCM and DCM still largely rely on echocardiography. However, in the near future, we foresee that existing databases will be enriched with data from CMR and thus with parameters of myocardial fibrosis. These parameters will be evaluated for their incremental prognostic impact – existing analyses from (small) cohorts suggest that LGE or T1 relaxation time may have incremental value in this respect. Clearly, this might change current algorithms with regards to timing of start of pharmacological therapies or implantation of ICDs. Clearly, performing LGE-CMR is more time-consuming and costly, and not every hospital has the required MRI equipment or techniques at their disposal, so proposed algorithms should also consider limited resources and identify patients in the gray zone whose management is most likely to change and justify using additional, more expensive techniques. Arguably, a pro-fibrotic phenotype might prompt a physician for fast referral for ICD or aggressive pharmacotherapy. On the other hand, in the absence of fibrosis, a strategy of watchful waiting may be justified as we know that short and middle term prognosis are good.

Concluding remarks

Detection of myocardial fibrosis *in vivo* using LGE or T1 mapping has been shown to be highly accurate, and to have great prognostic value in the types of cardiomyopathies that we have discussed in this review. Presence and extent of myocardial fibrosis have been associated with several adverse clinical outcomes. In addition, the different forms of cardiomyopathies that were discussed exert distinct types and patterns of myocardial fibrosis (summarized in Fig. 2), which may be useful in the identification of the disease. Moreover, there are several indications that myocardial fibrosis could be an early manifestation of cardiomyopathy, suggesting that early recognition could help in the determination of a therapeutic strategy.

References

- [1] Savarese G, Lund LH. Global public health burden of heart failure. *Card Fail Rev* 2017;3(1):7–11.
- [2] Seferović PM, Polovina M, Bauersachs J, Arad M, Ben Gal T, Lund LH, et al. Heart failure in cardiomyopathies: a position paper from the heart failure association of the european society of cardiology. *Eur J Heart Fail* 2019;21(5):553–76.
- [3] Piek A, de Boer RA, Silljé HHW. The fibrosis-cell death axis in heart failure. *Heart Fail Rev* 2016;21(2):199–211.
- [4] Nagaraju CK, Robinson EL, Abdesselem M, Trenson S, Dries E, Gilbert G, et al. Myofibroblast phenotype and reversibility of fibrosis in patients with end-stage heart failure. *J Am Coll Cardiol* 2019;73(18):2267–82.
- [5] Khalil H, Karch J, Molkentin JD, Khalil H, Kanisicak O, Prasad V, et al. Fibroblast-specific TGF- β -Smad2/3 signaling underlies cardiac fibrosis. *J Clin Invest* 2017;127(10):3770–83.
- [6] de Boer RA, De Keulenaer G, Bauersachs J, Brutsaert D, Cleland JG, Diez J, et al. Towards better definition, quantification and treatment of fibrosis in heart failure. a scientific roadmap by the committee of translational research of the heart failure association (HFA) of the European Society of Cardiology. *Eur J Heart Fail* 2019;21(3):272–85.
- [7] Creemers EE, Pinto YM. Molecular mechanisms that control interstitial fibrosis in the pressure-overloaded heart. *Cardiovasc Res* 2011;89(2):265–72.
- [8] Talman V, Ruskoaho H. Cardiac fibrosis in myocardial infarction—from repair and remodeling to regeneration. *Cell Tissue Res* 2016;365(3):563–81.

- [9] Marian AJ, Braunwald E. Hypertrophic cardiomyopathy. *Circ Res* 2017;121(7):749–70.
- [10] McNally EM, Mestroni L. Dilated cardiomyopathy: genetic determinants and mechanisms. *Circ Res* 2017;121(7):731–48.
- [11] Ellims AH, Shaw JA, Stub D, Iles LM, Hare JL, Slavina GS, et al. Diffuse myocardial fibrosis evaluated by post-contrast T1 mapping correlates with left ventricular stiffness. *J Am Coll Cardiol* 2014;63(11):1112–18.
- [12] De Jong S, Van Veen TAB, Van Rijen HVM, De Bakker JMT. Fibrosis and cardiac arrhythmias. *J Cardiovasc Pharmacol* 2011;57(6):630–8.
- [13] Doltra A, Amundsen B, Gebker R, Fleck E, Kelle S. Emerging concepts for myocardial late gadolinium enhancement MRI. *Curr Cardiol Rev* 2013;9(3):185–90.
- [14] Iles LM, Ellims AH, Llewellyn H, Hare JL, Kaye DM, McLean CA, et al. Histological validation of cardiac magnetic resonance analysis of regional and diffuse interstitial myocardial fibrosis. *Eur Heart J Cardiovasc Imaging* 2015;16(1):14–22.
- [15] Taylor AJ, Salerno M, Dharmakumar R, Jerosch-Herold M. T1 mapping basic techniques and clinical applications. *JACC Cardiovasc Imaging* 2016;9(1):67–81.
- [16] Elliott PM, Anastasakis A, Borger MA, Borggrefe M, Cecchi F, Charron P, et al. 2014 ESC guidelines on diagnosis and management of hypertrophic cardiomyopathy: the task force for the diagnosis and management of hypertrophic cardiomyopathy of the European Society of Cardiology (ESC). *Eur Heart J* 2014;35(39):2733–79.
- [17] Galati G, Leone O, Pasquale F, Olivetto I, Biagini E, Grigioni F, et al. Histological and histometric characterization of myocardial fibrosis in end-stage hypertrophic cardiomyopathy. *Circ Heart Fail* 2016;9(9):e003090.
- [18] Weisler-Snir A, Hindieh W, Spears DA, Adler A, Rakowski H, Chan RH. The relationship between the quantitative extent of late gadolinium enhancement and burden of nonsustained ventricular tachycardia in hypertrophic cardiomyopathy: a delayed contrast-enhanced magnetic resonance study. *J Cardiovasc Electrophysiol* 2019;30(5):651–7.
- [19] O'Hanlon R, Grasso A, Roughton M, Moon JC, Clark S, Wage R, et al. Prognostic significance of myocardial fibrosis in hypertrophic cardiomyopathy. *J Am Coll Cardiol* 2010;56(11):867–74.
- [20] Rubinshtein R, Glockner JF, Ommen SR, Araoz PA, Ackerman MJ, Sorajja P, et al. Characteristics and clinical significance of late gadolinium enhancement by contrast-enhanced magnetic resonance imaging in patients with hypertrophic cardiomyopathy. *Circ Heart Fail* 2010;3(1):51–8.
- [21] Chan RH, Maron BJ, Olivetto I, Pencina MJ, Assenza GE, Haas T, et al. Prognostic value of quantitative contrast-enhanced cardiovascular magnetic resonance for the evaluation of sudden death risk in patients with hypertrophic cardiomyopathy. *Circulation* 2014;130(6):484–95.
- [22] Bruder O, Wagner A, Jensen CJ, Schneider S, Ong P, Kispert EM, et al. Myocardial scar visualized by cardiovascular magnetic resonance imaging predicts major adverse events in patients with hypertrophic cardiomyopathy. *J Am Coll Cardiol* 2010;56(11):875–87.
- [23] Ho CY, López B, Coelho-Filho OR, Lakdawala NK, Cirino AL, Jarolim P, et al. Myocardial fibrosis as an early manifestation of hypertrophic cardiomyopathy. *N Engl J Med* 2010;363(6):552–63.
- [24] Dass S, Suttie JJ, Piechnik SK, Ferreira VM, Holloway CJ, Banerjee R, et al. Myocardial tissue characterization using magnetic resonance noncontrast T1 mapping in hypertrophic and dilated cardiomyopathy. *Circ Cardiovasc Imaging* 2012;5(6):726–33.
- [25] Puntmann VO, Voigt T, Chen Z, Mayr M, Karim R, Rhode K, et al. Native T1 mapping in differentiation of normal myocardium from diffuse disease in hypertrophic and dilated cardiomyopathy. *JACC Cardiovasc Imaging* 2013;6(4):475–84.
- [26] Malek ŁA, Werys K, Kłopotowski M, Śpiewak M, Miłoś-Wieczorek B, Mazurkiewicz Ł, et al. Native T1-mapping for non-contrast assessment of myocardial fibrosis in patients with hypertrophic cardiomyopathy – comparison with late enhancement quantification. *Magn Reson Imaging* 2015;33(6):718–24.
- [27] Ellims AH, Iles LM, Ling LH, Hare JL, Kaye DM, Taylor AJ. Diffuse myocardial fibrosis in hypertrophic cardiomyopathy can be identified by cardiovascular magnetic resonance, and is associated with left ventricular diastolic dysfunction. *J Cardiovasc Magn Reson* 2012;14(1):76.
- [28] Kawasaki T, Sakai C, Harimoto K, Yamano M, Miki S, Kamitani T. Usefulness of high-sensitivity cardiac troponin t and brain natriuretic peptide as biomarkers of myocardial fibrosis in patients with hypertrophic cardiomyopathy. *Am J Cardiol* 2013;112(6):867–72.
- [29] Gommans DHF, Cramer GE, Fouraux MA, Bakker J, Michels M, Dieker HJ, et al. Prediction of extensive myocardial fibrosis in nonhigh risk patients with hypertrophic cardiomyopathy. *Am J Cardiol* 2018;122(3):483–9.
- [30] Moreno V, Hernández-Romero D, Vilchez JA, García-Honrubia A, Cambrero F, Casas T, et al. Serum levels of high-sensitivity troponin T: a novel marker for cardiac remodeling in hypertrophic cardiomyopathy. *J Card Fail* 2010;16(12):950–6.
- [31] Roncarati R, Viviani Anselmi C, Losi MA, Papa L, Cavarretta E, Da Costa Martins P, et al. Circulating miR-29a, among other up-regulated microRNAs, is the only biomarker for both hypertrophy and fibrosis in patients with hypertrophic cardiomyopathy. *J Am Coll Cardiol* 2014;63(9):920–7.
- [32] Fernlund E, Gyllenhammar T, Jablonowski R, Carlsson M, Larsson A, Årnlöv J, et al. Serum biomarkers of myocardial remodeling and coronary dysfunction in early stages of hypertrophic cardiomyopathy in the young. *Pediatr Cardiol* 2017;38(4):853–63.
- [33] Rowin EJ, Maron MS, Lesser JR, Maron BJ. CMR with late gadolinium enhancement in genotype positive-phenotype negative hypertrophic cardiomyopathy. *JACC Cardiovasc Imaging* 2012;5(1):119–22.
- [34] Ho CY, Abbasi SA, Neilan TG, Shah RV, Chen Y, Heydari B, et al. T1 measurements identify extracellular volume expansion in hypertrophic cardiomyopathy sarcomere mutation carriers with and without left ventricular hypertrophy. *Circ Cardiovasc Imaging* 2013;6(3):415–22.
- [35] Looi JL, Edwards C, Armstrong GP, Scott A, Patel H, Hart H, et al. Characteristics and prognostic importance of myocardial fibrosis in patients with dilated cardiomyopathy assessed by contrast-enhanced cardiac magnetic resonance imaging. *Clin Med Insights Cardiol* 2010;4:129–34.
- [36] Gulati A, Jabbar A, Ismail TF, Guha K, Khwaja J, Raza S, et al. Association of fibrosis with mortality and sudden cardiac death in patients with nonischemic dilated cardiomyopathy. *JAMA - J Am Med Assoc* 2013;309(9):896–908.
- [37] Marra MP, De Lazzari M, Zorzi A, Migliore F, Zilio F, Calore C, et al. Impact of the presence and amount of myocardial fibrosis by cardiac magnetic resonance on arrhythmic outcome and sudden cardiac death in nonischemic dilated cardiomyopathy. *Heart Rhythm* 2014;11(5):856–63.
- [38] Lehrke S, Lossnitzer D, Schöb M, Steen H, Merten C, Kemmling H, et al. Use of cardiovascular magnetic resonance for risk stratification in chronic heart failure: prognostic value of late gadolinium enhancement in patients with non-ischaemic dilated cardiomyopathy. *Heart* 2011;97(9):727–32.
- [39] Yu M, Wen S, Wang M, Liang W, Li HH, Long Q, et al. TNF- α -secreting b cells contribute to myocardial fibrosis in dilated cardiomyopathy. *J Clin Immunol* 2013;33(5):1002–8.
- [40] Rubiś P, Wiśniowska-Śmialek S, Wypasek E, Biernacka-Fijalkowska B, Rudnicka-Sosin L, Dziewiecka E, et al. Fibrosis of extracellular matrix is related to the duration of the disease but is unrelated to the dynamics of collagen metabolism in dilated cardiomyopathy. *Inflamm Res* 2016;65(12):941–9.
- [41] Corrado D, Wichter T, Link MS, Hauer RNW, Marchlinski FE, Anastasakis A, et al. Treatment of arrhythmogenic right ventricular cardiomyopathy/dysplasia: an international task force consensus statement. *Circulation* 2015;132(5):441–53.
- [42] Te Riele ASJM, Tandri H, Bluemke DA. Arrhythmogenic right ventricular cardiomyopathy (ARVC): cardiovascular magnetic resonance update. *J Cardiovasc Magn Reson* 2014;16(1):50.
- [43] Tandri H, Saranathan M, Rodriguez ER, Martinez C, Bomma C, Nasir K, et al. Noninvasive detection of myocardial fibrosis in arrhythmogenic right ventricular cardiomyopathy using delayed-enhancement magnetic resonance imaging. *J Am Coll Cardiol* 2005;45(1):98–103.
- [44] Pfluger HB, Phrommintikul A, Mariani JA, Cherayath JG, Taylor AJ. Utility of myocardial fibrosis and fatty infiltration detected by cardiac magnetic resonance imaging in the diagnosis of arrhythmogenic right ventricular dysplasia—a single centre experience. *Hear Lung Circ* 2008;17(6):478–83.
- [45] Marra MP, Leoni L, Bauce B, Corbetti F, Zorzi A, Migliore F, et al. Imaging study of ventricular scar in arrhythmogenic right ventricular cardiomyopathy. *Circ Arrhythmia Electrophysiol* 2012;5(1):91–100.
- [46] Santangeli P, Pieroni M, Dello Russo A, Casella M, Pelargonio G, Macchione A, et al. Noninvasive diagnosis of electroanatomic abnormalities in arrhythmogenic right ventricular cardiomyopathy. *Circ Arrhythmia Electrophysiol* 2010;3(6):632–8.
- [47] Corrado D, Basso C, Leoni L, Tokajuk B, Bauce B, Frigo G, et al. Three-dimensional electroanatomic voltage mapping increases accuracy of diagnosing arrhythmogenic right ventricular cardiomyopathy/dysplasia. *Circulation* 2005;111(23):3042–50.
- [48] Santangeli P, Hamilton-Craig C, Dello Russo A, Pieroni M, Casella M, Pelargonio G, et al. Imaging of scar in patients with ventricular arrhythmias of right ventricular origin: cardiac magnetic resonance versus electroanatomic mapping. *J Cardiovasc Electrophysiol* 2011;22(12):1359–66.
- [49] Towbin JA, Jefferies JL. Cardiomyopathies due to left ventricular noncompaction, mitochondrial and storage diseases, and inborn errors of metabolism. *Circ Res* 2017;121(7):838–54.
- [50] Dursun M, Agayev A, Nisli K, Ertugrul T, Onur I, Ofaz H, et al. MR imaging features of ventricular noncompaction: emphasis on distribution and pattern of fibrosis. *Eur J Radiol* 2010;74(1):147–51.
- [51] Nucifora G, Aquaro GD, Pingitore A, Masci PG, Lombardi M. Myocardial fibrosis in isolated left ventricular non-compaction and its relation to disease severity. *Eur J Heart Fail* 2011;13(2):170–6.
- [52] Wan J, Zhao S, Cheng H, Lu M, Jiang S, Yin G, et al. Varied distributions of late gadolinium enhancement found among patients meeting cardiovascular magnetic resonance criteria for isolated left ventricular non-compaction. *J Cardiovasc Magn Reson* 2013;15(1):20.
- [53] Szemraj J, Masiarek K, Majos A, Szemraj-Rogucka ZM. Circulating microRNAs as biomarkers for myocardial fibrosis in patients with left ventricular non-compaction cardiomyopathy. *Arch Med Sci* 2019;15(2):376–84.
- [54] Araujo-Filho JAB, Assuncao AN, Tavares De Melo MD, Bière L, Lima CR, Dantas RN, et al. Myocardial T1 mapping and extracellular volume quantification in patients with left ventricular non-compaction cardiomyopathy. *Eur Heart J Cardiovasc Imaging* 2018;19(8):888–95.
- [55] Ashrith G, Gupta D, Light-McGroary KA, Weiss R. Cardiovascular magnetic resonance characterization of left ventricular non-compaction provides independent prognostic information in patients with incident heart failure or suspected cardiomyopathy. *J Am Coll Cardiol* 2014;16:64.
- [56] Zhou H, Lin X, Fang L, Zhao X, Ding H, Chen W, et al. Characterization of compacted myocardial abnormalities by cardiac magnetic resonance with native T1 mapping in left ventricular non-compaction patients. *Circ J* 2016;80(5):1210–16.

- [57] Kalavakunta JK, Tokala H, Gosavi A, Gupta V. Left ventricular noncompaction and myocardial fibrosis: a case report. *Int Arch Med* 2010;3(1):20.
- [58] Peretto G, Sala S, Benedetti S, Di Resta C, Gigli L, Ferrari M, et al. Updated clinical overview on cardiac laminopathies: an electrical and mechanical disease. *Nucleus* 2018;9(1):380–91.
- [59] Hasselberg NE, Haland TF, Saberniak J, Brekke PH, Berge KE, Leren TP, et al. Lamin A/C cardiomyopathy: young onset, high penetrance, and frequent need for heart transplantation. *Eur Heart J* 2018;39(10):853–60.
- [60] Graber HL, Unverferth DV, Baker PB, Ryan JM, Baba N, Wooley CF. Evolution of a hereditary cardiac conduction and muscle disorder: a study involving a family with six generations affected. *Circulation* 1986;74(1):21–35.
- [61] Hasselberg NE, Edvardsen T, Petri H, Berge KE, Leren TP, Bundgaard H, et al. Risk prediction of ventricular arrhythmias and myocardial function in Lamin A/C mutation positive subjects. *Europace* 2014;16(4):563–71.
- [62] Holmström M, Kivistö S, Heliö T, Jurkko R, Kaartinen M, Antila M, et al. Description of A/C gene mutation related dilated cardiomyopathy with gadolinium-enhanced magnetic resonance imaging. *J Cardiovasc Magn Reson* 2011;13(S1):30.
- [63] Raman S V, Sparks EA, Baker PM, McCarthy B, Wooley CF. Mid-myocardial fibrosis by cardiac magnetic resonance in patients with lamin A/C cardiomyopathy: possible substrate for diastolic dysfunction. *J Cardiovasc Magn Reson* 2007;9(6):907–13.
- [64] Kumar S, Androulakis AFA, Sellal JM, Maury P, Gandjbakhch E, Waintraub X, et al. Multicenter experience with catheter ablation for ventricular tachycardia in Lamin A/C cardiomyopathy. *Circ Arrhythmia Electrophysiol* 2016;9(8):e004357.
- [65] Hof IE, van der Heijden JF, Kranias EG, Sanoudou D, de Boer RA, van Tintelen JP, et al. Prevalence and cardiac phenotype of patients with a phospholamban mutation. *Neth Heart J* 2018;27(2):64–9.
- [66] Posch MG, Perrot A, Geier C, Boldt LH, Schmidt G, Lehmkühl HB, et al. Genetic deletion of arginine 14 in phospholamban causes dilated cardiomyopathy with attenuated electrocardiographic R amplitudes. *Heart Rhythm* 2009;6(4):480–6.
- [67] Te Rijdt WP, Ten Sande JN, Gorter TM, van der Zwaag PA, van Rijsingen IA, Boekholdt SM, et al. Myocardial fibrosis as an early feature in phospholamban p.Arg14del mutation carriers: phenotypic insights from cardiovascular magnetic resonance imaging. *Eur Heart J Cardiovasc Imaging* 2019;20(1):92–100.
- [68] Cho JMIH, van Es R, Stathonikos N, Harakalova M, Te Rijdt WP, Suurmeijer AJH, et al. High resolution systematic digital histological quantification of cardiac fibrosis and adipose tissue in phospholamban p.Arg14del mutation associated cardiomyopathy. *PLoS ONE* 2014;9(4):e94820.
- [69] te Rijdt WP, van Tintelen JP, Vink A, van der Wal AC, de Boer RA, van den Berg MP, et al. Phospholamban p.Arg14del cardiomyopathy is characterized by phospholamban aggregates, aggregates, and autophagic degradation. *Histopathology* 2016;69(4):542–50.
- [70] Sepehrkhoy S, Gho JMIH, van Es R, Harakalova M, de Jonge N, Dooijes D, et al. Distinct fibrosis pattern in desmosomal and phospholamban mutation carriers in hereditary cardiomyopathies. *Heart Rhythm* 2017;14(7):1024–32.
- [71] Liu G, Ma C, Yang H, Zhang PY. Transforming growth factor β and its role in heart disease. *Exp Ther Med* 2017;13(5):2123–8.
- [72] Nguyen DT, Ding C, Wilson E, Marcus GM, Olgin JE. Pirfenidone mitigates left ventricular fibrosis and dysfunction after myocardial infarction and reduces arrhythmias. *Heart Rhythm* 2010;7(10):1438–45.
- [73] Martin J, Kelly DJ, Mifsud SA, Zhang Y, Cox AJ, See F, et al. Tranilast attenuates cardiac matrix deposition in experimental diabetes: role of transforming growth factor- β . *Cardiovasc Res* 2005;65(3):694–701.
- [74] Engebretsen KVT, Skårdal K, Bjørnstad S, Marstein HS, Skrbic B, Sjaastad I, et al. Attenuated development of cardiac fibrosis in left ventricular pressure overload by SM16, an orally active inhibitor of ALK5. *J Mol Cell Cardiol* 2014;76:148–57.
- [75] Te Riet L, Van Esch JHM, Roks AJM, Van Den Meiracker AH, Danser AHJ. Hypertension: renin-Angiotensin-Aldosterone system alterations. *Circ Res* 2015;116(6):960–75.
- [76] Zhi H, Luptak I, Alreja G, Shi J, Guan J, Metes-Kosik N, et al. Effects of direct renin inhibition on myocardial fibrosis and cardiac fibroblast function. *PLoS ONE* 2013;8(12):e81612.
- [77] Abareshi A, Norouzi F, Asgharzadeh F, Beheshti F, Hosseini M, Farzadnia M, et al. Effect of angiotensin-converting enzyme inhibitor on cardiac fibrosis and oxidative stress status in lipopolysaccharide-induced inflammation model in rats. *Int J Prev Med* 2017;8(1):69.
- [78] Wu L, Iwai M, Nakagami H, Chen R, Suzuki J, Akishita M, et al. Angiotensin II type 1 receptor blockade prevents cardiac remodeling in Bradykinin B 2 receptor knockout Mice. *Arterioscler Thromb Vasc Biol* 2002;22:49–54.
- [79] Shibasaki Y, Nishiue T, Masaki H, Tamura K, Matsumoto N, Mori Y, et al. Impact of the angiotensin II receptor antagonist, losartan, on myocardial fibrosis in patients with end-stage renal disease: assessment by ultrasonic integrated backscatter and biochemical markers. *Hypertens Res* 2005;28(10):787–95.
- [80] Brilla CG, Matsubara LS, Weber KT. Antifibrotic effects of spironolactone in preventing myocardial fibrosis in systemic arterial hypertension. *Am J Cardiol* 1993;71(3):12A–16A.
- [81] Doltra A, Dietrich T, Schneeweis C, Kelle S, Doltra A, Stawowy P, et al. Magnetic resonance imaging of cardiovascular fibrosis and inflammation: from clinical practice to animal studies and back cardiovascular MRI view project magnetic resonance imaging of cardiovascular fibrosis and inflammation: from clinical practice to ANI. *Biomed Res Int* 2013;2013:676489.
- [82] Ismail TF, Jabbour A, Gulati A, Mallorie A, Raza S, Cowling TE, et al. Role of late gadolinium enhancement cardiovascular magnetic resonance in the risk stratification of hypertrophic cardiomyopathy. *Heart* 2014;100(23):1851–8.
- [83] Waterhouse DF, Ismail TF, Prasad SK, Wilson MG, O'Hanlon R. Imaging focal and interstitial fibrosis with cardiovascular magnetic resonance in athletes with left ventricular hypertrophy: implications for sporting participation. *Br J Sports Med* 2012;46(SUPPL. 1):69–77.
- [84] Rogucka ZS, Majos A. Left ventricular non-compaction: mid-myocardial distribution of late gadolinium enhancement in compacted segments. *Omi J Radiol* 2017;06(01):246.