

University of Groningen

Late-Onset Stargardt Disease Due to Mild, Deep-Intronic ABCA4 Alleles

Runhart, Esmee H.; Valkenburg, Dyon; Cornelis, Stephanie S.; Khan, Mubeen; Sangermano, Riccardo; Albert, Silvia; Bax, Nathalie M.; Astuti, Galuh D. N.; Gilissen, Christian; Pott, Jan-Willem R.

Published in:
Investigative ophthalmology & visual science

DOI:
[10.1167/iovs.19-27524](https://doi.org/10.1167/iovs.19-27524)

IMPORTANT NOTE: You are advised to consult the publisher's version (publisher's PDF) if you wish to cite from it. Please check the document version below.

Document Version
Publisher's PDF, also known as Version of record

Publication date:
2019

[Link to publication in University of Groningen/UMCG research database](#)

Citation for published version (APA):

Runhart, E. H., Valkenburg, D., Cornelis, S. S., Khan, M., Sangermano, R., Albert, S., Bax, N. M., Astuti, G. D. N., Gilissen, C., Pott, J-W. R., Verheij, J. B. G. M., Blokland, E. A. W., Cremers, F. P. M., van den Born, L. I., & Hoyng, C. B. (2019). Late-Onset Stargardt Disease Due to Mild, Deep-Intronic ABCA4 Alleles. *Investigative ophthalmology & visual science*, 60(13), 4249-4256. <https://doi.org/10.1167/iovs.19-27524>

Copyright

Other than for strictly personal use, it is not permitted to download or to forward/distribute the text or part of it without the consent of the author(s) and/or copyright holder(s), unless the work is under an open content license (like Creative Commons).

The publication may also be distributed here under the terms of Article 25fa of the Dutch Copyright Act, indicated by the "Taverne" license. More information can be found on the University of Groningen website: <https://www.rug.nl/library/open-access/self-archiving-pure/taverne-amendment>.

Take-down policy

If you believe that this document breaches copyright please contact us providing details, and we will remove access to the work immediately and investigate your claim.

Downloaded from the University of Groningen/UMCG research database (Pure): <http://www.rug.nl/research/portal>. For technical reasons the number of authors shown on this cover page is limited to 10 maximum.

Late-Onset Stargardt Disease Due to Mild, Deep-Intronic *ABCA4* Alleles

Esmee H. Runhart,^{1,2} Dyon Valkenburg,^{1,2} Stéphanie S. Cornelis,^{2,3} Mubeen Khan,^{2,3} Riccardo Sangermano,^{3,4} Silvia Albert,^{2,3} Nathalie M. Bax,^{1,2} Galuh D. N. Astuti,^{3,5} Christian Gilissen,^{2,3} Jan-Willem R. Pott,⁶ Joke B. G. M. Verheij,⁷ Ellen A. W. Blokland,³ Frans P. M. Cremers,^{2,3} L. Ingeborgh van den Born,⁸ and Carel B. Hoyng^{1,2}

¹Department of Ophthalmology, Radboud University Medical Center, Nijmegen, The Netherlands

²Donders Institute for Brain, Cognition and Behaviour, Radboud University Medical Center, Nijmegen, The Netherlands

³Department of Human Genetics, Radboud University Medical Center, Nijmegen, The Netherlands

⁴Ocular Genomics Institute, Massachusetts Eye and Ear Infirmary, Boston, Massachusetts, United States

⁵Division of Human Genetics, Center for Biomedical Research, Faculty of Medicine, Diponegoro University, Semarang, Indonesia

⁶Department of Ophthalmology, University Medical Center Groningen, University of Groningen, Groningen, The Netherlands

⁷Department of Medical Genetics, University Medical Center Groningen, University of Groningen, Groningen, The Netherlands

⁸The Rotterdam Eye Hospital, Rotterdam, The Netherlands

Correspondence: Carel B. Hoyng, Department of Ophthalmology (400), Radboud University Medical Center, P.O. Box 9101, 6500 HB Nijmegen, The Netherlands; carel.hoyng@radboudumc.nl.

FPMC, LlvDB, and CBH are joint senior authors.

Submitted: May 15, 2019

Accepted: September 6, 2019

Citation: Runhart EH, Valkenburg D, Cornelis SS, et al. Late-onset Stargardt disease due to mild, deep-intronic *ABCA4* alleles. *Invest Ophthalmol Vis Sci.* 2019;60:4249–4256. <https://doi.org/10.1167/iovs.19-27524>

PURPOSE. To investigate the role of two deep-intronic *ABCA4* variants, that showed a mild splice defect in vitro and can occur on the same allele as the low penetrant c.5603A>T, in Stargardt disease (STGD1).

METHODS. Ophthalmic data were assessed of 18 STGD1 patients who harbored c.769-784C>T or c.4253+43G>A in combination with a severe *ABCA4* variant. Subjects carrying c.[769-784C>T; 5603A>T] were clinically compared with a STGD1 cohort previously published carrying c.5603A>T noncomplex. We calculated the penetrances of the intronic variants using *ABCA4* allele frequency data of the general population and investigated the effect of c.769-784C>T on splicing in photoreceptor progenitor cells (PPCs).

RESULTS. Mostly, late-onset, foveal-sparing STGD1 was observed among subjects harboring c.769-784C>T or c.4253+43G>A (median age of onset, 54.5 and 52.0 years, respectively). However, ages of onset, phenotypes in fundus, and visual acuity courses varied widely. No significant clinical differences were observed between the c.[769-784C>T; 5603A>T] cohort and the c.4253+43G>A or the c.5603A>T cohort. The penetrances of c.769-784C>T (20.5%–39.6%) and c.4253+43G>A (35.8%–43.1%) were reduced, when not considering the effect of yet unidentified or known factors in *cis*, such as c.5603A>T (identified in 7/7 probands with c.769-784C>T; 1/8 probands with c.4253+43G>A). Variant c.769-784C>T resulted in a pseudo-exon insertion in 15% of the total mRNA (i.e., ~30% of the c.769-784C>T allele alone).

CONCLUSIONS. Two mild intronic *ABCA4* variants could further explain missing heritability in late-onset STGD1, distinguishing it from AMD. The observed clinical variability and calculated reduced penetrance urge research into modifiers within and outside of the *ABCA4* gene.

Keywords: Stargardt disease, *ABCA4*, disease expression, penetrance, differential diagnosis

Stargardt disease (STGD1 [Mendelian Inheritance in Man: 248200]) is typically characterized by rapid visual acuity (VA) decline in childhood or early adulthood, and by yellow-white pisciform flecks throughout the posterior pole and macular atrophy on funduscopy.^{1,2} We previously described a cohort of patients with late-onset STGD1, which was characterized by slowly progressive sharply demarcated retinal pigment epithelium (RPE) atrophy in a foveal-sparing pattern.^{3–5} However, the diagnosis of late-onset STGD1 remained questionable due to unidentified disease-causing *ABCA4* alleles, and phenotypic overlap with other macular diseases, the most frequent of which is AMD.⁶

Recently, a large part of the missing heritability of late-onset STGD1 was elucidated by the frequent *ABCA4* coding variant

c.5603A>T (p.Asn1868Ile), which was found to cause STGD1 only when present in combination with a deleterious mutation.⁷ Interestingly, this mild variant was associated with an exceptional clinical variability.⁸ Moreover, this variant clearly showed reduced penetrance in the Dutch population (~5%), that is, the vast majority of individuals carrying c.5603A>T in *trans* with (i.e., positioned on the other allele as) a severe variant do not manifest STGD1.^{8–10} Reduced penetrance has rarely been reported in autosomal-recessive retinal diseases.^{11–13} Occurrence of this phenomenon has major implications for genetic counseling and future directions for research into modifying factors, which could result in targets for therapeutics.



Very recently, we identified eight deep-intronic variants among 67% of genetically unsolved STGD1 patients.¹⁴ The two most frequently identified variants, c.769-784C>T and c.4253+43G>A, only showed a partial splice defect in vitro. Variant c.769-784C>T strengthened a cryptic splice site at a noncanonical nucleotide position resulting in pseudo-exon inclusion. As this c.769-784C>T variant was consistently found in *cis* with (i.e., positioned on the same allele as) the mild c.5603A>T variant, its causal role could not be fully established yet. Variant c.4253+43G>A disrupted predicted splice silencers and created an exonic splicing enhancer leading to partial skipping of exon 28. Like c.5603A>T, variant c.4253+43G>A was associated with late-onset STGD1 and found to be phenotypically expressed only when in *trans* with a severe variant.¹⁵

In this study, we investigate the phenotypic characteristics associated with deep-intronic *ABCA4* variants c.769-784C>T and c.4253+43G>A, and clinically compared these patients with our previously described patient cohort carrying c.5603A>T without variants in *cis*. Furthermore, we aim to strengthen the observation that c.769-784C>T has an effect on splicing, and to assess the penetrance of both intronic variants. This information is paramount for the differential diagnostics of late-onset STGD1 and to discern this disease from AMD.

METHODS

Subjects

Participants originated from the population of STGD1 patients in ophthalmic centers in The Netherlands participating in the RD5000 study group.¹⁶ Fifteen genetically unexplained probands and three affected siblings in whom the c.768-784C>T variant or the c.4253+43G>A variant was found as the second allele, after HaloPlex-based (Agilent, Santa Clara, CA, USA) sequencing and segregation analysis by Sangermano et al.,¹⁴ were identified. All records were reviewed retrospectively. Additionally, skin biopsies were collected from a STGD1 patient harboring c.769-784C>T and a control individual, and splice assays were performed in photoreceptor progenitor cells (PPCs). Ultimately, we performed penetrance calculations employing *ABCA4* allele frequency data of one European and two Dutch population databases.

All procedures were approved by the Medical Ethics Committee of Erasmus Medical Center (MEC-2010-359). Informed consent was obtained after explanation of the study, and the study adhered to the tenets of the Declaration of Helsinki.

Clinical Evaluation

Clinical data collected from medical records included age of onset and initial symptoms, age at diagnosis, best-corrected VA, findings on ophthalmoscopy, retinal imaging, and full-field (ff) ERG. We examined available fundus photography, fundus autofluorescence (FAF) imaging (using a confocal scanning laser ophthalmoscope; Spectralis; Heidelberg Engineering, Heidelberg, Germany), spectral domain-optical coherence tomography (OCT; Spectralis or Cirrus; Carl Zeiss Meditec, Inc., Dublin, CA, USA), and fERG acquired according to the International Society for Clinical Electrophysiology of Vision standards.¹⁷ We assessed the presence of foveal sparing, which we defined as RPE atrophy encircling a structurally and functionally (VA \geq 20/200 Snellen) preserved fovea by 180° or more, by evaluation of FAF and/or OCT.⁴ The previously described definition 'definitely decreased autofluorescence' was used in the assessment of FAF.¹⁸

Age of onset was defined as the age at which the patient first experienced visual complaints. In asymptomatic subjects or in case age at onset was not reported, we used the age at which decrease in VA was first documented or the age at which macular abnormalities were first diagnosed. Age of onset was compared across patient groups with different *ABCA4* genotypes, using Mann-Whitney *U* tests for independent samples. A *P* value < 0.05 was considered statistically significant.

We performed Kaplan-Meier survival analysis to determine the median survival time to develop severe visual impairment, defined as a VA of less than 20/200 Snellen (decimal, 0.10) in accordance with the International Classification of Diseases, 11th revision.¹⁹ Patients were censored if the time interval between the first measurement of severe visual impairment and the prior visit was more than 5 years, and patients were excluded if VA was available at only one time point and already was less than 20/200 Snellen. Additionally, we investigated whether c.769-784C>T has an additive effect on disease severity compared with the c.5603A>T variant alone by including age at onset and VA data of a previously described cohort of STGD1 patients carrying the noncomplex c.5603A>T variant.⁸

Assessment of RNA Splice Defects in Photoreceptor Progenitor Cells

To determine whether deep-intronic variant c.769-784C>T results in aberrant splicing of *ABCA4* pre-mRNA, fibroblasts of a patient and a control were reprogrammed into induced pluripotent stem cells and differentiated into PPCs as previously described.²⁰ All differentiations were performed in duplicate. RT-PCR was performed using *ABCA4* exonic primers located in *ABCA4* exon 6 and 8. Gel resolution, excision, and purification of the bands of RT-PCR products, and Sanger sequencing were performed as described elsewhere.²⁰ Details of RT-PCR primers are given in Supplementary Table S1.

To determine the fraction of correctly spliced product, densitometric analysis was performed using ImageJ software (<http://imagej.nih.gov/ij/>; provided in the public domain by the National Institutes of Health, Bethesda, MD, USA).²¹ The analysis was performed in duplicate, and values were normalized for the size of the different fragments present in each RT-PCR product mixture.

Penetrance Calculations

We assessed the penetrance of c.769-784C>T and c.4253+43G>A, when present in *trans* with a severe *ABCA4* variant, by comparing the observed number of patients carrying this combination of variants with the expected number of patients.

The expected number of patients was calculated based on *ABCA4* allele frequency data of the general population, as previously described.^{8,10} The cumulative frequency of severe *ABCA4* alleles was 0.00195, determined in our in-house whole-exome sequencing dataset, containing data of 21,559 individuals.¹⁰ We investigated the minor allele frequency (MAF) of the intronic variants of interest in the non-Finnish European (nFE) population in the Genome Aggregation Database (gnomAD),^{22,23} and the Dutch population in the Genome of The Netherlands database (GoNL).^{24,25} The median age at diagnosis in the study cohort of interest (i.e., c.769-784C>T or c.4253+43G>A carriers) served as a cut-off value to determine the number of individuals in The Netherlands at risk for disease due to both genotype and age.²⁶

The observed number of patients carrying the intronic variant of interest in The Netherlands could be extrapolated

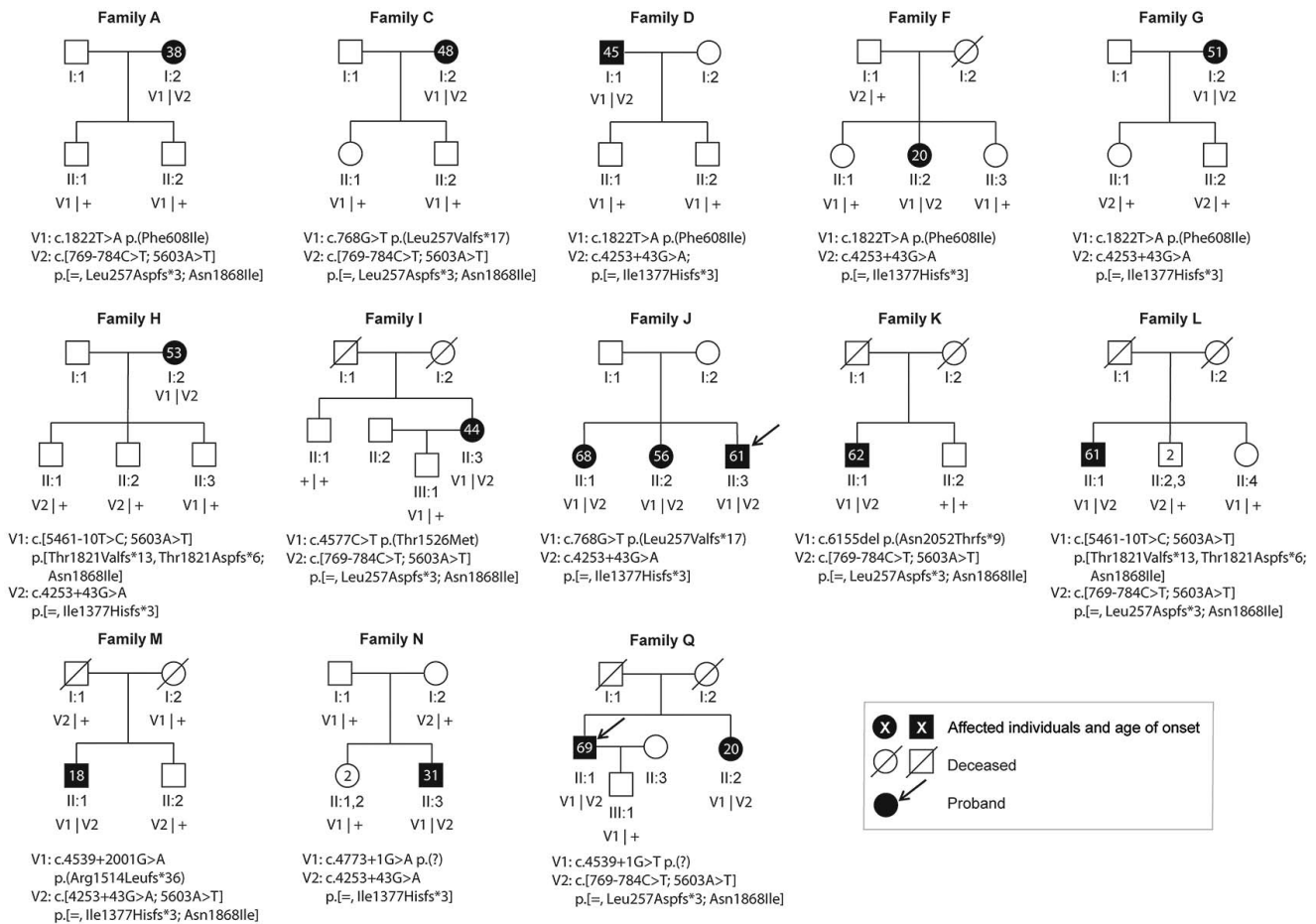


FIGURE 1. Genetic data and age of onset. Pedigrees, genotype, and age at onset of all patients for whom segregation analysis has been performed. Patient identifiers correspond with our previous genetic study in the genetically unexplained Stargardt cohort.¹⁴

given the proportion of patients harboring the intronic variant of interest at Radboud University Medical Center, the estimated STGD1 prevalence of 1 in 10,000 individuals,²⁷ and the total Dutch population.²⁶

RESULTS

Genetic Characteristics

A total of 15 probands was included in this study, and in 13 probands, the *trans* configuration of the identified *ABCA4* variants was confirmed (i.e., variants positioned on different alleles; Fig. 1). In families S and R, DNA of relatives was not available. Seven probands and one affected sibling harbored c.[769-784C>T; 5603A>T] in *trans* with a severe *ABCA4* variant. Eight probands and two affected siblings harbored c.4253+43G>A in *trans* with a severe *ABCA4* variant. One proband (M-II:1) also carried c.5603A>T on the same allele as c.4253+43G>A.

Clinical Characteristics

Detailed clinical characteristics of all subjects are displayed in Supplementary Table S2. Patients presented with decreased VA, central scotoma, and/or distorted vision, and one patient was asymptomatic. Patients harboring c.[769-784C>T; 5603A>T] reported a median age at onset of 54.5 (range, 20–69) years. This did not significantly differ from the age of

onset among 33 patients carrying the noncomplex c.5603A>T variant previously reported, of whom the median was 41 (range, 18–72) years⁵ (Mann-Whitney *U*: *P* = 0.146, Supplementary Fig. S1). Patients harboring c.4253+43G>A had a median age at onset of 52.0 (range, 20–68) years, while the single patient who carried c.[4253+43G>A; 5603A>T] had the youngest age at onset of 18 years.

Patients harboring c.[769-784C>T; 5603A>T] mainly manifested late-onset STGD1 characterized by pisciform yellow-white flecks throughout the posterior pole and midperiphery on funduscopy, appearing hyperautofluorescent on FAF, and sharply demarcated RPE atrophy in the macula on FAF, corresponding to loss of the outer retinal layers from the outer plexiform layer to the RPE on OCT, in a foveal-sparing pattern (Fig. 2A).

One patient, sibling Q-II:2, had a discordant onset: Q-II:2 already reported initial symptoms at the age of 20 years. Funduscopy showed an abnormal foveal reflex with surrounding hypopigmented lesions and yellow flecks at the age of 23, with a VA of 20/63 in the right eye and 20/100 in the left eye (Supplementary Fig. S2). Over the years, macular lesions of RPE atrophy extended, surrounded by yellow-white flecks throughout the posterior pole and midperiphery. During triennial follow-up, VA gradually declined and reached 20/200 in the left eye at the age of 26 years but not in the right eye until the age of 39 years. In striking contrast, the brother, Q-II:1, had an age at onset of 69 years and fundus features in accordance with the characteristic findings of the group. The VA first reached 20/200 in the right eye at the age of 75, while

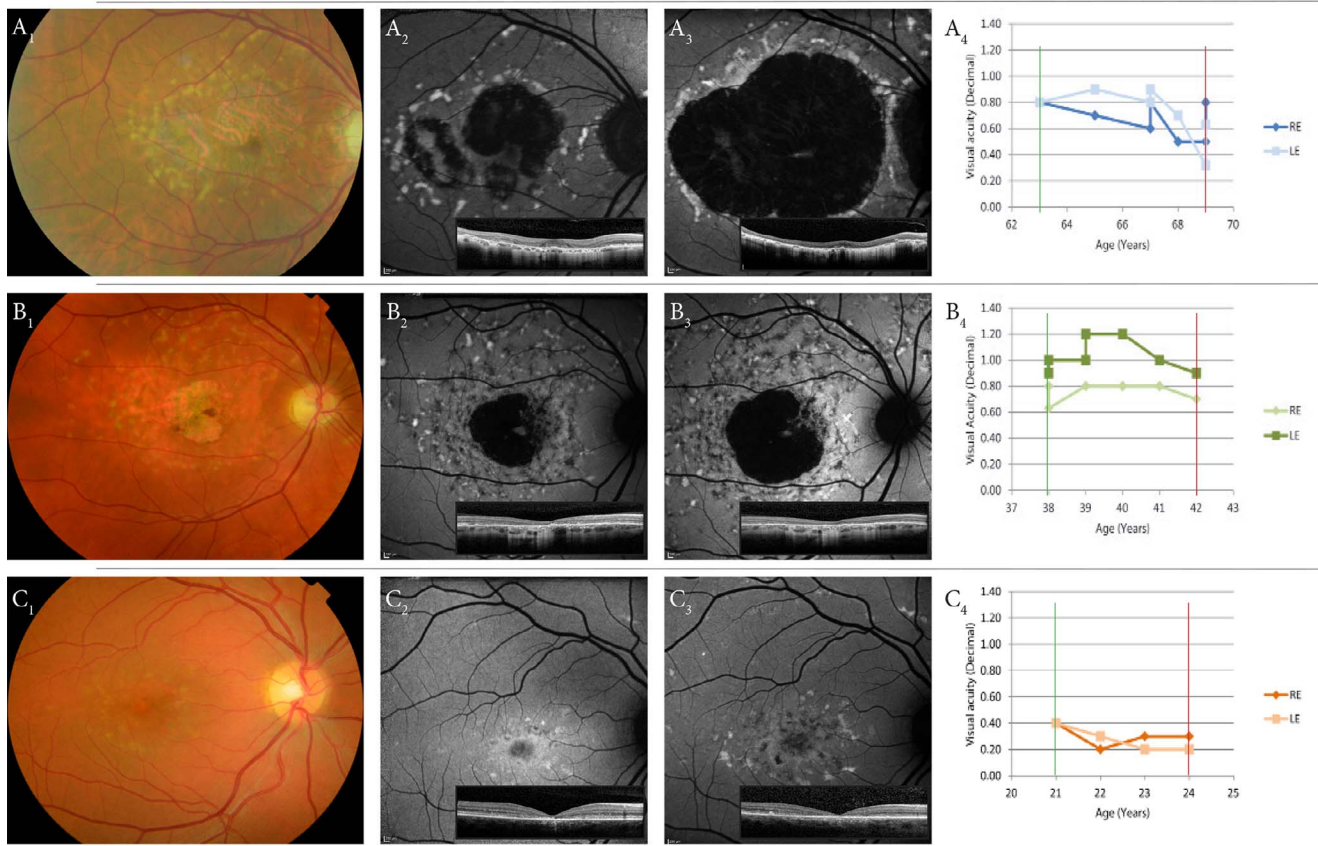


FIGURE 2. Fundus imaging follow-up and visual acuity decline of three subjects who harbor different *ABCA4* variants. The vertical lines represent the moments that the FAF images of the right eyes were acquired. (A) Fundus photography (A1) and FAF of patient L-II:1 at the age of 63 (A2) and 69 years (A3). VA remained stable at 20/25 Snellen (0.8 decimal) (A4). This patient harbored c.[769-784C>T; 5603A>T] in *trans* with c.768G>T. (B) Fundus photography (B1) and FAF of patient N-II:3 at the age of 38 (B2) and 42 years (B3), when VA was 20/25 (0.8) and 20/28 (0.7), respectively (B4). This patient harbored c.4253+43G>A in *trans* with c.4773+1G>A. (C) Fundus photography (C1) and FAF of patient M-II:1 at the age of 21 (C2) and 24 years (C3), when VA was 20/50 (0.4) and 20/60 (0.3), respectively (C4). The patient harbored c.[4253+43G>A; 5603A>T] in *trans* with c.4539+2001G>A.

VA in the left eye still was 20/100 at the last visit, at age 78 years (Supplementary Fig. S2).

Patients harboring c.4253+43G>A also mainly manifested the characteristic late-onset STGD1 features. Six patients (H-I:2, J-II:1, J-II:2, J-II:3, N-II:3, and R-II:3; age of onset 53, 68, 56, 61, 31, and 52 years, respectively) showed foveal sparing up to the latest visit at age 63, 71, 75, 71, 42, and 68 years, respectively

(Fig. 2B). Yet, three patients (D-I:1, F-II:2, G-I:2) showed fewer and smaller flecks, mostly confined to the macula, and did not exhibit the typical foveal sparing atrophy. Instead, FAF of patient D-I:1 and G-I:2 showed mottled decreased autofluorescence in the macula accompanied by one parafoveal, over the years expanding, sharply demarcated atrophic lesion. Interestingly, patient D-I:1 showed distinct intereye discordance in

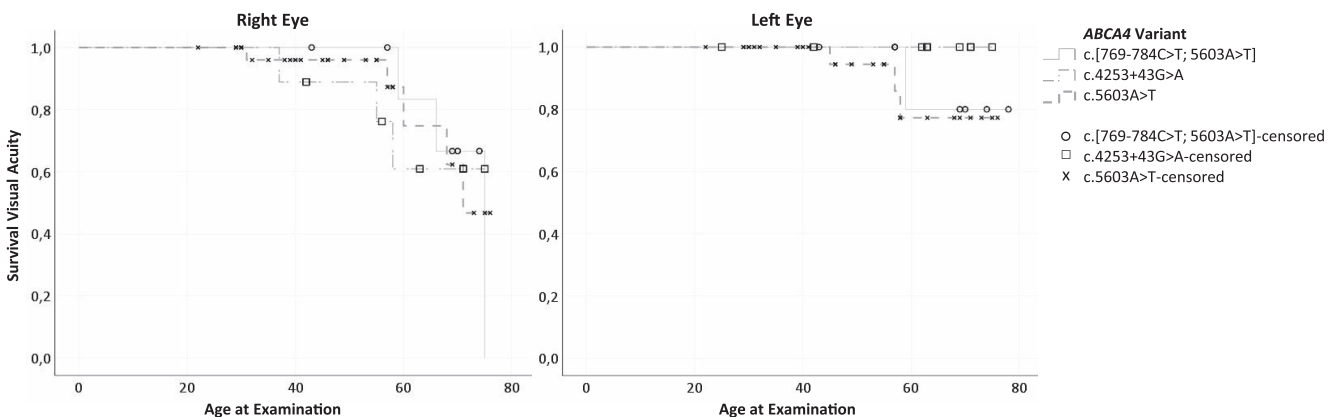


FIGURE 3. Visual acuity survival. Kaplan-Meier survival plots for the time to reach severe visual impairment of patients carrying either of the two intronic variants or the noncomplex c.5603A>T.

TABLE. Penetrance Calculations for *ABCA4* Variants c.769-784C>T and c.4253+43G>A When in *Trans* With a Severe *ABCA4* Variant, Not Taking Cis Variants Into Account

	c.769-784C>T	c.4253+43G>A
Observed number of patients		
Proportion of STGD1 cases carrying severe variant and intronic variant of interest	0.0167	0.0267
Number of STGD1 cases with severe variant and intronic variant of interest in the NL*	29	46
Expected number of patients		
Cumulative allele frequency of <i>ABCA4</i> protein-truncating, canonical splice-site variants, and severe noncanonical splice site variants in the NL† (p)	0.001953	0.001953
Allele frequencies of intronic variant of interest (q)		
nFE gnomAD	0.004147	0.006030
GoNL	0.008016	0.005010
Frequencies of individuals with severe variant and intronic variant of interest (2pq)		
Based on q nFE gnomAD	0.00001620	0.00002335
Based on q GoNL	0.00003131	0.00001957
Number of STGD1 cases with severe variant and the intronic variant of interest in the NL older than the median age at diagnosis‡		
Based on q nFE gnomAD	72	128
Based on q GoNL	139	106
Penetrance		
Penetrance of a severe variant with the intronic variant (observed/expected number of patients)		
Based on q nFE gnomAD	39.6%	35.8%
Based on q GoNL	20.5%	43.1%

NL, population of The Netherlands

* Conservatively assuming STGD1 prevalence in The Netherlands to be 1:10,000. Total Dutch population: 17,150,000.

† Based on in vitro splice assays of noncanonical splice-site variants.³⁵

‡ Median age at diagnosis in the c.769-784C>T cohort and the c.4253+43G>A cohort was 59 and 55 years, respectively.

fundoscopic features and the VA course (Supplementary Figs. S2 and S3). At the age of 56, the right eye showed progressed disease with a large macular lesion of definitely decreased autofluorescence and RPE atrophy, whereas no RPE atrophy was observed in the left eye during annual follow-up until the age of 61.

Patient F-II:2 had a much younger age at onset of 20 years and a rapid VA decline already at the age of 24 years. This patient initially manifested central RPE alterations and peri-foveal small yellow flecks. Over the years, flecks enlarged and spread across the posterior pole, and beaten bronze macular atrophy corresponding to mottled decreased autofluorescence appeared (Supplementary Fig. S3).

Patient M-II:1, the single patient who harbored c.4253+43G>A in *cis* with c.5603A>T showed flecks mostly confined to the macula, macular mottled decreased autofluorescence, and macular loss of the outer nuclear layer and ellipsoid zone at the age of 21, 3 years after the initial symptom of VA loss (Fig. 2C). At the age of 24, VA in the right and left eye had already declined to 20/66 and 20/100, respectively.

Results of fERG were abnormal in only two of nine patients in whom fERG had been performed. Patients A-I:2 and H-I:2 had severely reduced responses under light-adapted conditions and moderately reduced responses under dark-adapted conditions at the age of 56 and 60 years, respectively.

Two patients had ocular comorbidity. Patient S-II:1 had mild nonproliferative diabetic retinopathy and an amblyopic right eye. Over a decade after onset of STGD1, patient D-I:1 suffered from a central retinal vein occlusion in the right eye and a hemiretinal vein occlusion in the left eye.

The VA courses of all eyes are depicted in Supplementary Figure S2. Patients carrying c.[769-784C>T; 5603A>T] had a median VA at the latest visit, at a median disease duration of 14 (range, 8–28) years, of 20/180 (decimal, 0.11; range, 0.05–1.0) in the right eye and 20/125 (0.16; range, 0.05–0.63) in the left eye. Patients carrying c.4253+43G>A had a median VA at the

latest visit, at a median disease duration of 11 (range, 3–25) years, of 20/125 (0.16; range, 0.03–1.0) in the right and 20/25 (0.8; range, 0.05–1.0) in the left eye.

Survival analysis of the time to severe visual impairment of patients in this study and patients carrying the noncomplex c.5603A>T in our STGD1 cohort showed comparable survival times across groups, as depicted in Figure 3. Mean VA survival times for patients carrying c.[769-784C>T; 5603A>T] versus patients carrying the noncomplex c.5603A>T allele were 71 versus 69 years in the right eye, and 74 versus 71 years in the left eye, respectively. Mean survival time for right eyes of c.4253+43G>A carriers was 66 years. All left eyes were censored before reaching VA<20/200, at a median age of 63 (range, 25–71) years.

Splice Defect Due to c.769-784C>T in Patient-Derived Photoreceptor Progenitor Cells

RT-PCR was performed in PPCs derived from subject A-I:2. In the patient's PPCs treated with cycloheximide, which blocks nonsense-mediated decay of mRNA, gel analysis and Sanger sequencing revealed a band of 327 nucleotides, corresponding to the correct transcript, and another band of 489 nucleotides, corresponding to a 162-nucleotides pseudo-exon insertion (Supplementary Figs. S4 and S5). The pseudo-exon fragment accounted for 15% of the total mRNA (Supplementary Table S3).

Reduced Penetrance of c.769-784C>T and c.4253+43G>A When Not Taking Into Account Variants in *Cis*

The 'observed' number of STGD1 cases who harbor either c.769-784C>T or c.4253+43G>A in combination with a severe *ABCA4* variant in The Netherlands was extrapolated to be 29 and 46, respectively (Table).

The 'expected' number of patients carrying c.769-784C>T in combination with a severe variant was 72, based on the nFE MAF of c.769-784C>T of 0.00415. Based on the 2-fold higher Dutch MAF of c.769-784C>T (0.00802), 139 individuals were expected to be at risk for disease due to the *ABCA4* variants they harbor and their age (higher than median age at diagnosis in patient cohort).

For c.4253+43G>A, the 'expected' number of patients was 128, based on a nFE MAF of c.4253+43G>A of 0.00603. Based on a slightly different Dutch MAF of c.4253+43G>A of 0.00501, 106 individuals were expected to be at risk.

For c.769-784C>T and c.4253+43G>A in *trans* with a severe *ABCA4* variant, comparison of the expected numbers of patients with the observed number of patients in The Netherlands resulted in an estimated penetrance of 20.5% (Dutch MAF) to 39.6% (nFE MAF) and 35.8% (nFE MAF) to 43.1% (Dutch MAF), respectively.

DISCUSSION

Following the common c.5603A>T coding variant,^{7,8} two recently discovered frequent deep-intronic *ABCA4* variants could further explain the missing heritability in late-onset STGD1.^{14,15} The majority of the subjects in this study manifested late-onset STGD1 (72%) characterized by pisciform flecks throughout the posterior pole and midperiphery, and macular sharply demarcated RPE atrophy—if present at all—in a foveal-sparing pattern. No significant differences with respect to phenotypic features and VA course were observed between the c.769-784C>T and the c.4253+43G>A cohort.

The identification of the second disease-causing *ABCA4* allele in an increasing number of patients with late-onset STGD1 undeniably anchors the described phenotype in the spectrum of *ABCA4* disease. Still, patients are initially misdiagnosed with AMD on a regular basis. Important phenotypic differential diagnostic findings in late-onset STGD1 are the flecks, which, compared with drusen, are more irregularly shaped, often more intensely hyperautofluorescent on FAF images, often but not always more diffusely spread across the posterior pole and midperiphery²⁸ and correspond to hyperreflective depositions traversing photoreceptor-attributable bands on OCT.²⁹ Also, in contrast to AMD, STGD1 is only very rarely complicated by a neovascularization.^{30,31} The correct clinical diagnosis and the identification of underlying genetic variants have become paramount with emerging therapies for both STGD1 and geographic atrophy in AMD, not only for proper patient selection for trials, but also for the identification of therapeutic targets. In fact, both c.769-784C>T and c.4253+43G>A *ABCA4* variants were already shown to be targets for partial splice correction by antisense oligonucleotides.¹⁴

Although most subjects exhibited characteristic late-onset STGD1 features, we observed notable clinical variability among subjects carrying the same combination of an intronic and a severe *ABCA4* variant, even among siblings (family Q) and within subjects (D-I:1). Both the c.[769-784C>T; 5603A>T] and c.4253+43G>A cohort had a large range in age of onset, and VA courses varied widely. No comorbidities nor other factors were perceived that might explain the clinical variability. These results suggest that factors outside *ABCA4* may modify the disease course. A few studies indicated that the activation of the complement cascade could play a role in the pathogenesis of STGD1.^{32,33} Parallel to the complement cascade, other overlapping disease-modifying factors might act in late-onset STGD1 and AMD.

RNA analysis in patient-derived PPCs showed that c.769-784C>T results in a pseudo-exon insertion in 15% of total

mRNA, compared with 8.6% in HEK293T cells assessed previously.¹⁴ As the other allele of this patient harbored a missense variant (p.Phe608Ile), which is not expected to affect mRNA stability, the 15% defective total mRNA is considered to result from a 30% defective mRNA transcript from the c.769-784C>T allele alone, assuming that the missense allele in *trans* is equally expressed. The RNA analysis in PPCs corroborated a mild effect of c.769-784C>T on splicing. A similar observation was made for variant c.4539+2028C>T, which led to a 345-nt pseudo-exon insertion in patient-derived PPCs in 15% of total mRNA and approximately 30% of mRNA derived from the allele carrying c.4539+2028C>T.²⁰ In contrast, no pseudo-exon insertion was found in fibroblasts of the same patient. These results strongly suggest that retina-specific splice factors play a role in the defects observed for both c.769-784C>T and c.4539+2028C>T.

Despite the enrichment of the complex c.[769-784C>T; 5603A>T] allele among patients versus controls¹⁴ and our splice assays that indicate that variant c.769-784C>T has an additive pathogenic effect, significant clinical differences between patients who harbor c.[769-784C>T; 5603A>T] versus patients only harboring c.5603A>T were not observed. In the genetic study, the age of onset among patients carrying c.[769-784C>T; 5603A>T] was higher than the age of onset of patients carrying the single c.5603A>T variant, but the other cohort was smaller and included patients from abroad.¹⁴ Variant c.4253+43G>A was found in *cis* with c.5603A>T in only one patient. Interestingly, this patient had a strikingly early age of onset (18 years), discordant phenotype in fundus and a relatively fast VA decline. These results suggest that variant c.5603A>T and other, yet unidentified, *cis* variants might influence the expression, and possibly the penetrance, of the *ABCA4* allele.

We calculated the penetrance of c.769-784C>T and c.4253+43G>A, when present in *trans* with a severe variant, and found that, respectively, 20.5% to 39.6% and 35.8% to 43.1% of the individuals carrying these *ABCA4* variants actually manifest STGD1. Other *ABCA4* variants on the same allele might well influence the penetrance. In fact, in this study cohort, variant c.769-784C>T was consistently found in *cis* with c.5603A>T, the mild variant for which we previously calculated an extremely low penetrance (~5%), and for which we consequently argued that yet unidentified factors explain its penetrance in patients.^{8,10} It is possible that c.5603A>T acts as a modifier that results in full penetrance of the complex c.[769-784C>T; 5603A>T] allele. As expected, we recently identified variant c.769-784C>T without c.5603A>T in two late-onset STGD1 cases in a large follow-up study (Khan M, Cremers FPM, unpublished observations, 2019). Further studies are needed to corroborate current findings and provide undeniable evidence of the pathogenicity of the c.769-784C>T variant.

This study has a few limitations, mainly due to the complexity of penetrance calculations discussed previously.^{8,10} Population differences in the prevalence of the variants of interest and severe variants influence the calculated penetrance. To minimize the risk of this sampling bias, we used and compared allele frequencies of the European and the Dutch population. Missense variants that might have a severe effect on *ABCA4* protein function were not included in the calculation of severe *ABCA4* variant frequency, which has most likely resulted in overestimation of the calculated penetrance.³⁴ Second, age of onset was defined as the age at which the patient first experienced visual complaints. Alternatively, if complaints were absent or not reported (in only 2 subjects), we used age at which decrease in VA was first documented or the age at which macular abnormalities were first diagnosed. To a larger degree, age of onset might be

influenced by recall bias and other patient-specific factors, such as daily activities, comorbidities, and location of lesions.

In conclusion, this study showed that intronic *ABCA4* variants resulting in a mild splice defect, in addition to the coding c.5603A>T variant, could genetically explain a large proportion of the late-onset STGD1 cases, which aids in the differential diagnosis of late-onset STGD1 and AMD. At the same time, these mild variants were associated with a notable clinical variability, which needs to be considered in the design of upcoming clinical trials. The results of the present study and our previous studies on c.5603A>T,^{8,10} indicating that *cis* variants, such as c.5603A>T, as well as factors outside *ABCA4* could modify the disease course, should be considered in family counseling and warrant further studies on STGD1 modifiers.

Acknowledgements

The authors thank the gnomAD and the groups that provided exome and genome variant data to this resource. A full list of contributing groups can be found in the public domain, at <http://gnomad.broadinstitute.org/about>. Also, the authors thank the members of the RD5000 consortium and M.A. Meester-Smoor for their contributions to facilitate this research (in the public domain, <http://www.rd5000.nl/>). Finally, this study made use of data generated by the Genome of The Netherlands Project.

Samples were contributed by LifeLines (in the public domain, <http://lifelines.nl/lifelines-research/general>), The Leiden Longevity Study (in the public domain, <http://www.healthy-ageing.nl/>; in the public domain, <http://www.langleven.net/>), The Netherlands Twin Registry (NTR: in the public domain, <http://www.tweelingenregister.org/>), The Rotterdam studies, (in the public domain, <http://www.erasmus-epidemiology.nl/rotterdamstudy/>), and the Genetic Research in Isolated Populations program (in the public domain, <http://www.epib.nl/research/geneticepi/research.html#gip>). The sequencing was carried out in collaboration with the Beijing Institute for Genomics (BGI).

Supported by grants from The Netherlands Organization for Scientific Research under award number 184021007, dated July 9, 2009 and made available as a Rainbow Project of the Biobanking and Biomolecular Research Infrastructure Netherlands (BBMRI-NL; Utrecht, The Netherlands), Retina UK, Grant GR591 (FPMC, SA, and MK; Buckingham, United Kingdom), a Fighting Blindness Ireland grant (FPMC, JF, and SR; Dublin, Ireland), the FP7-PEOPLE-2012-ITN programme EyeTN, agreement 317472 (FPMC; Tübingen, Germany), the Rotterdamse Stichting Blindenbelangen, the Stichting Blindenhulp, and the Stichting tot Verbetering van het Lot der Blinden (FPMC; Rotterdam; Den Haag; Hilversum, The Netherlands), and by the Landelijke Stichting voor Blinden en Slechtzienden, Macula Degeneratie fonds and the Stichting Blinden-Penning that contributed through Uitzicht 2016-12 (FPMC; Ede, The Netherlands). This work was also supported by the Foundation Fighting Blindness USA, Grant PPA-0517-0717-RAD (FPMC, SR, and CBH; Columbia, MD, USA).

Disclosure: **E.H. Runhart**, None; **D. Valkenburg**, None; **S.S. Cornelis**, None; **M. Khan**, None; **R. Sangermano**, None; **S. Albert**, None; **N.M. Bax**, None; **G.D.N. Astuti**, None; **C. Gilissen**, None; **J.-W.R. Pott**, None; **J.B.G.M. Verheij**, None; **E.A.W. Blokland**, None; **F.P.M. Cremers**, None; **L.I. van den Born**, None; **C.B. Hoyng**, None

References

- Stargardt KI. Über familiäre, progressive degeneration in der maculagedend des Auges [in German]. *Graefes Arch Clin Exp Ophthalmol*. 1909;71:534-550.
- Franceschetti A. A special form of tapetoretinal degeneration: fundus flavimaculatus. *Trans Am Acad Ophthalmol Otolaryngol*. 1965;69:1048-1053.
- Fujinami K, Sergouniotis PI, Davidson AE, et al. Clinical and molecular analysis of Stargardt disease with preserved foveal structure and function. *Am J Ophthalmol*. 2013;156:487-501.
- van Huet RA, Bax NM, Westeneng-Van Haaften SC, et al. Foveal sparing in Stargardt disease. *Invest Ophthalmol Vis Sci*. 2014;55:7467-7478.
- Westeneng-van Haaften SC, Boon CJ, Cremers FP, Hoefsloot LH, den Hollander AI, Hoyng CB. Clinical and genetic characteristics of late-onset Stargardt's disease. *Ophthalmology*. 2012;119:1199-1210.
- Fritsche LG, Fleckenstein M, Fiebig BS, et al. A subgroup of age-related macular degeneration is associated with mono-allelic sequence variants in the *ABCA4* gene. *Invest Ophthalmol Vis Sci*. 2012;53:2112-2118.
- Zernant J, Lee W, Collison FT, et al. Frequent hypomorphic alleles account for a significant fraction of *ABCA4* disease and distinguish it from age-related macular degeneration. *J Med Genet*. 2017;54:404-412.
- Runhart EH, Sangermano R, Cornelis SS, et al. The common *ABCA4* variant p.Asn1868Ile shows nonpenetrance and variable expression of Stargardt disease when present in trans with severe variants. *Invest Ophthalmol Vis Sci*. 2018;59:3220-3231.
- Allikmets R, Zernant J, Lee W. Penetrance of the *ABCA4* p.Asn1868Ile allele in Stargardt disease. *Invest Ophthalmol Vis Sci*. 2018;59:5564-5565.
- Cremers FPM, Cornelis SS, Runhart EH, Astuti GDN. Author response: penetrance of the *ABCA4* p.Asn1868Ile allele in Stargardt disease. *Invest Ophthalmol Vis Sci*. 2018;59:5566-5568.
- Estrada-Cuzcano A, Koenekoop RK, Senechal A, et al. BBS1 mutations in a wide spectrum of phenotypes ranging from nonsyndromic retinitis pigmentosa to Bardet-Biedl syndrome. *Arch Ophthalmol*. 2012;130:1425-1432.
- Bernal S, Ayuso C, Antinolo G, et al. Mutations in *USH2A* in Spanish patients with autosomal recessive retinitis pigmentosa: high prevalence and phenotypic variation. *J Med Genet*. 2003;40:e8.
- Siemiakowska AM, Schuurs-Hoeijmakers JH, Bosch DG, et al. Nonpenetrance of the most frequent autosomal recessive Leber congenital amaurosis mutation in *NMNAT1*. *JAMA Ophthalmol*. 2014;132:1002-1004.
- Sangermano R, Garanto A, Khan M, et al. Deep-intronic *ABCA4* variants explain missing heritability in Stargardt disease and allow correction of splice defects by antisense oligonucleotides. *Genet Med*. 2019;21:1751-1760.
- Zernant J, Lee W, Nagasaki T, et al. Extremely hypomorphic and severe deep intronic variants in the *ABCA4* locus result in varying Stargardt disease phenotypes. *Cold Spring Harb Mol Case Stud*. 2018;4:a002733.
- van Huet RA, Oomen CJ, Plomp AS, et al. The RD5000 database: facilitating clinical, genetic, and therapeutic studies on inherited retinal diseases. *Invest Ophthalmol Vis Sci*. 2014;55:7355-7360.
- McCulloch DL, Marmor MF, Brigell MG, et al. ISCEV Standard for full-field clinical electroretinography (2015 update). *Doc Ophthalmol*. 2015;130:1-12.
- Kuehlewein L, Hariri AH, Ho A, et al. Comparison of manual and semiautomated fundus autofluorescence analysis of macular atrophy in Stargardt disease phenotype. *Retina*. 2016;36:1216-1221.
- World Health Organization. International classification of diseases. Available at: <http://www.who.int/classifications/icd/en/>. Accessed November 1, 2018.
- Albert S, Garanto A, Sangermano R, et al. Identification and rescue of splice defects caused by two neighboring deep-intronic *ABCA4* mutations underlying Stargardt disease. *Am J Hum Genet*. 2018;102:517-527.

21. Schneider CA, Rasband WS, Eliceiri KW. NIH Image to ImageJ: 25 years of image analysis. *Nat Methods*. 2012;9:671-675.
22. Genome Aggregation Database. Genome Aggregation Database. Available at: <http://gnomad.broadinstitute.org/>. Accessed February 1, 2019.
23. Lek M, Karczewski KJ, Minikel EV, et al. Analysis of protein-coding genetic variation in 60,706 humans. *Nature*. 2016;536:285-291.
24. Consortium Genome of The Netherlands. Whole-genome sequence variation, population structure and demographic history of the Dutch population. *Nat Genet*. 2014;46:818-825.
25. Genome of The Netherlands. <http://www.nlgenome.nl/>. Accessed December 21, 2018.
26. Statistics Netherlands. Bevolking; geslacht, leeftijd en burgerlijke staat, 1 Januari. Available at: <https://opendata.cbs.nl/statline/#/CBS/nl/dataset/7461bev/table?dl=5052>. Accessed December 21, 2018.
27. Blacharski P. *Retinal Dystrophies and Degenerations*. New York: Raven Press; 1988.
28. Saksens NT, Fleckenstein M, Schmitz-Valckenberg S, et al. Macular dystrophies mimicking age-related macular degeneration. *Prog Retin Eye Res*. 2014;39:23-57.
29. Sparrow JR, Marsiglia M, Allikmets R, et al. Flecks in recessive Stargardt disease: short-wavelength autofluorescence, near-infrared autofluorescence, and optical coherence tomography. *Invest Ophthalmol Vis Sci*. 2015;56:5029-5039.
30. Lindner M, Lambertus S, Mauschitz MM, et al. Differential disease progression in atrophic age-related macular degeneration and late-onset Stargardt disease. *Invest Ophthalmol Vis Sci*. 2017;58:1001-1007.
31. Pawlak D, Souied E, Mimoun G, Papp-Pawlak M, Coscas G, Soubrane G. Fundus flavimaculatus and choroidal neovascularization [in French]. *J Fr Ophtalmol*. 2006;29:188-194.
32. Radu RA, Hu J, Yuan Q, et al. Complement system dysregulation and inflammation in the retinal pigment epithelium of a mouse model for Stargardt macular degeneration. *J Biol Chem*. 2011;286:18593-18601.
33. Lenis TL, Sarfare S, Jiang Z, Lloyd MB, Bok D, Radu RA. Complement modulation in the retinal pigment epithelium rescues photoreceptor degeneration in a mouse model of Stargardt disease. *Proc Natl Acad Sci U S A*. 2017;114:3987-3992.
34. Cornelis SS, Bax NM, Zernant J, et al. In silico functional meta-analysis of 5,962 ABCA4 variants in 3,928 retinal dystrophy cases. *Hum Mutat*. 2017;38:400-408.
35. Sangermano R, Khan M, Cornelis SS, et al. ABCA4 midgenes reveal the full splice spectrum of all reported noncanonical splice site variants in Stargardt disease. *Genome Res*. 2018;28:100-110.