

University of Groningen

The neuropsychological rehabilitation of visual agnosia and Balint's syndrome

Heutink, Joost; Indorf, Dana L.; Cordes, Christina

Published in:
Neuropsychological Rehabilitation

DOI:
[10.1080/09602011.2017.1422272](https://doi.org/10.1080/09602011.2017.1422272)

IMPORTANT NOTE: You are advised to consult the publisher's version (publisher's PDF) if you wish to cite from it. Please check the document version below.

Document Version
Publisher's PDF, also known as Version of record

Publication date:
2019

[Link to publication in University of Groningen/UMCG research database](#)

Citation for published version (APA):

Heutink, J., Indorf, D. L., & Cordes, C. (2019). The neuropsychological rehabilitation of visual agnosia and Balint's syndrome. *Neuropsychological Rehabilitation*, 29(10), 1489-1508 .
<https://doi.org/10.1080/09602011.2017.1422272>

Copyright

Other than for strictly personal use, it is not permitted to download or to forward/distribute the text or part of it without the consent of the author(s) and/or copyright holder(s), unless the work is under an open content license (like Creative Commons).

The publication may also be distributed here under the terms of Article 25fa of the Dutch Copyright Act, indicated by the "Taverne" license. More information can be found on the University of Groningen website: <https://www.rug.nl/library/open-access/self-archiving-pure/taverne-amendment>.

Take-down policy

If you believe that this document breaches copyright please contact us providing details, and we will remove access to the work immediately and investigate your claim.

Downloaded from the University of Groningen/UMCG research database (Pure): <http://www.rug.nl/research/portal>. For technical reasons the number of authors shown on this cover page is limited to 10 maximum.

Neuropsychological Rehabilitation

An International Journal

ISSN: 0960-2011 (Print) 1464-0694 (Online) Journal homepage: <https://www.tandfonline.com/loi/pnrh20>

The neuropsychological rehabilitation of visual agnosia and Balint's syndrome

Joost Heutink, Dana L. Indorf & Christina Cordes

To cite this article: Joost Heutink, Dana L. Indorf & Christina Cordes (2019) The neuropsychological rehabilitation of visual agnosia and Balint's syndrome, *Neuropsychological Rehabilitation*, 29:10, 1489-1508, DOI: [10.1080/09602011.2017.1422272](https://doi.org/10.1080/09602011.2017.1422272)

To link to this article: <https://doi.org/10.1080/09602011.2017.1422272>



© 2018 The Author(s). Published by Informa UK Limited, trading as Taylor & Francis Group



Published online: 24 Jan 2018.



Submit your article to this journal [↗](#)



Article views: 3425



View related articles [↗](#)




View Crossmark data [↗](#)



Citing articles: 1 View citing articles [↗](#)

The neuropsychological rehabilitation of visual agnosia and Balint's syndrome

Joost Heutink ^{a,b}, Dana L. Indorf^a and Christina Cordes^{a,b}

^aDepartment of Clinical and Developmental Neuropsychology, University of Groningen, Groningen, The Netherlands; ^bRoyal Dutch Visio, Centre of Expertise for Visually Impaired and Blind People, Department of Knowledge, Expertise & Innovation, Huizen, The Netherlands

ABSTRACT

Visual agnosia and Balint's syndrome are complex neurological disorders of the higher visual system that can have a remarkable impact on individuals' lives. Rehabilitation of these individuals is important to enable participation in everyday activities despite the impairment. However, the literature about the rehabilitation of these disorders is virtually silent. Therefore, the aim of this systematic review is to give an overview of available literature describing treatment approaches and their effectiveness with regard to these disorders. The search engines Psychinfo, Amed, and Medline were used, resulting in 22 articles meeting the criteria for inclusion. Only articles describing acquired disorders were considered. These articles revealed that there is some information available on the major subtypes of visual agnosia as well as on Balint's syndrome which practising clinicians can consult for guidance. With regard to the type of rehabilitation, compensatory strategies have proven to be beneficial in most of the cases. Restorative training on the other hand has produced mixed results. Concluding, although still scarce, a scientific foundation about the rehabilitation of visual agnosia and Balint's syndrome is evolving. The available approaches give valuable information that can be built upon in the future.

ARTICLE HISTORY Received 22 August 2017; Accepted 21 December 2017

KEYWORDS Visual perception; Visual agnosia; Balint's syndrome; Neuropsychological rehabilitation; Rehabilitation

Introduction

Due to the complexity of neurological disorders and the individual nature of impairments, neuropsychological rehabilitation is a difficult endeavour. Especially the rehabilitation of visual (perceptual) disorders is multifaceted, since visual disturbances may take place at lower and/or at higher function levels. Vision is often affected in patients with neurological disorders. For example, about 30% of the patients with acquired brain injury show deficits in vision (Zihl, 2003) and 20–40% of the patients with cerebrovascular acquired brain injury or traumatic brain injury (TBI) have higher visual disorders

CONTACT Joost Heutink  j.h.c.heutink@rug.nl  Department of Clinical and Developmental Neuropsychology, University of Groningen, Grote Kruisstraat 2/1, 9712 TS Groningen, The Netherlands

© 2018 The Author(s). Published by Informa UK Limited, trading as Taylor & Francis Group

This is an Open Access article distributed under the terms of the Creative Commons Attribution-NonCommercial-NoDerivatives License (<http://creativecommons.org/licenses/by-nc-nd/4.0/>), which permits non-commercial re-use, distribution, and reproduction in any medium, provided the original work is properly cited, and is not altered, transformed, or built upon in any way.

(Zihl & Kennard, 2003). Visual perceptual disorders can have a tremendous impact on an individual's spatial orientation, learning, and motor activities (Zihl, 2003), which in turn can affect a person's independence, social participation, and vocational life. Therefore, rehabilitation of visual perceptual disorders is a central topic in clinical practice.

Two approaches can be distinguished in neuropsychological rehabilitation (Spikman & Fasotti, 2017). The first type, restoration, aims to improve a particular function by training the impaired function and thereby the damaged brain structure directly and repetitively. The second type, compensation, refers to using an intact function to compensate for the loss of the other one. Thus, the impaired function itself is not targeted, but functioning on an activity and participation level is rather attempted to be improved. Depending on the level of impairment of the patient, environmental adaptation, for example signposting a route, could also be implemented if the patient's ability to learn compensatory strategies is limited. Often, a combination of these approaches may be necessary in a rehabilitation regime. The type of treatment chosen should also consider the type of brain injury the patient suffers from.

Visual (perceptual) disorders such as visual field defects, neglect, or difficulties with contrasts and colours may arise from either acquired brain injury (ABI; e.g., stroke) or neurodegenerative disorders (e.g., dementia, Parkinson's disease, and multiple sclerosis). Although there are several treatment options available for the more frequent disorders like hemianopia and neglect (Bowen, Hazelton, Pollock, & Lincoln, 2013; De Haan, Heutink, Melis-Dankers, Tucha, & Brouwer, 2014; Pollock et al., 2011), some visual disorders have received only little attention regarding their rehabilitation. Two disorders for which the latter is true are visual agnosia and Balint's syndrome, which can manifest in patients following ABI as well as in neurodegenerative diseases.

According to Zihl (2003), visual agnosia is a difficulty or inability to identify familiar stimuli via the visual modality, although the patient possesses sufficient visual perceptual, cognitive, and verbal functioning, and is able to recognise the stimulus using other modalities. Pure visual agnosia is a relatively rare condition, with an estimated prevalence of about 1–3% (Zihl & Kennard, 2003). At least four types of visual agnosia can be differentiated: prosopagnosia (the inability to recognise familiar faces and to learn new faces); object agnosia (the inability to identify stimuli in the same class or differentiate between classes of stimuli); topographical agnosia (difficulties with geographical orientation); and letter agnosia or pure alexia (inability to recognise individual letters and their combinations; Damasio, Tranel, & Rizzo, 2000; Roberts, 1992; Zihl, 2003). However, also finer distinctions can be made and very specific agnosias can be found in the literature as well (e.g., colour agnosia; Nijboer & Heutink, 2017).

A remarkable syndrome arising from disturbances to the higher visual system is Balint's syndrome (Balint, 1909). Balint's syndrome usually occurs after damage to bilateral posterior-parietal brain areas, and can occur after ABI or due to neurodegenerative diseases, usually dementia (Kerkhoff & Heldmann, 1999). Damasio et al. (2000), define Balint's syndrome as

An acquired disturbance of the ability to perceive the visual field as a whole, resulting in the unpredictable perception and recognition of only parts of it (simultanagnosia); which is accompanied by an impairment of target pointing under visual guidance (optic ataxia) and an inability to shift gaze at will toward new visual stimuli (ocular apraxia). (p. 353)

Of these three symptoms, simultanagnosia is described as the essence of the syndrome. The impact of Balint's syndrome is often so grave, that patients might appear as if they were blind (Kerkhoff & Heldmann, 1999).

Individuals with acquired visual agnosia or Balint's syndrome require intensive rehabilitation to help them to overcome their deficits. In addition to that, spontaneous recovery in both visual agnosia and Balint's syndrome is assumed to be low (Zihl & Kennard, 2003). This emphasises the importance of rehabilitation as an invaluable tool for affected individuals. However, due to the much lower prevalence of these visual-perceptual disorders compared to hemianopia or neglect, there are not many studies on the rehabilitation of visual agnosia and Balint's syndrome available. The purpose of this article is therefore to conduct a systematic literature review on the rehabilitation of acquired visual agnosia and Balint's syndrome to explore the available treatment approaches and their effectiveness, and to give an indication of which sources to pursue for those interested in further detail. Thereby, we aim to provide a status update on the rehabilitation of visual agnosia and Balint's syndrome and give directions for future research.

Method

A comprehensive systematic literature search was conducted to retrieve literature addressing cognitive rehabilitation of acquired visual agnosia and Balint's syndrome.

Search strategy

This study utilised the academic databases Psychinfo, Medline, and Amed to search for peer-reviewed publications published in either English or German. Keywords used were "treatment" or "rehabilitation" in combination with each of the terms "visual agnosia," "simultanagnosia," "object agnosia," "prosopagnosia," "associative agnosia," "apperceptive agnosia," "colour agnosia," "form agnosia," "semantic agnosia," "topographical agnosia," and "Balint's syndrome" in either English or German translation. We did not define a certain time period for the inclusion of the listed results and did not include unpublished data. Abstracts of the listed results were reviewed to identify those articles addressing the topic at hand.

Study selection

The time period of the listed results ranged from 1948 until 2017. [Figure 1](#) shows the steps followed during the literature search (PRISMA flow diagram; Moher, Liberati, Tetzlaff, Altman & The PRISMA Group 2009). Exclusion criteria were: (a) if the deficit was caused by a congenital condition, meaning the visual system had not developed normally before the occurrence of the impairment; (b) if the rehabilitation was on pure alexia as there have been publications reviewing the current status of rehabilitation (e.g., Starrfelt, Ólafsdóttir, & Arendt, 2013); and (c) if the sections dealing with the rehabilitation of visual agnosia and Balint's syndrome only did so by describing other researchers' work. We included studies: (a) providing evidence about the effectiveness of a rehabilitation by empirically evaluating it; (b) giving recommendations for rehabilitation based on scientific foundations or clinical experience as long as the recommendations were specific enough to give guidance to

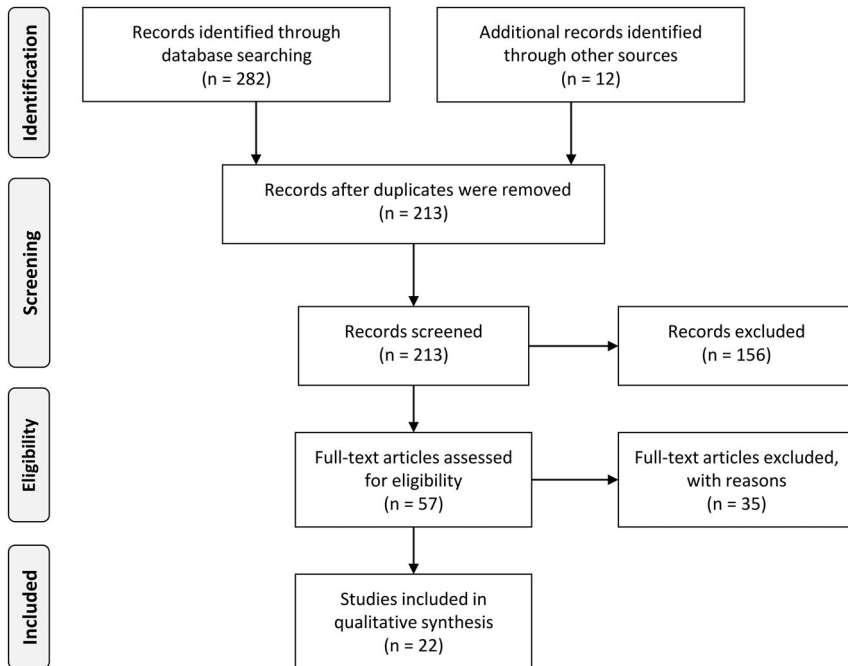


Figure 1. PRISMA flow diagram: Overview of the literature selection process.

practising clinicians; (c) describing the impairment as part of a more global deficit or in conjunction with other impairments (as we expected the literature to be too scarce to only consider “pure” impairments); and (d) investigating cases in which neurodegenerative disorders gave rise to visual agnosia or Balint’s syndrome. In case of doubt whether an article should be included in the review or not, the authors discussed them in the light of the purpose of the paper and whether the given information would be useful in guiding practising clinicians. We did not apply any criteria concerning the methodological quality of the studies, since we expected mostly studies with small sample sizes or case studies due to the rare occurrence of the deficits. A total of 22 sources published between 1992 and 2017 met the inclusion criteria, and are thus listed in the results.

Data synthesis

To differentiate between the rehabilitation of the different visual perceptual disorders, we divided the articles into three sections. The first section considers the rehabilitation of Balint’s syndrome, the second section describes the rehabilitation of prosopagnosia and object agnosia, and the third section deals with the rehabilitation of topographical agnosia. This division enabled us to separate all the articles except for one (Roberts, 1992), which addresses the rehabilitation of both Balint’s syndrome and visual agnosia. This article was therefore included in both the respective sections. Per article we further determined the rehabilitation approaches described (restorative or compensatory).

Results

Balint's syndrome

A total of 10 articles addressing the rehabilitation of Balint's syndrome met our criteria. Seven of these articles presented a case study including empirical validation of a treatment, while three articles gave suggestions and recommendations for treatment (Table 1). Generally, it can be observed that most rehabilitation approaches were multifaceted, and led to variable improvements in the treated patients. Compensatory strategies seemed to be widely applied and usually relatively successful. A small number of studies attempted to train the specific deficits arising from Balint's syndrome (Perez, Tunkel, Lachmann, & Nagler, 1996; Rosselli, Ardila, & Beltran, 2001; Zgaljardic, Yancy, Levinson, Morales, & Masel, 2011), with for example eye movement exercises or convergence exercises, which proved to be successful in some patients (Rosselli et al., 2001). Yet, some attempts remained less successful (Zgaljardic et al., 2011), allowing for little conclusiveness about the effectiveness of neuropsychological training or eye movement exercises. Several authors emphasised the importance of psychoeducation, strategies to promote the transfer from training situations to real-life situations, functional abilities, as well as building on strengths. Importantly, the choice for a rehabilitation approach and the expectations for an outcome depended heavily on the aetiology of Balint's syndrome. Perez et al. (1996) proposed to focus on learning and using strategies for neurodegenerative disorders that increase participation in everyday activities to increase coping and confidence in patients.

Based on the results of this search, we can conclude that a certain degree of rehabilitation of Balint's syndrome is possible for most patients, in so far as to regain functional capabilities and quality of life. A necessary condition might be that the treatment is individually tailored to the patient and the therapists maintain flexibility throughout the process.

Prosopagnosia and object agnosia

Much research on prosopagnosia has focused on the mechanisms by which we recognise faces and how these might be damaged. With regard to rehabilitation, two literature reviews could be found. The 12 case studies already reviewed by these two articles were not included in the present study. Instead, we added eight studies on the rehabilitation of prosopagnosia that were not included in these literature reviews (Table 2).

Both literature reviews concluded that restorative training has not yet proven to be very successful and that compensatory strategies appeared to be a more effective approach for the rehabilitation of acquired prosopagnosia (Bate & Bennetts, 2014; DeGutis, Chiu, Grosso, & Cohan, 2014). The additional eight articles appeared to be in line with the outcome of the literature reviews, especially with regard to transferring the training to real-life face recognition (Bate et al., 2015). The study by Davies-Thompson et al. (2017) describes a promising restorative approach, however training is very intense and does not improve real-life facial recognition in all participants involved. Concluding, compensation strategies seemed to be most promising for the rehabilitation of prosopagnosia.

With regard to object agnosia, the literature search revealed seven articles, describing the rehabilitation of object agnosia either in the context of other impairments (four studies) or as suggestions for rehabilitation strategies without clinical data (three

Table 1. Articles addressing the rehabilitation of Balint's syndrome.

Authors	Syndrome	Type of brain damage	Type of study	Type of rehabilitation	Treatment and outcome/Suggestion for treatment
Al-Khawaja, Haboubi, and Kerkhoff (2001)	Balint's syndrome	<ul style="list-style-type: none"> • First case: right occipito-parietal and left occipito-temporal lesions after TBI • Second case: traumatic, uraemic, and hypoxic brain damage • Third case: bilateral vascular parieto-occipital lesions 	Case correspondence (N = 3)	Compensatory	<p><i>Description:</i></p> <ul style="list-style-type: none"> • Three patients received individualised and systematic treatment based on an adaptive functional approach • Major aims were: <ul style="list-style-type: none"> → to improve basic visual abilities → to practise everyday tasks and activities • Approach included <ul style="list-style-type: none"> → relying on remaining abilities → compensatory strategies (e.g., auditory and tactile feedback) <p><i>Main outcome:</i></p> <ul style="list-style-type: none"> • All three patients achieved remarkable independence and improved functional abilities (e.g., living alone with minor assistance and using public transportation) → This demonstrates that significant improvements can be achieved with a flexible and systematic treatment
Gillen and Dutton (2003)	Balint's syndrome	Infarction of the right and left posterior parietal lobes due to infective endocarditis causing intracerebral haemorrhage	Case study (child, N = 1)	Compensatory	<p><i>Description:</i></p> <ul style="list-style-type: none"> • Psychoeducation and an adaptive approach building on strengths and remaining abilities were used to compensate for the patient's everyday difficulties (e.g., encouragement to keep surroundings organised and simple, doing homework in an oral instead of a written manner) <p><i>Main outcome:</i></p> <ul style="list-style-type: none"> • After a year the patient showed similar clinical symptoms as before the intervention, however, better adaption to everyday life activities were achieved (e.g., able to go to mainstream school with little assistance, improvement in independence, self-esteem, and behavioural problems)

Kerkhoff and Heldmann (1999)	Balint's syndrome	n.a.	Non-experimental report	Compensatory	<p><i>Suggestion:</i></p> <ul style="list-style-type: none"> • Rehabilitation might be limited for some patients suffering from Balint's syndrome, but systematic therapy could enhance daily life • Intact skills (e.g., processing object qualities like colour and movement) should be used to compensate for impairments • To break the spasmodic or wandering fixation, visual attention and fixation should be trained by using colourful (possibly moving objects) • Grasping could be improved by encouraging the patient to fixate an object before grasping • Simultaneous perception could be trained using common objects and pop-out stimuli • To train reading the denseness of words should be reduced • Eyelid closure can be helpful to ameliorate oscilloscopia and afterimages
Kerkhoff and Marquardt (2009a)	Balint's syndrome	n.a.	Non-experimental report	Restorative	<p><i>Suggestion:</i></p> <ul style="list-style-type: none"> • The authors present a standardised system for the assessment and treatment of visual search disorders (named EYEMOVE), of which Balint's syndrome is listed as a common cause • Though the authors do not present evidence for the beneficial effects of the training in Balint's syndrome (its efficiency was mostly tested in patients with homonymous hemianopia and neglect) some exercises could potentially be beneficial for training visual search in Balint's syndrome
Kerkhoff and Marquardt (2009b)	Balint's syndrome	Cerebral hypoxia	Case study (N = 1)	Compensatory	<p><i>Description:</i></p> <ul style="list-style-type: none"> • Introduction of an assessment and treatment method (named READ) for patients with reading disorders after ABI → Balint's syndrome is listed as a disorder that

(Continued)

Table 1. Continued.

Authors	Syndrome	Type of brain damage	Type of study	Type of rehabilitation	Treatment and outcome/Suggestion for treatment
Perez et al. (1996)	Balint's syndrome	Two cases with neurodegenerative disorders (posterior cortical atrophy) and a third case with bilateral occipito-parietal infarcts	Case study (N = 3)	Compensatory and restorative	<p>remarkably impacts reading ability</p> <ul style="list-style-type: none"> The method includes a "therapy package" for patients with Balint's syndrome utilising the "moving-window technique" A case study testing this technique over 50 sessions (each 40 min) is presented <p><i>Main outcome:</i></p> <ul style="list-style-type: none"> The patient significantly increased the number of correctly read words as well as significantly decreased the number of reading errors over the treatment period <p><i>Description:</i></p> <ul style="list-style-type: none"> Rehabilitation consisted of a multi-context approach aiming to maximise preserved visual functioning Strategies were used to improve assimilating visual information efficiently (e.g., colour coding items, using brightly coloured cards for reading assistance) Compensatory strategies, functional adaptive devices, verbal cueing, organisational strategies, and psychoeducation were used With less insight and more severe cognitive impairment, tactile and auditory techniques were used to increase visual scanning and cognitive status <p><i>Main outcome:</i></p> <ul style="list-style-type: none"> Increased self-esteem and more confidence in coping abilities were observed All patients improved in daily functional activities (e.g., dressing time) and learned compensatory strategies to adapt to the illness



Roberts (1992)	Balint's syndrome	n.a.	Non-experimental report	Compensatory	<p><i>Suggestion:</i></p> <ul style="list-style-type: none"> • Psychoeducation is important for Balint's syndrome • Patients may benefit from non-visual devices and techniques (e.g., talking books) and techniques to adapt to the condition (e.g., sitting further away from the television so more of the picture falls onto the fovea) • "Organised visuospatial exploration" exercises should be used to practise visuospatial skills
Roca, Gleichgerrcht, Torralva, and Manes (2010)	Balint's syndrome	Neuro-degenerative (posterior cortical atrophy)	Case study, pre- and post-intervention measurement	Compensatory	<p><i>Description:</i></p> <ul style="list-style-type: none"> • Neuropsychological functioning and subjective rating of everyday functioning was assessed at baseline and after training • Training consisted of a cognitive rehabilitation programme (45 min weekly) including psychoeducation, training of object letter recognition with salient features, visual scanning training, and using tactile instead of visual information (total duration: 1–5 weeks, depending on type of training) <p><i>Main outcome:</i></p> <ul style="list-style-type: none"> • Visuoperception problems showed improvement as demonstrated by better performance on the Complex Figure of Rey and TMT-A • Both subject himself and his wife reported better everyday functioning after treatment • Due to the nature of the subject's condition, further impairment arose after training
Rosselli et al. (2001)	Balint's syndrome	Significant bilateral parieto-occipito damage following an occlusion in posterior cerebral arteries caused by a fat embolism	Case study (N = 1)	Compensatory and restorative	<p><i>Description:</i></p> <ul style="list-style-type: none"> • The patient attended an outpatient programme over a period of 12 months, 2 hours a week • Visuoperceptual training was tailored to the patient's deficits • Exercises were made for home practice (eye movement, convergence, word reading, visuokinetic functioning, visual search, trail-making, and writing)

(Continued)

Table 1. Continued.

Authors	Syndrome	Type of brain damage	Type of study	Type of rehabilitation	Treatment and outcome/Suggestion for treatment
Zgaljardic et al. (2011)	Balint's syndrome	Severe TBI resulting in epidural haematoma and left occipito-parietal subdural haematoma with bilateral parenchymal contusions, cerebral oedema and multiple skull fractures	Case study (N = 1)	Compensatory and restorative	<ul style="list-style-type: none"> • A functional adaption programme encouraged the patient to participate in daily life and social activities, use public transportation, and remain active at home, or even reading newspapers and searching for educational courses <p><i>Main outcome:</i></p> <ul style="list-style-type: none"> • The follow-up neuropsychological assessment showed significant improvements especially in those tests sensitive to scanning deficits and simultanagnosia • Pronounced improvements in community independence and vocational life could be observed <p><i>Description:</i></p> <ul style="list-style-type: none"> • Patient received an individualised programme plan carried out for 6 hours per day, 5 days a week for 6 months • Rehabilitation included adaptive-functional strategies, remediation exercises (eye movement exercises, convergent exercises, and visual search exercises adapted from Rosselli et al. (2001), transfer of learned skills in multiple environments and situations, psychoeducation, and psychotherapy <p><i>Main outcome:</i></p> <ul style="list-style-type: none"> • The clinical symptoms of Balint's syndrome were not improved significantly, but the patient achieved important physical and functional progress, including changes in attitude, self-esteem, coping skills, understanding, and awareness of the clinical symptoms • Functional improvements seemed to provide a more robust indicator of the rehabilitation programme's value than the neuropsychological performance

Note: n.a. = not applicable.

Table 2. Articles addressing the rehabilitation of prosopagnosia and object agnosia.

Authors	Syndrome	Type of brain damage	Type of study	Type of rehabilitation	Treatment and outcome/Suggestion for treatment
Anderson and Rizzo (1995)	Visual recognition impairments	n.a.	Non-experimental report	Compensatory	<p><i>Suggestion:</i></p> <ul style="list-style-type: none"> • Patients that suffer from pure visual agnosia could be taught to compensate for their impairments by making use of preserved tactile and auditory modes and possibly by moving the stimuli in question • Recognition by voice may carry most potential for compensatory strategies in patients with prosopagnosia • Prosopagnosics may draw on persons' gaits, postures, and salient cues (hairstyles, teeth, etc.) for identification • Psychoeducation as well as addressing awareness of the disorder and its consequences is seen as important • The timing of possible restorative training is addressed
Bate and Bennetts (2014)	Prosopagnosia	n.a.	Literature review	Compensatory and restorative	<p><i>Suggestion:</i></p> <ul style="list-style-type: none"> • Remedial training is limited, compensatory training appears more successful • When choosing a type of treatment, factors, such as the timing of the injury, severity, and location of the lesion, and the precise functional implications of the lesion, need to be taken into account
Bate et al. (2015)	Prosopagnosia	Lesions in inferior and medial right temporal lobe extending back into the inferior, lateral, and posterior right occipital lobe as well as lesions in fusiform gyrus, inferior left temporal lobe, and inferolateral left	Case study (N = 1)	Restorative	<p><i>Description:</i></p> <ul style="list-style-type: none"> • The patient completed 30 hours of an individually tailored online training programme over 14 weeks to improve face perception skills • The programme provided increasing

(Continued)



Table 2. Continued.

Authors	Syndrome	Type of brain damage	Type of study	Type of rehabilitation	Treatment and outcome/Suggestion for treatment
		occipital lobe caused by herpes simplex encephalitis			levels of difficulty and required the patient to match faces with a different viewpoint to a target face <i>Main outcome:</i> <ul style="list-style-type: none"> • Face processing skills of trained and untrained faces were improved, while facial scanning focused more on inner facial features • The patient did not perceive any of these improvements in daily life
Burns (2004)	Agnosia in general (visual agnosias discussed include hemiachromatopsia, akinetopsia, prosopagnosia, pure object agnosia, pure alexia)	n.a.	Non-experimental report	Compensatory	<i>Suggestion:</i> <ul style="list-style-type: none"> • Compensatory strategies are recommended to promote independence and optimise the living environment • Supports strategies involving alternative modalities (e.g., tactile or auditory), verbal descriptions, and the use of alternate cues (e.g., colour and tactile cues)
Davies-Thompson et al. (2017)	Prosopagnosia	Location of lesion was inferior occipito-temporal (4 participants), anterior temporal (4 participants), or anterior temporal and occipito-temporal (2 participants)	Pre- and post-intervention measurement	Restorative	<i>Description:</i> <ul style="list-style-type: none"> • 10 patients completed an 11-week face training programme, either starting with the training itself or a control task • Before training, baseline measurements took place including neuropsychological and visual functioning assessment and MRI scans • Training consisted of photos of 12 faces at different angles (identity varying in degree) and with different emotional expressions (also varying in degree). Participants had to determine which of the faces resembled a target face most • Post-training evaluation included both trained and untrained faces to determine generalisation of the task

DeGutis et al. (2014)	Prosopagnosia	n.a.	Literature review	Compensatory and restorative	<ul style="list-style-type: none"> • Participants in the control task watched selected British television series of their choice <p><i>Outcomes:</i></p> <ul style="list-style-type: none"> • Training improved discrimination of trained and untrained faces 3 month post-training, however, performance on other face perception tests did not improve • Those with more severe impairment benefited most from the training • Subjective experience gave mixed results with only a few participants reporting improvement in recognising faces in real life <p><i>Suggestion:</i></p> <ul style="list-style-type: none"> • Both compensatory and remedial approaches in acquired prosopagnosia were reviewed • No evidence was found for the effectiveness of remedial approaches, whereas compensatory strategies (e.g., focusing on the specific deficit leading to prosopagnosia caused by the acquired brain injury and preserved abilities) were promoted • However, the authors denote that the strategies might not always work and that a thoughtful trial-and-error approach is sensible
Roberts (1992)	Visual agnosia	n.a.	Non-experimental report	Compensatory	<p><i>Suggestion:</i></p> <p>Gives a few compensatory strategies for different visual agnosias</p>
Rosenthal and Behrmann (2006)	Object agnosia, prosopagnosia	Extensive bilateral occipital extrastriate lesion, including area V2 and some of striate cortex, sparing high-level visual areas such as the fusiform region, the temporal	Case study and group comparison (4 controls)	Restorative	<p><i>Description:</i></p> <ul style="list-style-type: none"> • Goal of the study was to investigate if severely agnostic subject JW was capable of learning simple and complex visual stimuli

(Continued)

Table 2. Continued.

Authors	Syndrome	Type of brain damage	Type of study	Type of rehabilitation	Treatment and outcome/Suggestion for treatment
Seniow et al. (2003)	Complex cognitive deficit syndrome including visual associative agnosia	lobes, and prefrontal areas Gunshot injury leaving bilateral damage of the parietal-occipital regions	Case study (N = 1)	Compensatory and restorative	<ul style="list-style-type: none"> • Study consisted of 3 phases: <ul style="list-style-type: none"> – In the first experiment it was explored if JW can distinguish simple stripe stimuli by their stripe width – The goal of the second experiment (6 months later) was to assess the generalisation and long-term effects of experiment 1 – Experiment 3 assessed recovery of lower-level processes <p><i>Main outcome:</i></p> <ul style="list-style-type: none"> • Although his learning process was slower than that of the control groups, JW was able to learn to classify visual stimuli and maintained this ability over the long term <p><i>Description:</i></p> <ul style="list-style-type: none"> • Rehabilitation programme was given twice a week in 90-minute sessions over one year • It included computer (RehaCom) as well as paper-and-pen training and occupational therapy in the laboratory coupled with home exercises <p><i>Main outcome:</i></p> <ul style="list-style-type: none"> • Patient showed improvement in all affected cognitive domains and gained more independence in his everyday life back (both objectively and subjectively evaluated) • Especially performance on psychological testing (e.g., copying, drawing, and recognising simple objects) improved significantly • Unfortunately, rehabilitation and improvement were not described specific to agnosia

Tanemura (1999)	Object agnosia, picture agnosia, prosopagnosia, colour agnosia, and pure alexia	Damage to inferior medial side of temporal lobe, inferior temporal gyrus of the left temporal lobe, and a part of white matter of the occipital lobe after infarction of bilateral posterior cerebral artery	Case study (N = 1)	Compensatory	<p><i>Description:</i></p> <ul style="list-style-type: none"> • The patient received training to use kinaesthesia to improve visual perception, i.e., gazing and visual pursuit (colouring, sketching), discriminating figure and ground, using tactile and the kinaesthetic sense (wood and metal carving, leathercraft), working with stained glass, mosaic work with tiles or paper, fishing as recreational activity <p><i>Main outcome:</i></p> <ul style="list-style-type: none"> • Improvement concerning object agnosia, picture agnosia, alexia, and reaction time (as measured with "Perception Test for Agnosia") • Prosopagnosia remained similarly impaired • The integration of kinaesthetic information with visual information was evaluated as successful
Zihl (2011)	Object agnosia, prosopagnosia, and letter agnosia	Bilateral occipito-temporal infarction in one case and closed head trauma accompanied by severe chronic hypoxia in the second patient	Case study (N = 2)	Restorative	<p><i>Description:</i></p> <ul style="list-style-type: none"> • Patients received 2–4 training sessions each day, including 45 min information processing training, training for information selection, and developing and using cognitive strategies to supervise and control visual identification • Further training included recognising faces and letters by presenting stimuli in pairs and asking to differentiate them <p><i>Main outcome:</i></p> <ul style="list-style-type: none"> • Improvements in the identification of trained object classes and some generalisation to classes that were not practised • Training for letters and faces was not as effective, however the more elaborate training showed some successes

Note: n.a. = not applicable.

studies; Table 2). Generally, compensating for the deficit via tactile and auditory modes, as well as via verbal description and kinaesthetic information was frequently recommended (Tanemura, 1999). Zihl (2011) trained object recognition in two patients using a restorative approach, which led to improvements in both patients with some generalisation to non-trained objects. Seniow, Polanowska, Mandat, and Laudanski (2003) achieved improvements using both restorative and compensatory training. Therefore, it is hard to draw conclusions about which the effective component was. To summarise, there is only limited data available on effective rehabilitation of object agnosia, but evidence is beginning to emerge for the usefulness of both restorative and compensatory strategies.

Topographical agnosia

Literature on the rehabilitation of topographical agnosia is scarce; only two studies giving information on treatment approaches could be included (Table 3). In the first study, Bouwmeester, Van de Wege, Haaxma, and Snoek (2015) described a patient with a relatively severe clinical presentation who benefited from an individualised training programme. The patient did not improve much in location recognition, but nevertheless learned to reach desired destinations. This outcome provides evidence that training can significantly increase independence and quality of life even in patients with severe deficits. The second study described a generally more highly functioning individual, who suffered severely from topographical disorientation (Davis & Coltheart, 1999). By focusing on the patient's relevant environment and common routes, the patient was taught to use mnemonic techniques and a map to reach desired destinations independently and more securely. To conclude, both studies used compensatory strategies for the rehabilitation and offered some specific ideas about what may have been effective in these two cases.

Discussion

The aim of the present literature review was to systematically collect information or recommendations for the rehabilitation of visual agnosia and Balint's syndrome. The results show that especially compensatory strategies have proven to be beneficial in most cases, whereas restorative training has produced mixed results. Evidence for the effectiveness of restorative training in acquired prosopagnosia is currently not very persuasive. For the other subtypes of agnosia, it is not possible to draw conclusions about the effectiveness of restorative training as there is too little and contradictory research available. In Balint's syndrome, restorative training has been shown to be more successful, but there is also not enough research available to give a clear indication. Altogether, though still very scarce, a scientific foundation about the rehabilitation of these disorders is evolving and there are approaches giving valuable information that can be built upon in the future. Yet, a few issues require some further consideration.

First, for the treatment of agnosia, Groh-Bordin and Kerkhoff (2010) suggested that, based on their clinical experience, it might be more effective to treat deficits that occur with agnosia (e.g., hemianopia) rather than focusing on the agnosia itself. This approach is based on the view that, if other visual deficits are enhanced, recognition will likely be improved as well. However, Zihl (2011) failed to prove this approach. He

Table 3. Articles addressing the rehabilitation of topographical disorientation.

Authors	Syndrome	Type of brain damage	Type of study	Type of rehabilitation	Treatment and Outcome/ Suggestion for Treatment
Bouwmeester et al. (2015)	Topographical disorientation caused by landmark agnosia amongst other deficits	Damage to medial occipito-temporal region bilaterally, predominantly on the right side caused by a stroke	Case study (N = 1)	Compensatory	<p><i>Description:</i></p> <ul style="list-style-type: none"> • Individualised training (e.g., booklet containing meaningful routes using precise directions and landmarks) • Goal was to enable the patient to independently move to important destinations <p><i>Main outcome:</i></p> <ul style="list-style-type: none"> • After the training the patient was able to walk a number of routes independently and to learn new routes • The patient gained independence, confidence and quality of life
Davis and Coltheart (1999)	Topographical agnosia	Likely some neurological event but could not be confirmed by CAT/MRI/PET, patient described deterioration of cognitive function secondary to left-sided hemiparesis during a severe migraine	Case study (N = 1)	Compensatory	<p><i>Description:</i></p> <ul style="list-style-type: none"> • Individualised intervention with a focus on acquiring new topographical information, consisting of six sessions each not lasting longer than an hour • Patient was taught mnemonics to make use of street names and their location as well as how to apply this knowledge to a map <p><i>Main outcome:</i></p> <ul style="list-style-type: none"> • The studied information and strategies were reliably learned and used in everyday life (e.g., patient was able to construct a map which gave more independence and confidence in trying new routes)

Note: n.a. = not applicable.

attempted to improve identification and recognition by training oculomotor scanning in patients with homonymous visual field loss and disorientation, which resulted in improvement of the trained skill, yet none for recognition. Nevertheless, it seems plausible that improved lower visual functions will increase the chances to rehabilitate recognition as well. We would argue that clinicians need to consider how much the patients are – subjectively and objectively – impaired by the agnosia. If the agnosia dominates impairment caused by other deficient visual functions, rehabilitation should target the specific agnostic deficit at least by training compensatory strategies.

Another factor to consider in clinical rehabilitation is the cost-effectiveness of a certain approach. As mentioned before, the effectiveness of restorative training in visual agnosia and Balint's syndrome has not been fully proven. In addition to that, successful rehabilitation using restorative training usually follows an extensive period of training, sometimes up to hundreds of hours of practice with often only small improvements in daily life (e.g., Zihl, 2011). This might lead to potential frustration in patients. Compensatory strategies on the other hand have been shown to achieve meaningful progress in the patients' daily functioning and might therefore be more cost-effective. Yet, one pitfall may be that patients may not be ready to "accept" the impairment in early stages of the rehabilitation, decreasing the motivation to attempt compensation rather than training the deficit itself (Finauer, 2009). Most important, decisions about rehabilitation approaches need to be individualised, taking the circumstances and unique impairments of the patients into consideration.

Future research and clinical practice

Based on the current literature available, an evidence-based rehabilitation programme cannot be established. We therefore encourage clinicians to share any cases of visual agnosia and Balint's syndrome with the scientific community, and to make detailed rehabilitation plans available to benefit other practitioners. Especially the addition of more details about the rehabilitation approach, including pre- and post-measurements, would be helpful to establish an evidence-based practice. Future publications may take this literature review as a basis for further research to confirm the effectiveness of particular rehabilitation approaches and fill in further knowledge gaps. For example, existing cognitive rehabilitation software that was created to train people with visual agnosia and Balint's syndrome (for example, visual exploration exercises), could be incorporated into future rehabilitation programmes to be systematically evaluated. Furthermore, the literature described in the present manuscript rarely explored how well trained skills transferred into the relevant context for the patient. It is important for future research to not overlook this crucial step in determining the effectiveness of a certain rehabilitation approach.

Conclusion

The current article provides a basis and starting point for more systematic progress towards an evidence-based treatment approach for patients with visual agnosia and Balint's syndrome. Researchers and clinicians can use the information this article revealed to guide their research and fill in the knowledge gaps identified in the present literature review.

Disclosure statement

No potential conflict of interest was reported by the authors.

ORCID

Joost Heutink  <http://orcid.org/0000-0002-4811-968X>

References

- Al-Khawaja, I., Haboubi, N. H. J., & Kerkhoff, G. (2001). Neurovisual rehabilitation in Balint's syndrome. *Journal of Neurology, Neurosurgery & Psychiatry*, 70, 416–416. doi:10.1136/jnnp.70.3.416
- Anderson, S. W., & Rizzo, M. (1995). Recovery and rehabilitation of visual cortical dysfunction. *NeuroRehabilitation*, 5(2), 129–140. doi:10.3233/NRE-1995-5204
- Balint, R. (1909). Seelenlähmung des "Schauens": Optische Ataxie, räumliche Störung der Aufmerksamkeit [Paralysis of "seeing": Optical ataxia, spatial disorder of attention]. *Monatszeitschrift Für Psychiatrie Und Neurologie*, 25(1), 51–66. doi:10.1159/000210464
- Bate, S., & Bennetts, R. J. (2014). The rehabilitation of face recognition impairments: A critical review and future directions. *Frontiers in Human Neuroscience*, 8, 491–491. doi:10.3389/fnhum.2014.00491
- Bate, S., Bennetts, R., Mole, J. A., Ainge, J. A., Gregory, N. J., Bobak, A. K., & Bussunt, A. (2015). Rehabilitation of face-processing skills in an adolescent with prosopagnosia: Evaluation of an online perceptual training programme. *Neuropsychological Rehabilitation*, 25(5), 733–762. doi:10.1080/09602011.2014.973886
- Bouwmeester, L., Van de Wege, A., Haaxma, R., & Snoek, J. W. (2015). Rehabilitation in a complex case of topographical disorientation. *Neuropsychological Rehabilitation*, 25(1), 1–14. doi:10.1080/09602011.2014.923318
- Bowen, A., Hazelton, C., Pollock, A., & Lincoln, N. B. (2013). Cognitive rehabilitation for spatial neglect following stroke. *Cochrane Database of Systematic Reviews*, 7, CD003586. doi:10.1002/14651858.CD003586.pub3
- Burns, M. S. (2004). Clinical management of agnosia. *Topics in Stroke Rehabilitation*, 11(1), 1–9.
- Damasio, A. R., Tranel, D., & Rizzo, M. (2000). Disorders of complex visual processing. In M. M. Mesulam (Ed.), *Principles of behavioral and cognitive neurology* (pp. 332–364). New York: Oxford University Press.
- Davies-Thompson, J., Fletcher, K., Hills, C., Pancaroglu, R., Corrow, S. L., & Barton, J. J. S. (2017). Perceptual learning of faces: A rehabilitative study of acquired prosopagnosia. *Journal of Cognitive Neuroscience*, 29, 573–591. doi:10.1162/jocn_a_01063
- Davis, S. J. C., & Coltheart, M. (1999). Rehabilitation of topographical disorientation: An experimental single case study. *Neuropsychological Rehabilitation*, 9(1), 1–30. doi:10.1080/713755586
- DeGutis, J. M., Chiu, C., Grosso, M. E., & Cohan, S. (2014). Face processing improvements in prosopagnosia: Successes and failures over the last 50 years. *Frontiers in Human Neuroscience*, 8, 561–561. doi:10.3389/fnhum.2014.00561
- De Haan, G. A., Heutink, J., Melis-Dankers, B. J. M., Tucha, O., & Brouwer, W. H. (2014). Spontaneous recovery and treatment effects in patients with homonymous visual field defects: A meta-analysis of existing literature in terms of the ICF framework. *Survey of Ophthalmology*, 59(1), 77–96. doi:10.1016/j.survophthal.2013.02.006
- Finauer, G. (2009). *Therapiemanuale für die neuropsychologische Rehabilitation: Kognitive und kompetenzorientierte Therapie für die Gruppen- und Einzelbehandlung* [Manual for neuropsychological rehabilitation: Cognitive and competence-oriented therapy for group- and individual treatment]. Berlin: Springer.
- Gillen, J. A., & Dutton, G. N. (2003). Balint's syndrome in a 10-year-old male. *Developmental Medicine & Child Neurology*, 45(5), 349–352.
- Groh-Bordin, C., & Kerkhoff, G. (2010). Recovery and treatment of sensory perceptual disorders. In J. Gurd, U. Kischka, & J. Marshall (Eds.), *Handbook of clinical neuropsychology* (pp. 139–158). New York: Oxford University Press.
- Kerkhoff, G., & Groh-Bordin, C. (2010). Höhere visuelle Funktionen: Neglect, Raumorientierung, Balint-Holmes Syndrom und Agnosien [Higher visual functions: Neglect, spatial orientation, balint-holmes

- syndrome and agnosias]. In P. Frommelt & H. Lösslein (Eds.), *NeuroRehabilitation* (pp. 207–221). Berlin: Springer.
- Kerckhoff, G., & Heldmann, B. (1999). Balint syndrome and associated disorders. Anamnesis–diagnosis–approaches to treatment. *Der Nervenarzt*, *70*(10), 859–869.
- Kerckhoff, G., & Marquardt, C. (2009a). EYEMOVE. Standardized assessment and treatment of visual search disorders. *Der Nervenarzt*, *80*(10), 1190. doi:10.1007/s00115-009-2811-4
- Kerckhoff, G., & Marquardt, C. (2009b). Erworbene, visuell bedingte Lesestörungen: Standardisierte Diagnostik und Therapie mit READ [Acquired, visually based reading disorders: Standardised assessment and treatment with READ]. *Der Nervenarzt*, *80*(12), 1424–1439. doi:10.1007/s00115-009-2723-3
- Moher, D., Liberati, A., Tetzlaff, J., & Altman, D. G. (2009). Preferred reporting items for systematic reviews and meta-analyses: The PRISMA statement. *PLoS Medicine*, *6*(7), e1000097. doi:10.1371/journal.pmed.1000097
- Nijboer, T., & Heutink, J. (2017). Visual perception. In R. Kessels, P. Eling, R. Ponds, J. Spikman, & Van M. Zandvoort (Eds.), *Clinical neuropsychology* (pp. 137–157). Amsterdam: Boom.
- Perez, F. M., Tunkel, R. S., Lachmann, E. A., & Nagler, W. (1996). Balint's syndrome arising from bilateral posterior cortical atrophy or infarction: Rehabilitation strategies and their limitation. *Disability and Rehabilitation*, *18*(6), 300–304.
- Pollock, A., Hazelton, C., Henderson, C. A., Angillely, J., Dhillon, B., Langhorne, P., ... Shahani, U. (2011). Interventions for visual field defects in patients with stroke. *Cochrane Database of Systematic Reviews*, (10), CD008388. doi:10.1002/14651858.CD008388.pub2
- Roberts, S. P. (1992). Visual disorders of higher cortical function. *Journal of the American Optometric Association*, *63*(10), 723–732.
- Roca, M., Gleichgerrcht, E., Torralva, T., & Manes, F. (2010). Cognitive rehabilitation in posterior cortical atrophy. *Neuropsychological Rehabilitation*, *20*(4), 528–540. doi:10.1080/09602011003597408
- Rosenthal, O., & Behrmann, M. (2006). Acquiring long-term representations of visual classes following extensive extrastriate damage. *Neuropsychologia*, *44*(5), 799–815. doi:10.1016/j.neuropsychologia.2005.07.010
- Rosselli, M., Ardila, A., & Beltran, C. (2001). Rehabilitation of balint's syndrome: A single case report. *Applied Neuropsychology*, *8*(4), 242–247. doi:10.1207/09084280152829093
- Seniow, J., Polanowska, K., Mandat, T., & Laudanski, K. (2003). The cognitive impairments due to the occipito-parietal brain injury after gunshot. A successful neurorehabilitation case study. *Brain Injury*, *17*(8), 701–713. doi:10.1080/0269905031000088621
- Spikman, J., & Fasotti, L. (2017). Recovery and treatment. In R. Kessels, P. Eling, R. Ponds, J. Spikman, & M. Van Zandvoort (Eds.), *Clinical neuropsychology* (pp. 113–133). Amsterdam: Boom.
- Starrfelt, R., Ólafsdóttir, R. R., & Arendt, I.-M. (2013). Rehabilitation of pure alexia: A review. *Neuropsychological Rehabilitation*, *23*(5), 755–779. doi:10.1080/09602011.2013.809661
- Tanemura, R. (1999). Awareness in apraxia and agnosia. *Topics in Stroke Rehabilitation*, *6*(1), 33–42. doi:10.1310/U9KU-M4X8-DMRQ-9TR7
- Zgaljardic, D. J., Yancy, S., Levinson, J., Morales, G., & Masel, B. E. (2011). Balint's syndrome and post-acute brain injury rehabilitation: A case report. *Brain Injury*, *25*(9), 909–917. doi:10.3109/02699052.2011.585506
- Zihl, J. (2003). Recovery and rehabilitation of cerebral visual disorders. In M. Fahle & M. Greenlee (Eds.), *The neuropsychology of vision* (pp. 319–338). New York: Oxford University Press.
- Zihl, J. (2011). *Rehabilitation of visual disorders after brain injury*. New York: Psychology Press.
- Zihl, J., & Kennard, C. (2003). Disorders of higher visual function. In T. Brandt (Ed.), *Neurological disorders: Course and treatment* (pp. 255–261). Amsterdam: Academic Press.