

University of Groningen

Meta-analysis of 701 published cases of sinonasal neuroendocrine carcinoma

van der Laan, Tom P.; Iepsema, Rene; Witjes, Max J. H.; van der Laan, Bernard F. A. M.;
Plaat, Boudewijn E. C.; Halmos, Gyorgy B.

Published in:
Oral Oncology

DOI:
[10.1016/j.oraloncology.2016.10.002](https://doi.org/10.1016/j.oraloncology.2016.10.002)

IMPORTANT NOTE: You are advised to consult the publisher's version (publisher's PDF) if you wish to cite from it. Please check the document version below.

Document Version
Publisher's PDF, also known as Version of record

Publication date:
2016

[Link to publication in University of Groningen/UMCG research database](#)

Citation for published version (APA):

van der Laan, T. P., Iepsema, R., Witjes, M. J. H., van der Laan, B. F. A. M., Plaat, B. E. C., & Halmos, G. B. (2016). Meta-analysis of 701 published cases of sinonasal neuroendocrine carcinoma: The importance of differentiation grade in determining treatment strategy. *Oral Oncology*, 63, 1-9.
<https://doi.org/10.1016/j.oraloncology.2016.10.002>

Copyright


Other than for strictly personal use, it is not permitted to download or to forward/distribute the text or part of it without the consent of the author(s) and/or copyright holder(s), unless the work is under an open content license (like Creative Commons).

The publication may also be distributed here under the terms of Article 25fa of the Dutch Copyright Act, indicated by the "Taverne" license. More information can be found on the University of Groningen website: <https://www.rug.nl/library/open-access/self-archiving-pure/taverne-amendment>.

Take-down policy

If you believe that this document breaches copyright please contact us providing details, and we will remove access to the work immediately and investigate your claim.

Downloaded from the University of Groningen/UMCG research database (Pure): <http://www.rug.nl/research/portal>. For technical reasons the number of authors shown on this cover page is limited to 10 maximum.



Review

Meta-analysis of 701 published cases of sinonasal neuroendocrine carcinoma: The importance of differentiation grade in determining treatment strategy



Tom P. van der Laan MD^{a,b}, René Iepsma BSc^a, Max J.H. Witjes MD, PhD^c,
Bernard F.A.M. van der Laan MD, PhD^{a,b}, Boudewijn E.C. Plaat MD, PhD^a, Gyorgy B. Halmos MD, PhD^{a,*}

^a University of Groningen, University Medical Center Groningen, Dept. of Otorhinolaryngology/Head and Neck Surgery, The Netherlands

^b University of Groningen, Graduate School of Medical Sciences (Damage and Repair in Cancer Development and Cancer Treatment), The Netherlands

^c University of Groningen, University Medical Center Groningen, Department of Oral and Maxillofacial Surgery, The Netherlands

ARTICLE INFO

Article history:

Received 31 July 2016

Received in revised form 19 September 2016

Accepted 2 October 2016

Available online 31 October 2016

Keywords:

Head and neck cancer

Meta-analysis

Neuroendocrine carcinoma

Paranasal sinuses

Nasal cavity

Sinonasal undifferentiated carcinoma

Small cell carcinoma

ABSTRACT

The aim of this meta-analysis was to provide treatment guidelines for sinonasal neuroendocrine carcinoma (SNC) by combining all available data in the literature.

A literature search for all studies concerning SNC was performed against the MEDLINE and EMBASE databases. Available clinical data was normalized, pooled, and statistically analyzed.

A total of 701 cases of SNC were available for analysis, comprising 127 well or moderately differentiated sinonasal neuroendocrine carcinomas (SNEC), 459 sinonasal undifferentiated carcinoma (SNUC) and 115 sinonasal small cell carcinoma (SmCC). Tumor type was the most important predictor of survival, with a 5-year disease-specific survival (DSS) of 70.2% for SNEC, 35.9% for SNUC and 46.1% for SmCC. Tumor stage on presentation was of limited value in predicting survival or response to treatment. Overall, the application of surgery yielded significantly better results (5-year DSS 52.2% versus 30.1%, $p < 0.001$). In SNUC, radiotherapy was a beneficial supplement to surgery (5-year DSS 54.7% versus 15.7%, $p = 0.027$), while radiotherapy as monotherapy performed poorly (5-year DSS 17.9%). Chemotherapy did not appear to contribute to survival.

Based on these findings, we can conclude that the most important predictors of survival in SNC are differentiation grade and the associated choice of treatment modality. In contrast to other head and neck cancers, tumor staging appears of limited value in predicting survival or deciding on a treatment strategy. Surgery should be the cornerstone of treatment, supplemented by radiotherapy in poorly differentiated subtypes (SNUC, SmCC). Chemotherapy does not appear to contribute to survival.

© 2016 The Authors. Published by Elsevier Ltd. This is an open access article under the CC BY license (<http://creativecommons.org/licenses/by/4.0/>).

Introduction

Sinonasal tumors with neuroendocrine differentiation are a rare group of neoplasms that account for only 5% of all sinonasal malignancies [1]. A broad distinction is made between tumors of neuroectodermal origin - esthesioneuroblastoma - and those of epithelial origin - sinonasal neuroendocrine carcinoma (SNC). The

latter can be subdivided based on differentiation grade into well, moderately and poorly differentiated SNC. Poorly differentiated SNC are further subdivided into a small and large cell variants.

In the literature an ambiguous nomenclature is maintained. Confusingly, in contrast to well and moderately differentiated SNC, large cell poorly differentiated SNC are denoted by sinonasal undifferentiated carcinoma (SNUC) and small cell poorly differentiated SNC by sinonasal small cell carcinoma (SmCC), discounting their neuroendocrine nature. In order to prevent further ambiguity, well and moderately differentiated SNC are referred to by their common abbreviation, SNEC, in this article.

Previous studies have shown tumor behavior to differ markedly between the various entities of sinonasal tumors with neuroendocrine differentiation [2]. For esthesioneuroblastoma a well-defined treatment strategy is available that, in part due to their

Abbreviations: SNC, sinonasal neuroendocrine carcinoma; SNEC, well or moderately differentiated sinonasal neuroendocrine carcinoma; SNUC, sinonasal undifferentiated carcinoma; SmCC, sinonasal small cell carcinoma; DSS, Disease-Specific Survival.

* Corresponding author at: Department of Otorhinolaryngology/Head and Neck Surgery, University of Groningen, University Medical Center Groningen, P.O. Box 30.001, 9700RB Groningen, The Netherlands.

E-mail address: g.b.halmos@umcg.nl (G.B. Halmos).

<http://dx.doi.org/10.1016/j.oraloncology.2016.10.002>

1368-8375/© 2016 The Authors. Published by Elsevier Ltd.

This is an open access article under the CC BY license (<http://creativecommons.org/licenses/by/4.0/>).

more benign nature, yields reasonable results [3]. However, for SNC no clear guidelines are available and treatment outcome remains both variable and poor. Individual studies have shown large differences in response to treatment and prognosis between SNEC, SNUC, and SmCC and, more recently, have advocated the use of multimodality therapy in order to improve survival [4,5]. While valuable, these studies suffer from small sample size due to the rare nature of these tumors. This makes it hard to estimate the contribution of individual treatment modalities to treatment outcome, especially considering the possibility that treatment response might differ between tumor subtypes.

The aim of this meta-analysis was to provide treatment guidelines for SNC by combining all available data concerning factors influencing treatment response and survival in the literature.

Material and methods

A literature search for all clinical research concerning SNC was performed against the MEDLINE and EMBASE databases. The following combination of search terms was used: 'neuroendocrine carcinoma/tumor', 'undifferentiated carcinoma/tumor', 'small cell carcinoma/tumor', 'oat cell carcinoma/tumor', or 'carcinoid (tumor)' in combination with either 'nasal', 'sinonasal', 'paranasal (sinuses)', 'sinus(es)', 'ethmoid (sinus)', 'frontal (sinus)', 'maxillary (sinus)' or 'sphenoid (sinus)'. Full text copies of all relevant articles in English were retrieved and checked for references. When available, English abstracts of non-English articles containing relevant data were included. Articles and abstracts not containing (original) clinical data or compound data were discarded. The following variables were extracted from the remainder: age at diagnosis, gender, tumor type, tumor stage, ectopic hormone production, treatment and survival. If not reported, the tumor stage was determined using the TNM staging system. Duplicate cases were removed. Cases were divided in two cohorts in order to allow for analysis of trends over time: those reported before 2006 and those reported thereafter, effectively dividing the number of cases per cohort in two equal proportions. Statistical analysis was performed using IBM SPSS Statistics 22 for Microsoft Windows (Armonk, NY). Age was compared using the median test. Categorical data were analyzed using the exact chi-square test. Survival data were calculated

using the Kaplan-Meier estimator. Uni- and multivariate analysis was performed using the Cox proportional hazards model (enter method). Alpha was set at 0.05. Reported confidence intervals are for 95% probability.

Results

After discarding articles not including original clinical data or compound data, a total of 171 articles remained available for analysis [4–174]. Full text copies were available for 167 of these. Abstracts containing clinical data were included for five articles not in English [39,73,92,159,162] and one in English [168], yielding a total of 701 cases.

Patient characteristics

Patient characteristics are presented in Table 1. Most cases were classified as SNUC (459, 65.5%), followed by SNEC (127, 18.1%) and SmCC (115, 16.4%). The median age on presentation for all SNC was 53 years (range 12–89). Overall there was a male gender predilection (64.6%). The tumor stage on presentation was stage IV in 75.0% of cases. However, this distribution significantly differed amongst tumor types, with SNEC presenting with stage IV in 57.1% of cases, SmCC in 70.4% and SNUC in 80.6% ($p < 0.001$). It was not possible to reliably infer the original tumor location from the available data as most patients presented with advanced disease.

Treatment consisted of multimodality therapy in the majority of cases treated with curative intent (73.7%). Overall, radiotherapy was the most frequently employed modality in these patients with 84.3%, followed by 61.4% for chemotherapy and 60.2% for surgery. Combination therapy most often consisted of trimodality therapy (38.7%) or a combination of radiotherapy and chemotherapy (36.6%). The combination of surgery and radiotherapy was less often applied (22.7%). Only a small minority of patients was treated with a combination of surgery and chemotherapy (3.1%). There were significant differences in choice of treatment between subtypes. Compared to SNUC, SNEC and SmCC were more often treated with surgery as monotherapy (4.3% versus 24.4% and 17.4% respectively, $p < 0.001$). SNUC were more often treated with radiotherapy as monotherapy compared to SNEC and SmCC (12.4% versus 4.4%

Table 1
Patient characteristics of sinonasal neuroendocrine carcinoma. Bold numbers represent significant P-values ($P < 0.05$).

Variable	All (n = 701)	SNEC (n = 127)	SNUC (n = 459)	SmCC (n = 115)	P-value
Age (median, range)	53 (12–89)	50 (13–84)	53 (12–88)	56 (16–89)	0.023
Gender (male, %)	378 (64.6)	70 (56.9)	239 (68.7)	69 (60.5)	0.038
Tumor stage (%)					
Stage I	25 (5.0)	8 (10.4)	8 (2.5)	9 (9.2)	0.002
Stage II	38 (7.6)	15 (19.5)	10 (3.1)	13 (13.3)	<0.001
Stage III	61 (12.2)	10 (13.0)	45 (13.8)	6 (6.1)	0.125
Stage IV	375 (75.0)	44 (57.1)	262 (80.6)	69 (70.4)	<0.001
Stage IVA	116 (23.3)	16 (20.8)	67 (20.7)	33 (33.7)	0.025
Stage IVB	147 (29.5)	22 (28.6)	104 (32.2)	21 (21.4)	0.116
Stage IVC	22 (4.4)	2 (2.6)	17 (5.2)	3 (3.1)	0.480
Treatment (%)					
Surgery	56 (10.3)	22 (24.4)	15 (4.3)	19 (17.4)	<0.001
Radiotherapy	52 (9.5)	4 (4.4)	43 (12.4)	5 (4.6)	0.011
Chemotherapy	12 (2.2)	0 (0.0)	7 (2.0)	5 (4.6)	0.080
Surgery & Radiotherapy	88 (16.1)	22 (24.4)	54 (15.6)	12 (11.0)	0.033
Surgery & Chemotherapy	12 (2.2)	3 (3.3)	2 (0.6)	7 (6.4)	0.006
Surgery & Radiotherapy & Chemotherapy	150 (27.5)	16 (17.8)	110 (31.7)	24 (22.0)	0.015
Radiotherapy & Chemotherapy	138 (25.3)	21 (23.3)	85 (24.5)	32 (29.4)	0.546
Palliative care	38 (7.0)	2 (2.2)	31 (8.9)	5 (4.6)	0.044
Median disease specific survival	36 (27–45)	174 (69–279)	28 (23–33)	22 (6–38)	<0.001
Median overall survival	32 (25–39)	120 (55–185)	25 (21–29)	22 (14–30)	<0.001

SNEC, well or moderately differentiated sinonasal neuroendocrine carcinoma; SNUC, sinonasal undifferentiated carcinoma; SmCC, sinonasal small cell carcinoma.

and 4.6% respectively, $p = 0.011$), while SNEC were more frequently treated with surgery combined with radiotherapy (24.4% versus 15.6% for SNUC and 11.0% for SmCC, $p = 0.033$). SNUC was rarely managed with a combination of surgery and chemotherapy (0.6% versus 3.3% for SNEC and 6.4% for SmCC, $p = 0.006$), but more often treated with a trimodality approach compared to the other groups (31.7% versus 17.8% for SNEC and 22.0% for SmCC, $p = 0.015$).

Ectopic hormone production

Ectopic hormone production was described in ten cases (1.4%) [9,15,29,57,75,91,110,172]. These cases concerned patients with SNEC or SmCC with elevated levels of ACTH, beta-MSH, calcitonin, serotonin or ADH.

Survival

The median disease-specific survival (DSS) for SNEC was 36 months (CI 27–45) and the overall survival 32 months (CI, 25–39). Fig. 1A displays the influence of tumor type on DSS. SNEC performed significantly better with a 5-year DSS of 70.2% compared to 35.9% for SNUC and 46.1% for SmCC ($p < 0.001$). There was no significant difference between the 5-year DSS of SNUC and SmCC ($p = 0.792$). Comparable results were produced by the univariate analysis presented in Table 2. Overall, tumor stage did not significantly affect survival as shown in Fig. 1B. Similar results were produced when correcting for tumor type. The univariate analysis yielded varying results, with no significant difference in odds ratio (OR) between stage IVA and stage I disease (CI OR, 0.0871–5.607, $p = 0.095$).

Fig. 2 displays an exploratory analysis of the influence of different treatment modalities on DSS. Overall, only surgery had a significant effect on 5-year DSS with 52.2% for patients treated with surgery versus 30.1% for those without ($p < 0.001$).

While there was a trend favoring surgery in SNEC, no significant difference could be observed ($p = 0.077$). Radiotherapy did not yield better results in these patients ($p = 0.199$), while the application of chemotherapy was associated with a significantly unfavorable outcome (5-year DSS of 55.7% versus 82.2%, $p = 0.029$).

Both surgery and radiotherapy were associated with significantly better outcome in patients with SNUC (5-year DSS of 42.2% versus 26.9%, $p < 0.001$, and 38.0% versus 10.6%, $p = 0.008$, respectively). The application of chemotherapy did not improve survival in these patient (5-year DSS of 36.6% versus 33.3%, $p = 0.782$).

Table 2

Univariate analysis of factors influencing the disease-specific survival of sinonasal neuroendocrine carcinoma. Bold numbers represent significant P-values ($P < 0.05$).

Factor	OR (95% CI)	P-value
Age	1.009 (1.001–1.017)	0.019
Gender (male as reference)	0.874 (0.660–1.159)	0.351
Tumor type		
SNEC	1 (reference)	
SNUC	2.601 (1.783–3.794)	<0.001
SmCC	2.410 (1.539–3.774)	<0.001
Tumor stage		
Stage I	1 (reference)	
Stage II	2.152 (0.781–5.930)	0.139
Stage III	3.672 (1.425–9.460)	0.007
Stage IV	3.663 (1.462–9.180)	0.006
Stage IVA	2.210 (0.871–5.607)	0.095
Stage IVB	3.050 (1.224–7.597)	0.017
Stage IVC	7.612 (2.695–21.499)	<0.001
Treatment (decoupled, no as reference)		
Surgery	0.521 (0.400–0.677)	0.000
Radiotherapy	0.898 (0.631–1.279)	0.898
Chemotherapy	1.243 (0.944–1.636)	0.121
Treatment		
Surgery	1 (reference)	
Radiotherapy	2.261 (1.329–3.847)	0.003
Chemotherapy	6.182 (2.803–13.633)	<0.001
Surgery & Radiotherapy	0.779 (0.444–1.366)	0.383
Surgery & Chemotherapy	1.810 (0.801–4.090)	0.154
Surgery & Radiotherapy & Chemotherapy	1.052 (0.638–1.735)	0.905
Radiotherapy & Chemotherapy	1.712 (1.050–2.791)	0.031
Palliative care	15.769 (7.408–33.567)	<0.001

OR, odds ratio; CI, confidence interval; SNEC, well or moderately differentiated sinonasal neuroendocrine carcinoma; SNUC, sinonasal undifferentiated carcinoma; SmCC, sinonasal small cell carcinoma.

While not significant, surgery appeared to have a beneficial effect on treatment outcome in patients with SmCC (5-year DSS of 53.9% versus 32.0%, $p = 0.077$), while no difference in outcome could be observed for radiotherapy and chemotherapy (5-year DSS of 50.1% for patients treated with radiotherapy versus 39.6% for those without, $p = 0.287$ and 42.6% for patients treated with chemotherapy versus 52.9% for those without, $p = 0.287$ respectively).

A multivariate analysis of the influence of treatment (combinations) correcting for age on diagnosis and tumor stage on presentation is presented in Table 3. Patients with SNEC treated without

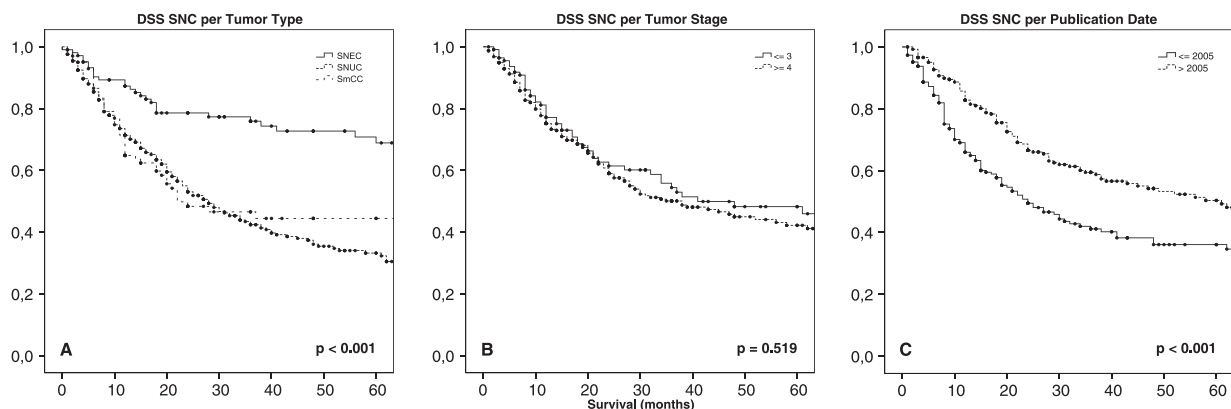


Fig. 1. Disease-specific survival (DSS) of sinonasal neuroendocrine carcinoma (SNC) per tumor type, stage and publication date. SNEC, well or moderately differentiated sinonasal neuroendocrine carcinoma; SNUC, sinonasal undifferentiated carcinoma; SmCC, sinonasal small cell carcinoma.

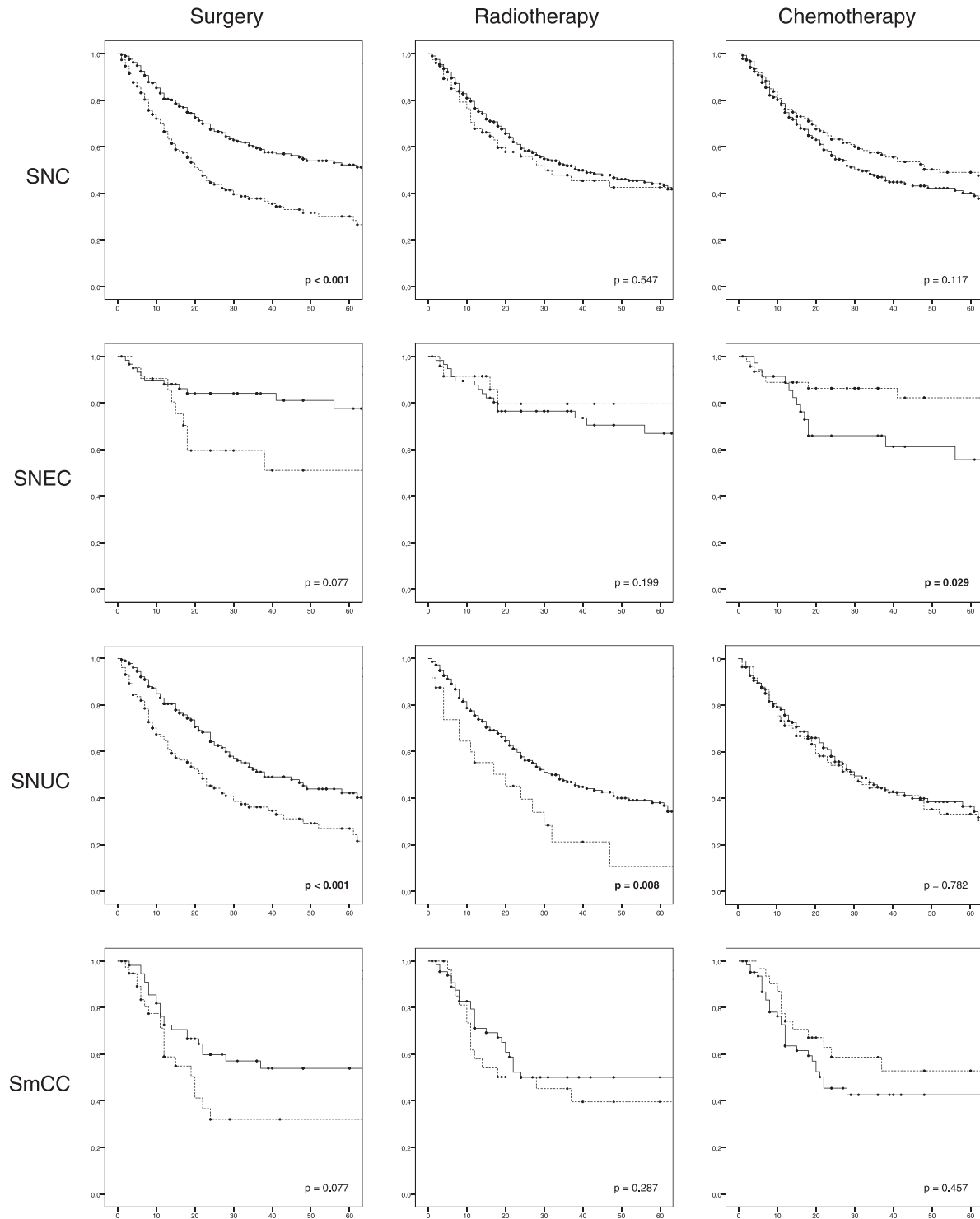


Fig. 2. Disease-specific survival of sinonasal neuroendocrine carcinoma (SNC) per tumor type and treatment modality. The straight line represents the cohort in which the treatment modality was applied. Survival in months. SNEC, well or moderately differentiated sinonasal neuroendocrine carcinoma; SNUC, sinonasal undifferentiated carcinoma; SmCC, sinonasal small cell carcinoma.

surgery had a significantly higher change of dying of disease (OR 11.464, CI 1.125–116.796, $p = 0.039$). No advantage from multimodality therapy could be inferred from this analysis. For SNUC, patients treated with a combination of surgery and radiotherapy, with or without chemotherapy, had better outcome than those treated with surgery alone (OR 0.337, CI 0.0125–0.908, $p = 0.032$ and OR 0.368, CI 0.147–0.921, $p = 0.033$ respectively). Chemotherapy as monotherapy yielded a significantly higher OR in patients

with SmCC (6.964, CI 1.104–43.930), while none of the other treatment (combinations) significantly differed from surgery as monotherapy.

5-Year DSS estimates per tumor type and treatment (combination) are presented in Table 4. Overall, the highest 5-year DSS was observed for the combination of surgery and radiotherapy (64.0%). For SNEC surgery as monotherapy produced the most favorable results (5-year DSS 83.3%). SNUC and SmCC responded best to a

Table 3

Multivariate analysis of factors^a influencing the disease-specific survival of sinonasal neuroendocrine carcinoma treated with curative intent per tumor type. Bold numbers represent significant P-values (P < 0.05).

Factor	OR (95% CI)	P-value
<i>Well or moderately differentiated sinonasal neuroendocrine carcinoma</i>		
Surgery	1 (reference)	
Radiotherapy	–	–
Chemotherapy	–	–
Surgery & Radiotherapy	4.604 (0.514–41.212)	0.172
Surgery & Chemotherapy	6.950 (0.355–135.961)	0.201
Surgery & Radiotherapy & Chemotherapy	4.804 (0.370–62.430)	0.230
Radiotherapy & Chemotherapy	11.464 (1.125–116.796)	0.039
<i>Sinonasal undifferentiated carcinoma</i>		
Surgery	1 (reference)	
Radiotherapy	0.643 (0.254–1.632)	0.353
Chemotherapy	1.644 (0.443–6.105)	0.458
Surgery & Radiotherapy	0.337 (0.125–0.908)	0.032
Surgery & Chemotherapy	3.164 (0.359–27.890)	0.300
Surgery & Radiotherapy & Chemotherapy	0.368 (0.147–0.921)	0.033
Radiotherapy & Chemotherapy	0.471 (0.185–1.200)	0.115
<i>Sinonasal small cell carcinoma</i>		
Surgery	1 (reference)	
Radiotherapy	3.669 (0.677–19.900)	0.132
Chemotherapy	6.964 (1.104–43.930)	0.039
Surgery & Radiotherapy	0.529 (0.123–2.278)	0.393
Surgery & Chemotherapy	1.057 (0.239–4.669)	0.942
Surgery & Radiotherapy & Chemotherapy	0.811 (0.234–2.806)	0.741
Radiotherapy & Chemotherapy	1.078 (0.370–3.146)	0.890

OR, odds ratio; CI, confidence interval. Reported odds ratios for patient dying of disease.

^a Not shown but included in the models are the factors age and tumor stage. Both of which did not reach significance in any of the models.

combination of surgery and radiotherapy (5-year DSS of 54.7% and 71.3% respectively).

Trends over time

As shown in Fig. 1C, cases reported after 2006 show improved outcome compared to those reported before this date (5-year DSS of 50.4% versus 36.1%, $p < 0.001$). This trend was present for all tumor types, although only SNUC remained significant after sub-analysis ($p = 0.001$). Patients with SNUC, reported before 2006, were more often treated with radiotherapy as monotherapy (21.1% versus 4.3%), while those reported after 2006 were more often treated with a combination of surgery and radiotherapy with or without chemotherapy (65.9% versus 40.6%).

Discussion

Synopsis

This study offers the most comprehensive overview of knowledge concerning SNC available today by pooling all available cases

published in the literature. It is clear from our data, that prognosis is primarily determined by histological subtype and thus differentiation grade, rather than by TNM classification. Overall, SNEC have a reasonable prognosis, with a 5-year DSS of about 70%, while SNUC and SmCC perform poorly with a 5-year DSS of approximately 40%. Surgery should be the cornerstone of treatment as it was associated with improved outcome, regardless of its combination with other treatment modalities or tumor subtype. Postoperative radiotherapy should be applied in patients with SNUC or SmCC.

Classification

As noted in the introduction, the nomenclature of SNC applied in the literature is both confusing and ambiguous. This is a common problem concerning neuroendocrine carcinoma of the head and neck, as evidenced by the diverse terminology used for their more common laryngeal counterparts [175]. In 2002, Mills already recognized the similarities between (the subtypes of) neuroendocrine carcinoma of the head and neck of different locations and suggested that SNUC was probably best recognized as the equivalent of the large cell neuroendocrine carcinoma of the larynx [176]. While similar tumors in different locations may behave differently and require a different treatment approach, certain similarities are lost in translation. This is crucial problem, as it is clear from our data that the histological diagnosis is the single most important factor influencing response to treatment and survival.

In order to solve this problem in laryngeal neuroendocrine carcinoma (LNC), Lewis et al. proposed to adopt the classification system of pulmonary neuroendocrine carcinoma, in which neuroendocrine carcinoma are classified based on differentiation grade [175]. We suggest extending this classification to SNC as well, additionally labeling poorly differentiated SNC A for small and B for large cell features (Table 5). Unifying the classification system for neuroendocrine carcinoma of the head and neck would yield a more intuitive way of thinking about these neoplasms and prevent relevant data from not being taken into consideration due to semantic deficiencies.

Tumor stage on presentation

Sinonasal malignancies often present at an advanced stage due to the lack of disconcerting symptoms. This reduces the value of the TNM classification system (or any other classification system for that matter) in predicting prognosis and aiding in treatment selection. This holds true for SNC as well, with 75.0% of patients presenting with stage IV disease. In patients presenting with early stage disease the TNM classification remains of poor value as univariate analysis revealed that patients with stage III disease had a higher OR for dying of disease compared to patients with stage IVA disease (3.672 versus 2.210), while no significant difference in OR could be observed between stage I and stage IVA disease. A similar

Table 4

5-year disease-specific survival estimates of sinonasal neuroendocrine carcinoma per tumor type and treatment (combination) of patients treated with curative intent.

Treatment	All	SNEC	SNUC	SmCC
All	43.9 (2.8)	70.2 (5.9)	35.9 (3.5)	46.1 (5.9)
Surgery	52.7 (8.3)	83.3 (9.0)	15.7 (13.1)	52.1 (13.9)
Radiotherapy	22.7 (7.3)	100.0 (–)	17.9 (7.1)	0.0 (0.0)
Chemotherapy	0.0 (0.0)	–	0.0 (0.0)	0.0 (0.0)
Surgery & Radiotherapy	64.0 (6.4)	77.9 (10.2)	54.7 (9.2)	71.3 (14.1)
Surgery & Chemotherapy	30.0 (14.0)	66.7 (27.2)	0.0 (0.0)	28.6 (17.1)
Surgery & Radiotherapy & Chemotherapy	47.0 (5.6)	73.8 (13.8)	40.2 (6.8)	57.6 (11.6)
Radiotherapy & Chemotherapy	36.3 (5.4)	39.2 (13.5)	40.2 (6.8)	39.9 (10.9)

SNEC, well or moderately differentiated sinonasal neuroendocrine carcinoma; SNUC, sinonasal undifferentiated carcinoma; and SmCC, sinonasal small cell carcinoma.

Table 5
Classification schemes for sinonasal neuroendocrine carcinoma.

Legacy terminology	Common abbreviation	Differentiation grade	Cell size	Proposed terminology
Carcinoid	SNEC	Well	–	Grade I
Atypical carcinoid	SNEC	Moderate	–	Grade II
Small cell (neuroendocrine) carcinoma	SmCC	Poor	Small	Grade IIIA
Sinonasal undifferentiated carcinoma	SNUC	Poor	Moderate to large	Grade IIIB

pattern is seen in LNC and can probably be attributed to a high propensity for recurrence and early distant metastasis [177]. Due to the nature of the data and the confusing outcome of the resulting analyses, the relationship between tumor stage on presentation and survival remains uncertain. However, as patients with limited disease potentially have a similar prognosis to those with advanced disease, we think that treatment strategy should not be influenced by this factor, except in specific cases in which isolated lesions can be excised and surgical margins evaluated properly.

Ectopic hormone production

The incidence of ectopic hormone production is likely higher than the reported 1.4% due to under-diagnosis and under-reporting. However, only a small number of patients presented with clinical features in the form of the associated paraneoplastic syndrome and it remains unclear whether routine tests should be incorporated in the work-up of these patients.

Treatment and survival

Due to the nature of the study care should be taken in interpreting the resulting analyses. Incomplete data results in some seemingly contradictory figures (e.a. an overall survival estimate that is lower than the disease-specific survival). However, by including these data points we utilize the available information to its fullest and are able to provide estimates that are as close to reality as possible.

While decoupling the combination of treatment modalities introduces an obvious bias, Fig. 2 allows for an exploratory analysis of the contribution of different treatment modalities to treatment outcome. Combined with the results from the uni- and multivariate analysis, and the 5-year DSS per tumor subtype and treatment (combination) presented in Table 4 a general pattern can be observed.

It appears clear that, irrespective of the histological diagnosis, surgery has a beneficial effect on survival and should be the cornerstone of any treatment strategy. This is supported by both the univariate and multivariate analyses in which treatment (combinations) incorporating surgery produced the best results with the exception of four patients with a SNEC who were successfully treated with radiotherapy as monotherapy. It is unfortunate that most authors do not make a distinction between well and moderately differentiated SNEC as the former could probably be treated by surgery alone while the latter may require a more aggressive approach incorporating postoperative radiotherapy.

Radiotherapy appeared especially beneficial in patients with SNUC, but only if combined with surgery. In fact, the combination of surgery and radiotherapy with or without chemotherapy yielded a significantly lower OR for patients dying of disease in the multivariate analysis (0.337, CI 0.125–0.908 and 0.368, CI 0.147–0.921 respectively), making it the de facto treatment strategy for this group. Radiotherapy as monotherapy performed poorly with the exception of the four patients mentioned above (5-year DSS of 17.9% for SNUC and 0.0% for SmCC) and should not be performed in curative setting.

No benefit from the application of chemotherapy could be deduced from our results. Chemotherapy as monotherapy had the worst 5-year DSS, with no patients surviving regardless of tumor subtype.

The improvement in treatment outcome over time is best explained by the shift towards multimodality therapy as advocated by several authors. Especially the abandonment of radiotherapy as monotherapy appears to have contributed to improved survival. Furthermore, the advance of treatment modalities, e.a. the introduction of image guided surgery, could have positively affected treatment outcome in the last decade.

Conclusions

This article presents a near complete overview of all available data concerning SNC. It offers a basic understanding of their clinical behavior and a general direction for deciding on a treatment strategy. While the nature of the data does not allow for definite treatment guidelines, certain overall conclusions and recommendations can be made.

It is clear that a proper histological diagnosis with emphasis on differentiation grade is of paramount importance in predicting prognosis and treatment response in SNC. Well and moderately differentiated SNC perform significantly better and may require a less aggressive treatment approach than their poorly differentiated counterparts. However, no strong recommendations can be made in this regard, due to semantic deficiencies in the literature. Therefore, we strongly advocate the application of a uniform classification system for neuroendocrine carcinoma of the head and neck.

As we are unable to reliably infer the relationship between tumor stage on presentation and survival from our data, we feel caution is justified in taking a more conservative approach in treating patients with early stage disease.

Surgery should be the cornerstone of any treatment strategy with curative intent, supplemented by radiotherapy in poorly (and perhaps moderately) differentiated subtypes. Chemotherapy does not appear to contribute to survival.

Overcoming the limitations of this study would require a long term multi-center clinical trial. Until such a study is performed we have to rely on fragmented data such as presented in this paper. Therefore, we encourage institutions to keep publishing their experiences with these rare neoplasms.

Conflict of interest statement

None declared.

Acknowledgement

This research did not receive any specific grant from funding agencies in the public, commercial, or not-for-profit sectors.

References

- [1] Mitchell EH, Diaz A, Yilmaz T, Roberts D, Levine N, DeMonte F, et al. Multimodality treatment for sinonasal neuroendocrine carcinoma. *Head Neck* 2012;34:1372–6.

- [2] Rosenthal DI, Barker Jr JL, El-Naggar AK, Glisson BS, Kies MS, Diaz Jr EM, et al. Sinonasal malignancies with neuroendocrine differentiation: patterns of failure according to histologic phenotype. *Cancer* 2004;101:2567–73.
- [3] Dulguerov P, Allal AS, Calcaterra TC. Esthesioneuroblastoma: a meta-analysis and review. *Lancet Oncol* 2001;2:683–90.
- [4] Fried D, Zanation AM, Huang B, Hayes N, Morris DE, Rosenman J, et al. Management of nonesthesioneuroblastoma sinonasal malignancies with neuroendocrine differentiation. *Laryngoscope* 2012;122:2210–5.
- [5] van der Laan TP, Bijl HP, van Hemel BM, Plaat BE, Wedman J, van der Laan BF, et al. The importance of multimodality therapy in the treatment of sinonasal neuroendocrine carcinoma. *Eur Arch Otorhinolaryngol* 2013;270:2565–8.
- [6] Raychowdhuri RN. Oat-cell carcinoma and paranasal sinuses. *J Laryngol Otol* 1965;79:253–5.
- [7] Koss LG, Spiro RH, Hajdu S. Small cell (oat cell) carcinoma of minor salivary gland origin. *Cancer* 1972;30:737–41.
- [8] Hartenian KM, Stenger TG. Carcinoma of the maxillary sinus: report of case. *J Oral Surg* 1978;36:898–901.
- [9] Kameya T, Shimosato Y, Adachi I, Abe K, Ebihara S, Ono I. Neuroendocrine carcinoma of the paranasal sinus: a morphological and endocrinological study. *Cancer* 1980;45:330–9.
- [10] Rejowski JE, Campanella RS, Block LJ. Small cell carcinoma of the nose and paranasal sinuses. *Otolaryngol Head Neck Surg* 1982;90:516–7.
- [11] Sriumpai S, Dharamadhach A. Carcinoid tumor of the maxillary antrum: a case report. *J Med Assoc Thai* 1982;65:45–122.
- [12] Weiss MD, deFries HO, Taxy JB, Braine H. Primary small cell carcinoma of the paranasal sinuses. *Arch Otolaryngol* 1983;109:341–3.
- [13] Siwersson U, Kindblom LG. Oncocytic carcinoid of the nasal cavity and carcinoid of the lung in a child. *Pathol Res Pract* 1984;178:562–9.
- [14] Contrucci RB, Holmes WF, Heffron T. Neuroendocrine tumors of the nose and upper airway. *Ear Nose Throat J* 1985;64:235–8.
- [15] Werner S, Jacobsson B, Boström L, Curstedt T, Weger A, Biberfeld P. Cushing's syndrome due to an ACTH-producing neuroendocrine tumour in the nasal roof. *Acta Med Scand* 1985;217:235–40.
- [16] Baugh RF, Wolf GT, McClatchey KD. Small cell carcinoma of the head and neck. *Head Neck Surg* 1986;8:343–54.
- [17] Frierson Jr HF, Mills SE, Fechner RE, Taxy JB, Levine PA. Sinonasal undifferentiated carcinoma. An aggressive neoplasm derived from schneiderian epithelium and distinct from olfactory neuroblastoma. *Am J Surg Pathol* 1986;10:771–9.
- [18] Helliwell TR, Yeoh LH, Stell PM. Anaplastic carcinoma of the nose and paranasal sinuses. Light microscopy, immunohistochemistry and clinical correlation. *Cancer* 1986;58:2038–45.
- [19] Frierson Jr HF, Ross GW, Stewart FM, Newman SA, Kelly MD. Unusual sinonasal small-cell neoplasms following radiotherapy for bilateral retinoblastomas. *Am J Surg Pathol* 1989;13:947–54.
- [20] Janjan NA, Campbell B, Wilson JF, Zellmer D. Small cell undifferentiated carcinoma of the maxillary sinus: technical considerations for radiation therapy. *Med Dosim* 1989;14:273–6.
- [21] Stewart FM, Lazarus HM, Levine PA, Stewart KA, Tabbara IA, Spaulding CA. High-dose chemotherapy and autologous marrow transplantation for esthesioneuroblastoma and sinonasal undifferentiated carcinoma. *Am J Clin Oncol* 1989;12:217–21.
- [22] Greger V, Schirmacher P, Bohl J, Bornemann A, Hürter T, Passarge E, et al. Possible involvement of the retinoblastoma gene in undifferentiated sinonasal carcinoma. *Cancer* 1990;66:1954–9.
- [23] Soussi AC, Benghiat A, Holgate CS, Majumdar B. Neuro-endocrine tumours of the head and neck. *J Laryngol Otol* 1990;104:504–7.
- [24] Lloreta-Trull J, Mackay B, Troncoso P, Ribalta-Farres T, Smith T, Khorana S. Neuroendocrine tumors of the nasal cavity: an ultrastructural and morphometric study of 24 cases. *Ultrastruct Pathol* 1992;16:165–75.
- [25] Saw D, Chan JK, Jagirdar J, Greco MA, Lee M. Sinonasal small cell neoplasm developing after radiation therapy for retinoblastoma: an immunohistologic, ultrastructural, and cytogenetic study. *Hum Pathol* 1992;23:896–9.
- [26] Deutsch BD, Levine PA, Stewart FM, Frierson Jr HF, Cantrell RW. Sinonasal undifferentiated carcinoma: a ray of hope. *Otolaryngol Head Neck Surg* 1993;108:697–700.
- [27] Gallo O, Graziani P, Fini-Storchi O. Undifferentiated carcinoma of the nose and paranasal sinuses. An immunohistochemical and clinical study. *Ear Nose Throat J* 1993;72(588–90):593–5.
- [28] Ogawa T, Nishioka K, Nakagawa MF, Manabe T, Asano T, Nishio S, et al. A case of carcinoid tumor in the sphenoid sinus. *Practica oto-rhino-laryngologica* 1993;Supp64:106–12.
- [29] Pierce ST, Cibul ML, Metcalfe MS, Sloan D. Bone marrow metastases from small cell cancer of the head and neck. *Head Neck* 1994;16:266–71.
- [30] Ascaso FJ, Adiego MI, Garcia J, Royo J, Valles H, Palomar A, et al. Sinonasal undifferentiated carcinoma invading the orbit. *Eur J Ophthalmol* 1994;4:234–6.
- [31] Chaudhry MR, Akhtar S, Kim DS. Neuroendocrine carcinoma of the ethmoid sinus. *Eur Arch Otorhinolaryngol* 1994;251:461–3.
- [32] Lo Re G, Canzonieri V, Veronesi A, Dal Bo V, Barzan L, Zancanaro C, et al. Extrapulmonary small cell carcinoma: a single-institution experience and review of the literature. *Ann Oncol* 1994;5:909–13.
- [33] Lopategui JR, Gaffey MJ, Frierson Jr HF, Chan JK, Mills SE, Chang KL, et al. Detection of Epstein-Barr viral RNA in sinonasal undifferentiated carcinoma from Western and Asian patients. *Am J Surg Pathol* 1994;18:391–8.
- [34] Leung SY, Yuen ST, Chung LP, Kwong WK, Wong MP, Chan SY. Epstein-Barr virus is present in a wide histological spectrum of sinonasal carcinomas. *Am J Surg Pathol* 1995;19:994–1100.
- [35] McCluggage WG, Napier SS, Primrose WJ, Adair RA, Toner PG. Sinonasal neuroendocrine carcinoma exhibiting amphicrine differentiation. *Histopathology* 1995;27:79–82.
- [36] Pitman KT, Costantino PD, Lassen LF. Sinonasal undifferentiated carcinoma: current trends in treatment. *Skull Base Surg* 1995;5:269–72.
- [37] Austin JR, Cebrun H, Kershisnik MM, El-Naggar AK, Garden AS, Demonte F, et al. Olfactory neuroblastoma and neuroendocrine carcinoma of the anterior skull base: treatment results at the m.d. Anderson cancer center. *Skull Base Surg* 1996;6:1–8.
- [38] Righi PD, Francis F, Aron BS, Weitzner S, Wilson KM, Gluckman J. Sinonasal undifferentiated carcinoma: a 10-year experience. *Am J Otolaryngol* 1996;17:167–71.
- [39] Takahashi N, Tsukuda M, Mochimatsu I, Furukawa M, Matsuda H. Neuroendocrine carcinomas of the head and neck. *Nihon Jibiinkoka Gakkai Kaiho* 1996;99:567–75.
- [40] Yang YJ, Abraham JL. Undifferentiated carcinoma arising in oncocytic Schneiderian (cylindrical cell) papilloma. *J Oral Maxillofac Surg* 1997;55:289–94.
- [41] Perez-Ordóñez B, Caruana SM, Huvos AG, Shah JP. Small cell neuroendocrine carcinoma of the nasal cavity and paranasal sinuses. *Hum Pathol* 1998;29:826–32.
- [42] Heib C, Grüning H, Stasche N. Atypical localization of a small cell carcinoma in the paranasal sinus area—case report. *Laryngorhinotologie* 1998;77:394–7.
- [43] Houston GD. Sinonasal undifferentiated carcinoma: report of two cases and review of the literature. *Oral Surg Oral Med Oral Pathol Oral Radiol Endod* 1998;85:185–8.
- [44] Kerrebijn JD, Tietze L, Mock D, Freeman JL. Sinonasal undifferentiated carcinoma. *J Otolaryngol* 1998;27:40–2.
- [45] Waldron JN, O'Sullivan B, Warde P, Gullane P, Lui FF, Payne D, et al. Ethmoid sinus cancer: twenty-nine cases managed with primary radiation therapy. *Int J Radiat Oncol Biol Phys* 1998;41:361–9.
- [46] Chen CL, Hsu MM. Second primary epithelial malignancy of nasopharynx and nasal cavity after successful curative radiation therapy of nasopharyngeal carcinoma. *Hum Pathol* 2000;31:227–32.
- [47] Eusebi V, Damiani S, Pasquinelli G, Lorenzini P, Reuter VE, Rosai J. Small cell neuroendocrine carcinoma with skeletal muscle differentiation: report of three cases. *Am J Surg Pathol* 2000;24:223–30.
- [48] Gorelick J, Ross D, Marentette L, Blaivas M. Sinonasal undifferentiated carcinoma: case series and review of the literature. *Neurosurgery* 2000;47:750–4.
- [49] Kanamalla US, Kesava PP, McGuff HS. Imaging of nonlaryngeal neuroendocrine carcinoma. *AJNR Am J Neuroradiol* 2000;21:775–8.
- [50] Lee AG, Chokshi A, Goodman JC. Neuro-ophthalmologic manifestations of neuroendocrine carcinoma. *J Neuroophthalmol* 2000;20:106–10.
- [51] Miyamoto RC, Gleich LL, Biddinger PW, Gluckman JL. Esthesioneuroblastoma and sinonasal undifferentiated carcinoma: impact of histological grading and clinical staging on survival and prognosis. *Laryngoscope* 2000;110:1262–5.
- [52] Nayak DR, Hazarika P, Gopal A, Sharma S, Rau S. Recurrent metastasi zing neuroendocrine tumor of paranasal sinuses. *Indian J Otolaryngol Head Neck Surg* 2000;52:259–60.
- [53] Smith SR, Som P, Fahmy A, Lawson W, Sacks S, Brandwein M. A clinicopathological study of sinonasal neuroendocrine carcinoma and sinonasal undifferentiated carcinoma. *Laryngoscope* 2000;110:1617–22.
- [54] Cerilli LA, Holst VA, Brandwein MS, Stoler MH, Mills SE. Sinonasal undifferentiated carcinoma: immunohistochemical profile and lack of EBV association. *Am J Surg Pathol* 2001;25:156–63.
- [55] Galera-Ruiz H, Villar-Rodríguez JL, Sanchez-Calzado JA, Martín-Mora J, Ruiz-Carmona E. Sinonasal neuroendocrine carcinoma presenting as a nasopharyngeal mass. *Otolaryngol Head Neck Surg* 2001;124:475–6.
- [56] Ghosh S, Weiss M, Streeter O, Sinha U, Commins D, Chen TC. Drop metastasis from sinonasal undifferentiated carcinoma: clinical implications. *Spine (Phila Pa 1976)* 2001;26:1486–91.
- [57] Mineta H, Miura K, Takebayashi S, Araki K, Ueda Y, Harada H, et al. Immunohistochemical analysis of small cell carcinoma of the head and neck: a report of four patients and a review of sixteen patients in the literature with ectopic hormone production. *Ann Otol Rhinol Laryngol* 2001;110:76–82.
- [58] Sakamoto M, Nakamura K, Nishimura S. An alternative therapeutic procedure for sinonasal undifferentiated carcinoma. *Eur Arch Otorhinolaryngol* 2001;258:226–9.
- [59] Sharara N, Muller S, Olson J, Grist WJ, Grossniklaus HE. Sinonasal undifferentiated carcinoma with orbital invasion: report of three cases. *Ophthal Plast Reconstr Surg* 2001;17:288–92.
- [60] Westerveld GJ, van Diest PJ, van Nieuwkerk EB. Neuroendocrine carcinoma of the sphenoid sinus: a case report. *Rhinology* 2001;39:52–4.
- [61] Cohen ZR, Marmor E, Fuller GN, DeMonte F. Misdiagnosis of olfactory neuroblastoma. *Neurosurg Focus* 2002;12:e3.
- [62] Jeng YM, Sung MT, Fang CL, Huang HY, Mao TL, Cheng W, et al. Sinonasal undifferentiated carcinoma and nasopharyngeal-type undifferentiated carcinoma: two clinically, biologically, and histopathologically distinct entities. *Am J Surg Pathol* 2002;26:371–6.
- [63] Musy PY, Reibel JF, Levine PA. Sinonasal undifferentiated carcinoma: the search for a better outcome. *Laryngoscope* 2002;112:1450–5.

- [64] Noguchi K, Urade M, Sakurai K, Nishimura N, Hashitani S, Kishimoto H. Small cell neuroendocrine carcinoma of the maxillary sinus—a case report and nude mouse transplantable model. *Head Neck* 2002;24:491–6.
- [65] Rosenthal G, Gomori JM, Tobias S, Diment J, Shoshan Y. Unusual cases involving the CNS and nasal sinuses: case 2. Sinonasal undifferentiated carcinoma. *J Clin Oncol* 2003;21:3877–80.
- [66] Watanabe K, Ogura G, Suzuki T. Intra-epithelial neuroendocrine carcinoma of the nasal cavity. *Pathol Int* 2003;53:396–400.
- [67] Avitia S, Osborne RF. Blindness: a sequela of sinonasal small cell neuroendocrine carcinoma. *Ear Nose Throat J* 2004;83(530):532.
- [68] Georgiou AF, Walker DM, Collins AP, Morgan GJ, Shannon JA, Veness MJ. Primary small cell undifferentiated (neuroendocrine) carcinoma of the maxillary sinus. *Oral Surg Oral Med Oral Pathol Oral Radiol Endod* 2004;98:572–8.
- [69] Kim BS, Vongtama R, Juillard G. Sinonasal undifferentiated carcinoma: case series and literature review. *Am J Otolaryngol* 2004;25:162–6.
- [70] Kouri M, Kankaanranta L, Seppälä T, Tervo L, Rasilainen M, Minn H, et al. Undifferentiated sinonasal carcinoma may respond to single-fraction boron neutron capture therapy. *Radiother Oncol* 2004;72:83–5.
- [71] Kramer D, Durham JS, Sheehan F, Thomson T. Sinonasal undifferentiated carcinoma: case series and systematic review of the literature. *J Otolaryngol* 2004;33:32–6.
- [72] Liang BC, Chau YP, Lam DS, Chan NR. Undifferentiated sinonasal carcinoma with nasolacrimal duct obstruction. *Arch Ophthalmol* 2004;122:290–3.
- [73] Pino Rivero V, Montero García C, Marcos García M, Trinidad Ruiz G, Pardo Romero G, González Palomino A, et al. Sino-nasal undifferentiated carcinoma. Report of 1 case and literature review. *An Otorrinolaringol Ibero Am* 2004;31:325–31.
- [74] Rischin D, Porceddu S, Peters L, Martin J, Corry J, Weih L. Promising results with chemoradiation in patients with sinonasal undifferentiated carcinoma. *Head Neck* 2004;26:435–41.
- [75] Vasan NR, Medina JE, Canfield VA, Gillies EM. Sinonasal neuroendocrine carcinoma in association with SIADH. *Head Neck* 2004;26:89–93.
- [76] Madison Michael 2nd L, Sorenson JM, Samant S, Robertson JH. The treatment of advanced sinonasal malignancies with pre-operative intra-arterial cisplatin and concurrent radiation. *J Neurooncol* 2005;72:67–75.
- [77] Norleza AN, Gendeh BS. Challenges in the treatment of sinonasal undifferentiated carcinoma: a ray of hope. *Med J Malaysia* 2005;60:281–5.
- [78] Solares CA, Fakhri S, Batra PS, Lee J, Lanza DC. Transnasal endoscopic resection of lesions of the clivus: a preliminary report. *Laryngoscope* 2005;115:1917–22.
- [79] Babin E, Rouleau V, Vedrine PO, Toussaint B, de Raucourt D, Malard O, et al. Small cell neuroendocrine carcinoma of the nasal cavity and paranasal sinuses. *J Laryngol Otol* 2006;120:289–97.
- [80] Donald PJ. Sinonasal undifferentiated carcinoma with intracranial extension. *Skull Base* 2006;16:67–74.
- [81] Edwards PC, Hess SJ, Saini T. Sinonasal undifferentiated carcinoma of the maxillary sinus. *J Can Dent Assoc* 2006;72:163–7.
- [82] Esposito F, Kelly DF, Vinters HV, DeSalles AA, Sercarz J, Gorgulhos AA. Primary sphenoid sinus neoplasms: a report of four cases with common clinical presentation treated with transsphenoidal surgery and adjuvant therapies. *J Neurooncol* 2006;76:299–306.
- [83] Hakuba N, Hyodo M, Yokoi T, Sato H. Irinotecan (CPT-11) combined with cisplatin for small cell carcinoma of the nasal cavity. *Auris Nasus Larynx* 2006;33:67–70.
- [84] Kumar R, Chandra A, Rastogi A. Intracranial sinonasal undifferentiated carcinoma (SNUC) in a child. *Childs Nerv Syst* 2006;22:1208–11.
- [85] Loo CK, Chin M, Farrell M, Wu XJ. Sinonasal neuroendocrine carcinoma: case report with FNA findings. *Pathology* 2006;38:181–4.
- [86] Nishimura G, Sano D, Tanigaki Y, Taguchi T, Horiuchi C, Matsuda H, et al. Maxillary sinus carcinoma: the only symptom was neck lymph node swelling. *Auris Nasus Larynx* 2006;33:57–61.
- [87] Reichel O, Ihrler S, Born F, Andratschke M, Rasp G, Hagedorn H. Sinonasal undifferentiated carcinoma. A rare and aggressive neoplasm of the nasal cavity and paranasal sinuses. *HNO* 2006;54(394–6):398–9.
- [88] Gandeh BS. Recurrent small cell neuroendocrine carcinoma of the nasal cavity with co-existing right frontal cyst - a rare entity. *Pak J Otolaryngol* 2007;23:76–7.
- [89] González-García R, Fernández-Rodríguez T, Naval-Gías L, Rodríguez-Campo FJ, Nam-Cha SH, Díaz-González FJ, et al. Small cell neuroendocrine carcinoma of the sinonasal region. A propose of a case. *Br J Oral Maxillofac Surg* 2007;45:676–8.
- [90] Kajikawa H, Nario Kazuhiko, Miyahara Hiroshi. Carcinoid tumor in the paranasal sinus: a case report. *Practica Oto-Rhino-Laryngologica* 2007;7:533–7.
- [91] Lee DH, Cho HH, Cho YB. Typical carcinoid tumor of the nasal cavity. *Auris Nasus Larynx* 2007;34:537–9.
- [92] Rossi P, Suissa J, Bagnères D, Martin F, Edy E, Demoux AL, et al. Syndrome of inappropriate antidiuretic hormone secretion disclosing a sinonasal neuroendocrine carcinoma: case report. *Rev Med Interne* 2007;28:426–8.
- [93] Sobota A, Pena M, Santi M, Ali Ahmed A. Undifferentiated sinonasal carcinoma in a patient with nevoid basal cell carcinoma syndrome. *Int J Surg Pathol* 2007;15:303–6.
- [94] Tamhankar MA, Volpe NJ, Loevner LA, Palmer JN, Feldman M. Primary sinonasal undifferentiated carcinoma presenting with bilateral retrobulbar optic neuropathy. *J Neuroophthalmol* 2007;27:189–92.
- [95] Tarozzi M, Demarosi F, Lodi G, Sardella A, Carrassi A. Primary small cell carcinoma of the nasal cavity with an unusual oral manifestation. *J Oral Pathol Med* 2007;36:252–4.
- [96] Weinreb I, Perez-Ordoñez B. Non-small cell neuroendocrine carcinoma of the sinonasal tract and nasopharynx. Report of 2 cases and review of the literature. *Head Neck Pathol* 2007;1:21–6.
- [97] Bellizzi AM, Bourne TD, Mills SE, Stelow EB. The cytologic features of sinonasal undifferentiated carcinoma and olfactory neuroblastoma. *Am J Clin Pathol* 2008;129:367–76.
- [98] Bourne TD, Bellizzi AM, Stelow EB, Loy AH, Levine PA, Wick MR, et al. P63 Expression in olfactory neuroblastoma and other small cell tumors of the sinonasal tract. *Am J Clin Pathol* 2008;130:213–8.
- [99] De Simone P, Coletti L, Campani D, Falcone A, Filipponi F. Liver transplantation for metastatic sinonasal undifferentiated carcinoma: a case report. *Transplant Proc* 2008;40:3821–2.
- [100] Deviprasad S, Rajeshwari A, Tahir M, Adarsha TV, Gangadhara S. Small-cell neuroendocrine carcinoma originating from the lateral nasopharyngeal wall. *Ear Nose Throat J* 2008;87:E1–3.
- [101] Mendis D, Malik N. Sinonasal neuroendocrine carcinoma: a case report. *Ear Nose Throat J* 2008;87(280–2):293.
- [102] Renuka IV, Rao BS, Sasank R. Sinonasal neuro endocrine carcinoma extending into orbit - a case report. *Ind J Otolaryngol Head Neck Surg* 2008;60:156–8.
- [103] Schmidt ER, Berry RL. Diagnosis and treatment of sinonasal undifferentiated carcinoma: report of a case and review of the literature. *J Oral Maxillofac Surg* 2008;66:1505–10.
- [104] Spittelie PH, Jordan DR, Brownstein S, Gooi P, Burns B. Sinonasal undifferentiated carcinoma with a frozen globe. *Ophthal Plast Reconstr Surg* 2008;24:225–7.
- [105] Stelow EB, Bellizzi AM, Taneja K, Mills SE, Legallo RD, Kutok JL, et al. NUT rearrangement in undifferentiated carcinomas of the upper aerodigestive tract. *Am J Surg Pathol* 2008;32:828–34.
- [106] Tanzler ED, Morris CG, Orlando CA, Werning JW, Mendenhall WM. Management of sinonasal undifferentiated carcinoma. *Head Neck* 2008;30:595–9.
- [107] Wallace S, Pilon A, Kwok P, Messner LV, Hitchcock Y. Ophthalmic manifestations of an undifferentiated sinonasal carcinoma. *Optom Vis Sci* 2008;85:226–9.
- [108] Wang CP, Hsieh CY, Chang YL, Lou PJ, Yang TL, Ting LL, et al. Postirradiated neuroendocrine carcinoma of the sinonasal tract. *Laryngoscope* 2008;118:804–9.
- [109] Weng CT, Chu PY, Liu MT, Chen MK. Small cell carcinoma of the head and neck: a single institution's experience and review of the literature. *J Otolaryngol Head Neck Surg* 2008;37:788–93.
- [110] Ma AT, Lei KI. Small cell neuroendocrine carcinoma of the ethmoid sinuses presenting with generalized seizure and syndrome of inappropriate antidiuretic hormone secretion: a case report and review of literature. *Am J Otolaryngol* 2009;30:54–7.
- [111] Ahossi V, Vincent S, Duvillard C. Sinonasal undifferentiated carcinoma, or schneiderian carcinoma arising from an aspergillosis: a case history. *Br J Oral Maxillofac Surg* 2009;47:316–7.
- [112] Chatterjee DN, Mondal A. Small cell neuroendocrine carcinoma of nose and paranasal sinuses: a study of three cases with short review of the literature. *Ind J Otolaryngol Head Neck Surg* 2009;61:43–6.
- [113] Chernock RD, Perry A, Pfeifer JD, Holden JA, Lewis Jr JS. Receptor tyrosine kinases in sinonasal undifferentiated carcinomas—evaluation for EGFR, c-KIT, and HER2/neu expression. *Head Neck* 2009;31:919–27.
- [114] Franchi A, Sardi I, Cetica V, Buccoliero A, Giordano F, Mussa F, et al. Pediatric sinonasal neuroendocrine carcinoma after treatment of retinoblastoma. *Hum Pathol* 2009;40:750–5.
- [115] Galm T, Turner N. Primary carcinoid tumour of nasal septum. *J Laryngol Otol* 2009;123:789–92.
- [116] Hatoum GF, Patton B, Takita C, Abdel-Wahab M, LaFave K, Weed D, et al. Small cell carcinoma of the head and neck: the university of Miami experience. *Int J Radiat Oncol Biol Phys* 2009;74:477–81.
- [117] Lin CH, Chiang TP, Shum WY, Hsu CH, Tsai YC, Tsao TY, et al. Primary small cell neuroendocrine carcinoma of the nasal cavity after successful curative therapy of nasopharyngeal carcinoma: a case report. *Kaohsiung J Med Sci* 2009;25:145–50.
- [118] Zandifar H, Hamilton JS, Osborne RF, Kellman RM. Clinical manifestations of sinonasal undifferentiated carcinoma. *Ear Nose Throat J* 2009;88:1252–4.
- [119] Chang CF, Li WY, Shu CH, Ho CY. Sino-nasal neuro-endocrine carcinoma. *Acta Otolaryngol* 2010;130:392–7.
- [120] Chu MW, Karakla DW, Silverberg M, Han JK. Primary carcinoid tumor of the frontal sinus: a case report. *Ear Nose Throat J* 2010;89:E13–6.
- [121] Furuta A, Kudo M, Kanai K, Ohki S, Suzuki H. Typical carcinoid tumor arising in the nose and paranasal sinuses—case report. *Auris Nasus Larynx* 2010;37:381–5.
- [122] Hubalewska-Dydejczyk A, Trofimiuk M, Sowa-Staszczak A, Gilis-Januszewska A, Baczynska E, Szybiński P, et al. Neuroendocrine tumours of rare location. *Endokrynol Pol* 2010;61:322–7.
- [123] Parbhoo KC, Galler KE, Murphy BA, Pitchford CW, Mawn LA. Primary ocular presentation of sinonasal undifferentiated carcinoma. *Ophthal Plast Reconstr Surg* 2010;26:61–3.
- [124] Li AL, Wehrli B, Rotenberg BW. Carcinoid tumour arising simultaneous to an inverted papilloma in the nasal cavity. *J Otolaryngol Head Neck Surg* 2010;39(6):E78–82.

- [125] Lin EM, Sparano A, Spalding A, Eisbruch A, Worden FP, Heth J, et al. Sinonasal undifferentiated carcinoma: a 13-year experience at a single institution. *Skull Base* 2010;20:61–7.
- [126] Menon S, Pai P, Sengar M, Aggarwal JP, Kane SV. Sinonasal malignancies with neuroendocrine differentiation: case series and review of literature. *Ind J Pathol Microbiol* 2010;53:28–34.
- [127] O'Reilly AG, Wismayer DJ, Moore EJ. Prognostic factors for patients with sinonasal undifferentiated carcinoma. *Laryngoscope* 2010;120(Suppl 4):S173.
- [128] Sohsman M, Yang HM, Cassarino DS. Sinonasal undifferentiated carcinoma metastatic to the skin. *J Cutan Pathol* 2010;37:1241–4.
- [129] Vandist V, Deridder F, Waelput W, Parizel PM, Van de Heyning P, Van Laer C. A neuroendocrine tumour of the sphenoid sinus and nasopharynx: a case report. *B-ENT* 2010;6:147–51.
- [130] Wilson JR, Vachhrajani S, Li J, Sun M, Hawkins C, Rutka JT. Pediatric sinonasal undifferentiated carcinoma: case report and literature review. *Can J Neurol Sci* 2010;37:873–7.
- [131] Iacovou E, Chrysovergis A, Eleftheriadou A, Yiotakis I, Kandiloros D. Neuroendocrine carcinoma arising from the septum. A very rare nasal tumour. *Acta Otorhinolaryngol Ital* 2011;31:50–3.
- [132] Likhacheva A, Rosenthal DI, Hanna E, Kupferman M, Demonte F, El-Naggar AK. Sinonasal neuroendocrine carcinoma: impact of differentiation status on response and outcome. *Head Neck Oncol* 2011;27(3):32.
- [133] Revenaugh PC, Seth R, Pavlovich JB, Knott PD, Batra PS. Minimally invasive endoscopic resection of sinonasal undifferentiated carcinoma. *Am J Otolaryngol* 2011;32:464–9.
- [134] Wadsworth B, Bumpous JM, Martin AW, Nowacki MR, Jensen AB, Farghaly H. Expression of p16 in sinonasal undifferentiated carcinoma (SNUC) without associated human papillomavirus (HPV). *Head Neck Pathol* 2011;5:349–54.
- [135] Aggarwal SK, Keshri A, Rajkumar. Sinonasal undifferentiated carcinoma presenting as recurrent fronto-ethmoidal pyomucocele. *Natl J Maxillofac Surg* 2012;3:55–8.
- [136] Flavahan PW, Keir J, Srinivasan V. Neuroendocrine carcinoma of the ethmoid sinuses treated with radiotherapy alone. *J Laryngol Otol* 2012;126:1066–8.
- [137] Goel R, Ramalingam K, Ramani P, Chandrasekar T. Sino nasal undifferentiated carcinoma: a rare entity. *J Nat Sci Biol Med* 2012;3:101–4.
- [138] Han G, Wang Z, Guo X, Wang M, Wu H, Liu D. Extralaryngeal small cell neuroendocrine carcinoma of the paranasal sinuses: a case report and review of the literature. *J Oral Maxillofac Surg* 2012;70:2347–51.
- [139] Hofer MJ, Rohlf J, Teymoortash A, Pagenstecher A. A 62-year-old female with an intranasal mass extending into the lamina cribrosa. *Brain Pathol* 2013;23:105–8.
- [140] Kusunoki T, Ikeda K. Neuroendocrine carcinoma arising in a wound of the postoperative maxillary sinus. *Clin Pract* 2012;24. 2(1):e16.
- [141] Mourad WF, Hauerstock D, Shourbaji RA, Hu KS, Culliney B, Li Z, et al. Trimodality management of sinonasal undifferentiated carcinoma and review of the literature. *Am J Clin Oncol* 2013;36:584–8.
- [142] Tran T, Manolidis S, Schantz S, Urken M, Persky M, Harrison LB. Trimodality management of sinonasal undifferentiated carcinoma and review of the literature. *Am J Clin Oncol* 2013;36:584–8.
- [143] Tang IP, Singh S, Krishnan G, Looi LM. Small cell neuroendocrine carcinoma of the nasal cavity and paranasal sinuses: a rare case. *J Laryngol Otol* 2012;126:1284–6.
- [144] Terada T. Primary small cell carcinoma of the maxillary sinus: a case report with immunohistochemical and molecular genetic study involving KIT and PDGFRA. *Int J Clin Exp Pathol* 2012;5:264–9.
- [145] Hosokawa S, Okamura J, Takizawa Y, Mineta H. Long-term survival of a patient with primary small cell neuroendocrine carcinoma of the maxillary sinus: a case report. *J Oral Maxillofac Surg* 2013;71:e248–52.
- [146] Kang SY, McHugh JB, Sullivan SE, Marentette LJ, McKean EL. Sinonasal undifferentiated carcinoma and esthesioneuroblastoma recurring as nonintestinal adenocarcinoma. *Laryngoscope* 2013;123:1121–4.
- [147] Krishnamurthy A, Ravi P, Vijayalakshmi R, Majhi U. Small cell neuroendocrine carcinoma of the paranasal sinus. *Natl J Maxillofac Surg* 2013;4:111–3.
- [148] Liu SV, Wagle N, Zada G, Sun B, Go J, Rashtian A. Leptomeningeal carcinomatosis in sinonasal undifferentiated carcinoma. *Head Neck* 2013;35:E343–5.
- [149] Mahdavi O, Boostani N, Karimi S, Tabesh A. Intraoral mass presenting as maxillary sinus carcinoma: a case report. *J Dent (Tehran)* 2013;10:562–8.
- [150] Matsuyama H, Yamazaki K, Tomita M, Takahashi S. Small cell carcinoma of the head and neck: report of three cases. *J Laryngol Otol* 2013;127:942–6.
- [151] Sirsath NT, Babu KG, Das U, Premalatha CS. Paranasal sinus neuroendocrine carcinoma: a case report and review of the literature. *Case Rep Oncol Med* 2013;2013:728479.
- [152] Singhal A, Singla S, Sharma P, Dhull VS, Khangembam BC, Kumar R. 68Ga DOTANOC PET/CT for accurate delineation of disease extent in a case of sinonasal small cell neuroendocrine carcinoma. *Clin Nucl Med* 2013;38:e395–6.
- [153] Tsukahara K, Nakamura K, Motohashi R, Sato H. Two cases of small cell cancer of the maxillary sinus treated with cisplatin plus irinotecan and radiotherapy. *Case Rep Otolaryngol* 2013;2013:893638.
- [154] Chai L, Ying HF, Wu TT, Zhou SH, Bao YY, Yao HT, et al. Clinical features and hypoxic marker expression of primary sinonasal and laryngeal small-cell neuroendocrine carcinoma: a small case series. *World J Surg Oncol* 2014;12(12):199.
- [155] Duan YF, Tan Y, Yuan B, Zhu F. Spontaneous rupture of hepatic metastasis from small cell neuroendocrine carcinoma of maxillary sinus. *World J Surg Oncol* 2014;27(12):126.
- [156] Gray ST, Herr MW, Sethi RK, Diercks G, Lee L, Curry W, et al. Treatment outcomes and prognostic factors, including human papillomavirus, for sinonasal undifferentiated carcinoma: a retrospective review. *Head Neck* 2015;37:366–74.
- [157] Hong SL, Kim SD, Roh HJ, Cho KS. The sphenoid sinus: an unusual presentation of a typical carcinoid tumor. *J Craniofac Surg* 2014;25:e483–5.
- [158] Khan M, Nizami S, Mirrahimov AE, Maughan B, Bishop JA, Sharfman WH. Primary small cell neuroendocrine carcinoma of paranasal sinuses. *Case Rep Med* 2014;2014:874719.
- [159] Ono Y, Hisamatsu Y, Kuramoto S, Katsumata A, Kawauchi M, Kanai K, et al. A case of intracranial invasion from sinonasal small cell neuroendocrine carcinoma. *No Shinkei Geka* 2014;42:453–9.
- [160] Treglia G, Bongiovanni M, Giovannella L. Rare sinonasal small cell neuroendocrine carcinoma evaluated by F-18-FDG PET/MRI. *Endocrine* 2014;47:654–5.
- [161] Yadav SK, Shetty P. Primary small cell undifferentiated (neuroendocrine) carcinoma of the maxillary sinus. *Case Rep Dent* 2014;2014:463109.
- [162] Yu A. Sinonasal undifferentiated carcinoma: 2 cases report. *Lin Chung Er Bi Yan Hou Tou Jing Wai Ke Za Zhi* 2014;28:1176–7.
- [163] Nudell J, Chiosea S, Thompson LD. Carcinoma ex-Schneiderian papilloma (malignant transformation): a clinicopathologic and immunophenotypic study of 20 cases combined with a comprehensive review of the literature. *Head Neck Pathol* 2014;8:269–86.
- [164] Stephenson KA, Lubbe DE. Primary atypical carcinoid tumour of the sphenoid sinus rostrum. *Case Rep Otolaryngol* 2014;2014:753964.
- [165] Bell D, Hanna EY, Agaimy A, Weissferdt A. Reappraisal of sinonasal undifferentiated carcinoma: SMARCB1 (INI1)-deficient sinonasal carcinoma: a single-institution experience. *Virchows Arch* 2015;467:649–56.
- [166] Chiang WY, Chen MH, Huang HM. Sinonasal carcinoma presenting as chronic sinusitis and sequential bilateral visual loss. *Ind J Ophthalmol* 2015;63:528–31.
- [167] Hosokawa S, Takahashi G, Baba S, Mineta H. Small cell neuroendocrine carcinomas arising in the head and neck region. *J Oral Maxillofac Surg* 2016;74:1091–5.
- [168] Mao CP, Zhang M, Niu C, Li M, Wang Y. Radiographic findings of a well-differentiated sinonasal neuroendocrine neoplasm: case report and review of the literature. *Ear Nose Throat J* 2015;94:E26–9.
- [169] Noticewala SS, Mell LK, Olson SE, Read W. Survival in unresectable sinonasal undifferentiated carcinoma treated with concurrent intra-arterial cisplatin and radiation. *World J Clin Cases* 2015;16(3):191–5.
- [170] Rivas-Tolosa N, Llombart B, Traves V, Guillén C. Small-cell neuroendocrine carcinoma, not Merkel cell carcinoma, in the sinonasal region: a case report. *Actas Dermosifiliogr* 2015;106:143–5.
- [171] Sugawara T, Aoyagi M, Ogishima T, Kawano Y, Tamaki M, Yano T, et al. Extended orbital exenteration for sinonasal malignancy with orbital apex extension: surgical technique and clinical analysis. *J Neurosurg* 2015;123:52–8.
- [172] Bach CA, Guilleré L, Le Stanc E, Chabolle F. Small cell neuroendocrine carcinoma of the ethmoid sinus revealed by syndrome of inappropriate antidiuretic hormone secretion. *Eur Ann Otorhinolaryngol Head Neck Dis* 2016;133:71–2.
- [173] Thompson ED, Stelow EB, Mills SE, Westra WH, Bishop JA. Large cell neuroendocrine carcinoma of the head and neck: a clinicopathologic series of 10 cases with an emphasis on HPV status. *Am J Surg Pathol* 2016;40:471–8.
- [174] Zielinski V, Laban S, Tribius S, Schaffhausen P, Veldhoen S, Knecht R, et al. Management of sinonasal undifferentiated carcinoma with intracerebral invasion: clinical experience at a single institution and review of the literature. *Ear Nose Throat J* 2016;95:23–8.
- [175] Lewis Jr JS, Ferlito A, Gnepp DR, Rinaldo A, Devaney KO, Silver CE, et al. International Head and Neck Scientific Group. Terminology and classification of neuroendocrine neoplasms of the larynx. *Laryngoscope* 2011;121:1187–93.
- [176] Mills SE. Neuroectodermal neoplasms of the head and neck with emphasis on neuroendocrine carcinomas. *Mod Pathol* 2002;15:264–78.
- [177] van der Laan TP, Plaat BE, van der Laan BF, Halmos GB. Clinical recommendations on the treatment of neuroendocrine carcinoma of the larynx: a meta-analysis of 436 reported cases. *Head Neck* 2015;37:707–15.