

University of Groningen

Spontaneous resolution of left bundle branch block and biventricular stimulation lead to reverse remodeling in dyssynchronopathy

Kloosterman, Marielle; Rienstra, Michiel; Van Gelder, Isabelle C.; Maass, Alexander H.

Published in:
Journal of Electrocardiology

DOI:
[10.1016/j.jelectrocard.2016.07.008](https://doi.org/10.1016/j.jelectrocard.2016.07.008)

IMPORTANT NOTE: You are advised to consult the publisher's version (publisher's PDF) if you wish to cite from it. Please check the document version below.

Document Version
Publisher's PDF, also known as Version of record

Publication date:
2016

[Link to publication in University of Groningen/UMCG research database](#)

Citation for published version (APA):

Kloosterman, M., Rienstra, M., Van Gelder, I. C., & Maass, A. H. (2016). Spontaneous resolution of left bundle branch block and biventricular stimulation lead to reverse remodeling in dyssynchronopathy. *Journal of Electrocardiology*, 49(5), 696-698. <https://doi.org/10.1016/j.jelectrocard.2016.07.008>

Copyright

Other than for strictly personal use, it is not permitted to download or to forward/distribute the text or part of it without the consent of the author(s) and/or copyright holder(s), unless the work is under an open content license (like Creative Commons).

The publication may also be distributed here under the terms of Article 25fa of the Dutch Copyright Act, indicated by the "Taverne" license. More information can be found on the University of Groningen website: <https://www.rug.nl/library/open-access/self-archiving-pure/taverne-amendment>.

Take-down policy

If you believe that this document breaches copyright please contact us providing details, and we will remove access to the work immediately and investigate your claim.

Downloaded from the University of Groningen/UMCG research database (Pure): <http://www.rug.nl/research/portal>. For technical reasons the number of authors shown on this cover page is limited to 10 maximum.

Spontaneous resolution of left bundle branch block and biventricular stimulation lead to reverse remodeling in dyssynchronopathy[☆]

Mariëlle Kloosterman, BSc, Michiel Rienstra, MD, PhD, Isabelle C. Van Gelder, MD, PhD, Alexander H. Maass, MD, PhD*

Department of Cardiology, Thoraxcenter, University of Groningen, University Medical Center Groningen, Groningen, The Netherlands

Abstract

Left bundle branch block (LBBB) is considered a marker of underlying structural cardiac disease. To determine whether LBBB is cause or consequence of deterioration of left ventricular (LV) function is difficult as both are often diagnosed concomitantly. We discuss a patient where reversal of LBBB and subsequent normalization of LV function was observed after 2 different therapies, first after start of heart failure medication, and years later after implantation of a cardiac resynchronization device. This indicates that LBBB *per se* may result in the development of non-ischemic cardiomyopathy and that LBBB resolution can lead to reverse remodeling in dyssynchronopathy.

© 2016 The Authors. Published by Elsevier Inc. This is an open access article under the CC BY license (<http://creativecommons.org/licenses/by/4.0/>).

Keywords:

Left bundle branch block; Dyssynchronopathy; Cardiac resynchronization therapy; Reverse remodeling; Non-ischemic cardiomyopathy

Introduction

Left bundle branch block (LBBB) may occur in asymptomatic individuals, patients with extensive myocardial infarction, and in those with heart failure (HF), especially in non-ischemic cardiomyopathies. It may even be the first manifestation of heart disease whereas the clinical presentation of a non-ischemic cardiomyopathy develops years later [1]. LBBB causes slow activation of left ventricular (LV) septum and delayed activation of the lateral and basal walls of the LV that can eventually lead to depressed left ventricular ejection fraction (LVEF) [2]. Because LBBB itself can accelerate LV dysfunction, LBBB and HF may have synergistic effects. Determining whether LBBB or deterioration of LV function is the trigger is often unclear as both are diagnosed concomitantly.

Case report

A 50-year-old Caucasian male presented himself at our hospital with increasing complaints of dyspnea on exertion.

[☆] Disclosures: Ms. Kloosterman has nothing to disclose. Dr. Rienstra reports grants from Netherlands Organisation of Scientific Research (Veni grant 016.136.055), outside the submitted work. Dr. Van Gelder reports receiving grant support for the institution from Medtronic, Biotronik, and St. Jude Medical. Dr. Maass reports receiving lecture fees from Biotronik, Boston Scientific, Medtronic, Sorin, and St. Jude Medical.

* Corresponding author at: Department of Cardiology, Thoraxcenter, University of Groningen, University Medical Center Groningen, P.O. Box 30.001, 9700 RB, Groningen, The Netherlands.

E-mail address: a.h.maass@umcg.nl

The patient experienced no other complaints. The electrocardiogram (ECG) demonstrated sinus rhythm, 95 bpm, with complete LBBB and QRS duration of 134 ms. No previous ECGs were present. Laboratory findings were non-contributory. Chest radiography and computed tomographic scan showed no hilar and mediastinal lymphadenopathy, parenchymal changes, pulmonary edema, pericardial thickening or pleural effusion. Pulmonary function testing revealed a restrictive, impaired lung volume, impaired diffusing capacity, and normal airway resistance. Bronchoscopy showed no abnormalities. Echocardiography showed dilatation of the LV and asynchronous ventricular contraction. Echocardiographic data were as follows: left ventricular end diastolic diameter (LVEDD) 67 mm; left ventricular end systolic diameter (LVESD) 55 mm; interventricular septal thickness 10 mm; and left ventricular poster wall thickness 9 mm. No valve dysfunctions were observed. The multigated acquisition scan (MUGA) showed severely compromised LV function with a LVEF of 23%. ^{99m}Tc MIBI scintigraphy revealed diffusely reduced uptake of the myocardium, most notably anterior, infero-apical and at the basal septal and inferior wall. Coronary angiography showed no significant coronary artery disease. Results were consistent with non-ischemic cardiomyopathy. The patient was started on standard HF medication including ACE-inhibitor, diuretic, β -blocker, carbasalate calcium, and begun an individualized cardiac rehabilitation program.

He was seen regularly at the outpatient clinic and almost immediately after starting medication his condition started to rapidly improve. Within six months after medication initiation

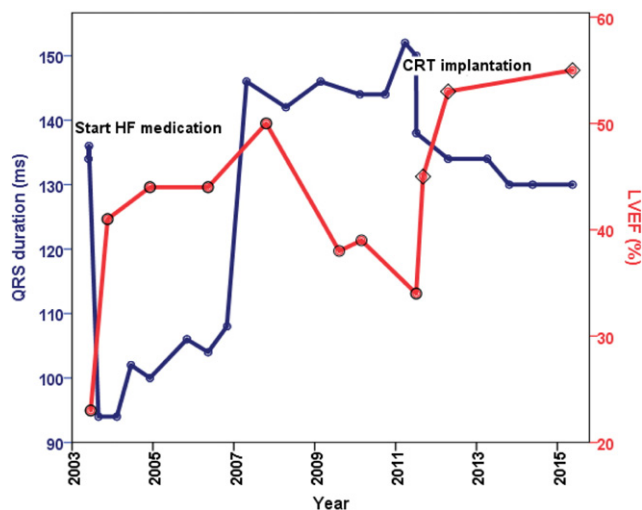


Fig. 1. QRS duration (blue) and LVEF (red) changes from the moment of presentation in 2003 until late 2015. After the start of HF medication QRS duration rapidly decreased, only to increase again in 2007. LVEF closely follows the changes in QRS duration, improving when QRS duration decreases and deteriorating when QRS duration increases. After CRT implantation in 2011 QRS duration and LVEF decreased and increased once more respectively, then stabilized. *CRT denotes cardiac resynchronization therapy; HF, heart failure; LVEF, left ventricular ejection fraction. Methods for LVEF measurements: ○ MUGA scan; ◇ Echocardiography using biplane Simpson's method (performed by AHM).

his complaints disappeared and cardiac function and disturbances of the conduction system dramatically improved. The LVEF increased to 41%, LBBB resolved and QRS duration shortened to 94 ms. (Figs. 1 and 2) LV dimensions decreased; LVEDD was 57 mm and 49 mm and LVESD 48 mm and 39 mm after six months and one year respectively. The patient's condition remained stable for almost four years even though during this time QRS duration began to increase again. Four years after initial admission, movement of QRS frontal plane from a normal axis to left axis deviation was observed and LBBB returned with QRS duration of 146 ms followed by a decline of LVEF. In the next four years MUGA and echocardiograms showed progressive dilatation of LV. The mid anteroseptal wall became akinetic, the basal septal wall hypokinetic and impaired relaxation was observed together with a reduction of LVEF, eventually being 34%. Four years after the recurrence of LBBB the decision was made to implant a cardiac resynchronization device (CRT). Within two months after implantation QRS decreased from 150 ms to 120 ms and LVEF increased to 45%. Now, four years after CRT implantation at an age of 62 years, LVEF and QRS duration stabilized. LVEF is 55% and he has no complaints.

Discussion

Collected ECG, echocardiography and MUGA data in our case indicate that LBBB may have precipitated deterioration of the LV function (Fig. 1). Progression of LV failure, four years after the initiation of HF medication, was preceded by a progressive increase in QRS duration together with the change from normal QRS axis to left axis deviation. ECGs before initial presentation are not present, but it is plausible that

initially prolongation of QRS duration occurred, causing silent onset of LBBB, which eventually led to HF with physical complaints. It seems that in our case both medication and CRT could resolve LBBB, along with a reduction in QRS duration and re-establishment of LV synchrony, implying a relationship between LBBB induced dyssynchrony and dilatation with concomitant HF.

Blanc et al. reported that in some patients complete normalization of LV function could be achieved after LV resynchronization pacing in patients with non-ischemic cardiomyopathy who had LBBB and severe HF. From these results they speculate that LBBB-induced dyssynchrony leads to a form of LV dysfunction, which aggravates intraventricular conduction disturbances [3]. Vaillant et al. showed the existence of a similar, specific LBBB-induced cardiomyopathy resolved by CRT in 6 patients [4]. The Predictors of Response to CRT–ECG substudy showed that narrowing of the QRS duration after CRT predicted more LV volume reduction, especially in patients with non-ischemic cardiomyopathy and LBBB [5].

The mechanisms of narrowing of QRS duration observed after start of medication and later after initiation of CRT in the present case are unclear. It may be due to either changes in the specialized cardiac conduction system, or changes in intramyocardial impulse transmission. If the change is the result of improved impulse transmission in the specialized conduction tissue this could be the result of improved hemodynamics or secondary to remodeling or perhaps even electrical regeneration of the conduction tissue. In a recent study by Ogano et al., CRT restored ventricular septal myocardial perfusion and enhanced ventricular remodeling in patients with non-ischemic cardiomyopathy presenting with LBBB [6]. Similarly, more efficient intramyocardial impulse transmission could possibly result from improved hemodynamics or mechanical reverse remodeling of the heart with smaller chamber sizes. Studies of myocardial impulse transmissions in canine models of dyssynchrony have shown changes in conduction velocity and action potential duration, as well as distribution and expression of connexins, also in the lateral wall of the LV during LBBB [7]. Vernooij et al. demonstrated, in canine hearts with long-term isolated LBBB, that biventricular pacing could largely reverse the functional and structural abnormalities induced by LBBB. This reversal occurred both globally and regionally introducing the idea that dyssynchronopathy as a result of LBBB can be “cured” by CRT [8]. The temporal pattern and relationship that we describe is conjectural and it is possible that another factor can be the driving force behind the changes we observed.

This is, to our knowledge, the first case that describes reversal of LBBB and the subsequent normalization of LV function after 2 different therapies, first after start of HF medication, and years later after implantation of a CRT device. Usually LBBB is considered as a marker of underlying structural cardiac disease. Fig. 1 suggests that LBBB *per se* may result in the development of non-ischemic cardiomyopathy due to permanent dyssynchronous activation of the LV. The idea of LBBB as a possible reversible cause of non-ischemic cardiomyopathy warrants further investigation.

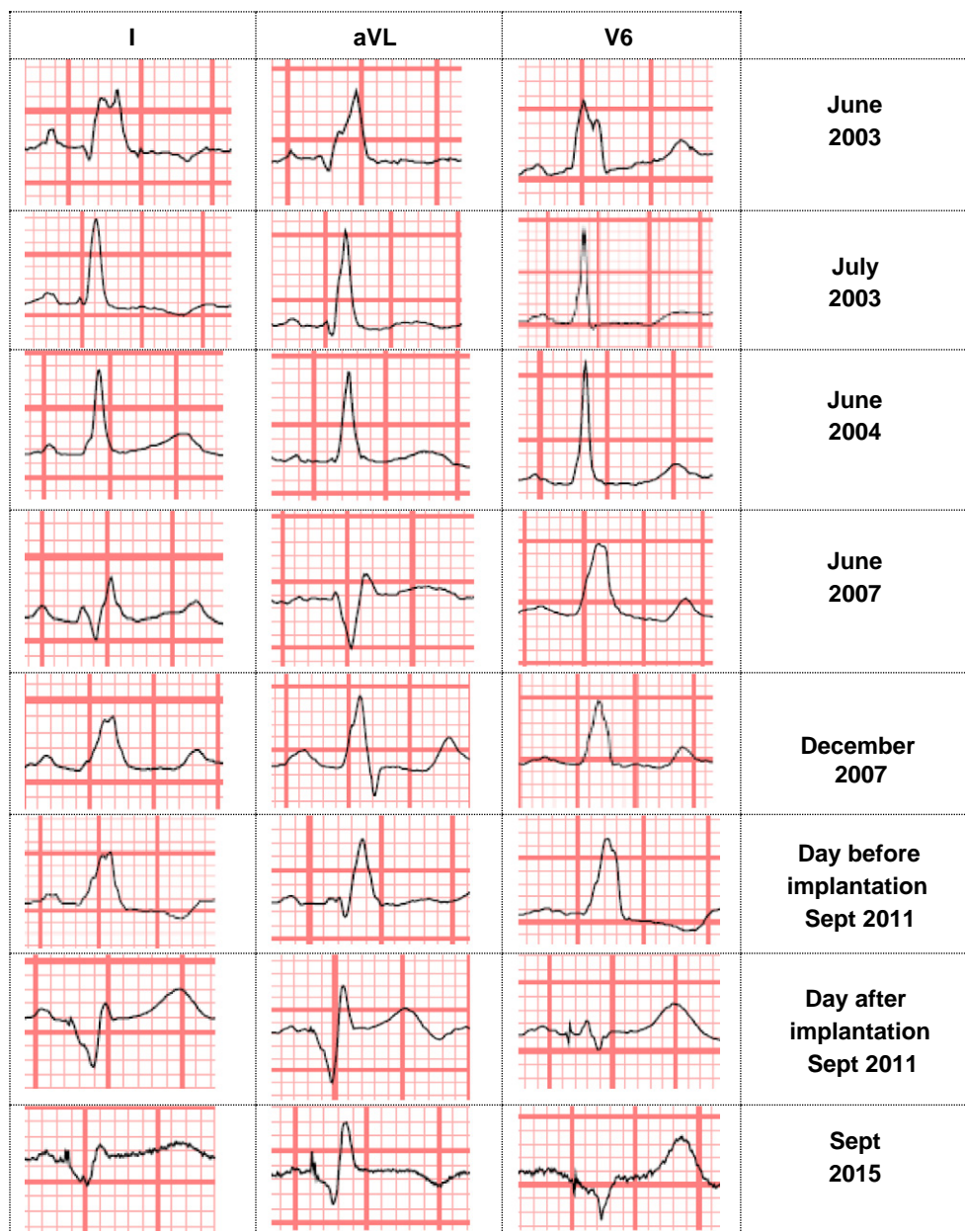


Fig. 2. Serial changes in the electrocardiogram leads I, aVL and V6. At initial presentation in June 2003 complete LBBB was present. However, after medication LBBB resolved until in 2007 LBBB recurred which persisted until CRT implantation in 2011. *LBBB denotes left bundle branch block.

References

- [1] Breithardt G, Breithardt OA. Left bundle branch block, an old-new entity. *J Cardiovasc Transl Res* 2012;5:107–16.
- [2] Littmann L, Symanski JD. Hemodynamic implications of left bundle branch block. *J Electrocardiol* 2000;33(Suppl):115–21.
- [3] Blanc JJ, Fatemi M, Bertault V, Baraket F, Etienne Y. Evaluation of left bundle branch block as a reversible cause of non-ischaemic dilated cardiomyopathy with severe heart failure. A new concept of left ventricular dyssynchrony-induced cardiomyopathy. *Europace* 2005;7:604–10.
- [4] Vaillant C, Martins RP, Donal E, Leclercq C, Thebault C, Behar N, et al. Resolution of left bundle branch block-induced cardiomyopathy by cardiac resynchronization therapy. *J Am Coll Cardiol* 2013;61:1089–95.
- [5] Hsing JM, Selzman KA, Leclercq C, Pires LA, McLaughlin MG, McRae SE, et al. Paced left ventricular QRS width and ECG parameters predict outcomes after cardiac resynchronization therapy: PROSPECT-ECG substudy. *Circ Arrhythm Electrophysiol* 2011;4:851–7.
- [6] Ogano M, Iwasaki YK, Tanabe J, Takagi H, Umemoto T, Hayashi M, et al. Cardiac resynchronization therapy restored ventricular septal myocardial perfusion and enhanced ventricular remodeling in patients with nonischemic cardiomyopathy presenting with left bundle branch block. *Heart Rhythm* 2014;11:836–41.
- [7] Jansen JA, van Veen TA, de Bakker JM, van Rijen HV. Cardiac connexins and impulse propagation. *J Mol Cell Cardiol* 2010;48:76–82.
- [8] Vermooy K, Cornelussen RN, Verbeek XA, Vanagt WY, van Hunnik A, Kuiper M, et al. Cardiac resynchronization therapy cures dyssynchronopathy in canine left bundle-branch block hearts. *Eur Heart J* 2007;28:2148–55.