

University of Groningen

## Cerebral reorganization and motor imagery after flexor tendon Repair

Stenekes, Martin Willian

**IMPORTANT NOTE: You are advised to consult the publisher's version (publisher's PDF) if you wish to cite from it. Please check the document version below.**

*Document Version*

Publisher's PDF, also known as Version of record

*Publication date:*

2009

[Link to publication in University of Groningen/UMCG research database](#)

*Citation for published version (APA):*

Stenekes, M. W. (2009). *Cerebral reorganization and motor imagery after flexor tendon Repair*. [s.n.].

### Copyright

Other than for strictly personal use, it is not permitted to download or to forward/distribute the text or part of it without the consent of the author(s) and/or copyright holder(s), unless the work is under an open content license (like Creative Commons).

The publication may also be distributed here under the terms of Article 25fa of the Dutch Copyright Act, indicated by the "Taverne" license. More information can be found on the University of Groningen website: <https://www.rug.nl/library/open-access/self-archiving-pure/taverne-amendment>.

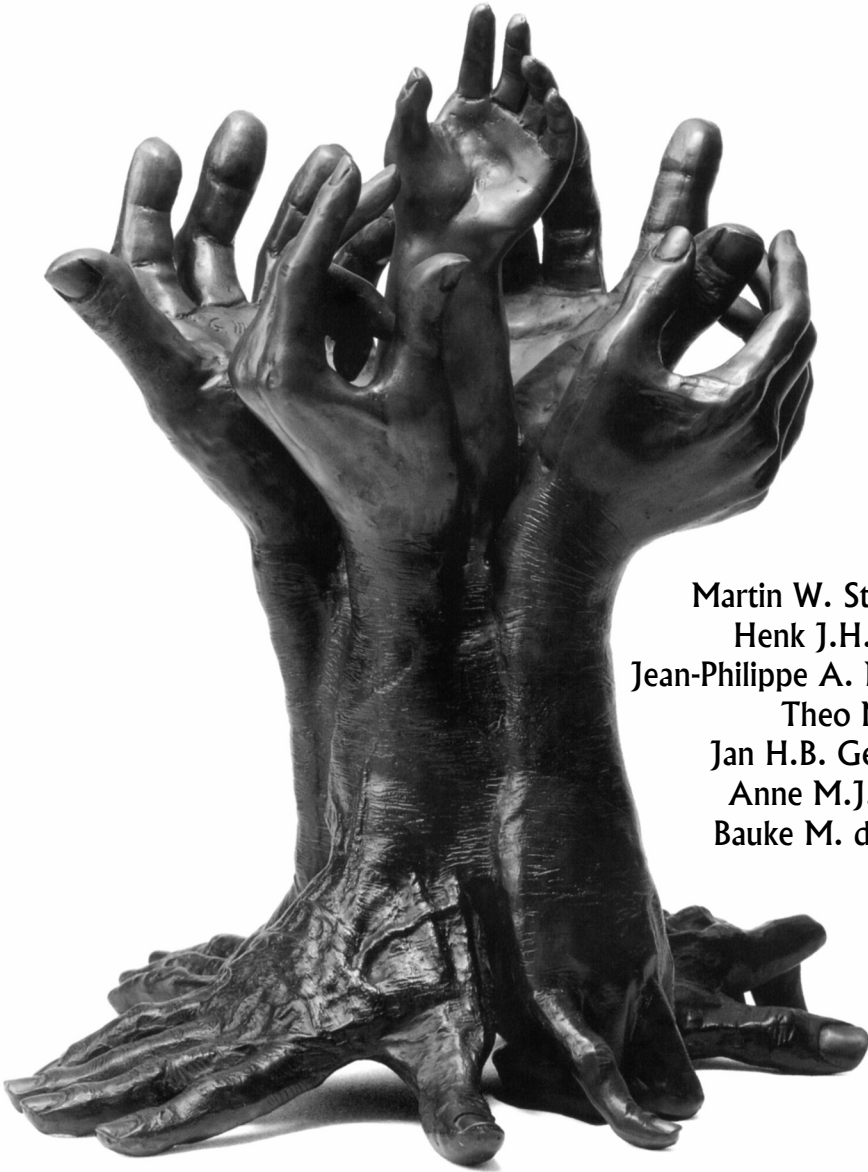
### Take-down policy

If you believe that this document breaches copyright please contact us providing details, and we will remove access to the work immediately and investigate your claim.

Downloaded from the University of Groningen/UMCG research database (Pure): <http://www.rug.nl/research/portal>. For technical reasons the number of authors shown on this cover page is limited to 10 maximum.

Chapter **3**

**Cerebral consequences of dynamic immobilization  
after primary digital flexor tendon repair**



**Martin W. Stenekes  
Henk J.H. Coert  
Jean-Philippe A. Nicolai  
Theo Mulder  
Jan H.B. Geertzen  
Anne M.J. Paans  
Bauke M. de Jong**

*Submitted*

## **Abstract**

Current treatment protocols for flexor tendon injuries of the hand generally result in an acceptable function, which can be quantified by objective parameters such as range of motion. The latter does not always match the patients' subjective experiences of persisting dysfunction. This raises the question whether changes in the cerebral control of movement might contribute to the perceived deficit.

The main objective of the present Positron Emission Tomography (PET) study was to characterize the cerebral responses in movement-associated areas during simple finger flexion immediately after dynamic immobilization and after a subsequent six-week period of active training.

Ten subjects with flexor tendon injury participated in the PET study. EMG recordings were made during finger flexion and extension in an additional subject. The main finding was that the (ventral) putamen contralateral to flexor movement was not activated immediately after release from splinting, while such activation reappeared after a period of training. This indicates a temporary loss of efficient motor control of over learned movements. The increase of unwanted co-contractions during flexion in a first EMG session, and not during extension, supports a concept of lost skills.

## Introduction

Treatment of a flexor tendon injury of the hand has greatly improved over recent decades. The introduction of dynamic splinting in the 1970s, enabling passive gliding of the tendon with little stress across the suture site, has proven to be a major milestone in the recovery of hand function after surgical treatment<sup>1</sup>. Protocols concerning dynamic postoperative immobilization have later been refined and there is a continuous search for new suture techniques and materials<sup>2</sup>. While current treatment protocols generally result in an acceptable function, which can be quantified by objective parameters such as range of motion, the latter does not always match the patients' subjective experiences. Clumsiness may be a complaint after the immobilization period, which is phrased by e.g. "I feel like a four-year-old when I tie my shoes". The discrepancy between normal joint movement and suboptimal use in daily life led to the question whether changes in the cerebral control of movement might contribute to the perceived deficit. In this respect it is of conceptual importance to notice that in case of flexor tendon injury treatment, an essential characteristic of dynamic immobilization is the prolonged period during which only passive and no active flexion movements are made. In contrast, extension movements of the affected hand remain to be performed by direct cerebral command. Because fine-tuned purposeful movements, as seen in grasping, are particularly the result of flexor control<sup>3</sup>, prolonged flexor disuse may have a specific impact on purposeful movements, indeed resulting in clumsiness.

Since the availability of neuroimaging techniques such as Positron Emission Tomography (PET), and more recently also functional Magnetic Resonance Imaging (fMRI)<sup>4</sup>, it has become possible to study the functional anatomy underlying the cerebral control of motor actions, both in normal and pathological conditions. In these studies, a subject is scanned while performing a specific task. These tasks are related with local increases of neuronal activity in the brain, which further induces local increases of cerebral bloodflow. PET and fMRI enable the assessment of these regional bloodflow changes, thus providing a tool to localize cerebral functions. A prominent feature of cerebral motor control is the somatotopical representation of function on the primary sensorimotor cortex<sup>5-7</sup>. Previous studies have demonstrated that this somatotopy is subject to change induced by changes in anatomy of the represented limb<sup>8-10</sup>.

Postoperative functional disability after flexor tendon repair may have several causes of which local restrictions such as adhesions of the tendon to the tendon sheath, joint stiffness or shortening of the tendon are most plausible. In a recent pilot study with PET, we emphasized that central consequences of rehabilitation after flexor tendon repair should not be neglected<sup>11</sup>. This pilot study on 4 subjects showed that the experienced clumsiness, after a six week dynamic immobilization period, was indeed associated with functional changes in the cerebral control of

finger movements. Finger flexion was demonstrated to coincide with increased parietal cortex- and reduced striatum activations. This was inferred to reflect an increased demand on body scheme representation in the circumstance that movements lost their automated character<sup>12;13</sup>. The parietal increase disappeared after active flexor training, together with re-established striatum activation. The latter indeed logically reflected a striatal role in (re-)learned movements<sup>14;15</sup>. In the present paper we present functional imaging data on a larger group, together with detailed clinical information. We were particularly interested to find out whether the findings of the pilot study could be reproduced and proved statistically significant in a larger patient group.

The present study included patients with either left- or right hand lesions. In order to perform a group analyse of the complete set of imaging data, which allows the identification of common changes in the patterns of movement-related cerebral activation, some aspects of lateralized brain functions need to be considered. On the one hand, a general principle of organization is that the motor cortex and supporting basal ganglia in one hemisphere are linked to movements of the contralateral hand. Flipping e.g. the right hand imaging data would thus provide a single group with only ‘virtual’ left hand movement, allowing the optimal assessment of contralateral (right) hemisphere activations. However, limb-independent specialization for each of the hemispheres also exists. In the 19<sup>th</sup> century Broca and Wernicke were among the first to discover such lateralized brain function: left hemisphere regions play a dominant role in language<sup>16-18</sup>. The right hemisphere is thought to play a major role in spatial relations, verbal emotional stimuli and complex sounds or music<sup>19</sup>. The ability to perform precise technical motor skills with a preferred (generally right) hand, may be regarded as an argument for an associated (left) hemisphere dominance<sup>20</sup>. However, the status of such hemisphere dominance in motor skill, as well as the functional organization of motor areas in right- and left-handed people, remain subjects of debate<sup>21;22</sup>. It has even been argued that differences in the motor systems in these two groups may be indicative for difference in recovery from injury<sup>23</sup>. In addition to the optimal assessment of cerebral activations contralateral to hand movement, limb-independent motor activations in each of the two hemispheres were aimed to be identified by the group analysis of the non-mirrored data set.

The main objective of the present study was to characterize motor areas associated with finger flexion after dynamic immobilization and compare them with the areas after subsequent training. We hypothesized that immobilization leads to a temporary change in cerebral organization underlying the control of finger flexion movement, thus confirming the results of our pilot study described above.

## Materials and Methods

### *Subjects*

A total of 10 patients participated in the PET study, whereas EMG recordings were obtained from one additional patient. Characteristics are listed in the results section. Patients with zone II finger flexor tendon injury caused by a sharp transection (knife or glass) were eligible for inclusion if they were between 18 and 65 years of age. The lesion may inflict the volar side of either the left or the right hand. Patients were referred to our hand surgery unit for tenorrhaphy and subsequent rehabilitation according to our standard protocol. This protocol consisted of six weeks of relative immobilization. Four weeks after surgery the use of the splint is reduced and place-hold exercises are performed by the patient for two weeks using a so-called wrist band. Only right-handed patients according to the Edinburgh inventory were included<sup>24</sup>. Digital nerve injury occurs often together with zone II flexor tendon injury. For practical reasons, patients with only a restricted area of sensory deficit (digital nerve injury) were not excluded from the study even though there is some evidence that patients with isolated tendon repairs have better results than those with associated digital nerve injury<sup>25</sup>. Patients with other (more proximal) nerve and vascular injuries or fractures were excluded. None of the subjects had pre-existent neurological disorders or other upper extremity disorders. All subjects gave informed consent to a protocol approved by the Medical Ethics Committee of our institution.

### *PET study*

Experience of clumsiness was quantified by asking all subjects to fill in a visual analogue scale (VAS) regarding their injured hand skill after both scan series. The VAS was recorded on a 0-100 scale where 100 implied perfect hand skills. The VAS data were analysed using the Wilcoxon signed ranks test. Each subject underwent two series of PET scans (Siemens ECAT HR+ scanner operated in 3D mode, 15.2cm axial field of view). Task related increases of regional cerebral blood flow were used as indicators for local neuronal activation and measured with Oxygen-15-labelled water that was injected prior to each scan<sup>26</sup>. During the PET measurements, subjects were in a supine position with the forearm and wrist supported by a pillow with the volar side facing down while the fingers could be moved freely. The first scan session took place immediately after removal of the splint, whereas the second series of scans was performed after at least six weeks of active exercising. In each of the two sessions, six scans were made while repeated double flexion movements (M) were carried out, and three scans were made in a control resting state (C). Scans were ordered C-M-M-M-C-M-M-M-C. During the

flexion condition beeps were presented at random intervals (1.5 to 4.5 s). The subjects responded to each beep by making two brisk flexion movements of digits 2 to 5, with relaxation in between, enabling the fingers to passively regain their neutral position. During the control condition, subjects only listened to similar beeps without making a movement response. Such a control condition is required in order to filter out brain activation not related to finger flexion (e.g. activation evoked by the instruction beeps and sensations of lying on the back in the scanner).

PET image processing and analysis were conducted with SPM99<sup>27</sup>. Due to the strict exclusion criteria applied, it was not possible to include a large number of subjects with identical lesions in the study period. In order to increase the efficiency of the study, subjects with both left and right sided injury were included. The data of subjects with right sided lesions (and right sided finger flexion) were mirrored so that all subjects could be analyzed as one group. We are aware that the results of this analysis should be considered carefully and potential relevant areas should also be ascertained in the 'non-mirrored' dataset, as explained in the Introduction. Images were realigned to the first image to correct for head movements and normalized onto a standard brain template (Montreal Neurological Institute, MNI template in SPM99). Subsequently, the images were smoothed with a 10 mm Gaussian filter full width at half maximum to correct small inter-subject differences in the pattern of gyri and sulci. The above mentioned realignment, normalization and smoothening procedures resulted in a data set of brains with virtually identical spatial dimensions. This enables statistical analysis of changes in local cerebral bloodflow in a group of subjects.

Brain activation during finger flexion was determined by contrasting the movement to the control condition. These comparisons were made in the first as well as the second scan session. For the group analysis, statistical thresholds were initially set at  $P < 0.001$  for response height at voxel level and a cluster size (kE) of minimally 8 voxels. Resulting clusters were considered significant at  $P < 0.05$  after (cluster-level) correction for the entire brain volume.

### ***Electromyography (EMG)***

Surface EMG of finger flexor and extensor muscles of the subject were recorded twice from each arms successively (Nicolet EMG apparatus, Viking IV, sampling frequency 20 kHz). A first EMG was recorded immediately after removal of the splint and a second EMG after six weeks of active practicing of the hand and fingers. For this purpose two electrodes were placed on the forearm, approximately 10 cm distal to the elbow joint. One electrode was placed

ventrally, superficial to the flexor digitorum muscles and one electrode was placed dorsally, superficial to the extensor digitorum muscles.

During EMG recordings, the subject was positioned identically to the position of subjects during the PET measurements (supine, wrist and arm supported, volar side of wrist facing down). Similar to the PET series, two successive EMGs of the injured hand were recorded. In contrast to the PET study, in which the number of measurements was restricted by the maximal radioactivity dose, thus allowing only a flexion and no extension condition, EMG was recorded during flexion as well as during extension. In the flexion condition the stimulus and response were identical to the PET study, while in the extension condition the only difference was that the beeps were followed by two brisk extension movements, each followed by relaxation in a similar way as during flexion.

## Results

Ten subjects (mean age 38 yrs, standard deviation (SD) 12 yrs) were included in the PET study, while one subject (male, 21 yrs) underwent only EMG examination. Five of the subjects included for PET had a left hand injury; another five had a right hand injury. Table 3.1 shows the demographics of these 10 subjects. Two of them participated only in the first and not in the second PET session: one subject was excluded due to suture rupture, requiring a secondary tendon repair, while the other subject was not motivated for a second session. The subject who participated in the EMG study had a left hand injury.

The average period between surgery and the first scan series was 40 days (SD = 3 days). The average interval between the first and second scan session was 55 days (SD = 14 days). All subjects were able to perform the tasks. The minimum distance between the finger tip and the distal palmar crease<sup>28</sup> was always less than 1 cm and passive finger flexion went smooth. Nevertheless, all subjects reported difficulties in performance during the first scan session, which was immediately after removal of the splint. The average VAS scores on hand skills after the first PET session was 53 (SD = 16), while after the second series it was 87 (SD = 6), this difference was significant ( $p = 0.012$ ,  $Z = -2.5$ ). This effect was seen for the left hand as well as the right hand injuries. After the first PET session, the VAS scores were 51 for the left hand and 55 for the right hand lesions, while after the second session they were 87 respectively 85.



**Table 3.1** Characteristics of subjects participating in the PET study

No	Age	Sex	Dominance	Lesion side	Injury
1	49	Male	Right	Left	Digit 2: FDS, FDP, radiovolar digital nerve
2	37	Male	Right	Right	Digit 5: FDP, ulnovolar digital nerve
3	24	Male	Right	Right	Digit 2: FDS, FDP, radiovolar digital nerve
4	36	Male	Right	Left	Digit 4: FDS, FDP, ulnovolar digital nerve
5	46	Male	Right	Left	Digit 2: FDP
6	36	Male	Right	Right	Digit 3: FDS, FDP, ulnovolar digital nerve, Digit 4: FDS, FDP, ulno- and radiovolar digital nerves
7	49	Male	Right	Right	Digit 4: FDS
8	20	Male	Right	Left	Digit 2: FDP, FDS, radiovolar digital nerve
9	26	Female	Right	Left	Digit 2: FDP
10	57	Male	Right	Right	Digit 2, FDP, FDS, ulno- and radiovolar digital nerves
11*	21	Male	Right	Left	Digit 4, FDP

All subjects suffered a zone II sharp flexor tendon injury. FDS = Flexor Digitorum Superficialis tendon, FDP = Flexor Digitorum Profundus tendon.

\* Subject 11 only participated in the EMG study

### *Cerebral activations identified by PET.*

Group analysis of the non-mirrored data-set revealed that repeated finger flexion, compared with rest, resulted in bilateral activations in the sensorimotor cortex and cerebellum, respectively (Fig. 3.1, see Appendix). Sensorimotor activations corresponded with finger movements of the contralateral hand, which is illustrated for the right motor cortex in Fig. 3.3a. When the brains of the right hand performers were mirrored, a strong lateralization of these sensorimotor and cerebellar activations was seen. Now, sensorimotor activation in a single hemisphere (Fig. 3.2, see Appendix) represented the relation with all contralateral movements (Fig. 3.3b), while, as expected, cerebellar activation was ipsilateral to these movements (Fig. 3.2, see Appendix). These effects were seen to occur highly similar in the first as well as the second scan session.

In the first scan session, no putamen activation was seen in the non-mirrored nor in the mirrored data set. In session 2, however, right-sided putamen activation was seen in the non-mirrored data-set, which remained lateralized to the right in the mirrored data set (Figs. 3.1 & 3.2 section  $z = -2$  mm, see Appendix). Only the dorsal extension of the right putamen activation was smaller after flipping. Plotting the putamen effects in the mirrored data-set demonstrated that the increase of putamen activation in the second session was contralateral to movements irrespectively whether they were made with the left or the right hand (Fig. 3.3f). Opposite to the temporal profile of putamen activation, increased activation of the right posterior parietal cortex

was seen in the first session while it disappeared in the second (Figs. 3.1 & 3.2, see Appendix). This activation in the first session, however, was only related to movements made with the left hand (Fig. 3.3cd).

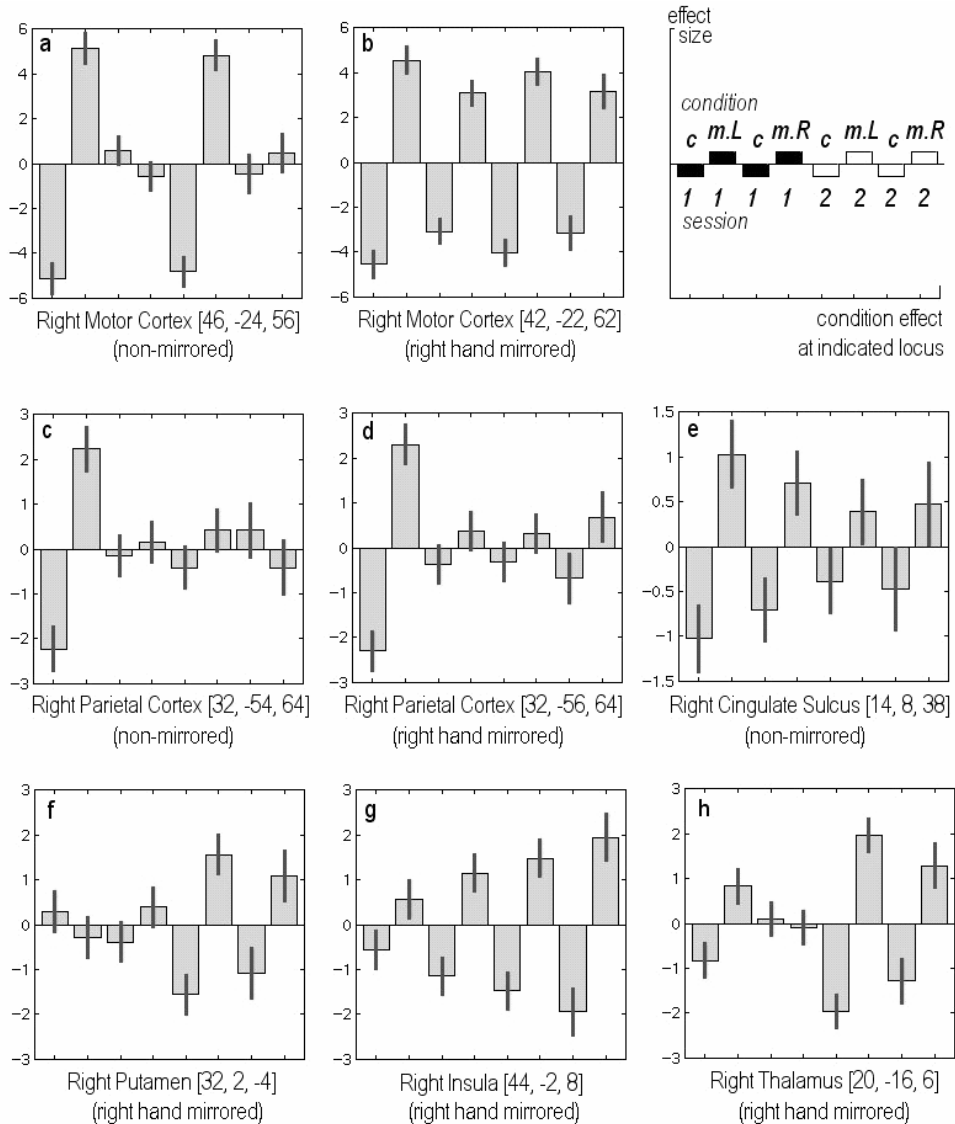
These results confirmed what we previously presented in a short report of only 4 subjects with a left hand lesion<sup>11</sup>. In that study, we additionally found a decrease in the magnitude of anterior cingulate activation over time. In the present data, such effect was only subtle, but indeed present at the same anterior cingulate location (Fig. 3.3e). This activation, however, was part of a larger region of activation that extended in dorsal-posterior direction, where the centre of activation was in the Supplementary Motor Area (SMA) (Fig. 3.1 & 3.2, see Appendix). The magnitude of activation in the SMA was similar in the two scan sessions. Consistent with the previous description of the small group, the magnitude of activation in the posterior insula, contralateral to finger flexion, increased between the two scan sessions (Fig. 3.3g). On the antero-ventral surface of both parietal lobes, i.e. in the secondary somatosensory cortex S2, activations were similarly seen during contralateral as well as ipsilateral hand movement. The only exception was that in the first scan session, left S2 was not evoked during right hand movement.

In contrast to the findings in the previous study on 4 subjects, activation of the lateral thalamus, contralateral to the finger movements, reached statistical significance in the second scan session (Figs. 3.1 & 3.2, see Appendix). In the first session, minor activation was found in only the right thalamus, contralateral to left hand movement (non-mirrored data) (Fig. 3.1 & 3.3h, also see Appendix), while right hand movement was not related with left thalamus activation in this session. Coordinates and Z-scores of maxima in the regions of significant activation are summarized in Table 3.2.

### ***EMG study***

The EMG recordings of one typical subject (Fig. 3.4) demonstrated that within the pairs of two successive flexor movements made in the first session, no complete relaxation occurred, while such relaxation did occur in session 2. The fact that the splinting procedure had generated this effect on specifically flexor movements, which were only passively made during splinting, was inferred from the relaxation recorded in between the brisk extension movements in both session 1 and 2.

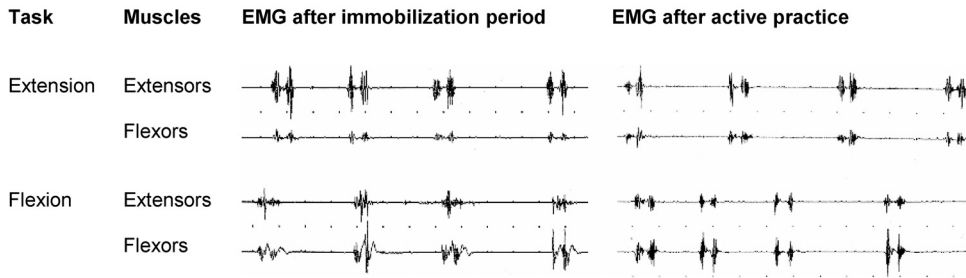
Cerebral consequences of dynamic immobilization after primary digital flexor tendon repair



**Figure 3.3** Contrast of parameter estimates. The condition effects are expressed as effect size and are plotted for the regions as indicated below each graph. The scheme in the upper right corner illustrates the graphs design in which the left and right hand movement conditions were contrasted to the control condition in respectively session 1 and 2. c= control condition without movement, m.L= left hand movers, m.R= right hand movers

*Non-mirrored* implies that the datasets were not mirrored. Therefore figure 3a demonstrates that left hand injuries (= left hand movers) showed an effect in the contralateral (right) motor cortex. Right hand injuries (= right hand movers) did not induce activation in the right but in the left motor cortex, which is not depicted here.

*Right hand mirrored* implies that the effects of right hand movers were processed as if they were effects from left sided movements and thus correspond with right motor cortex activation (figure 3b). The magnitude of activation in the contralateral primary motor cortex did not change over time.



**Figure 3.4** Surface EMG of finger flexors and extensors. Surface finger flexor and extensor EMG results during four stimuli are shown during different conditions. A typical subject responded to each beep by making two brisk flexion or extension movements of digit 2-5, with relaxation in between. In the PET experiment, only flexion movements were studied (due to limitations in applying radioactivity).

## Discussion

The functional outcome of surgery and subsequent dynamic splinting was good in the patients studied in terms of range of motion. Their hand function was not impaired due to e.g. tendon adhesions or joint stiffness. This was demonstrated by the smooth passive flexion as well as the low minimum distance between the fingertips and distal palmar crease although total active motion was not recorded. Nevertheless, the low VAS scores on hand skills after 6 weeks of immobilization pointed at manual disability. Improvement after a subsequent period of actively using the flexor function again was demonstrated by the significant increase on these VAS scores. This provided a quantitative parameter supporting that immobilization following surgery led to the temporary clumsiness as reported earlier<sup>11</sup> and thus confirmed the rationale to perform this functional brain imaging study.

Application of the Kleinert splint implied that finger flexion movements were only performed passively for a period of 6 weeks. No active flexion commands were given to the affected hand while extension movements were still actively performed. The obtained EMG recordings provided support for the assumption that the absence of active movement is a cause of functional deficit. Flexion, and not extension, was specifically disturbed after splint removal, while it was normalized 6 weeks later. This disturbance was particularly characterized by incomplete flexor relaxation in between two brisk contractions. The fact that this distinct movement pattern was associated with flexion and not extension is an argument supporting the concept that the splinting procedure itself was the cause of dysfunction. It should be noticed, in this respect, that the inclusion of a healthy control group with only dynamic splinting, without a tendon lesion and subsequent repair, was not considered feasible for ethical reasons. The finding of insufficient

relaxation within serial contraction provides a logical link between the clumsiness reported by our subjects and the concept of lost skill. Lost skill can also be inferred from the absent putamen activation in the first PET session. In skilled movement, relaxation of unwanted muscle contractions plays an important role<sup>29,30</sup>. In normal circumstances, the putamen is implicated in general skill learning, as has been demonstrated in functional imaging studies<sup>14,15,31</sup>. Moreover, in basal ganglia disorders such as Parkinson's disease and dystonia, the failure to inhibit unwanted movements is a prominent feature<sup>32</sup>.

Theoretically, one might argue that the nearby absence of putamen activation we found in the first PET session was the normal base-line, while increased activation in the second session reflected excessive practice. We have recently proved otherwise by demonstrating that in healthy volunteers, performance of the same double-flexion task evoked a pattern of significant cerebral activations that included the contralateral putamen<sup>33</sup>. We therefore conclude that the reduced putamen activation in session 1 reflected loss of over-learned movement induced by not actively making such movement.

The effects we observed in the (ventral) putamen were contralateral to movements of left as well as right hand movement, which confirmed the data of our pilot study<sup>11</sup>. In that study on four subjects with left hand injury we found increased right posterior parietal activation in the first session, which was strongly reduced in session 2. In the present study, this temporal profile remained present for left hand movement, but was not found for right hand movement. The latter did not evoke significant increase of posterior parietal activation in session 1, neither in the right-, nor in the left hemisphere. This means that our previous explanation of an increased demand of body scheme information in order to overcome the movement difficulty, can only be maintained for the left hand<sup>11-13</sup>. Possibly, the non-dominant left hand needs such additional support more than the dominant right hand. Alternatively, one might speculate that particularly the left hand is in a better position than the right hand to gain access to compensatory circuitry that is specifically present in the (contralateral) right hemisphere. In this respect, right-hemisphere circuitry related to visuomotor imagination may be considered.

Activation of the motor portion of the cingulate gyrus in session 1 was larger than in session 2. This effect was seen for both hands in the present study and confirmed the result of our previous four-subject study (Fig. 3.3). The recruitment of this secondary motor function<sup>34</sup>, possibly mediated by aspects of attention<sup>35</sup> thus implies to be more general than the posterior parietal recruitment, which only held for the left hand. In the pilot study, however, cingulate activation in session 1 was seen as a distinct cluster, which was not the case in the present study (Table

3.2). Now, it was part of a larger cluster comprising the SMA and not distinguished as an independent focus. Activation of the SMA was similarly strong in both sessions.

Activations in the contralateral insula and antero-ventral parietal cortex (S2) were increased in session 2. This was also described in our pilot study, in which we provided arguments that these increases might well reflect improved sensorimotor integration, facilitating efficient motor control<sup>11</sup>. Particularly S2 on the parietal operculum has recently been described to act as an important interface between proprioceptive information processing and the organization underlying motor control<sup>36</sup>. We therefore conclude that by actively using the hand, proprioceptive information is used for efficient motor control, while during passive flexion, proprioceptive information is not used for the latter.

**Table 3.2** Activations related to unilateral hand movement (mirrored data-set)

Brain region	Session 1 (10 subjects)					Session 2 (8 subjects)				
	x	y	z	kE	Z-score	x	y	Z	kE	Z-score
Sensori-motor cortex	50	-22	56	2840	>8	44	-30	62	2788	7.09
Cerebellum	-18	-54	-10	3051	7.74	-18	-50	-18	3526	>8
	22	-62	-22	537	5.66					
Supplementary motor area	2	-8	52	368	4.84	8	-4	52	388	4.40
Posterior parietal cortex	32	-55	66	96	4.29 <sup>*1)</sup>	--	--	--	--	--
Antero-ventral parietal cortex	--	--	--	--	--	50	-24	18	197	4.38
Insula	--	--	--	--	--	44	-2	8	360 <sup>*2)</sup>	4.71
Putamen	--	--	--	--	--	32	-2	-6		3.70
Thalamus	--	--	--	--	--	20	-16	6	395	4.86

Location of clusters with significantly increased perfusion during repeated flexion movement as compared to rest (group analysis,  $p < 0.05$ , cluster-level corrected for whole brain volume), see also \*1) and \*2). Imaging data of right hand movement were mirrored, which implies that all activations are related to 'virtual' left hand finger flexion. Coordinates (in mm) refer to the centre of maximum within a cluster. Positive x, y and z coordinates indicate locations respectively right, anterior and superior of the middle of the anterior commissure. Initial voxel threshold was at  $P < 0.001$  (uncorrected) with extends (kE) of 8 voxels. At voxel-level, all foci of activation reached False-Detection-Rate corrected significance  $P < 0.001$ , only the putamen maximum in session 2 reached FDR corrected  $P = 0.004$ .

\*1) The posterior parietal cluster did only reach an uncorrected cluster-level significance ( $p = 0.03$ ).

\*2) The local insula- and putamen activations touched each other and merged into a common cluster (kE 360).

During finger flexion the contralateral primary sensorimotor cortex and ipsilateral cerebellum were similarly active right after the immobilization period and also after active training. This demonstrated that at a basic level, movements could be performed as requested, but that indeed movement efficiency was deteriorated.

In conclusion, we showed that six weeks of relative immobilization results in a temporary loss of efficient cerebral control of finger flexion. This is characterized by an increased cortical demand and reduced striate involvement. These findings show the impact of a relatively short period of immobilization on the functional organization of the brain. While this cerebral reorganization may occur after any type of immobilization, we are not aware of reports regarding taking measures in the clinical situation to prevent this reorganization from taking place. For the development of new treatment protocols of peripheral lesions in which immobilization is required, the central consequences of this immobilization should be considered.

## References

1. Kleinert HE, Kutz JE, Atasoy E, Stormo A. Primary repair of flexor tendons. *Orthop. Clin. North Am.* 1973; 4: 865-76.
2. Strickland JW. Development of flexor tendon surgery: twenty-five years of progress. *J.Hand Surg.- Am.Vol.* 2000; 25: 214-35.
3. Castiello U. The neuroscience of grasping. *Nat. Rev. Neurosci.* 2005; 6: 726-36.
4. Raichle ME. Behind the scenes of functional brain imaging: a historical and physiological perspective. *Proc. Natl. Acad. Sci. U.S.A.* 1998; 95: 765-72.
5. Dechent P, Frahm J. Functional somatotopy of finger representations in human primary motor cortex. *Hum.Brain Mapp.* 2003; 18: 272-83.
6. Hlustik P, Solodkin A, Gullapalli RP, Noll DC, Small SL. Somatotopy in human primary motor and somatosensory hand representations revisited. *Cereb.Cortex* 2001; 11: 312-21.
7. Penfield W, Rasmussen T. The cerebral cortex of man: a clinical study of localization of function. New York: Macmillan, 1950.
8. Neugroschl C, Denolin V, Schuind F *et al.* Functional MRI activation of somatosensory and motor cortices in a hand-grafted patient with early clinical sensorimotor recovery. *Eur. Radiol.* 2005; 15: 1806-14.

9. Blake DT, Byl NN, Merzenich MM. Representation of the hand in the cerebral cortex. *Behav. Brain Res.* 2002; 135: 179-84.
10. Kew JJ, Ridding MC, Rothwell JC *et al.* Reorganization of cortical blood flow and transcranial magnetic stimulation maps in human subjects after upper limb amputation. *J. Neurophysiol.* 1994; 72: 2517-24.
11. de Jong BM, Coert JH, Stenekes MW *et al.* Cerebral reorganisation of human hand movement following dynamic immobilisation. *Neuroreport* 2003; 14: 1693-6.
12. de Jong BM, van der Graaf FH, Paans AM. Brain activation related to the representations of external space and body scheme in visuomotor control. *Neuroimage* 2001; 14: 1128-35.
13. Poizner H, Clark MA, Merians AS *et al.* Joint coordination deficits in limb apraxia. *Brain* 1995; 118: 227-42.
14. Jueptner M, Weiller C. A review of differences between basal ganglia and cerebellar control of movements as revealed by functional imaging studies. *Brain* 1998; 121: 1437-49.
15. van der Graaf FH, de Jong BM, Maguire RP, Meiners LC, Leenders KL. Cerebral activation related to skills practice in a double serial reaction time task: striatal involvement in random-order sequence learning. *Brain Res. Cogn. Brain Res.* 2004; 20: 120-31.
16. Wernicke C. Der aphasische Symptomenkomplex. In Cohn Weigert, ed. Breslau: 1874.
17. Rogers BP, Carew JD, Meyerand ME. Hemispheric asymmetry in supplementary motor area connectivity during unilateral finger movements. *Neuroimage* 2004; 22: 855-9.
18. Broca P. Du siège de la faculté du langage articulé. *Bulletins de la Société d'Anthropologie* 1865;6:377-93.
19. Joseph R. The right cerebral hemisphere: emotion, music, visual-spatial skills, body-image, dreams, and awareness. *J.Clin.Psychol.* 1988; 44: 630-73.
20. Volkman J, Schnitzler A, Witte OW, Freund H. Handedness and asymmetry of hand representation in human motor cortex. *J.Neurophysiol.* 1998; 79: 2149-54.
21. Serrien DJ, Ivry RB, Swinnen SP. Dynamics of hemispheric specialization and integration in the context of motor control. *Nat.Rev.Neurosci.* 2006; 7: 160-6.
22. Kobayashi M, Hutchinson S, Schlaug G, Pascual-Leone A. Ipsilateral motor cortex activation on functional magnetic resonance imaging during unilateral hand movements is related to interhemispheric interactions. *Neuroimage* 2003; 20: 2259-70.



## Cerebral consequences of dynamic immobilization after primary digital flexor tendon repair

23. Solodkin A, Hlustik P, Noll DC, Small SL. Lateralization of motor circuits and handedness during finger movements. *Eur. J. Neurol.* 2001; 8: 425-34.
24. Oldfield RC. The assessment and analysis of handedness: the Edinburgh inventory. *Neuropsychologia* 1971; 9: 97-113.
25. Elhassan B, Moran SL, Bravo C, Amadio P. Factors that influence the outcome of zone I and zone II flexor tendon repairs in children. *J. Hand Surg.-Am. Vol.* 2006; 31: 1661-6.
26. Raichle ME. Circulatory and metabolic correlates of brain function in normal humans. *Handbook of Physiology, Vol. 5, The Nervous System*, pp 643-74. New York: American Physiology Society, 1987.
27. SPM99. <http://www.fil.ion.ucl.ac.uk/spm/software/spm99/> . 2005.  
Ref Type: Internet Communication
28. Buck-Gramcko D, Dietrich FE, Gogge S. Evaluation criteria in follow-up studies of flexor tendon therapy. *Handchirurgie.* 1976; 8: 65-9.
29. Mink JW, Thach WT. Basal ganglia motor control. II. Late pallidal timing relative to movement onset and inconsistent pallidal coding of movement parameters. *J. Neurophysiol.* 1991; 65: 301-29.
30. de Jong BM, Paans AM. Medial versus lateral prefrontal dissociation in movement selection and inhibitory control. *Brain Res.* 2007; 1132: 139-47.
31. van der Graaf FH, Maguire RP, Leenders KL, de Jong BM. Cerebral activation related to implicit sequence learning in a Double Serial Reaction Time task. *Brain Res.* 2006; 1081: 179-90.
32. Mink JW. The Basal Ganglia and involuntary movements: impaired inhibition of competing motor patterns. *Arch. Neurol.* 2003; 60: 1365-8.
33. Stenekes MW, Hoogduin JM, Mulder T *et al.* Functional dominance of finger flexion over extension, expressed in left parietal activation. *Neuroimage* 2006; 32: 676-83.
34. Picard N, Strick PL. Motor areas of the medial wall: a review of their location and functional activation. *Cereb. Cortex* 1996; 6: 342-53.
35. Gitelman DR, Nobre AC, Parrish TB *et al.* A large-scale distributed network for covert spatial attention: further anatomical delineation based on stringent behavioural and cognitive controls. *Brain* 1999; 122: 1093-106.
36. Hinkley LB, Krubitzer LA, Nagarajan SS, Disbrow EA. Sensorimotor integration in S2, PV, and parietal rostroventral areas of the human sylvian fissure. *J. Neurophysiol.* 2007; 97: 1288-97.