

University of Groningen

Performance of the Straumann Bone Level Implant system for anterior single-tooth replacements in augmented and nonaugmented sites

Santing, Hendrik J.; Raghoobar, Gerry M.; Vissink, Arjan; den Hartog, Laurens; Meijer, Henny J. A.

Published in:
CLINICAL ORAL IMPLANTS RESEARCH

DOI:
[10.1111/j.1600-0501.2012.02486.x](https://doi.org/10.1111/j.1600-0501.2012.02486.x)

IMPORTANT NOTE: You are advised to consult the publisher's version (publisher's PDF) if you wish to cite from it. Please check the document version below.

Document Version
Publisher's PDF, also known as Version of record

Publication date:
2013

[Link to publication in University of Groningen/UMCG research database](#)

Citation for published version (APA):

Santing, H. J., Raghoobar, G. M., Vissink, A., den Hartog, L., & Meijer, H. J. A. (2013). Performance of the Straumann Bone Level Implant system for anterior single-tooth replacements in augmented and nonaugmented sites: A prospective cohort study with 60 consecutive patients. *CLINICAL ORAL IMPLANTS RESEARCH*, 24(8), 941-948. <https://doi.org/10.1111/j.1600-0501.2012.02486.x>

Copyright

Other than for strictly personal use, it is not permitted to download or to forward/distribute the text or part of it without the consent of the author(s) and/or copyright holder(s), unless the work is under an open content license (like Creative Commons).

The publication may also be distributed here under the terms of Article 25fa of the Dutch Copyright Act, indicated by the "Taverne" license. More information can be found on the University of Groningen website: <https://www.rug.nl/library/open-access/self-archiving-pure/taverne-amendment>.

Take-down policy

If you believe that this document breaches copyright please contact us providing details, and we will remove access to the work immediately and investigate your claim.

Downloaded from the University of Groningen/UMCG research database (Pure): <http://www.rug.nl/research/portal>. For technical reasons the number of authors shown on this cover page is limited to 10 maximum.

Hendrik J. Santing
 Gerry M. Raghoobar
 Arjan Vissink
 Laurens den Hartog
 Henny J. A. Meijer

Performance of the Straumann Bone Level Implant system for anterior single-tooth replacements in augmented and nonaugmented sites: A prospective cohort study with 60 consecutive patients

Authors' affiliations:

Hendrik J. Santing, Gerry M. Raghoobar, Arjan Vissink, Laurens den Hartog, Henny J. A. Meijer, Department of Oral and Maxillofacial Surgery, University Medical Center Groningen, University of Groningen, Groningen, the Netherlands
 Laurens den Hartog, Henny J. A. Meijer, Department of Fixed and Removable Prosthodontics, University Medical Center Groningen, University of Groningen, Groningen, the Netherlands

Corresponding author:

Dr. H. J. Santing
 Department of Oral and Maxillofacial Surgery
 University Medical Center Groningen
 Hanzeplein 1
 PO Box 30.001, 9700 RB, Groningen,
 the Netherlands
 Tel.: +31 (0)50 3611054
 Fax: +31 (0)50 3611136
 e-mail: h.j.santing@umcg.nl

Key words: biomaterials, bone regeneration, clinical assessment, clinical research, clinical trials, diagnosis, guided tissue regeneration, periodontology, prosthodontics, soft tissue-implant interactions

Abstract

Aim: The purpose of this prospective study was to evaluate radiographic, clinical and aesthetic outcomes and patient satisfaction of cases treated with platform-switched single implant restorations in the aesthetic region of the maxilla. Furthermore, the influence of an augmentation procedure 3 months before implant placement and the type of restoration (screw-retained vs. cement-retained) was evaluated.

Material and methods: Sixty patients with a missing anterior tooth in the maxilla were treated with a Straumann Bone Level Implant. Bone augmentation was performed in 29 patients at 3 months before implant placement. Implants were loaded after 3 months of submerged healing. Follow-up was conducted at 7 and 18 months after implant placement. Peri-implant mucosa and implant crown aesthetic outcomes were determined using the Implant Crown Aesthetic Index (ICAI) and the Pink Esthetic Score-White Esthetic Score (PES-WES).

Results: No implants were lost. At 18 months after implant placement, mean bone level change was -0.10 ± 0.27 mm and mean probing pocket depth was 2.57 mm. No differences were found between augmented and nonaugmented sites ($P = 0.28$). The ICAI indicated satisfactory mucosa and crown aesthetics in 67% and 75% of the cases, respectively, while the PES score was 14.4. ICAI mucosa ($P = 0.004$) and PES ($P = 0.02$) scores were significantly less favourable for augmented sites compared with nonaugmented sites. Patient satisfaction was high (8.9 ± 1.1 on VAS-score).

Conclusions: From the present prospective, clinical study, it can be concluded that the Straumann Bone Level Implant shows an excellent survival rate, marginal bone stability and good clinical and aesthetic results. Bone augmentation before implant placement does not lead to more marginal bone loss. However, less favourable pink aesthetic outcomes were found in augmented sites compared with nonaugmented sites, while no differences were found between cement-retained and screw-retained restorations.

The use of dental implants in oral rehabilitation has become a standard of care in daily practice. High survival rates are generally reported (den Hartog et al. 2008). However, to further improve the survival rates and to raise the quality of survival, new implant systems, implant surfaces and implant designs are continuously developed.

In 2007, the Straumann Bone Level Implant system (Institut Straumann AG, Basel, Switzerland) was introduced to the

market. This implant system offers various features that claim to improve implant survival, decrease bone loss and improve aesthetic outcomes. The Straumann Bone Level Implant is equipped with the SLActive implant surface (Ferguson et al. 2006; Rupp et al. 2006). This implant surface has shown to accelerate osseointegration compared to the SLA surface (Oates et al. 2007; Schatzle et al. 2009) and provides high survival rates even in sites with compromised bone (Gane-

Date:
 Accepted 21 March 2012

To cite this article:

Santing HJ, Raghoobar GM, Vissink A, den Hartog L, Meijer HJA. Performance of the Straumann Bone Level Implant system for anterior single-tooth replacements in augmented and nonaugmented sites: A prospective cohort study with 60 consecutive patients.
Clin. Oral Impl. Res. 24, 2013, 941–948
 doi: 10.1111/j.1600-0501.2012.02486.x

les et al. 2008; Rocuzzo & Wilson 2009). The implant-prosthetic connection of the Straumann Bone Level Implant shows a platform switch. The rationale behind this feature is displacing the implant-abutment interface, and thereby the microgap, away from the edge of the implant platform. According to a recent review, various studies have shown that platform-switched implants show less marginal bone loss compared to platform-matched implants (Atieh et al. 2010). It is hypothesized that marginal bone is crucial not only for maintaining soft tissue levels, and thereby obtaining aesthetically satisfying results, but also for limiting formation of pockets around the implant. Another important condition for establishing aesthetic results is control of the emergence profile. Increasing the distance between the top of the implant and the soft tissue margin by placing the top of the implant at bone level provides more prosthetic freedom than positioning the top of the implant beyond bone level (e.g. transmucosal implants).

Bone augmentation is often needed before implant placement due to insufficient bone volume. A recent review showed that bone augmentation procedures are effective in promoting bone fill and defect resolution at implants in postextraction sites. However, these procedures are more successful with immediate (type 1) and early placement (type 2 and type 3) than with late placement (type 4, completely healed sites) (Chen & Buser 2009). Type 2 is defined as early placement with soft tissue healing (typically 4–8 weeks) without significant bone healing, whereas type 3 is defined as early placement with partial bone healing (typically 12–16 weeks).

The purpose of this prospective study was to evaluate radiographic, clinical and aesthetic outcomes and patient satisfaction of cases treated with platform-switched single implant restorations in the aesthetic region of the maxilla. Furthermore, the influence of an augmentation procedure 3 months before implant placement and the type of restoration (screw-retained vs. cement-retained) was evaluated.

Materials and methods

Study design

This clinical study was designed as a single-cohort, prospective case series ($n = 60$) with an 18-month follow-up (Fig. 1). The study was conducted at the Department of Oral and Maxillofacial Surgery of the University Medical Center Groningen, Groningen, the Netherlands. The study protocol has been

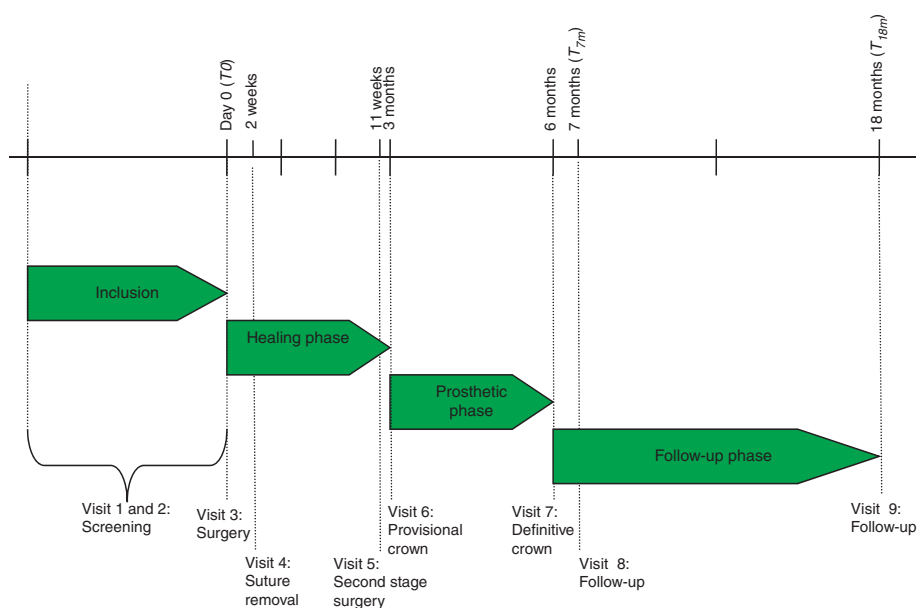


Fig. 1. Schedule of visits and procedures.

independently reviewed and approved by the Medical Ethical Committee of the University Medical Center Groningen. Written informed consent was obtained from all eligible patients before enrolment. Patients were included between October 2007 and June 2009. The study was performed in compliance with Good Clinical Practice, the Declaration of Helsinki and local legal and regulatory requirements.

Participants

Patients referred for single-implant treatment in the maxillary aesthetic zone were considered for inclusion if they fulfilled the following criteria:

- At least 18 years of age.
- One missing tooth being an incisor, canine or first premolar in the maxilla with adjacent natural teeth.
- Space width with mesial–distal width of at least 6 mm.

Patients were excluded from participation in this study if they met one of the following criteria:

- American Society of Anesthesiologists (ASA) physical status classification system score \geq III (Smeets et al. 1998).
- Presence of clinically active periodontal disease as expressed by probing pocket depths \geq 4 mm in combination with bleeding on probing.
- Presence of peri-apical lesions or any other abnormalities in the anterior region

of the maxilla as detected on a radiograph.

- Smoking <3 months before bone augmentation (if applicable) or implant placement.
- Tooth extraction <3 months before implant placement.

Intervention

Implant placement

The implants used in this study were 3.3 mm Bone Level NC[®] and 4.1 mm Bone Level RC[®] implants (Institut Straumann AG). A bone augmentation procedure was carried out if insufficient bone volume was present (Raghoobar et al. 2009). As a grafting material, autogenous bone from the retromolar ramus was used. Implants were inserted 3 months after the augmentation procedure.

Prophylactic antibiotic therapy started 1 day before implant placement surgery (amoxicillin 500 mg, three times daily for 7 days or clindamycin 300 mg, four times daily for 7 days in case of amoxicillin allergy). Patients were instructed to use a 0.2% chlorhexidine mouthwash (two times daily for 7 days) for oral disinfection starting 1 day before surgery. Following local anaesthesia, a slightly palatal crest-incision was made with extensions through the buccal and palatal sulci of the adjacent teeth and a divergent releasing incision at the buccodistal aspect of the distal tooth. A minimal mucoperiosteal flap was raised to expose the alveolar ridge. To obtain an ideal position for the implant

and subsequent implant crown, a surgical template was used. Local augmentation with autogenous bone chips and anorganic bovine bone (Geistlich Bio-Oss; Geistlich Pharma AG, Wolhusen, Switzerland) covered with Geistlich Bio-Gide membrane (Geistlich Pharma AG) was performed when parts of the implant remained uncovered or when the bone wall thickness buccally to the implant was less than 2 mm. It was aimed for a thickness of the labial bone of at least 2 mm. The wound was closed with Ethilon 5-0 nylon sutures (Johnson & Johnson Gateway, Piscataway, NJ, USA).

Healing phase

During the healing phase, patients wore a removable partial denture that did not interfere with the wound. Patients were instructed in postoperative dental hygiene procedures. Sutures were removed 2 weeks after surgery. After 3 months, implants were uncovered and a healing abutment (Institut Straumann AG) was placed.

Prosthetic phase

One week after second-stage surgery, an implant-level impression was made. A screw-retained provisional crown was screwed directly onto the implant with 35 N cm with a manual torque wrench (Institut Straumann AG). After a provisional phase of 3 months (i.e. 6 months after implant placement), a final impression was taken at implant level. In the dental laboratory, a soft tissue cast was prepared. After placement of a scanbody (Straumann Scanbody®; Institut Straumann AG) in the implant analogue (Implant analog, Institut Straumann AG), the cast was scanned using an Etkon es1 scanner (Etkon es1®; Etkon, Gräfelfing, Germany) according to the manufacturer's guidelines. Subsequently, a CARES custom abutment was designed using the CAD abutment manager software. The digital design was transferred to the milling centre (CAD/CAM Milling Production Europe, Straumann CAD/CAM GmbH, Markleeberg, Germany) where a ZrO₂ abutment was milled. Depending on the location of the screw access hole, the final crown was either cement-retained using a zirconia coping (CAD/CAM Milling Production Europe, Straumann CAD/CAM GmbH, veneered with porcelain (Emax Ceram, Ivoclar Vivadent, Liechtenstein; $n = 27$) or screw-retained ($n = 33$) by fusing porcelain (Emax Ceram) directly to the abutment. Abutment screws were torqued to 35 Ncm. Cement-retained crowns were cemented with glass ionomer cement (Fuji Plus; GC Europe,

Leuven, Belgium). The mutually protected articulation concept was used for the implant-supported restoration.

Outcomes

Before implant placement (T_{pre}) and 7 months (T_{7m} , i.e. 1 month after definitive crown placement, 4 months of functional loading, 7 months after implant placement) and 18 months after implant placement (T_{18m} , 12 months after definitive crown placement and 15 months of functional loading), patients were seen for clinical data collection and photographic assessment. Radiographic assessment took place after implant placement (baseline, T_0) and 7 (T_{7m}) and 18 months (T_{18m}) after implant placement. Outcome variables were survival rate, marginal bone level changes, buccal marginal recession, papilla height change, papilla volume, presence of plaque, bleeding on probing, probing pocket depth, aesthetics and patient satisfaction.

Survival rate

Survival rate was determined at T_{7m} and T_{18m} , and was defined as the percentage of the implants that remained in the mouth.

Radiographic evaluation

Change in marginal bone level was calculated from standardized digital intra-oral radiographs taken with an individualized aiming device as described by Meijndert et al. (Meijndert et al. 2004). Full-screen analysis of the radiographs was performed using the known implant diameter as a reference value for calibration of the radiograph. One examiner evaluated all radiographs. The vertical distance from the shoulder of the implant to the first bone-to-implant contact was measured at both the distal and mesial site of the implant. In addition, the vertical distance from a reference line on top of the implant shoulder to the first bone-to-tooth contact at the neighbouring sites of the adjacent teeth was measured.

Photographic evaluation

Standardized digital photographs (camera: Fuji-film FinePix S3 Pro) were taken at T_{pre} , T_{7m} and T_{18m} using a technique that has been described comprehensively by Meijndert et al. (Meijndert et al. 2004). An additional photograph was taken while a periodontal probe was held in close proximity and parallel to the long axis of the adjacent tooth. The known dimensions of the periodontal probe allowed calibration of the photographs. Full-screen analysis of the photographs was

performed using a digital picture editing program (Adobe Photoshop CS3 Extended; Adobe Systems Inc., San Jose, USA). The following variables were assessed on the photographs, both at the implant and adjacent teeth:

- *Buccal marginal recession*: the change between different follow-up examinations, in vertical distance from the incisal edge of the crown to the soft tissue margin at the mid-buccal aspect of both the implant and adjacent teeth.
- *Papilla height change*: the change between different follow-up examinations, in vertical distance from the line through the incisal edges of the implant crown and crown of the adjacent tooth to the most coronal point of the papilla.
- *Papilla volume*: assessing the mesial and distal papilla adjacent to the implant using the papilla index (Jemt 1997): 0 = no papilla, 1 = less than half of the papilla fills up the proximal space, 2 = at least half of the papilla is present, but not all the way up to the contact point, 3 = papilla fills up the entire proximal space, and 4 = papilla is hyperplastic.

Clinical evaluation

The following clinical variables were assessed, both at the implant and adjacent teeth at T_{pre} (only adjacent teeth), T_{7m} and T_{18m} :

- *Plaque*: assessed at four sites per implant/adjacent tooth (mesial, buccal, distal and lingual) using the modified plaque index (Mombelli et al. 1987): 0 = no detection of plaque; 1 = plaque can be detected by running a probe across the surface of the crown; 2 = plaque visible with the naked eye; and 3 = abundance of plaque.
- *Bleeding*: assessed at four sites per implant/adjacent tooth (mesial, buccal, distal and lingual) using the modified sulcus bleeding index (Mombelli et al. 1987): 0 = no bleeding running a periodontal probe along the sulcus; 1 = isolated bleeding spots visible; 2 = a confluent red line of blood along the gingival margin; and 3 = profuse bleeding.
- *Probing pocket depth*: measured to the nearest 1 mm using a manual periodontal probe (Williams Color-Coded Probe; Hu-Friedy, Chicago, IL, USA) at the mesial, buccal, distal and lingual aspects of the implant and adjacent teeth.

Aesthetic evaluation

Aesthetic outcome was assessed on standardized digital photographs (camera: Fuji-film FinePix S3 Pro) taken at T_{18m} . The implant crown and adjacent dentition were captured on one photograph centred at the facial midline. Of implant crowns replacing the lateral, canine or bicuspid, two additional photographs were taken on which the implant and contralateral tooth were captured.

Peri-implant mucosa and implant crown aesthetic outcomes were determined using the Implant Crown Aesthetic Index (ICAI) (Meijer et al. 2005) and the Pink Esthetic Score-White Esthetic Score (PES-WES) (Belser et al. 2009). Measurements were carried out independently by two examiners. The results were averaged.

Patient satisfaction

Patient satisfaction was assessed at T_{7m} and T_{18m} using a questionnaire (den Hartog et al. 2011a,b) consisting of questions regarding form and colour of the crown and form and colour of the peri-implant mucosa. Answers were to be given using a five-point scale ranging from "very dissatisfied" to "very satisfied". Overall satisfaction was questioned using a 100-mm visual analogue scale (VAS) with word descriptors "very dissatisfied" and "very satisfied" on the left end and right end respectively.

Statistical methods

Data analysis was performed using a statistical software package (PASW Statistics 18.0, SPSS Inc.; An IBM Company, IBM Corporation, Chicago, IL, USA). Non-normally distributed variables were analysed using the Wilcoxon signed-rank test. Between-group comparisons were statistically explored with Mann-Whitney *U*-test.

Dependent dichotomous variables were analysed using the McNemar test.

The inter-examiner reliability was assessed based on 15 randomly selected photographs independently evaluated by two examiners using both aesthetic indices. The intra-observer reliability has been reported as acceptable in earlier studies (Meijer et al. 2005; Belser et al. 2009).

Results

Baseline demographic and clinical characteristics are depicted in Table 1. All patients completed the study and attended the follow-up visits. The majority (65%) of the implants were placed at the position of the central incisor. Most patients needed implant treat-

Table 1. Summary of demographic and baseline characteristics

	<i>N</i> = 60
Mean age (SD) in years	36.9 (15.09)
Range of age in years	18–71
Male/female ratio	29/31
Implant site location I1/I2/C/P1	39/10/5/6
Implant diameter 3.3 mm/4.1 mm	12/48
Implant length 12 mm/14 mm	16/44
Augmentation before surgery*, <i>n</i>	29
Reason for tooth loss, <i>n</i>	
Fracture	29
Unsuccessful endodontic treatment	19
Root resorption	5
Periodontal disease	4
Agnesis	3
Type of final restoration, <i>n</i>	
Screw-retained	33
Cement-retained	27

*implant was placed 3 months later.

ment because of tooth loss directly or indirectly related to trauma (fracture, unsuccessful endodontic treatment, root resorption). Bone augmentation was performed in 29 of the 60 patients and 33 restorations were screw-retained vs. 27 cement-retained.

No implants were lost during the study resulting in an implant survival rate of 100% at T_{18m} . Mesial and distal bone level changes are summarized in Table 2. The mean bone level change at the implants was -0.08 ± 0.24 mm from T_0 to T_{7m} and -0.10 ± 0.27 mm from T_0 to T_{18m} . There was no difference in mean marginal bone level changes between augmented (-0.08 ± 0.17 mm, [95% CI = 0.04–0.12]) and nonaugmented sites (-0.12 ± 0.34 mm, 95% CI = 0.02–0.10]; ($P = 0.28$, Mann-Whitney *U*-test). The type of restoration (screw retained vs. cement

retained) showed no difference in mean marginal bone level changes ($P = 0.72$, Mann-Whitney *U*-test).

The level of the mid-buccal peri-implant mucosa remained stable after placement of the definitive crown, while a gain in papilla height was observed between T_{7m} and T_{18m} (mean 0.23 ± 0.41 mm). From T_{pre} to T_{18m} , the mid-buccal gingival level of the adjacent teeth showed a mean recession of 0.21 ± 0.43 mm. No differences in mid-buccal mucosa recession between augmented and nonaugmented sites ($P = 0.19$, Mann-Whitney *U*-test) and type of restoration (screw-retained vs. cement-retained) ($P = 0.41$, Mann-Whitney *U*-test) were found. Gingival recession predominantly occurred during the first 7 months after adjacent implant placement (Table 2). Only one implant showed more than 1 mm recession. The volume of the mesial papilla, as determined by the papilla index, increased significantly from T_{7m} to T_{18m} ($P = 0.009$, Wilcoxon signed rank test). The volume of the distal papilla did not significantly change between both examinations. In three patients, either one of the papillae was absent (score 0), whereas in 12 patients, the papillae completely filled both the mesial and distal interdental space (score 3). Seven patients received score 1 as the least score for the mesial and/or the distal papilla and 38 patients received a worst score of 2 (at least half of the papilla present) (Fig. 2).

At T_{18m} , 15% of the implants/patients harboured plaque at the mesial, distal, buccal or lingual sites of the implant, whereas plaque at the adjacent teeth was observed in 13.3%

Table 2. Change in marginal bone level and marginal soft tissue levels at implant and tooth sides from baseline to 18 months

	Baseline [†] –T7 m	T7–T18 m	Baseline [†] T18 m
Marginal bone level changes [‡] (mm)			
Mesial of implant	-0.05 ± 0.16	-0.01 ± 0.10	-0.06 ± 0.17
Distal of implant	-0.10 ± 0.35	-0.03 ± 0.16	-0.14 ± 0.40
Mesial tooth side	-0.01 ± 0.09	0.02 ± 0.08	0.01 ± 0.12
Distal tooth side	-0.02 ± 0.18	0.00 ± 0.14	-0.01 ± 0.21
Implant bone loss* (%)			
0–0.5 mm	97.5	100	95.8
0.5–1 mm	0	0	0.8
1–1.5 mm	1.7	0	2.5
1.5–2 mm	0	0	0
≥ 2 mm	0.8	0	0.8
Marginal soft tissue level changes [‡] (mm)			
Mesial implant papilla		0.19 ± 0.39	
Distal implant papilla		0.27 ± 0.46	
Mid-facial of implant		0.04 ± 0.29	
Mesial tooth	-0.13 ± 0.32	-0.06 ± 0.26	-0.19 ± 0.41
Distal tooth	-0.19 ± 0.39	-0.03 ± 0.33	-0.22 ± 0.48

*Mesial and distal sides combined.

[†]After implant placement for bone levels, before implant placement for soft tissue levels.

[‡]Means \pm SDs.

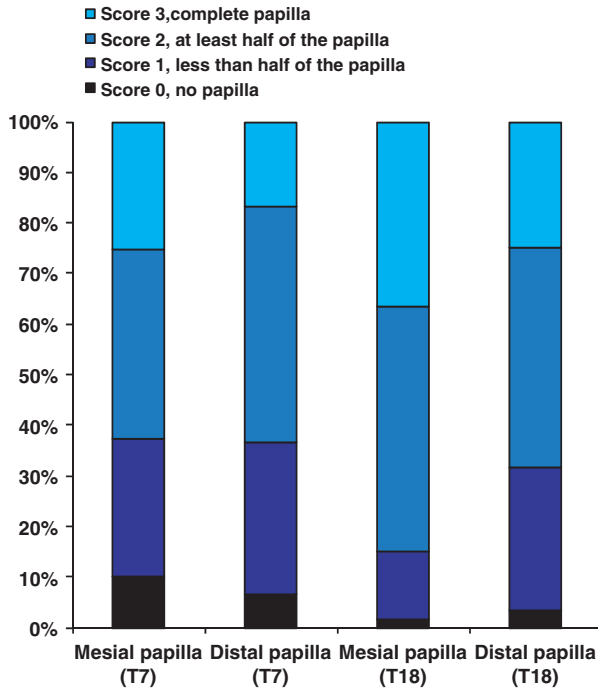


Fig. 2. Frequency distribution of papilla index scores at 7 and 18 months after implant placement.

of the patients. Bleeding on probing was seen more frequently at implants (38.3% of implants/patients) than at adjacent teeth (23.3% of patients) ($P < 0.0032$, McNemar), but remained constant over time for both implants and adjacent teeth (Fig. 3). However, not reaching the level of significance, probing pocket depths at implants showed a tendency to decrease between T_{7m} and T_{18m}

($P = 0.09$, Wilcoxon signed rank test), whereas probing pocket depths at adjacent teeth remained stable. At two implants, a

probing pocket depth of 5 mm was observed (Table 3). All other probing pocket depth measurements fell within the range of 2–4 mm (Fig. 4). The type of restoration revealed no difference ($P = 0.65$, Mann–Whitney U -test).

The ICAI showed satisfactory inter-observer agreement with a weighted κ -value of 0.61. A weighted κ -value of 0.72 and 0.61 for the PES and WES, respectively, was calculated showing also satisfactory inter-observer agreement for these indices.

According to the ICAI, 40 patient cases (66.7%) showed satisfactory or excellent mucosa aesthetics. ICAI mucosa showed significantly worse scores ($P = 0.004$, Mann–Whitney U -test) when bone augmentation before implant placement was conducted. A PES-score of more than 6 (acceptable mucosa aesthetics) was given in 71.7% of the cases. The PES also showed a significant difference between augmented (6.3) and nonaugmented cases (7.5) ($P = 0.02$, Mann–Whitney U -test). A total of 45 cases showed satisfactory crown aesthetics on the ICAI (75%), whereas a WES-score higher than 6 (acceptable crown aesthetics) was given in 86.7% of the cases (Table 4).

Table 3. Probing pocket depths at implant and tooth sides from baseline to 18 months.

	Baseline [†]	T7 m	T18 m
Pocket depth (mm)			
Mesial of implant		2.82 ± 0.65	2.67 ± 0.71
Distal of implant		2.88 ± 0.72	2.75 ± 0.68
Mid-facial of the implant		2.58 ± 0.59	2.68 ± 0.62
Palatal of the implant		2.38 ± 0.54	2.24 ± 0.48
Proximal of teeth*	2.15 ± 0.45	2.08 ± 0.43	2.10 ± 0.52
Mid-facial of teeth	1.47 ± 0.53	1.53 ± 0.57	1.49 ± 0.45
Palatal of teeth	1.38 ± 0.38	1.40 ± 0.42	1.40 ± 0.34

*Mesial and distal sides combined.
[†]After implant placement for bone levels, before implant placement for soft tissue levels.

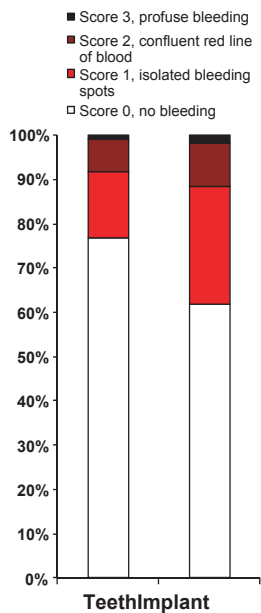


Fig. 3. Frequency distribution of bleeding index scores of implants and adjacent teeth at 18 months after implant placement (highest score per implant/tooth).

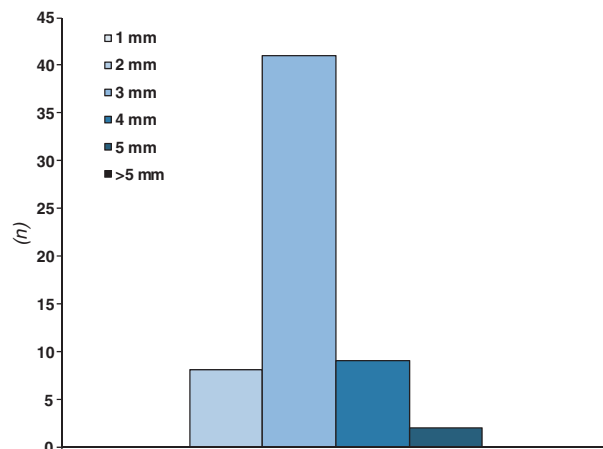


Fig. 4. Frequency distribution of probing pocket depth at 18 months after implant placement (highest score per implant).

Table 4. ICAI mucosa, ICAI crown, PES and WES scores

	ICAI mucosa	ICAI crown	PES	WES
Excellent	1 (1.7%)	2 (3.3%)		
Satisfactory	39 (65.0%)	43 (71.7%)		
Moderate	13 (21.7%)	12 (20.0%)		
Poor	7 (11.7%)	3 (5%)		
Mean ± SD			6.9 ± 1.8	7.5 ± 1.7
Range			2–9.5	4–10

The type of restoration revealed no difference ($P = 0.73$, Mann–Whitney U -test). The patient satisfaction was high as demonstrated in Table 5. General patient satisfaction as scored using the VAS ranged from 6 to 10.

Complications

All 60 patients had a stable and functional prosthetic restoration at T_{18m} . During the follow-up period, one patient returned to the prosthodontist with a porcelain fracture. Because it was a screw-retained restoration, the crown could easily be removed and sent to the laboratory for repair. No screw loosening or other mechanical complications occurred.

Discussion

This study evaluated the performance of the Straumann Bone Level Implant for single-tooth replacements in the aesthetic zone. The 18-month implant survival rate was 100%. The other radiographic, clinical and aesthetic parameters also showed excellent results. Sites with bone augmentation before implant placement did not show differences in marginal bone level changes; however, mucosa aesthetics were significantly worse compared with nonaugmented sites.

A meta-analysis published in 2008 on the implant survival of conventionally placed and conventionally loaded implants in the aesthetic zone revealed an implant survival rate after one year of 92.8% (95% CI 82.7–97.2) (den Hartog et al. 2008). This is somewhat lower than the survival rate found in the present study, indicating that the Straumann Bone Level Implant performs at least

equally well to other implant systems with regard to establishment of osseointegration. A recent prospective study using 20 Straumann Bone Level implants with an early placement protocol reported a mean marginal bone loss of 0.18 mm after 36 months of loading (Buser et al. 2011). Frequency analysis demonstrated minimal bone resorption (<0.25 mm) for 15 of 20 implants. Of 20 implants, only two showed bone loss between 0.5 and 1.0 mm. This observation resembles our findings of almost negligible bone loss. In the present study, little marginal bone loss was observed 18 months after implant placement (0.10 mm). Frequency analysis demonstrated minimal bone resorption (<0.50 mm) for 57 of 60 implants. Of 60 implants, only two showed bone loss between 1.0 and 1.5 mm, while one implant showed more than 2.0 mm bone loss. Most bone loss occurred during the first 7 months after implant placement and virtually no bone loss occurred after placement of the definitive crown, indicating stable bone levels. The amount of bone loss after definitive crown placement found in the present study (0.02 mm) is low compared with what has been reported in other studies on conventional single-tooth implant therapy in the aesthetic zone. A meta-analysis conducted in 2008 revealed a mean bone loss of 0.20 mm (95% CI: [0.034–0.36]) occurring from definitive crown placement to 1 year thereafter (den Hartog et al. 2008). In a more recent study, Meijndert et al. reported a mean marginal bone loss of 0.14 mm using the Straumann aesthetic plus implant (SLA surface) (Meijndert et al. 2008). Den Hartog et al. reported a comparable amount of bone loss (0.11 mm) after definitive crown placement

using the NobelReplace tapered groovy implant (Nobel Biocare AB) (den Hartog et al. 2011b). In both studies, loading protocols and techniques for taking and analysing the standardized radiographs were similar to those in the present study. However, Den Hartog et al. found noticeably more bone loss in the initial healing phase (0.80 mm from implant placement to crown placement) compared with the present study (0.10 mm). It is hypothesized that this difference is caused by differences in implant surface, the design of the implant abutment-connection providing a good seal between the implant and the abutment and the platform switch design. These factors might reduce the amount of bone loss observed during the establishment of the biological width. However, thereafter, stable bone levels can be reached in both situations.

The level of the mid-buccal peri-implant mucosal margin remained stable during the follow-up period, as could be derived from the low amount of mucosal recession (0.04 mm between T_{7m} and T_{18m}) that has been found in the present study. Only one implant showed more than 1 mm recession. It might be hypothesized that these stable buccal peri-implant mucosa levels are the result of the stable marginal bone levels. This is consistent with the results of Nisapakultorn and coworkers (Nisapakultorn et al. 2010), who found that the facial marginal mucosal level is, amongst other factors such as peri-implant biotype, the implant fixture angle and the depth of implant platform, affected by the facial bone crest level, the interproximal bone crest level and the level of first bone to implant contact. However, Cairo et al. concluded in a systematic review that future mucosal recession around dental implants is not associated with peri-implant bone level (Cairo et al. 2008).

The volume of the interdental papilla, as indicated by the papilla index, significantly increased during follow-up (from T_{7m} to T_{18m}). The papilla height also increased during that same interval (by on average 0.23 mm). Several studies have shown that the level of the interdental papilla is independent of the peri-implant marginal bone level, but is related to the marginal bone level at the adjacent teeth (Choquet et al. 2001; Kan et al. 2003; Tarnow et al. 2003; Romeo et al. 2008; Kourkouta et al. 2009; Nisapakultorn et al. 2010). In our study, the marginal bone levels of adjacent tooth sites were very stable during the entire study period, from pre-implantation to 18 months of follow-up. However, this does not explain the increase in papilla height and fill that has been

Table 5. Patient satisfaction

	Colour of the crown	Form of the crown	Colour of the mucosa around the implant	Form of the mucosa around the implant	General patient satisfaction (VAS-score; mean ± SD)
Number of patients being satisfied (%) [*]	57 (95.0%)	58 (96.7%)	54 (90.0%)	52 (86.7%)	8.9 ± 1.1

^{*}Measured on a 5-point scale (4 and 5 denote satisfied and very satisfied respectively).

observed after placement of the definitive crown. A possible explanation for this phenomenon might be the increase in pressure on the peri-implant soft tissues resulting from replacing a healing abutment or provisional crown by a definitive crown with larger dimensions. It has been found that insertion of an implant crown (without any previous soft-tissue conditioning or prosthodontic treatment) affects the peri-implant mucosa morphology by an apical displacement at the mid-facial aspect, but a coronal displacement at the mesial and distal sites (Buser et al. 2011). Although it is expected that most change in papilla volume will occur immediately after placement of the crown, soft tissues might need more than one month to mature and establish their 'definitive' position and dimensions.

The gingiva of the adjacent teeth showed less bleeding on probing than the peri-implant mucosa. A possible explanation might be the anatomical variability between gingiva and peri-implant mucosa, making the latter more prone to damage as a result of probing pockets (Gerber et al. 2009).

In the present study, the aesthetic outcome of the treatment was evaluated using two different objective indices: the ICAI and the PES/WES. Using the ICAI, peri-implant mucosa esthetics were rated as satisfactory in 66.7% of the patients. Crown esthetics were satisfactory in 75% of the cases. The ICAI has been used in two other studies performed at the same research clinic as our study, applying the delayed loading protocol

in the aesthetic zone (Meijndert et al. 2007; den Hartog et al. 2011a). Den Hartog et al. reported satisfactory results for peri-implant mucosa and crown aesthetics in respectively 56.5% and 62% of the patients, and Meijndert et al. reported an overall satisfaction of 66%. The overall results from the PES/WES were also satisfying, showing a score of 6.9 for the PES and 7.5 for the WES. Comparable result were found by Den Hartog et al. (6.3 and 7.3 respectively) using the same loading protocol (den Hartog et al. 2011a). Both the ICAI and the PES/WES revealed less favourable results for the peri-implant mucosa compared with the crown.

A significant difference was found between augmented and nonaugmented cases with both the ICAI mucosa and PES indicating less favourable aesthetic outcomes after augmentation. As there was no difference in mean marginal bone loss between augmented and nonaugmented sites, the less favourable preoperative situation leading to augmentation is, in our opinion, responsible for the differences in aesthetic outcomes regarding ICAI mucosa and the PES. Furthermore, the surgical procedure leads to the formation of scar tissue, thereby compromising aesthetics.

Patient satisfaction was very high and comparable to other studies (Schropp et al. 2004; Pjetursson et al. 2005; den Hartog et al. 2008). Patients were satisfied with the appearance of both the peri-implant mucosa (88.3%) and the crown (91.7%). A difference exists between the professional and patient perception of the aesthetic outcomes, as is

consistent with what can be found in the literature (Chang et al. 1999; Meijndert et al. 2007; den Hartog et al. 2011a). Differences in relevance of factors affecting the aesthetic outcome between patients and professionals could explain the discrepancy in aesthetic perception (Chang et al. 1999). Furthermore, the final appreciation of the patient could have been affected by the preoperative situation. When the preoperative situation is compromised and the patient has a realistic expectation, the patient might be satisfied with the final result even when the outcome of an objective aesthetic index is poor. The aesthetic indices were not applied preoperatively.

Conclusion

From the present prospective, clinical study, it can be concluded that the Straumann Bone Level Implant shows a high survival rate, little marginal bone loss and good clinical and aesthetic results. Bone augmentation before implant placement does not lead to more marginal bone loss, but shows less favourable aesthetic outcomes compared to nonaugmented sites. No differences were found between cement-retained and screw-retained restorations.

Acknowledgements: This research was supported by Institut Straumann AG with a grant.

References

- Atieh, M.A., Ibrahim, H.M. & Atieh, A.H. (2010) Platform switching for marginal bone preservation around dental implants: a systematic review and meta-analysis. *Journal of Periodontology* **81**: 1350–1366.
- Belser, U.C., Grutter, L., Vailati, F., Bornstein, M.M., Weber, H.P. & Buser, D. (2009) Outcome evaluation of early placed maxillary anterior single-tooth implants using objective esthetic criteria: a cross-sectional, retrospective study in 45 patients with a 2- to 4-year follow-up using pink and white esthetic scores. *Journal of Periodontology* **80**: 140–151.
- Buser, D., Wittneben, J., Bornstein, M.M., Grütter, L., Chappuis, V. & Belser, U.C. (2011) Stability of contour augmentation and esthetic outcomes of implant-supported single crowns in the esthetic zone: 3-year results of a prospective study with early implant placement postextraction. *Journal of Periodontology* **82**: 342–349.
- Cairo, F., Pagliaro, U. & Nieri, M. (2008) Soft tissue management at implant sites. *Journal of Clinical Periodontology* **35**: 163–167.
- Chang, M., Odman, P.A., Wennstrom, J.L. & Andersson, B. (1999) Esthetic outcome of implant-supported single-tooth replacements assessed by the patient and by prosthodontists. *The International Journal of Prosthodontics* **12**: 335–341.
- Chen, S. T. & Buser, D. (2009) Clinical and esthetic outcomes of implants placed in postextraction sites. *The International Journal of Oral & Maxillofacial Implants* **24**(Suppl): 186–217.
- Choquet, V., Hermans, M., Adriaenssens, P., Daelemans, P., Tarnow, D.P. & Malevez, C. (2001) Clinical and radiographic evaluation of the papilla level adjacent to single-tooth dental implants. A retrospective study in the maxillary anterior region. *Journal of Periodontology* **72**: 1364–1371.
- Ferguson, S.J., Brogini, N., Wieland, M., de Wild, M., Rupp, F., Geis-Gerstorfer, J., Cochran, D.L. & Buser, D. (2006) Biomechanical evaluation of the interfacial strength of a chemically modified sandblasted and acid-etched titanium surface. *Journal of Biomedical Materials Research. Part A* **78**: 291–297.
- Ganeles, J., Zollner, A., Jackowski, J., ten Bruggenkatte, C., Beagle, J. & Guerra, F. (2008) Immediate and early loading of Straumann implants with a chemically modified surface (SLActive) in the posterior mandible and maxilla: 1-year results from a prospective multicenter study. *Clinical Oral Implants Research* **19**: 1119–1128.
- Gerber, J.A., Tan, W.C., Balmer, T.E., Salvi, G.E. & Lang, N.P. (2009) Bleeding on probing and pocket probing depth in relation to probing pressure and mucosal health around oral implants. *Clinical Oral Implants Research* **20**: 5–78.
- den Hartog, L., Huddleston Slater, J.J., Vissink, A., Meijer, H.J. & Raghoobar, G.M. (2008) Treatment outcome of immediate, early and conventional single-tooth implants in the aesthetic zone: a systematic review to survival, bone level, soft-tissue, aesthetics and patient satisfaction. *Journal of Clinical Periodontology* **35**: 1073–1086.
- den Hartog, L., Raghoobar, G.M., Huddleston Slater, J.J., Stellingsma, K., Vissink, A. & Meijer, H.J. (2011a) Single-tooth implants with different neck designs: a randomized clinical trial evaluating the aesthetic outcome. *Clinical Implant Dentistry and Related Research* doi: 10.1111/j.1708-8208.2011.00372.x

- den Hartog, L., Raghoobar, G.M., Stellingsma, K., Vissink, A. & Meijer, H.J. (2011b) Immediate non-occlusal loading of single implants in the aesthetic zone: a randomized clinical trial. *Journal of Clinical Periodontology* **38**: 186–194.
- Jemt, T. (1997) Regeneration of gingival papillae after single-implant treatment. *The International Journal of Periodontics & Restorative Dentistry* **17**: 326–333.
- Kan, J.Y., Rungcharassaeng, K., Umezū, K. & Kois, J.C. (2003) Dimensions of peri-implant mucosa: an evaluation of maxillary anterior single implants in humans. *Journal of Periodontology* **74**: 557–562.
- Kourkouta, S., Dedi, K.D., Paquette, D.W. & Mol, A. (2009) Interproximal tissue dimensions in relation to adjacent implants in the anterior maxilla: clinical observations and patient aesthetic evaluation. *Clinical Oral Implants Research* **20**: 1375–1385.
- Meijer, H.J., Stellingsma, K., Meijndert, L. & Raghoobar, G.M. (2005) A new index for rating aesthetics of implant-supported single crowns and adjacent soft tissues – the implant crown aesthetic index. *Clinical Oral Implants Research* **16**: 645–649.
- Meijndert, L., Meijer, H.J., Raghoobar, G.M. & Vissink, A. (2004) A technique for standardized evaluation of soft and hard peri-implant tissues in partially edentulous patients. *Journal of Periodontology* **75**: 646–651.
- Meijndert, L., Meijer, H.J., Stellingsma, K., Stegenga, B. & Raghoobar, G.M. (2007) Evaluation of aesthetics of implant-supported single-tooth replacements using different bone augmentation procedures: a prospective randomized clinical study. *Clinical Oral Implants Research* **18**: 715–719.
- Meijndert, L., Raghoobar, G.M., Meijer, H.J. & Vissink, A. (2008) Clinical and radiographic characteristics of single-tooth replacements preceded by local ridge augmentation: a prospective randomized clinical trial. *Clinical Oral Implants Research* **19**: 1295–1303.
- Mombelli, A., van Oosten, M.A., Schurch, E. Jr & Land, N.P. (1987) The microbiota associated with successful or failing osseointegrated titanium implants. *Oral Microbiology and Immunology* **2**: 145–151.
- Nisapakulorn, K., Suphanantachat, S., Silkosessak, O. & Rattanamongkolgul, S. (2010) Factors affecting soft tissue level around anterior maxillary single-tooth implants. *Clinical Oral Implants Research* **21**: 662–670.
- Oates, T.W., Valderrama, P., Bischof, M., Nedir, R., Jones, A., Simpson, J., Toutenburg, H. & Cochran, D.L. (2007) Enhanced implant stability with a chemically modified SLA surface: a randomized pilot study. *The International Journal of Oral & Maxillofacial Implants* **22**: 755–760.
- Pjetursson, B.E., Karoussis, I., Burgin, W., Bragger, U. & Lang, N.P. (2005) Patients' satisfaction following implant therapy. A 10-year prospective cohort study. *Clinical Oral Implants Research* **16**: 185–193.
- Raghoobar, G.M., Slater, J.J., Hartog, L., Meijer, H.J. & Vissink, A. (2009) Comparison of procedures for immediate reconstruction of large osseous defects resulting from removal of a single tooth to prepare for insertion of an endosseous implant after healing. *International Journal of Oral and Maxillofacial Surgery* **38**: 736–743.
- Roccuzzo, M. & Wilson, T.G. Jr (2009) A prospective study of 3 weeks' loading of chemically modified titanium implants in the maxillary molar region: 1-year results. *The International Journal of Oral & Maxillofacial Implants* **24**: 65–72.
- Romeo, E., Lops, D., Rossi, A., Storelli, S., Rozza, R. & Chiapasco, M. (2008) Surgical and prosthetic management of interproximal region with single-implant restorations: 1-year prospective study. *Journal of Periodontology* **79**: 1048–1055.
- Rupp, F., Scheideler, L., Olshanska, N., de Wild, M., Wieland, M. & Geis-Gerstorfer, J. (2006) Enhancing surface free energy and hydrophilicity through chemical modification of microstructured titanium implant surfaces. *Journal of Biomedical Materials Research. Part A* **76**: 323–334.
- Schatzle, M., Mannchen, R., Zwahlen, M. & Lang, N.P. (2009) Survival and failure rates of orthodontic temporary anchorage devices: a systematic review. *Clinical Oral Implants Research* **20**: 1351–1359.
- Schropp, L., Isidor, F., Kostopoulos, L. & Wenzel, A. (2004) Patient experience of, and satisfaction with, delayed-immediate vs. delayed single-tooth implant placement. *Clinical Oral Implants Research* **15**: 498–503.
- Smeets, E.C., de Jong, K.J. & Abraham-Inpijn, L. (1998) Detecting the medically compromised patient in dentistry by means of the medical risk-related history. A survey of 29,424 dental patients in the Netherlands. *Preventive Medicine* **27**: 530–535.
- Tarnow, D., Elian, N., Fletcher, P., Froum, S., Magner, A., Cho, S.C., Salama, M., Salama, H. & Garber, D.A. (2003) Vertical distance from the crest of bone to the height of the interproximal papilla between adjacent implants. *Journal of Periodontology* **74**: 1785–1788.