

University of Groningen

Multicenter Evaluation of the Course of Coagulopathy in Patients with Isolated Traumatic Brain Injury

Franschman, Gaby; Boer, Christa; Andriessen, Teuntje M. J. C.; van der Naalt, Joukje; Horn, Janneke; Haitsma, Iain; Jacobs, Bram; Vos, Pieter E.

Published in:
Journal of Neurotrauma

DOI:
[10.1089/neu.2011.2044](https://doi.org/10.1089/neu.2011.2044)

IMPORTANT NOTE: You are advised to consult the publisher's version (publisher's PDF) if you wish to cite from it. Please check the document version below.

Document Version
Publisher's PDF, also known as Version of record

Publication date:
2012

[Link to publication in University of Groningen/UMCG research database](#)

Citation for published version (APA):

Franschman, G., Boer, C., Andriessen, T. M. J. C., van der Naalt, J., Horn, J., Haitsma, I., Jacobs, B., & Vos, P. E. (2012). Multicenter Evaluation of the Course of Coagulopathy in Patients with Isolated Traumatic Brain Injury: Relation to CT Characteristics and Outcome. *Journal of Neurotrauma*, 29(1), 128-136. <https://doi.org/10.1089/neu.2011.2044>

Copyright

Other than for strictly personal use, it is not permitted to download or to forward/distribute the text or part of it without the consent of the author(s) and/or copyright holder(s), unless the work is under an open content license (like Creative Commons).

The publication may also be distributed here under the terms of Article 25fa of the Dutch Copyright Act, indicated by the "Taverne" license. More information can be found on the University of Groningen website: <https://www.rug.nl/library/open-access/self-archiving-pure/taverne-amendment>.

Take-down policy

If you believe that this document breaches copyright please contact us providing details, and we will remove access to the work immediately and investigate your claim.

Downloaded from the University of Groningen/UMCG research database (Pure): <http://www.rug.nl/research/portal>. For technical reasons the number of authors shown on this cover page is limited to 10 maximum.

Multicenter Evaluation of the Course of Coagulopathy in Patients with Isolated Traumatic Brain Injury: Relation to CT Characteristics and Outcome

Gaby Franschman,¹ Christa Boer,¹ Teuntje M.J.C. Andriessen,² Joukje van der Naalt,³ Janneke Horn,⁴ Iain Haitsma,⁵ Bram Jacobs,³ and Pieter E. Vos²

Abstract

This prospective multicenter study investigated the association of the course of coagulation abnormalities with initial computed tomography (CT) characteristics and outcome in patients with isolated traumatic brain injury (TBI). Patient demographics, coagulation parameters, CT characteristics, and outcome data of moderate and severe TBI patients without major extracranial injuries were prospectively collected. Coagulopathy was defined as absent, early but temporary, delayed, or early and sustained. Delayed/sustained coagulopathy was associated with a higher incidence of disturbed pupillary responses (40% versus 27%; $p < 0.001$) and higher Traumatic Coma Data Bank (TCDB) CT classification (5 (2–5) versus 2 (1–5); $p = 0.003$) than in patients without or with early, but short-lasting coagulopathy. The initial CT of patients with delayed/sustained coagulopathy more frequently showed intracranial hemorrhage and signs of raised intracranial pressure (ICP) compared to patients with early coagulopathy only. This was paralleled by higher in-hospital mortality rates (51% versus 33%; $p < 0.05$), and poorer 6-month functional outcome in patients with delayed/sustained coagulopathy. The relative risk for in-hospital mortality was particularly related to disturbed pupillary responses (OR 8.19; 95% CI 3.15,21.32; $p < 0.001$), early, short-lasting coagulopathy (OR 6.70; 95% CI 1.74,25.78; $p = 0.006$), or delayed/sustained coagulopathy (OR 5.25; 95% CI 2.06,13.40; $p = 0.001$). Delayed/sustained coagulopathy is more frequently associated with CT abnormalities and unfavorable outcome at 6 months after TBI than early, short-lasting coagulopathy. Our finding that not only the mere presence but also the time course of coagulopathy holds predictive value for patient outcome underlines the importance of systematic hemostatic monitoring over time in TBI.

Key words: coagulation disorders; CT characteristics; hemostatic monitoring; neurotrauma; patient outcome

Introduction

BRAIN TISSUE INJURY is associated with the release of cerebral tissue factor and alterations in the thrombomodulin-protein C pathway, both contributing to a disparity in clot formation and lysis (Cohen et al., 2007; Drake et al., 1989; Goodnight et al., 1974; Morel et al., 2008). The consequent development of coagulation disturbances in patients with traumatic brain injury (TBI) is frequently independent of the presence of extracranial bleeding (Zehtabchi et al., 2008). The incidence of early coagulopathy as a complication of TBI in patients without extracranial injuries is estimated at 20–35%,

and is strongly associated with unfavorable outcome (Greuters et al., 2011; Harhangi et al., 2008; Wafaisade et al., 2010). Moreover, several studies have shown that the number of patients with isolated TBI-associated coagulopathy increased in the days following trauma, further contributing to TBI-related mortality (Carrick et al., 2005; Greuters et al., 2011).

Although TBI-related coagulopathy is an independent predictor for unfavorable outcome (Greuters et al., 2011), it is not included as a prognostic indicator for severe TBI in the evidence-based guidelines of the Brain Trauma Foundation (BTF; Chesnut et al., 2000), and recently developed prognostic models (Perel et al., 2008; Steyerberg et al., 2008). This is partly

¹Department of Anesthesiology, Institute for Cardiovascular Research, VU University Medical Center, Amsterdam, the Netherlands.

²Department of Neurology, Radboud University Nijmegen Medical Center, Nijmegen, the Netherlands.

³Department of Neurology, University Medical Center Groningen, Groningen, the Netherlands.

⁴Department of Intensive Care, Academic Medical Center, Amsterdam, the Netherlands.

⁵Department of Neurosurgery, Erasmus MC, Rotterdam, the Netherlands.

due to the limited number of prospective studies focusing on coagulopathy in isolated TBI. Although coagulation parameters have been proposed as possible predictors of outcome, they did not contribute to an improved prognostic value when added to a multifactorial model (van Beek et al., 2007). Moreover, a large number of investigations only focused on signs of hemostatic disorders upon emergency department (ED) admission (Bullock et al., 1996; Harhangi et al., 2008). As a consequence, data describing the relation of clinical indicators for the severity of TBI and the development of coagulopathy after TBI is limited.

Evidence-based predictors for outcome in patients with TBI include age, the initial Glasgow Coma Scale (GCS) score, disturbances in pupillary responses, and computed tomography (CT) abnormalities (Chesnut et al., 2000; Maas et al., 2007; Marshall et al., 1992). CT imaging of the brain is the current radiological investigation of choice to detect acute intracranial abnormalities related to head injury. During the last decade, distinct cranial CT characteristics predictive for outcome in TBI patients have been identified, including the Traumatic Coma Data Bank (TCDB) CT classification, and the presence of intraparenchymal contusions, midline shift, or subarachnoid hemorrhage (Jacobs et al., 2011; Marshall et al., 1992; Wardlaw et al., 2002; Vos et al., 2001). The association between intracranial pathology and the development of coagulopathy is, however, unclear. We therefore investigated whether the initial presence of specific CT characteristics, such as intracerebral hemorrhage and signs of raised intracranial pressure (ICP), are associated with the development of coagulopathy in the first 48 h after trauma. This was addressed by investigating the incidence and course of coagulopathy in a prospective, multicenter cohort of patients with isolated TBI, and by exploring the relation of the development of TBI-associated coagulopathy with initial CT characteristics and outcome.

Methods

Study population

The Prospective Observational COhort study Neurotrauma (POCON) study is a multicenter study executed in the Netherlands. The POCOD database includes prospective data for moderate (GCS score 9–13) and severe (GCS score 3–8) TBI patients admitted between June 1, 2008 and May 31, 2009 to the emergency department (ED) of one of the following ACS-COT level I trauma centers: Radboud University Nijmegen Medical Center (RUNMC), University Medical Center Groningen, VU University Medical Center, Academic Medical Center, and Erasmus Medical Center. Patients were eligible for study inclusion in case of TBI and an ED admission GCS score ≤ 13 . For the present study, a selection was made of patients with isolated TBI, defined as head CT scan-confirmed brain tissue injury without other major extracranial injuries, like pelvis or femur fractures, or severe abdominal or thoracic invasive injuries, as indicated by an extracranial Abbreviated Injury Scale (AIS) < 3 . Exclusion criteria were an extracranial AIS score ≥ 3 , age < 16 years, use of coumarin, liver failure, or missing coagulation parameters upon ED admission.

The prehospital trauma care system is uniform for all regions in the Netherlands. Ambulance paramedics are educated in advanced basic life support, including intravenous access, and oxygen therapy through facemask or bag-valve ventilation. Dutch ambulance paramedics are not allowed to

perform endotracheal intubation in case of a GCS score of 4 or more. Additionally, four centrally divided helicopter-based emergency medical services staffed by anesthesiologists or trauma surgeons are dispatched to support ambulance paramedics in severely-injured patients.

Protocol approval and patient consent

The local ethics committee of the coordinating hospital (RUNMC) approved the study protocol. The other participating hospitals all provided a feasibility statement. After discharge, surviving patients or their proxy received a study information letter inviting patients to contact their local physician or the study coordinator if they had any objections against being contacted for follow-up. For follow-up through telephone interview, verbal informed consent was obtained, and in case of outcome assessment through postal questionnaires, written informed consent was gained.

Demographic and injury severity variables

Demographic and clinical variables, complications, and treatment modalities were collected from medical records by trained research staff affiliated with the trauma centers. The data were checked for completeness by the study coordinator and were entered into a Microsoft Access[®] database available as a stand-alone at each individual study center. Demographic and injury severity variables included age, gender, Injury Severity Score (ISS), AIS head, extracranial AIS, TCDB classification, placement of an ICP catheter, the GCS score at the scene of the accident and upon ED admission, pupil responses defined as both responding versus 1 or both not responding or dilated, and day-of-injury alcohol intoxication. TBI severity was categorized as moderate (GCS 9–13) or severe (GCS 3–8).

CT classification

CT imaging of the head was performed upon ED admission and scans were assessed by three raters (M.J.C.T.A., B.J., and P.E.V.) using a standardized data sheet as previously described (Jacobs et al., 2011). Head CT scans were assessed for the presence of epidural (EDH), subdural hemorrhage (SDH), subarachnoid, and intraventricular hemorrhage, and the presence of parenchymal/hemorrhagic contusion. Volumes of EDH, SDH, and parenchymal/hemorrhagic contusions were measured and dichotomized into lesions with a volume < 25 mL or ≥ 25 mL, in line with the TCDB CT classification (Marshall et al., 1990). In addition, status of the ambient cisterns and the presence of midline shift were assessed. CT characteristics were further classified as signs of cerebral hemorrhage (all signs of intracranial bleeding), signs of increased ICP (compression of the ambient cisterns and/or midline shift), and signs of tissue contusion (parenchymal or hemorrhagic contusion.) The TCDB CT classification includes six categories ranging from I (no visible injury) to VI (non-surgical evacuated intracranial mass lesions ≥ 25 mL; Marshall et al., 1990,1992).

Coagulation parameters

For this study we registered lactate in mmol/L, blood pH, hemoglobin in mmol/L, activated partial thromboplastin time (aPTT), prothrombin time (PT), the International Normalized Ratio (INR) of the PT, and platelet count upon ED admission and in the first 48 h after trauma. Coagulopathy

was defined as an aPTT > 40 sec and/or a PT in INR > 1.2, and/or a platelet count < 120×10^9 per liter. For the PT, the reference values of the distinct level I trauma centers were used. Patients were divided into four groups: (1) patients without coagulopathy (no coagulopathy); (2) patients with early coagulation disturbances upon ED arrival that were normalized in the hours following ED admission (early coagulopathy); (3) patients without early coagulopathy who developed hemostatic abnormalities after ED admission (delayed coagulopathy); and (4) patients with early coagulation disturbances that did not normalize within 48 h following trauma (early + sustained coagulopathy).

Outcome parameters

Outcome parameters included need for transfusion of red blood cells, fresh frozen plasma or platelets, length of ICU stay, length of hospital stay, hospital mortality, and the 6-month Glasgow Outcome Scale Extended (GOSE). The GOSE is a standardized questionnaire to assess the functional status of the patient and consists of an 8-point scale ranging from 1 (death) to 8 (full recovery; Wilson et al., 1998).

Statistical analysis

Data were collected and analyzed using IBM SPSS Statistics 17.0 (IBM, New York, NY). Descriptive statistics included mean, standard deviation, and median with interquartile range (ISS, TCDB, and GCS). Data were analyzed by a one-

way analysis of variance (ANOVA) (parametric data), a Kruskal-Wallis test for three-group comparisons (ordinal data), or a chi-square test (nominal data). Multinomial logistic regression was used to investigate the relation between age, TCDB CT classification, pupillary response, TBI category (moderate or severe injury) scored at the accident scene, and either early, short-term coagulopathy or delayed or sustained coagulopathy within 48 h after the incident with in-hospital mortality. The Nagelkerke R^2 was used to determine the explained variation in outcome. For all analyses, $p < 0.05$ was considered statistically significant.

Results

Clinical characteristics of patients with TBI-related coagulopathy

The POC database ($n = 508$) included 296 patients with isolated TBI. Seventy-eight cases were excluded due to incomplete coagulation data in the first 48 h after trauma ($n = 218$). The overall incidence of early coagulopathy was 34%. Figure 1 represents the aPTT (panel A), platelet count (panel B), INR (panel C), and PT (panel D), in 218 patients with complete coagulation data. In this population, 41% had no coagulopathy, 10% showed early but transient coagulation abnormalities, 20% developed delayed coagulopathy, and 29% revealed early and sustained coagulation disturbances. A marked number of patients developed coagulopathy in the hours after ED admission, which was characterized by an

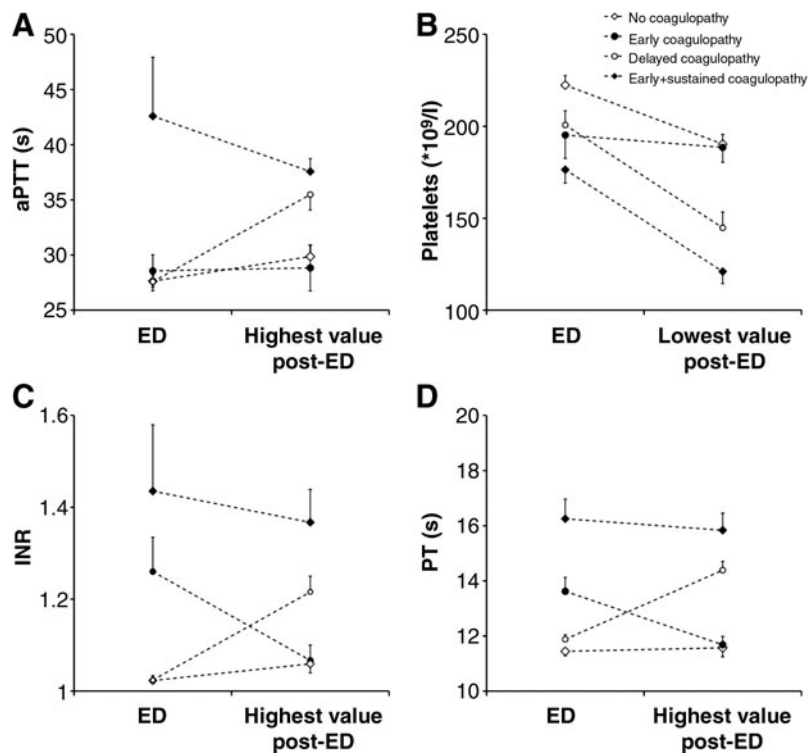


FIG. 1. Values for the activated partial thromboplastin time (aPTT; **A**), platelets (**B**), International Normalized Ratio (INR; **C**), and prothrombin time (PT; **D**) upon emergency department (ED) admission, and the highest or lowest value in 48 h post-trauma. Patients were divided into four categories: patients without coagulopathy (no coagulopathy; open squares), patients with early coagulopathy only (early coagulopathy; closed circles), patients who developed delayed coagulopathy without signs of early hemostatic disturbances (delayed coagulopathy; open circles), and subjects with early and sustained coagulopathy (closed squares). Values represent mean \pm standard error of the mean.

TABLE 1. DEMOGRAPHICS OF PATIENTS WITHOUT COAGULOPATHY, WITH EARLY SHORT-LASTING COAGULATION DISTURBANCES OR WITH DELAYED OR SUSTAINED COAGULOPATHY

	No coagulopathy	Early short-lasting coagulopathy	Delayed or sustained coagulopathy	p Value
n	85	34	99	
Males (n)	52 (61%)	21 (62%)	66 (67%)	n.s.
Age (y)	48±21	54±25	52±21	n.s.
ISS (median)	17 (10–23)	17 (10–25)	25 (16–26)	< 0.001
AIS head (median)	4 (3–4)	4 (3–5)	5 (4–5)	< 0.001
GCS accident scene (median)	7 (3–10)	7 (4–11)	6 (3–9)	n.s.
GCS ED admission (median)	7 (3–12)	3 (3–10)	3 (3–8)	< 0.001
TCDB CT classification	1 (1–2)	2 (1–5)	5 (2–5)	0.003
Disturbed pupil response	16%	27%	40%	< 0.001
Hemoglobin at ED (mmol/L)	8.4±0.8	7.6±1.5	7.7±1.2	< 0.001
Lactate at ED (mmol/L)	2.7±2.3	2.6±2.0	2.4±2.0	n.s.
pH at ED	7.34±0.10	7.33±0.08	7.33±0.10	n.s.
Alcohol	42%	12%	26%	0.02

Values represent mean±standard deviation, frequencies or median with interquartile range. Data were analyzed by analysis of variance, Kruskal-Wallis, or chi-square testing. Multi-group comparison *p* values are shown in the table.

ISS, Injury Severity Score; TCDB, Traumatic Coma Data Bank; GCS, Glasgow Coma Scale; AIS, Abbreviated Injury Scale; ED, emergency department; CT, computed tomography; n.s., not significant.

increase in aPTT, INR, and PT and a decrease in platelet count when compared to ED values.

Table 1 represents the demographic characteristics of patients with isolated TBI without coagulopathy, with early short-lasting coagulopathy, or with delayed or sustained coagulopathy. There was no difference in gender, age, and pH among groups. Patients with delayed or sustained coagulopathy had higher median AIS head values (5 [4–5]) than patients with early (4 [3–5]) or no (4 [3–4]) coagulopathy ($p < 0.001$). The median GCS score at the accident scene was similar between groups, whereas the median GCS score upon hospital admission was lower in patients with delayed or sustained coagulopathy (3 [3–8]) or early coagulopathy (3 [3–10]) compared to patients without coagulopathy (7 [3–12]; $p < 0.001$). The median TCDB CT classification was higher in patients with delayed or sustained coagulopathy (5 [2–5]) compared to subjects with early (2 [1–5]) or no coagulopathy (1 [1–2]). Disturbed pupillary responses were more frequent in patients with coagulopathy. In addition, coagulopathy was associated with slightly lower hemoglobin levels upon ED admission, but these differences were of no clinical relevance. Patients without coagulopathy more frequently used alcohol on the day of injury.

Cranial CT characteristics in early and delayed coagulopathy

The presence of individual cranial CT characteristics in the patient subgroups is depicted in Figure 2 ($n = 205$). Interestingly, the CT scans of patients with delayed coagulopathy more frequently revealed SDH, SAH, and lesion volumes of ≥ 25 mL (panels B, C, and E), compared to patients without and with short-lasting coagulopathy. The relative numbers of EDH and intraventricular hemorrhage were similar among groups (panels A and D). Cranial CT imaging revealed more patients with contusions (panel F), compressed ambient cisterns (panel G), and a midline shift (panel H), in patients with delayed/sustained coagulopathy. An ICP catheter was placed in 37% of patients with

TBI-related early coagulopathy compared to 14% of patients without coagulopathy ($p < 0.001$). Table 2 represents the frequency analysis of signs for cerebral hemorrhage, parenchymal/hemorrhagic tissue contusion or compression, or increased ICP in patients without or with delayed/sustained coagulopathy. The incidence of delayed/sustained coagulopathy was the highest in patients with signs of increased ICP.

Delayed and sustained coagulopathy and outcome

Table 3 represents outcome data for patients without coagulopathy, with early short-lasting coagulopathy, and with delayed or sustained coagulopathy ($n = 205$). Patients with delayed or sustained coagulopathy more frequently required blood product transfusion and had a longer ICU and length of hospital stay than patients without coagulopathy or with early coagulopathy. In-hospital mortality was higher in patients with delayed or sustained coagulopathy compared to subjects without coagulopathy or patients with early coagulopathy only. Long-term functional outcome at 6 months after trauma as measured by the GOSE showed a favorable outcome profile in patients without hemostatic disorders (Table 3).

Multinomial regression analysis for in-hospital death included the parameters age, TCDB classification, early coagulation disturbances that were normalized after ED admission, delayed or sustained coagulopathy, pupillary responses, and GCS score category at the scene of the accident ($n = 205$). The odds ratio (OR) for TBI category was not significant. The relative risk for mortality was highest in patients with a disturbed pupillary response (OR 8.2; 95% CI 3.2,21.3; $p < 0.001$), and in patients with early short-lasting coagulopathy (OR 6.7; 95% CI 1.7,25.8; $p = 0.006$), or delayed or sustained coagulopathy (OR 5.3; 95% CI 2.1,13.4; $p = 0.001$). The OR for age and a higher TCDB score estimated 1.1 (95% CI 1.0,1.1; $p < 0.001$) and 1.7 (95% CI 1.3,2.2; $p < 0.001$), respectively. The Nagelkerke R^2 for the model was 0.58, with a reported likelihood ratio χ^2 of 113.0 ($p < 0.001$).

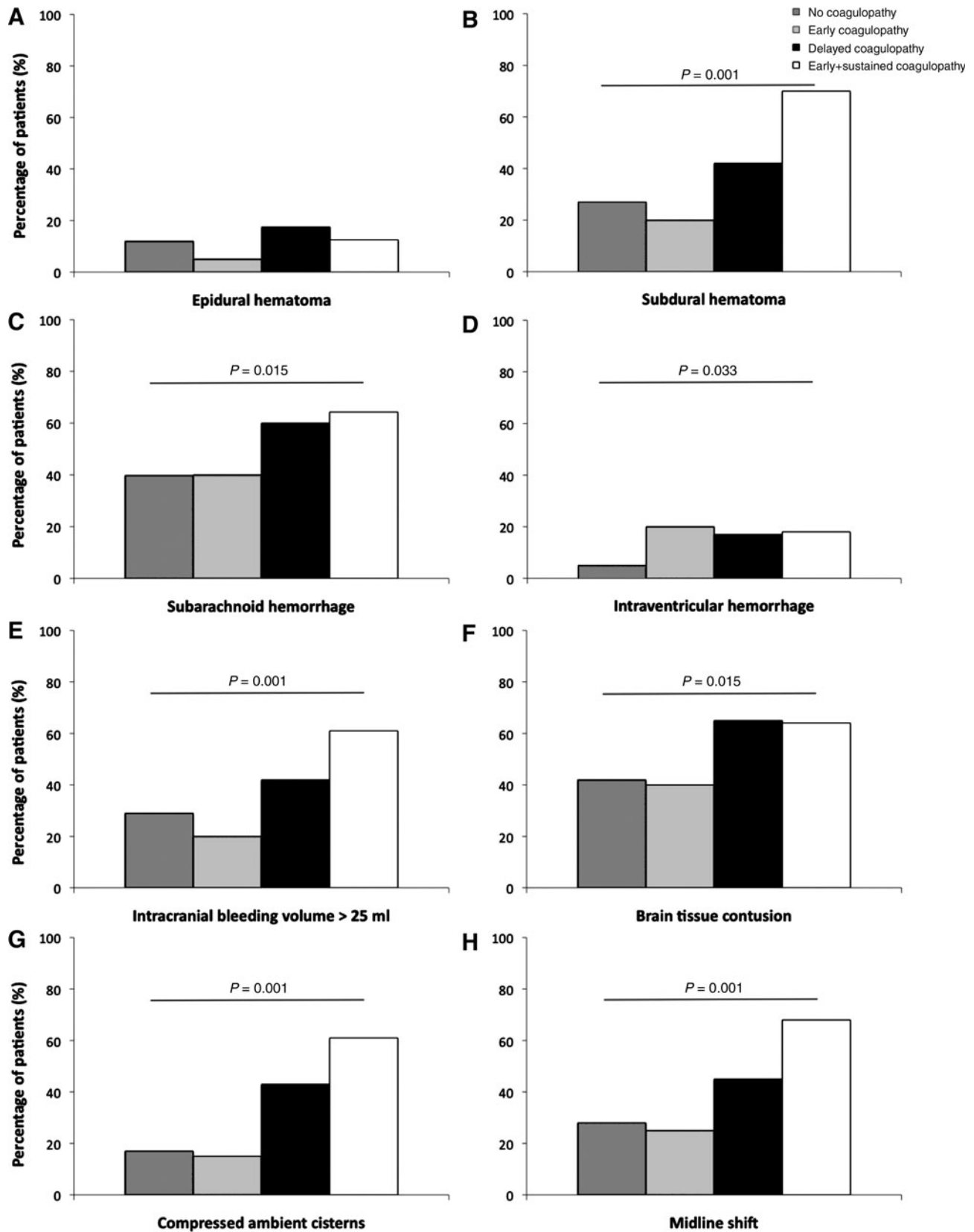


FIG. 2. Cranial computed tomography (CT) findings for patients with or without traumatic brain injury (TBI)-associated coagulation disorders. Panels represent the presence of epidural hematoma (A), subdural hematoma (B), subarachnoid hemorrhage (C), intraventricular hemorrhage (D), an intracranial bleeding volume > 25 mL (E), brain tissue contusion (F), compressed ambient cisterns (G), and a midline shift (H). Values represent the relative number of patients for each subgroup. Data were analyzed by chi-square analysis.

TABLE 2. FREQUENCY ANALYSIS FOR SIGNS OF CEREBRAL HEMORRHAGE, TISSUE CONTUSION, OR TISSUE COMPRESSION IN PATIENTS WITH OR WITHOUT DELAYED/SUSTAINED COAGULOPATHY IN ISOLATED TRAUMATIC BRAIN INJURY

	No coagulopathy	Delayed/sustained coagulopathy	X ²
Cerebral hemorrhage	49 (38%)	80 (62%)	13.05*
Tissue contusion	35 (36%)	62 (64%)	9.00*
Increased intracranial pressure	26 (29%)	64 (71%)	22.24*

* $p < 0.01$.

Value represent frequencies. Data were analyzed by chi-square testing.

Discussion

This prospective, multicenter study showed that a large proportion of patients with isolated TBI developed hemostatic disturbances, and confirmed an estimated incidence rate of TBI-related early coagulopathy of 20–35%, as reported by others (Greuters et al., 2011; Harhangi et al., 2008; Wafaisade et al., 2010). In addition, an equal proportion of patients developed late-onset coagulopathy within the first 48 h after trauma. The relative risk for in-hospital mortality was comparable for patients with early short-lasting coagulopathy and delayed/sustained coagulopathy. However, patients with delayed or sustained coagulopathy more frequently showed intracranial hemorrhage and signs of increased ICP. This was paralleled by a higher risk for blood transfusion and a prolonged ICU and hospital stay. Six months after trauma, patients without coagulopathy or early short-lasting coagulopathy showed better functional outcomes compared with patients with delayed/sustained coagulopathy. The predictive value of coagulopathy for unfavorable outcome was stronger than the TCDB CT classification.

Although we and others show that the occurrence of coagulopathy in the first 48 h after trauma is independently and strongly associated with unfavorable outcome in TBI (Carrick et al., 2005; Greuters et al., 2011; Harhangi et al., 2008; Wafaisade et al., 2010; Zehtabchi et al., 2008;), it is not identified as an independent risk factor for survival (Chesnut et al., 2000; Perel et al., 2008; Steyerberg et al., 2008). Our study further

provides additional information with respect to the course of coagulopathy and its relation to initial CT findings in these patients. Early, but short-lasting coagulopathy was associated with a similar relative risk for in-hospital mortality compared to delayed or sustained coagulopathy, but lacks an association with intracranial pathology and long-term outcome. This disparity between early transient signs of coagulation disturbances and delayed/sustained coagulopathy may be related to distinct pathophysiological mechanisms. The initiation of a cascade of intracerebral and systemic processes and the pathophysiology underlying coagulopathy in isolated TBI is, however, complex and multifactorial (Brohi et al., 2008). The initiation of the procoagulant cascade primarily lies in the excessive release of tissue factor due to the brain injury itself. Tissue factor is initially highly expressed by the cortical parenchyma of the brain, but may subsequently induce systemic activation of the coagulation pathway (Drake et al., 1989; Goodnight et al., 1974). This may result in the development of cerebral microthrombi, disseminated intravascular coagulation, and consumption coagulopathy (Goodnight et al., 1974; Hulka et al., 1996; Morel et al., 2008). Others proposed that mechanisms secondary to brain injury, such as cerebral hypoperfusion caused by systemic hypotension, lead to activation of the anticoagulant protein C pathway, and a rise in plasma thrombomodulin levels (Cohen et al., 2007). Moreover, overt hyperfibrinolysis due to systemic hypoperfusion may increase the risk for delayed or secondary bleeding (Brohi et al., 2008). Additionally, excessive fluid

TABLE 3. OUTCOME PARAMETERS IN PATIENTS WITHOUT COAGULOPATHY, WITH SHORT-LASTING EARLY COAGULOPATHY, AND PATIENTS WITH DELAYED OR SUSTAINED COAGULOPATHY

	No coagulopathy	Early short-lasting coagulopathy	Delayed or sustained coagulopathy
Need for transfusion	13%	10%	41%*,#
ICU stay (days)	4 ± 6	4 ± 4	8 ± 10*
Length of hospital stay (days)	10 ± 14	6 ± 5	18 ± 23*,#
In-hospital mortality (n)	12 (14%)	7 (33%)	51 (52%)*,#
6-month GOSE (n; $p < 0.01$)	69	17	94
Died	12 (17%)	7 (41%)	51 (54%)
Vegetative state	0 (0%)	0 (0%)	0 (0%)
Lower severe disability	2 (3%)	1 (6%)	10 (11%)
Upper severe disability	6 (9%)	0 (0%)	4 (4%)
Lower moderate disability	8 (12%)	2 (12%)	8 (9%)
Upper moderate disability	8 (12%)	2 (12%)	8 (9%)
Good recovery	16 (23%)	1 (6%)	6 (6%)
Restless recovery	17 (24%)	4 (23%)	7 (7%)

* $p < 0.05$ versus no coagulopathy; # $p < 0.05$ versus early coagulopathy.

Values represent mean ± standard deviation, frequencies, or median with interquartile range. GOSE, Glasgow Outcome Scale Extended; ICU, intensive care unit.

resuscitation to prevent cerebral hypoperfusion may further contribute to hemodilution with depletion of platelets and clotting factors (Wafaisade et al., 2010). The pathophysiological mechanisms underlying early and transient or delayed/sustained coagulopathy may therefore be based on an imbalance between procoagulant and anticoagulant processes in the cerebral and systemic circulation.

Although we showed that coagulopathy is associated with unfavorable outcome in isolated TBI, it remains unclear whether coagulopathy is a primary cause for patient mortality or is secondary to pathophysiological processes, including cerebral hemorrhage, contusions, or raised ICP. The present study demonstrated that intracranial hemorrhage is less frequently observed in patients with early, transient coagulation disturbances, whereas subarachnoid or intracranial hemorrhage and signs of raised ICP frequently paralleled delayed/sustained coagulopathy. Earlier studies showed that an increase in ICP and consequent cerebral tissue compression and edema was associated with the development of coagulopathy, but these studies did not focus on the time course of coagulation disturbances (Barklin et al., 2009; Fleck et al., 1990; Talving et al., 2009). In an experimental pig model, increased ICP resulted in acute thrombin generation and shortening of the prothrombin time (Barklin et al., 2009).

An explanation for the association between TBI-related cerebral tissue damage and compression may be related to the release of tissue factor from the cortex and adventitial vessel layers into the systemic circulation (Goodnight et al., 1974; Fleck et al., 1990; Barklin et al., 2009). However, since cerebral tissue factor measurements are difficult to perform to confirm this hypothesis, the development of novel indicators for TBI-related coagulopathy is warranted.

Head CT imaging plays an important role in the diagnosis of the injury severity in TBI. In this study we assumed that the TCDB CT classification as an indicator of the level of injury severity is associated with the development of coagulopathy and mortality (Maas et al., 2007; Marshall et al., 1991; Wardlaw et al., 2002). Although we demonstrated that a higher TCDB classification score and coagulopathy are both associated with unfavorable outcome, a specific interaction between CT parameters may be more predictive for mortality (Maas et al., 2005; Marshall et al., 1992). Furthermore, regression analysis revealed that coagulopathy itself is associated with a higher relative risk for mortality than the TCDB CT classification. This might suggest that, in addition to the severity of brain injury, coagulation disorders itself add up to an unfavorable outcome.

Our finding that not only the mere presence but also the time course of coagulopathy holds predictive value for patient outcome, underlines the importance of systematic hemostatic monitoring over time and the need for development of treatment strategies for coagulation abnormalities in TBI patients (Carrick et al., 2005; Lustenberger et al., 2010). However, this requires closer evaluation of diagnostic tools and treatment modalities for hemostatic disturbances other than those that are currently available. In the present study we used the aPTT, INR, PT, and platelet values for the diagnosis and definition of coagulopathy, since rotational thromboelastometry or thromboelastography was not available at the time of data collection. Although these parameters are the most commonly used tests for the detection of hemostatic and thrombotic disturbances, they do not elucidate the mechanisms underlying TBI-related coagulopathy. Mon-

itoring of platelet function, clot formation, and fibrinolysis require additional measurement techniques, such as platelet aggregation analysis, rotation thromboelastometry, or thromboelastography. These novel tests may provide an important and more detailed alternative for the monitoring of changes in hemostatic and thrombotic parameters in TBI (Allard et al., 2009; Levrat et al., 2008; Nekludov et al., 2007; Rugeri et al., 2007). Furthermore, novel diagnostic tools may enhance our insight into the contribution of fibrinogen and platelets to clot formation and fibrinolysis, thereby enhancing our knowledge about the pathophysiological mechanisms underlying the development of coagulopathy in isolated TBI. Moreover, the insufficient evidence for the effectiveness of administration of coagulation factors like heparin, antifibrinolytics, or recombinant factor VII, as treatment for TBI-associated coagulopathy, prohibits the design of an effective therapeutic regimen in these patients (Pahatouridis et al., 2010; Perel et al., 2010).

Our study is limited by the retrospective retrieval and 48-h time frame of hemostatic parameters, which resulted in the exclusion of several cases due to incomplete coagulation parameters. In addition, there were no data available about pre-existing hemostatic abnormalities in our trauma population. Moreover, hemostatic testing differed among participating hospitals, and included both INR and PT as coagulation parameters. We were further unable to study the relation of hemodilution or hypothermia, both well-known influencers of traumatic coagulopathy, as they were not included as study parameters in the present study (Fenger-Eriksen et al., 2009; Maegele et al., 2007). However, despite the associative nature of our findings, the prospective character of our investigation and the focus on early and delayed coagulopathy provided novel insight into the course of coagulopathy and its relation to outcome after brain injury.

In conclusion, the present study shows that patients who develop TBI-related coagulopathy in the absence of extracranial bleeding injury in the days following hospital admission are at greater risk for unfavorable outcome and mortality. Our findings suggest that specific CT parameters, including signs of increased ICP and intracranial hemorrhage, are associated with delayed or sustained coagulopathy in isolated TBI. This underlines the need for continuous monitoring of hemostatic parameters in isolated TBI, as early coagulopathy may resolve and patients without initial hemostatic disorders may develop coagulopathy at a later stage.

Acknowledgments

The POCON study is funded by the Dutch Brain Foundation (Hersenstichting - HSN-07-01). The authors express their gratitude to Dick Drost, Annemiek Coers, Annelou van der Veen, Joshua Field, Vivian de Ruijter, and Heleen Biersteker for their help with data collection. We thank Amon Heijne for his help with development and maintenance of the POCON database.

The POCON study has been funded by the Netherlands Brain Foundation (HSN-07-01).

We thank the Trauma Unit AMC for providing us with emergency department admission data.

Author Disclosure Statement

No competing financial interests exist for any of the authors.

References

- Allard, C.B., Scarpelini, S., Rhind, S.G., Baker, A.J., Shek, P.N., Tien, H., Fernando, M., Tremblay, L., Morrison, L.J., Pinto, R., and Rizoli, S.B. (2009). Abnormal coagulation tests are associated with progression of traumatic intracranial hemorrhage. *J. Trauma* 67, 959–967.
- Barklin, A., Tønnesen, E., Ingerslev, J., Sørensen, B., and Fenger-Eriksen, C. (2009). Coagulopathy during induced severe intracranial hypertension in a porcine donor model. *Anesthesiology* 110, 1287–1292.
- Brohi, K., Cohen, M.J., Ganter, M.T., Schultz, M.J., Levi, M., Mackersie, R.C., and Pittet, J.F. Acute coagulopathy of trauma: hypoperfusion induces systemic anticoagulation and hyperfibrinolysis. *J. Trauma* 64, 1211–1217.
- Bullock, R., Chesnut, R.M., Clifton, G., Ghajar, J., Marion, D.W., Narayan, R.K., Newell, D.W., Pitts, L.H., Rosner, M.J., and Wilberger, J.W. (1996). Guidelines for the management of severe head injury. Brain Trauma Foundation. *Eur. J. Emerg. Med.* 3, 109–127.
- Carrick, M.M., Tyroch, A.H., Youens, C.A., and Handley, T. (2005). Subsequent development of thrombocytopenia and coagulopathy in moderate and severe head injury: support for serial laboratory examination. *J. Trauma* 58, 725–729.
- Chesnut, R.M., Ghajar, J., Maas, A.I., Marion, D.W., Servadei, F., Bufalini, O.M., Teasdale, G.M., Unterberg, A., Van Holst, H., and Walters, B.C (2000). Early indicators of prognosis in severe traumatic brain injury, in: *Guidelines for the Management of Severe Traumatic Brain Injury*, 3rd ed. Brain Trauma Foundation, pps. 155–203.
- Cohen, M.J., Brohi, K., Ganter, M.T., Manley, G.T., Mackersie, R.C., and Pittet, J.F. (2007). Early coagulopathy after traumatic brain injury: the role of hypoperfusion and the protein C pathway. *J. Trauma* 63, 1254–1261.
- Drake, T.A., Morrissey, J.H., and Edgington, T.S. (1989). Selective cellular expression of tissue factor in human tissues. Implications for disorders of hemostasis and thrombosis. *Am. J. Pathol.* 134, 1087–1097.
- Fenger-Eriksen, C., Tonnesen, E., Ingerslev, J., and Sørensen, B. (2009). Mechanisms of hydroxyethyl starch-induced dilutional coagulopathy. *J. Thromb. Haemost.* 7, 1099–1105.
- Fleck, R.A., Rao, L.V., Rapaport, S.I., and Varki, N. (1990). Localization of human tissue factor antigen by immunostaining with monospecific, polyclonal anti-human tissue factor antibody. *Thromb. Res.* 59, 421–437.
- Goodnight, S.H., Kenoyer, G., Rapaport, S.I., Patch, M.J., Lee, J.A., and Kurze, T. (1974). Defibrination after brain-tissue destruction: A serious complication of head injury. *N. Engl. J. Med.* 290, 1043–1047.
- Greuters, S., van den Berg, A., Franschman, G., Viersen, V.A., Beishuizen, A., Peerdeman, S.M., and Boer, C. (2011). ALARM-BLEEDING investigators. Acute and delayed mild coagulopathy are related to outcome in patients with isolated traumatic brain injury. *Crit. Care* 15, R2.
- Harhangi, B.S., Kompanje, E.J., Leebeek, F.W., and Maas, A.I. (2008). Coagulation disorders after traumatic brain injury. *Acta Neurochir. (Wien.)* 150, 165–175.
- Hulka, F., Mullins, R.J., and Frank, E.H. (1996). Blunt brain injury activates the coagulation process. *Arch. Surg.* 131, 923–927.
- Jacobs, B., Beems, T., Stulemeijer, M., van Vugt, A.B., van der Vliet, T.M., Borm, G.F., and Vos, P.E. (2010). Outcome prediction in mild traumatic brain injury: age and clinical variables are stronger predictors than CT abnormalities. *J. Neurotrauma* 27, 655–668.
- Jacobs, B., Beems, T., van der Vliet, T.M., Diaz-Arrastia, R.R., Borm, G.F., and Vos, P.E. (2011). Computed tomography and outcome in moderate and severe traumatic brain injury: hematoma volume and midline shift revisited. *J. Neurotrauma* 28, 203–215.
- Levrat, A., Gros, A., Rugeri, L., Inaba, K., Floccard, B., Negrier, C., and David, J.S. (2008). Evaluation of rotation thrombelastography for the diagnosis of hyperfibrinolysis in trauma patients. *Br. J. Anaesth.* 100, 792–797.
- Lustenberger, T., Talving, P., Kobayashi, L., Inaba, K., Lam, L., Plurad, D., and Demetriades, D. (2010). Time course of coagulopathy in isolated severe traumatic brain injury. *Injury* 41, 924–928.
- Maas, A.I., Hukkelhoven, C.W., Marshall, L.F., and Steyerberg, E.W. (2005). Prediction of outcome in traumatic brain injury with computed tomographic characteristics: a comparison between the computed tomographic classification and combination of computed tomographic predictors. *Neurosurgery* 57, 1173–1182.
- Maas, A.I., Steyerberg, E.W., Butcher, I., Dammers, R., Lu, J., Marmarou, A., Mushkudiani, N.A., McHugh, G.S., and Murray, G.D. (2007). Prognostic value of computerized tomography scan characteristics in traumatic brain injury: results from the IMPACT study. *J. Neurotrauma* 24, 303–314.
- Maegele, M., Lefering, R., Yucel, N., Tjardes, T., Rixen, D., Paf-frath, T., Simanski, C., Neugebauer, E., and Bouillon, B. (2007). AG Polytrauma of the German Trauma Society (DGU). Early coagulopathy in multiple injury: an analysis from the German Trauma Registry on 8724 patients. *Injury* 38, 298–304.
- Marshall, L.F., and Gautille, T. (1990). Large and small “holes” in the brain: reversible or irreversible changes in head injury. *Acta Neurochir. Suppl. (Wien.)* 51, 300–301.
- Marshall, L.F., Marshall, S.B., Klauber, M.R., and Clark, M. (1991). A new classification of head injury based on computerized tomography. *J. Neurosurg.* 75, S14–S20.
- Marshall, L.F., Marshall, S.B., Klauber, M.R., Van Berkum Clark, M., Eisenberg, H., Jane, J.A., Luerssen, T.G., Marmarou, A., and Foulkes, M.A. (1992). The diagnosis of head injury requires a classification based on computed axial tomography. *J. Neurotrauma* 9, S287–S292.
- Morel, N., Morel, O., Petit, L., Hugel, B., Cochard, J.F., Freyssi-net, J.M., Sztark, F., and Dabadie, P. (2008). Generation of procoagulant microparticles in cerebrospinal fluid and peripheral blood after traumatic brain injury. *Trauma* 64, 698–704.
- Nekludov, M., Bellander, B.M., Blombäck, M., and Wallen, H.N. (2007). Platelet dysfunction in patients with severe traumatic brain injury. *J. Neurotrauma* 24, 1699–1706.
- Pahatouridis, D., Alexiou, G.A., Zigouris, A., Mihos, E., Drosos, D., and Voulgaris, S. (2010). Coagulopathy in moderate head injury. The role of early administration of low molecular weight heparin. *Brain Inj.* 24, 1189–1192.
- Perel, P., Arango, M., Clayton, T., Edwards, P., Komolafe, E., Poccock, S., Roberts, I., Shakur, H., and Steyerberg, E., and Yuthakasemsunt, (2008). S. MRC CRASH Trial Collaborators. Predicting outcome after traumatic brain injury: practical prognostic models based on large cohort of international patients. *BMJ* 336, 425–429.
- Perel, P., Roberts, I., Shakur, H., Thinkhamrop, B., Phu-en-pathom, N., and Yuthakasemsunt, S. (2010). Haemostatic drugs for traumatic brain injury. *Cochrane Database Syst. Rev.* 20, CD007877.
- Rugeri, L., Levrat, A., David, J.S., Delecroix, E., Floccard, B., Gros, A., Allaouchiche, B., and Negrier, C. (2007). Diagnosis of

- early coagulation abnormalities in trauma patients by rotation thrombelastography. *J. Thromb. Haemost.* 5, 289–295.
- Steyerberg, E.W., Mushkudiani, N., Perel, P., Butcher, I., Lu, J., McHugh, G.S., Murray, G.D., Marmarou, A., Roberts, I., Habbema, J.D., and Maas, A.I. (2008). Predicting outcome after traumatic brain injury: development and international validation of prognostic scores based on admission characteristics. *PLoS Med.* 5, e165.
- Talving, P., Benfield, R., Hadjizacharia, P., Inaba, K., Chan, L.S., and Demetriades, D. (2009). Coagulopathy in severe traumatic brain injury: a prospective study. *J. Trauma* 66, 55–61.
- Van Beek, J.G., Mushkudiani, N.A., Steyerberg, E.W., Butcher, I., McHugh, G.S., Lu, J., Marmarou, A., Murray, G.D., and Maas, A.I. (2007). Prognostic value of admission laboratory parameters in traumatic brain injury: results from the IMPACT study. *J. Neurotrauma* 24, 315–328.
- Vos, P.E., van Voskuilen, A.C., Beems, T., Krabbe, P.F., and Vogels, O.J. (2001). Evaluation of the traumatic coma data bank computed tomography classification for severe head injury. *J. Neurotrauma* 18, 649–655.
- Wafaisade, A., Lefering, R., Tjardes, T., Wutzler, S., Simanski, C., Paffrath, T., Fischer, P., Bouillon, B., Maegele, M., Trauma Registry of DGU. (21010). Acute coagulopathy in isolated blunt traumatic brain injury. *Neurocrit. Care* 12, 211–219.
- Wardlaw, J.M., Easton, V.J., and Statham, P. (2002). Which CT features help predict outcome after head injury? *J. Neurol. Neurosurg. Psychiatry* 72, 188–192.
- Wilson, J.T., Pettigrew, L.E., and Teasdale, G.M. (1998). Structured interviews for the Glasgow Outcome Scale and the Extended Glasgow Outcome Scale: Guidelines for their use. *J. Neurotrauma* 15, 573–585.
- Zehtabchi, S., Soghoian, S., Liu, Y., Carmody, K., Shah, L., Whittaker, B., and Sinert, R. (2008). The association of coagulopathy and traumatic brain injury in patients with isolated head injury. *Resuscitation* 76, 52–56.

Address correspondence to:

Gaby Franschman, M.D.

Department of Anesthesiology

VU University Medical Center

De Boelelaan 1117

1081 HV Amsterdam, The Netherlands

E-mail: g.franschman@vumc.nl