

University of Groningen

One intra-articular injection of hyaluronan prevents cell death and improves cell metabolism in a model of injured articular cartilage in the rabbit

Jansen, Edwin J. P.; Ernans, Pieter J.; Douw, Conny M.; Guidemond, Nick A.; Van Rhijn, Lodewijk W.; Bulstra, Sjoerd K.; Kuijer, Roell

Published in:
Journal of Orthopaedic Research

IMPORTANT NOTE: You are advised to consult the publisher's version (publisher's PDF) if you wish to cite from it. Please check the document version below.

Document Version
Publisher's PDF, also known as Version of record

Publication date:
2008

[Link to publication in University of Groningen/UMCG research database](#)

Citation for published version (APA):

Jansen, E. J. P., Ernans, P. J., Douw, C. M., Guidemond, N. A., Van Rhijn, L. W., Bulstra, S. K., & Kuijer, R. (2008). One intra-articular injection of hyaluronan prevents cell death and improves cell metabolism in a model of injured articular cartilage in the rabbit. *Journal of Orthopaedic Research*, 26(5), 624-630.

Copyright

Other than for strictly personal use, it is not permitted to download or to forward/distribute the text or part of it without the consent of the author(s) and/or copyright holder(s), unless the work is under an open content license (like Creative Commons).

The publication may also be distributed here under the terms of Article 25fa of the Dutch Copyright Act, indicated by the "Taverne" license. More information can be found on the University of Groningen website: <https://www.rug.nl/library/open-access/self-archiving-pure/taverne-amendment>.

Take-down policy

If you believe that this document breaches copyright please contact us providing details, and we will remove access to the work immediately and investigate your claim.

Downloaded from the University of Groningen/UMCG research database (Pure): <http://www.rug.nl/research/portal>. For technical reasons the number of authors shown on this cover page is limited to 10 maximum.

One Intra-Articular Injection of Hyaluronan Prevents Cell Death and Improves Cell Metabolism in a Model of Injured Articular Cartilage in the Rabbit

Edwin J.P. Jansen,¹ Pieter J. Emans,¹ Conny M. Douw,² Nick A. Guldemon,¹ Lodewijk W. Van Rhijn,¹ Sjoerd K. Bulstra,³ Roel Kuijer⁴

¹Department of Orthopaedic Surgery, University Hospital of Maastricht, Maastricht, The Netherlands

²Department of Orthopaedic Surgery, Jeroen Bosch hospital, 's-Hertogenbosch, The Netherlands

³Department of Orthopaedic Surgery, University Medical Center Groningen, Groningen, The Netherlands

⁴Department of Biomedical Engineering, University Medical Center Groningen, University of Groningen, Groningen, The Netherlands

Received 11 March 2007; accepted 11 October 2007

Published online in Wiley InterScience (www.interscience.wiley.com). DOI 10.1002/jor.20569

ABSTRACT: The purpose of this study was to determine the effect of one intra-articular injection of hyaluronan on chondrocyte death and metabolism in injured cartilage. Twenty-three 6-month-old rabbits received partial-thickness articular cartilage defects created on each medial femoral condyle. In order to examine the effect on articular cartilage surrounding iatrogenic cartilage lesions, which can occur during arthroscopic procedures, Study 1 was performed: in 14 rabbits both knees were immediately rinsed with 0.9% NaCl. Experimental knees were treated with hyaluronan. Six rabbits were sacrificed at 2 days; eight rabbits 3 months postoperatively. Histomorphometric analysis was used for studying cell death in cartilage next to the defect. In order to examine the effect on longer lasting lesions, more reflecting the clinical situation, Study 2 was performed: after 6 months knee joints of nine rabbits were (i) irrigated with 0.9% NaCl, (ii) treated with hyaluronan after irrigation with 0.9% NaCl, or (iii) sham-treated. After 7 days patellas were used to study the chondrocyte metabolism by measuring the [³⁵S]sulfate incorporation. Study 1: Two days postoperatively, in hyaluronan-treated cartilage the percentage of dead cells was 6.7%, which was significantly lower compared to 16.2% in saline-treated cartilage. After 3 months the percentages of dead cells in both groups were statistically similar. Study 2: Hyaluronan treatment resulted in significantly higher [³⁵S]sulfate incorporation compared to knees irrigated with 0.9% NaCl. These results suggest a potential role for hyaluronan in preventing cell death following articular cartilage injury. One injection of hyaluronan improved cartilage metabolism in knees with 6-month-old cartilage defects. © 2008 Orthopaedic Research Society. Published by Wiley Periodicals, Inc. *J Orthop Res* 26:624–630, 2008

Keywords: hyaluronan; cartilage; rabbit; cell death; chondrocyte metabolism

INTRODUCTION

Hyaluronan (HYA) has received a great deal of attention as a potential agent of intervention in osteoarthritis. The results of clinical studies on the effect of HYA are equivocal. Significant improvements in pain, patient global assessment, and functional outcomes with few adverse events were found due to the intra-articular injection of

HYA,^{1,2} while others only found a small effect.^{3,4} HYA is an important contributor to joint homeostasis and is normally present in the joint's synovial fluid in high concentrations.^{5,6} HYA covers cartilage surfaces, is found in high concentrations in the direct vicinity of the chondrocyte, and has been reported to have anti-inflammatory, anabolic, analgesic, and chondroprotective qualities.⁷

During arthroscopic procedures, joint irrigation results in dilution of synovial fluid with diminishing HYA concentrations. As a result, the physical characteristics and protective functions of the synovial fluid deteriorate, possibly leading to a higher vulnerability of the cartilage. In a clinical trial HYA was injected after an arthroscopic knee

Correspondence to: Edwin J.P. Jansen (Telephone: +31-43-3877038; Fax: +31-43-3874893; E-mail: ejpjansen@hotmail.com)

© 2008 Orthopaedic Research Society. Published by Wiley Periodicals, Inc.

joint lavage, which resulted in reduction of pain and joint effusion together with an improvement in daily activities during the first 28 days.⁸ We propose that the mechanism behind these effects is improvement of joint homeostasis which in turn maintains cartilage metabolism through prevention of cell death. We further elaborate this theory. In previous animal experiments we have shown that one injection with high molecular weight HYA restored the metabolism of chondrocytes that was inhibited by the irrigation solution.^{9,10} While these experiments were done in anatomically normal cartilage, in a clinical setting cartilage metabolism is often negatively influenced by cartilage lesions and a disturbed joint homeostasis.¹¹

First, we studied the effect of HYA on chondrocyte death surrounding a freshly prepared partial-thickness articular cartilage lesion as can occur during arthroscopic procedures. Second, the effect of HYA on chondrocyte metabolism in knee joints with a long-existing cartilage lesion was studied, better reflecting the clinical situation, when arthroscopy is first performed weeks to months after the original injury.

METHODS

Animals

The experiments were conducted following the national and European guidelines for animal experiments. The Maastricht University committee for animal experiments approved all experiment protocols. A total of 23 6-month-old female New Zealand white (NZW) rabbits were used. Postoperatively, the rabbits were housed in a cage, after which they were allowed unlimited activity in groups in a stable. They were fed a standard rabbit diet with water ad libitum. During follow-up no joint immobilization was used.

HYA

The HYA in Ostenil (Chemedica, Munich, Germany) has a mean molecular weight of 1.2 MDa. Ostenil was diluted with a solution of 0.9% NaCl to a concentration of 5 mg/mL HYA.¹⁰

Surgical Procedure of Creating Partial-Thickness Articular Cartilage Defects

Preoperatively each rabbit was fasted for 12 h. General anesthesia was induced by intramuscular injection of 35 mg/kg body weight ketamine hydrochloride and 5 mg/kg xylazine and maintained throughout the surgical procedure by administration of 2% halothane and a mixture of oxygen and nitrous oxide delivered through an automatic ventilator using a specially designed mask. Preoperatively, all rabbits received an intramuscular injection of 10 mg/kg body weight

ceftiofur (Pharmacia & Upjohn, Woerden, The Netherlands) to reduce the risk of pre- or postoperative infections. Postoperative pain killing was done by administering 50 µg/kg buprenorphine at 2 h and 1 day. All operations were performed under strictly aseptic conditions. An arthrotomy of the tibia-femoral articulation was performed and the patella was dislocated laterally to expose the medial femoral condyle. A 4 mm diameter skin-biopsy punch (Kai Medical, Solingen, Germany) was used to circumscribe the defect centered on the weight-bearing part of the medial femoral condyle. Noncalcified cartilage was removed from the outlined defect using a scalpel. Special care was taken to prevent penetration of the subchondral bone.

Study Design

The 23 NZW rabbits that had received partial-thickness articular cartilage defects created on each medial femoral condyle, were divided into two groups. Fourteen rabbits were used to study the effect of HYA in preventing cell death peripheral to a partial-thickness articular cartilage defect (Study 1). The remaining nine rabbits were used to study the effect of HYA on cartilage metabolism in joints with long-lasting partial-thickness articular cartilage defects (Study 2).

Study 1: Effect of HYA on Cell Death Peripheral to a Partial-Thickness Articular Cartilage Lesion

Knee joints were rinsed with 0.9% NaCl immediately after creating the cartilage lesion, and subsequently closed in layers. In the experimental knee 1 mL HYA solution was injected (HYA group); the contralateral knee received 1 mL 0.9% NaCl (NaCl group). At 2 days following surgery six animals were sacrificed, and at 3 months follow-up eight animals were sacrificed. Condyles were fixated in a 10% formalin solution over 5 days at 4°C. After decalcification in EDTA, samples were dehydrated in a series of increasing concentrations of ethanol and embedded in 2-hydroxyethyl methacrylate (Technovit 7100; Heraeus Kulzer, Wehrheim, Germany). Sections of 5 µm were cut along the midsagittal plane using a microtome (LKB Multirange Microtome, Stockholm, Sweden), and stained with thionine. All sections were examined blindly to group assignment. A 50 µm region of the articular cartilage adjacent to either side of the defect was examined using 200X and 400X magnification to assess peripheral chondrocyte death and viability. The percentage of cell death was measured as ratio between the number of dead cells and a total of at least 300 cells. Cell death was defined as the presence of a condensed, pyknotic nucleus and either a shrunken or deeply eosinophilic cytoplasm, or fragmentation of the nucleus/cytoplasm, or an empty lacuna.¹²⁻¹⁴ The cell densities were determined in the sections of the 3 months follow-up samples by counting the number of living cells in an area of 50 × 100 µm alongside the defect. The cell density of the lateral condyle present on the same object glass served as a 100% control.

Study 2: Effect of HYA on Chondrocyte Metabolism

Six months after creating the partial-thickness articular cartilage defects, knee joints of nine rabbits were treated again. An injection needle was placed into the knee joints, and (i) were not irrigated (sham group, $n = 6$ knees); or (ii) were irrigated with 10 mL 0.9% NaCl (NaCl group, $n = 6$ knees); or (iii) received 1 mL HYA solution after irrigation with 10 mL 0.9% NaCl (HYA group, $n = 6$ knees). Seven days postoperatively, patellae were harvested to study the total sulfate incorporation rate (in dpm/patella) using a previously described method.^{15,16} In brief, patellae were transferred to tubes containing 1 mL of medium (Dulbecco's Modified Eagle's Medium supplemented with 10% fetal bovine serum [Invitrogen, Breda, The Netherlands], ascorbic acid 2-phosphate [0.2 mM; Sigma-Aldrich Chemie B.V., Zwijndrecht, The Netherlands], penicillin [100 U/mL], streptomycin [100 µg/mL], and amphotericin B [0.25 µg/mL; Invitrogen]). The medium was discarded and to each patella 1 mL medium supplemented with 5.7 µCi/mL Na₂ ³⁵SO₄ (³⁵S)sulfate medium; Amersham Biosciences Benelux, Roosendaal, The Netherlands) was added. The samples were incubated in a humidified CO₂-incubator O/N. The [³⁵S]sulfate medium was removed and patellae were washed 2 × 10 min with 1 mL sterile phosphate-buffered saline. To the patella specimens 0.15 µg/µL proteinase K, 50 mM Tris-HCl (pH 7.9), and 1 mM CaCl₂ were added, and subsequently patellae were left in a shaking water bath at 56°C O/N. After centrifugation at 3,000 × *g* for 5 min, supernatants were supplemented with 25 µL 0.1% cetylpyridinium chloride (CPC; Merck-Europe B.V., Amsterdam, The Netherlands) solution and 25 µL 4 mg/mL proteoglycan solution (A1 fraction, isolated from human articular cartilage). Samples were incubated at 37°C for 1 h to precipitate the glycosaminoglycans, which were then centrifuged at 15,000 × *g* for 5 min. The supernatants were discarded and the pellets were washed once with 100 µL of a solution of 0.1% CPC in 0.2 M NaCl and then dried. Pellets were dissolved in formic acid (Merck-Europe B.V.) at room temperature O/N. A 20 µL aliquot of each sample was mixed with 2 mL Formula 989 scintillation fluid (DuPont, Dordrecht, The Netherlands) and counted in a liquid scintillation counter. The total sulfate incorporation rate of each sample was calculated using the specific activity of the medium.

Statistical Analysis

Differences were tested for significance through non-parametric statistical tests. The Wilcoxon rank sum test for paired-samples was applied in the case of intra-animal comparisons to compare percentages of cell death for each follow-up separately (Study 1), and to evaluate the effect of HYA on chondrocyte metabolism (Study 2). The Mann-Whitney *U*-test for independent samples was applied when comparing the results obtained from different animals to evaluate the statistical difference in the percentage of dead cells between

2 days and 3 months follow-up (Study 1). The Mann-Whitney *U*-test was applied when comparing the cell densities of living cells between the HYA and NaCl groups. All statistical analyses were performed by a statistician (N. G.) using SPSS-pc, version 12.0.1 (SPSS Inc., Chicago). An alpha level of 0.05 was chosen to judge statistical significance.

RESULTS

Study 1: Effect of HYA on Cell Death Peripheral to a Partial-Thickness Articular Cartilage Lesion

In the postoperative period, no limp or swollen knee joints were observed in any of the rabbits. No complications such as infection or patellar luxations occurred.

Macroscopic impressions of HYA- and NaCl-treated knees were similar, with smooth and glossy cartilage that surrounded the defect (Fig. 1). Gross osteoarthritic features, like osteophytes and other joint deformities, were not observed. Lesions were centered on the weight-bearing part of the medial femoral condyle, and were not healed at 2 days or 3 months follow-up.

Histologic analyses confirmed the macroscopic observation that none of the partial-thickness articular cartilage defects were healed at 2 days (Fig. 2) or 3 months (Fig. 3) after surgery. Defects were up to the calcified cartilage without penetrating the subchondral bone (Figs. 2A,C and 3A,C), indicating that true partial-thickness articular cartilage defects were created. Some defects were covered with debris, which never filled the defects completely. Three months postsurgery, the cartilage peripheral to the defects showed degenerative features like surface irregularities, cluster formation, and loss of proteoglycan staining (Fig. 3), irrespective of the applied treatment. Signs of synovial tissue inflammation were absent.

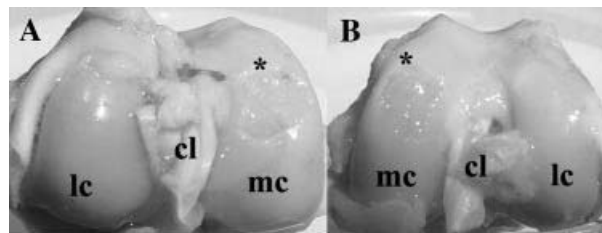


Figure 1. Representative photographs are shown from articular surfaces 2 days after creating partial-thickness articular cartilage defects (*) on rabbit medial femoral condyles. (A) Injected with hyaluronan after irrigation with 0.9% NaCl immediately after creating the defects, or (B) irrigated with 0.9% NaCl. Note that in both hyaluronan- and NaCl-treated knees the surface is smooth and glossy without gross osteoarthritic features. mc, medial femoral condyle; lc, lateral femoral condyle; cl, cruciate ligaments.

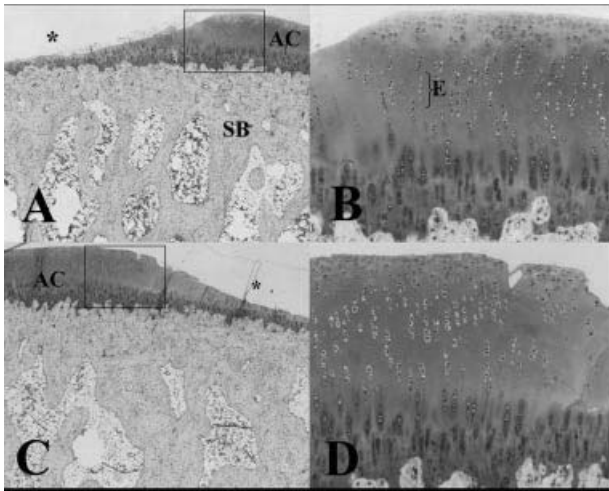


Figure 2. These micrographs represent thionine-stained sections of articular cartilage at the periphery of partial-thickness articular cartilage defects (*) created on rabbit medial femoral condyles that were immediately treated with hyaluronan or 0.9% NaCl solution. Animals were sacrificed 2 days postoperatively. Note defects have not penetrated the subchondral bone. (A) Irrigated with 0.9% NaCl; (B) is an enlargement of the box in (A). (C) Injected with hyaluronan after irrigation with 0.9% NaCl; (D) is an enlargement of the box in (C). Note that more empty lacunae (E) can be detected in the area surrounding the lesion after 0.9% NaCl irrigation only. Original magnifications: (A,C)50X, (B,D)200X. AC, articular cartilage; SB, subchondral bone; E, empty lacunae indicative for dead chondrocytes.

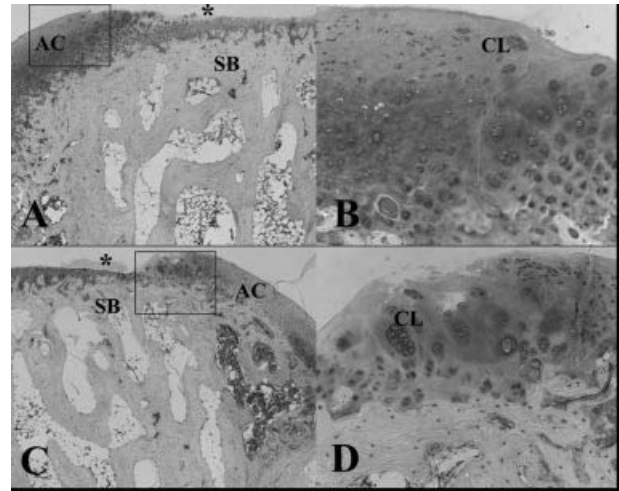


Figure 3. These micrographs represent thionine-stained sections of articular cartilage at the periphery of partial-thickness articular cartilage defects created on rabbit medial femoral condyles that were immediately treated with hyaluronan or 0.9% NaCl solution. Animals were sacrificed 3 months postoperatively. Note that none of the defects was healed. (A) Irrigated with 0.9% NaCl; (B) is an enlargement of the box in (A). (C) Injected with hyaluronan after irrigation with 0.9% NaCl; (D) is an enlargement of the box in (C). Note the similar features concerning cluster (CL) formation and loss of proteoglycan staining in cartilage from hyaluronan- and 0.9% NaCl-treated knees. Original magnifications: (A,C)50X, (B,D)200X. AC, articular cartilage; SB, subchondral bone; CL, cell cluster.

At 200X and 400X magnification we judged whether chondrocytes were alive or dead. Two days after creating a partial-thickness cartilage lesion, the percentage of dead cells in the periphery of the defect in the group treated with HYA was significantly lower ($p = 0.028$) as compared to the NaCl group: 6.7 ± 4.1 versus 16.2 ± 4.6 , respectively (Table 1; Fig. 4). At 3 months follow-up the percentage of dead cells did not differ significantly ($p = 0.327$) between the NaCl and the HYA group: 6.1 ± 4.1 versus 9.5 ± 8.1 , respectively (Table 1; Fig. 4). In the NaCl group the percentage of dead cells was significantly lower after 3 months compared to 2 days after surgery ($p = 0.004$). In HYA-treated knees, the percentage of dead cells remained statistically similar over the course of 3 months ($p = 0.747$).

At 3 months follow-up the cell densities of the cartilage alongside the defects varied from 10–120% of the control, due to either hypocellularity or the presence of cell clusters, respectively. Cell densities of the HYA- and the NaCl-treated cartilage samples did not differ significantly: 53.7% (range, 10–120) compared to 73.3%

Table 1. Number of Living and Dead Cells Counted at the Periphery of Partial-Thickness Articular Cartilage Defects

NaCl-treated knees		Hyaluronan-treated knees	
Living cells	Dead cells	Living cells	Dead cells
2 days postinjury			
300	38	300	4
307	56	300	20
341	52	301	18
317	31	313	12
316	61	315	28
310	69	302	40
3 months postinjury			
328	7	335	6
311	20	323	69
300	4	320	13
316	13	338	15
349	39	327	59
350	12	250	6
351	25	305	54
314	40	303	18

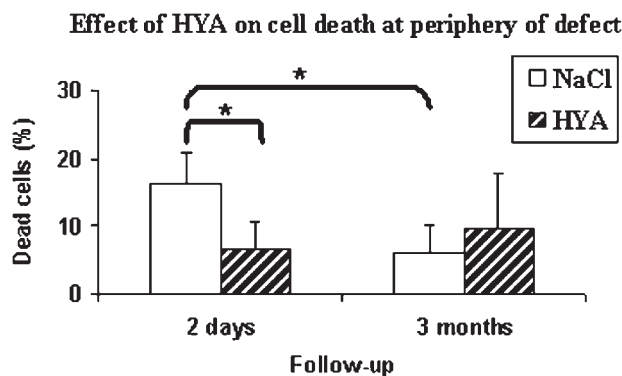


Figure 4. This histogram represents the mean percentages of dead chondrocytes. Partial-thickness articular cartilage defects were created and rinsed with 0.9% NaCl. Experimental knees were immediately injected with hyaluronan; control knees with 0.9% NaCl. Follow-up was 2 days (HYA, $n = 6$ knees; NaCl, $n = 6$ knees) and 3 months (HYA, $n = 8$ knees; NaCl, $n = 8$ knees). Error bars designate means plus standard deviation. $*p < 0.05$; HYA, hyaluronan.

(range, 44–114) for the HYA and NaCl group, respectively.

Study 2: Effect of HYA on Chondrocyte Metabolism

The average incorporated [35 S]sulfate (dpm/patella) in glycosaminoglycans of the HYA-treated group was significantly higher ($p = 0.029$) compared to knee joints that were not treated with HYA after 0.9% NaCl irrigation (NaCl group): 16,751 ($\pm 3,261$) versus 13,503 ($\pm 1,329$) for HYA- and NaCl-treated knees, respectively (Fig. 5). The incorporated [35 S]sulfate in glycosaminoglycans of HYA-treated knees was slightly, but not significantly, higher than in sham-treated knees:

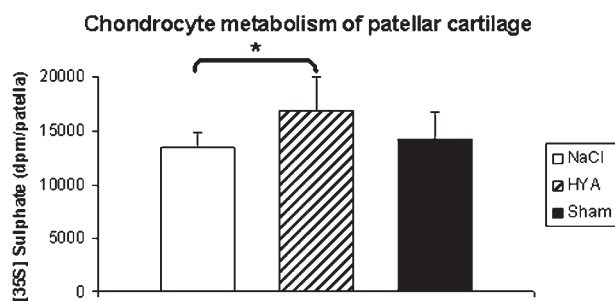


Figure 5. This histogram represents the mean [35 S]sulfate incorporation, expressed in dpm/patella. Knee joints were (i) left untreated, that is, no irrigation, no treatment (Sham, $n = 6$ knees); or after 6 months (ii) irrigated with 0.9% NaCl (NaCl, $n = 6$ knees); or (iii) injected with hyaluronan solution after irrigation with 0.9% NaCl (HYA, $n = 6$ knees). Cartilage metabolism was assessed on the patella ex vivo 7 days after the treatment. Error bars designate means plus standard deviation. $*p < 0.05$; HYA, hyaluronan.

16,751 ($\pm 3,261$) versus 14,283 ($\pm 2,368$) for HYA- and sham-treated knees, respectively.

Irrigation of previously injured rabbit joints with NaCl solution inhibited cartilage metabolism, as was shown by a lower [35 S]sulfate incorporation into the glycosaminoglycans as compared to the sham-treated knees: 13,503 ($\pm 1,329$) versus 14,283 ($\pm 2,368$) for NaCl- and sham-treated knees, respectively. Differences between the NaCl- and sham-treated knees were not statistically significant.

DISCUSSION

This in vivo study shows the effect on chondrocyte death and chondrocyte metabolism after one intra-articular injection of HYA in the injured rabbit knee. It is known from literature that chondrocyte death occurs close to a lesion in response to experimental mechanical compression and cartilage injury.¹⁷ The earliest signs of apoptosis appear around 6 h postinjury and the percentage of apoptotic cells increases up to 7 days after injury.¹⁸ In the present study we evaluated cell death after one intra-articular injection with HYA, which was injected immediately after creating a partial-thickness articular cartilage defect. Treatment with HYA resulted in the protection of chondrocytes peripheral to the cartilage defect, whereas a relatively high percentage of dead cells was observed in untreated knees 2 days after creating the defect. This is in agreement with the findings of Díaz-Gallego et al.,¹⁹ who pointed out that intra-articular treatment with HYA exerts a protective role in cartilage, reducing apoptosis when treatment is started early. These findings support the theory of a therapeutic window during which apoptosis may be inhibited by therapeutic agents,²⁰ in which HYA likely exerts its protective effect by HYA-induced reduction of anti-Fas-induced chondrocyte apoptosis.²¹ It remains unclear as to whether HYA is chondroprotective in the long-term. In the current study the percentage of dead chondrocytes in HYA-treated knees did not increase between 2 days and 13 weeks postoperatively. Unexpectedly, in untreated knees the percentage of dead chondrocytes decreased over the course of 13 weeks, showing comparable percentages of cell death as those seen in the HYA-treated knees. This most likely is due to removal of the dead cells, which will ultimately result in a lower cell density of the cartilage. However, assessment of the cell densities did not provide an answer, due to the high variability between the samples caused by

both hypocellular regions and regions with cell clusters. During the occurring degeneration the empty cell lacunae were removed or masked, resulting in a too low number of dead cells. Our histology was not conclusive at this point. Finding no convincing evidence for a protective role of HYA for the long term corroborates with data of Mendelson et al.²² Weekly HYA injections for 3 weeks, starting at either 1 or 3 weeks following injury, did not provide protection to zones peripheral to partial-thickness articular cartilage lesions at either 2 or 6 months. In the latter study the timing of initiation of the injection differed from our study. This could be an important factor concerning the therapeutic window in which HYA could exert its beneficial effect.

Knee joints having 6-month-old partial-thickness articular cartilage defects were irrigated with NaCl and subsequently treated with one intra-articular HYA injection. Seven days later chondrocyte metabolism was improved in these injured knees as compared to saline-treated controls. We used a previously described model in which cartilage degeneration was induced by well-circumscribed, surgically created partial-thickness articular cartilage defects to reflect the clinical situation more accurately.²³ In order to measure the effect of HYA in knee joints with degenerative changes, cartilage from a primary noninjured part of the knee was used. Using this method, the lesion area was avoided. Analysis of the patella is suggested to reflect the metabolism in a damaged joint more accurately. Chondrocyte metabolism was studied through measuring the [³⁵S]sulfate incorporation into the glycosaminoglycans of whole patellas. This method was found as reliable and has been described by de Vries et al.¹⁵ It has been shown that 98% of the radiolabel is taken up by the cartilage of the patella and only 2% by bone, making it unnecessary to measure these separately. We have shown previously that joint irrigation caused a disturbed chondrocyte metabolism in anatomically healthy knee joints: after NaCl irrigation, chondrocyte metabolism in patellas was inhibited for 7 days after the procedure.²⁴ However, one injection of 5 mg/mL HYA was able to restore the NaCl-disturbed cartilage metabolism completely to normal.¹⁰ The current study showed that also in injured knees HYA can restore the impaired chondrocyte metabolism, caused by the irrigation procedure.

In summary, HYA has a chondroprotective effect on the short-term when applied immediately post-injury, and improves chondrocyte metabolism in

knee joints with long-existing lesions. However, the effect of HYA on the long-term, and the relationship between cell death and cell metabolism remains unclear. Future studies are designed to show a possible relationship between prevention of cell death due to HYA and improved cell metabolism in knee joints with long-existing articular cartilage lesions.

ACKNOWLEDGMENTS

We wish to thank Don Surtel, Martine Hulsbosch, and Mireille Schrooten-van Helden for their laboratory assistance. We thank Joyce Suyk, Monique de Jong, Frans Slangen, and May Bost from the Central Experimental Animal Facility of Maastricht University for their assistance in surgery and animal care. We also thank Els Terwindt-Rouwenhorst and Paul van Dijk from the Department of Anatomy and Embryology for their technical assistance in processing histological samples. This study was supported by a grant from Senter (BTS00021).

REFERENCES

- Bellamy N, Campbell J, Robinson V, et al. 2005. Viscosupplementation for the treatment of osteoarthritis of the knee. *Cochrane Database Syst Rev* CD005321.
- Wang CT, Lin J, Chang CJ, et al. 2004. Therapeutic effects of hyaluronic acid on osteoarthritis of the knee. A meta-analysis of randomized controlled trials. *J Bone Joint Surg Am* 86-A:538–545.
- Lo GH, LaValley M, McAlindon T, et al. 2003. Intra-articular hyaluronic acid in treatment of knee osteoarthritis: a meta-analysis. *JAMA* 290:3115–3121.
- Arrich J, Piribauer F, Mad P, et al. 2005. Intra-articular hyaluronic acid for the treatment of osteoarthritis of the knee: systematic review and meta-analysis. *Cmaj* 172: 1039–1043.
- Laurent TC, Fraser JR. 1992. Hyaluronan. *FASEB J* 6: 2397–2404.
- Balazs EA, Denlinger JL. 1993. Viscosupplementation: a new concept in the treatment of osteoarthritis. *J Rheumatol Suppl* 39:3–9.
- Watterson JR, Esdaile JM. 2000. Viscosupplementation: therapeutic mechanisms and clinical potential in osteoarthritis of the knee. *J Am Acad Orthop Surg* 8:277–284.
- Mathies B. 2006. Effects of Viscosel, a synovial fluid substitute, on recovery after arthroscopic partial meniscectomy and joint lavage. *Knee Surg Sports Traumatol Arthrosc* 14:32–39.
- Bulstra SK, Kuijjer R, Eerdmans P, et al. 1994. The effect in vitro of irrigating solutions on intact rat articular cartilage. *J Bone Joint Surg Br* 76:468–470.
- Bulstra SK, Douw C, Kuijjer R. 1999. NaCl irrigation of the rat knee inhibits cartilage metabolism; hyaluronan restores this disturbed metabolism to normal. In: 45th

- Annual Meeting, Orthopaedic Research Society. Anaheim, CA.
11. Saris DB, Dhert WJ, Verbout AJ. 2003. Joint homeostasis. The discrepancy between old and fresh defects in cartilage repair. *J Bone Joint Surg Br* 85:1067–1076.
 12. Bos PK, DeGroot J, Budde M, et al. 2002. Specific enzymatic treatment of bovine and human articular cartilage: implications for integrative cartilage repair. *Arthritis Rheum* 46:976–985.
 13. Kim HA, Lee YJ, Seong S-C, et al. 2000. Apoptotic Chondrocyte Death in Human Osteoarthritis. *J Rheumatol* 27:455–462.
 14. Bos PK, DeGroot J, Budde M, et al. 2002. Specific enzymatic treatment of bovine and human articular cartilage: Implications for integrative cartilage repair. *Arthritis Rheum* 46:976–985.
 15. de Vries BJ, van den Berg WB, Vitters E, et al. 1986. Quantitation of glycosaminoglycan metabolism in anatomically intact articular cartilage of the mouse patella: in vitro and in vivo studies with ³⁵S-sulfate, ³H-glucosamine, and ³H-acetate. *Rheumatol Int* 6:273–281.
 16. Verschure PJ, Joosten LA, van der Kraan PM, et al. 1994. Responsiveness of articular cartilage from normal and inflamed mouse knee joints to various growth factors. *Ann Rheum Dis* 53:455–460.
 17. Colwell CW Jr, D'Lima DD, Hoenecke HR, et al. 2001. In vivo changes after mechanical injury. *Clin Orthop Relat Res* S116–123.
 18. D'Lima DD, Hashimoto S, Chen PC, et al. 2001. Human chondrocyte apoptosis in response to mechanical injury. *Osteoarth Cart* 9:712–719.
 19. Diaz-Gallego L, Prieto JG, Coronel P, et al. 2005. Apoptosis and nitric oxide in an experimental model of osteoarthritis in rabbit after hyaluronic acid treatment. *J Orthop Res* 23:1370–1376.
 20. D'Lima DD, Hashimoto S, Chen PC, et al. 2001. Prevention of chondrocyte apoptosis. *J Bone Joint Surg Am* 83-(Suppl 2):25–26.
 21. Lisignoli G, Grassi F, Zini N, et al. 2001. Anti-Fas-induced apoptosis in chondrocytes reduced by hyaluronan: evidence for CD44 and CD54 (intercellular adhesion molecule 1) involvement. *Arthritis Rheum* 44:1800–1807.
 22. Mendelson S, Wooley P, Lucas D, et al. 2004. The effect of hyaluronic acid on a rabbit model of full-thickness cartilage repair. *Clin Orthop Relat Res* 266–271.
 23. Lu Y, Markel MD, Swain C, et al. 2006. Development of partial thickness articular cartilage injury in an ovine model. *J Orthop Res* 24:1974–1982.
 24. Bulstra SK, Kuijer R, Eerdmans P, et al. 1994. The effect in vitro of irrigating solutions on intact rat articular cartilage. *J Bone Joint Surg (Br)* 76-B:468–470.