

University of Groningen

Zoning of mucosal phenotype, dysplasia, and telomerase activity measured by telomerase repeat assay protocol in Barrett's esophagus

Going, JJ; Fletcher-Monaghan, AJ; Neilson, L; Wisman, BA; van der Zee, A; Stuart, RC; Keith, WN

Published in:
Neoplasia

IMPORTANT NOTE: You are advised to consult the publisher's version (publisher's PDF) if you wish to cite from it. Please check the document version below.

Document Version
Publisher's PDF, also known as Version of record

Publication date:
2004

[Link to publication in University of Groningen/UMCG research database](#)

Citation for published version (APA):

Going, JJ., Fletcher-Monaghan, AJ., Neilson, L., Wisman, BA., van der Zee, A., Stuart, RC., & Keith, WN. (2004). Zoning of mucosal phenotype, dysplasia, and telomerase activity measured by telomerase repeat assay protocol in Barrett's esophagus. *Neoplasia*, 6(1), 85-92.

Copyright

Other than for strictly personal use, it is not permitted to download or to forward/distribute the text or part of it without the consent of the author(s) and/or copyright holder(s), unless the work is under an open content license (like Creative Commons).

The publication may also be distributed here under the terms of Article 25fa of the Dutch Copyright Act, indicated by the "Taverne" license. More information can be found on the University of Groningen website: <https://www.rug.nl/library/open-access/self-archiving-pure/taverne-amendment>.

Take-down policy

If you believe that this document breaches copyright please contact us providing details, and we will remove access to the work immediately and investigate your claim.

Downloaded from the University of Groningen/UMCG research database (Pure): <http://www.rug.nl/research/portal>. For technical reasons the number of authors shown on this cover page is limited to 10 maximum.

Zoning of Mucosal Phenotype, Dysplasia, and Telomerase Activity Measured by Telomerase Repeat Assay Protocol in Barrett's Esophagus¹

James J. Going*, Aileen J. Fletcher-Monaghan[†], Lisa Neilson^{*‡}, Bea A. Wisman[§], Ate van der Zee[§], Robert C. Stuart[‡] and W. Nicol Keith[†]

Departments of *Pathology, [†]Medical Oncology and [‡]Surgery, University of Glasgow, Glasgow, Scotland, UK; [§]Department of Gynecology, University Hospital Groeningen, Groeningen, The Netherlands

Abstract

Glandular dysplasia in Barrett's esophagus may regress spontaneously but can also progress to cancer. The human telomerase RNA template and the human telomerase reverse transcriptase enzyme which do not, of themselves, correlate strongly with telomerase activity, are too often overexpressed in Barrett's dysplasia to predict individual cancer risk. This study relates telomerase activity, mucosal phenotype, and dysplasia in Barrett's esophagus. Biopsies ($n = 256$) from squamous esophagus, columnar-lined esophagus every 2 cm, esophago-gastric junction, gastric body, and antrum from 32 patients with long-segment Barrett's esophagus were evaluated by telomerase repeat assay protocol (TRAP). Three biopsies for histology ($n = 794$) were simultaneously taken at each anatomical level. These and all prior and subsequent biopsies ($n = 1917$) were reviewed for mucosal phenotypes and dysplasia severity. Intestinal-type Barrett's mucosa was present at all levels in Barrett's esophagus. At least one Barrett's biopsy was TRAP⁺ in 22 of 32 patients. TRAP positivity of intestinal-type Barrett's mucosa increased distally, possibly as a consequence of mucosal exposure to acid or bile reflux. Native gastric mucosa was rarely TRAP⁺ (1/31 corpus, 2/32 antrum), whereas native squamous mucosa usually was TRAP⁺ (31/32). Dysplasia almost always involved intestinal-type Barrett's mucosa (85/87; $P < .00001$), without evidence of proximal–distal zoning. TRAP could be positive without dysplasia and negative in extensive, even high-grade, dysplasia. TRAP activity merits evaluation as a candidate biomarker for increased risk of persistent dysplasia and cancer progression in Barrett's esophagus.

Neoplasia (2004) 6, 85–92

Keywords: Barrett's esophagus, telomerase, dysplasia, neoplasia, cancer progression.

Introduction

Glandular metaplasia or Barrett's esophagus is present in about 10% of adult gastro-esophageal reflux patients, with progression to invasive esophageal adenocarcinoma in

0.5% to 1% of patients per annum [1]. As few patients survive symptomatic esophageal adenocarcinoma [2], management of Barrett's esophagus aims to detect early progression to cancer, which may occur despite acid suppression and control of reflux.

Many gastroenterologists adopt endoscopic and biopsy surveillance to detect progression from metaplasia through low-grade to high-grade dysplasia, which is usually associated with high rates of progression to invasive adenocarcinoma [3], especially when widespread [4]. However, the benefits are debated [5]. Not all gastroenterologists think the cancer risk in Barrett's esophagus justifies regular endoscopy and biopsy, and many elderly patients are not fit for esophagectomy [6,7]. On the other hand, surveillance-detected cancer has a better prognosis than symptomatic cancer [8,9], and mucosal treatments may control high-grade dysplasia and intramucosal carcinoma in patients unfit for surgery [10].

Although accepted as the most reliable available predictor of cancer risk, histological diagnosis of dysplasia is challenging [2,11], and even high-grade Barrett's dysplasia may be less aggressive than usually thought. In the Hines VA Hospital study [12], only 12 of 63 high-grade dysplasia patients followed for a mean of 7.3 years progressed to invasive cancer after prevalent cancer had been excluded by intensive biopsy during the year following initial diagnosis. Such data highlight the absence of effective biomarkers of cancer risk in Barrett's esophagus [13].

The enzyme, telomerase, has recently received attention as a marker expressed at high frequency across the whole spectrum of tumor types [14]. Telomerase is a ribonucleoprotein reverse transcriptase involved in the maintenance of chromosomal telomeres. It allows cancer cells to bypass

Abbreviations: EG junction, esophago-gastric junction; EGTA, ethylene glycol-bis(aminooethyl ether)-tetraacetic acid; hTR, human telomerase RNA template; hTERT, human telomerase reverse transcriptase enzyme; ITAS, internal telomerase assay standard; NO, nitric oxide; PCR, polymerase chain reaction; TBE, TRIS–borate–EDTA buffer; TRAP, telomerase repeat assay protocol; "Z line", esophageal squamo-columnar junction. Address all correspondence to: Dr. James J. Going, Department of Pathology, Western Infirmary, Glasgow G11 6NT, UK. E-mail: going@udcf.gla.ac.uk

¹This work was supported by the Scottish Hospital Endowments Research Trust (SHERT), Cancer Research UK, and Glasgow University.

Received 24 September 2003; Revised 7 November 2003; Accepted 19 November 2003.

cellular senescence and acquire cellular immortality. Over-expression of the human telomerase RNA template (hTR) is frequent in squamous and glandular esophageal carcinomas [15], and increasing hTR expression from Barrett's metaplasia through low-grade to high-grade dysplasia and Barrett's adenocarcinoma has been described [16]. Lord et al. [17] reported increasing expression of mRNA for human telomerase reverse transcriptase enzyme (hTERT) through Barrett's mucosa and dysplasias. Telomerase is, therefore, of interest for its possible role in facilitating esophageal tumor progression, its potential as a predictive biomarker, and as a target for therapy [14], but a full picture of telomerase activity and cellular senescence in the esophagus has not yet emerged.

Appropriate samples in a well-characterized pathological and clinical context are critical to the evaluation of new molecular markers. These are available to our group, which also has experience in telomerase research [18–23] and esophageal carcinogenesis [15,24,25]. Because most patients with Barrett's dysplasia do not develop cancer, the finding of relatively ubiquitous expression of hTR and hTERT in Barrett's dysplasia suggests that their predictive power will be limited. However, measurements of hTR or hTERT mRNA or protein levels do not actually measure telomerase activity. We therefore undertook a survey of mucosal telomerase activity in patients with Barrett's esophagus to evaluate actual telomerase activity as a possible biomarker of cancer risk in Barrett's esophagus.

Patients and Methods

Patients

Thirty-two consecutive patients with biopsy-proven long-segment Barrett's esophagus attending Glasgow Royal Infirmary were recruited over a 10-week period. Apart from five newly diagnosed patients, all were already undergoing at least annual endoscopy and biopsy, with three biopsies being taken for every 2 cm of columnar-lined esophagus (every 1 cm in patients with a previous diagnosis of dysplasia). Patients with previously diagnosed invasive adenocarcinoma were not included. In all, the 32 patients had experienced 152 endoscopies with biopsy, including 77 before the 32 study endoscopies, and 43 after. All patients had more than 3 cm of columnar mucosa in the distal tubular esophagus. Median length of Barrett's esophagus was 8 cm (range 3–16 cm). Mean and median age of patients at the time of the study endoscopy was 64 and 70 years (range 37–84), respectively. There were 24 males and 8 females. Dysplasia was identified in at least one biopsy in 10 of these patients, and indefinite changes not amounting to confirmed dysplasia in a further seven. The study was approved by the Glasgow Royal Infirmary Research Ethics Committee and patients gave written informed agreement to participate.

Biopsy Protocol

At the telomerase study endoscopy, three biopsies were taken for histology from the following locations: original

squamous mucosa proximal to the Barrett's segment, columnar side of the squamo-columnar junction (Z line), Barrett's segment every 2 cm, anatomical esophago-gastric (EG) junction (defined by the most proximal gastric folds), gastric corpus, and antrum. Figure 1 illustrates the anatomy of Barrett's esophagus and the biopsy sites. All biopsies for diagnostic histology were fixed overnight in 4% neutral buffered formaldehyde and embedded in paraffin wax, and 4- μ m sections cut at three histological levels. Dewaxed sections were stained with hematoxylin–eosin. A fourth biopsy taken at each anatomical level for telomerase (telomerase repeat assay protocol, or TRAP) assay was immediately snap-frozen in liquid nitrogen. From these study endoscopies, a total of 256 individual biopsies was examined for telomerase activity (median 8, range 6–11 per patient) and three biopsies from 268 sites ($n = 794$) were examined histologically. In addition, histological review was performed of all esophageal and gastric sites previously ($n = 488$) and subsequently ($n = 401$) biopsied, representing 1057 sites and 3171 individual mucosal biopsies.

Biopsy Review

The same pathologist with an interest in Barrett's esophagus (J.J.G.) was responsible for initial reporting of all biopsies from all endoscopies. Subsequently, all biopsies

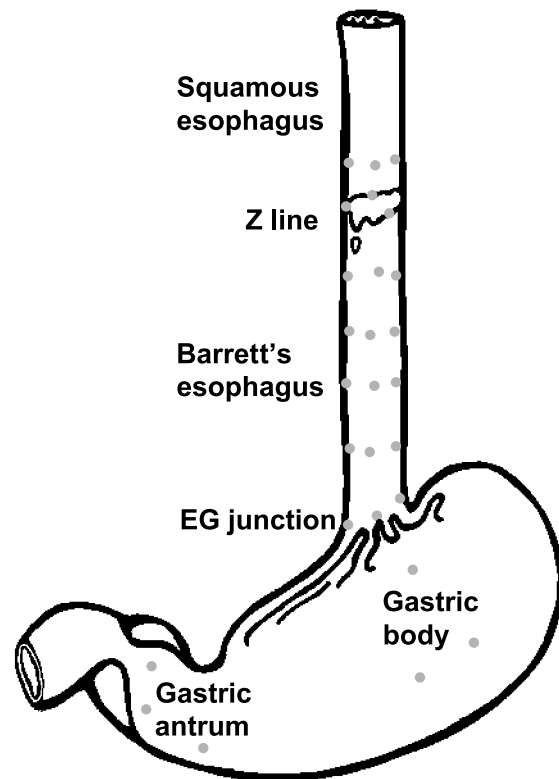


Figure 1. Anatomy of Barrett's esophagus and stomach, with biopsy sites. Proximal esophagus is lined by its native squamous epithelium. Distal to the "Z line," this is replaced by characteristic glandular Barrett's mucosa. Z line is often irregular and there may be residual islands of squamous epithelium below it. Anatomical esophago-gastric (EG) junction is taken as the most proximal extension of the mucosal folds (rugae). Gastric biopsy sites are indicated in the body (proximally) and antrum (distally).

were reviewed by the same pathologist "blind" to the original report. Presence or absence of the following mucosal types was recorded for each biopsy: 1 = full-thickness squamous epithelium; 2 = immature squamous "islands" overlying glandular mucosa; 3 = "specialized" Barrett's mucosa, defined by goblet cells; 4 = mucosa resembling gastric cardia, without goblet cells or oxyntic cells; 5 = cardio-oxyntic mucosa with oxyntic cells, or fully developed gastric fundic mucosa; 6 = antral mucosa (in gastric biopsies). Intestinal metaplasia in biopsies from gastric sites was separately recorded.

Glandular dysplasia was evaluated using published criteria [7,26] in conformity with the Vienna classification [27,28] in the following groups: 1 = no dysplasia; 2 = mild changes, possibly reactive: indefinite for dysplasia; 3 = definite dysplasia of mild or moderate severity: low-grade dysplasia; 4 = severe dysplasia/adenocarcinoma *in situ*: high-grade dysplasia. Although this category may also include biopsies in which invasion is suspected, our series did not include such biopsies. Phenotype of the dysplastic mucosa and biopsy level were also recorded.

Published studies show good interobserver and intraobserver agreement in recognizing high-grade glandular dysplasia in Barrett's esophagus [11,29], but less robust discrimination between no dysplasia, indefinite for dysplasia, and low-grade dysplasia. To evaluate the observer's consistency of dysplasia grading in this study, all biopsies were rescored "blind" to the original reading, after a minimum delay of 6 months. The review dysplasia coding was compared with the grading originally assigned. If these were in agreement, that grading was accepted. If discrepant, a third "blind" review was undertaken before the final allocation of dysplasia grade was based on the majority reading. Reproducibility of dysplasia grading was evaluated by comparison of the first and second overall readings for each biopsy group from a specific site. Although application of diagnostic criteria has been reviewed with histopathologist colleagues in the same and other institutions, interobserver agreement was not evaluated formally.

Derived Calculations and Statistical Analysis

The spatial distribution of mucosal phenotypes in Barrett's esophagus was examined by graphing the percentage of biopsy groups in which each mucosal phenotype was present as a function of the distance from the Z line to the anatomical esophago-gastric junction. The distance along each Barrett's esophagus was also expressed as a percentage to compensate for the variable length of Barrett's esophagus in different patients. This was done by mapping the percentage of biopsies in which a particular mucosal type was present in each centimeter of a particular Barrett's esophagus to the corresponding section of the graph, and averaged for all 32 patients. The mean percentage was calculated for every length centile by summation (Σ) over all 32 patients as $\Sigma(100 n_1 / L) / \Sigma(100 n_2 / L)$, where n_1 is the number of biopsy groups containing the feature in question, n_2 is the total number of biopsy groups, and L is the length of each Barrett's esophagus in centimeters. This strategy gives

equal weight to all biopsies. Zonal distribution of dysplasia was examined identically, taking n_1 as the number of biopsy sites found to be dysplastic, and n_2 as the number of sites in which "specialized" Barrett's mucosa was confirmed (because dysplasia was almost exclusively associated with the intestinal phenotype). Zonal distribution of telomerase activity was mapped analogously.

The κ statistic [30] was calculated as a measure of agreement using Analyse-It version 1.48 (Analyse-It Co., Leeds, UK) in Microsoft Excel '97. Group comparisons were made using Fisher's exact test.

TRAP Assay

Telomerase activity of biopsy samples was determined by a modification of the telomeric repeat amplification protocol described by Kim and Wu [31]. Figure 2 shows representative analysis results. Biopsy samples were lysed with 200 μ l of TRAP lysis buffer, as described [32]. Ten microliters of appropriately diluted extracts (containing 2 and 0.2 μ g of protein extract of each sample) was added to 40 μ l of elongation buffer [50 μ M dNTPs, 1 μ g of telomerase substrate primer (5'-AATCCGTCGAGCAGAGTT-3'), 20 mM Tris/HCl, pH 8.3, 1.5 mM MgCl₂, 63 mM KCl, 1 mM EGTA, and 0.1 mg/ml BSA]. Samples were incubated at room temperature for 30 minutes to allow telomerase-mediated extension of the substrate primer. Endogenous nonspecific inhibitors of Taq DNA polymerase and, consequently, polymerase chain reaction (PCR) [33] can be removed by purification of the extension product prior to PCR. Accordingly, the extension product was purified with QIAquick Nucleotide Removal Kit (Qiagen, Crawley, West Sussex, UK) according to the manufacturer's protocol and eluted from the spin column in 40 μ l of dH₂O. Eluted product was

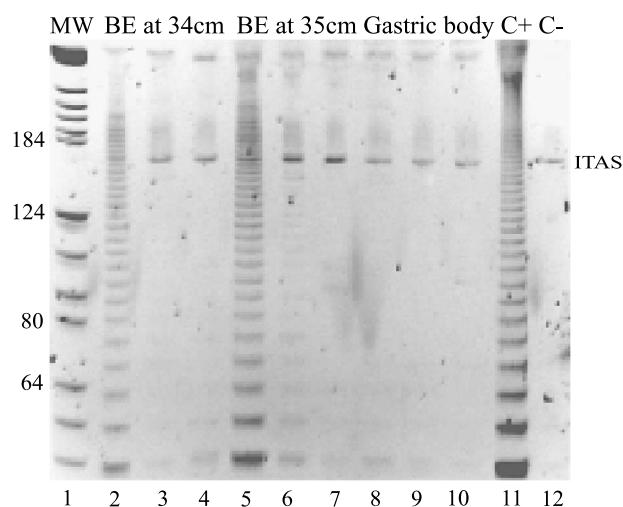


Figure 2. Example of TRAP assay. Lane 1 = molecular weight (MW) markers. In lanes 2 to 4, 5 to 7, and 8 to 10, the first and second lanes represent analysis of 2 or 0.2 μ g of protein extract, whereas the third lane is a heat-inactivated control. BM = Barrett's mucosa. Lanes 2 to 4 = Barrett's mucosa at 34 cm. Lanes 5 to 7 = Barrett's mucosa at 35 cm. Lanes 8 to 10 = gastric body mucosa. Lane 11 is a positive control (C+; GLC4 cells) and lane 12 is a negative control (C-). ITAS is the internal PCR control.

added to PCR buffer [50 μ M dNTPs, 1 μ g of telomerase substrate primer, 20 mM Tris/HCl, pH 8.3, 1.5 mM MgCl₂, 63 mM KCl, 1 mM EGTA, 0.1 mg/ml BSA, 2 U of Taq DNA polymerase (Invitrogen, Paisley, Scotland, UK), 1 μ g of alternative complementary (ACX) primer (5'-GCGCGGCTTACCCTTACCCTTACCCTAACC-3')] [31]. The reaction mixture was heat-inactivated in a thermal cycler for 10 minutes at 85°C and 90 seconds at 90°C, then 31 cycles of 94°C for 30 seconds, 50°C for 30 seconds, and 72°C for 90 seconds. Five microliters of PCR product and 2.5 μ l of high-density TRIS–borate–EDTA buffer (TBE) sample dye (Invitrogen) were analyzed on a 12% nondenaturing polyacrylamide gel in 0.5 \times TBE running buffer. Local optimization determined the use of 31 cycles, which did not lead to false-positive results. Following electrophoresis, gels were stained for 20 minutes with 1 \times SYBR Green (Invitrogen) diluted in running buffer and visualized on a UV transilluminator. An aliquot of each sample was also heat-treated (10 minutes, 85°C) before assaying to serve as a negative control. To control for inhibition of Taq DNA polymerase, an internal telomerase assay standard (ITAS; 15 ag) amplified by the same two primers used for the telomerase activity assay was included in the PCR buffer. Telomerase activity levels in the biopsies were determined using GLC4 cells as standard in each assay. Samples were scored as positive when compared to the GLC4 telomerase extension products for that assay. Limit of detection was 100 GLC4 cell equivalents. All samples were assayed blind in duplicate.

Results

Repeatability of Dysplasia Reading

We have established and validated a large database of comprehensive, closely spaced Barrett's esophagus biopsy samples. This enables us to investigate in detail the spatial distribution of molecular changes. To demonstrate the reproducibility of the dysplasia scoring, repeat scores are presented for individual biopsy sites ($N = 612$) in Table 1. The overall κ score (0.62) represents good agreement. There is most discrepancy between no dysplasia and indefinite for dysplasia, and least between low-grade and high-grade dysplasia. Merging "no dysplasia" with "indefinite for

dysplasia" creates three categories (no definite dysplasia, low-grade dysplasia, high-grade dysplasia) with a κ score representing excellent repeatability (0.79). Although changes suspicious of invasion are often associated with high-grade dysplasia, we did not identify such changes in these patients, probably because only five of our patients were recently diagnosed. The others had been biopsied previously, and patients with evidence of invasion had been excluded.

Zonal Distribution of Different Mucosal Types in Barrett's Esophagus

In order to investigate the zonal distribution of mucosal types in Barrett's esophagus, biopsies were taken for histology from the following locations: original squamous mucosa proximal to the Barrett's segment, columnar side of the squamo-columnar junction (Z line), Barrett's segment every 2 cm, anatomical esophago-gastric junction (defined by the most proximal gastric folds), gastric corpus, and antrum.

This analysis showed a pronounced proximal-to-distal zonation of mucosal phenotype in long-segment Barrett's esophagus, which was reflected in the probability of detecting different mucosal types at different levels in the Barrett's segment. Table 2 is an overview of the data looking at Barrett's esophagus by thirds, and Figure 3 is a more detailed graph of the mean probability for all 32 patients of different mucosal types being present in Barrett's esophagus as a function of anatomical level from the Z line to the most distal Barrett's esophagus, excluding the esophago-gastric junction itself.

Full-thickness squamous epithelium was often detectable in the upper third of the Barrett's segment, diminishing in frequency distally. Superficial squamous islands overlying glandular mucosa were present less often, but at all levels without much variation in frequency. Cardiac-like mucosa occurred at all levels in Barrett's esophagus, but more often distally. Oxyntic differentiation hardly occurred above the lower third. In this location, some biopsies may actually derive from native gastric mucosa, but there is no doubt that oxyntic differentiation in an otherwise cardiac-like mucosa can be found in the true esophagus, confirmed by the presence of esophageal submucosal glands or their ducts. In contrast, "specialized" intestinal-type Barrett's mucosa was likely to be found at all levels in every case, confirming its ubiquitous status in Barrett's esophagus. Equally characteristic in individual cases was the occurrence of several different mucosal phenotypes at a single anatomical level (i.e., mucosal zonation in Barrett's esophagus is present but does not create horizontal bands of uniform mucosal type, but a patchwork of mucosal types varying in proportion with anatomical level).

Dysplasia and Mucosal Phenotype

Our data confirm that dysplasia in Barrett's esophagus is especially likely to occur in "specialized" intestinal type mucosa, and not in other mucosal types [34]. Definite dysplasia, low- or high-grade, was present at 87 sites biopsied; in 85 of these, the dysplasia was in continuity with

Table 1. Repeatability of dysplasia grading at 612 individual Barrett's esophagus biopsy sites.

Second Reading	First Reading			
	No Dysplasia	Indefinite	Low Grade	High Grade
High grade	0	0	6	21
Low grade	9	6	46	0
Indefinite	20	15	5	0
No dysplasia	469	34	8	0

The same observer was responsible for the first and second readings, which were performed independently of each other. On the basis of these data, repeatability of dysplasia grading was regarded as acceptable.

Table 2. Zonation of mucosal type and telomerase activity (right-hand column) in 32 cases of Barrett's esophagus.

Location	Squamous Mucosa	Squamous Islands	Specialized Barrett's Mucosa	Cardiac Mucosa	Fundic-Like Mucosa	TRAP ⁺
Z line	32 100%	10 31%	31 97%	7 22%	0 0%	—
Z line and upper third	32 100%	14 44%	32 100%	10 31%	2 6%	17 53%
Middle third	19 59%	18 56%	32 100%	17 53%	5 16%	8 25%
Lower third	16 50%	15 47%	32 100%	27 84%	32 72%	10 31%
EG junction	7 22%	8 25%	18 56%	23 72%	30 94%	3 10%

Columns show the number and percentage of cases in which different mucosal types were present at various levels including the Z line alone and the upper, middle, and lower thirds of the Barrett's segment. The last column shows the frequency of TRAP positivity at the same levels.

histologically confirmed "specialized" intestinal type found at 616 sites (14%), and only two dysplastic sites were in continuity with histologically confirmed cardiac-type mucosa found at 156 esophageal sites (1.3%) ($P < .00001$).

Telomerase Activity and Mucosal Phenotype

Telomerase positivity was identifiable at all levels in Barrett's esophagus (Table 2), but did fluctuate with location (Figure 4, *a* and *b*; Table 2). Interestingly, TRAP positivity was most frequent in the upper third of Barrett's esophagus ($P < .02$), fell to a pronounced minimum at the junction of the upper with the middle third, before rising and falling again as the esophago-gastric junction is approached.

The original squamous mucosa proximal to Barrett's esophagus was almost invariably TRAP⁺ (31/32, 97%). To investigate whether the proximal-to-distal gradient of decreasing TRAP positivity in the proximal third of Barrett's esophagus might reflect a contribution from residual islands of native squamous epithelium, we looked at TRAP data for 117 biopsies from sites in which "specialized" Barrett's

mucosa was present. Twenty of 48 biopsies (42%) from sites where full-thickness squamous epithelium was also present were TRAP⁺, against 23/69 (33.3%) from sites in which squamous epithelium had not been demonstrated. Similarly, 9 of 21 biopsies (43%) from sites with squamous islands were TRAP⁺, against 34/96 (35.4%) without evidence of squamous differentiation. Although there is a trend toward greater TRAP positivity at Barrett's sites with residual squamous mucosa or squamous island differentiation, it does not reach statistical significance (Fisher's exact test).

TRAP positivity was unusual in gastric mucosal biopsies from Barrett's patients: 1/31 (3%) of gastric body and 2/32 (6%) of gastric antral biopsies. Intestinal metaplasia was also infrequent in gastric locations [gastric body, 3/32 (9%) and

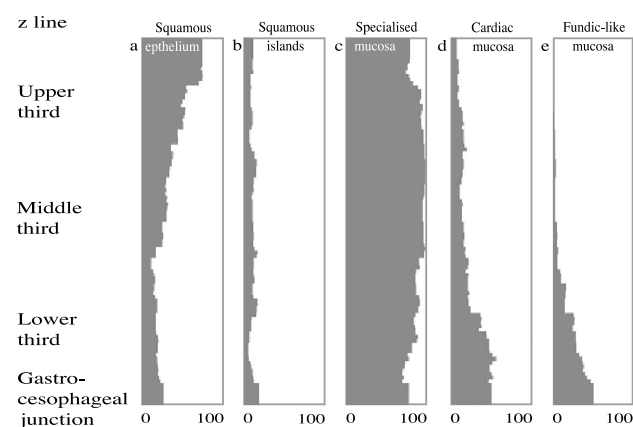


Figure 3. Mean probability (expressed as a percentage) for all 32 patients of different mucosal types being identified in Barrett's esophagus as a function of anatomical level, on the vertical axis, from the Z line proximally (top) down to, but not including, the anatomical esophago-gastric junction distally (bottom). The grey shaded area in each box shows how often that particular component is found at that level. The five boxes represent (a) full-thickness squamous epithelium, (b) squamous islands over glandular mucosa, (c) "specialized" intestinal-type Barrett's mucosa, (d) cardiac-type mucosa, and (e) cardio-oxynic or fundic mucosa.

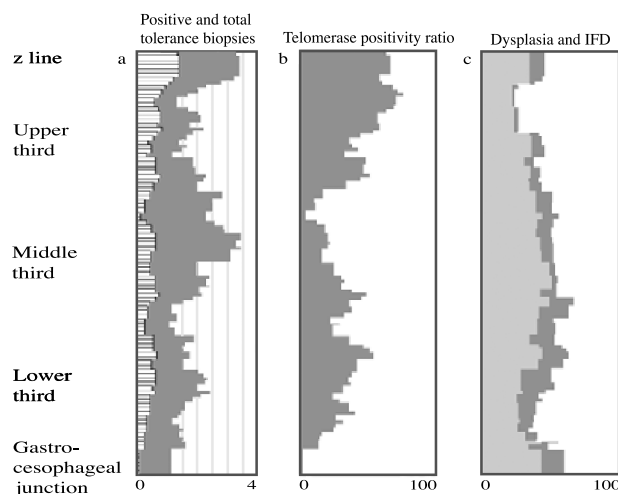


Figure 4. The left-hand box (*a*) shows a stacked graph of the number of telomerase-positive biopsies and the total number of telomerase biopsies as a function of anatomical level, on the vertical axis, from the Z line proximally (top) down to, but not including, the anatomical esophago-gastric junction distally (bottom). Data for all 32 patients with long-segment Barrett's esophagus. Horizontal scale is the number of biopsies represented by each centile. The center graph (*b*) plots the mean percentage of telomerase biopsies, which were TRAP⁺ for all 32 patients with long-segment Barrett's esophagus, as a function of anatomical level on the vertical axis. There is pronounced fluctuation in the percentage of TRAP⁺ biopsies with anatomical level. The right-hand box (*c*) plots the average probability of dysplasia being present in "specialized" intestinal Barrett's mucosa as a function of anatomical level. Data are averaged for the 10 patients with definite dysplasia and seven patients indefinite for dysplasia. There is no evidence of any significant proximal-to-distal gradient in dysplasia frequency.

Table 3. Telomerase positivity in one or more Barrett's mucosa biopsies as a function of worst recorded dysplasia in any biopsy from any endoscopy (center column) or only in biopsies taken at the study endoscopy (right column).

Most Severe Dysplasia Identified	Telomerase Positivity by Worst Dysplasia in Any Biopsy from Any Endoscopy	Telomerase Positivity by Worst Dysplasia in Any Biopsy from Telomerase Endoscopy
No dysplasia	9/16 56%	12/19 63%
Indefinite for dysplasia	5/6 83%	5/6 83%
Low-grade dysplasia	3/4 75%	3/5 60%
High-grade dysplasia	5/6 83%	2/2 100%

6/32 (19%)] and gastric intestinal metaplasia was not identified in the three patients with telomerase-positive gastric biopsies (Figure 4).

Zonal Distribution of Dysplasia

This was examined in the same way as the zonal distribution of mucosal phenotype. Figure 4c shows the average probability of dysplasia for 10 cases in which there was definite dysplasia, and a further seven cases indefinite for dysplasia. Although some fluctuation in the probability of dysplasia being present was observed, there was no evidence of any major proximal to distal trend.

Telomerase Activity and Dysplasia

Histological diagnosis of dysplasia is accepted as the most reliable predictor of cancer risk, yet is not without difficulties. It is therefore of value to investigate the relationship of any new molecular marker such as telomerase for its relationship to dysplasia, as this may give an indication of its potential use in risk assessment as well as basic biological information on the underlying causes of disease progression. Table 3 gives an overview of telomerase activity in relation to the patient's overall dysplasia status and their dysplasia status on the occasion of the telomerase endoscopy. Although there is a trend toward more frequent telomerase positivity with increasing dysplasia, it does not achieve statistical significance, and some patients with no evidence of dysplasia had multiple TRAP⁺ biopsies from the Barrett's segment, whereas others with extensive dysplastic change were TRAP⁻ in all biopsies.

Discussion

Barrett's mucosa is phenotypically complex. "Specialized" intestinal-type Barrett's mucosa is invariably present in long-segment Barrett's esophagus, and the previously reported association of dysplasia with intestinal Barrett's mucosa is very striking in our series [34]. We show also that native esophageal squamous epithelium, in which consistent expression of hTR has been described [15–17,35], is also consistently TRAP⁺. Esophageal squamous epithelium is exposed to physical, thermal, and—in the case of Barrett's

patients—chemical trauma, so this could potentially be an adaptation to a relatively stressful niche environment, especially in Barrett's patients. A study to determine whether TRAP positivity is likewise ubiquitous in esophageal squamous epithelium of patients without Barrett's esophagus would be of value. Although telomerase activity in native gastric mucosae is rare in Barrett's patients, esophageal biopsies in which "specialized" intestinal-type Barrett's mucosa is characteristic are frequently telomerase-positive.

The absence of obvious zonation of dysplasia in this study supports the previous observation from relatively small patient numbers that dysplasia is evenly distributed along the length of Barrett's esophagus [36]. The current recommendation for uniformly distributed endoscopic biopsies of the entire Barrett's segment is therefore supported. The impressive association between dysplasia and intestinal metaplasia in our series confirms that endoscopic or molecular markers of the intestinal phenotype might allow useful biopsy targeting [24].

The low frequency, small size, and unknown telomerase status of islands of squamous differentiation "floating" over glandular mucosa make their contribution to TRAP positivity in our biopsies hard to evaluate, but residual native squamous epithelium may contribute some TRAP⁺ biopsies in the proximal third of long Barrett's segments. More targeted analysis of telomerase activity of specific cell populations (e.g., squamous islands *versus* adjacent Barrett's mucosa), by analysis of microdissected samples or *in situ* methods could clarify this issue. Similarly, TRAP⁻ cardiac and cardio-oxynitic mucosae could account for the falling proportion of TRAP⁺ biopsies in the distal Barrett's esophagus. This leaves a steep rise in TRAP positivity beginning at the junction of the upper third with the middle third of Barrett's esophagus to be accounted for (Figure 4b). Unlike native squamous esophageal mucosa, telomerase activity appears not to be an intrinsic property of "specialized" intestinal-type Barrett's mucosa, as many biopsies from sites where this mucosa is well represented are TRAP⁻. One possibility is that it is inducible by local environmental influences, possibly related to reflux, and susceptibility to such activation could underlie its powerful association with dysplasia and neoplasia in Barrett's esophagus.

Recently published data suggest a possible mechanism of telomerase activation in intestinal-type Barrett's mucosa [37]. Dietary nitrate, resecreted in saliva, is reduced to nitrite by oral microorganisms, and swallowed nitrite is further reduced to nitric oxide (NO) on encountering gastric acid. Nitrate ingestion leads to a substantial rise in peak nitric oxide concentration in the esophago-gastric lumen, just distal to the point at which the luminal pH falls to gastric levels. Low esophageal pH values could elevate NO levels in the esophageal lumen, and although there are no published data for the effect of NO on telomerase activity in Barrett's, gastric, or intestinal epithelia, nitric oxide is known to activate telomerase in endothelial cells [38].

Telomerase activity induced by nitric oxide in intestinal-type glandular mucosa in Barrett's patients could confer a survival advantage accounting for increased goblet cell

numbers with age in Barrett's esophagus [39]. A high frequency of telomerase activity in Barrett's mucosa of intestinal type could also facilitate survival of clones of cells with pro-oncogenic mutations. The question immediately suggests itself why there is no obvious relationship between dysplasia and location in Barrett's esophagus (as we and others have shown). One possibility is that abnormal cellular motility appears often to be a feature of such cellular clones, identified by a variety of abnormalities such as tetraploidy, aneuploidy [40], epigenetic changes [41,42], or *p16* mutation [41], all of which may colonize large areas of Barrett's mucosa. Such population movement would tend to make geographical relationships less obvious. Furthermore, the emergence of dysplasia and telomerase activation are clearly two different things, with multiple causes.

This series shows not only that telomerase-positive mucosa can be present in patients in whom extensive repeated biopsy showed no dysplasia, but also that patients with extensive dysplasia can be telomerase-negative. Morales et al. [16] found a strong association between dysplasia and telomerase RNA template (hTR) expression, and Lord et al. [17] showed the same in respect of hTERT mRNA. It may appear paradoxical, therefore, that such a strong association does not emerge in our own studies, but we know that most Barrett's patients with dysplasia, even high-grade dysplasia, will never develop esophageal adenocarcinoma, and it follows that hTR and hTERT, which are overexpressed in most examples of Barrett's dysplasia [16,17], cannot identify Barrett's esophagus patients most at risk of esophageal adenocarcinoma. TRAP activity is likely to give a better idea of telomere maintenance status, and precisely because telomerase is *not* active in all Barrett's dysplasia, it may be a more effective marker of dysplasia persistence and cancer risk in Barrett's esophagus. Some Barrett's dysplasias disappear over time: perhaps such examples are not protected from cellular senescence by telomerase activation. Reliable *in situ* assays of telomerase activity [43], or simultaneous morphological and biochemical evaluations of the same biopsies allowing histology and telomerase activity to be evaluated simultaneously in the same cells (with microdissection, where appropriate) would help to clarify the role of telomerase activity in the emergence and evolution of Barrett's neoplasia.

References

- Shaheen NJ, Crosby MA, Bozynski EM, and Sandler RS (2000). Is there publication bias in the reporting of cancer risk in Barrett's esophagus? *Gastroenterology* **119**, 333–338.
- Heath EI, Limburg PJ, Hawk ET, and Forastiere AA (2000). Adenocarcinoma of the esophagus: risk factors and prevention. *Oncology (Huntington)* **14**, 507–514.
- Reid BJ, Levine DS, Longton G, Blount PL, and Rabinovitch PS (2000). Predictors of progression to cancer in Barrett's esophagus: baseline histology and flow cytometry identify low- and high-risk patient subsets. *Am J Gastroenterol* **95**, 1669–1676.
- Buttar NS, Wang KK, Sebo TJ, Riehle DM, Krishnadath KK, Lutzke LS, Anderson MA, Petterson TM, and Burgart LJ (2001). Extent of high-grade dysplasia in Barrett's esophagus correlates with risk of adenocarcinoma. *Gastroenterology* **120**, 1630–1639.
- Soni A, Sampliner RE, and Sonnenberg A (2000). Screening for high-grade dysplasia in gastroesophageal reflux disease: is it cost-effective? *Am J Gastroenterol* **95**, 2086–2093.
- Macdonald CE, Wicks AC, and Playford RJ (2000). Final results from 10 year cohort of patients undergoing surveillance for Barrett's esophagus: observational study. *BMJ* **321**, 1252–1255.
- Riddell RH (1996). Early detection of neoplasia of the esophagus and gastroesophageal junction. *Am J Gastroenterol* **91**, 853–863.
- Wright TA, Gray MR, Morris AI, Gilmore IT, Ellis A, Smart HL, Myskow J, Nash J, Donnelly RJ, and Kingsnorth AN (1996). Cost effectiveness of detecting Barrett's cancer. *Gut* **39**, 574–579.
- Incarbone R, Bonavina L, Saino G, Bona D, and Peracchia A (2002). Outcome of esophageal adenocarcinoma detected during endoscopic biopsy surveillance for Barrett's esophagus. *Surg Endosc* **16**, 263–266.
- May A, Gossner L, Pech O, Fritz A, Gunter E, Mayer G, Muller H, Seitz G, Vieth M, Stolte M, and Ell C (2002). Local endoscopic therapy for intraepithelial high-grade neoplasia and early adenocarcinoma in Barrett's esophagus: acute-phase and intermediate results of a new treatment approach. *Eur J Gastroenterol Hepatol* **14**, 1085–1091.
- Montgomery E, Bronner MP, Goldblum JR, Greenson JK, Haber MM, Hart J, Lamps LW, Lauwers GY, Lazenby AJ, Lewin DN, Robert ME, Toledano AY, Shyr Y, and Washington K (2001). Reproducibility of the diagnosis of dysplasia in Barrett esophagus: a reaffirmation. *Hum Pathol* **32**, 368–378.
- Schnell TG, Sontag SJ, Chejfec G, Aranha G, Metz A, O'Connell S, Seidel UJ, and Sonnenberg A (2001). Long-term nonsurgical management of Barrett's esophagus with high-grade dysplasia. *Gastroenterology* **120**, 1607–1619.
- Krishnadath KK, Reid BJ, and Wang KK (2001). Biomarkers in Barrett esophagus. *Mayo Clin Proc* **76**, 438–446.
- Keith WN and Evans RM (2001). Telomerase and cancer: time to move from a promising target to a clinical reality. *J Pathol* **195**, 404–414.
- Downey MG, Going JJ, Stuart RC, and Keith WN (2001). Expression of telomerase RNA in esophageal and oral cancer. *J Oral Pathol Med* **30**, 577–581.
- Morales CP, Lee EL, and Shay JW (1998). *In situ* hybridization for the detection of telomerase RNA in the progression from Barrett's esophagus to esophageal adenocarcinoma. *Cancer* **83**, 652–659.
- Lord RV, Salonga D, Danenberg KD, Peters JH, DeMeester TR, Park J, Johansson J, Skinner KA, Chandrasoma P, DeMeester SR, Bremner PI, Tsai PI, and Danenberg PV (2000). Telomerase reverse transcriptase expression is increased early in the Barrett's metaplasia, dysplasia, adenocarcinoma sequence. *J Gastrointest Surg* **4**, 135–142.
- Bryce LA, Morrison N, Hoare SF, Muir S, and Keith WN (2000). Mapping of the gene for the human telomerase reverse transcriptase, hTERT, to chromosome 5p15.33 by fluorescence *in situ* hybridization. *Neoplasia* **2**, 197–201.
- Hoare SF, Bryce LA, Wisman GB, Burns S, Going JJ, van der Zee AG, and Keith WN (2001). Lack of telomerase RNA gene hTERC expression in alternative lengthening of telomeres cells is associated with methylation of the hTERC promoter. *Cancer Res* **61**, 27–32.
- Soder AI, Hoare SF, Muir S, Going JJ, Parkinson EK, and Keith WN (1997). Amplification, increased dosage and *in situ* expression of the telomerase RNA gene in human cancer. *Oncogene* **14**, 1013–1021.
- Soder AI, Hoare SF, Muire S, Balmain A, Parkinson EK, and Keith WN (1997). Mapping of the gene for the mouse telomerase RNA component, *Terc*, to chromosome 3 by fluorescence *in situ* hybridization and mouse chromosome painting. *Genomics* **41**, 293–294.
- Soder AI, Going JJ, Kaye SB, and Keith WN (1998). Tumour specific regulation of telomerase RNA gene expression visualized by *in situ* hybridization. *Oncogene* **16**, 979–983.
- Zhao JQ, Hoare SF, McFarlane R, Muir S, Parkinson EK, Black DM, and Keith WN (1998). Cloning and characterization of human and mouse telomerase RNA gene promoter sequences. *Oncogene* **16**, 1345–1350.
- Going JJ, Stuart RC, Downie M, Fletcher-Monaghan AJ, and Keith WN (2002). "Senescence-associated" beta galactosidase activity in mucosae of the upper gastrointestinal tract. *J Pathol* **196**, 394–400.
- Going JJ, Keith WN, Neilson L, Stoeber K, Stuart RC, and Williams GH (2001). Aberrant expression of minichromosome maintenance proteins 2 and 5, and Ki-67 in dysplastic squamous esophageal epithelium and Barrett's mucosa. *Gut* **50**, 373–377.
- Haggitt RC (1994). Barrett's esophagus, dysplasia, and adenocarcinoma. *Hum Pathol* **25**, 982–993.
- Schlemper RJ, Riddell RH, Kato Y, Borchard F, Cooper HS, Dawsey MF, Dixon MF, Fenoglio-Preiser CM, Flejou JF, Geboes K, Hattori

- T, Hirota T, Itabashi M, Iwafuchi M, Iwashita A, Kim YI, Kirchner T, Klimpfinger M, Koike M, Lauwers GY, Lewin KJ, Oberhuber G, Offner F, Price AB, Rubio CA, Shimizu M, Shimoda T, Sipponen P, Solcia E, Stolte M, Watanabe H, and Yamabe H (2000). The Vienna classification of gastrointestinal epithelial neoplasia. *Gut* **47**, 251–255.
- [28] Schlemper RJ, Kato Y, and Stolte M (2001). Review of histological classifications of gastrointestinal epithelial neoplasia: differences in diagnosis of early carcinomas between Japanese and Western pathologists. *J Gastroenterol* **36**, 445–456.
- [29] Reid BJ, Haggitt RC, Rubin CE, Roth G, Surawicz CM, VanBelle G, Lewin K, Weinstein WM, Antonioli DA, Goldman H, MacDonald W, Owen D (1988). Observer variation in the diagnosis of dysplasia in Barrett's esophagus. *Hum Pathol* **19**, 166–178.
- [30] Silcocks PB (1983). Measuring repeatability and validity of histological diagnosis—a brief review with some practical examples. *J Clin Pathol* **36**, 1269–1275.
- [31] Kim NW and Wu F (1997). Advances in quantification and characterisation of telomerase activity by the telomerase repeat amplification protocol. *Nucleic Acids Res* **25**, 2595–2597.
- [32] Schroder CP, Wisman GB, deJong S, van der Graaf WT, Ruiters MH, Mulder NH, de Leij LF, van der Zee AG, and de Vries EG (2001). Telomere length in breast cancer patients before and after chemotherapy with or without stem cell transplantation. *Br J Cancer* **84**, 1348–1353.
- [33] Nakamura Y, Tahara E, Tahara H, Yasui W, and Ide T (1999). Quantitative reevaluation of telomerase activity in cancerous and noncancerous gastrointestinal tissues. *Mol Carcinog* **26**, 312–320.
- [34] Schmidt HG, Riddell RH, Walther B, Skinner DB, and Riemann JF (1985). Dysplasia in Barrett's esophagus. *J Cancer Res Clin Oncol* **110**, 145–152.
- [35] Bachor C, Bachor OA, and Boukamp P (1999). Telomerase is active in normal gastrointestinal mucosa and not up-regulated in precancerous lesions. *J Cancer Res Clin Oncol* **125**, 453–460.
- [36] McArdle JE, Lewin KJ, Randall G, and Weinstein W (1992). Distribution of dysplasias and early invasive carcinoma in Barrett's esophagus. *Hum Pathol* **23**, 479–482.
- [37] Iijima K, Henry E, Moriya A, Wirz A, Kelman AW, and McColl KE (2002). Dietary nitrate generates potentially mutagenic concentrations of nitric oxide at the gastroesophageal junction. *Gastroenterology* **122**, 1248–1257.
- [38] Vasa M, Breitschopf K, Zeiher AM, and Dimmeler S (2000). Nitric oxide activates telomerase and delays endothelial cell senescence. *Circ Res* **87**, 540–542.
- [39] Qualman SJ, Murray RD, McClung HJ, and Lucas J (1990). Intestinal metaplasia is age related in Barrett's esophagus. *Arch Pathol Lab Med* **114**, 1236–1240.
- [40] Rabinovitch PS, Reid BJ, Haggitt RC, Norwood TH, and Rubin CE (1989). Progression to cancer in Barrett's esophagus is associated with genomic instability. *Lab Invest* **60**, 65–71.
- [41] Wong DJ, Paulson TG, Prevo LJ, Galipeau PC, Longton G, Blount PL, and Reid BJ (2001). p16(INK4a) lesions are common, early abnormalities that undergo clonal expansion in Barrett's metaplastic epithelium. *Cancer Res* **61**, 8284–8289.
- [42] Eads CA, Lord RV, Kurumboor SK, Wickramasinghe K, Skinner ML, Long TI, Peters JH, DeMeester TR, Danenberg KD, Danenberg PV, Laird PW, and Skinner KA (2000). Fields of aberrant CpG island hypermethylation in Barrett's esophagus and associated adenocarcinoma. *Cancer Res* **60**, 5021–5026.
- [43] Youssef N, Paradis V, Ferlicot S, and Bedossa P (2001). *In situ* detection of telomerase enzymatic activity in human hepatocellular carcinogenesis. *J Pathol* **194**, 459–465.