

University of Groningen

## Oral sequelae resulting from head and neck radiotherapy

Jansma, Johan

**IMPORTANT NOTE: You are advised to consult the publisher's version (publisher's PDF) if you wish to cite from it. Please check the document version below.**

*Document Version*

Publisher's PDF, also known as Version of record

*Publication date:*

1991

[Link to publication in University of Groningen/UMCG research database](#)

*Citation for published version (APA):*

Jansma, J. (1991). *Oral sequelae resulting from head and neck radiotherapy: Course, prevention and management of radiation caries and other oral complications.* [S.n.].

### Copyright

Other than for strictly personal use, it is not permitted to download or to forward/distribute the text or part of it without the consent of the author(s) and/or copyright holder(s), unless the work is under an open content license (like Creative Commons).

The publication may also be distributed here under the terms of Article 25fa of the Dutch Copyright Act, indicated by the "Taverne" license. More information can be found on the University of Groningen website: <https://www.rug.nl/library/open-access/self-archiving-pure/taverne-amendment>.

### Take-down policy

If you believe that this document breaches copyright please contact us providing details, and we will remove access to the work immediately and investigate your claim.

*Downloaded from the University of Groningen/UMCG research database (Pure): <http://www.rug.nl/research/portal>. For technical reasons the number of authors shown on this cover page is limited to 10 maximum.*

# Oral sequelae resulting from head and neck radiotherapy

Course, prevention and management  
of radiation caries and other oral complications

Johan Jansma

The bottom of the page features a decorative graphic consisting of several overlapping, wavy, horizontal bands in shades of light orange and cream, creating a soft, abstract landscape-like effect.

# **ORAL SEQUELAE RESULTING FROM HEAD AND NECK RADIOTHERAPY**

Course, prevention and management of radiation caries  
and other oral complications

Cover: T. Jansma & E. G. C. van Ommen  
Typesetting: STYX Publications

**STELLINGEN**  
behorend bij het proefschrift

**ORAL SEQUELAE RESULTING FROM HEAD AND NECK RADIOTHERAPY**

Course, prevention and management of radiation caries  
and other oral complications

- 1 Tandglazuur bestraald met een therapeutische dosis ioniserende stralen, ondervindt hiervan geen schadelijke gevolgen.  
Dit proefschrift
- 2 De in de literatuur geadviseerde dagelijkse applicatie van een fluoride-gel bij patiënten bestraald op het hoofd-halsgebied kan, mits gecombineerd met een goede mondhygiëne, worden teruggebracht tot eenmaal per twee dagen.  
Dit proefschrift
- 3 Bij de bestralingsbehandeling van patiënten met hoofd-halstumoren dient men te beschikken over een goed opgeleid tandheelkundig team.
- 4 Hyposialie wordt door veel medici onderschat.
- 5 Een speekselsubstituut op maat bestaat niet.  
(Levine et al. J Dent Res 1987;66:693-698)
- 6 Het onderzoek van Franzén et al. naar de effecten van gefractioneerde bestraling op de morfologie en functie van speekselklierweefsel gaat voorbij aan de huidige inzichten in de mechanismen van stralingsschade aan dat weefsel.  
(Franzén et al. Lab Invest 1991;64:279-283)
- 7 Een Abbe-plastiek moet bij schisispatiënten niet worden toegepast indien er geen normale intermaxillaire relatie bestaat.
- 8 Het is te hopen dat er na de stormachtige ontwikkeling die de orale implantologie heeft doorgemaakt geen toekomst is weggelegd voor de orale explantologie.
- 9 Het verwijderen van een verstandskies in de onderkaak zonder gebruikmaking van een adequate röntgenfoto getuigt van weinig gevoel voor de onderlip.

- 10 De relatie tussen de concentratie N-acetyl-L-aspartaat in bepaalde hersengebieden en de ernst van dementie bij de ziekte van Alzheimer is aan kritiek onderhevig.  
(Kwo-On-Yuen et al. Soc Magn Res Med 1991;1:429)
- 11 Diabetische retinopathie is alleen goed te beoordelen indien gespiegeld wordt in mydriasis.
- 12 In het kader van infectie-preventie, waarvan men zich steeds meer bewust is geworden door de AIDS problematiek, dienen kappers voor iedere klant een nieuw scheermes te gebruiken.
- 13 De term kijkoperatie dient te worden gereserveerd voor die ingrepen waarbij de assistent in opleiding slechts mag toekijken.
- 14 Veel politie-agenten en militairen ontlenen een deel van hun gezag aan hun snor.

Groningen, 13 november 1991

Johan Jansma

RIJKSUNIVERSITEIT GRONINGEN

**ORAL SEQUELAE RESULTING FROM HEAD AND NECK RADIOTHERAPY**

Course, prevention and management of radiation caries  
and other oral complications

**PROEFSCHRIFT**

ter verkrijging van het doctoraat in de Geneeskunde  
aan de Rijksuniversiteit Groningen  
op gezag van de Rector Magnificus Dr. S. K. Kuipers  
in het openbaar te verdedigen op woensdag 13 november 1991  
des namiddags te 2.45 uur precies  
door

**JOHAN JANSMA**

geboren op 24 januari 1962  
te Leeuwarden

DRUKKERIJ VAN DENDEREN B.V.  
Groningen  
1991

Promotores                    Prof. Dr. E. J. 's-Gravenmade  
                                     Prof. Dr. A. K. Panders  
                                     Prof. Dr. A. Vermey, FACS

Referent                        Dr. A. Vissink

Promotiecommissie        Prof. Dr. G. Boering  
                                     Prof. Dr. D. H. Retief  
                                     Prof. Dr. B. G. Szabó

Paranimfen                    Drs. A. G. Becking  
                                     Drs. R. J. Bun



Aan mijn ouders  
Voor Dionne

ISBN 90-9004462-0  
©by J. Jansma, Groningen, 1991

Parts of this study were financially supported by:  
Koningin Wilhelmina Fonds (grant no. 84-4)  
Praeventiefonds (grant no. 28-1290)

Contributions to the printing costs of this thesis were made by:  
Stichting Het Scholten-Cordes Fonds  
Dr. L. A. Buma Stichting  
Pharmachemie BV

# CONTENTS

## VOORWOORD

1	INTRODUCTION AND AIMS OF THE INVESTIGATION	1
2	REVIEW OF THE LITERATURE	5
	Introduction	5
	Radiation treatment	5
	Oral consequences of head and neck radiotherapy	7
	<i>Oral mucosa</i>	7
	<i>Salivary glands</i>	9
	<i>Dentition</i>	12
	<i>Periodontium</i>	16
	<i>Bone</i>	16
	<i>Taste</i>	19
	<i>Muscles and joints</i>	19
	<i>Pattern of complaints</i>	20
	Prevention and treatment of oral sequelae resulting from head and neck radiotherapy	21
	<i>Mucositis</i>	21
	<i>Hyposalivation</i>	25
	<i>Radiation caries</i>	28
	<i>Periodontal disease</i>	33
	<i>Osteoradionecrosis</i>	33
	<i>Taste loss</i>	37
	<i>Trismus</i>	38
3	RADIATION CARIES: IN VITRO AND IN SITU EXPERIMENTS	51
	The effect of X-ray irradiation on the demineralization of bovine dental enamel	52
	The effect of X-ray irradiation on the permeability of bovine dental enamel	58
	A model to investigate xerostomia-related dental caries	66
	A SEM study of natural and induced radiation caries	75
	In situ study on the prevention of radiation caries	89
4	A SURVEY OF THE PREVENTION AND TREATMENT REGIMENS OF ORAL SEQUELAE RESULTING FROM HEAD AND NECK RADIOTHERAPY USED IN DUTCH RADIOTHERAPY INSTITUTES	101

5	PROTOCOL FOR THE PREVENTION AND TREATMENT OF ORAL SEQUELAE RESULTING FROM HEAD AND NECK RADIOTHERAPY	117
	Introduction	119
	Prevention and treatment of oral sequelae	119
	Pre-irradiation patient management	123
	<i>Physical and radiographic examination</i>	123
	<i>Treatment and prophylaxis</i>	124
	<i>Initiation of a new preventive regimen</i>	126
	<i>Nutritional instructions</i>	128
	Patient management during radiation treatment	129
	Post-irradiation patient management	130
	<i>Oral mucosa</i>	131
	<i>Oral dryness</i>	131
	<i>Dentition</i>	132
	<i>Trismus prevention</i>	133
	<i>Nutritional counseling</i>	134
	Epilogue	134
	SUMMARY	137
	SAMENVATTING	141
	APPENDIX: QUESTIONNAIRE	147
	CURRICULUM VITAE	157

## VOORWOORD

Toen ik vijf jaar geleden met dit onderzoek begon en het nog niet vast stond dat het tot een proefschrift zou leiden, had ik er geen idee van dat ik met zeer veel verschillende mensen van zeer verschillende afdelingen op uiterst plezierige wijze zou gaan samenwerken. Ik kijk dan ook terug op een boeiende en leerzame periode die ik beslist niet had willen missen. Op deze plaats wil ik graag al diegenen bedanken, die op enigerlei wijze hebben bijgedragen aan het tot stand komen van dit proefschrift. Een aantal personen wil ik met name noemen.

Prof. Dr. E. J. 's-Gravenmade, hooggeachte promotor, beste professor. U bent degene geweest die mijn interesse heeft gewekt voor het verrichten van een promotie-onderzoek. De positief kritische en altijd bijzonder stimulerende wijze waarop U dit werk vanaf het begin hebt begeleid en de wijze waarop U mij wegwijs maakte in 'onderzoeksland' heb ik zeer gewaardeerd. Mijn dank daarvoor is groot.

Prof. Dr. A. K. Panders, hooggeachte promotor, beste Arend. Jouw grote klinische kennis en ervaring waren onontbeerlijk voor het klinische deel van het onderzoek. Je commentaren en onze discussies heb ik als zeer waardevol ervaren en hoop ze, ook binnen andere richtingen van ons vak, nog vaak met je over te doen.

Prof. Dr. A. Vermey, hooggeachte promotor, beste professor. Ik ben blij dat U, als nestor van de preventieve zorg bij hoofd-halsbestralings patiënten in Groningen, betrokken was bij mijn onderzoek. U bent reeds vaak geroemd vanwege de snelheid waarmee U manuscripten op kundige wijze van commentaar voorziet en ik sluit mij in dat opzicht dan ook graag bij vorige promovendi aan. Bedankt voor de prettige samenwerking.

Dr. A. Vissink, zeer geleerde referent, beste Arjan. Een ieder die jou kent, hoeft ik het niet uit te leggen en een ieder die jou niet kent, zal het niet direct begrijpen, maar een betere begeleider dan jij bestaat er niet. Je was zeer betrokken bij het onderwerp en het onderzoek met zowel raad als daad. Ik heb erg veel van je geleerd en altijd uiterst plezierig en vriendschappelijk met je samengewerkt en hoop dat ook in de toekomst te blijven doen.

Prof. Dr. G. Boering, beste professor. Ik ben U zeer dankbaar dat U mij de mogelijkheid hebt geboden om naast mijn opleiding tot kaakchirurg mijn onderzoek voort te zetten. U was altijd zeer geïnteresseerd in mijn vorderingen. Ik beschouw het als een eer, dat U bereid was zitting te nemen in de promotiecommissie.

Prof. Dr. D. H. Retief, beste professor. Ek is U groot dank verskuldig vir die samenwerking met U gedurende die eerste jaar van die navorsingsprojek asook vir die vinnige beoordeling van hierdie tesis. Ek beskou dit as 'n groot eer dat U bij die promosie teenwoordig sal wees. Baie, baie dankie.

Prof. Dr. B. G. Szabó, beste professor. Graag wil ik U bedanken voor Uw welwillendheid om deel uit te maken van de promotiecommissie en voor de tijd en aandacht die U aan mijn proefschrift hebt willen besteden.

Dr. W. L. Jongebloed, beste Wim. Ik ben jou, als expert op het gebied van cariës in de hoogste vergroting, veel dank verschuldigd voor de grote vakkundigheid waarmee je de vele scanning-elektronenmicroscopische opnamen hebt gemaakt en voor je inbreng in de discussies over wat er allemaal op te zien was.

Prof. Dr. B. Löwenberg van het Rotterdams Radio-Therapeutisch Instituut/ Daniel den Hoed Kliniek dank ik hartelijk voor de gelegenheid mij geboden om gedurende een jaar verbonden te zijn geweest aan genoemd instituut.

Drs. L. L. Visch, beste Leo. Onze contacten in de beginfase van het onderzoek hebben in belangrijke mate bijgedragen tot wat het onderzoek uiteindelijk is geworden. Bedankt daarvoor.

Prof. Dr. F. C. M. Driessens, Dr. J. M. P. M. Borggreven en Dhr. R. Gorissen van de afdelingen Tandheelkundige Materialen en Biochemie M.W. van de Katholieke Universiteit Nijmegen. Hartelijk dank voor de goede en efficiënte samenwerking bij de diffusie- en impedantie-experimenten en voor de hulp bij het op schrift stellen van deze, wat mij betreft, zeer ingewikkelde materie.

Dr. J. A. K. M. Buskes, beste Hans. Hartelijk dank voor je begeleiding tijdens mijn eerste stappen 'in' jouw 'constant composition' apparaat en voor je hulp bij mijn eerste geschriften.

Dr. V. Fidler wil ik danken voor het uitvoeren van de statistische analyses bij het cariës onderzoek, waarvan U altijd zei dat het sneller was om ze zelf uit te voeren, dan om ze aan mij uit te leggen.

Prof. Dr. W. G. Perdok, beste professor. Hartelijk dank voor het uitvoeren van het röntgendiffractie onderzoek en de interpretatie van de gegevens.

Mw. I. Retief. Baie dankie vir die nougesetheid waarmee U die fluoridebepalings uitgevoer het.

Drs. D. M. Mehta en Dhr. A. A. Canrinus wil ik danken voor hun hulp bij het bestralen van de vele glazuurpreparaten, beter bekend als 'koeietanden' en de adviezen daaromtrent.

Dr. E. de Josselin de Jong, beste Elbert. Bedankt voor je microradiografische adviezen in de ontwikkelingfase van het cariësmodel.

Prof. Dr. J. Arends en Prof. Dr. J. J. ten Bosch. In de beginfase van mijn onderzoek heb ik veelvuldig gebruik mogen maken van het goed geoutilleerde laboratorium voor Materia Technica. Ik ben U beiden daarvoor zeer erkentelijk.

Dr. J. Bouma, beste Jelte. Jij hebt me wegwijs gemaakt in de wereld van het interview en de vragenlijst. Ik hoop dat je mij in de toekomst nog eens vaker iets wijs zult willen maken.

Drs. H. J. Guchelaar, beste Henk-Jan. Dank voor je hulp bij de ontwikkeling en verfijning van de samenstelling van de fluoride gel.

Dr. F. K. L. Spijkervet en Dr. J. L. N. Roodenburg, beste Fred en Jan. Hartelijk dank voor jullie expertise bij de ontwikkeling van het protocol. Fred wil ik in het bijzonder bedanken voor onze vele vruchtbare discussies die, hoewel vaak gramnegatief getint, voor mij een zeer positieve herinnering vormen.

De heren M. Hummel en A. Wietsma, beste Martin en Anne. Dankzij jullie vakmanschap leken mijn glazuurhouders wel van zwitserse makelij. Reuze bedankt.

Mw. L. E. Noordhof wil ik graag bedanken voor de hulp bij het opsporen van de vele, soms haast onvindbare, literatuur.

Dr. J. K. Tidwell, dear John. Thanks for the many fruitful discussions we had during the Arnhem period and for correcting parts of the English text.

Mw. M. A. de Jong, beste Mirabelle. Bedankt voor je correcties van mijn gebruik van ons Nederlands.

De heren P. van der Sijde, D. Huizinga, H. R. A. Meiborg, R. L. Dijkstra en H. R. Luurtsema wil ik bedanken voor de vele fraaie foto's die zij in de loop der jaren voor mij hebben gemaakt en waarvan een deel nu mijn proefschrift siert.

De heren H. Flanderijn en E. G. C. van Ommen, beste Henk en Erik. Zeer bedankt voor jullie professionele tekenwerk en voor het goede contact dat we er altijd over hadden.

Drs. G. Steensma en Drs. J. W. Braams, beste Gauke en Jan-Willem. Bedankt voor het kritisch doorlezen van de zetproeven. Dankzij jullie staan de puntjes nu op de i.

Mw. G. Boezerooy-Nobach, Mw. K. Wolhuis en Mw. E. van Drooge, beste Gerda, Karin en Ellen. Bedankt voor jullie secretariële en morele ondersteuning.

De medewerkers van alle Nederlandse afdelingen voor Radiotherapie en hun tandheelkundige teams wil ik graag bedanken voor hun spontane medewerking aan het inventarisatie onderzoek.

Alle medewerkers, waarvan enkele inmiddels ex-medewerkers, van de afdeling Mondziekten, Kaakchirurgie en Bijzondere Tandheelkunde, die hebben bijgedragen aan een prettige werksfeer en begrip toonden wanneer ik tijdens de experimenten en in de afrondingsfase af en toe eens verstek moest laten gaan, wil ik hartelijk bedanken.

Alle patiënten die geheel belangeloos hun medewerking verleenden aan mijn experimenten en bij wie ik vaak wekelijks zeer gastvrij werd onthaald, mijn hartelijke dank.

Mijn ouders, jullie dank ik dat jullie mij in de gelegenheid hebben gesteld om een universitaire opleiding te volgen en vooral voor de warme belangstelling en interesse die jullie steeds voor mijn bezigheden hebben getoond. Aan jullie draag ik daarom mijn proefschrift op.

Dionne. Het tot stand komen van dit proefschrift is niet in de laatste plaats ook jouw verdienste. Jij was mijn dagelijkse inspiratiebron en mijn belangrijkste co-auteur. Ik ben je zeer dankbaar voor je opgewektheid, je steun en al je geduld.

The research was carried out at the Department of Oral and Maxillofacial Surgery of the University Hospital Groningen in cooperation with the Laboratory for Materia Technica, the Department of Radiotherapy and the Laboratory for Histology and Cell Biology of the University of Groningen; the Daniel den Hoed Kliniek/Rotterdam Radiotherapeutic Institute; the Departments of Oral Biomaterials and Biochemistry of the University of Nijmegen and the Institute of Dental Research of the University of Alabama, U.S.A.





## Chapter 1

### INTRODUCTION AND AIMS OF THE INVESTIGATION

#### INTRODUCTION

Malignant tumors of the head and neck comprise all malignant tumors located above the level of the clavicles with the exception of those originating from the central nervous system. These tumors can be grouped according to the anatomic location and histology of the involved tissues and include: facial skin and lips, upper aero-digestive tract (nasal cavity, paranasal sinuses, oral cavity, pharynx, cervical oesophagus, larynx, trachea), salivary glands, thyroid and parathyroid glands, bone and soft tissues, orbits, and lymph nodes. Similarity in etiology, patterns of metastasis, diagnostics and treatment justify these malignant neoplasms to be put together in one group: head and neck cancer. The incidence of head and neck cancer (skin cancer excluded) in Western Europe and the U.S.A. is about 23/100,000 inhabitants, i.e. about 8% of all malignant tumors.<sup>1</sup> The tumors addressed in this thesis are especially those malignant tumors originating from the upper aero-digestive tract.

Malignant neoplasms in the head and neck region are often treated with a combination of surgery and radiotherapy, while malignant lymphomas in this area are usually treated with radiotherapy and/or chemotherapy.<sup>2</sup> In addition to anti-tumor effects, radiation also induces damage in normal tissues, irrespective of individual treatment plans and in spite of the improved tissue-sparing properties of modern radiation techniques. In patients with head and neck cancer, radiation treatment often involves the tissues of the oral cavity and the major and minor salivary glands as well as the jaws, either because of the location of the primary tumor or of the lymph node metastases.

Radiation injury of salivary glands, oral mucosa and jaws may lead to early or late occurring oral sequelae like xerostomia,<sup>3</sup> taste loss,<sup>4</sup> irradiation mucositis,<sup>4,5</sup> radiation caries,<sup>6,7</sup> soft-tissue necrosis and osteoradionecrosis of the jaw bone.<sup>8-10</sup> These sequelae form a heavy burden for these patients, may cause a lot of pain and distress during and after radiotherapy and may become dose-limiting. Similar oral sequelae (e.g. mucositis, hyposalivation) can be observed during a course of chemotherapy, but they have a more temporary character.<sup>11,12</sup>

There are many indications that oral sequelae resulting from head and neck radiotherapy can be prevented or reduced in severity.<sup>5,13-20</sup> As the prognosis for localized head and neck cancer and malignant lymphomas is relatively favorable, 5-year survival rates of 50% or more have been reported,<sup>21,22</sup> the dental and oral status of the patient should be considered with great care. Especially in cases of tumor control, irradiation-induced changes in oral and adjacent structures are major factors determining the patient's quality of life.

Concerning the prevention of radiation caries, only a few of the approaches reported in the literature are based on fundamental research.<sup>13,15,16</sup> These caries prophylactic regimens are inconvenient for the patient because of the lifelong need for daily fluoride applications. This implies a risk of compliance failure leading to increased caries activity. Preservation of a healthy dentition is a matter of increasing significance since the number of (aged) dentulous patients and the dental mindedness in developed countries is increasing considerably. Optimization of radiation caries prevention as one of the main missing links in a proper overall protocol for the prevention and treatment of oral sequelae resulting from head and neck radiotherapy is therefore a major subject of this thesis.

## AIMS OF THE INVESTIGATION

The general aim of this thesis is to study the course and prevention of radiation caries and to propose an overall protocol for the prevention and treatment of oral sequelae resulting from head and neck radiotherapy. The specific aims are:

- *to review the literature regarding the effects of ionizing irradiation on normal tissues in the head and neck region, the resulting sequelae and their prevention and treatment, specifically to develop an overall preventive protocol (chapter 2).*  
Radiation treatment in the head and neck region may cause many changes in normal tissues resulting in e.g. mucositis, hyposalivation and radiation caries. Knowledge of these sequelae as well as their prevention and treatment is essential to develop a proper preventive protocol (chapter 5).
- *to study the course and prevention of radiation caries (chapter 3).*  
Irradiation-induced hyposalivation, the resulting changes in the composition of saliva and oral flora and the altered dietary habits are all agreed upon *indirect* factors contributing to an increased caries susceptibility after radiotherapy. The *direct* effect of ionizing irradiation on the (in)organic components of dental enamel is unclear. Furthermore, there is no proper model known in the literature suitable to study the development and prevention of radiation caries. The following *in vitro* and *in situ* studies were performed:
  - studies on the direct effects of ionizing irradiation on the acid solubility and permeability of dental enamel;
  - development of an *in situ* model for studying the onset, progression and prevention of radiation caries as a function of time;
  - comparison of the initiation and progression of induced radiation caries with those of natural radiation caries;
  - study on the prevention of radiation caries by evaluating the effects of different fluoride concentrations and application procedures.
- *to survey the prevention and treatment regimens of oral sequelae resulting from head and neck radiotherapy applied in all radiotherapy institutes in the Netherlands and to evaluate the differences in these regimens (chapter 4).*

Most prevention procedures described in the literature are based on clinical experience. The result is a great diversity in policies, which may lead to a variety in the preventive approach in daily practice. To study this assumption a survey of the preventive regimens applied in all Dutch radiotherapy institutes was performed. A survey of these regimens is needed to determine what caries prophylactic methods and other preventive measures are used in a clinical setting as well as to assess the need for the development of an overall protocol for the prevention and treatment of oral complications of head and neck radiotherapy. This survey was not intended to evaluate the effects of the various regimens in the patient situation.

- *to develop an overall protocol for the prevention and treatment of oral sequelae resulting from head and neck radiotherapy (chapter 5).*

When covering the subject of radiation caries it is difficult to look at this side effect as a single entity without taking into account other side effects. Hyposalivation, mucositis and trismus all directly interfere with the oral status, the well-being, the degree of oral hygiene and the dietary habits of the patient and emphasize the need for an overall prevention and treatment protocol. Furthermore, such a protocol can be a major tool in the prevention of acute exacerbation of foci of infection and the prevention of osteoradionecrosis. A scientific basis for the development of a feasible overall protocol for the prevention and treatment of oral sequelae resulting from head and neck radiotherapy is formed by the hyposalivation studies of Vissink,<sup>18</sup> the mucositis studies of Spijkervet<sup>20</sup> and the radiation caries studies described in this thesis in combination with data derived from the literature (chapter 2).

## REFERENCES

- 1 Vermey A, Oldhoff J, Panders AK. Hoofd-hals oncologie. In: de Boer J, Derom F, Gruwez JA, Kuijter PJ, den Otter G, Zwaveling A, eds. *Leerboek chirurgie* 3rd ed. Bohn, Scheltema & Holkema, Utrecht/Antwerpen 1988, 556–570.
- 2 Al-Sarraf M. Chemotherapeutic management of head and neck neoplasia. In: Peterson DE, Elias EG, Sonis ST, eds. *Head and neck management of the cancer patient*. Martinus Nijhoff, Boston 1986,299-330.
- 3 Dreizen S, Brown LR, Handler S, Levy BM. Radiation induced xerostomia in cancer patients. Effect on salivary and serum electrolytes. *Cancer* 1976;38:273–278.
- 4 Beumer J, Curtis T, Harrison RE. Radiation therapy of the oral cavity: Sequelae and management. Part I. *Head Neck Surg* 1979;1:301–312.
- 5 Lockhart PB. Oral complications of radiation therapy. In: Peterson DE, Elias EG, Sonis ST, eds. *Head and neck management of the cancer patient*. Martinus Nijhoff, Boston 1986,429–449.
- 6 Frank RM, Herdly J, Philippe E. Acquired dental defects and salivary gland lesions after irradiation for carcinoma. *J Am Dent Assoc* 1965;70:868–883.
- 7 Karmiol M, Walsh RF. Dental caries after radiotherapy of the oral regions. *J Am Dent Assoc* 1975;91: 838–845.
- 8 Murray CG, Herson J, Daly TE, Zimmerman S. Radiation necrosis of the mandible: a 10-year study. Part I. Factors influencing the onset of necrosis. *Int J Radiat Oncol Biol Phys* 1980;6:543–548.
- 9 Murray CG, Herson J, Daly TE, Zimmerman S. Radiation necrosis of the mandible: a 10-year study. Part II. Dental factors, onset, duration and management of necrosis. *Int J Radiat Oncol Biol Phys* 1980;6:549–553.
- 10 Marx RE. Osteoradionecrosis. A new concept of its pathophysiology. *J Oral Maxillofac Surg* 1983;41: 283–288.

- 11 Sonis ST, Sonis AL, Lieberman A. Oral complications in patients receiving treatment for malignancies other than the head and neck. *J Am Dent Assoc* 1978;97:468–472.
- 12 Dreizen S, McCredie KB, Bodey GP, Keating MJ. Quantitative analysis of the oral complications of antileukemia chemotherapy. *Oral Surg Oral Med Oral Pathol* 1986;62:650–653.
- 13 Daly TE, Drane JB, MacComb WS. Management of problems of the teeth and jaw in patients undergoing irradiation. *Am J Surg* 1972;124:539–542.
- 14 Keys HM, McCasland JP. Techniques and results of a comprehensive dental care program in head and neck cancer patients. *Int J Radiat Oncol Biol Phys* 1976;1:859–865.
- 15 Dreizen S, Brown LR, Daly TE, Drane JB. Prevention of xerostomia-related dental caries in irradiated cancer patients. *J Dent Res* 1977;56:99–104.
- 16 Horiot JC, Schraub S, Bone MC, Bain Y, Ramadier J, Chaplain G, Nabid N, Thevenot B, Bransfield D. Dental preservation in patients irradiated for head and neck tumours: A 10-year experience with topical fluoride and a randomized trial between two fluoridation methods. *Radiother Oncol* 1983;1:77–82.
- 17 Toljanic JA, Saunders VW. Radiation therapy and management of the irradiated patient. *J Prosthet Dent* 1984;52:852–858.
- 18 Vissink A. Xerostomia. Development, properties and application of a mucin-containing saliva substitute; thesis Groningen, 1985.
- 19 Wright WE, Haller M, Harlow SA, Pizzo PA. An oral disease program for patients receiving radiation and chemotherapy. *J Am Dent Assoc* 1985;110:43–47.
- 20 Spijkervet FKL. Irradiation mucositis and oral flora. Reduction of mucositis by selective elimination of oral flora; thesis Groningen, 1989.
- 21 Hakulinen T, Pukkala E, Hakama M, Lehtonen M, Saxn, E, Teppo L. Survival of cancer patients in Finland in 1953-1974. *Ann Clin Res* 1981;13:Suppl 31,101–105.
- 22 Sonis ST. Cancer, its complications, and the head and neck. In: Peterson DE, Elias EG, Sonis ST, eds. *Head and neck management of the cancer patient*. Martinus Nijhoff, Boston 1986,3–15.

## Chapter 2

### REVIEW OF THE LITERATURE

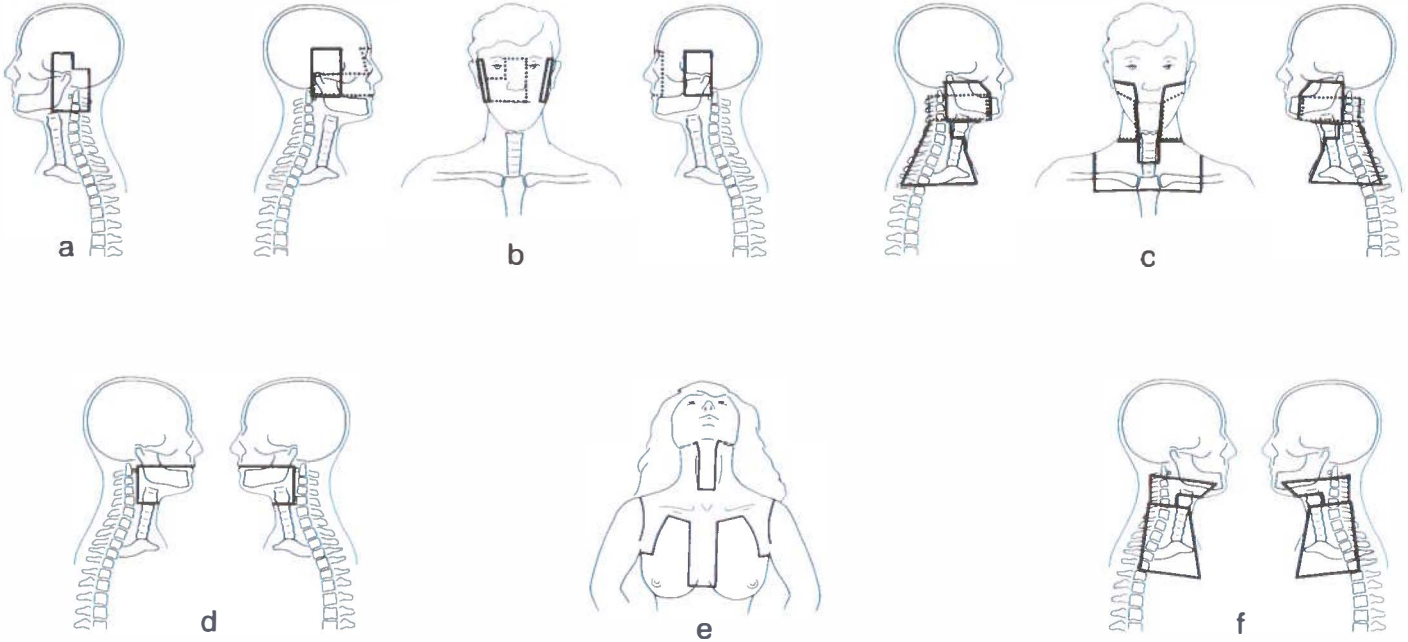
#### INTRODUCTION

In addition to anti-tumor effects, ionizing irradiation causes damage in normal tissues located in the field of radiation. The oral complications of radiotherapy in the head and neck region are the result of the deleterious effects of irradiation on e.g. salivary glands, oral mucosa, bone, dentition, masticatory musculature and temporomandibular joints (TMJ). The clinical consequences of radiation treatment include mucositis, hyposalivation, taste loss, osteoradionecrosis, radiation caries and trismus. Mucositis and taste loss are reversible consequences that usually subside early post-irradiation while hyposalivation is normally an irreversible effect. Furthermore, the risk of developing radiation caries and osteoradionecrosis are life-long threats. All these consequences form a heavy burden for the patients and have a tremendous impact on their quality of life during and after radiotherapy.

In this chapter the role of radiation treatment in head and neck oncology, the irradiation-induced changes in normal oral tissues, the resulting clinical consequences, and the possibilities for prevention and treatment of these consequences are reviewed. The irradiation-related changes in the oral mucosa, salivary glands, dentition, periodontium, bone, muscles and joints are described in that order.

#### RADIATION TREATMENT

Radiation treatment plays an important role in the management of head and neck cancer. According to Rothwell approximately 50% of all new cases of invasive head and neck cancer will need radiation therapy as a primary treatment, as palliation, or as an adjunct to surgery or chemotherapy.<sup>1</sup> Low energy, superficial (50–140 kV) and orthovoltage (140–500 kV) irradiation, is used in the treatment of skin and other superficial tumors, whereas high energy external beam irradiation (500 kV–20 MV) including cobalt-60 irradiation and megavoltage irradiation produced by linear accelerators (8–20 MV photons, 4–20 MeV electrons) and internal irradiation are used in the treatment of deeper located malignancies.<sup>2</sup> Important advantages of high energy irradiation as compared to low energy irradiation in the treatment of head and neck cancer are: reduced absorption in bone, less damage to the skin and reduced scatter of radiation into other body tissues. The result is a decrease of the incidence and severity of head and neck complications.<sup>3</sup> The advantage of internal radiotherapy (interstitial or intracavitary with radium needles, radon seeds and other radioactive elements such as cesium and iridium) is that



**Fig. 1** Common fields of radiation therapy for head and neck tumors are shown schematically by solid lines. Dotted lines indicate fields when increased dosages are used. **A** Parotid field. **B** Antrum field. **C** Oropharynx field. **D** Floor of mouth field. **E** Mantle fields for Hodgkin disease. **F** Fields for lymphatics of the neck.<sup>80</sup>

there is a high irradiation dose directed to the tumor without a high dose to the surrounding tissues. Internal irradiation may be used for the total treatment or in combination with external irradiation.<sup>4</sup>

The radiation dose needed for the treatment of cancer is based on location and type of malignancy, and whether or not radiotherapy will be used solely or as a pre- or postsurgical treatment modality.

Most patients with head and neck carcinomas receive between 50 and 70 Gy (1 Gy = 1 J/kg = 100 rad) as a curative dose. This dose is usually given over a five to seven week period, once a day, five days a week, with a daily tumor dose of about 2 Gy. The advantages of fractionated irradiation in contrast with single dose treatment are that time is allowed for healthy tissues to repair and repopulate and for the tumor to 'shrink' slowly, enabling reoxygenation and redistribution of the hypoxic tumor cell fraction and therefore more efficient treatment.<sup>4</sup> In case of pre-operative irradiation or irradiation for malignant lymphomas usually lower total doses are used.<sup>5,6</sup>

Because of the location of the primary tumor and regional lymph nodes, the oral cavity, salivary glands and jaws of most head and neck cancer patients are in the field of radiation (Fig. 1). As a result, unwanted radiation induced changes will occur in these tissues. An important limiting factor in tumor irradiation is the radiation dose that adjacent normal tissues can tolerate. Tissues with rapid turnover rates show acute reactions to irradiation (early effects), while in tissues with slower turnover rates damage may not become evident for months or years after therapy (late effects).<sup>7</sup>

## **ORAL CONSEQUENCES OF HEAD AND NECK RADIOTHERAPY**

### **Oral mucosa**

The damage to the oral mucosa in the path of radiation depends upon the total irradiation dose, volume of irradiated tissue, fractionation and type of ionizing irradiation.<sup>4,8</sup> As mucosal cells turn over rapidly, they have a low resistance to radiation. Oral side effects following therapeutic irradiation therefore develop quickly.<sup>9</sup>

Mucositis induced by irradiation is defined as the reactive inflammatory-like process of the oropharyngeal mucous membrane during therapeutic head and neck irradiation. Irradiation mucositis is an inevitable but transient side effect.<sup>4,10,11</sup> It is an integral part of the radiation therapy in terms of morbidity. The early radiation reaction causes local discomfort as well as difficulties in drinking, eating, swallowing and speech. Therefore it can give rise to nutritional problems and in severe cases nasogastric feeding may become necessary, which is very uncomfortable.<sup>12,13</sup> Severe mucositis may necessitate an interruption of the course of radiation treatment and thus can serve as a dose-limiting factor.<sup>1,3</sup> Such interruptions must be



prevented because they may result in prolongation of treatment and reduction in therapeutic effect.<sup>14,15</sup>

Various signs of mucositis may emerge during radiotherapy.<sup>3,13,16,17</sup> The first clinical signs of mucositis occur at the end of the first week of a conventional six week radiation protocol (daily dose of 2 Gy, five times a week). There is no consensus regarding what is the first sign of mucositis. Some authors describe a white discoloration of the oral mucosa, which is an expression of hyperkeratinization as the first symptom, followed by or in combination with erythema.<sup>18-20</sup> Others consider erythema, due to vascular dilatation (hyperaemia) or obstructive changes in arterioles, to be the first reaction.<sup>8,21,22</sup> As radiation therapy progresses, superficial cells are no longer replaced because irradiation-induced cell loss in the basal cell layer exceeds the proliferation of new cells, and the mucosa becomes thin, red and friable.<sup>20</sup> Vascular dilatation and edema of the submucosa lead to further weakening of the oral mucosa and can provoke an epithelial breakdown.<sup>3</sup> After about three weeks of irradiation more severe symptoms of mucositis such as the formation of pseudomembranes and ulcerations may appear.<sup>21,22</sup> Some authors consider pseudomembranes to be ulcers covered by fibrinous exudate.<sup>3,21</sup> Others suggest pseudomembranes to be related to yeast stomatitis<sup>19</sup> or to colonization of the oral cavity with gram-negative bacilli.<sup>17</sup> Mucosal ulcerations can occur either spontaneously or secondary to minor trauma from teeth, prosthetic appliances and abrasive foods.<sup>3</sup> Mucositis generally persists throughout radiotherapy, is at its maximum at the end of the irradiation period, and continues for one to two weeks after treatment has ceased.<sup>1,20,23</sup>

The severity of mucositis varies considerably between patients. Furthermore, the mucosa of the oral cavity does not react in the same manner at all locations. Mucositis is most severe in the soft palate, followed in order by the mucosa of the hypopharynx, the floor of the mouth, the cheek, the base of the tongue and the dorsum of the tongue. Patients with compromised oral mucous membranes secondary to alcoholism and/or excessive smoking exhibit the most severe mucosal changes.<sup>13</sup>

After radiotherapy, there are significant changes within the field of radiation that predispose to tissue breakdown and delayed healing. These late irradiation-induced changes in the oral mucosa are thought to be primarily due to damaged microvascular structures and connective tissue.<sup>16,24</sup> The thin atrophic and relatively avascular mucous membranes are hypersensitive to trauma and infection and make tolerance of wearing a prosthesis more difficult.<sup>2,25</sup> Minimal trauma can result in ulcerations that often take months to heal and occasionally lead to exposure of bone. Recovery from minor oral surgery procedures and tooth extraction is prolonged.<sup>16</sup>

Most authors agree that mucositis in patients with head and neck cancer is basically a tissue reaction due to the trauma of irradiation.<sup>4,16,26</sup> Until recently, the contribution of an increase in the carriage rate of gram-negative bacilli in the oropharynx (*Enterobacteriaceae*, *Pseudomonaceae*, *Acinetobacter* species) to the development of mucositis had not been elucidated.<sup>2,27-29</sup> Less than 10% of healthy individuals are colonized in the oral cavity with these non-indigenous gram-negative



bacilli.<sup>30</sup> This is due to oropharyngeal colonization defence which is determined by: integrity of the anatomical structures, physiology, motility, secretions, secretory immunoglobulin A, mucosal cell turnover and the indigenous flora. These factors are impaired by therapeutic irradiation for head and neck cancer and are negatively influenced by more generalized factors such as advanced age, medical interventions (e.g. surgery) and underlying disease.<sup>31</sup> Spijkervet et al.<sup>32,33</sup> observed in a clinical study that selective elimination of gram-negative bacilli was associated with the prevention of pseudomembranes and ulcerations. In this study it was postulated that gram-negative bacilli or endotoxin released by gram-negative bacilli could play a major role in the development of the advanced stages of irradiation mucositis, while the initial signs are basically related to irradiation only. This finding seems to be of great importance in terms of mucositis prevention.

The most common infection in the oral cavity during or shortly after radiation therapy is candidiasis.<sup>34</sup> It has been observed that many patients become intra-orally colonized with *Candida albicans* during radiotherapy.<sup>28,35</sup> In a study by Silverman et al. it was found that the number of patients with positive *Candida* cultures increased from 22% before radiation treatment to 49% at the end of therapy and to 59% during the follow up period.<sup>36</sup> The increased incidence of oral candidiasis is related to hyposalivation and the altered salivary composition. An increase in *Candida* species is particularly apparent in denture wearers.<sup>20,29,35</sup> Recent data from in vitro studies suggest that enterobacteria such as *Klebsiella* and *Escherichia coli* promote yeast colonisation on epithelial surfaces. These data are of interest because the gram-negative bacilli co-exist with yeasts in many head and neck cancer patients treated with high radiation dosages.<sup>37</sup> According to Martin et al. yeast colonization remains increased until approximately six months after radiotherapy.<sup>38</sup> Some authors believe that oral mucositis is aggravated by fungal infections.<sup>13,23</sup> Martin et al.,<sup>38</sup> Chen and Webster<sup>35</sup> and Pau et al.<sup>39</sup> showed, however, that the severity of irradiation mucositis was not influenced by *Candida* species. Furthermore, it should be mentioned that herpes simplex virus infection is not a significant contributing factor in irradiation mucositis, this in contrast to the commonly seen herpes simplex virus reactivation in chemotherapy patients.<sup>40</sup>

### Salivary glands

The parotid, submandibular and sublingual salivary glands contain serous cells, serous and mucous cells, and mucous cells, respectively. These major glands produce over 90% of the salivary flow and the minor salivary glands account for the remainder. In non-stimulated situations the submandibular glands produce about 70% of the total flow. Stimulation results in an increased contribution of the parotid gland. At moderate flow rates, the parotid secretion accounts for half of all salivary output, while at high flow rates it can account for two-thirds of the secretory production.<sup>41-43</sup>

Based on the slow turnover rates of their cells the salivary glands are expected to be relatively radioresistant.<sup>44</sup> Yet, the changes in quantity and composition of saliva

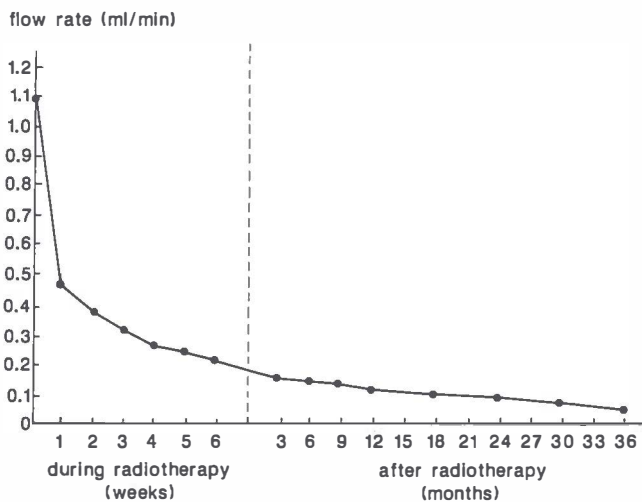


Fig. 2 Average flow rates of whole saliva in 42 patients with oral cancer in response to masticatory stimulation before, during and after radiotherapy.<sup>21</sup>

that occur shortly after irradiation indicate that the gland tissue is acutely radiosensitive, at least in a functional context.<sup>13</sup> It is not clear whether irradiation damage of salivary gland tissue is caused by the direct effects of radiation on the secretory and ductal cells, or that it is secondary to injury of the fine vascular structures, increased capillary permeability, interstitial edema and inflammatory infiltrations.<sup>4</sup> Early in the radiation treatment period, there is edema as well as infiltration of the interlobular connective tissue with lymphocytes and plasma cells. As treatment continues, there is progressive degeneration of the acinar epithelium and development of interstitial fibrosis. Serous acinar cells appear to be more readily affected by irradiation than mucous acinar cells and ductal cells.<sup>24,26,45,46</sup> However, based on comparison of in vivo and in vitro results, Stephens et al. concluded from experiments with primates that the acute functional impairment is caused directly by serous acinar cell death rather than being the result of inflammatory processes and circulatory compromise due to vascular injury.<sup>47</sup> The cytoplasmic membrane is the likely target of radiation injury according to these authors. Furthermore, there are some indications from animal studies that the granulation level of serous cells just prior to irradiation is a major factor determining the radiosensitivity of these cells.<sup>48,49</sup>

Depending on the localization of the radiation field, a rapid decrease of the salivary flow rate is observed during the first week of radiation treatment, after which there is a gradual decrease to about 5% of the initial flow rate (Fig. 2).<sup>50-53</sup> The final degree of irradiation-induced hyposalivation depends on individual patient characteristics such as pre-irradiation salivary gland activity, age and sex.<sup>54,55</sup> Salivary glands with high flow rates before starting radiotherapy show less reduction of the salivary flow rate.<sup>55-57</sup> Clinically of more importance is the volume of salivary gland

tissue that is irradiated, because this volume correlates directly with the severity of oral complications.<sup>2,58,59</sup> Mira et al. reported that the level of the upper border of the radiation field is an important factor for the post-irradiation level of salivary secretion.<sup>55</sup> More than 50% of the parotid glands need to be outside the treatment portals to prevent severe dryness of the mouth.<sup>55,60</sup> Irradiation of submandibular and sublingual glands, while sparing most parotid tissue, rarely causes the problem of severe hyposalivation even though these glands are the major sources of resting saliva secretion<sup>55,61</sup> and even though it has recently been found that the submandibular gland function is permanently impeded after irradiation.<sup>62</sup> In case of cumulative doses larger than approximately 40 Gy, the early loss of salivary gland function is usually permanent (Table 1). Liu et al. recently found a significant reduction in salivary flow even 18 years after mantle field radiation with cumulative dosages of 27 to 40 Gy (cobalt 60 source).<sup>59</sup> Partial recovery of salivary flow has been reported up to eight months after radiotherapy and is dependent upon the age of the patient, the radiation field and the radiation dose.<sup>13,56,63,64</sup>

**Table 1** Relationship between radiation dose and clinical symptoms (all salivary glands within the treatment portals; radiation dose: 2 Gy/day, 5 times/week)<sup>47:163:335-337</sup>

Dosage	Symptom
<10 Gy	transient reduction of salivary flow
10–15 Gy	clinically clearly demonstrable hyposalivation
15–40 Gy	further reduction of the salivary flow, mostly reversible
>40 Gy	irreversible damage to the glandular parenchyma, followed by atrophy and fibrosis; frequently irreversible hyposalivation

Aside from the quantity of saliva, irradiation also results in a change of the salivary composition. Saliva becomes a very viscous, white, yellow or brown fluid.<sup>3,51,65</sup> The obvious qualitative salivary changes are a reduced pH and buffering capacity, changed salivary electrolyte levels, and changed nonimmune and immune antibacterial systems. The average pH decreases from about 7.0 to 5.0.<sup>51,65</sup> The reduced buffering capacity is primarily due to a reduction of bicarbonate concentration in parotid saliva.<sup>51,66</sup> An increase in the concentrations of sodium, chloride, calcium and magnesium is reported, while the concentration of potassium varies only slightly.<sup>51,62,65,67</sup> The concentrations of immunoproteins (e.g. sIgA) and lysozyme per unit volume of saliva are increased.<sup>68-71</sup> The decrease of salivary flow rate is, however, larger than the increase in immunoprotein and lysozyme levels thus resulting in a significant immunoprotein deficit. Since oral clearance and immunologic mechanisms are potent means of host protection, their compromise is intrinsically related to changes in the oral flora as seen in irradiated patients.<sup>13,27</sup> One of the major irradiation-induced changes in the oral flora is a pronounced increase in acidogenic, cariogenic micro-organisms at the expense of non-cariogenic micro-organisms. The most clinically significant changes are the increase of *Streptococcus*

**Table 2** Consequences of radiation-induced hyposalivation<sup>163</sup>

---

Dryness of the mouth	Burning sensation
Thirst	Taste disturbances
Difficulties in oral functioning	Alterations of soft tissues
Difficulties in wearing dentures	Shift in oral microflora
Nocturnal oral discomfort	Radiation caries
Mucus accumulation	Periodontal disease

---

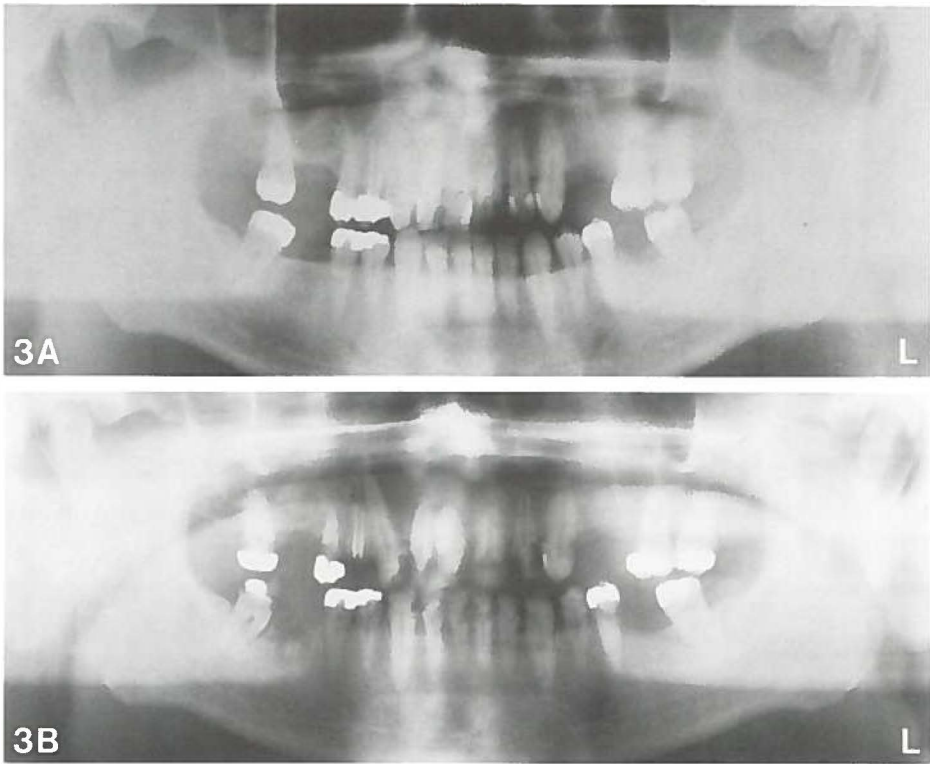*mutans*, *Lactobacillus* species and *Candida* species.<sup>27,69,72-75</sup> The major changes in the oral flora as a result of hyposalivation after radiotherapy are observed in the period from the onset of radiation treatment to six months after completion. Compared to the initial composition, the maximum change is observed between three and six months after irradiation. From that moment on, the composition of the oral flora remains constant or partially returns to the initial situation.<sup>69</sup>

The quantitative and qualitative salivary changes predispose the irradiated patient to a variety of problems that develop either directly or as an indirect result of the diminished salivary output. In Table 2 a general outline of the consequences of irradiation-induced hyposalivation is given. Oral functioning (speech, chewing and swallowing) is hindered because of e.g. insufficient wetting and lubrication of the mucosal surfaces. Moreover, swallowing and chewing are impeded because of insufficient moistening of food by saliva. The increased viscosity and reduced flow of saliva cause intolerance to prosthetic appliances.<sup>1</sup> Saliva is an effective lubricant at the denture-mucosal interface. With lesser amounts of saliva present, retention of the denture is poor and more friction is produced during functioning, which may easily traumatize the vulnerable irradiated oral mucosa.<sup>13,76</sup>

Many patients suffer from nocturnal oral discomfort.<sup>77</sup> They are often awakened by a serious dryness of the mouth or have to get up frequently because of polyuria due to polydipsia throughout the day. The oral mucosa can have a dry, atrophic, pale or hyperemic appearance. The mucosa of the tongue can show the same aspect or can be fissured. The lips may be dry, cracked or fissured. These changes in the oral mucosa are in general typical for xerostomia of any origin.<sup>78</sup> The shift in oral flora towards cariogenic bacteria, the reduced salivary flow (oral clearance) and the changed saliva composition (buffer capacity, pH, immunoproteins, oral clearance) may result in rapidly progressing radiation caries, along with a greater incidence of periodontal infections. The caries susceptibility is further increased by altered eating habits. Due to the radiation mediated changes such as mucositis, atrophy of oral mucous membranes, hyposalivation and taste loss, the diet of irradiated patients shifts to softer, sticky, carbohydrate rich foods with an increase in the frequency of intake, thus promoting caries.<sup>51,79</sup>

### **Dentition**

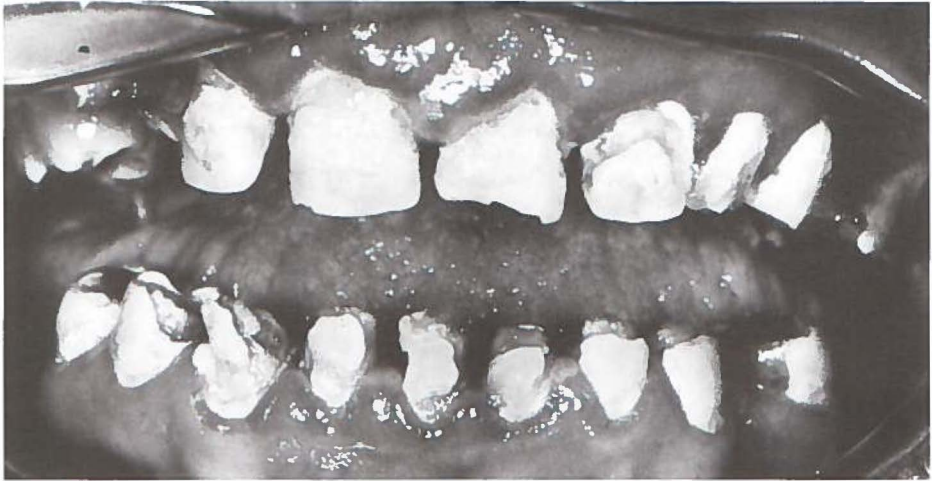During and following a full-course of radiation treatment many patients experience an increased dental sensitivity to temperature changes and to sweet and sour



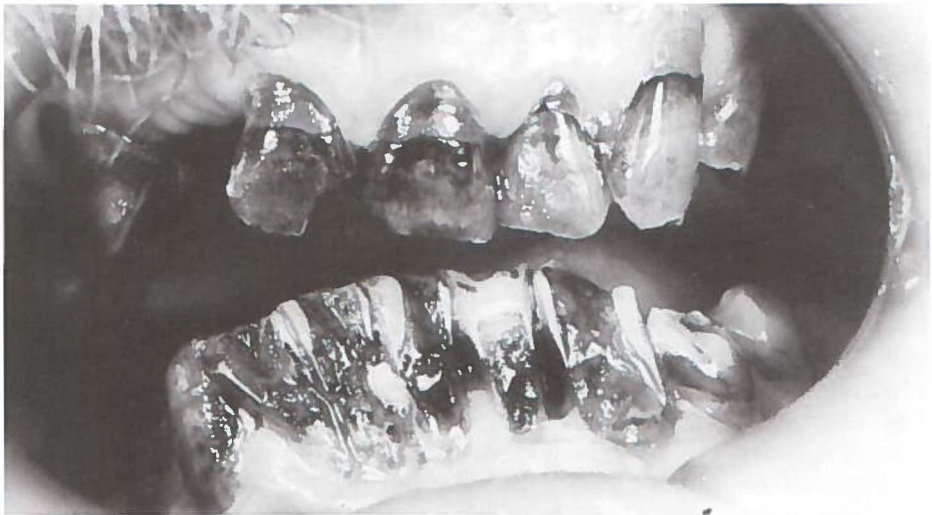**Fig. 3** Panoramic radiographs of a patient who developed severe radiation caries due to neglect and noncompliance. **A** Pre-irradiation situation. **B** Nine months post-irradiation. Note the extensive cervical lesions.

tasting foods.<sup>13,80,81</sup> A possible explanation is the loss of the protective layer of saliva.<sup>80,82</sup> The most threatening complication for the dentition, however, is radiation caries. Radiation caries is a highly destructive form of dental caries which has a rapid onset and progression.<sup>83</sup> Dental caries may become evident as early as three months following the initiation of radiotherapy. In severe cases, a previously healthy dentition can be lost within one year (Fig. 3).<sup>84</sup>

Clinically, three types of carious lesions can be observed. The *first* type is a frequently observed lesion that starts on the labial surface of the cervical area of the incisors and canines (Fig. 4). Initially the lesion extends superficially around the entire cervical area of the tooth and then progresses inwardly often resulting in complete amputation of the crown. In the region of the molars complete amputation of the tooth occurs less frequently, however, the caries tends to spread over all surfaces of the molar with changes in translucency and color leading to increased friability and breakdown of the tooth. Occasionally, only a rapid wearing away of the incisal and occlusal surfaces of the teeth is seen either with or without cervical lesions.



**Fig. 4** Clinical example of a characteristic type of radiation caries. Carious lesions are predominantly observed in the cervical and incisal regions.



**Fig. 5** Clinical example of a brown-black discoloration of entire tooth crowns ('ebony' teeth).

The *second* type of lesion is a generalized superficial defect that first affects the buccal and later the lingual or palatal surfaces of the tooth crowns. The proximal surfaces are less affected. This lesion often begins as a diffuse, punctate defect and then progresses to generalized, irregular erosion of the tooth surfaces. In this type of lesion, decay localized at the incisal or occlusal edges is often observed. The result is a destruction of the coronal enamel and dentin, especially on the buccal and palatal surfaces.



The *third* type is less frequently observed (Fig. 5). It consists of a heavy brown-black discoloration of the entire tooth crown, accompanied by wearing away of the incisal and occlusal surfaces.<sup>83,85-87</sup> All three types of lesions can be observed within the same mouth.<sup>88</sup> In view of the rapid progression it is surprising that there is rarely any acute pain associated with radiation caries even in its most severe manifestations.<sup>88,89</sup>

Besides the rapid onset and progression, radiation caries is most commonly found on tooth surfaces (buccal, labial, lingual, palatal, incisal, occlusal) that are normally relatively immune to dental caries. The areas just below the contact points seem to be the last areas to be affected by radiation caries. In healthy subjects these areas are very susceptible to ordinary smooth-surface dental caries. Furthermore, the mandibular anterior teeth, which under normal conditions are the teeth most resistant to caries, are equally if not more affected by radiation caries.<sup>87</sup> The characteristic attack on normally caries immune, self-cleansing areas, may be caused by the altered oral environment produced by changes in salivary flow and consistency that give rise to accumulation of highly acidogenic dental plaque on these surfaces, producing rapid decalcification of enamel.<sup>87</sup> Similar destructive lesions of teeth have been described with hyposalivation associated with Sjögren's syndrome<sup>90</sup> and in cases of congenital dysfunction of the major salivary glands.<sup>91</sup>

The morphological characteristics of radiation caries are scarcely reviewed in the literature.<sup>83,92,93</sup> Histological features of the initial radiation caries lesions are similar to those observed in normal incipient dental caries lesions.<sup>93,94</sup>

It has always been a matter of debate whether radiation caries is due to a direct or indirect effect of irradiation on teeth, or to both. Several investigators reported that the development of radiation caries was not dependent on the presence of teeth in the field of irradiation,<sup>83,85,87</sup> but that the determining factor was whether the main salivary glands were within the radiation field.<sup>51,54,68,79</sup> The current opinion is that radiation caries is due to salivary gland damage resulting in hyposalivation.<sup>52,83,84</sup> Hyposalivation-related alterations in microbial, chemical, immunologic and dietary parameters of cariogenicity, thus collectively, contribute to an enormous increase in the caries challenge in irradiated patients.<sup>21,84</sup>

Whether a direct effect of irradiation on teeth also contributes to the development of radiation caries has not been fully elucidated, and reports are contradictory. Irradiation *in vitro* with 10,000 Gy, either as a single dose or cumulatively, results in changes in the crystalline structure of enamel.<sup>95</sup> Wiemann et al.<sup>96</sup> and Zach,<sup>97</sup> however, found no structural changes after irradiation at a therapeutic level. Some investigators have reported that irradiated teeth decalcify more readily than non-irradiated teeth<sup>98</sup> while others noted no differences in decalcification rates *in vitro*.<sup>96,99,100</sup> Joyston-Bechal<sup>101</sup> and Markitziu et al.<sup>102</sup> reported a decrease of enamel acid solubility after irradiation. Some authors suggest that irradiation may cause denaturation of the organic matrix of enamel and dentin which can be followed by dissolution of the calcified component.<sup>103-106</sup> No studies on the effect of irradiation on the organic matrix of enamel have been reported to date.

Many studies have been conducted to determine the effect of therapeutic irra-

diation on the dental pulp and the developing tooth. Some investigators demonstrated odontoblastic and reticular atrophy,<sup>103,106,107</sup> while others could not observe changes in the odontoblastic layer.<sup>83,108,109</sup> Abnormal tooth deposits, with excessive formation of osteodentin by odontoblasts, have been observed in several studies.<sup>107,110-113</sup> Most investigators agree that the pulp shows a decrease in vascularity with fibrosis and atrophy.<sup>106,107,112</sup> According to Anneroth et al. metaplastic fibrous transformation of pulp tissue and secondary formation of dentin and cementum are more likely a reaction to caries or previous dental treatment than a manifestation of irradiation damage.<sup>92</sup>

High levels of radiation exposure can markedly affect tooth development. The extent of the effect is dependent on the radiation dose and the stage of tooth development.<sup>106,114,115</sup> Most investigators agree that odontogenic cells in the preformative and differentiation phases are more radiosensitive than cells in the secretory or mature stage.<sup>110</sup> If exposure to irradiation occurs before calcification, the tooth bud may be destroyed. Radiation at a later stage of development may arrest further growth and result in irregularities in enamel and dentin together with shortened roots.<sup>106,110,113,114,116,117</sup> According to Scheibe et al. tooth eruption is mostly delayed but not hindered.<sup>117</sup>

## **Periodontium**

Analogous to the teeth, the effect of irradiation on the periodontium can be divided into direct and indirect effects. Decreased vascularity and acellularity of the periodontal membrane with rupturing, thickening and disorientation of Sharpey's fibers and widening of the periodontal space have been reported after irradiation.<sup>92,118-120</sup> Others, however, found normal alignment of periodontal fibers.<sup>117</sup> The cementum appears completely acellular and its capacity for repair and regeneration is severely compromised.<sup>13,118</sup> Some authors consider the changes in cementum and periodontal ligament to predispose to infection.<sup>13,22,121,122</sup> The risk of periodontal infection is also increased due to radiation induced hyposalivation with increased plaque accumulation and a shift in oral flora. Among others, *Actinomyces naeslundii*, which has been reported to be associated with periodontal disease and root caries, is increased after irradiation.<sup>74</sup>

## **Bone**

Irradiation-induced changes in bone are comparable to those observed in soft tissues. With megavoltage irradiation, bone absorbs the same dose of radiation (Gy) per unit mass as does soft tissue. However, since bone is 1.8 times as electron dense as soft tissue, it absorbs a larger proportion of radiation per unit volume than does soft tissue.<sup>4,13</sup> The gross changes in the matrix of bone after irradiation develop relatively slowly. The initial changes in bone result from injury to the remodeling system (osteocytes, osteoblasts, osteoclasts). Osteoblasts tend to be more radiosensitive than osteoclasts, thus a relative increase in the lytic activity



may occur.<sup>16</sup> Whether the altered bone remodeling activity is the result of direct irradiation injury to the cells of the remodeling system or the indirect result of irradiation-induced vascular injury, or a combination of both phenomena, is still a matter of debate. Radiation injury to the fine vasculature of bone and its surrounding tissues first leads to hyperaemia, followed by endarteritis, thrombosis and a progressive occlusion and obliteration of small vessels. Within bone this results in a further reduction of the number of cells and in progressive fibrosis. With time the marrow exhibits marked acellularity and hypo- or avascularity, with significant fibrosis and fatty degeneration. Some lacunae may become devoid of osteocytes. The endosteum atrophies with significant loss of active osteoblasts and osteoclasts. The periosteum demonstrates significant fibrosis with a similar loss of remodeling elements.<sup>3,13,16,21,118</sup> Marx and Johnson found hypovascularity and fibrosis to be the common end stage of irradiation-induced tissue injury.<sup>123</sup> Considering these facts it is obvious that irradiated bone renders a poor response to trauma and infection.

The most severe potential complication threatening irradiated bone is osteoradionecrosis. The definition of osteoradionecrosis is bone death due to radiation.<sup>123</sup> There is little consistency in terminology. Some authors discriminate between aseptic and septic osteoradionecrosis.<sup>3,124</sup> The terms osteoradionecrosis, osteomyelitis and radio-osteomyelitis are often used synonymously when referring to irradiated patients.<sup>118,125</sup>

The diagnosis of osteoradionecrosis is based mainly on patient history and clinical signs such as severe pain, non-healing (exposed) bone within the treatment area after completion of radiotherapy and repeated infections. This process may progress to fistula or sequestrum formation and eventual spontaneous fracture.<sup>126-129</sup>

In the early literature the pathogenesis of osteoradionecrosis of the jaws was accepted as the inevitable triad radiation, trauma and infection.<sup>130-132</sup> In this concept the role of trauma is that of a portal of entry for oral bacteria into the underlying bone. Osteoradionecrosis is thus considered to be an infectious process, that progresses rapidly and spreads throughout the bone which cannot wall off the infection because of compromised vascularity and minimal regenerative capabilities. The source of trauma may be anything, including denture irritation, sharp or hard food particles and sharp bony ridges. Tooth removal is said to be the most common cause of trauma.<sup>4,132</sup> More recently, Marx suggested that osteoradionecrosis is a problem of wound healing rather than of infection in which microorganisms play only a contaminating role.<sup>133</sup> Furthermore, osteoradionecrosis is as much a disease process of the covering soft tissues as of the underlying bone. This view has been accepted by many authors.<sup>128,134-136</sup> According to Marx<sup>133</sup> the sequence in the development of osteoradionecrosis is:

- a radiation;
- b hypoxic-hypovascular-hypocellular tissue: the ability to replace normal collagen loss or normal cellular loss is severely compromised or nonexistent;
- c tissue breakdown: unrelated to microorganisms but related to the degree of radiation damage and the rate of normal or induced cellular death. Collagen

lysis and cell death exceed synthesis and cellular replication;  
d chronic non-healing wounds: energy, oxygen, and metabolic demands exceed the supply.

In this concept spontaneous and trauma-induced osteoradionecrosis are different entities.

Spontaneous osteoradionecrosis, which has been reported to occur in almost 35% of all cases of osteoradionecrosis, is related to increased age, high radiation dose (>65 Gy), field of radiation (volume of the mandible included in the field and proximity of maximal dosing to bone), hyperfractionation, use of implant sources too close to the bone, and combined interstitial and external beam irradiation.<sup>123, 129, 133, 137-140</sup> It represents a greater outright cellular kill of normal tissue elements and an inability of soft and hard tissue to keep up with cellular turnover and collagen synthesis. This type of necrosis usually occurs within the first 2 years after radiotherapy.<sup>123, 133</sup>

Trauma-induced osteoradionecrosis represents a mixture of cell death and cell injury. As the years pass after irradiation, the tissue becomes more fibrotic and more hypovascular. If the tissue is traumatised by surgical procedures (e.g. extractions) or by persistent infection, it is suddenly required to meet the demands of wound healing. The reduced healing capacity may result in osteoradionecrosis, a risk which increases with time.<sup>123</sup> Several pre- and post-irradiation factors may increase the risk of osteoradionecrosis. Pre-irradiation extraction followed by inadequate healing time is known to predispose to osteoradionecrosis.<sup>21, 25, 123</sup> In dentulous patients the osteoradionecrosis risk is increased after irradiation in case of trauma in the radiation field such as tooth removal or other surgical procedures (periodontal procedures, biopsies), poor oral hygiene and inadequate home care, and ongoing periodontal or periapical infection.<sup>16, 21, 123, 129, 138, 141, 142</sup> In edentulous patients trauma induced by prosthetic appliances is seen as a predisposing factor,<sup>21, 80</sup> especially when related to certain mastication and parafunctional habits.<sup>143</sup> According to Beumer et al.<sup>76</sup> and Curtis et al.<sup>144</sup> the risk of osteoradionecrosis does not appear to be related to denture wearing in patients who have experience in wearing full dentures prior to therapy. If teeth are extracted shortly before radiotherapy, the risk of developing significant complications when wearing dentures increases.<sup>22, 76, 129</sup> In all patients, continued heavy use of mouthirritants, especially alcohol and tobacco, can significantly contribute to the breakdown of mucosa and exposure of bone.<sup>21, 129</sup> Poor follow-up and poor patient selection for radiotherapy (poor nutritional status or extensive systemic disease) must also be mentioned as predisposing to osteoradionecrosis.<sup>21, 80</sup>

The incidence of osteoradionecrosis varied from 1–44% when low energy treatment was used.<sup>140</sup> The high energy radiation currently used has a relatively low radiation absorption in bone compared to conventional X-ray therapy and is therefore associated with reduced risk of necrosis.<sup>145</sup> However, because increased dosages are used nowadays, osteoradionecrosis may still occur as a serious complication in connection with the treatment of malignant tumors.<sup>25, 129, 138, 142, 145</sup> According to many authors, the incidence of osteoradionecrosis has decreased to ap-

proximately 10% or less.<sup>129,140,146-148</sup> Osteoradionecrosis is observed with higher incidence after cumulative radiation doses to the bone exceed 65 Gy.<sup>80,126,138,149</sup> According to some authors the danger of osteoradionecrosis becomes more acute when radiation is followed by neck dissection, eliminating much of the blood supply to the mucosal lining and periosteum.<sup>150</sup> Dentulous patients have more than twice the risk of developing necrosis than edentulous patients.<sup>3,126,138</sup> Finally, osteoradionecrosis is much more common in the mandible than in the maxilla.<sup>25,137,145,151,152</sup>

## **Taste**

Alteration in taste is an early response to radiation and often precedes mucositis and hyposalivation.<sup>4</sup> Taste sensations may be either intensified or suppressed.<sup>8</sup> Most patients experience partial or complete loss of taste acuity during radiotherapy.<sup>13</sup> Conger found that taste sensation decreases exponentially up to a cumulative dose of about 30 Gy (3 weeks) after which it virtually becomes absent.<sup>153</sup> The loss in perception of all flavors rarely occurs.<sup>81</sup> Perception of bitter and acid flavors is more susceptible to impairment than perception of salt and sweet flavors.<sup>154-156</sup>

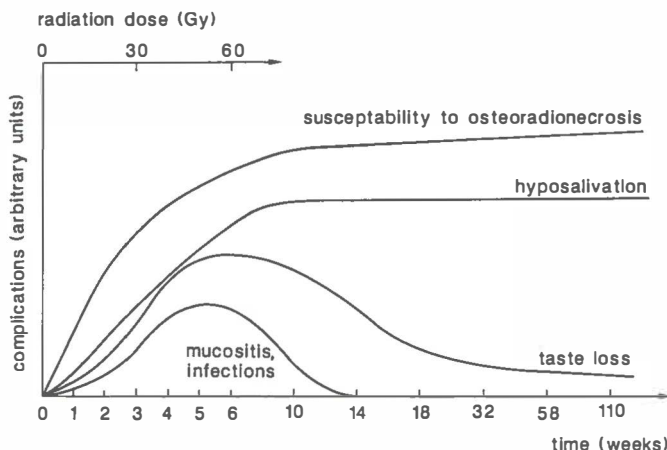
Direct radiation damage to the taste buds or their innervating nerve fibers has been reported as the main cause of taste loss.<sup>21,153,157,158</sup> Histologically, taste buds showed signs of degeneration and atrophy at 10 Gy (2 Gy per day), while at therapeutic levels the architecture of the buds was almost completely destroyed.<sup>157</sup> Dreizen et al. proposed damage to the microvilli and outer surface of the taste cells to be the principal mechanism for loss of the sense of taste.<sup>21</sup> Others consider taste buds to be relatively radioresistant.<sup>4,81</sup> Although taste buds may be injured directly, dysfunction of the salivary glands definitely contributes to decreased taste sensitivity and abnormal taste sensations as saliva acts as a solvent for food substances.<sup>47,159</sup> Furthermore, moderate to severe hyposalivation appears to decrease the number of taste buds and probably alters the form and function of the remaining buds.<sup>159</sup>

Loss of taste is usually transient.<sup>160</sup> Taste gradually returns to normal or near-normal levels within one year after radiotherapy. The degree of taste recovery is dose-dependent. Some patients may keep a residual reduction in taste acuity (hypogeusia), or even a permanent impairment in sensation (dysgeusia).<sup>3,81,153,156</sup> Mossman et al. found a discrepancy between measurable taste loss and subjective awareness of taste loss which may be due to adaptation of the patient to the sensory loss.<sup>155,156</sup>

It has been shown in many studies that taste impairment has profound effects on the nutritional status of the patient and is associated with weight loss through reduced appetite and altered patterns of food intake.<sup>12,155,161</sup>

## **Muscles and joints**

Trismus, or limited jaw opening, may develop due to tumor invasion and during or after radiotherapy if masticatory muscles and/or the TMJ are included in the field of radiation, or a combination of both.<sup>1,13,21</sup> Trismus occurs with unpredictable fre-



**Fig. 6** Schematic diagram illustrating time of onset and duration of radiation induced oral sequelae (modified after Maxymiw and Wood<sup>20</sup>).

quency and severity. Generally, trismus develops 3 to 6 months after completion of radiation treatment and frequently becomes a lifelong problem.<sup>3,81</sup> Trismus is attributed to muscle fibrosis and scarring in response to radiation injury as well as to fibrosis of the ligaments around the TMJ and scarring of the pterygomandibular raphe.<sup>3,4,21,162</sup> Besides tumor growth and surgical procedures, the severity of trismus is dependent on the configuration of the radiation field and whether it is unilateral or bilateral, the radiation source, and the radiation dose.<sup>13,80,82</sup>

Limited jaw opening interferes with oral hygiene, speech, nutritional intake, examination of the oropharynx and dental treatment, and can be particularly discomforting to the patient.<sup>3</sup>

### Pattern of complaints

Oral sequelae of radiotherapy in the head and neck region are the result of the deleterious effects of radiation on salivary glands, oral mucosa, bone, dentition, masticatory musculature and TMJ. Clinical consequences of radiation treatment include hyposalivation, mucositis, taste loss, radiation caries, osteoradionecrosis and trismus, and have all been described in detail in the previous section. The manifestations vary in pattern, duration and intensity, and do not all occur in every patient. Furthermore, they are strongly related to radiation type, techniques, fields, and dosages.<sup>21</sup> Figure 6 outlines the time frame involved in the development of each particular problem.

At the end of the first week of a six week conventional radiation protocol (daily dose of 2 Gy, five times a week), loss of taste acuity<sup>4</sup> and the first clinical signs of mucositis<sup>17</sup> become apparent together with a significant decrease of the salivary flow.<sup>21</sup> Both mucositis and hyposalivation may cause local discomfort and pain as well as difficulties in drinking, eating, swallowing and speech.<sup>13,163</sup>

Several studies have shown that up to 60% of head and neck cancer patients were nutritionally compromised on initial diagnosis.<sup>164-166</sup> During radiotherapy oral intake of food may be impeded due to loss of taste acuity, hyposalivation, changes in viscosity of saliva and especially pain on eating and swallowing due to mucositis or yeast stomatitis which predispose the patient to loss of appetite, nausea and malaise, and may thus further decrease the nutritional status and result in significant weight loss.<sup>12,13,155,166</sup> Donaldson and Lenon reported that the patients lost about 3.7 kg during the course of radiation therapy,<sup>164</sup> while Beumer et al. reported weight losses of 7–11 kg not to be uncommon.<sup>13</sup> In severe cases of weight loss, nasogastric tube feeding may become necessary.<sup>12,17</sup> Weight loss leads to weakness, inactivity, discouragement, anorexia and susceptibility to infection. It has been postulated that patients with a good nutritional and emotional status have improved tumor response to both radiation therapy and chemotherapy.<sup>167</sup> For several reasons it is therefore of the utmost importance to maintain a good nutritional and positive emotional status in the head and neck irradiation patient.

Mucositis generally persists throughout radiotherapy and continues for one to two weeks after treatment has ceased.<sup>1</sup> Oral erythema disappears completely within four to six months.<sup>23</sup> An easily traumatized thin atrophic and relatively avascular oral mucosa is left.<sup>2</sup> Taste gradually returns to normal or near-normal levels within one year after radiotherapy.<sup>3</sup> When a substantial volume of parotid gland tissue has been irradiated with dosages larger than approximately 40 Gy, the resulting hyposalivation is usually irreversible (Table 1). Thus the oral phenomena related to hyposalivation persist (Table 2) and the patient is subject to a lifelong increased risk for the development of oral infections and dental caries. Radiation induced trismus may even further increase this risk by interfering with oral hygiene and dental treatment.<sup>3</sup>

Osteoradionecrosis is another lifelong serious potential complication which is threatening the irradiated patient, especially when the mandible has been in the field of radiation.<sup>123</sup> Because the compromised vascularity and the minimal regenerative capabilities are not limited to the irradiated bone, there is also a permanent risk of soft-tissue necrosis.

In many cases radiation induced side-effects can be eradicated or minimized with appropriate prevention and/or treatment. In the remaining part of this chapter the prevention and treatment considerations are reviewed.

## **PREVENTION AND TREATMENT OF ORAL SEQUELAE RESULTING FROM HEAD AND NECK RADIOTHERAPY**

### **Mucositis**

Irradiation mucositis is considered to be an inevitable but transient side effect of therapeutic head and neck irradiation.<sup>4,10</sup> Its occurrence and severity are strongly related to dose, field, fractionation and type of ionizing irradiation.<sup>4,8</sup> The use of

various radiation treatment modalities can play an important role in the prevention of mucositis. In recent decades, the use of linear accelerators rather than orthovoltage, and other improvements in radiotherapeutic techniques resulted in a major decrease in the incidence and severity of mucositis.<sup>3</sup>

It has been claimed that new irradiation techniques like hyperfractionation and accelerated treatment improve local control in head and neck cancer.<sup>168-170</sup> The aim of hyperfractionation is to further reduce late effects, while achieving the same or better tumor control, and the same or only slightly increased early effects (mucositis). The aim of accelerated treatment is to reduce repopulation in rapidly proliferating tumors. While there is little or no change in the late effects, the early effects (mucositis) are the limiting factor. Thus proper control of mucositis becomes of utmost importance when implementing these new irradiation techniques.

To prevent or reduce mucositis, normal tissues, especially the tongue and mandible, can be protected by direct shielding, movement of these structures outside the field of radiation, or movement to a lower dose area within the field. This type of tissue protection can be accomplished by individually made shielding- or positioning prostheses, but unfortunately is often not applicable due to the localization of the tumor.<sup>80,171-173</sup>

The Consensus Development Panel of the National Institutes of Health (USA) recently stated that no currently available drugs can prevent mucositis.<sup>174</sup> It is also the opinion of most authors that irradiation mucositis is not preventable other than by shielding.<sup>3</sup> The ultimate goal of most protocols described is to reduce the severity and complaints of mucositis. Most oral care programs aim at: removal of mucosal irritating factors, cleansing of the oral mucosa, maintaining the moisture of the lips and the oral cavity, relief of mucosal pain and inflammation, and prevention or treatment of infection.<sup>175-178</sup> Although it has been suggested that good oral hygiene may reduce the development and severity of mucositis, no controlled studies of large numbers of patients have been performed.<sup>34</sup>

*Irritating factors* such as sharp or rough fillings should be smoothed or polished prior to radiotherapy and prosthetic appliances should be closely evaluated to ensure that they are not irritating to the tissues.<sup>80,179</sup> Some authors recommend to discourage the wearing of dentures during the radiation treatment period.<sup>22,144,180</sup> As denture surfaces may be colonized with *Candida* species, others recommend special attention to denture hygiene and removal of the appliance at least at night.<sup>1,3,34</sup> Within the scope of the elimination of irritating factors, the use of tobacco, alcohol, and spicy and acidic foods should also be discouraged.<sup>179,181</sup>

Several *cleansing agents and devices* have been recommended to reduce mucosal irritation, to remove thickened secretions and debris from the mouth, and to increase moisture of the mucosa. The three major cleansing agents reported are: hydrogen peroxide and water, saline solution, and sodium (bi)carbonate solution.<sup>3,175</sup> Hydrogen peroxide may assist in removing debris,<sup>34,182</sup> but should not be used when there are fresh granulation surfaces in the mouth, because of a tendency to break down new tissues.<sup>178</sup> Saline mouthwashes are known to be safe and economical.<sup>183</sup> Sodium (bi)carbonate has been used as a cleansing agent because of its ability to



dissolve mucus and loosen debris, either as a single agent<sup>184</sup> or in combination with saline.<sup>181,185-187</sup> Based on experience, most routine oral hygiene protocols recommend oral cleansing three times during day-time and once before sleep. In case of severe mucositis, the frequency has to be increased to every two hours or even every hour.<sup>178</sup> Despite the fact that the optimal mouthwash to be used in the treatment of mucositis has not yet been determined, it seems that mechanical cleansing itself is the primary active mechanism. Besides rinsing by the patient himself, additional frequent professional spraying of the oral cavity (oral hygienist) may provide an extra benefit for the patient when considering this mechanical cleansing activity.<sup>31,188,189</sup> Many investigators note that the systematic performance of oral care is more effective in reducing the incidence of mucositis than the type of agent or device used.<sup>175,178,190,191</sup>

*Lubricants* must be used to keep the lips clean, moist and intact. The most commonly used lubricants are K-Y jelly, vaseline and mineral oil. They should be used with caution, because ingestion can cause aspiration pneumonia.<sup>175,177,192</sup> Lubricants for the oral mucosa will be discussed on pages 27–28.

For relief of pain and discomfort due to mucositis several anesthetics, analgesics and mucosal coating agents are mentioned in the literature. Periodic rinses with topical anesthetics such as viscous xylocaine (lidocaine) are often advised.<sup>3,21,187,192</sup> These rinses can be used every 2–3 hours. When used before meals, care should be taken, because reflexes may be impaired and aspiration can occur.<sup>3</sup> Whether these anesthetics are to be used as topical rinses (i.e. swish and spit out) or must be ingested (i.e. swish and swallow) to have maximum therapeutic effect has not been addressed. In case of localized areas of mucositis, benzocaine in Orabase can also be applied.<sup>3</sup> When topical anesthetics are inadequate to control pain, the use of systemic analgesics is advised.<sup>3,21</sup> For relief of pain and resolution of mucositis, encouraging results have also been reported with the use of sucralfate suspensions in both chemotherapy<sup>193,194</sup> and radiotherapy patients.<sup>195-197</sup> According to Shenep et al., sucralfate may prevent colonization of organisms by interfering with adherence of microbes to mucous membranes.<sup>198</sup> This might also contribute to pain reduction. Benzydamine hydrochloride (BZD), a nonsteroidal drug with analgesic, anesthetic, anti-inflammatory and antimicrobial properties, has also been proposed for pain relief. Although Samaranyake et al. found that a BZD rinse provided no therapeutic advantage when compared with a chlorhexidine rinse in a group of head and neck irradiation patients,<sup>37</sup> Epstein and Stevenson-Moore have shown that BZD was superior to placebo in reducing pain<sup>199</sup> and Kim et al. reported evidence of anti-inflammatory action.<sup>200</sup> An advantage was that pain relief occurred without significant anesthesia, and thus without influence on reflex mechanisms. In several publications it has been shown that BZD has a potential to reduce the severity of mucositis, although ulcerations and secondary candidiasis still occur.<sup>34,201,202</sup> It seems to be a disadvantage that many authors reported burning sensations associated with BZD rinses, probably due to its 10% alcohol content.<sup>199</sup> Other agents

with promising results in terms of mucositis reduction are prostaglandin E2 and beta-carotene.<sup>203,204</sup> Finally, dentulous patients can wear a soft mucosal guard to reduce pain.<sup>80</sup>

Because *oral flora* is thought to contribute to mucositis, oral antimicrobial agents, particularly chlorhexidine mouthrinses, are used in the treatment of mucositis in order to prevent or treat oral infections and to reduce colonization.<sup>205</sup> Chlorhexidine has proven its effectiveness as a plaque control agent in the reduction of caries and periodontal disease,<sup>206,207</sup> but there are no consistent reports of its value in reducing mucositis or preventing colonization of bacterial pathogens and yeasts.<sup>34</sup> McGaw and Belch<sup>208</sup> and Ferretti et al.<sup>209,210</sup> reported significant reduction of the incidence and severity of mucositis in chemotherapy patients with concomitant reductions in total oral *Streptococci* and oral *Candida* levels, but they observed some increase in gram-negative bacilli when compared with controls. Other authors found no reduction in the number of colony forming units of *Candida* species or nonindigenous flora.<sup>34,211</sup> A reason for these conflicting results may be the amount of confounding factors such as the simultaneous use of other topical or systemic antimicrobial agents, differences in the assessment of tissue reactions, hematologic status, and compliance in chemotherapy patients. Recent studies in radiotherapy patients have shown the use of chlorhexidine to be of no benefit.<sup>210,212</sup> Development and severity of irradiation mucositis did not differ between chlorhexidine rinse groups and placebo groups. Furthermore, only a reduction of the indigenous microorganisms (*Viridans Streptococci*) was found, without any differences in *Candida* species and gram-negative bacilli (*Enterobacteriaceae*, *Pseudomonaceae*, *Acinetobacter* species).<sup>37,210,212</sup> Possible explanations are inactivation of chlorhexidine by saliva<sup>32</sup> and the lack of salivary glycoproteins as necessary cofactors for mucosal cell protection.<sup>205</sup> Therefore, it seems that chlorhexidine is of limited value in decontaminating the oral cavity and should not be used for the prevention or reduction of mucositis.

Because of the high carriage rate of gram-negative bacilli found in many high dose radiotherapy patients,<sup>29,51,212</sup> Spijkervet et al.<sup>32,33</sup> performed a pilot study which was aimed at the selective oral decontamination of these gram-negative bacilli using polymyxin E/tobramycin/amphotericin B (PTA)-containing lozenges. Although it is unlikely that yeast colonization is related to the pathogenesis of mucositis,<sup>35,38,39</sup> Spijkervet et al.<sup>32,33</sup> administered the antifungal amphotericin B to prevent yeast stomatitis. Results were very encouraging in that eradication of gram-negative bacilli (selective elimination of oral flora) was associated with a significant reduction of mucositis. No pseudomembranes were observed and mucositis was confined to erythema only in all selectively decontaminated patients. According to these results, it seems that the advanced stages of mucositis can be totally prevented by eradication of gram-negative bacilli, while the initial phase of erythema seems to be purely irradiation induced. Extended studies are needed to confirm these promising results.

In relation to mucositis some remarks on nutritional care must be made. The oral food intake during radiation therapy may be severely impeded due to loss of



taste acuity, hyposalivation, changes in viscoelasticity of saliva, and pain when eating and swallowing due to mucositis or yeast stomatitis. By preventing or reducing the oral complications of radiotherapy, food intake can be facilitated. Nutritional counseling and continuous dietary instructions can minimize weight loss.<sup>166,213,214</sup> Consultation with a dietitian prior to radiotherapy can be of great value. A basic meal plan including the addition of supplementary feedings should be started at the beginning of therapy and followed with modifications during the total period of treatment or until complaints subside. Encouraging moistened foods and an increased fluid intake will make the mastication process easier in case of hyposalivation. Spicy and acidic foods can result in mucosal irritation and should be avoided. Food served at room temperature will make ingestion less painful in case of mucosal erythema. As oral reactions become more profound, the diet should be modified to adjust texture, consistency and portion sizes, depending on specific patient needs. Raw or course foods should be eliminated and the diet changed to a soft or semisoft consistency. Care should be taken to avoid foods that favor an increase in the activity of cariogenic flora. Small frequent feedings should be recommended when appetite is poor, when nausea is present and when swallowing is very difficult. Enriched dietary supplements are recommended during nutritionally difficult periods.<sup>13,214</sup> Adequacy of the patient's oral intake should be carefully monitored by measuring the amount of calories and protein consumed and especially by noting changes in body weight.<sup>166</sup> As a general rule, when a loss of 10% of the body weight is seen in the third or fourth week of radiotherapy, a nasogastric tube is inserted.<sup>214</sup> Total parenteral nutrition is rarely indicated and used only when patients cannot tolerate the use of the gastrointestinal tract.<sup>166</sup> After radiotherapy the patient will generally progress to a normal diet, however, foods may have to continue to be moistened and served with liquids for an indefinite period of time because of the radiation-induced hyposalivation.<sup>214</sup>

## **Hyposalivation**

Prevention of radiation injury to salivary gland tissue is limited to excluding the salivary glands, especially a portion of the parotid gland, from the treatment field by field configuration and shielding.<sup>34,172,215</sup> This approach might compromise complete coverage of the tumor and/or regional lymph nodes.<sup>47</sup> Fractionation schedules have a special influence on the recovery of salivary gland tissue.<sup>216</sup> Hyperfractionation, in particular, has been claimed to reduce the late effects of irradiation<sup>7</sup> and may result in less hyposalivation.<sup>170</sup> Although with limited indications, surgical transposition of the submandibular salivary glands outside the treatment portals has been described as a successful method for the prevention of hyposalivation.<sup>217,218</sup>

Radioprotection of the parotid gland has focused on pharmacological manipulation of the radiosensitivity of this tissue. WR-2721,<sup>219-224</sup> isoprotenerol,<sup>221</sup> cAMP,<sup>225,226</sup> acetylsalicylic acid<sup>227,228</sup> and lidocaine<sup>47</sup> have been reported to be effective in protecting the rat parotid gland from radiation injury. The radioprotective properties of these drugs are probably based on their ability to act as a radical

scavenger, to increase the intracellular level of glutathione, to stimulate the proliferation of salivary gland cells and to deplete the cells from granules. Although most compounds are probably too toxic at radioprotective doses to be of clinical usefulness, WR-2721 is currently tested in phase II and phase III trials.

Because salivary glands are usually located within the treatment portals for head and neck cancer and because at present there is no proper clinically acceptable radioprotection, the treatment of hyposalivation has to be palliative and can be roughly divided in: oral hygiene measures, stimulation of residual salivary gland tissue (sialogogues) and symptomatic relief of oral dryness.<sup>78</sup>

Continuous maintenance of effective *oral hygiene* and the use of an adequately protective topical fluoride are the most important methods for preventing the dental complications of hyposalivation and will be discussed on pages 28–33.

**Table 3** Gustatory and tactile sialogogues<sup>262</sup>

---

**Acid-tasting substances:**

- vitamin C tablets
- citric acid crystals
- acid (sugar-free) sweets
- lemon pastilles
- lemon slices
- acid or effervescent drinks (lemon juice, citric acid, buttermilk)
- cotton-wool gauze soaked in a citric acid and glycerine solution

**Miscellaneous substances:**

- sugar-free chewing gum
  - sugar-free sweets
  - dried pieces of reed root (calami rhizoma)
  - vegetables or fruits
- 

*Sialogogues* can be used to treat hyposalivation, but they require a functional salivary gland parenchyma to be effective. Although a significant proportion of the salivary glands may be included in the radiation fields in patients with malignancies in the head and neck, it is rare that all the minor and major glands will be totally compromised by the radiation therapy.<sup>229</sup> Sialogogues can be divided into gustatory, tactile and pharmacological substances. With regard to gustatory stimuli, particularly acid tasting substances are applied to increase salivary secretion. In case of mucositis, they should not be prescribed.<sup>214</sup> Bitter tasting substances also stimulate salivary secretion. Sweet tasting substances stimulate salivary flow to a lesser extent and can even exacerbate the sensation of a dry mouth.<sup>230</sup> A combination of tactile and gustatory stimuli is found in chewing gum. In all compositions of gustatory sialogogues the sugar free ones are widely recommended. In Table 3 a survey is given of some frequently used gustatory and tactile sialogogues.

Several drugs, including anetholetrithione<sup>231-234</sup> and pilocarpine,<sup>235-238</sup> have been assessed for their effectiveness as sialogogues in clinical trials. Epstein and Schubert reported a significant increase in salivary volume after the combined use of pilocarpine and anetholetrithione in patients who had not responded to any single

**Table 4** Pharmacologic sialogogues<sup>262</sup>

---

Pilocarpine hydrochloride, pilocarpine nitrate
Anetholetrithione
Carbachol
Folia Jaborandi and tinctura Jaborandi
Betanechol chloride
Neostigmine, neostigmine bromide, pyridostigmine bromide, destigmine bromide
Trithioparamethoxyphenylpropene
Benzapyrone
Potassium iodide
Nicotinamide and nicotine acid

---

modality.<sup>239</sup> The usefulness of pilocarpine and other pharmacological sialogogues seems to be limited due to their potential for gastrointestinal, cardiovascular and other side effects.<sup>47,240</sup> Common pharmacological sialogogues are listed in Table 4.

Electrical stimulation of the oral and pharyngeal afferent nervous system with a special device, leading to increased salivation from all residual salivary tissue, is a relatively new approach to the treatment of xerostomia. The electronic stimulator seems to have been successful in treating xerostomic patients regardless of the etiology of their dry mouths.<sup>241</sup>

When stimulation of residual secretion is insufficient to relieve the patients' complaints a purely *symptomatic approach* remains. Many rinsing solutions are applied to moisten the dry, irritated, vulnerable mucosa with the aim of reducing secondary effects. The simplest technique is frequent moistening of the mouth with water, tea, saline, solutions containing sodium (bi)carbonate and sodium chloride, Emser salt, or diluted milk of magnesia.<sup>242-249</sup> Extracts of camomile, solutions of potassiumpermanganate,<sup>232</sup> or camphor in water and paraffin<sup>250</sup> are also mentioned in the literature. Mouthwashes containing irritating substances (sharp tastes, alcohol) must be avoided because of their effect on the thin, dry, atrophic mucosa.<sup>251</sup> The solutions mentioned are helpful for relief of soreness of the denuded mucosa and assist in swallowing and speaking.

An important disadvantage of all these mouthwashes is the necessity of frequent applications because of poor retention properties.<sup>78</sup> For this reason many authors treated xerostomia with more viscous glycerine-containing mouthwashes, which required less frequent application.<sup>77,245,252,253</sup> Furthermore, complex saliva substitutes were developed not only containing agents to impart viscosity and to keep soft tissues moist but also including inorganic substances to retard enamel solubility. Matzker and Schreiber developed a carboxymethylcellulose (CMC) preparation and administered it to patients with chronic xerostomia; all who used it reported symptomatic improvement.<sup>254</sup> Shannon et al. developed a saliva substitute containing fluoride in addition to CMC.<sup>255</sup> Fluoride increases the potentially enamel remineralizing properties of the saliva substitute.<sup>256</sup> They reported this substitute to be a well-tolerated and useful product. In attempts at developing a more natural artificial saliva, 's-Gravenmade et al.<sup>257</sup> proposed a mucin-containing saliva substitute that was preferred above a CMC-containing substitute by patients with

Sjögren's syndrome or radiation-induced xerostomia.<sup>258,259</sup> Weerkamp et al. suggested that a mucin-based artificial saliva is also more effective in restoring normal oral flora.<sup>260</sup>

Patients often object to the taste or inconvenience of using artificial saliva and return to the use of water.<sup>3</sup> Klestov et al.,<sup>77</sup> Visch et al.<sup>259</sup> and Vissink et al.<sup>261</sup> felt that the most useful indices of the effectiveness of artificial saliva are night-time discomfort and difficulty in talking. Furthermore, it was stated that the success of artificial saliva usage is strictly dependent on the instructions delivered with its prescription.<sup>262</sup> Intraoral devices, i.e. the construction of an artificial saliva reservoir, have been reported to be useful in providing sustained release of artificial saliva.<sup>263-266</sup>

Another possibility in the treatment of xerostomia, which is currently under investigation, is the use of mucin-containing lozenges, alone or in combination with mucin-containing artificial saliva. Promising results with these lozenges in patients with Sjögren's syndrome will be published in due course.<sup>267</sup> These lozenges may also serve as a time-releasing system for pilocarpine or other sialogogues.

### **Radiation caries**

Radiation caries is an effect of irradiation-induced changes in salivary gland tissue that result in hyposalivation, changed salivary composition, a shift in oral flora towards cariogenic bacteria (*S. mutans*, *Lactobacillus* species) and dietary changes. For this reason prevention of hyposalivation will invariably contribute to the prevention of radiation caries.

In the early days of radiotherapy, extraction of the teeth prior to irradiation was proposed.<sup>85</sup> Advocates for oral hygiene regimens<sup>268</sup> and restorative procedures<sup>269</sup> met with limited success in caries prevention in those days. Since then comprehensive preventive measures have been recommended for head and neck cancer patients before, during and after radiation therapy.<sup>185,270</sup> Some of the recommended measures have included rigorous oral hygiene, daily self-application of topical fluoride, limitation of cariogenic foods, remineralizing mouthrinse solutions and artificial saliva preparations. It is now generally accepted that almost complete caries prevention can be achieved in irradiated patients by the daily use of fluoride in conjunction with strict oral hygiene.<sup>74,84,271</sup>

Before the onset of radiotherapy, pre-therapeutic dental care should be performed which includes careful cleaning, scaling and polishing of the teeth, and restorative procedures as needed.<sup>192,270,272,273</sup> An important management aspect includes efforts to improve the patient's dental care and cooperation. The ability and willingness of the patient to cooperate in the dental therapy and preventive regimen should be assessed.<sup>74,192,273</sup> Removal of foci of infection and pre-irradiation extractions will be dealt with on pages 33–35.

Before irradiation, all patients should be instructed in oral hygiene measures including meticulous brushing techniques using a fluoride-containing toothpaste and interdental techniques such as flossing, if necessary assisted with plaque disclosing

agents, as well as dietary instructions about non-cariogenic foods.<sup>3,84,273</sup> Oral hygiene should be maintained at a high level. Painful mucositis may make hygienic care difficult so that professional tooth cleaning (oral hygienist, nursing staff) may be necessary during the last weeks of radiation treatment. Topical anesthetics may provide sufficient temporary pain relief to allow soft-bristle toothbrushing and gentle flossing. If brushing must be discontinued, frequent mouthrinses will help to eliminate bacterial and food debris.<sup>1,3</sup> Although oral hygienic measures are important in the prevention of radiation caries, it has been shown that oral hygiene alone is totally inadequate as a safeguard against radiation caries.<sup>84</sup>

The cornerstone and most important component in the prevention of radiation caries is the use of daily self-applied topical fluoride preparations. Both 1.0% neutral and acidulated sodium fluoride (NaF) gels have been recommended, as well as a 0.4% stannous fluoride (SnF<sub>2</sub>) gel. At present there is no clinical evidence available to indicate relative superiority of one of these preparations over another with respect to caries control.<sup>274,275</sup> Although severe radiation caries among noncompliant patients has been observed, most investigators have indicated remarkable success in using topical fluorides for caries prevention, irrespective of the chemical formulation or the method of application.<sup>74,186,270,271,276-278</sup> Frequency and persistence of fluoride use seem to be critical in this group of patients.<sup>84,145</sup> Less concentrated fluoride mouthrinse preparations (3 to 300 ppm) have been recommended in some instances,<sup>279,280</sup> but their effectiveness in caries control in xerostomic patients has not been established.<sup>274</sup>

Despite the magnitude of the problem of radiation caries, only a few reports on fundamental research in this field have been published. The preventive caries program consisting of daily oral hygiene and daily topical 1.0% NaF gel application using custom-made fluoride carriers developed by Daly and Drane at the M.D. Anderson Cancer Center at Houston, Texas (USA),<sup>82,272,281</sup> has been supported by investigations of Dreizen et al.,<sup>21,84</sup> Brown et al.<sup>27,69</sup> and Keene et al.<sup>75</sup> This regimen dramatically reduced caries incidence and was also successful in arresting existing lesions, regardless of the cariogenicity of the patient's diet.<sup>84</sup> On the basis of a more than 10-year experience with 935 head and neck cancer patients, Horiot et al. also concluded that this fluoride protocol was a highly reliable method for prevention of radiation caries, and that the use of a toothpaste with a high fluoride content (3.0% NaF) twice a day was a good alternative, provided its prerequisites (higher level of compliance is needed) were well understood by both clinician and patient.<sup>271</sup> Because studies have shown the additional plaque inhibition benefit of SnF<sub>2</sub>,<sup>282-284</sup> the caries preventive program used at the M.D. Anderson Cancer Center as well as that of some other centers currently involves the daily topical application of a 0.4% SnF<sub>2</sub> gel combined with strict oral hygiene procedures.<sup>3,74,274,285,286</sup> In addition to prevention of caries, fluoride applications have also been used to eliminate root surface hypersensitivity to cold, hot, acidic and sweet foods as is often experienced during and after radiotherapy.<sup>3,82</sup>

Most authors prefer the use of fluoride in gel form, applied with a custom-made plastic fluoride carrier.<sup>3,82,84,271,285,286</sup> In almost all studies patients are instructed to

apply the fluoride gel for 5–10 minutes once daily after toothbrushing and flossing, preferably just before bedtime.<sup>1,82,84,192,271,285</sup> At present, at the M.D. Anderson Cancer Center, the carrier method is restricted to those patients in whom severe xerostomia is anticipated or whose caries history suggests the possibility of future high caries risk. In cases in which it is anticipated that the radiotherapy will result in a partial, less severe type of xerostomia, a simple brush-in technique is used.<sup>274,285</sup> It has been reported that the brush-in technique with 0.4% SnF<sub>2</sub> gel can be used with good success for all irradiated patients, irrespective of the degree of anticipated xerostomia.<sup>74</sup>

**Table 5** Advantages and disadvantages of three commonly used topical fluorides<sup>286</sup>

	Advantages	Disadvantages
Stannous fluoride (SnF <sub>2</sub> )	<ol style="list-style-type: none"> <li>1. Has antimicrobial properties</li> <li>2. Equivalent in effectiveness to APF gel</li> <li>3. Will arrest incipient lesions</li> </ol>	<ol style="list-style-type: none"> <li>1. Bad taste</li> <li>2. May cause sensitivity of teeth and gingiva</li> <li>3. May pigment arrested lesions</li> </ol>
Acidulated phosphate fluoride (APF)	<ol style="list-style-type: none"> <li>1. More acceptable taste than SnF<sub>2</sub></li> <li>2. No staining or pigmentation of hard or soft tissues</li> </ol>	<ol style="list-style-type: none"> <li>1. Should have a pH &lt; 4.0 to be effective (most flavored APF gels have pH &gt; 5.0)</li> <li>2. May damage porcelain restorations</li> <li>3. Must etch the tooth surface to be effective</li> </ol>
Sodium fluoride (NaF)	<ol style="list-style-type: none"> <li>1. Neutral pH for the acid environment of the mouth</li> <li>2. No sensitivity to hard and soft tissues</li> <li>3. Can be substituted for while overcoming disadvantages of SnF<sub>2</sub></li> <li>4. Pleasant taste</li> </ol>	<ol style="list-style-type: none"> <li>1. Not as effective as SnF<sub>2</sub> for antimicrobial activity</li> </ol>

There is no consensus about the use of acidulated or neutral forms of topical fluorides. Although acidulated forms have the advantage of facilitated uptake, the low pH may result in significant mucosal irritation, burning pain, erythema and ulceration, thereby affecting patient compliance to therapy.<sup>145,192</sup> For this reason many authors advocate the use of neutral or slightly acidic forms of especially NaF gel that are well tolerated by the patients.<sup>1,84,271,281</sup> Others prescribed acidulated phosphate fluoride (APF) gel<sup>88,287,288</sup> or acidulated forms of SnF<sub>2</sub> gel<sup>285,286</sup> without experiencing the above mentioned problems. Fleming reported that in less than 2% of the patients using an acidulated 0.4% SnF<sub>2</sub> gel (pH 3.2) soft tissue irritation was experienced.<sup>285</sup> It appears therefore that the form of topical fluoride used, may



be dictated by the patient's tolerance and acceptance. The advantages and disadvantages of three commonly used topical fluorides are summarized in Table 5.

The mechanisms of fluoride protection have not yet been fully elucidated. Especially the effect of fluoride on the oral flora of irradiated patients is still unclear. Brown et al.<sup>27</sup> and Keene and Fleming<sup>274</sup> found that the only effect of daily application of 1.0% NaF gel was a temporary delay in the increase of cariogenic microorganisms in irradiated patients. This finding means that the cariostatic effect of NaF in these patients is not associated with a reduction in the oral load of *S. mutans* and lactobacilli. The decrease in cariogenicity may in part be attributed to inhibition of metabolic enzymes resulting in a decrease in acid production and demineralization of enamel and other virulence factors, such as glucan production and adherence.<sup>279,289</sup> Results from several other studies, however, suggest that, among cooperative patients, prolonged use (>5 years) of a 1.0% NaF gel may help to reduce the oral load of both *S. mutans* and lactobacilli.<sup>75,290</sup> A gradual restoration of partial salivary function in some long-term survivors could also be involved in these findings.<sup>10</sup> In a recent study by Keene and Fleming it was found that post-radiotherapy *S. mutans* levels in a SnF<sub>2</sub> gel group were significantly lower than in a NaF gel group, but that *Lactobacillus* levels did not differ.<sup>274</sup> These findings were in agreement with those reported by Tinanoff<sup>291</sup> in healthy subjects and lead to the assumption that this antimicrobial action of SnF<sub>2</sub> gel could be of benefit in lowering the caries risk in irradiated patients, in particular when considering the results reported by Brown et al.<sup>69</sup> They found that the *S. mutans* increase in caries-active patients was 25 times greater than in the caries-inactive group.

The most important benefit of fluorides probably is the shift of the demineralization-remineralization equilibrium in favor of remineralization, resulting in incorporation of fluoride into enamel and dentin, with an increase in the resistance of enamel to (further) caries attacks.<sup>145,279,292</sup>

Because hyposalivation is irreversible in the majority of head and neck irradiation patients, most authors have stated that, irrespective of the chemical formulation and application method, fluoride applications must be continued indefinitely in these patients and that, if fluoride use is discontinued, caries will develop within months.<sup>74,84,187,271,272</sup> No proper data concerning the reduction of the fluoride application frequency have been published to date. Beumer and Brady<sup>22</sup> and Beumer et al.<sup>145</sup> stated that in some cases fluoride use can be reduced based on improved salivary gland function and continued good oral hygiene. Others mentioned that the frequency of fluoride applications may be reduced to twice a week after radiotherapy is completed, but this reduction is probably based on clinical experience.<sup>186,293,294</sup>

A continuing concern has been expressed regarding the total amount of fluoride ingested over a number of years with high dose regimens. Johansen and Olsen therefore designed an alternative preventive program using a remineralizing solution containing calcium and phosphate in conjunction with a 1.0% NaF gel and strict oral hygiene.<sup>278</sup> After four weeks daily fluoride applications were stopped, while twice daily rinses with the remineralizing solution were continued. After

four years, a minimal number of carious lesions had developed and tooth surfaces had hardened considerably.<sup>295</sup> Enamel rehardening effects have also been found in vitro for saliva substitutes.<sup>256,296</sup> These authors consider saliva substitutes as a valuable adjunct but not as a substitute for topical fluorides.

The additional use of chlorhexidine in the prevention of radiation caries has only been reported by Katz<sup>297</sup> and Epstein et al.<sup>298,299</sup> Lactobacilli and especially *S. mutans* have been proven to be sensitive to the effects of chlorhexidine in the plaque of healthy individuals.<sup>300-302</sup> Katz reported total prevention of radiation caries in patients with a fair to poor dental status and without oral hygiene instructions when using a regimen of four topical fluoride applications (1.0% NaF-1.0% chlorhexidine digluconate) followed by daily rinses with a 0.05% NaF-0.2% chlorhexidine solution.<sup>297</sup> Without chlorhexidine, this regimen was insufficient to prevent radiation caries. Recently, Epstein et al. found a modest reduction in *S. mutans* and little effect on *Lactobacillus* counts with intermittent rinse schedules with chlorhexidine (0.2%) in conjunction with daily fluoride applications (0.5% NaF gel), while radiation caries was found to be significantly correlated with *Lactobacillus* species.<sup>298</sup> With the use of a chlorhexidine gel (1%), applied twice a day in custom-made carriers, they found a more marked but still transient effect especially on *Lactobacillus* counts.<sup>299</sup> A schedule for use of the chlorhexidine remains to be delineated and the caries risk as identified by bacterial counts and the importance of these risk levels in the irradiated patient in the long term have to be assessed.

The importance of a thorough follow-up after radiotherapy cannot be overemphasized. In most studies with successful fluoride regimens it has been reported that radiation caries breakthroughs invariably stemmed from a failure of the patient to completely comply with the prescribed use of the fluoride.<sup>75,84,271,272</sup> The caries risk is so enormous and omnipresent that constant lifelong patient cooperation and vigilance is the sine qua non of caries prevention in the xerostomic patient.<sup>84</sup> During regular follow-up visits patients can be continuously encouraged to adhere to therapy, and oral hygiene and fluoride usage can be evaluated and reinforced. If caries appears, restorative care should be provided as necessary and, as mentioned before, duration and frequency of fluoride applications can be increased temporarily for remineralization and caries arrest.<sup>1,3,145,187</sup>

A totally different approach to radiation caries prevention was advocated by Coffin who suggested full coverage of teeth with cemented acrylic splints to protect them by insulating them from the unnaturally dry oral environment.<sup>303,304</sup> These splints had to be left in place until the salivary flow had returned to near-normal levels, which may be more than two years according to the author.

Scant information is available concerning radiation caries prevention and treatment for the pediatric patient treated with head and neck radiotherapy. Pediatric patients under head and neck irradiation are usually treated conservatively with respect to their dentition. When tooth germs, erupting teeth and jaws are irradiated there is often a lack of growth of these structures if the pediatric patient becomes a long-term survivor. Therefore, when there are various permanent teeth that may not erupt, it is important to conserve the deciduous teeth that are present. It has



been found that fluoride treatment works as well with the pediatric patients as with the adult. An intensive home-care and prevention program must therefore be established with the patient and his parents and/or nurses.<sup>3,82,305,306</sup>

### **Periodontal disease**

There have been no specific reports on the prevention of periodontal disease in patients irradiated to the head and neck region. Silverman and Chierici stated that extreme care must be taken in evaluating the periodontal status before, during and after treatment.<sup>118</sup> Mechanical oral hygiene procedures (calculus removal, root planing, soft tissue curettage, tooth surface polishing and daily plaque removal) are to remove the local etiologic factors of inflammatory diseases of the periodontium. The overall effect of mechanical procedures is the reversal or control of inflammation, and there is no controversy that these positive effects on the periodontium are beneficial as pretreatment interventions.<sup>307</sup> Optimal oral- and periodontal hygiene must be maintained indefinitely, due to the lowered biological potential for healing of the periodontium (alveolar bone, periodontal ligament, cementum) after radiotherapy.<sup>13,118</sup> Daly reported that periodontal problems were diminished in those patients receiving topical fluoride applications and maintaining good oral hygiene.<sup>89</sup>

### **Osteoradionecrosis**

Osteoradionecrosis is one of the most serious complications of radiation therapy for head and neck tumors. Etiology, incidence and causative factors have been described on pages 16–19. The concepts of pathophysiology, prevention and treatment have changed over the past decade.<sup>123,127,136,308,309</sup>

The best method to control osteoradionecrosis is prevention.<sup>81</sup> Besides proper irradiation techniques and shielding, the first step toward prevention of osteoradionecrosis is by thorough, early pre-irradiation dental assessment. This pretreatment oral examination attempts to identify the main factors that will cause risk so that steps may be taken to control or eliminate as many factors as are practical before radiation treatment begins.<sup>310</sup> The primary goal should be to optimize the condition of the patient's dentition, so that high-risk procedures, such as extraction of teeth, apicoectomies etc. will not have to be performed in the post-irradiation period.<sup>13,22,145</sup> If this oral screening is performed so close to the initiation of radiotherapy as to preclude dental intervention, the value is limited. To maximize the impact of screening, adequate time for treatment and healing must be allowed.<sup>311</sup>

It has long been controversial whether or not to extract teeth prior to irradiation in order to eliminate this potential source of infection.<sup>25</sup> Originally, the favored approach was to extract all teeth in the path of radiation,<sup>107,312</sup> or at least molars.<sup>85</sup> Current research findings no longer support this concept.<sup>81</sup> The timing of dental extractions in relation to the beginning or completion of radiotherapy has been studied by many authors, with a wide range of results. Pre-irradiation extractions

were shown to increase the potential for osteoradionecrosis compared to patients who did not require dental surgery.<sup>25,88,137,139,149,313</sup> Furthermore, post-irradiation extractions were shown to be the significant factor predisposing to osteoradionecrosis.<sup>25,126,138,145,149,273,314</sup> Because pre-irradiation extractions, when performed and timed correctly, do not significantly increase the overall risk of osteoradionecrosis,<sup>25,315,316</sup> it is now generally accepted that all teeth with a questionable prognosis must be extracted before radiotherapy.<sup>13,81,140,277</sup> The criteria suggested by Hayward et al. still appear to be suitable to determine which teeth should be removed before the start of radiotherapy.<sup>317</sup> These include<sup>3,13,25,140,149</sup>:

- advanced carious lesions with questionable pulpal status or pulpal involvement;
- moderate to advanced periodontal disease with advanced bone loss and mobility or furcation involvement;
- lack of opposing teeth and consequent loss of function and self-cleansing action;
- close proximity of teeth to tumor;
- partial impaction or incomplete eruption mostly of wisdom teeth;
- extensive periapical lesions.

To locate problems that have not been demonstrated during clinical examination X-ray films should be made in both dentulous and edentulous patients. A panoramic radiograph, when necessary supplemented by intraoral films, is most suitable for the detection of adjacent unerupted teeth, residual root tips and the presence of periodontal bone loss or periapical radiolucency.<sup>1,3,273,310</sup> The patient's periodontal status is the most important consideration in the pretreatment assessment. The presence of seriously periodontally involved teeth increases the likelihood of post-irradiation extractions, which, as mentioned earlier, are the major cause of trauma-induced osteoradionecrosis. An aggressive extraction regimen is recommended in the management of serious periodontal involvement. Furcation involvement of mandibular molars within the radiation field is ground for extraction and the same applies to periapical involvement.<sup>13,140,145,149,192</sup> Teeth within the primary beam should receive the closest scrutiny.<sup>13</sup> Deeply impacted teeth which are covered completely by bone and mucosa can usually be left in place without risk of late problems.<sup>1,3,317</sup> The patient's dental awareness is an important consideration in the evaluation for dental extractions prior to radiotherapy. Patients must possess the motivation and physical ability to maintain their dentition properly. Without the patient's help and cooperation the risk of complications is significantly increased. The less motivated the patient, the more aggressive one should be in extracting teeth prior to radiotherapy.<sup>13,22,81,192,273</sup> Other factors on which to base the decision to perform pre-irradiation extractions should be: age, general condition and life expectancy of the patient as well as prognosis, immediacy of treatment and radiation type, field and dose.<sup>13,287,318</sup> Osteoradionecrosis is observed with higher incidence after cumulative doses to the bone exceeding 65 Gy.<sup>80,126,138,149</sup>

Pre-irradiation extractions should be performed as atraumatically (careful tissue handling) as possible. According to most authors alveolotomy should be performed in order to permit primary closure of the wound without developing tension on the

soft tissues. All irregular and sharp edges must be removed to avoid future trauma to the overlying tissue. This is especially of importance for future prosthetic considerations, because negligible bone remodeling can be expected after radiotherapy and sharp ridges may increase the risk of bony exposure in a patient wearing (complete) dentures.<sup>3,22,128,149,187,287</sup> Some authors<sup>145,192</sup> recommend to do pre-irradiation extractions under antibiotic coverage, while others<sup>1</sup> mention that in the absence of infection there is no evidence that antibiotics influence healing.

Adequate healing time before radiation therapy begins is essential. Hayward et al. believed that the surface coverage of any exposed bone should be complete before radiation is begun.<sup>317</sup> Frequently suggested healing intervals ranged from 10 to 14 days,<sup>25,145,273,281,317</sup> 14 to 21 days,<sup>192</sup> up to 25 days.<sup>315</sup> Prolonged healing periods of three weeks are also reported in case of removal of impacted teeth, multiple extractions and radiation doses in excess of 65 Gy.<sup>145,281</sup> A study by Marx and Johnson has shown that removal of teeth from segments 14 days before radiation still poses a risk for osteoradionecrosis. The risk was reduced to zero if there was a 21-day or greater interval between extraction and initiation of radiation therapy.<sup>123</sup> According to several authors the extraction sites must always be carefully examined for epithelialization before radiotherapy is begun, enabling the physician to adjust the healing period for each individual patient.<sup>1,145,187</sup>

Prevention of osteoradionecrosis is linked not only to removal of potential causal factors (teeth) prior to radiation, but also to maintenance of residual teeth and periodontium. To this end, restoration of moderate caries, pre-irradiation scaling, root-planing and polishing, evaluation of dentures, oral hygiene instructions, topical fluoride carriers and other intraoral preparations are advocated to prevent caries and periodontal problems that may lead to infection or tooth loss.<sup>1,129,140,149,186,187,192</sup> In this respect it is important that regular follow-up is instituted in the post-irradiation period. According to Beumer and Brady the patient must be judiciously followed for the rest of his life.<sup>22</sup>

Extraction of teeth or wounding during radiation therapy will create an extremely high risk of osteoradionecrosis and is strongly discouraged because surgical wounding and radiation wounding are additive.<sup>123,128,140</sup>

Post-irradiation extraction is a controversial subject. Most studies have shown post-irradiation extraction of teeth from irradiated jaw segments to be the significant factor predisposing to osteoradionecrosis, and most protocols therefore aim at preventing the need for post-irradiation extraction. Evidence derived from animal studies implies that some revascularization does take place within irradiated tissue after therapy.<sup>319</sup> Indeed, several authors have reported that fewer cases of osteoradionecrosis occur after a one or two-year period has elapsed since completion of radiation therapy.<sup>128,151,281,319</sup> An attempt was thus made to defer extractions and other high risk procedures until a suitable time period had elapsed in the hope of reducing the risk of osteoradionecrosis. More recently, investigators have shown that revascularization does not occur and that the time elapsed between radiation therapy and tooth removal has little direct bearing on the occurrence of osteoradionecrosis.<sup>140,145,314</sup> In fact, according to Marx and Johnson,

the risk of osteoradionecrosis increases 6 months after radiation therapy and continues to increase with time as vascularity and tissue perfusion decrease and fibrosis increases.<sup>123</sup> In their philosophy, extraction in the early post-irradiation period would probably be most safe, because then the tissue is in its most favorable physiologic state to cope with a surgical wound.

It is suggested by most authors that, if indicated, post-irradiation extractions be performed as atraumatically as possible with radical alveolotomies, smoothing of the alveolar ridge and primary wound closure without tension.<sup>128,139,145,287,318</sup> According to Carl the number of extractions should be limited to two or three at any one time so that the already limited blood supply is not overtaxed.<sup>318</sup> Horiot et al. reported very good results with extractions under general anesthesia (no vasoconstrictive action of local anesthetic) and post-operative nasogastric tube feeding for approximately one week.<sup>271,273</sup> Antibiotic coverage is strongly recommended by almost all authors. Because of the compromised blood supply to the extraction site, higher doses than usual and longer courses of therapy were mentioned as being useful.<sup>1</sup>

Recently, evidence has been presented that hyperbaric oxygen (HBO) treatment is more beneficial than conventional antibiotic prophylaxis in preventing osteoradionecrosis (5% incidence of osteoradionecrosis versus 30%, respectively).<sup>123,308</sup> HBO therapy stimulates angiogenesis with increased neovascularization and optimization of cellular levels of oxygen for osteoblast and fibroblast proliferation, collagen formation and support of ingrowing blood vessels, thereby enhancing the healing potential in irradiated compromised tissues.<sup>309</sup> If extensive wounding or extraction in irradiated fields is necessary, HBO treatment should be used both prior to surgery and after wounding.<sup>309</sup>

As an alternative for post-irradiation extraction, many authors advocated maintenance of teeth through endodontic therapy with or without coronal recontouring (crown amputation).<sup>1,140,192</sup> It has been shown that meticulous endodontic management of teeth in previously irradiated segments did not increase the incidence of osteoradionecrosis.<sup>145,320,321</sup> However, uncovered roots left in the alveolus are still subject to periodontal disease, a condition which should not be overlooked.<sup>318</sup>

Use of dentures on irradiated tissues is another controversial issue and must be weighed carefully by the clinician. Trauma to the edentulous ridge can cause soft-tissue necrosis and may lead to osteoradionecrosis. Dentures are a potential source of this trauma.<sup>4,81</sup> It is often advised not to use existing dentures during radiotherapy, at least at night, since denture irritation to an irradiated mucosa will aggravate mucosal pain and interfere with healing.<sup>1,3,34,144,180</sup> Furthermore, denture surfaces are easily colonized with *Candida* species creating a source of infection and should thus be cleaned carefully.<sup>3,34</sup> After the initial mucosal changes have subsided, factors such as patient compliance, aptitude, adequate amount and consistency of saliva, and the presence of recent extraction sites are parameters for making decisions about denture use.<sup>76,81,137,149</sup> Patients who have worn dentures for a long time prior to radiation therapy seem to be at substantially less risk of developing radionecrosis than patients who have had pre- or post-irradiation

extractions.<sup>22,76,145</sup> The importance of sufficient alveolotomies in this respect has already been mentioned. Recommendations for the timing of placement of tissue-supported prostheses vary from author to author. Some researchers refer to a safe period that exists one month after radiation treatment during which fabrication of a denture can be carried out.<sup>287,322</sup> It is felt that subsequent vascular changes and fibrosis make prosthetic treatment on a later date more difficult. Others, especially in the older literature, have recommended waiting periods that range from one to three years.<sup>281,323-325</sup> According to Beumer et al.,<sup>145</sup> Murray et al.<sup>25</sup> and Lockhart<sup>3</sup> six months is a reasonable minimal interval to wait before placement of prostheses in patients who were edentulous and have used dentures prior to radiotherapy whereas extended periods may be necessary for selected patients who had extractions of teeth within the field of radiation. The condition of the oral cavity seems to be the best parameter in evaluating these patients. This should be done on an individual basis.<sup>81</sup>

Silicone liners have been introduced as a means to minimize mucosal trauma by mandibular dentures.<sup>323,326</sup> They present a problem in that they exhibit reduced wettability. This creates the possibility of increased friction and drag, which is heightened by the irradiation-induced hyposalivation. In addition, because of significant increase in yeast populations in patients with radiation-induced xerostomia, more rapid deterioration of silicone liners has been observed. The use of liners should therefore be discouraged.<sup>1,81,145,281</sup>

The importance of cleanliness and care of the dentures must be stressed to the patients. If any irritation develops, the dentures should be removed immediately and the mouth examined. Stringent continual aftercare is essential.<sup>81,287,322</sup>

For the treatment of osteoradionecrosis, many investigators have recommended an initial trial of conservative measures consisting of improving local oral hygiene, avoiding local irritants like alcohol and tobacco that have been proven to be important etiological factors, wound irrigation, topical and systemic antibiotics, packing with a variety of agents, and minor surgical procedures (debridement, removal of sequestered bone fragments).<sup>1,25,129,148,149,327</sup> These conservative measures were especially successful in localized cases, when the radiation dose to the bone had been relatively low, and when instituted early.<sup>126,149,314</sup> Some authors consider that aggressive surgical management is required.<sup>124</sup> Hyperbaric oxygen treatment (HBO) has been shown to be an effective adjunctive treatment for osteoradionecrosis, mostly combined with surgery.<sup>127,328,329</sup> Promising results with electromagnetic stimulation alone or in combination with HBO have also been reported.<sup>330,331</sup> A more detailed description of the treatment of osteoradionecrosis is beyond the scope of this review.

## **Taste loss**

Alteration of taste sensation occurs as a result of the direct effect of radiation on the taste buds<sup>153,157,158</sup> and from changes in the saliva.<sup>47,159</sup> In most instances taste gradually returns to normal or near-normal levels within one year after radio-

therapy.<sup>21,156,160</sup> Because of this transitory aspect most authors see no need for treatment.<sup>81,88</sup>

Some patients may be left with residual hypogeusia after radiotherapy. Zinc supplements are reported to be helpful in increasing taste acuity in such patients.<sup>155,332</sup> It is probably of more benefit in acceleration of taste improvement in the post-irradiation period than in the preservation of taste during radiotherapy.<sup>333</sup> In an uncontrolled study, Henkin treated some patients prophylactically with zinc prior to radiotherapy.<sup>332</sup> The patients reported that they experienced both less gustatory complaints and hypogeusia than nontreated patients.

Prevention of taste loss can best be accomplished through direct shielding of healthy tissue or movement outside the radiation field by means of shielding- or repositioning prostheses.<sup>80,172</sup>

Since taste loss can result in weight loss, many authors stress the importance of dietary counseling. Food with pleasing taste, color and smell and substitution of food aromas for the sense of taste may improve food intake.<sup>187,192,214</sup>

## Trismus

Trismus may be a significant sequela of radiation therapy especially in combination with tumor invasion and surgery. It is most noticeable when the muscles of mastication and the TMJ are within the field of radiation, especially when bilaterally.<sup>13</sup>

Prevention of trismus, rather than its treatment, is the most desirable objective.<sup>80,179</sup> The maximum mouth opening (interarch distance) should be measured before radiotherapy is started, and the patient and/or clinician should measure this distance frequently thereafter to assure its maintenance.<sup>80,272</sup> Patients at risk of trismus should be put on home exercises to maintain maximum opening and jaw mobility as soon as radiotherapy begins.<sup>3,21,80,81,179,187,272</sup> Dreizen et al. recommended mandibular opening exercises to prevent progressive muscle fibrosis.<sup>21</sup> Lockhart recommended the use of tongue blades or rubber stops of increasing size in addition to mandibular opening exercises.<sup>3</sup>

In patients in whom trismus has developed, the exercise program should be intensified, if necessary combined with physiotherapy to regain the lost interarch distance.<sup>21,187</sup> Prosthetic appliances (dynamic bite openers) containing springs and bands designed to restretch the muscles have been helpful in some patients.<sup>21,80,323,334</sup> Whatever the approach of this problem, patient compliance and perseverance are critical for success because dramatic results are not achieved immediately.<sup>3,272</sup>

## REFERENCES

- 1 Rothwell BR. Prevention and treatment of the orofacial complications of radiotherapy. *J Am Dent Assoc* 1987;114:316-322.
- 2 Makkonen TA. Studies on oral complications of head and neck cancer radiotherapy. *Proc Finn Dent Soc* 1988;84 suppl 4-5:1-111.



- 3 Lockhart PB. Oral complications of radiation therapy. In: Peterson DE, Elias EG, Sonis ST, eds. Head and neck management of the cancer patient. Martinus Nijhoff, Boston 1986;429-449.
- 4 Rubin RL, Doku HC. Therapeutic radiology — the modalities and their effects on oral tissues. *J Am Dent Assoc* 1976;92:731-739.
- 5 Kortekangas AE, Nordman EM, Vuotilainen A. Experience with preoperative irradiation in head and neck cancer. *Acta Otolaryngol* 1978;85:122-127.
- 6 Tong DY. Radiotherapeutic management of head and neck neoplasia. In: Peterson DE, Elias EG, Sonis ST, eds. Head and neck management of the cancer patient. Martinus Nijhoff, Boston 1986, 275-297.
- 7 Hall EJ. Radiobiology for the radiobiologist. 3rd ed. JB Lippincott Company, Philadelphia 1988, 239-259.
- 8 Rubin P, Casarett GW. Oral cavity and pharynx. In: Rubin P, Casarett GW. Clinical radiation pathology. WB Saunders Co., Philadelphia 1968, 120-152.
- 9 Blozis GG, Robinson JE. Oral tissue changes caused by radiation therapy and their management. *Dent Clin North Am* 1968;643-656.
- 10 Pyykönen JG, Malmström M, Oikarinen VJ, Salmo M, Vehkalahti M. Late effects of radiation treatment of tongue and floor-of-mouth cancer on the dentition, saliva secretion, mucous membranes and lower jaw. *Int J Oral Maxillofac Surg* 1986;15:401-409.
- 11 Spijkervet FKL, van Saene HKF, Panders AK, Vermey A, Mehta DM. Scoring irradiation mucositis in head and neck cancer patients. *J Oral Pathol Med* 1989;18:167-171.
- 12 Donaldson SS. Nutritional consequences of radiotherapy. *Cancer Res* 1977;37:2407-2413.
- 13 Beumer J, Curtis T, Harrison R. Radiation therapy of the oral cavity: Sequelae and management, Part 1. *Head Neck Surg* 1979;1:301-312.
- 14 Kirk J, Gray WM, Watson WR. Cumulative radiation effect. Part V. Time gaps in treatment regimens. *Clin Radiol* 1975;26:159-176.
- 15 Fowler JF. Potential for increasing the differential response between tumors and normal tissue: can proliferation rate be used? *Int J Radiat Oncol Biol Phys* 1986;12:641-646.
- 16 Baker DG. The radiobiological basis for tissue reactions in the oral cavity following therapeutic X-irradiation. *Arch Otolaryngol* 1982;108:21-24.
- 17 Spijkervet FKL. Irradiation mucositis and oral flora. Reduction of mucositis by selective elimination of oral flora; thesis Groningen, 1989.
- 18 White DC. An atlas of radiation histopathology. Washington DC: Technical information center, office of public affairs. U.S. Energy research and development administration, 1975:126-134.
- 19 Robinson JE. Characteristics of irradiated soft and hard tissues. *J Prosthet Dent* 1976;35:549-552.
- 20 Maxymiw WG, Wood RE. The role of dentistry in head and neck radiation therapy. *J Canadian Dent Assoc* 1989;55:193-198.
- 21 Dreizen SA, Daly TE, Drane JB, Brown LR. Oral complications of cancer radiotherapy. *Postgrad Med* 1977;61:85-92.
- 22 Beumer J, Brady FA. Dental management of the irradiated patient. *Int J Oral Surg* 1978;7:208-220.
- 23 Al-Tikriti U, Martin MV, Bramley A. A pilot study of the clinical effects of irradiation on the oral tissues. *Br J Oral Maxillofac Surg* 1984; 22:77-86.
- 24 Rubin P, Casarett GW. Clinical radiation pathology as applied to curative radiotherapy. *Cancer* 1968;22:767-778.
- 25 Murray CG, Herson J, Daly TE, Zimmerman S. Radiation necrosis of the mandible: a 10-year study. Part II. Dental factors, onset, duration and management of necrosis. *Int J Radiat Oncol Biol Phys* 1980;6:549-553.
- 26 Kashima HK, Kirkham WR, Andrews JR. Postirradiation sialadenitis: a study of the clinical features, histopathological changes, and serum enzyme variations following irradiation of human salivary glands. *Am J Roentgenol Rad Ther Nucl Med* 1965;94:271-291.
- 27 Brown LR, Dreizen S, Handler S, Johnston DA. The effect of radiation-induced xerostomia on human oral microflora. *J Dent Res* 1975;54:740-750.
- 28 Rice DH, Gill G. The effect of irradiation upon the bacterial flora in patients with head and neck cancer. *Laryngoscope* 1979;89:1839-1841.
- 29 Bernhoft CH, Skaug N. Oral findings in irradiated edentulous patients. *Int J Oral Surg* 1985;14: 416-427.
- 30 Yourassowsky E, van der Linden MP, Pardaens Y, Crokaert F, Glupczynski Y. Selection and counting of aerobic gram-negative bacilli in saliva by the spiral system. *Eur J Clin Microbiol* 1987;6:634-636.
- 31 Spijkervet FKL. Irradiation mucositis. Prevention and treatment. Munksgaard, Copenhagen, 1991.

- 32 Spijkervet FKL, van Saene HKF, van Saene JJM, Panders AK, Vermey A, Mehta DM. Mucositis prevention by selective elimination of oral flora in irradiated head and neck cancer patients. *J Oral Pathol Med* 1990;19:486–489.
- 33 Spijkervet FKL, van Saene HKF, van Saene JJM, Panders AK, Vermey A, Mehta DM, Fidler V. Effect of selective elimination of the oral flora on mucositis in irradiated head and neck cancer patients. *J Surg Oncol* 1991;46:167–173.
- 34 Epstein JB. Infection prevention in bone marrow transplantation and radiation patients. *NCI Monogr* 1990;9:73–85.
- 35 Chen TY, Webster JH. Oral monilia study on patients with head and neck cancer during radiotherapy. *Cancer* 1974;34:246–249.
- 36 Silverman S, Luangjarmekorn L, Greenspan D. Occurrence of oral candida in irradiated head and neck cancer patients. *J Oral Med* 1984;39:194–196.
- 37 Samaranayake LP, Robertson AG, MacFarlane TW, Hunter IP, MacFarlane G, Soutar DS, Ferguson MM. The effect of chlorhexidine and benzydamine mouthwashes on mucositis induced by therapeutic irradiation. *Clin Radiol* 1988;39:291–294.
- 38 Martin MV, Al-Tikriti U, Bramley PA. Yeast flora of the mouth and skin during and after irradiation for oral and laryngeal cancer. *J Med Microbiol* 1981;14:457–467.
- 39 Pau HW, Straehler-Pohl HJ, Exner M. Untersuchungen zur Sproßpilzflora während Tumor-Bestrahlungen im oberen Aerodigestivtrakt. *HNO* 1985;33:485–488.
- 40 Redding SW, Luce EB, Boren MW. Oral herpes simplex virus infection in patients receiving head and neck radiation. *Oral Surg Oral Med Oral Pathol* 1990;69:578–580.
- 41 Schneyer LH, Levin LE. Rate of salivary secretion. *J App Physiol* 1955;7:508–513.
- 42 Ferguson DB. Salivary glands and saliva. In: Lavelle CLB, ed. *Applied physiology of the mouth*. John Wright and Sons Ltd., Bristol 1975, 145–179.
- 43 Jenkins GN. *The physiology and biochemistry of the mouth*. 4th ed. Blackwell, Oxford 1978,284–359.
- 44 Zajicek G, Yagil C, Michaeli Y. The streaming submandibular gland. *Anat Rec* 1985;213:150–158.
- 45 Seifert G, Geier W. Zur Pathologie der Strahlen-Sialadenitis. *Z Laryngol Rhinol* 1971;24:376–388.
- 46 Dreyer JO, Sakuma Y, Seifert G. Die Strahlen-Sialadenitis. *Stadieneinteilung und Immunhistologie*. *Pathologie* 1989;10:165–170.
- 47 Stephens LC, Schultheiss TE, Kiang Ang K, Peters LJ. Pathogenesis of radiation injury to the salivary glands and potential methods of protection. *Cancer Bull* 1989;41:106–114.
- 48 Vissink A, 's-Gravenmade EJ, Ligeon EE, Konings AWT. Effects of split-dose X-irradiation on rat salivary gland function. *Radiat Res* 1991;127:52–57.
- 49 Norberg L, Forsberg B. Alpha-adrenergic stimulation and radiosensitivity on the rat submaxillary gland. *ORL* 1987;49:302–313.
- 50 Eneroth CM, Henrikson CO, Jakobsson PA. The effect of irradiation in high doses on parotid glands. *Acta Otolaryngol* 1971;71:349–356.
- 51 Dreizen SA, Brown LR, Handler S, Levi BM. Radiation induced xerostomia in cancer patients. *Cancer* 1976;38:273–278.
- 52 Shannon IL, Starcke EN, Wescott WB. Effect of radiotherapy on whole saliva flow. *J Dent Res* 1977;56:693.
- 53 Wescott WB, Mira JG, Starcke EN, Shannon IL, Thornby JI. Alterations in whole saliva flow rate induced by fractionated radiotherapy. *Am J Roentgenol* 1978;130:145–149.
- 54 Eneroth CM, Henrikson CO, Jakobsson PA. Effect of fractionated radiotherapy on salivary gland function. *Cancer* 1972;30:1147–1153.
- 55 Mira JG, Wescott WB, Starcke EN, Shannon IL. Some factors influencing salivary function when treating with radiotherapy. *Int J Radiol Oncol Phys* 1981;71:535–541.
- 56 Eneroth CM, Henrikson CO, Jakobsson PA. Pre-irradiation qualities of a parotid gland in predicting the grade of functional disturbance by radiotherapy. *Acta Otolaryngol* 1972;7:436–444.
- 57 Mira JG, Fullerton GD, Wescott WB. Correlation between initial salivary flow rate and radiation dose in production of xerostomia. *Acta Radiol Oncol* 1982;21:151–154.
- 58 Tsujii H. Quantitative dose-response analysis of salivary function following radiotherapy using sequential RI-sialography. *Int J Radiat Oncol Biol Phys* 1985;11:1603–1612.
- 59 Liu RP, Fleming TJ, Toth BB, Keene HJ. Salivary flow rates in patients with head and neck cancer 0.5 to 25 years after radiotherapy. *Oral Surg Oral Med Oral Pathol* 1990;70:724–729.
- 60 Cheng VST, Downs J, Herbert D, Aramany M. The function of the parotid gland following radiation therapy for head and neck cancer. *Int J Radiat Oncol Biol Phys* 1981;7:253–258.



- 61 Shannon IL, Trodahl JN, Starcke EN. Radiosensitivity of the human parotid gland. *Proc Soc Exp Biol Med* 1978;157:50-53.
- 62 Valdez IH, Atkinson JC, Ship JA, Macynski AA, Bermudez DA, Fox PC. Effects of radiotherapy on major salivary gland function. *J Dent Res* 1991;70:286.
- 63 Theuring F, Reichel G, Schmidt W. Die Wirkung von Röntgenbestrahlungen auf die Proliferationskinetik der Rattenspeicheldrüsen. *Radiobiol Radiother* 1976;3:397-404.
- 64 Schubert MM, Izutsu KT. Iatrogenic causes of salivary gland dysfunction. *J Dent Res* 1987;66:680-688.
- 65 Ben-Aryeh H, Gutman D, Szargel R, Laufer D. Effects of irradiation on saliva in cancer patients. *Int J Oral Surg* 1975;4:205-210.
- 66 Marks JE, Davis CC, Gottsman VL, Purdy JE, Lee F. The effects of radiation on parotid salivary function. *Int J Radiat Oncol Biol Phys* 1981;7:1013-1019.
- 67 Anderson MW, Izutsu KT, Rice JC. Parotid gland pathophysiology after mixed gamma and neutron irradiation of cancer patients. *Oral Surg* 1981;52:495-500.
- 68 Brown LR, Dreizen S, Rider LJ, Johnston DA. The effect of radiation-induced xerostomia on saliva and serum lysozyme and immunoglobulin levels. *Oral Surg Oral Med Oral Pathol* 1976;1:83-92.
- 69 Brown LR, Dreizen S, Daly TE, Drane JB, Handler S, Riggan LJ, Johnston DA. Interrelations of oral microorganisms, immunoglobulins, and dental caries following radiotherapy. *J Dent Res* 1978;57:882-893.
- 70 Mossman KL, Shatzman AR, Chencharick JD. Effects of radiotherapy on human parotid saliva. *Radiat Res* 1981;88:403-412.
- 71 Makkonen TA, Tenovuo J, Vilja P, Heimdahl A. Changes in the protein composition of whole saliva during radiotherapy in patients with oral or pharyngeal cancer. *Oral Surg Oral Med Oral Pathol* 1986;62:270-275.
- 72 Lory H, Dammron A, Frank RM. Les modifications de la flore buccale aérobie après radiothérapie bucco-pharyngée. *Arch Oral Biol* 1971;16:617-630.
- 73 Lory H, Dammron A, Gioanni N, Frank RM. Some population changes in oral anaerobic microorganisms, *Streptococcus mutans* and yeasts following irradiation of the salivary glands. *Caries Res* 1972;6:298-311.
- 74 Wescott WB, Starcke EN, Shannon IL. Chemical protection against postirradiation dental caries. *Oral Surg* 1975;40:709-719.
- 75 Keene HJ, Daly T, Brown LR, Dreizen S, Drane JB, Horton IM, Handler SF, Perkins DH. Dental caries and *Streptococcus mutans* prevalence in cancer patients with irradiation-induced xerostomia: 1-13 years after radiotherapy. *Caries Res* 1981;15:416-427.
- 76 Beumer J, Curtis T, Morrish R. Radiation complications in edentulous patients. *J Prosthet Dent* 1976;36:193-203.
- 77 Klestov AC, Webb J, Latt D, Schiller G, McNamara K, Young DY, Bobbes J, Fetherston J. Treatment of xerostomia: A double blind trial in 108 patients with Sjögren's syndrome. *Oral Surg* 1981;51:594-599.
- 78 Vissink A. Xerostomia. Development, properties and application of a mucin-containing saliva substitute; thesis Groningen, 1985.
- 79 Fay JT, O'Neal R. Dental responsibility for the medically compromised patient. *J Oral Med* 1984;39:218-223.
- 80 Engelmeier RL, King GE. Complications of head and neck radiation therapy and their management. *J Prosthet Dent* 1983;49:514-522.
- 81 Toljanic JA, Saunders VW. Radiation therapy and management of the irradiated patient. *J Prosthet Dent* 1984;52:852-858.
- 82 Daly TE, Drane JB. Prevention and management of dental problems in irradiated patients. *J Am Soc Prev Dent* 1976;6:21-25.
- 83 Frank RM, Herdly J, Philippe E. Acquired dental defects and salivary gland lesions after irradiation for carcinoma. *J Am Dent Assoc* 1965;70:868-883.
- 84 Dreizen SA, Brown LR, Daly TE, Drane JB. Prevention of xerostomia-related dental caries in irradiated cancer patients. *J Dent Res* 1977;56:99-104.
- 85 Del Regato JA. Dental lesions observed after roentgen therapy in cancer of the buccal cavity, pharynx and larynx. *Am J Roentgenol* 1939;42:404-410.
- 86 Cernea NMP, Bataille R. Les alterations dentaires provoquées par la radiothérapie où la curie-thérapie de la région cervicale. *Rev Stomatol* 1947;48:509-531.

- 87 Karmioli M, Walsh RF. Dental caries after radiotherapy of the oral regions. *J Am Dent Assoc* 1975;91:838–845.
- 88 Reynolds WR, Hickey AJ, Feldman MI. Dental management of the cancer patient receiving radiation therapy. *Clin Prevent Dent* 1980;2:5–9.
- 89 Daly TE. Dental care of head and neck cancer patients receiving radiation therapy. In: Chalian VA, Drane JB, Standish SM, eds. *Maxillofacial Prosthetics-multidisciplinary practice*. Williams & Wilkins, Baltimore 1972, 196–207.
- 90 Jacobson FL. Xerostomia (Sjögren's syndrome) associated with unusual dental caries. *Oral Surg* 1966;21:34–38.
- 91 Zaus E, Teuscher GW. Report on three cases of congenital dysfunction of the major salivary glands. *J Dent Res* 1940;19:326–329.
- 92 Anneroth G, Holm LE, Karlsson G. The effect of radiation on teeth. A clinical, histological and microradiographic study. *Int J Oral Surg* 1985;14:269–274.
- 93 Jongebloed WL, 's-Gravenmade EJ, Retief DH. Radiation caries. A review and SEM study. *Am J Dent* 1988;4:139–146.
- 94 Haikel J, Frank RM, Voegel JC. Scanning electron microscopy of the human enamel surface layer of incipient carious lesions. *Caries Res* 1983;17:1–13.
- 95 Jervøe P. X-ray diffraction investigation of the effect of experimental and in situ radiation on mature human teeth. A preliminary report. *Acta Odontol Scand* 1970;28:623–631.
- 96 Wiemann MR, Davis MK, Besic FC. Effects of X-radiation on enamel solubility. *J Dent Res* 1972; 51:868.
- 97 Zach GA. X-ray diffraction and calcium-phosphorus analysis of irradiated human teeth. *J Dent Res* 1976;55:907–909.
- 98 Castanera TJ, Jones DC, Kimeldorf DJ. Gross dental lesions in the rat induced by X-ray and neutrons. *Radiation Res* 1963;20:577–580.
- 99 Walker R. Direct effect of radiation on the solubility of human teeth in vitro. *J Dent Res* 1975;54: 901.
- 100 Shannon IL, Wescott WB, Starcke EN, Mira J. Laboratory study of cobalt-60-irradiated human dental enamel. *J Oral Med* 1978;33:23–27.
- 101 Joyston-Bechal S. The effect of X-radiation on the susceptibility of enamel to an artificial caries-like attack in vitro. *J Dent* 1985;13:41–44.
- 102 Markitziu A, Weshler R, Grajover M, Avital M, Gedalia A. Solubility, wear and microhardness in irradiated rat molars. *J Dent Res* 1989;68:876.
- 103 Leist M. Über Röntgenschädigung der Zähne. *Z Stomat* 1925;23:796–801.
- 104 Lüdin M, Müller O. Zahnveränderungen nach protrahiert-fraktionierter Röntgenbestrahlung. *Strahlentherapie* 1936;56:644–649.
- 105 Bianchi M. Les lésions maxillaires et dentaires consécutives à l'action des rayons X et des substances radioactives. *Schweiz Monatsschr Zahnheilk* 1943;53:1007–1077.
- 106 Poyton HG. The effects of radiation on teeth. *Oral Surg* 1968;26:639–646.
- 107 Gowgiel JM. Experimental radio-osteonecrosis of the jaws. *J Dent Res* 1960;39:176–197.
- 108 Meyer I, Shklar G, Turner JA. A comparison of the effects of 200 KV radiation and cobalt 60 radiation on the jaws and dental structure of the white rat. A preliminary report. *Oral Surg* 1962;15:1098–1099.
- 109 Hutton MF, Patterson SS, Mitchell DF, Chalian VA, Hornback NB. The effect of cobalt-60 radiation on the dental pulps of monkeys. *Oral Surg* 1974;38:279–286.
- 110 Kimeldorf DJ, Jones DC, Castanera TJ. The radiobiology of teeth. *Radiat Res* 1963;20:518–540.
- 111 Collet WK, Thonard JC. The effect of fractional radiation on dentinogenesis in the rat. *J Dent Res* 1965;44:84–90.
- 112 Nathanson A, Bäckström A. Effect of cobalt-60-irradiation on teeth and jaw bone in the rabbit. *Scand J Plast Reconstr Surg* 1977;26:639–644.
- 113 Takeda Y, Kuroda M, Amari E, Yanagisawa T. Failure of root development of human permanent teeth following irradiation. *Int J Oral Maxillofac Surg* 1987;16:376–382.
- 114 Gorlin RJ, Mishkin LH. Severe irradiation during odontogenesis. *Oral Surg* 1963;16:35–38.
- 115 Petrokovski J, Menczel J. Tooth dwarfism and root underdevelopment following irradiation. *Oral Surg* 1966;22:95–99.
- 116 Elfenbaum A. Irradiation and the developing teeth. *Dental Digest* 1972;78:199–201.
- 117 Scheibe B, Düker J, Wannemacher M. Das Zahnwurzelwachstum nach Bestrahlung. Eine tierexperimentelle Studie. *Dtsch Zahnärztl Z* 1980;35:78–81.

- 118 Silverman S, Chierici G. Radiation therapy of oral carcinoma. I. Effects on oral tissues and management of the periodontium. *J Periodontol* 1965;36:478–484.
- 119 Rohrer MD, Kim Y, Fayos JU. The effect of cobalt-60-irradiation on monkey mandibles. *Oral Surg* 1979;48:424–440.
- 120 Fujita M, Tanimoto K, Wada T. Early radiographic changes in radiation bone injury. *Oral Surg Oral Med Oral Pathol* 1986;61:641–644.
- 121 Schüle H, Betzold J. Experimentelle Untersuchungen über den Einfluss von Röntgenstrahlen auf das marginale Parodontium. *Dtsch Zahnärztl Z* 1969;24:140–143.
- 122 Kärcher H, Schmid AP. Prophylaxe und Therapie der lokalen Nebenwirkungen der Strahlenbehandlung im Kiefer- und Gesichtsbereich. *Röntgenpraxis* 1985;8:337–341.
- 123 Marx RE, Johnson RP. Studies in the radiobiology of osteoradionecrosis and their clinical significance. *Oral Surg Oral Med Oral Pathol* 1987;64:379–390.
- 124 Dolezal RF, Baker SR, Krause CJ. Treatment of the patient with extensive osteoradionecrosis of the mandible. *Arch Otolaryngol* 1982;108:179–183.
- 125 Titterington WP. Osteomyelitis and osteoradionecrosis of the jaws. *J Oral Med* 1971;26:13–17.
- 126 Morrish RB, Chan E, Silverman S, Meyler J, Fu KK, Greenspan D. Osteonecrosis in patients irradiated for head and carcinoma. *Cancer* 1981;47:1980–1983.
- 127 Marx RE. A new concept in the treatment of osteoradionecrosis. *J Oral Maxillofac Surg* 1983;41:351–357.
- 128 Marciani RD, Ownby HE. Osteoradionecrosis of the jaws. *J Oral Maxillofac Surg* 1986;44:218–223.
- 129 Kluth EV, Rani Jain P, Stuchell RN, Frich JC. A study of factors contributing to the development of osteoradionecrosis of the jaws. *J Prosthet Dent* 1988;59:194–201.
- 130 Watson WJ, Scarborough JE. Osteoradionecrosis in intraoral cancer. *Am J Roentgenol* 1938;40:524–534.
- 131 Meyer I. Osteoradionecrosis of the jaws. *Pract Dent Monographs. Year Book, Chicago* 1958.
- 132 Meyer I. Infectious diseases of the jaws. *J Oral Surg* 1970;28:17–22.
- 133 Marx RE. Osteoradionecrosis. A new concept of its pathophysiology. *J Oral Maxillofac Surg* 1983;41:283–288.
- 134 Epstein JB, Rea G, Wong FLW, Spinelli J, Stevenson-Moore P. Osteoradionecrosis: Study of the relationship of dental extractions in patients receiving radiotherapy. *Head Neck Surg* 1987;10:48–54.
- 135 Goaz PW, White SC. Radiation biology. In: Goaz PW, White SC, eds. *Oral radiology, principles and interpretation*. 2nd ed. Mosby, St. Louis 1987, 44–71.
- 136 Bras J, de Jonge HKT, van Merkesteyn JPR. Osteoradionecrosis of the mandible: pathogenesis. *Am J Otolaryngol* 1990;11:244–250.
- 137 Bedwinek JM, Schukovsky LJ, Fletcher GH, Daly TE. Osteoradionecrosis in patients treated with definitive radiotherapy for squamous cell carcinomas of the oral cavity and naso- and oropharynx. *Ther Radiol* 1976;119:665–667.
- 138 Murray CG, Herson J, Daly TE, Zimmerman S. Radiation necrosis of the mandible: a 10-year study. Part I. Factors influencing the onset of necrosis. *Int J Radiat Oncol Biol Phys* 1980;6:543–548.
- 139 Widmark G, Sagne S, Heikel P. Osteoradionecrosis of the jaws. *Int J Oral Maxillofac Surg* 1989;18:302–306.
- 140 Friedman RB. Osteoradionecrosis: causes and prevention. *NCI Monogr* 1990;9:145–149.
- 141 Murray CG, Daly TE, Zimmerman S. The relationship between dental disease and radiation necrosis of the mandible. *Oral Surg Oral Med Oral Pathol* 1980;49:99–104.
- 142 Larson DL, Lindberg RD, Lane E, Goepfert H. Major complications of radiotherapy in cancer of the oral cavity and oropharynx. A 10 year retrospective study. *Am J Surg* 1983;146:531–536.
- 143 Marunick MT, Leveque F. Osteoradionecrosis related to mastication and parafunction. *Oral Surg Oral Med Oral Pathol* 1989;68:582–585.
- 144 Curtis TA, Griffith M, Firtell DN. Complete denture prosthodontics for the radiation patient. *J Prosthet Dent* 1976;36:66–76.
- 145 Beumer J, Curtis T, Harrison R. Radiation therapy of the oral cavity: Sequelae and management, Part 2. *Head Neck Surg* 1979;1:392–408.
- 146 Wang CC. Management and prognosis of squamous cell carcinomas of the tonsillar region. *Radiology* 1972;104:667–671.
- 147 Cheng VST, Wang CC. Osteoradionecrosis of the mandible resulting from external megavoltage radiation therapy. *Radiology* 1974;112:685–689.

- 148 Epstein JB, Wong FLW, Stevenson-Moore P. Osteoradionecrosis: Clinical experience and a proposal for classification. *J Oral Maxillofac Surg* 1987;45:104–110.
- 149 Beumer J, Harrison R, Sanders B, Kurrasch M. Osteoradionecrosis: predisposing factors and outcomes of therapy. *Head Neck Surg* 1984;6:819–827.
- 150 Carl W, Schaaf NG, Sako K. Oral surgery and the patient who has had radiation therapy for head and neck cancer. *Oral Surg* 1973;36:651–657.
- 151 Beumer J, Silverman S, Benak SB. Hard and soft tissue necrosis following radiation therapy for oral cancer. *J Prosthet Dent* 1972;27:640–644.
- 152 Marciani RD, Plezia RA. Osteoradionecrosis of the mandible. *J Oral Surg* 1974;32:435–440.
- 153 Conger AD. Loss and recovery of taste acuity in patients irradiated to the oral cavity. *Radiat Res* 1973;53:338–347.
- 154 Bonanni G, Perazzi F. Variation of taste sensitivity in patients subjected to high energy irradiation for tumors of the oral cavity. *Nunt Radiol* 1965;31:383–397.
- 155 Mossman KL, Henkin RI. Radiation-induced changes in taste acuity in cancer patients. *Int J Radiat Oncol Biol Phys* 1978;4:663–670.
- 156 Mossman KL, Shatzman AR, Chencharick JD. Long-term effects of radiotherapy on taste and salivary function in man. *Int J Radiat Oncol Biol Phys* 1982;8:991–997.
- 157 Conger AD, Wells MA. Radiation and ageing effect on taste structure and function. *Radiat Res* 1969;37:31–49.
- 158 Mossman KL. Gustatory tissue injury in man: Radiation dose response relationship and mechanism of taste loss. *Br J Cancer* 1986;53:9–11.
- 159 Henkin RI, Talal N, Larson AL, Mattern CFT. Abnormalities of taste and smell in Sjögren's syndrome. *Ann Intern Med* 1972;76:375–383.
- 160 Tomita Y, Osaki T. Gustatory impairment and salivary gland pathophysiology in relation to oral cancer treatment. *Int J Oral Maxillofac Surg* 1990;19:299–304.
- 161 Bolze MS, Fosmire GJ, Stryker JA, Chung CK, Flipse BG. Taste acuity, plasma zinc levels, and weight loss during radiotherapy. A study of relationships. *Radiology* 1982;144:163–169.
- 162 Brahm RL. Intra-oral problems associated with head and neck irradiation for malignant disease in children and adolescents. *Practitioner* 1981;225:1309–1314.
- 163 Vissink A, Panders AK, 's-Gravenmade EJ, Vermey A. The causes and consequences of hyposalivation. *Ear Nose Throat J* 1988;67:166–176.
- 164 Donaldson SS, Lenon RA. Alterations of nutritional status: impact of chemotherapy and radiation therapy. *Cancer* 1979;43:2036:2052.
- 165 Bassett MR, Dobie RA. Patterns of nutritional deficiency in head and neck cancer. *Otolaryngol Head Neck Surg* 1983;91:119–125.
- 166 Wood RM, Lauder VL, Mosby EL, Hiatt WR. Nutrition and the head and neck cancer patient. *Oral Surg Oral Med Oral Pathol* 1989;68:391–395.
- 167 Copeland EM, Daly JM, Oto DM, Dudrick SJ. Nutrition, cancer and intravenous hyperalimentation. *Cancer* 1979;43:2108–2116.
- 168 Horiot JC. EORTC prospective trials of altered fractionation using multiple fractions per day (MFD). *Sonderb Strahlenther Onkol* 1987;81:135–140.
- 169 Parsons JT, Mendenhall WM, Cassisi NJ, Isaacs JH, Million RR. Hyperfractionation for head and neck cancer. *Int J Radiat Oncol Biol Phys* 1988;14:649–658.
- 170 Leslie MD, Dische S. Parotid gland function following accelerated and conventionally fractionated radiotherapy. *Radiother Oncol* (in press, 1991).
- 171 Fleming TJ, Rambach SC. A tongue shielding radiation stent. *J Prosthet Dent* 1983;49:389–390.
- 172 Epstein JB, Stafehl DM, Stevenson-Moore P. Use of intra-oral prosthesis in external beam radiation of oral and perioral cancer. *J Prosthet Dent* 1985;54:100–107.
- 173 Poole TS, Flaxman NA. Use of protective protheses during radiation therapy. *J Am Dent Assoc* 1986;11:485–488.
- 174 Anonymous. Consensus statement: Oral complications of cancer therapies. *NCI Monogr* 1990;9:3–8.
- 175 Daeffler R. Oral hygiene measures for patients with cancer (I). *Cancer Nurs* 1980;3:347–356.
- 176 Daeffler R. Oral hygiene measures for patients with cancer (II). *Cancer Nurs* 1980;3:427–432.
- 177 Daeffler R. Oral hygiene measures for patients with cancer (III). *Cancer Nurs* 1981;4:29–35.
- 178 Miaskowski C. Management of mucositis during therapy. *NCI Monogr* 1990;9:95–98.
- 179 Schaaf JE. Dealing with oral complications in irradiated cancer patients. *Alumni Bulletin I.U.S.D.* 1982;14–17(Spring).
- 180 Dodson WS. Irradiation osteomyelitis of the jaws. *J Oral Surg* 1962;20:467–474.

- 181 Bennett J. Oral care of cancer patients undergoing head and neck irradiation. *Dent Hyg (Chic)* 1979;53:209–212.
- 182 Bruya M, Powell N. Stomatitis after chemotherapy. *Am J Nurs* 1975;75:1349–1352.
- 183 Towbridge JE, Carl W. Oral care of the patient having head and neck irradiation. *Am J Nurs* 1975;75:2146–2149.
- 184 Maurer J. Providing optimal oral health. *Nurs Clin North Am* 1977;12:671–685.
- 185 Regezi JA, Courtney RM, Kerr DA. Dental management of patients irradiated for oral cancer. *Cancer* 1976;8:994–1000.
- 186 Wright WE, Haller M, Harlow SA, Pizzo PA. An oral disease prevention program for patients receiving radiation and chemotherapy. *J Am Dent Assoc* 1985;110:43–47.
- 187 Ritchie JR, Brown JR, Guerra LR, Mason G. Dental care for the irradiated cancer patient. *Quintessence Int* 1985;12:837–842.
- 188 Stalman M, van Dijk HA, Buiting-Hazelaar HG. Hebben kinderen die met cytostatica worden behandeld extra mondverzorging nodig? *Ned Tijdschr Geneesk* 1985;129:2060–2062.
- 189 Vissink A, Spijkervet FKL, Panders AK, Vermey A. Radiotherapie en mondverzorging. *Gamma* 1988;38:37–42.
- 190 van Drimmelen J, Rollins HF. Evaluation of commonly used oral hygiene agents. *Nurs Res* 1969;18:327–332.
- 191 Hickey AJ, Toth BB, Lindquist SF. Effect of intravenous hyperalimentation and oral care on the development of oral stomatitis during cancer chemotherapy. *J Prosthet Dent* 1982;47:188–193.
- 192 Lowe O. Pretreatment dental assessment and management of patients undergoing head and neck irradiation. *Clin Prevent Dent* 1986;8:24–30.
- 193 Ferraro JM. Sucralfate suspension for mouth ulcers. *Drug Intell Clin Phar* 1985;19:480.
- 194 Solomon MA. Oral sucralfate suspension for mucositis. *N Engl J Med* 1986;315:459–460.
- 195 Adams S, Toth B, Dudley BS. Evaluation of sucralfate as a compounded oral suspension for the treatment of stomatitis. *Clin Pharmacol Ther* 1985;2:178–181.
- 196 Scherlacher A, Beaufort-Spontan F. Strahlentherapie von Kopf-Hals-Malignomen: Entzündungsprophylaxe der Schleimhaut durch Sucralfatbehandlung. *HNO* 1990;38:24–28.
- 197 Barker G, Loftus L, Cuddy P, Barker B. The effects of sucralfate suspension and diphenhydramine syrup plus kaolin-pectin on radiotherapy-induced mucositis. *Oral Surg Oral Med Oral Pathol* 1991;71:288–293.
- 198 Shenep JL, Kalwinsky DK, Hutson PR, George SL, Dodge RK, Blankenship KR, Thornton D. Efficacy of oral sucralfate suspension in prevention and treatment of chemotherapy-induced mucositis. *J Pediatr* 1988;113:758–763.
- 199 Epstein JB, Stevenson-Moore P. Benzzydamine hydrochloride in prevention and management of pain in oral mucositis associated with radiation therapy. *Oral Surg Oral Med Oral Pathol* 1986;6:145–148.
- 200 Kim JH, Chu FCH, Lakshmi V, Houde R. Benzydamine HCl, a new agent for the treatment of radiation mucositis of the oropharynx. *Am J Clin Oncol* 1986;9:132–134.
- 201 Prada A, Lozza L, Moglia D, Sala L, Chiesa F. Effects of benzydamine on radio-polychemotherapeutic mucositis of the oral cavity. *Int J Tissue React* 1985;7:237–239.
- 202 Kim JH, Chu FCH, Lakshmi V, Houde R. A clinical study of benzydamine for the treatment of radiotherapy-induced mucositis of the oropharynx. *Int J Tissue React* 1985;7:215–218.
- 203 Matejka M, Nell A, Kment G, Schein A, Leukauf M, Porteder H, Mailath G, Sinzinger H. Local benefit of prostaglandin E2 in radiochemotherapy-induced oral mucositis. *Br J Oral Maxillofac Surg* 1990;28:89–91.
- 204 Mills EED. The modifying effect of beta-carotene on radiation and chemotherapy induced oral mucositis. *Br J Cancer* 1988;57:416–417.
- 205 Ferretti GA, Brown AT, Raybould TP, Lillich TT. Oral antimicrobial agents-chlorhexidine. *NCI Monogr* 1990;9:51–55.
- 206 Loë H, Schiott RC. The effect of mouthrinses and topical application of chlorhexidine on the development of dental plaque and gingivitis in man. *J Periodont Res* 1970;5:79–87.
- 207 Brown AT, Largent BA, Ferretti GA. Chemical control of plaque-dependent oral diseases: The use of chlorhexidine. *Compand Contin Educ Dent* 1987;7:719–724.
- 208 McGaw WT, Belch A. Oral complications of acute leukemia: Prophylactic impact of a chlorhexidine mouth rinse regimen. *Oral Surg Oral Med Oral Pathol* 1985;60:275–280.
- 209 Ferretti GA, Ash RC, Brown AT, Largent BM, Kaplan A, Lillich TT. Chlorhexidine for prophylaxis against oral infections and associated complications in patients receiving bone marrow transplants. *J Am Dent Assoc* 1987;114:461–467.



- 210 Ferretti GA, Raybould TP, Brown AT, MacDonald JS, Greenwood M, Maruyama Y, Geil J, Lillich TT, Ash RC. Chlorhexidine prophylaxis for chemotherapy- and radiotherapy-induced stomatitis: A randomized double-blind trial. *Oral Surg Oral Med Oral Pathol* 1990;69:331-338.
- 211 Sharon A, Berdicevsky I, Ben-Aryeh H, Gutman D. The effect of chlorhexidine mouth rinses on oral *Candida* in a group of leukemic patients. *Oral Surg Oral Med Oral Pathol* 1977;44:201-205.
- 212 Spijkervet FKL, van Saene HKF, Panders AK, Vermey A, van Saene JJM, Mehta DM, Fidler V. Effect of chlorhexidine on the oropharyngeal ecology in patients with head and neck cancer who have irradiation mucositis. *Oral Surg Oral Med Oral Pathol* 1989;67:154-161.
- 213 Pelham M, Polunsky B. Feeding head and neck patients undergoing radiation therapy. In: Fletcher GH, ed. *Textbook of radiotherapy*. 2nd ed. Lea and Febiger, Philadelphia 1973,152-156.
- 214 Johnson CH. Nutritional care of cancer patients receiving radiotherapy. In: Fletcher GH, ed. *Textbook of radiotherapy*. 3rd ed. Lea and Febiger, Philadelphia 1980,92-102.
- 215 Suit HD. The scope of the problem of primary tumor control. *Cancer* 1988;61:2141-2147.
- 216 Karim ABMF, Yap LY, Njo KH, Hasman A, Tabak JM. Ervaringen in het Academisch Ziekenhuis der Vrije Universiteit bij de behandeling van patiënten met late stadia hoofd/halscarcinoom met "meerdere fracties per dag" radiotherapie. *Ned Tijdschr Geneesk* 1985;48:2335-2336.
- 217 Wambersie A, Richard F. Problèmes poses par l'irradiation des tumeurs endobuccales. *Acta Stomatol Belg* 1979;6:209-226.
- 218 Bourdin S, Desson P. Prévention de la xérostomie post-radique par la transportation d'une glande sous-maxillaire. *Ann Otolaryngol Chir Cervicofac* 1982;99:265-268.
- 219 Sodicoff M, Conger AD, Trepper P, Pratt NE. Short-term protective effects of WR-2721 on rat parotid gland. *Radiat Res* 1978;75:317-326.
- 220 Sodicoff M, Conger AD, Pratt NE, Trepper P. Radioprotection by WR-2721 against long-term chronic damage to the rat parotid gland. *Radiat Res* 1978;76:172-179.
- 221 Sodicoff M, Conger AD, Pratt NE. Isoproterenol in comparison to WR-2721 as a chemoradioprotector of the rat parotid gland. *Invest Radiol* 1979;14:166-170.
- 222 Utley JF, Quinn CA, White FC, Seaver NA, Bloor CM. Protection of normal tissue against late radiation injury by WR-2721. *Radiat Res* 1981;85:408-415.
- 223 Glover D, Negendank W, Delivorva-Papadopoulos M, Glick JH. Alterations in oxygen transport following WR-2721. *Int J Radiat Oncol Biol Phys* 1984;10:1565-1568.
- 224 Lespinasse F, Oiry J, Fatome M, Ardain P, Imbach J, Malaise EP, Guichard M. Radioprotection of EMT G tumor by a new class of radioprotectors based on a pseudo-peptide cysteamine combination. *Int J Radiat Oncol Biol Phys* 1985;11:1035-1038.
- 225 Sodicoff M, Conger AD. Radioprotection of the rat parotid gland by cAMP. *Radiat Res* 1983;96:90-94.
- 226 Conger AD, Sodicoff M, Samel A. Comparison of cAMP with other radioprotectors against chronic damage to the rat parotid gland. *Radiat Res* 1985;102:99-105.
- 227 Goldberg RI. Protection of irradiated parotid by prostaglandin synthesis inhibitors. *J Am Dent Assoc* 1986;112:179-181.
- 228 Pillsbury HC, Webster WP, Rosenman J. Prostaglandin inhibitor and radiotherapy in advanced head and neck cancers. *Arch Otolaryngol Head Neck Surg* 1986;112:552-553.
- 229 Greenspan D. Management of salivary dysfunction. *NCI Monogr* 1990;9:159-161.
- 230 Jongkees LBW. Over oorsuizen, droge mond, keelpijn en de dingen die niet voorbij gaan. *Ned Tijdschr Geneesk* 1982;126:2332-2334.
- 231 DeBuck R, Titeca R, Pelc I. Controlled study of the action of anetholetrithione (sulfarlem) on asialia and hyposialia due to psychotropic drugs. *Acta Psychiatr Belg* 1973;73:510-519.
- 232 Hassenstein E, Muller R, Reinhard HJ. Effect of SL25 on radiogenic xerostomia in the radiotherapy of tumors in the region of neck and face. *Strahlentherapie* 1978;154:554-558.
- 233 Schiødt M, Oxholm P, Jacobson A. Treatment of xerostomia in patients with primary Sjögren's syndrome with Sulfarlem. *Scand J Rheumatol Suppl* 1986;61:250-252.
- 234 Epstein JB, Decoteau WE, Wilkinson A. Effects of Sialor in treatment of xerostomia in Sjögren's syndrome. *Oral Surg Oral Med Oral Pathol* 1983;56:495-499.
- 235 Fox PC. Systemic therapy of salivary gland hypofunction. A six month trial. *J Dent Res (spec iss)* 1987;66:689-692.
- 236 Fox PC, van der Ven PF, Baum BJ, Mandel D. Pilocarpine for the treatment of xerostomia associated with salivary gland dysfunction. *Oral Surg Oral Med Oral Pathol* 1986;61:243-245.
- 237 Fox PC, Atkinson JC, Macynski A, Wolff DS, Kung J, Shiroky H, Jackson BJ. Pilocarpine for the treatment of salivary hypofunction. *Abstr 1017. J Dent Res* 1989;68:315.

- 238 Greenspan D, Daniels TE. Effectiveness of pilocarpine in postradiation xerostomia. *Cancer* 1987; 59:1123–1125.
- 239 Epstein JB, Schubert MM. Synergistic effect of sialogogues in management of xerostomia after radiation therapy. *Oral Surg Oral Med Oral Pathol* 1987;64:179–182.
- 240 von Hornstein OP. Chronische Mundtrockenheit - klinische und therapeutische Probleme. *Dtsch Z Mund Kiefer Gesichtschir* 1981;5:14–20.
- 241 Weiss WW, Brenman HS, Katz P, Bennett JA. Use of an electronic stimulator for the treatment of dry mouth. *J Oral Maxillofac Surg* 1986;44:845–850.
- 242 Fine L. Dental care of the radiated patient. *J Hosp Dent Pract* 1975;9:127–132.
- 243 Halpern IL, Freedman AL. Dental management of the irradiated patient. *Dent Survey* 1975;51:18–23.
- 244 Bakdash MB. Oral management of patients with xerostomia. *Quintessence Int* 1976;7:1–5.
- 245 Ettinger RL. Xerostomia – a complication of ageing. *Aust Dent J* 1981;26:365–371.
- 246 Smith QT. Xerostomia and salivary substitutes. *Northwest Dent* 1981;60:90–93.
- 247 Peterson DE, Sonis ST. Oral complications of cancer chemotherapy. Martinus Nijhoff, The Hague 1983,151–168.
- 248 's-Gravenmade EJ, Vissink A, Panders AK, Vermey A. Artificial saliva in the management of patients suffering from xerostomia. *Gerodontology* 1984;3:243–250.
- 249 's-Gravenmade EJ, Vissink A, Panders AK, Visch LL, Vermey A. Mucin-containing artificial saliva and the management of cancer of the oral cavity. *J Exp Clin Canc Res* 1984;3:161–167.
- 250 's-Gravenmade EJ, Panders AK. Clinical applications of saliva substitutes. In: Ferguson DB, ed. *The environment of the teeth*. Karger, Basel etc. 1981,154–161.
- 251 Remick RA, Blasberg B, Patterson BD, Carmichael RP, Miles JE. Clinical aspects of xerostomia. *J Clin Psychiatry* 1983;44:63–65.
- 252 Mason DK, Chisholm DM. *Salivary glands in health and disease*. Saunders, London etc. 1975,119–137.
- 253 Wiesenfeld D, Stewart AM, Mason DK. A critical assessment of oral lubricants in patients with xerostomia. *Br Dent J* 1983;155:155–157.
- 254 Matzker J, Schreiber J. Synthetischer Speichel zur Therapie der Hyposalien insbesondere bei der radiogenen Sialadenitis. *Z Laryngol Rinol Otol* 1972;51:422–428.
- 255 Shannon IL, McCrary BR, Starcke EN. A saliva substitute for use by xerostomic patients undergoing radiotherapy to the head and neck. *Oral Surg* 1977;44:656–661.
- 256 Shannon IL, Trodahl JN, Starcke EN. Remineralization of enamel by a saliva substitute designed for use by irradiated patients. *Cancer* 1978;41:1746–1750.
- 257 's-Gravenmade EJ, Roukema DA, Panders AK. The effects of mucin-containing artificial saliva on severe xerostomia. *Int J Oral Surg* 1974;3:435–439.
- 258 Vissink A, 's-Gravenmade EJ, Panders AK, Vermey A, Petersen JK, Visch LL, Schaub RMH. A clinical comparison between commercially available mucin- and CMC-containing saliva substitutes. *Int J Oral Surg* 1983;12:232–238.
- 259 Visch LL, 's-Gravenmade EJ, Schaub RMH, van Putten WLJ, Vissink A. A double-blind crossover trial of CMC- and mucin-containing saliva substitutes. *Int J Oral Maxillofac Surg* 1986;15:395–400.
- 260 Weerkamp AH, Wagner K, Vissink A, 's-Gravenmade EJ. Effect of the application of a mucin-based saliva substitute on the oral microflora of xerostomic patients. *J Oral Pathol* 1987;16:474–478.
- 261 Vissink A, Schaub RMH, van Rijn LJ, 's-Gravenmade EJ, Panders AK, Vermey A. The efficacy of mucin-containing artificial saliva in alleviating symptoms of xerostomia. *Gerodontology* 1987;6:95–101.
- 262 Vissink A, 's-Gravenmade EJ, Panders AK, Vermey A. Treatment of hyposalivation. *Ear Nose Throat J* 1988;67:179–185.
- 263 Vergo TJ, Kadish SP. Dentures as artificial saliva reservoirs in irradiated edentulous patients with xerostomia: A pilot study. *Oral Surg* 1981;51:229–234.
- 264 Toljanic JA, Zucuskie TG. Use of a palatal reservoir in denture patients with xerostomia. *J Prosthet Dent* 1984;52:540–545.
- 265 Vissink A, 's-Gravenmade EJ, Panders AK, Olthof A, Vermey A, Huisman MC, Visch LL. Artificial saliva reservoirs. *J Prosthet Dent* 1984;52:710–715.
- 266 Vissink A, Huisman MC, 's-Gravenmade EJ. Construction of an artificial saliva reservoir in an existing upper denture. *J Prosthet Dent* 1986;56:70–74.
- 267 's-Gravenmade EJ, Vissink A. Mucin-containing lozenges in the treatment of intra-oral problems associated with Sjögren's syndrome. *Oral Surg Oral Med Oral Pathol* (submitted, 1991).

- 268 Martin HE, Sugarbaker EL. Cancer of the floor of the mouth. *Surgery Gynec Obstet* 1940;71:347–359.
- 269 Frisch J, Sproull R. Dental treatment after irradiation. *J Prosthet Dent* 1962;12:182–189.
- 270 Daly TE, Drane JB, MacComb WS. Management of problems of the teeth and jaws in patients undergoing irradiation. *Am J Surg* 1972;124:539–542.
- 271 Horiot JC, Schraub S, Bone MC, Bain Y, Ramadier J, Chaplain G, Nabid N, Thevenot B, Bransfield D. Dental preservation in patients irradiated for head and neck tumors: a 10-year experience with topical fluoride and a randomized trial between two fluoridation methods. *Radiother Oncol* 1983;1:77–82.
- 272 Daly TE, Drane JB. Management of teeth related to the treatment of oral cancer. *National Cancer Conference Proceedings* 7. American Cancer Society, New York 1973,147–151.
- 273 Horiot JC, Bone MC, Ibrahim E, Castro JR. Systematic dental management in head and neck irradiation. *Int J Radiat Oncol Biol Phys* 1981;7:1025–1029.
- 274 Keene HJ, Fleming TJ. Prevalence of caries-associated microflora after radiotherapy in patients with cancer of the head and neck. *Oral Surg Oral Med Oral Pathol* 1987;64:421–426.
- 275 Geddes DAM, Rølla G. Fluoride in saliva and dental plaque. In: Ekstrand J, Fejerskov O, Silverstone LM, eds. *Fluoride in dentistry*. 1st ed. Munksgaard, Copenhagen 1988,60–76.
- 276 Carl W, Schaaf NG, Chen TY. Oral care of patients irradiated for cancer of the head and neck. *Cancer* 1972;30:448–453.
- 277 Keys HM, McCasland JP. Techniques and results of a comprehensive dental care program in head and neck cancer patients. *Int J Radiat Oncol Biol Phys* 1976;1:859–865.
- 278 Johansen E, Olsen TO. Topical fluorides in the prevention and arrest of dental caries. In: Johansen E, Taves DR, Olsen TO, eds. *Continuing evaluation of the use of fluorides*. Boulder, Colorado: Westview Press 1979,61–110.
- 279 Hutton J, Koulourides T, Borden L. Evaluation of cariostatic disciplines for postradiation caries. *Caries Res* 1982;16:390–397.
- 280 Makkonen TA, Tenuvuo J, Vilja P, Heimdahl A. Changes in the protein composition of whole saliva during radiotherapy in patients with oral or pharyngeal cancer. *Oral Surg Oral Med Oral Pathol* 1986;62:270–275.
- 281 Daly TE, Drane JB. *Management of dental problems in irradiated patients*. University of Texas Press, Houston, 1972.
- 282 Rølla G. Effects of fluoride on initiation of plaque formation. *Caries Res* 1977;11:243–261(Suppl 1).
- 283 Tinanoff N, Hock J, Camosci D, Hellden L. Effect of stannous fluoride mouthrinse on dental plaque formation. *J Clin Periodontol* 1980;7:232–241.
- 284 Mazza JE, Newman MG, Sims TN. Clinical and antimicrobial effect of stannous fluoride on periodontitis. *J Clin Periodontol* 1981;8:203–212.
- 285 Fleming TJ. The use of topical fluoride by patients receiving cancer therapy. *Curr Probl Cancer* 1983;7:37–41.
- 286 Myers RE, Mitchell DL. Fluoride for the head and neck radiation patient. *Military Medicine* 1988;153:411–413.
- 287 Carl W, Schaaf NG. Dental care for the cancer patient. *J Surg Oncol* 1974;6:293–310.
- 288 Tatum RC, Daniels R. The correlation of radiotherapy to salivary gland reduction and increased caries incidence. A caries control method. *Quintessence Int* 1982;1:9–11.
- 289 Ferretti GA, Tanzer JM, Tinanoff N. The effect of fluoride and stannous ions on *Streptococcus mutans* viability, growth, acid, glucan production and adherence. *Caries Res* 1982;16:298–307.
- 290 Brown LR, White JO, Horton IM, Dreizen S, Streckfuss JL. Effect of continuous fluoride gel use on plaque fluoride retention and microbial activity. *J Dent Res* 1983;62:746–751.
- 291 Tinanoff N. Stannous fluoride in clinical dentistry. In: Wei SHY, ed. *Clinical uses of fluorides*. Lea and Febiger, Philadelphia 1985,25–34.
- 292 Koulourides T, Cameron B. Enamel remineralization as a factor in the pathogenesis of dental caries. *J Oral Pathol* 1980;9:255–269.
- 293 Szpirglas J, Tsamis J, Piade R. Prophylaxie des complications buccodentaires de l'irradiation des tumeurs cervico-faciales par la fluoruration topique. *L'information Dentaire* 1979;1:33–34.
- 294 Mignon H, Labayle J, Dahan S, Lachman M. Préparation des bouches avant irradiation pour cancers cervicofaciaux. Prophylaxie fluorée des lésions dentaires. *Ann Otolaryngol* 1980;97:501–504.
- 295 Love WD. Fluoride therapy in clinical practice. *Dent Clin North Am* 1984;28:611–629.
- 296 Vissink A, 's-Gravenmade EJ, Gelhard TBFM, Panders AK, Franken MH. Rehardening properties of mucin- or CMC-containing saliva substitutes on softened human enamel. Effects of sorbitol, xylitol and increasing viscosity. *Caries Res* 1985;19:212–218.



- 297 Katz S. The use of fluoride and chlorhexidine for the prevention of radiation caries. *J Am Dent Assoc* 1982;104:164-170.
- 298 Epstein JB, Loh R, Stevenson-Moore P, McBride BC, Spinelli J. Chlorhexidine rinse in prevention of dental caries in patients following radiation therapy. *Oral Surg Oral Med Oral Pathol* 1989;68:401-405.
- 299 Epstein JB, McBride BC, Stevenson-Moore P, Merilees H, Spinelli J. The efficacy of chlorhexidine gel in reduction of *Streptococcus mutans* and *Lactobacillus* species in patients treated with radiation therapy. *Oral Surg Oral Med Oral Pathol* 1991;71:172-178.
- 300 Emilson CG. Susceptibility of various microorganisms to chlorhexidine. *Scand J Dent Res* 1977;85:255-265.
- 301 Emilson CG. Effect of chlorhexidine gel treatment on *Streptococcus mutans* population in human saliva and dental plaque. *Scand J Dent Res* 1981;89:239-246.
- 302 Zickert I, Emilson CG, Ekblom K, Krasse B. Prolonged oral reduction of *Streptococcus mutans* in humans after chlorhexidine desinfection followed by fluoride treatment. *Scand J Dent Res* 1987;95:315-319.
- 303 Coffin F. The control of radiation caries. *British J Radiol* 1973;46:365-368.
- 304 Coffin F. The management of radiation caries. *British J Oral Surg* 1973;11:54-59.
- 305 Carpenter JS. Dental care for children who have received head and neck therapeutic radiation. *J Pedodont* 1978;3:36-51.
- 306 Hazra TA, Shipman B. Dental problems in pediatric patients with head and neck tumors undergoing multiple modality therapy. *Medical and Pediatric Oncology* 1982;10:91-95.
- 307 Wright WE. Pretreatment oral health care interventions for radiation patients. *NCI Monogr* 1990;9:57-59.
- 308 Marx RE, Johnson RP, Kline SN. Prevention of osteoradionecrosis: A randomized prospective clinical trial of hyperbaric oxygen versus penicillin. *J Am Dent Assoc* 1985;111:49-54.
- 309 Myers RAM, Marx RE. Use of hyperbaric oxygen in postradiation head and neck surgery. *NCI Monogr* 1990;9:151-157.
- 310 Stevenson-Moore P. Essential aspects of a pretreatment oral examination. *NCI Monogr* 1990;9:33-36.
- 311 Sonis ST, Woods PD, White A. Pretreatment oral assessment. *NCI Monogr* 1990;9:29-32.
- 312 MacComb WS. Necrosis in treatment of intraoral cancer by radiation therapy. *Am J Roentgenol* 1962;87:431-440.
- 313 Beumer J, Harrison R, Sanders B, Kurrasch M. Preradiation dental extractions and the incidence of bone necrosis. *Head Neck Surg* 1983;5:514-521.
- 314 Beumer J, Harrison R, Sanders B, Kurrasch M. Postradiation dental extractions: A review of the literature and a report of 72 episodes. *Head Neck Surg* 1983;6:581-586.
- 315 Starcke EN, Shannon IL. How critical is the interval between extractions and irradiation in patients with head and neck malignancy. *Oral Surg Oral Med Oral Pathol* 1977;43:333-337.
- 316 Makkonen TA, Kiminki A, Makkonen TK, Nordman E. Dental extractions in relation to radiation therapy of 224 patients. *Int J Oral Maxillofac Surg* 1987;16:56-64.
- 317 Hayward JR, Kerr DA, Jesse RH, Lampe I, Ingle JJ. The management of teeth related to the treatment of oral cancer. *Cancer* 1969;19:98-106.
- 318 Carl W. Dental management of head and neck cancer patients. *J Surg Oncol* 1980;15:265-281.
- 319 Hoffmeister FS, Macomber WB, Wang MK. Radiation in dentistry - surgical comments. *J Am Dent Assoc* 1969;78:511-516.
- 320 Cox FL. Endodontics and the irradiated patient. *Oral Surg* 1976;42:679-684.
- 321 Seto BG, Beumer J, Kagawa T, Klokkevold P, Wolinsky L. Analysis of endodontic therapy in patients irradiated for head and neck cancer. *Oral Surg Oral Med Oral Pathol* 1985;60:540-545.
- 322 Behesti N, Javid N. Oral tissue and irradiation therapy. *Israel J Dent Med* 1978;27:31-35.
- 323 Rahn AO, Matalon V, Drane JB. Prosthetic evaluation of patients who have received irradiation to the head and neck region. *J Prosthet Dent* 1968;19:174-179.
- 324 King RE, Elzay RP, Prentiss MD. Effects of ionizing radiation in the human oral cavity and oropharynx. *Radiology* 1968;91:1001-1007.
- 325 Krajicek DD. Oral radiation in prosthodontics. *J Am Dent Assoc* 1969;79:320-322.
- 326 Griem ML, Robinson JE, Barnhart GW. The use of a soft denture-base material in the management of postradiation denture problems. *Radiology* 1964;82:320-321.
- 327 Hahn G, Gorgill DA. Conservative treatment of radionecrosis of the mandible. *Oral Surg* 1967;24:701-711.

- 328 Hart GB, Mainous EG. The treatment of radiation necrosis with hyperbaric oxygen (HBO). *Cancer* 1976;37:2580–2585.
- 329 van Merkesteyn JPR, Bakker DJ, Dellelijn HL. The use of hyperbaric oxygen in the treatment of osteomyelitis and osteoradionecrosis of the jaw. In: Bakker DJ, Schmutz J, eds. *Proc 2nd European Conf on Hyperbaric Med. Foundation for hyperbaric medicine, Basel 1990*,151–154.
- 330 Barak S, Rosenblum I, Czerniak P, Arieli J. Treatment of osteoradionecrosis combined with pathologic fracture and osteomyelitis of the mandible with electromagnetic stimulation. *Int J Oral Maxillofac Surg* 1988;17:253–256.
- 331 King GE, Scheetz J, Jacob RF, Martin JW. Electrotherapy and hyperbaric oxygen: Promising treatments for postradiation complications. *J Prosthet Dent* 1989;62:331–334.
- 332 Henkin RI. Prevention and treatment of hypogeusia due to head and neck irradiation. *J Am Med Assoc* 1972;220:870–871.
- 333 Silverman JE, Weber CW, Silverman S, Coulthard SL, Manning MR. Zinc supplementation and taste in head and neck cancer patients undergoing radiation therapy. *J Oral Med* 1983;38:14–16.
- 334 Kropmans ThJB, Dijkstra PU, Tamminga RYJ. Modified use of a dynamic bite opener: Treatment and prevention of trismus in a child with head and neck cancer. *J Craniomand Prat* (submitted, 1991).
- 335 Seifert G, Donath K. Die Morphologie der Speicheldrüsenerkrankungen. *Arch Otorhinolaryngol* 1976;213:111–208.
- 336 Ernst H, Koppenhagen K, Ziegast J. Strahlenreaktion und Strahlenfolgen an den Kopfspeicheldrüsen. *Strahlentherapie* 1977;153:9–12.
- 337 Haubrich J. Etiology and pathogenesis of the inflammatory diseases of the cephalic salivary glands. *Adv Otolaryngol* 1981;26:39–48.

## Chapter 3

### **RADIATION CARIES: IN VITRO AND IN SITU EXPERIMENTS**

---

This chapter is based on the following publications:

Jansma J, Buskes JAKM, Vissink A, Mehta DM, 's-Gravenmade EJ. The effect of X-ray irradiation on the demineralization of bovine dental enamel. A constant composition study. *Caries Res* 1988;22:199–203;

Jansma J, Borggreven JMPM, Driessens FCM, 's-Gravenmade EJ. The effect of X-ray irradiation on the permeability of bovine dental enamel. *Caries Res* 1990;24:164–168;

Jansma J, Vissink A, 's-Gravenmade EJ, de Josselin de Jong E, Jongebloed WL, Retief DH. A model to investigate xerostomia-related dental caries. *Caries Res* 1988;22:357–361;

Jansma J, Vissink A, Jongebloed WL, Retief DH, 's-Gravenmade EJ. A SEM study of natural and induced radiation caries. *Am J Dent* (submitted, 1991);

Jansma J, Vissink A, 's-Gravenmade EJ, Visch LL, Fidler V, Retief DH. In vivo study on the prevention of radiation caries. *Caries Res* 1989;23:172–178.

All papers have been reprinted with permission of the publisher.

# THE EFFECT OF X-RAY IRRADIATION ON THE DEMINERALIZATION OF BOVINE DENTAL ENAMEL

## INTRODUCTION

In patients receiving irradiation therapy for malignancies of the head and neck region a highly destructive form of dental caries is frequently observed.<sup>1,2</sup> In general a pronounced hyposalivation is considered to be the most important etiological factor. The reduction in salivary flow results in a loss of the protective properties of saliva, a decrease of the pH of saliva and a quantitative and qualitative shift in oral microflora. This shift in microflora often occurs in combination with a change in the pattern of food consumption to frequent, sticky, high-carbohydrate meals.<sup>1-7</sup>

X-ray irradiation could also change the enamel susceptibility to acid dissolution by affecting the enamel structure. Results from literature are contradictory.<sup>6,8-13</sup> The reason for this contradiction of data may be the variable concentration conditions under which the demineralization studies on irradiated dental enamel were performed. For this reason these studies are incomparable and non-reproducible.

In this study a constant composition technique<sup>14</sup> was chosen for demineralization of enamel for three main reasons: (1) during artificial lesion formation the composition of the demineralization solution remains constant, providing a reproducible method; (2) the constant composition renders a constant driving force for demineralization; (3) the liquid flowing across the enamel specimens imitates the constant salivary flow in the oral situation.

For practical reasons the demineralization process was investigated in a solution containing methylhydroxydiphosphonate (MHDP), which inhibited demineralization and induced the formation of subsurface lesions *in vitro*.<sup>15-17</sup> Demineralization of irradiated enamel in the absence of MHDP was also performed to exclude possible effects of MHDP on the surface layer formation.<sup>16</sup> The aim of this *in vitro* study was to investigate the effect of X-ray irradiation on demineralization of bovine dental enamel under constant composition conditions.

## MATERIALS AND METHODS

*Enamel specimens preparation.* Labial enamel surfaces of freshly extracted mature bovine incisors, that contain more enamel mass, are more homogeneous and contain less fluoride than human teeth, were partially ground flat (Siawat grit 600) and cut in rectangles by means of a water-cooled diamond saw. After carefully checking for the presence of preparation damage or lesions, the enamel specimens were embedded in polymethylmethacrylate (de Trey) and polished with grinding paper (Siawat grit 800). Subsequently, they were cleaned ultrasonically in tap water for

ten minutes.

The embedded specimens ( $n=56$ ) were divided at random into four groups. Two groups were irradiated, two others served as nonirradiated control groups.

*X-ray irradiation.* To approach oral circumstances during irradiation, the embedded enamel specimens were immersed in an open glass container under 2 cm of water and the irradiation was carried out fractionally. All samples were irradiated twice daily with 2 Gy, during a period of 18 days. The cumulative dose was 72 Gy (Linac, 8 MV photon irradiation, source to specimen distance 100 cm, field size  $15 \times 15$  cm).

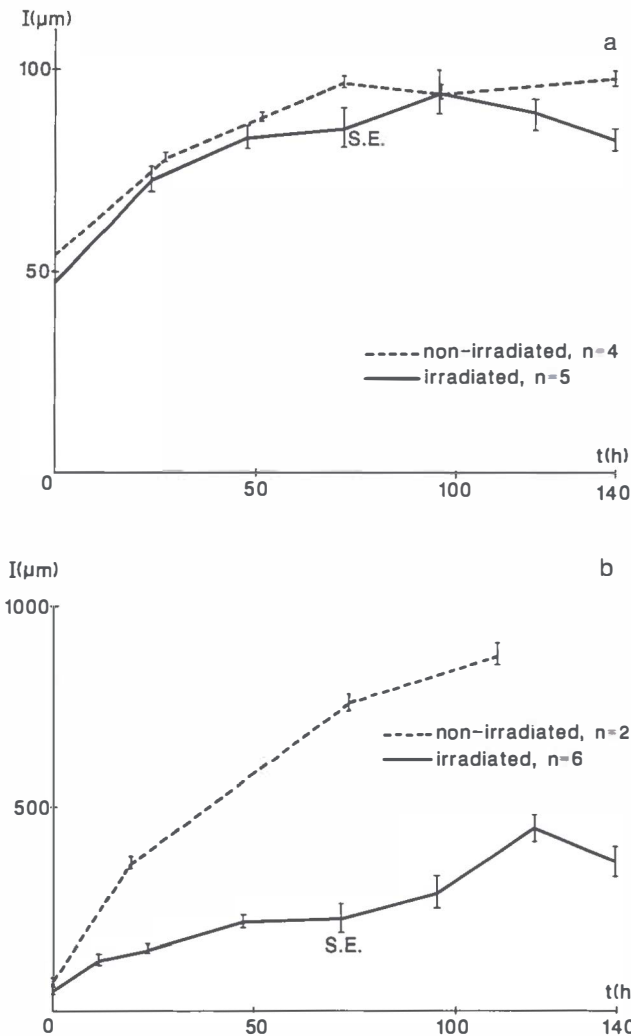
After irradiation all control and irradiated enamel surfaces were partially covered with nail varnish in order to preserve an internal control area.

*Demineralization.* The irradiated and control specimens were demineralized as described by Buskes et al.<sup>14</sup> Artificial lesions were produced by means of an acidic solution of 10 litres containing 3 mM  $\text{CaCl}_2 \cdot 2\text{H}_2\text{O}$ , 3 mM  $\text{KH}_2\text{PO}_4$  and 50 mM  $\text{CH}_3\text{COOH}$ . The solution was buffered by adding 48 ml 10 M KOH; the pH of the solution was 5. A trace of thymol (Reinst) was added as a fungistat. All chemicals used were of pA purity from Merck. One group of control and one group of irradiated specimens were demineralized in the same acidic solution containing supplementary 6  $\mu\text{M}$ -MHDP (Procter & Gamble). The specimens of the other two groups were demineralized in the acid solution without MHDP.

*Hardness measurements.* To check changes caused by demineralization in the outer enamel surface, microhardness measurements were performed with a Leitz miniload hardness tester with a Knoop diamond at a load of 50 g. Ten indentations were made perpendicular to the enamel surface (a) before irradiation, (b) immediately after irradiation ( $t=0$  h) and (c) longitudinally during demineralization ( $t=24, 48, 72, 96, 120$  and 140 h).

*Microradiography.* The microradiographic method of de Josselin de Jong and ten Bosch<sup>18,19</sup> was applied to determine the type of lesion, its depth and the mineral loss  $\Delta Z$ . The lesion depth is defined as the distance from the enamel surface to the point where the mineral volume differs more than 5% from that of sound enamel. After 48 and 96 h and at the end of each experiment (140 h) microradiograms were made. For this purpose the enamel specimens were sectioned with a water-cooled diamond saw in two or three slices of 600  $\mu\text{m}$  thickness. The slices were polished on grinding paper (Siawat grit 800) to a thickness of  $80 \pm 10$   $\mu\text{m}$  measured with a micrometer gauge. Microradiograms were made on photographic film (Kodak SO-253) with a  $\text{Cu-K}\alpha$  source (Philips X-ray diffractometer PW 1730). After development the film was scanned on a microdensitometer (Leitz MPV) connected to a microcomputer (Apple II<sup>+</sup>). Each microradiogram was scanned at three different spots. Two tracings were chosen at random in the demineralized area, one was made in the nondemineralized control area.

*X-ray diffraction.* To investigate possible changes of the crystalline structure of enamel caused by irradiation, an X-ray diffraction study was performed. For this purpose labial enamel of ten caries-free bovine incisors was pulverized. The powder was divided into two equal portions of which diffractograms were made by using an



**Fig. 1** Microhardness indentation length (I) as a function of demineralization time for the irradiated and control specimens in the presence of 6 μM MHDP (A) and without MHDP (B). Each value is an average of n enamel specimens. Ten indentations were made on each specimen. SE is standard error.

X-ray diffractometer with filtered Cu-Kα radiation (Philips X-ray diffractometer PW 1730). Subsequently, without changing the orientation of the enamel granules, a single dose irradiation was achieved (Orthovolt, 125 kV, 23 mA, total dose 72 Gy) and the diffraction study repeated.

*Scanning electron microscopy.* From each labial enamel surface of three mature bovine incisors, which were prepared as before ('enamel specimens preparation'), two blocks were cut out. From the resulting six blocks, three were irradiated (Or-

thovolt, 125 kV, 23 mA, total dose 72 Gy), the three others served as controls. Of all blocks SEM pictures were taken to determine changes at the crystalline level. For this purpose the enamel specimens were broken and cleaned with freon. Subsequently a thin Au-layer (approx. 12.5 nm) was sputtered on the broken specimens. With a JEOL-35C Scanning Electron Microscope, operated at 25 kV, scanning micrographs were taken at various magnifications.

**Table 1** Mineral loss and lesion depth of the irradiated and non-irradiated enamel specimens after various demineralization periods (mean  $\pm$  SD)

Time, h	X-ray	$\Delta Z$ , kg.m <sup>-2</sup>	$l_d$ , $\mu$ m	n
48	+	0.029 $\pm$ 0.020	30 $\pm$ 15	16
	-	0.047 $\pm$ 0.007	42 $\pm$ 3	15
96	+	0.050 $\pm$ 0.030	53 $\pm$ 21	11
	-	—	—	—
140	+	0.044 $\pm$ 0.030	51 $\pm$ 27	25
	-	0.093 $\pm$ 0.018	90 $\pm$ 15	25

$\Delta Z$  = mineral loss;  $l_d$  = lesion depth; + = irradiated; - = non-irradiated. Demineralization was performed in a solution as described under Materials and Methods containing supplementary 6  $\mu$ M MHDP; n denotes the number of tracings.

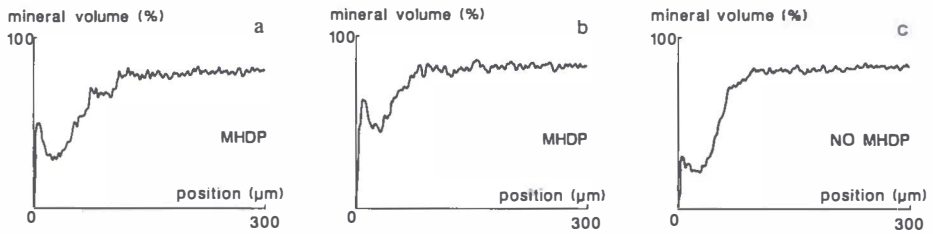
## RESULTS

In figure 1 the results of the microhardness tests are given. Specimens demineralized in an acid solution containing MHDP showed no significant differences. The microhardness data for irradiated and control enamel specimens demineralized in an acid solution without MHDP were significantly different ( $p < 0.001$ , t-test).

Lesion depth and mineral loss estimated microradiographically after 48, 96 and 140 h demineralization are compiled in Table 1. For the irradiated specimens compared with the control ones mineral loss and lesion depth after 48 and 140 h were significantly different ( $p < 0.001$ , t-test). After 140 h of demineralization the following relation was calculated:

$$\Delta Z \text{ irradiated enamel} \simeq \frac{1}{2} \Delta Z \text{ nonirradiated enamel}$$

Although less pronounced, a similar relation for the lesion depth was obtained. Typical microradiograms of irradiated and control specimens after demineralization with or without MHDP are shown in figure 2.



**Fig. 2** A Typical microradiogram of a control specimen after demineralization (140 h) in the presence of MHDP ( $6 \mu M$ ). B Typical microradiogram of an irradiated enamel specimen after demineralization (140 h) in the presence of MHDP ( $6 \mu M$ ). C Typical microradiogram of an irradiated enamel specimen after demineralization (60 h) without MHDP.

After demineralization of irradiated and control enamel specimens in a demineralization solution without MHDP the created lesions had weakened most specimens in such a way that sectioning for microradiography was impossible without damaging. In all irradiated enamel slices which were not damaged by sectioning a surface layer was observed (Fig. 2C). X-ray diffractograms made before and immediately after irradiation were identical. No differences for the characteristic reflections were observed. SEM pictures of irradiated enamel compared with the controls did not show structural differences.

## DISCUSSION

Obviously there is much controversy in literature about the effect of X-rays on the acid solubility of dental enamel. From most studies it is difficult to draw an exact parallel, because the circumstances of demineralization are different. Wiemann et al.,<sup>10</sup> Walker<sup>11</sup> and Shannon et al.<sup>6</sup> demineralized in small volumes of liquid so the calcium and phosphate concentrations increased with time. Joyston-Bechal<sup>13</sup> used an artificial gelatin gel, but gel systems also contain many impurities. The constant composition method used in this study resulted in negligible calcium (<2.5%), phosphate (<1.5%) and pH (<0.04) variations, through which comparison of the demineralization behaviour between irradiated and nonirradiated enamel was possible.

From the microradiographic data (type of lesion, mineral loss and lesion depth) it is apparent that the acid solubility of dental enamel is reduced by X-ray irradiation. Considering these data it is remarkable that in case of demineralization of irradiated enamel specimens in a solution without MHDP, surface layer formation was observed. To our best knowledge surface layer formation in non-irradiated enamel demineralized under similar conditions has not been published before. Because hardness is a qualitative parameter for the outer enamel region, the presence of this surface layer might also explain the significant differences in indentation length between these two groups of specimens.

The surface layer formation as well as the differences in mineral loss and lesion



depth might consequently be caused by irradiation effects. In this study neither differences in X-ray diffractograms nor in SEM pictures could be observed. According to our findings and the results reported by Zach<sup>12</sup> it is probably not the inorganic phase which is responsible for the altered behaviour of enamel after irradiation at a therapeutic level. However, when increasing the total dose far beyond this level (10,000 Gy) Jervøe<sup>9</sup> found in an X-ray diffraction study irradiation induced changes in the crystalline structure of human enamel. A better explanation for the alterations observed at a therapeutic level might be that irradiation of enamel causes changes in the organic matrix resulting in changed permeability properties. A study concerning the latter is presented in the next paragraph.

## REFERENCES

- 1 del Regato JA. Dental lesions observed after roentgen therapy in cancer of the buccal cavity, pharynx and larynx. *Am. J Roentgenol* 1939;42:404–410.
- 2 Frank RM, Herdly J, Philippe E. Acquired dental defects and salivary gland lesions after irradiation for carcinoma. *J Am Dent Assoc* 1965;70:868–883.
- 3 Brown LR, Dreizen S, Handler S, Johnston DA. Effect of radiation-induced xerostomia on human oral microflora. *J Dent Res* 1975;54:740–750.
- 4 Brown LR, Dreizen S, Handler S. Effects of selected caries preventive regimens on microbial changes following irradiation induced xerostomia in cancer patients. In: Stiles HM, Loesche WJ, O'Brien TC, eds. *Microbial Aspects of dental caries*, vol I. Information Retrieval Inc., Washington D.C. 1976.
- 5 Shannon IL, Starcke EN, Wescott WB. Effect of radiotherapy on whole saliva flow. *J Dent Res* 1977;56:693.
- 6 Shannon IL, Wescott WB, Starcke EN, Mira J. Laboratory study of cobalt-60-irradiated human dental enamel. *J Oral Med* 1978;33:23–27.
- 7 Cowman RA, Baron SS, Glassman AH, Davis ME, Strosberg AM. Changes in protein composition of saliva from radiation-induced xerostomia patients and its effect on growth of oral streptococci. *J Dent Res* 1983;62:336–340.
- 8 Poyton HG. The effects of radiation on teeth. *Oral Surg* 1968;26:639–646.
- 9 Jervøe P. X-ray diffraction investigation on the effect of experimental and in situ radiation on mature human teeth. A preliminary report. *Acta Odontol Scand* 1970;28:623–631.
- 10 Wiemann MR, Davis MK, Besic FC. Effect of X-radiation on enamel solubility. *J Dent Res* 1972;51:868.
- 11 Walker R. Direct effect of radiation on the solubility of human teeth in vitro. *J Dent Res* 1975;54:901.
- 12 Zach GA. X-ray diffraction and calcium-phosphorus analysis of irradiated human teeth. *J Dent Res* 1976;55:907–909.
- 13 Joyston-Bechal S. The effect of X-radiation on the susceptibility of enamel to an artificial caries-like attack in vitro. *J Dent* 1985;13:41–44.
- 14 Buskes JAKM, Christoffersen J, Arends J. Lesion formation and lesion remineralization in enamel under constant composition conditions. *Caries Res* 1985;19:490–496.
- 15 Francis MD. The inhibition of calcium hydroxyapatite crystal growth by polyphosphonates and polyphosphates. *Calc Tiss Res* 1969;3:151–162.
- 16 Featherstone JDB, Duncan JF, Cutress TW. Surface layer phenomena in in vitro early caries-like lesions of human tooth enamel. *Arch Oral Biol* 1978;23:397–404.
- 17 Featherstone JDB, Duncan JF, Cutress TW. A mechanism for dental caries based on enamel processes and diffusion phenomena during in vitro caries simulation on human tooth enamel. *Arch Oral Biol* 1979;24:101–112.
- 18 de Josselin de Jong E, ten Bosch JJ. Error analysis of the microradiographic determination of mineral content in mineralized tissue slices. *Phys Med Biol* 1985;30:1067–1075.
- 19 de Josselin de Jong E, ten Bosch JJ. Measurement and optimization of the microradiographic method and its subsystems. *SPIE Proceedings* 1985;492:485–492.

## THE EFFECT OF X-RAY IRRADIATION ON THE PERMEABILITY OF BOVINE DENTAL ENAMEL

### INTRODUCTION

Bovine dental enamel irradiated at a therapeutic level (2 Gy doses, twice daily, to a total of 72 Gy) and subsequently demineralized under constant composition conditions showed a decrease in enamel acid solubility *in vitro*.<sup>1</sup> Joyston-Bechal<sup>2</sup> reported similar results after demineralization of enamel under less reproducible circumstances.

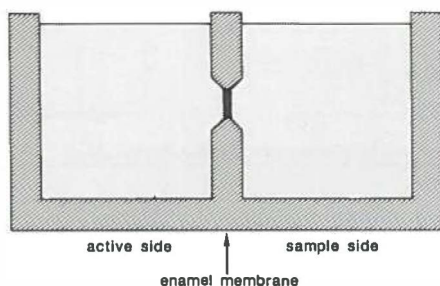
The reduced acid solubility of irradiated enamel could be ascribed to possible changes in the inorganic phase or to structural changes of the organic matrix, the latter influencing the permeability of enamel.

Earlier studies, using scanning electron microscopy and X-ray diffraction,<sup>1,3</sup> did not show any changes in the crystalline structure after irradiation at a therapeutic level. In view of the above reports, it was the purpose of this study to investigate possible changes in permeability of enamel after irradiation. Measuring techniques applied are complex impedance measurements and radioisotope diffusion experiments.<sup>4,5</sup>

### MATERIALS AND METHODS

*Preparation of enamel membranes.* Enamel membranes (200  $\mu\text{m}$  thick) were prepared from mature bovine incisors extracted just before eruption by sawing parallel to the labial surface of the tooth. The first slice (surface layer) was discarded. Only slices without microcracks and inhomogeneities were used for the experiments.

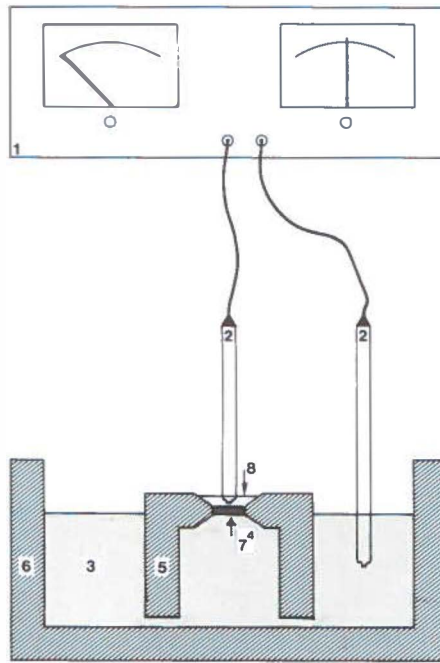
*Measurement of radioisotope diffusion.* Effective diffusion coefficients ( $D$ ) of radioisotopes were measured according to the method described by Borggreven et al.<sup>4,6</sup> This method made use of a diffusion cell consisting of two compartments, between which an enamel membrane (membrane area 0.071  $\text{cm}^2$ ) was mounted (Fig. 1). At the start of the experiment one compartment contained [ $^3\text{H}$ ]-sorbitol, [ $^{14}\text{C}$ ]-glycerol,  $^{36}\text{Cl}^-$  and  $^{86}\text{Rb}^+$  as radiotracers; to the other compartment equivalent amounts of nonradioactive components were added to maintain equal concentrations at both sides of the membrane. Radiotracers which did not show a strong interaction with enamel apatite were chosen, so as to obtain information about the transport of ionic as well as nonionic compounds of different molecular sizes. The concentrations of all compounds were chosen as described by Borggreven et al.<sup>4</sup> The solutions used were equilibrated for at least 10 days with powdered enamel at 4° C, before the radiotracers were added. Over a period of 2 weeks, samples



**Fig. 1** Schematic drawing of the diffusion cell. Radiotracers were added to the active side at the start of the experiment. Effective diffusion coefficients were calculated from the tracer concentrations in the samples taken from the initially nonradioactive compartment over a period of two weeks. The core carrying the enamel membrane was taken out for irradiation.

were taken from the initially nonradioactive compartment and prepared for counting in a six-channel liquid scintillation spectrometer. The effective diffusion coefficients were calculated from the measured tracer concentrations.<sup>4</sup> Subsequently the same enamel membranes were prepared for X-ray irradiation. For this purpose the chambers of the diffusion cell were emptied, and the enamel surface was carefully washed with water and wiped off with cleansing tissue. The diffusion cell was dismantled, with the exception of the core carrying the enamel membrane. After X-ray irradiation the diffusion cell was mounted again and filled with labeled and nonlabeled solutions as described above, after which the diffusion was measured again over a period of 14 days to determine the effect of irradiation. Diffusion coefficients were also measured during two consecutive periods of 14 days, under similar conditions, but without irradiation between both periods. All diffusion experiments were performed at 4°C to reduce possible bacterial growth.

*Electrical impedance measurements.* A slice of enamel was mounted in the core of the same diffusion cell as for the radioisotope measurements. This core was placed in a container (Fig. 2) with approximately 30 ml of measuring solution, in such a way that only the lower surface of the slice was in contact with the measuring solution. This solution consisted of 2 mmol/l HEPES-buffer (Merck, Darmstadt, FRG) of pH 7.4, 40  $\mu$ mol/l Hibitane (I.C.I., Macclesfield, Cheshire, England) as a disinfectant and 50 mmol/l rubidium chloride as an electrolyte. A calomel electrode was placed in this solution. Approximately 1 ml of measuring solution was subsequently put on the upper surface of the slice and a second calomel electrode was placed in it. Thus the electrodes were connected via the enamel membrane. Impedance measurements were performed 48 and 24 h before X-ray irradiation and 6 h after X-ray irradiation of a specimen. Complex impedance measurements were performed with an Apple II<sup>+</sup> microcomputer, which was used to operate a sine-wave function generator (range 0.1 Hz – 1 MHz, Krohn & Hite 4141R, Avon, Mass.), an optimal amplifier to enable measurements of high impedances, a vector-impedance meter (range 1 Hz – 1 MHz, Hewlett & Packard 3575A), a video-screen and a printer. The  $R_0$  (the real impedance extrapolated to 0 Hz) of a membrane



**Fig. 2** Schematic representation of the electrical impedance measuring device. 1 Vector impedance meter, 2 Calomel electrode, 3 Measuring solution, 4 Enamel membrane, 5 Supporting block, 6 Container, 7 Measuring solution in the supporting block which is in direct contact with the bulk measuring solution, 8 Measuring solution on the upper surface of the enamel membrane.

was determined as follows: the total impedance vector and the phase angle were measured at 49 frequencies (8 per decade) between 1 Hz and 1 MHz. These values were used to calculate the real and imaginary part of the impedance at each frequency. The values were plotted in a Cole-Cole plot in which the real impedance is plotted against the imaginary impedance for each frequency.<sup>7</sup> Using this plot, the  $R_0$  was determined by extrapolation.<sup>8,9</sup>

*X-ray irradiation.* To simulate oral conditions during irradiation, the cores carrying the enamel membranes were placed in an open glass container, with the enamel membranes under 2 cm of water. The enamel membranes were irradiated in a single dose of 72 Gy (Linac, 6 MV photon irradiation, source to specimen distance 100 cm, field size  $15 \times 15$  cm). Irradiation was performed at room temperature. During transport to and from the irradiation unit the enamel membranes were kept in a humidified atmosphere.

*Mathematical and statistical analysis.* The mean diffusion coefficient for RbCl was calculated using the equation described by Borggreven et al.<sup>6,10</sup>:

$$D_{\text{RbCl}} = \frac{2D_{\text{Rb}} \times D_{\text{Cl}}}{D_{\text{Rb}} + D_{\text{Cl}}} \quad (1)$$

**Table 1** Effective diffusion coefficients (D) of [<sup>3</sup>H]-sorbitol, [<sup>14</sup>C]- glycerol, <sup>36</sup>Cl<sup>-</sup>, <sup>86</sup>Rb<sup>+</sup> and RbCl for the enamel membranes before (I) and after (II) irradiation (n=4)

Tracer	Enamel slice	I cm <sup>2</sup> .s <sup>-1</sup> .10 <sup>8</sup>	II cm <sup>2</sup> .s <sup>-1</sup> .10 <sup>8</sup>	D* (II/I) ×100%	D* %
Sorbitol	1	0.47	0.47	100	
	2	0.58	0.73	126	
	3	0.27	0.45	167	
	4	0.45	0.61	136	132±28
Glycerol	1	0.61	0.63	104	
	2	0.76	0.98	129	
	3	0.38	0.66	174	
	4	0.66	0.89	135	135±29
Cl	1	1.25	1.39	111	
	2	1.56	2.19	140	
	3	1.04	1.85	178	
	4	1.66	2.28	137	142±27
Rb	1	1.79	1.73	97	
	2	2.28	2.58	113	
	3	1.11	1.84	166	
	4	1.84	2.41	131	127±29
RbCl	1	1.47	1.54	105	
	2	1.85	2.37	128	
	3	1.07	1.84	172	
	4	1.74	2.34	134	135±28

For D\* mean values ± SD are given

The normalized effective diffusion coefficient (D\*) after irradiation was calculated as a percentage of the value before irradiation, as follows:

$$D^* = \frac{D \text{ after irradiation}}{D \text{ before irradiation}} \times 100\% \quad (2)$$

The normalized value of the impedance (R\*) was similarly calculated from:

$$R^* = \frac{R \text{ after irradiation}}{R \text{ before irradiation}} \times 100\% \quad (3)$$

A matched two-tailed t test was used to analyze the changes in D and R.

**Table 2** Values of  $R_0$  ( $k\Omega$ ) before (Ia, Ib) and after (II) irradiation of seven different slices of enamel

Enamel slice	Ia, $k\Omega$	Ib, $k\Omega$	II, $k\Omega$	$R^*$ , %
1	35	33	38	115
2	95	95	99	104
3	339	328	305	93
4	182	174	183	105
5	136	131	143	109
6	293	284	278	98
7	33	32	33	102
Overall mean				104 $\pm$ 7.1

Ia = 48 h before irradiation; Ib = 24 h before irradiation; II = 6 h after irradiation.

## RESULTS

Table 1 shows the effective diffusion coefficients before and after irradiation of four different enamel membranes. The increase of the effective diffusion measured after irradiation was not significant ( $p>0.05$ ). In non-irradiated control membranes ( $n=12$ )  $D^*$  for sorbitol, glycerol and RbCl was  $121\pm 24$ ,  $122\pm 18$  and  $127\pm 27\%$ , respectively ( $p>0.05$ ).

The results of the impedance measurements on seven different enamel membranes are summarized in Table 2. No significant changes in impedance values were observed ( $p>0.05$ ).

## DISCUSSION

The differences in the diffusion coefficients and  $R_0$  of the various bovine enamel slices used in the experiments (Tables 1 and 2) may be ascribed to biological variation or to heterogeneity of the enamel composition.<sup>11</sup> Because in our experiments the effects of X-ray irradiation on the enamel slices were compared to the pre-irradiation values of the same slices, these differences were of no importance.

In most enamel membranes the rate of transport increased after irradiation (Table 1). This may be due to some solubilization of the enamel in the transport medium, as indicated by the results of the control experiments. The increase of the diffusion coefficients was about the same for the irradiated and the nonirradiated specimens. Solubilization of enamel may occur even in previously saturated media, because the surface composition and hence the solubility properties are different for each specimen of enamel.<sup>12</sup> The measured increases of transport are therefore not thought to be caused by irradiation, but by the relatively long stay ( $2\times 14$  days) of the enamel in the transport medium. This is in accordance with the results of the much faster impedance measurements (Table 2), in which solubilization effects are of less importance. To limit the possibility of solubilization during irradiation treatment all enamel membranes were irradiated in a single dose.

In the literature we could find no evidence of studies on the effect of X-ray irradiation on the organic matrix of enamel. Some authors suggested that X-ray irradiation may cause denaturation of the organic component of tooth substance which can be followed by dissolution of the calcified component.<sup>13-16</sup>

Analogous with our findings<sup>1</sup> and those of Joyston-Bechal<sup>2</sup> after X-ray irradiation, it is known that laser irradiated dental enamel also produces less subsurface demineralization than enamel not subjected to laser irradiation on exposure to acid.<sup>17</sup> The laser-induced physical and/or chemical changes that cause this reduced subsurface demineralization are unknown. They are expected, however, to primarily arise from localized heating.<sup>18-20</sup> Because X-ray irradiation at a therapeutic level does not produce substantial heating of enamel it is difficult to draw any parallel with laser irradiation effects.

Since in the present study no decrease in permeability of enamel was found after X-ray irradiation in two independent experiments it might be that chemical modifications (solubility), rather than physical modifications (permeability) were responsible for the decreased subsurface demineralization rates observed for X-ray irradiated enamel.<sup>1,2</sup> As mentioned in the introduction neither SEM nor X-ray diffraction brought to light any changes in the crystalline structure of enamel after X-ray irradiation.<sup>1</sup> Similar results were reported by Zach<sup>3</sup> and Wiemann et al.<sup>21</sup> who found no chemical or structural changes in enamel subjected to X-ray irradiation treatment using X-ray diffraction and dispersion staining procedures, respectively. Jervøe,<sup>22</sup> however, demonstrated changes in the crystalline structure of enamel with X-ray diffraction but he irradiated in an extremely high single experimental dose of 10,000 Gy. He concluded that the effect of X-ray irradiation on enamel might not be exclusively a radiation-induced effect in the crystal structure but that it might also be possible that the effect in the crystal is the result of a chemical reaction caused by radiolysis.

Similar radiation-induced effects have been observed in the electron microscopy of octacalcium phosphate.<sup>23</sup> The formation of voids, strain fields and even dislocations has been observed in that structure during radiation damage by the electron beam. That this is a case of radiation damage, is clear from the fact that the octacalcium phosphate structure contains relatively loose water molecules and that irradiation took place in vacuum, which makes the structural changes irreversible in that case.

In our present study we irradiated with X-rays under wet conditions and we dealt with a calcium phosphate having an apatitic structure. The apatitic crystals of tooth enamel have incorporated some sodium, carbonate and magnesium by entrapment during their formation.<sup>24</sup> X-ray irradiation at room temperature will probably mobilize the point defects in this apatite somewhat, whereby entrapped ions can be removed from the surface layer of the crystals (compare the data on irradiation effects for many other ionic compounds as given by Kröger<sup>25</sup> and Hasiguti<sup>26</sup>) through the aqueous solution in the pores of the enamel. Therefore, the expected result of irradiation under moist conditions on the inorganic phase of tooth enamel is that the surface layers of the apatite crystals are stabilized and, hence, will develop a



decreased rate of dissolution into slightly acidic buffers.

This elucidates the decreased subsurface demineralization of dental enamel after X-ray irradiation somewhat but it seems that further research especially concerning the inorganic phase is needed in order to prove this hypothesis. Solubility experiments and tunneling microscopy studies could be of great value. In view of the high sensitivity reported for the techniques applied in the present study, it may be concluded that X-ray irradiation of dental enamel at a therapeutic level has no influence on its permeability and that it is probably not the organic phase which is responsible for the decreased subsurface demineralization after X-ray irradiation.

## REFERENCES

- 1 Jansma J, Buskes JAKM, Vissink A, Mehta DM, 's-Gravenmade EJ. The effect of X-ray irradiation on the demineralization of bovine dental enamel. A constant composition study. *Caries Res* 1988;22:199-203.
- 2 Joyston-Bechal S. The effect of X-radiation on the susceptibility of enamel to an artificial caries-like attack in vitro. *J Dent* 1985;13:41-44.
- 3 Zach GA. X-ray diffraction and calcium-phosphorus analysis of irradiated human teeth. *J Dent Res* 1976;55:907-909.
- 4 Borggreven JMPM, van Dijk JWE, Driessens FCM. A quantitative radiochemical study of ionic and molecular transport in bovine dental enamel. *Arch Oral Biol* 1977;22:467-472.
- 5 Scholberg HPF, Borggreven JMPM, Driessens FCM. A phenomenological interpretation of the frequency-dependent impedance behaviour of bovine dental enamel. *Arch Oral Biol* 1984;29:965-970.
- 6 Borggreven JMPM, Driessens FCM. Effect of phytate and hexadecylamine on the permeability of bovine dental enamel. *Arch Oral Biol* 1983;28:375-379.
- 7 Cole KS, Cole RH. Dispersion and absorption in dielectrics. *J Phys Chem* 1941;9:341-351.
- 8 Scholberg HPF, Borggreven JMPM, Driessens FCM. The analysis of the small-signal AC-response of bovine enamel membranes. *Ber Bunsenges Phys Chem* 1987;91:129-134.
- 9 Scholberg HPF, Borggreven JMPM, Driessens FCM. A structural interpretation of impedance spectra and radioisotope diffusion in dental enamel. *Ber Bunsenges Phys Chem* 1987;91:135-140.
- 10 Borggreven JMPM, Driessens FCM, van Dijk JWE. Diffusion through bovine tooth enamel as related to the water structure in its pores. *Arch Oral Biol* 1980;25:345-348.
- 11 Bakhos Y, Brudevold F, Aasenden R. Permeability of surface and subsurface enamel. *Internat Ass for Dent Res*, 1976; Preprinted abstracts, 54th General Meeting. Abstract 583.
- 12 Patel PR, Brown WE. Thermodynamic solubility product of human tooth enamel: powdered sample. *J Dent Res* 1975;54:728-736.
- 13 Leist M. Über Röntgenschädigung der Zähne. *Z Stomat* 1925;23:796-801.
- 14 Lüdín M, Müller O. Zahnveränderungen nach protrahiert-fraktionierter Röntgenbestrahlung. *Strahlentherapie* 1936;56:644-649.
- 15 Bianchi M. Les lésions maxillaires et dentaires consécutives à l'action des rayons X et des substances radioactives. *Schweiz Mschr Zahnheilk* 1943;53:1007-1077.
- 16 Poyton HG. The effects of radiation on teeth. *Oral Surg* 1968;26:639-646.
- 17 Fowler BO, Kuroda S. Changes in heated and laser-irradiated human tooth enamel and their effects on solubility. *Calcif Tissue Int* 1986;38:197-208.
- 18 Stern RH, Vahl J, Sognaes RF. Lased enamel: ultrastructural observations of pulsed carbon dioxide laser effects. *J Dent Res* 1972;51:455-460.
- 19 Yamamoto H, Sato K. Prevention of dental caries by Nd: YAG laser irradiation. *J Dent Res* 1980;59:2171-2177.
- 20 Borggreven JMPM, van Dijk JWE, Driessens FCM. Effect of laser irradiation on the permeability of bovine dental enamel. *Arch Oral Biol* 1980;25:831-832.
- 21 Wiemann MR, Davis MK, Besic FC. Effects of X-radiation on enamel solubility. *J Dent Res* 1972;51:868.
- 22 Jervøe P. X-ray diffraction investigation on the effect of experimental and in situ radiation on mature human teeth. A preliminary report. *Acta Odontol Scand* 1970;28:623-631.



- 23 Aoba T, Takahashi J, Yagi T, Doi Y, Okazaki M, Moriwaki Y. High-voltage electron microscopy of radiation damages in octacalcium phosphate. *J Dent Res* 1981;60:954–959.
- 24 Driessens FCM, Verbeek RMH. *Biominerals*. CRC Press, Boca Raton 1989.
- 25 Kröger FA. *The chemistry of imperfect crystals*. North-Holland Publ., Amsterdam 1964.
- 26 Hasiiguti RR. *Lattice defects and their interactions*. Gordon and Breach, New York 1967.

## A MODEL TO INVESTIGATE XEROSTOMIA-RELATED DENTAL CARIES

### INTRODUCTION

The clinical appearance and distribution of xerostomia-related dental caries after radiotherapy have been described in detail.<sup>1-3</sup> The lesions most frequently observed, are generalized superficial defects that initially affect the buccal and later on the palatal or lingual surfaces of the tooth crowns. These lesions may progress towards complete amputation of the crowns. Decay localized at the incisal or occlusal edges of the teeth is often noticed. Similar changes were observed in subjects with xerostomia resulting from other etiology.<sup>4</sup>

Xerostomia-related dental caries progresses so rapidly that a perfect dentition can be totally ruined within one year.<sup>5</sup> In clinical trials it has been shown, however, that good oral hygiene in combination with daily fluoride applications can reduce caries progression.<sup>5-9</sup> The prophylactic regimens applied in these subjects are mainly based on clinical experience. Because these regimens are often inconvenient and time consuming for the patient, increased caries activity invariably results from a failure to comply completely with the prescribed use of fluoride-containing gels or mouthrinses.<sup>6</sup> To optimize the cariostatic disciplines, the aim of this study was to develop an in situ model in which onset, progression and prevention of xerostomia-related dental caries can be studied as a function of time with nondestructive methods such as scanning longitudinal microradiography (LMR), scanning optical monitoring (OM) and hardness measurements.

### MATERIALS AND METHODS

*Subjects.* Seven edentulous subjects, 4 men and 3 women, suffering from irradiation-induced xerostomia participated in this study. The mean radiation dose to the head and neck area was 55.5 Gy (range 50–66 Gy). In all cases the period of irradiation was completed at least 1 year before starting the present experiment. The mean age of the patients was 67.3 years (range 55–73 years).

Because the flow rate was too low to be estimated, the degree of hyposalivation was expressed as the amount of oral fluid present in the oral cavity. This was measured by soaking up all the oral fluid on the mucosa and dentures with a water-absorbent gauze, which was weighed before and after the collection. The test was performed on three different days between 10.00 and 10.30 a.m. and the subjects were not allowed to take food or beverages during 2 h before the test.<sup>10</sup>

In each subject the left and right molars of the lower denture were replaced by a metal sample holder.<sup>11</sup> Each holder could house 6 enamel blocks, namely 1 block

for fluoride analysis, 2 blocks for LMR and OM and 3 blocks for scanning electron microscopy (SEM) and hardness measurements. By unscrewing the occlusal part of the holder, the enamel blocks could readily be removed for the measurements which were performed weekly. During the 6-week study period the patients were not allowed to clean the enamel blocks. During the night the dentures were kept in tap water, which contained 0.1 mg/l F<sup>-</sup>.

*Preparation of the enamel blocks.* The labial surfaces of noncarious human mandibular permanent incisors and canines were partially ground flat on 1,200 grit silicon carbide paper on a polishing machine (Buehler Ltd., Lake Bluff, Ill, USA), polished on a Kent Mark II polisher (Engis, Maidstone, England) using Hypress diamond compounds (1 μm; Engis) and cut in blocks (3×4×1.5 mm). For LMR and OM the pulpal aspects of the enamel specimens were ground on 220 grit silicon carbide paper in such a way that planoparallel specimens with a thickness of 340 ± 20 μm were obtained. Subsequently all enamel specimens were embedded in polymethylmethacrylate (Rapid Repair, De Trey, Wiesbaden, FRG). Care was taken to keep the polished enamel surfaces free from acrylic resin. Finally the specimens were ultrasonically cleaned in tap water for 10 min.

*Scanning longitudinal microradiography.* The embedded tooth samples for LMR and OM were adjusted with impression material (President regular body, Coltène, Altstätten, Switzerland) to a polymethylmethacrylate sample holder. In this way the enamel specimens could be exactly repositioned in the holder at each measuring interval. The sample holder fitted precisely into an aluminum sliding bar which was mounted in a camera for X-ray exposure. Adjacent to the sliding bar at the position of the tooth specimen an aluminum calibration stepwedge was permanently mounted in the camera. On Kodak SO-253 high resolution photographic film (Eastman Kodak, Rochester, NY, USA) an X-ray projection of the tooth specimen together with the aluminum stepwedge was made (CuKα X-ray radiation). The X-ray tube (PW 2253/20; Philips, Eindhoven, The Netherlands) was operated at 20 kV, 50 mA, and the exposure time was 2 min. After standardized film development, two-dimensional scans of the X-ray images were made using a densitometer (MPV Compact Ortholux II; Leitz, Wetzlar, FRG; diameter circular densitometer window: 400 μm) which was connected to a microcomputer (model Apple IIe, Apple Computer, Cupertino, Calif., USA). The X-ray images of the separate enamel samples were scanned automatically on a XY table at the same discrete positions on a predefined point matrix (11 × 11 points, scan area 2 × 2 mm).

The absolute mineral content per unit area, m(x,y) at each scan point was calculated from:

$$m(x,y) = \frac{A_{n,slice}(x,y)}{(\mu/\rho)_m} = \frac{(\mu/\rho)_{Al} m_{Al,slice}(x,y)}{(\mu/\rho)_m}$$

where  $A_{n,slice}(x,y)$  is the X-ray absorbance of the enamel specimen at position (x,y),  $(\mu/\rho)_m$  is the mass attenuation coefficient of enamel mineral and  $(\mu/\rho)_{Al}$  the mass attenuation coefficient of pure aluminum. To obtain  $(\mu/\rho)_m$  it was assumed that

the enamel only consists of stoichiometric hydroxyapatite  $\text{Ca}_{10}(\text{PO}_4)_6(\text{OH})_2$ . For details of the LMR technique and calculation method see de Josselin de Jong.<sup>12</sup> LMR was performed before the start of the experiment (baseline) and once a week thereafter.

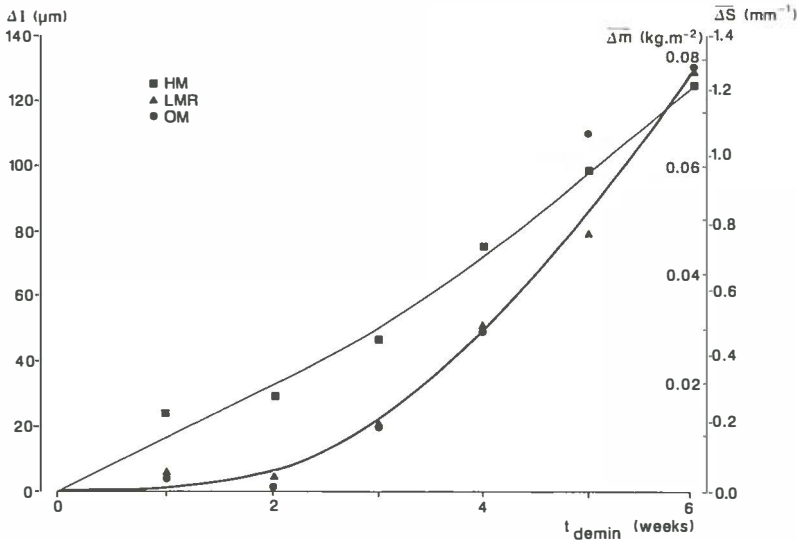
*Scanning optical monitoring.* The OM technique, as described by ten Bosch et al.<sup>13,14</sup> was performed with the optical monitor measuring head in a fixed position. The enamel specimens were placed in the sample holders as described previously. The sample holders and calibration strips were moved under the measuring head on the same XY table as used for LMR. The collected light flux of the enamel specimens was measured at the same  $11 \times 11$  scan points and the same scan area ( $2 \times 2$  mm), therefore the data obtained with LMR and OM can be compared. OM was performed before the start of the experiment (baseline) and weekly thereafter.

*Scanning electron microscopy.* The enamel specimens were washed in running tap water to remove surface debris. Subsequently the specimens were glued on aluminum stubs with fast curing epoxy resin and coated with gold (approximately 15 nm) in a sputter coater (Balzers Union, Balzers, Liechtenstein). The specimens were examined in a JEOL scanning electron microscope type 35C (JEOL, Tokyo, Japan) operated at 25 kV. SEM was performed at weekly intervals.

*Microhardness measurements.* Microhardness measurements perpendicular to the enamel surface were carried out with a Leitz Durimet Microhardness tester fitted with a Knoop diamond (Leitz). A load of 100 g was applied for 20 s. Five indentations were made in a definite pattern at the center of each enamel sample. The measurements were taken at weekly intervals.

*Biopsy procedures and fluoride analysis.* Three successive acid etch biopsies were performed on the ground enamel surface of each enamel specimen prior to insertion in the intraoral device. Biopsy sites were demarcated by placing an adhesive tape with a circular hole of 1 mm in diameter on the enamel surface. Then  $0.4 \mu\text{l}$  of 1 M perchloric acid was deposited on the demarcated biopsy site, and absorbed after 5 s with a filter paper disc which was placed in a polyethylene tube containing  $25 \mu\text{l}$  total ionic strength adjustment buffer (TISAB) (Orion Research, Cambridge, Mass., USA). The etched area was washed twice in quick succession with TISAB and the washings transferred to the polyethylene tube.

The F concentrations in  $5\text{-}\mu\text{l}$  volumes of the etching solutions were determined by a microanalytical technique developed by Vogel et al.<sup>15</sup> The phosphorous concentrations were determined in  $10\text{-}\mu\text{l}$  volumes by the analytical technique developed by Chen et al.<sup>16</sup> using a Spectronic 2000 spectrophotometer (Bausch and Lomb, Rochester, N.Y., USA). The mass enamel in the etching solutions was calculated by assuming that enamel contains 18.0 % P,<sup>17</sup> and expressed in micrograms. The enamel F concentrations were adjusted to standardized depths of  $5 \mu\text{m}$ .<sup>18</sup> After the enamel specimens were exposed to the intraoral environment for 6 weeks, three successive acid etch biopsies were again carried out on demarcated biopsy sites immediately adjacent to the initial biopsy sites and the enamel F concentrations again adjusted to standardized depths of  $5 \mu\text{m}$ .



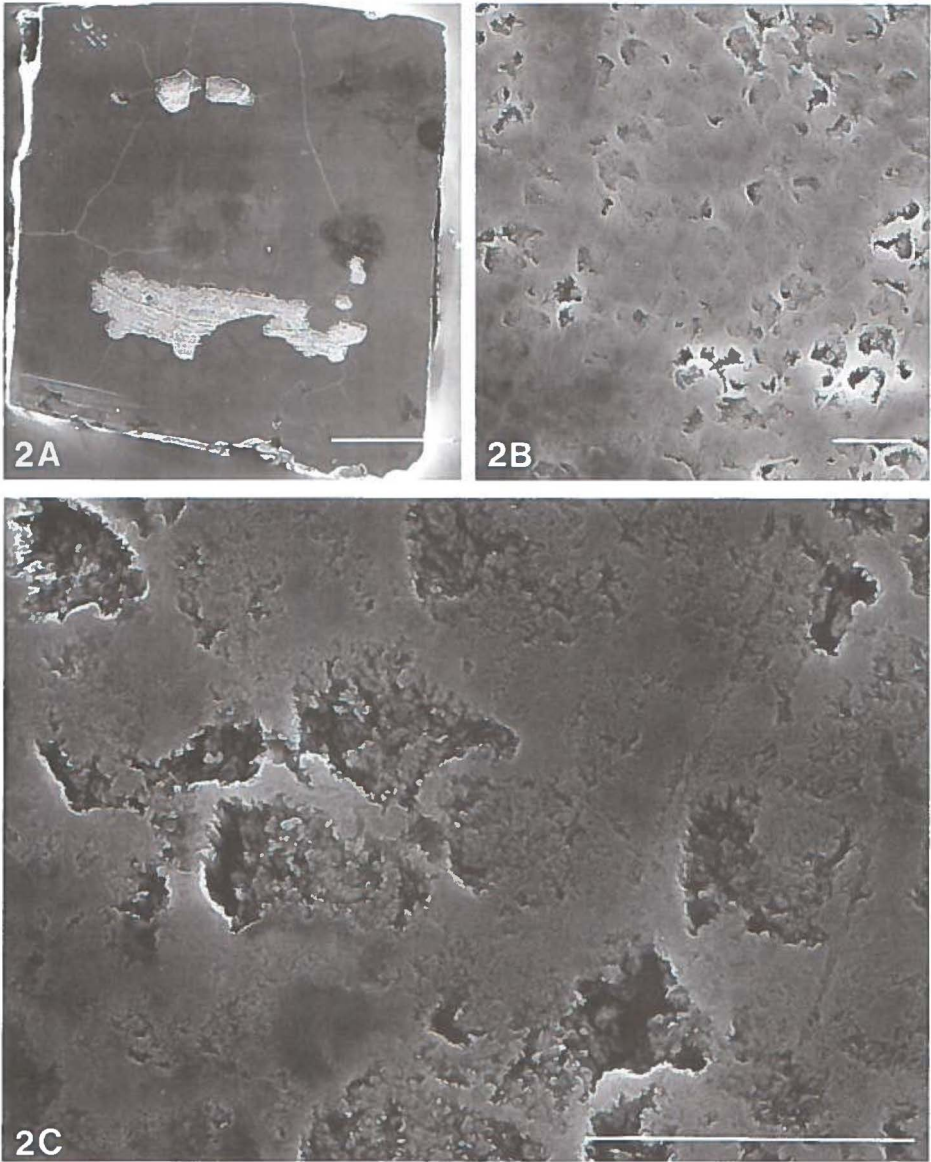
**Fig. 1** Change in mineral content measured by LMR, ( $\overline{\Delta m}$  hydroxyapatite), optical scattering ( $\overline{\Delta S}$ ) and indentation length ( $\Delta I$ ) of the enamel specimens as a function of the time of demineralization  $t_{demin}$  ( $n=7$ ). The parabola, which represents the relation between the LMR and OM, is drawn by means of polynomial regression analysis. HM is Hardness measurements.

**Statistical analysis.** The data obtained with LMR, OM, hardness measurements and fluoride analysis were analyzed using a paired t test.

## RESULTS

The subjects suffered from moderate to severe xerostomia, the mean amount of fluid in the oral cavity was  $414 \pm 218$  mg. Figure 1 shows the mineral loss,  $\overline{\Delta m}$  ( $\text{kg}\cdot\text{m}^{-2}$ ), of the scanned area, the changes in optical scattering,  $\overline{\Delta S}$  ( $\text{mm}^{-1}$ ), and the changes in indentation length,  $\Delta I$  ( $\mu\text{m}$ ), of the enamel specimens observed during the 6-week study period. After 4 weeks about one third of the enamel slabs were damaged so severely by the progressive caries process that further measurements were not reliable, hence median values are presented in all figures instead of mean values and no standard deviations are given. The hardness measurements indicated a demineralization of the samples within 2 weeks ( $p < 0.02$ ), while LMR ( $p < 0.05$ ), OM ( $p < 0.05$ ) and SEM showed the first signs of demineralization in most samples not earlier than in the 3rd week. The relationship between LMR and OM is given in figure 1. A high correlation between the two techniques was established ( $r = 0.979$ ).

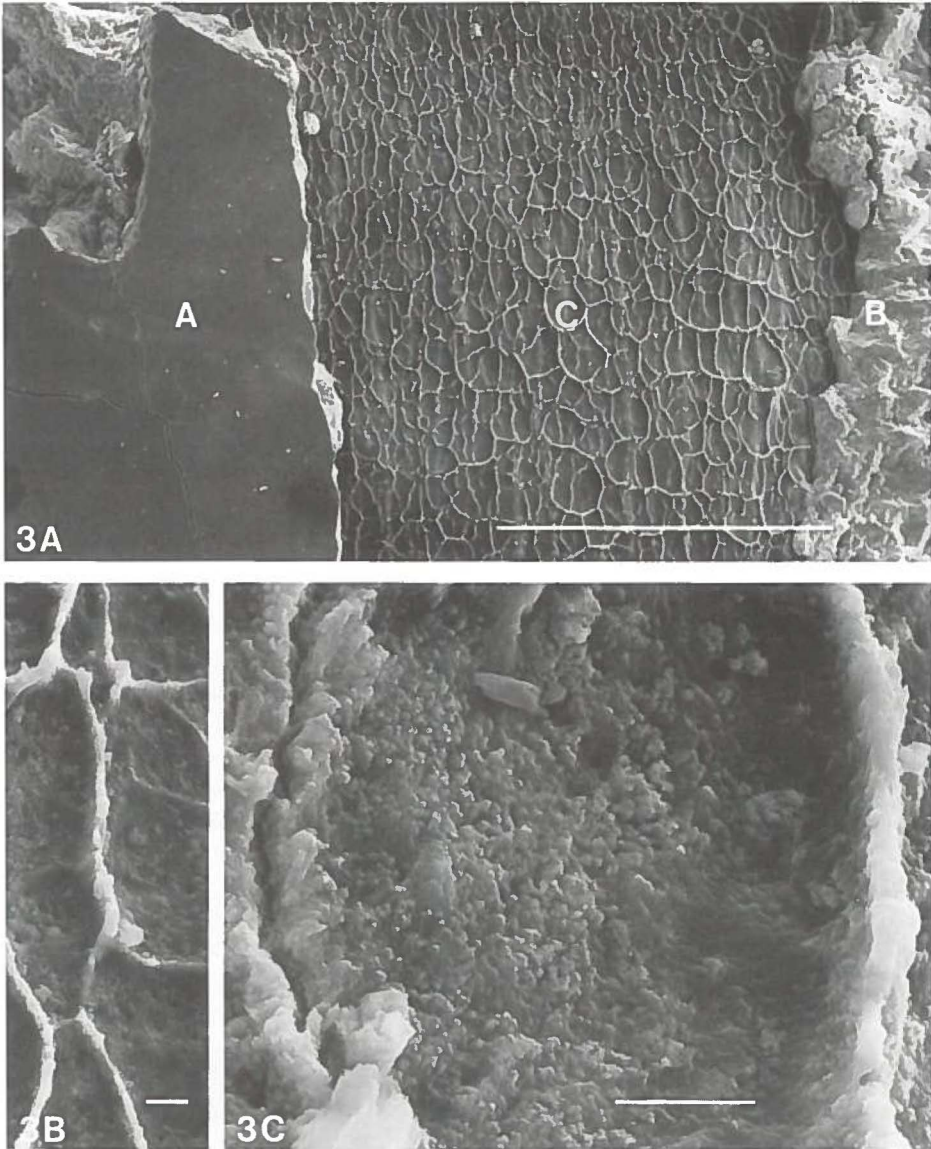
SEM showed a dense plaque accumulation which consisted of spherical, spheroidal, rod-shaped and filamentous bacteria on most specimens. From the 3rd week onward most samples showed a porous enamel surface, starting crater formation and a hollowing out of prism cores (Figs. 2A-C). The enamel damage was more



**Fig. 2** A Overall view of an enamel specimen after 3-week intraoral exposure in a xerostomic subject. At certain places at the periphery severe destruction of the surface layer has occurred. Bar:1 mm. B Detail of A. In the central part of the specimens a more superficial attack is visible. Bar: 10  $\mu$ m. C Higher magnification of B. Exposure of prisms is seen. Bar: 10  $\mu$ m.

marked at the peripheral parts of the samples and progressed with time. After 6 weeks the enamel specimens were severely damaged and demineralized. In some cases the enamel had even peeled off exposing the dentin (Fig. 3A). It looked as





**Fig. 3** A Overall view of an enamel sample after 6-week intraoral exposure in a xerostomic subject. Bar: 1  $\mu\text{m}$ . Three stages of enamel damage are visible: A Presence of a relatively unaffected enamel layer, B Partial loss of the surface enamel layer, C complete absence of enamel and exposure of the underlying dentin. B Detail of A (C). Ridges of calcified material are seen. Bar: 10  $\mu\text{m}$ . C Higher magnification of B. Dentine surface with deposits of calcified material. Bar: 10  $\mu\text{m}$ .

if calcium phosphate salts had dissolved from some areas of the remaining enamel and had precipitated in adjacent areas (Figs. 3B,C).

At week 0 the mean fluoride concentrations at 0–5, 5–10 and 10–15  $\mu\text{m}$  depth were  $353 \pm 143$ ,  $344 \pm 134$  and  $331 \pm 65$  ppm  $\text{F}^-$ , respectively; these differences were not significant ( $p > 0.10$ ). After 6 weeks the fluoride concentration in the outer enamel region (0–5  $\mu\text{m}$ ) was significantly increased to  $533 \pm 157$  ppm  $\text{F}^-$  ( $p < 0.02$ ). At 5–10  $\mu\text{m}$  ( $395 \pm 86$  ppm  $\text{F}^-$ ) and 10–15  $\mu\text{m}$  ( $371 \pm 201$  ppm  $\text{F}^-$ ) the fluoride concentration was not significantly changed ( $p > 0.10$ ).

## DISCUSSION

The severity of hyposalivation measured corresponded with moderate to severe xerostomia.<sup>10</sup> The caries process induced in the proposed model resembled natural xerostomia-related dental caries. The induced porosity of the enamel surface followed by crater formation, hollowing out of prism cores and partial loss of enamel exposing the underlying dentin surface was also observed in teeth of patients suffering from xerostomia.<sup>19</sup> In addition, the demineralizing pattern of exposed dentin and the morphology of the plaque were similar to those reported in the present study.

The major advantages of the model are the possibility (1) to study the mineral content of the enamel specimens during the course of treatment in a nondestructive way, (2) to follow changes in mineral content of a specific specimen as a function of time, and (3) to detect the exact spot in a specimen where the mineral content changes. In other words, the application of the LMR and OM techniques provides time and position-dependent information to the investigator, which is not possible with transversal microradiography or other routine measuring methods which are applied in caries research. These advantages may be a solution to the disadvantages from which most *in vitro*-, *in situ*- and *in vivo* models for studying de- and remineralization of caries lesions in human dental enamel suffer: (1) it is not possible to determine the mineral content of the enamel under investigation during the course of the experiment, and (2) this cannot be resolved by taking sections from the same tooth, because variations in mineral content exist within a single section.<sup>20</sup> A further advantage of the proposed model is the possibility to use edentulous subjects, namely the data obtained are not influenced by the oral hygiene or other preventive measures which a dentulous subject has to apply in order to preserve his dentition (in particular fluoride applications). Even if oral hygiene measures are applied after the appliance temporarily has been removed (dentulous patients) as proposed by Kotsanos et al.<sup>21</sup> and Meyerowitz et al.,<sup>22</sup> retention of fluoride in the mouths of participating subjects may interfere with the results obtained. The latter is of greater significance in xerostomic patients because fluoride retention is increased.<sup>23</sup> Furthermore, it was observed that only minor differences in the composition of oral microflora existed between dentulous and denture-wearing edentulous patients suffering from xerostomia.<sup>24</sup> The minor differences in oral microflora, however, can be seen as a slight disadvantage of performing the experiments with edentulous subjects.



Comparison of the results obtained with LMR, OM and hardness measurements showed a significant increase in indentation length before any significant shift in mineral composition could be observed with LMR and OM. Although hardness measurements are not reliable on severely damaged enamel surfaces as depicted in figures 2 and 3, they may be a good marker for the initial softening of the enamel specimens; in other words, they characterize the onset of the caries process. As soon as more severe demineralization occurs, LMR or OM are the methods of choice. The high correlation observed between both techniques was also reported previously.<sup>12</sup>

The fluoride concentration in the outer region of the ground and polished enamel specimens was increased by a factor 1.5, although the patients did not use any fluoride-containing agents when cleansing their dentures. This may be ascribed to the use of fluoride containing beverages (e.g. tea). The fluoride content of tap water may be negligible.

From this study it may be concluded that the proposed in situ model is suitable to study the onset and progression of xerostomia-related dental caries and may be useful to study the efficacy of preventive measures.

## REFERENCES

- 1 del Regato JA. Dental lesions observed after roentgen therapy in cancer of the buccal cavity, pharynx and larynx. *Am J Roentgenol* 1939;42:404-410.
- 2 Frank RM, Herdly J, Philippe E. Acquired dental defects and salivary gland lesions after irradiation for carcinoma. *J Am Dent Assoc* 1965;70:868-883.
- 3 Karmiol M, Walsh RF. Dental Caries after Radiotherapy of the Oral Regions. *J Am Dent Assoc* 1975;91:838-845.
- 4 van Palenstein Helderman WH, Beijm W. Een geval van hoge cariëactiviteit bij medicatie tegen de ziekte van Parkinson. *Ned Tijdschr Tandheelkd* 1983;90:545-550.
- 5 Dreizen S, Brown LR, Thomas TE, Drane JB. Prevention of xerostomia-related dental caries in irradiated cancer patients. *J Dent Res* 1977;56:99-104.
- 6 Wescott WM, Starcke EN, Shannon IL. Chemical protection against postirradiation dental caries. *Oral Surg Oral Med Oral Pathol* 1975;40:709-719.
- 7 Katz S. The use of fluoride and chlorhexidine for the prevention of radiation caries. *J Am Dent Assoc* 1982;104:164-170.
- 8 Markitziu A, Gedalia I, Stabholz A, Shuval J. Prevention of caries progress in xerostomic patients by topical fluoride applications: a study in vivo and in vitro. *J Dent* 1982;10:248-253.
- 9 Horiot JC, Schraub S, Bone MC, Bain Y, Ramadier J, Chaplain G, Nabid N, Thevenot B, Bransfield D. Dental preservation in patients irradiated for head and neck tumours: A 10-year experience with topical fluoride and a randomized trial between two fluoridation methods. *Radiother Oncol* 1983;1:77-82.
- 10 Vissink A, 's-Gravenmade EJ, Panders AK, Vermey A, Petersen JK, Visch LL, Schaub RMH. A clinical comparison between commercially available mucin- and CMC-containing saliva substitutes. *Int J Oral Surg* 1983;12:132-138.
- 11 de Bruyn H, Hummel M, Arends J. In vivo effect of a fluoridating varnish with various fluoride contents on human enamel. *Caries Res* 1985;19:407-413.
- 12 de Josselin de Jong E. Comparison of methods in caries research; thesis Groningen, 1986.
- 13 ten Bosch JJ, Borsboom PCF, ten Cate JM. A nondestructive method for monitoring de- and remineralization of enamel. *Caries Res* 1980;14:90-95.
- 14 ten Bosch JJ, van der Mei HC, Borsboom PCF. Optical monitor of in vitro caries. A comparison with chemical and microradiographical determination of mineral loss in early caries lesions. *Caries Res* 1984;18:540-547.
- 15 Vogel GL, Chow LC, Brown WE. A microanalytical procedure for the determination of calcium, phosphate and fluoride in enamel biopsy samples. *Caries Res* 1983;17:23-31.

- 16 Chen PS, Toribara TY, Warner H. Microdetermination of phosphorous. *Anal Chem* 1956;28:1756–1758.
- 17 Söremark R, Samsahl K. Gamma-ray spectrometric analysis of elements in normal human enamel. *Archs Oral Biol* 1961; 6:275–283.
- 18 Retief DH, Sorvas P, Bradley E, Taylor R, Walker A. In vitro fluoride uptake, distribution and retention by human enamel after 1- and 24-hour application of various topical fluoride agents. *J Dent Res* 1980;59:573–582.
- 19 Jansma J, Vissink A, Jongebloed WL, Retief DH, 's-Gravenmade EJ. A SEM study of natural and induced radiation caries. *Am J Dent* (submitted, 1991).
- 20 Creanor SL, Strang R, Telfer S, MacDonald I, Smith MJ, Stephen KW. In situ appliance for the investigation of enamel de- and remineralisation. A pilot study. *Caries Res* 1986;20:385–391.
- 21 Kotsanos N, Darling AI, Levers BGH. A model for the production of artificial caries in the mouth of man. *Archs Oral Biol* 1986;31:491–495.
- 22 Meyerowitz C, Featherstone JDB, Shariati M, Eisenberg AD. Radiation-induced hyposalivation and caries. *J. Dent. Res.* 1986;65:831.
- 23 Billings RJ, Meyerowitz C, Featherstone JDB. Oral fluoride retention in temporary drug-induced xerostomic subjects. *J Dent Res* 1986;65:782.
- 24 Weerkamp AH, Wagner K, Vissink A, 's-Gravenmade EJ. Effect of the application of a mucin-based saliva substitute on the oral microflora of xerostomic patients. *J Oral Pathol* 1987;16:474–478.

## A SEM STUDY OF NATURAL AND INDUCED RADIATION CARIES

### INTRODUCTION

Radiation caries, a highly destructive form of dental caries, is a well-known indirect side effect of radiation treatment for malignant tumors in the head and neck region.<sup>1-3</sup> Irradiation-induced hyposalivation is considered to be the most important etiological factor. Reduced salivary flow and changed salivary composition result in a loss of the protective properties of saliva, a decrease of the salivary pH and buffering capacity, changed nonimmune and immune antibacterial systems, and a shift in oral flora towards cariogenic microorganisms. Hyposalivation gives rise to a change in the pattern of food consumption to frequent, sticky, high-carbohydrate meals.<sup>2,4-11</sup> These factors contribute to an enormous increase in the caries challenge in irradiated patients. In recent studies it was shown that X-irradiation decreased the enamel acid solubility.<sup>12-14</sup> This implies that irradiated enamel is not more susceptible to demineralization than non-irradiated dental enamel, and that irradiation-induced hyposalivation is the main causative factor of radiation caries.

As soon as three months after radiotherapy, radiation caries may become clinically evident. It appears independent on whether the teeth are included in the field of irradiation or not.<sup>15,16</sup> Radiation caries progresses so rapidly that a healthy dentition can be totally ruined within one year.<sup>16</sup> Generalized superficial defects that initially affect the smooth surfaces of the teeth are frequently observed. These lesions may result in complete destruction of the coronal enamel and dentin. Decay localized at the incisal or occlusal edges of the teeth is often noticed with these lesions. A second common type of lesion is localized at the cervical regions of the teeth. Progression of these lesions all around the necks may lead to amputation of the crowns of the teeth, particularly the incisors. Occasionally, a brown-black discoloration of the entire tooth crown is observed with abrasion of incisal and occlusal edges.<sup>2,3</sup>

The morphological characteristics of radiation caries have been described.<sup>2,3,17,18</sup> No details of the morphologic development of radiation caries as a function of time, however, were given in these studies. In this paper the morphological features of natural and induced radiation caries are described. The initiation and progression of this type of caries were studied using the in situ model for the induction of xerostomia-related dental caries as described on pages 66–73.

## MATERIALS AND METHODS

### Natural radiation caries

*Patients.* Eleven permanent molars and incisors, extracted from six patients who had undergone head and neck radiotherapy (50–70 Gy, 2 Gy/day, 5 days/week), were used. The mean age of the subjects was 63.4 years (range 40–70 years) and all the salivary glands had been included in the treatment portals. Because of the relatively low salivary flow rate, the degree of hyposalivation could be estimated only as the amount of oral fluid present in the oral cavity. This was measured by wiping the oral cavity after swallowing with a water-absorbant gauze, which was weighed before and after saliva collection. The test was performed on three different days at approximately the same point of time, and the subjects were not allowed to take food or beverages for two hours before the test.<sup>19</sup> The teeth that were extracted were all caries free pre-irradiation and had developed radiation caries during a period of non-compliance with preventive measures. They were divided into two categories based on the extent of decay of the crowns:

- 1 crowns with superficial smooth surface caries and/or slight decay at the cervical regions (n=4);
- 2 severely decayed crowns with exposure of dentin (n=7).

*Scanning electron microscopy.* The teeth were washed in running tap water to remove surface debris. Thereafter the teeth were fixed in a 2% (w/v) buffered (0.1 M sodium cacodylate, pH 7.4) glutaraldehyde solution at 20°C for 16 hours, washed with 0.1 M sodium cacodylate buffer solution (pH 7.4) for 10 minutes to remove excess glutaraldehyde and post-fixed in a 1% (w/v) OsO<sub>4</sub> in cacodylate buffer solution for eight hours at 4°C. After fixation, the teeth were washed in the same buffer solution to remove the non-bound OsO<sub>4</sub> and then in distilled water to remove the buffer. Subsequently, the teeth were dehydrated in a graded series of ethanol up to 100% ethanol. The ethanol was exchanged for iso-amyl acetate in a critical point apparatus and dried with liquid CO<sub>2</sub> (C<sub>T</sub> 33°C, C<sub>P</sub> 72 atm.). The prepared teeth were glued on aluminium stubs with fast curing epoxy resin, coated with gold (approximately 15 nm) in a sputter coater (Balzers Union, Balzers, Liechtenstein) and examined in a JEOL 35C SEM (JEOL, Tokyo, Japan) operated at 15 or 25 kV.

### Induced radiation caries

*Patients and control subjects.* Seven irradiated edentulous patients, four men and three women (mean age 67.3 years, range 55–73 years) and six non-irradiated edentulous subjects, two men and four women (mean age 56.2 years, range 43–67 years), participated in this part of the study. The irradiated patients all suffered from xerostomia. They had received an average radiation dose of 55 Gy (range 50–66 Gy) at a level of 2 Gy/day, 5 days/week to the head and neck area. All salivary glands were included in the treatment portals and irradiation treatment was completed

at least one year before starting the experiment. All patients and control subjects wore full dentures. The salivary secretion was estimated with the wiping method.

*Modification of dentures.* Both the left and right molars of the lower denture of a patient or control subject were replaced by a metal sample holder.<sup>20</sup> Each holder contained six enamel slabs (three slabs buccally and three lingually), which could be removed and replaced by unscrewing the occlusal part of the holder. About 9 mm<sup>2</sup> of each slab was exposed to the oral environment and the surface of each slab was about 0.5 mm below the outer surface of the sample holder.

*Enamel slab preparation.* The labial surfaces of cariesfree human mandibular permanent incisors and canines were partially ground flat on 1,200 grit silicon carbide paper on a polishing machine (Buehler Ltd., Lake Bluff, Ill., USA), polished on a Kent Mark II polisher (Engis, Maidstone, England) using Hypress diamond compounds (1 µm; Engis) and cut in rectangular blocks (3×4×1.5 mm) by means of a water-cooled diamond saw (Horico, Berlin, FRG). All enamel slabs were embedded in cold-curing polymethylmethacrylate (Rapid Repair, DeTrey, Wiesbaden, FRG). Care was taken to keep the polished enamel surfaces free from acrylic resin. Finally, the slabs were ultrasonically cleaned in tap water for 10 min.

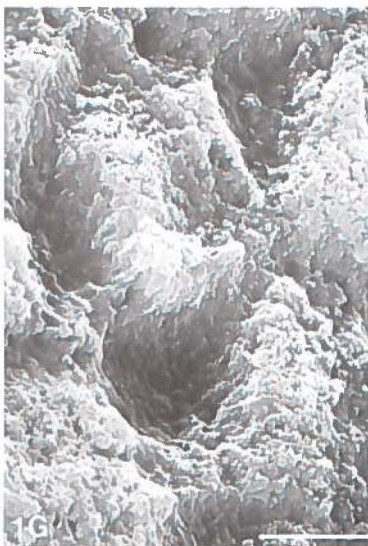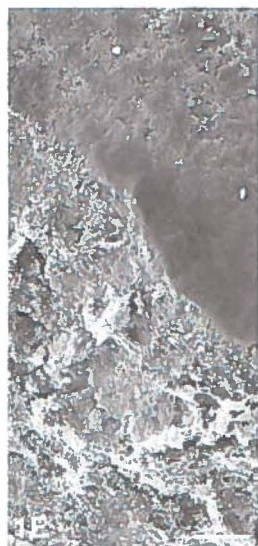
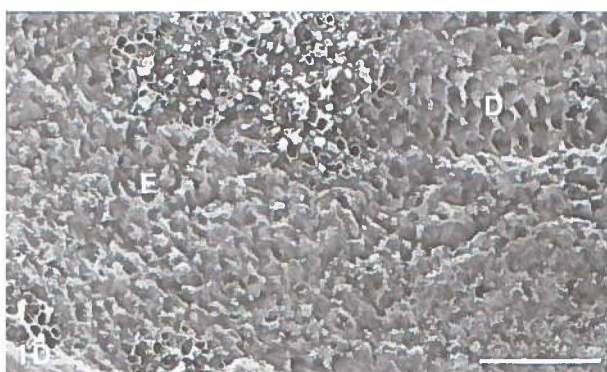
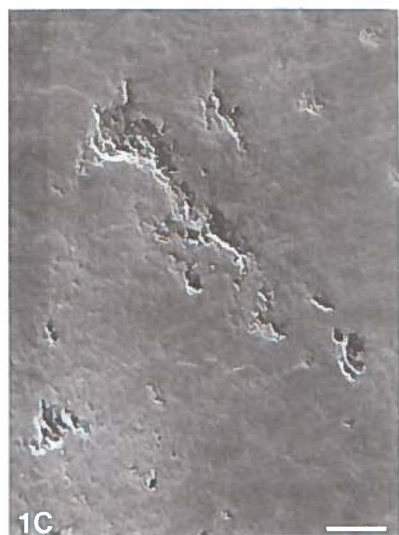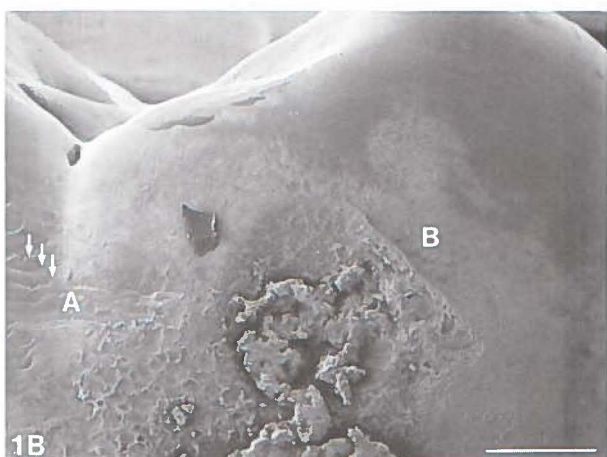
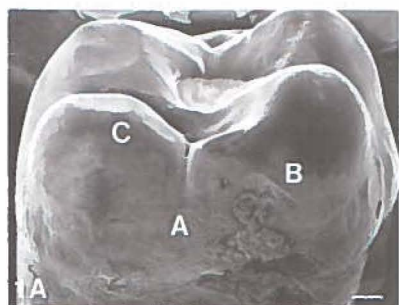
*Hardness measurements.* Microhardness measurements perpendicular to the enamel surface were performed with a Leitz Durimet miniloading hardness tester fitted with a Knoop diamond (Leitz, Wetzlar, FRG). A load of 100 g was applied for 20 s. Five indentations were made in a definite pattern in the central area of each enamel slab.

*Scanning electron microscopy.* The enamel slabs were washed under running tap water and wiped with cleansing tissue to remove surface debris, dried in air and subsequently glued on aluminium stubs with fast curing epoxy resin. Specimens were not fixed with glutaraldehyde and OsO<sub>4</sub> and critical point dried, as was performed with the natural radiation caries samples, because the presence of bacteria was not an important part of the study of induced radiation caries. When transverse examinations were required, the slabs were also fractured. A thin Au layer (approximately 15 nm) was sputtered on the slabs. Scanning electron micrographs were taken with a JEOL 35C SEM operated at 15 or 25 kV.

*Experimental set-up.* In irradiated patients the experiments extended over a six week period as beyond this period most enamel slabs were so severely affected that the enamel was lost. At weekly intervals an enamel slab was removed randomly from the dentures of each patient for SEM evaluation. The control experiments extended over a 12 week period. Three, 6, and 12 weeks after the start of the experiment an enamel slab was removed for SEM. In both patients and control subjects, hardness measurements were performed on enamel slabs at the times mentioned above.

All subjects were not allowed to clean the enamel slabs other than under running tap water. The remaining parts of their dentures were brushed with toothpaste containing no fluoride (Prodent Non-Fluoride, Kortman Intradal, Veenendaal, The Netherlands). The participants were instructed to keep their dentures in tap water (0.1 mg/l F<sup>-</sup>) during the night.





## RESULTS

All irradiated patients suffered from moderate to severe xerostomia with the amount of saliva in the oral cavities being less than 450 mg. The control subjects had amounts of saliva greater than 1.5 g in their oral cavity, which can be considered to be normal.<sup>19</sup>

### Natural radiation caries


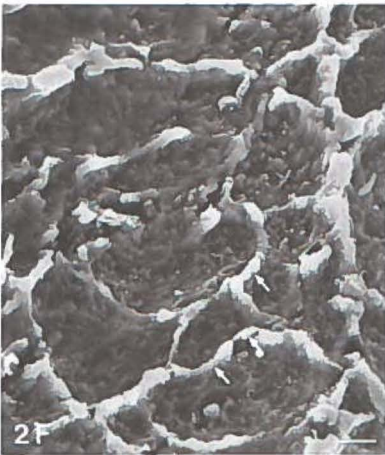
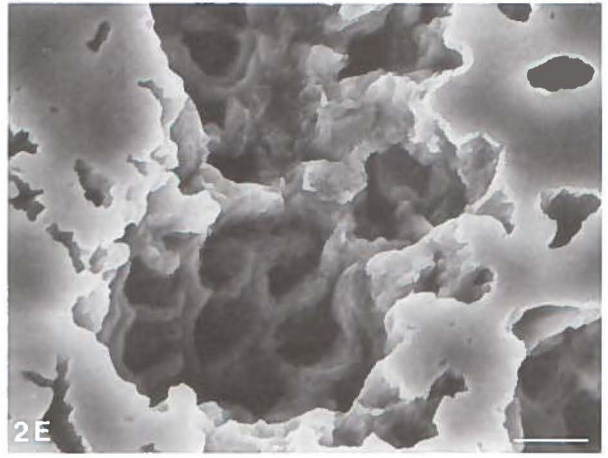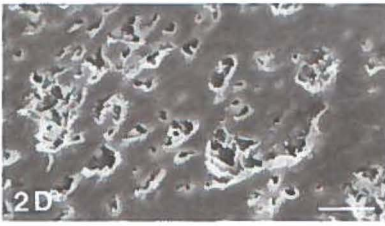
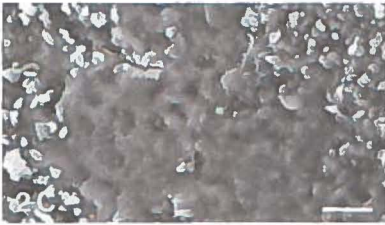
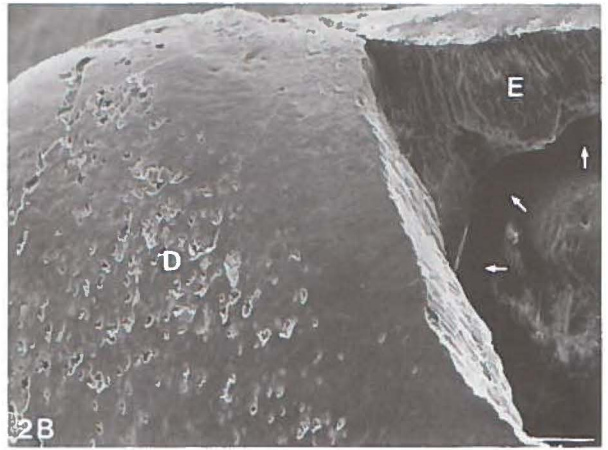
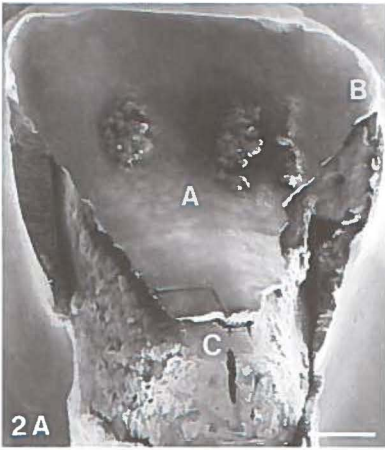
Characteristic morphological features of natural radiation caries are depicted in SEM micrographs from a representative maxillary molar (Fig. 1), incisor (Fig. 2), and cuspid (Fig. 3). At most carious sites the teeth were covered with a dense plaque accumulation, consisting of spheroidal, spherical, rod-shaped and filamentous bacteria.

*Figure 1: maxillary molar.* The distal surface of a maxillary molar is shown in Figs. 1A and 1B. The neighboring tooth was removed before irradiation. The crown of the molar is relatively intact, but signs of superficial smooth surface decay can be seen on almost the entire distal surface (Fig. 1B, areas A and B) and the cusps (Fig. 1A, area C). The pattern of decay is widespread and irregular. At location A demineralization resulted in the exposure of well pronounced perikymata (Fig. 1B, arrows). Higher magnifications of this region (Figs. 1D, 1F, 1G) show a key hole like appearance with two patterns of destruction. The most characteristic type is due to preferential dissolution of the prism cores whereas interprismatic substance is less affected (area D on Fig. 1D, Fig. 1F). Similar hollowing out of prism cores can be observed at location B which is depicted at a higher magnification in Fig. 1E. Instead of hollowing out, a peripheral dissolution of prism sheaths with simultaneous dissolution of the interprismatic space was observed in some regions of the surface area (area E on Fig. 1D, Fig. 1G). A higher magnification of a functional cusp tip area (area C on Fig. 1A) shows porosity of enamel and crater formation (Figs. 1C). Subsurface enamel is exposed due to demineralization of the surface enamel at these locations.

*Figure 2: maxillary incisor.* Fig. 2A shows a severely decayed maxillary incisor with extensive cervical caries. Most enamel is lost from the cervical and proximal areas. It is a characteristic finding that in the more advanced cases of radiation decay fractures occur within the enamel and large parts of the tooth crowns become

**Fig. 1** Maxillary molar. **A** Distal surface of a maxillary molar (Bar 1 mm). **B** Higher magnification of distal surface with smooth surface demineralization at location A with exposure of well pronounced perikymata (arrows) (Bar 1 mm). **C** Higher magnification of a functional cusp tip area at location C showing porosity of enamel and crater formation (Bar 50  $\mu\text{m}$ ). **D** Higher magnification of location A with key hole like appearance. Two different patterns of demineralization at locations D and E. (Bar 50  $\mu\text{m}$ ). **E** Higher magnification of location B showing porosity and crater formation on a smooth surface and hollowing out of prism cores in an area with large plaque deposits (Bar 50  $\mu\text{m}$ ). **F** Preferential dissolution of prism cores with remnants of interprismatic substance at location D (Bar 3  $\mu\text{m}$ ). **G** Dissolution of prism sheaths as observed at location E (Bar 3  $\mu\text{m}$ ).





denuded of enamel resulting in exposure of the underlying dentin. The gap between enamel and dentin shown in the SEM micrographs (Fig. 2B, arrows) is an artefact caused by differences in shrinkage of enamel and dentin during preparation of the specimens for SEM. The palatal (area A on Fig. 2A, Fig. 2C) and incisal (area D on Fig. 2B, Fig. 2D) surfaces show evidence of demineralization. The enamel in these regions shows large areas with irregular patterns of surface destruction with crater formation. Exposure of subsurface enamel in such craters with evidence of hollowing out of prism cores is depicted at a higher magnification in Fig. 2E. Fig. 2F represents an area of exposed dentin at the cervical region (area C on Fig. 2A). In most of these cases it looked as if the enamel mineral had dissolved from some areas and had reprecipitated in adjacent areas (Fig. 2F, arrows). A higher magnification of an area where fracture has occurred within the enamel (area E on Fig. 2B) shows preferential dissolution and hollowing out of prism cores (Fig. 2G and 1F).


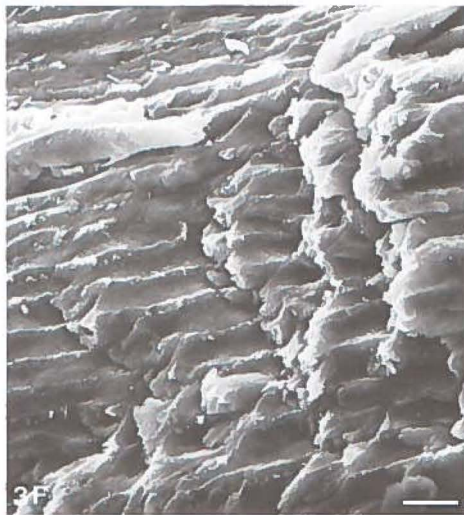



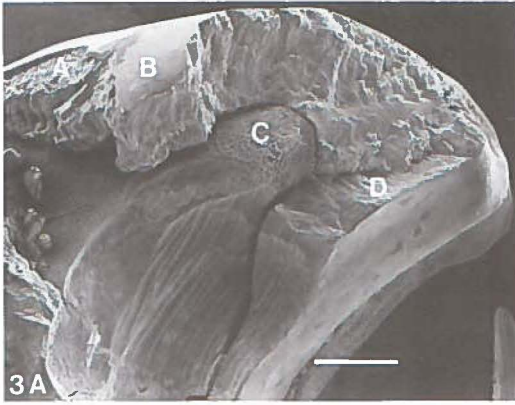
*Figure 3: maxillary cuspid.* Fig. 3A depicts a severely decayed maxillary cuspid with major parts of the labial, incisal, palatal and mesial surfaces denuded of enamel. Both exposure and decay of dentin can be observed. At location A, a large area of surface enamel has been lost (Fig. 3A). The result is exposure of subsurface enamel with pronounced perikymata and preferential dissolution of prism cores with remnants of interprismatic substance (Figs. 3B, 3E). Higher magnifications of the labial surface (area B on Fig. 3A) show wide-spread crater formation (Figs. 3C, 3D). Areas of fractured enamel (Fig. 3F) and exposed dentin (Fig. 3G) show the same phenomena as in Fig. 2, namely typical patterns of hollowing out of prism cores (Fig. 2G) and reprecipitation of dissolved enamel mineral (Fig. 2F).

### Induced radiation caries

SEM of the enamel slabs from irradiated patients all showed characteristic patterns of demineralization and decay. The SEM micrographs from representative enamel slabs obtained from different patients are depicted in Figs. 4 and 5.

*Figure 4: early stages.* During the first weeks most enamel slabs showed an accentuation of an arcade-formed prismatic structure (Figs. 4A, 4B, Fig. 4D area A). In many slabs microfractures developed along these prismatic arcades (Fig. 4C, Fig. 4D area B). From the third week onward most of the samples showed a porous enamel surface and starting crater formation (Figs. 4E, 4F). Although plaque accumulation was greater at the peripheral parts of the slabs, the carious destruction

**Fig. 2** Maxillary incisor. **A** Palatal surface of a severely decayed maxillary incisor with extensive cervical caries, loss of enamel from cervical and proximal areas, enamel fractures (location B) and exposure of dentin (Bar 1 mm). **B** Detail of the incisal edge showing demineralization (location D) and fractured enamel (location E); gap (arrows) due to shrinkage (Bar 100  $\mu\text{m}$ ). **C** Detail of demineralization at location A (Bar 10  $\mu\text{m}$ ). **D** Higher magnification of location D with an irregular pattern of porosity and crater formation (Bar 30  $\mu\text{m}$ ). **E** Detail of location A with crater formation and exposure of subsurface enamel (Bar 5  $\mu\text{m}$ ). **F** Exposed dentin at location C with characteristic precipitation of calcium phosphate salts (arrows)(Bar 10  $\mu\text{m}$ ). **G** Higher magnification of fractured enamel at location E showing preferential dissolution of prisms (Bar 5  $\mu\text{m}$ ).





was extensive in both the central and peripheral parts of the slabs.

*Figure 5: advanced stages.* After three to six weeks most enamel slabs were severely damaged and demineralized. In many slabs large parts of the surface enamel were lost exposing the deeper enamel layers (area A on Fig. 5A). At higher magnification a characteristic pattern of demineralization, namely preferential dissolution of the prism cores with remnants of interprismatic substance, was observed. The result is a key hole like appearance (Figs. 5B, 5C). Fig. 5D represents a detail of area B on Fig. 5A, where generalized porosity with starting crater formation is depicted. In some cases the enamel had even peeled off exposing the dentin (Fig. 5E). The pictures suggest that the tooth mineral was dissolved from some areas and was reprecipitated in adjacent areas (Figs. 5E, 5F).

Most control enamel slabs showed no demineralization during the twelve week experimental period when viewed in the SEM. At most, local areas with slight porosity of the enamel surface were observed.

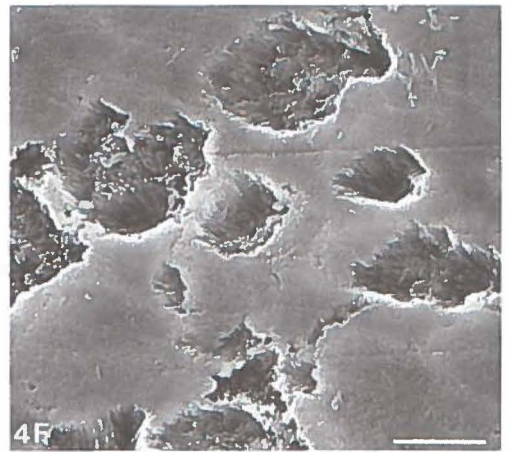
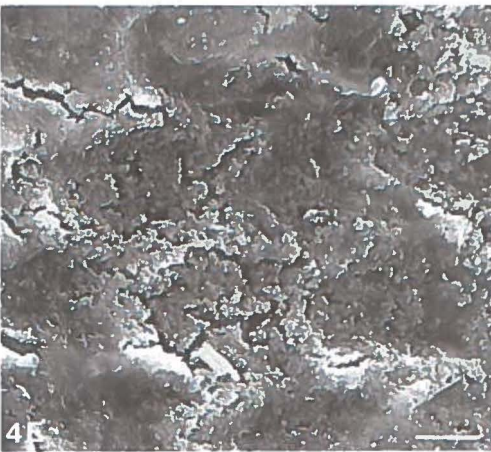
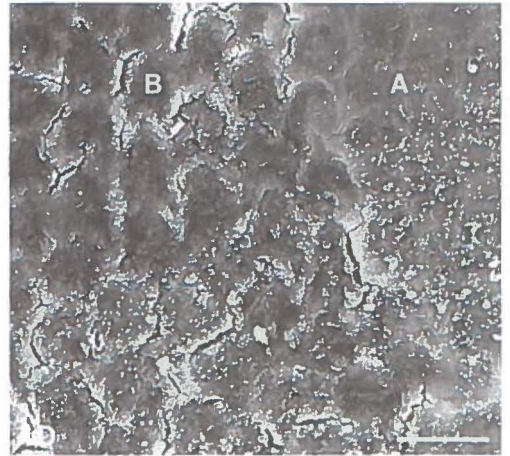

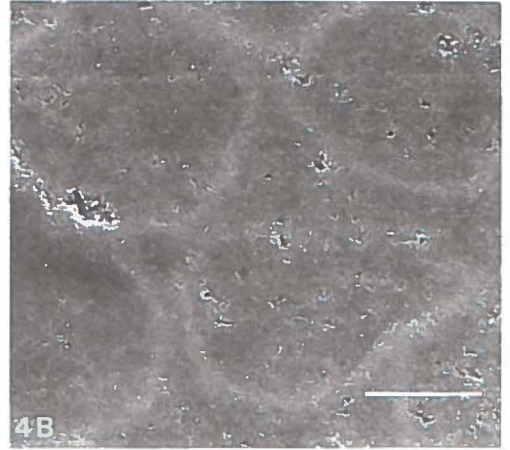
*Hardness measurements.* The changes in indentation length,  $I$  ( $\mu\text{m}$ ), of the enamel slabs placed in the oral cavities of irradiated patients (0-6 weeks) and control subjects (0-12 weeks) are shown in Fig. 6. In irradiated patients, about one third of the enamel slabs was damaged so severely by the progressive caries process after the third week that further measurements were not reliable. For that reason median values are presented instead of mean values, and no standard deviations are given. The hardness measurements indicated a significant demineralization of the samples in irradiated patients within 2 weeks. In control samples no increase in indentation length was observed.

## DISCUSSION

Early radiation caries lesions seem to be similar to incipient normal caries lesions in permanent teeth.<sup>2,18,21,22</sup> The prismatic pattern of demineralization and the irregular pattern of destruction have also been observed in normal incipient carious lesions.<sup>21</sup> Striking differences between normal and radiation caries are the rapid onset and progression of radiation caries, its widespread occurrence on enamel surfaces, the loss of large enamel parts and the fact that radiation caries is most commonly found on tooth surfaces that are relatively immune to dental caries.

As mentioned in the introduction, the main etiological factor for radiation caries

**Fig. 3** Maxillary cuspid. **A** Severely decayed maxillary cuspid with major parts of labial, incisal, palatal and mesial surfaces denuded of enamel (Bar 1 mm). **B** Higher magnification of location A with loss of large part of surface enamel exposing subsurface enamel with pronounced perikymata (Bar 50  $\mu\text{m}$ ). **C** Higher magnification of labial smooth surface at location B showing demineralization (Bar 100  $\mu\text{m}$ ). **D** Higher magnification of location B with porosity of enamel and crater formation (Bar 10  $\mu\text{m}$ ). **E** Detail of location A showing characteristic hollowing out of prism cores with remnants of interprismatic substance (Bar 10  $\mu\text{m}$ ). **F** Higher magnification of fractured enamel at location D showing a longitudinal view with evidence of preferential prism dissolution (Bar 10  $\mu\text{m}$ ). **G** Higher magnification of exposed dentin at location C with characteristic precipitation of calcium phosphate salts (arrows)(Bar 10  $\mu\text{m}$ ).



is irradiation-induced hyposalivation. The quantitative and qualitative changes of whole saliva and the concomitant shift in the oral flora towards cariogenic microorganisms produce a cariogenic environment that is aggravated by the changed pattern of food consumption.<sup>8</sup> Direct effects of ionizing irradiation on dental enamel do not contribute significantly to the demineralization process.<sup>12-14,23</sup> In radiation caries the characteristic demineralization on caries immune, self-cleansing areas, is also related to the altered oral environment produced by irradiation-induced changes in salivary flow, composition and consistency of saliva that gives rise to accumulation of highly acidogenic dental plaque on these surfaces.<sup>3</sup> The aggressiveness of the oral environment was clearly demonstrated in the model by the difference in progression between caries induced in irradiated versus non-irradiated subjects.

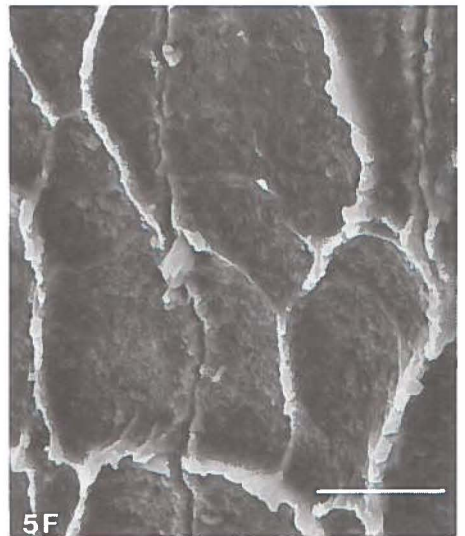



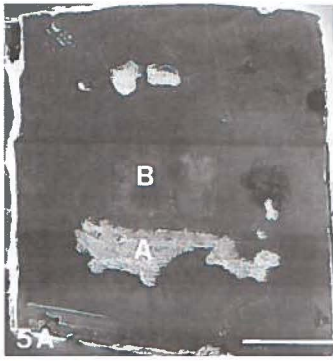
To induce radiation caries lesions in a relatively standardized and reproducible way, the surface layer of the enamel slabs was removed in the model. Previous studies carried out in our laboratory had shown that the enamel fluoride concentrations in adjacent sites on unground surfaces varied significantly, whereas removal of the surface enamel by grinding resulted in enamel fluoride concentrations in adjacent sites that were not significantly different.<sup>24</sup> The occurrence of dissolution of prism sheaths in some surface areas of extracted teeth in stead of the mostly observed hollowing out of prisms, may be related to local differences in the fluoride content of the surface layer<sup>25</sup> and was probably seen less in the model because of removal of the surface layer during slab preparation. Edentulous subjects were chosen because data obtained in these subjects are not influenced by variables such as oral hygiene or other preventive measures (topical fluoride applications) which an irradiated dentulous subject has to apply in order to preserve his dentition. Considering the oral flora, only minor differences in its composition exist between dentulous and denture-wearing edentulous xerostomic patients.<sup>26</sup>

From the rapid, standardized and reproducible induction of radiation caries in the in situ model, the sequence of the stages in the development of radiation caries can be followed. The initial step in the demineralization process is the occurrence of porosity on widespread areas of enamel. This is followed by crater formation with exposure of subsurface enamel, preferential dissolution and hollowing out of prism cores, loss of large parts of surface enamel and loss of full enamel coverage exposing the underlying dentin. The same morphological features were observed in the extracted teeth with natural radiation caries. In these teeth, however, the more advanced stages predominated.

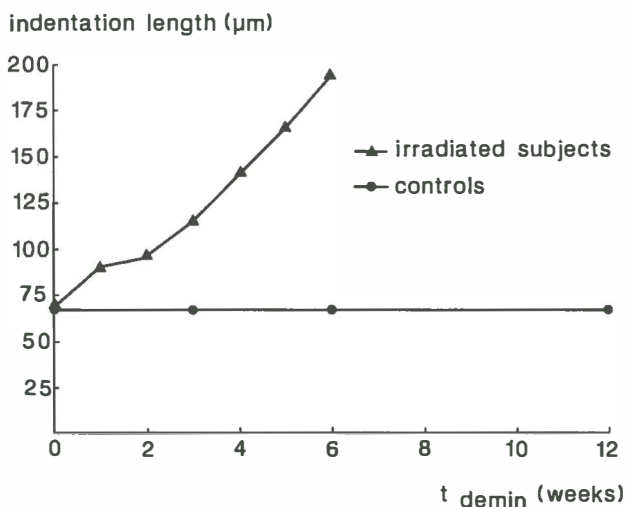
In a previous investigation, comparison of results obtained with scanning longi-

**Fig. 4** Early stages of induced radiation caries. **A** Accentuation of arcade-formed prismatic structure (Bar 10  $\mu\text{m}$ ). **B** Detail of accentuated arcade-formed prismatic structure (Bar 3  $\mu\text{m}$ ). **C** Development of splits and microfractures along prismatic arcades (Bar 3  $\mu\text{m}$ ). **D** Starting crater formation from third week onward (Bar 10  $\mu\text{m}$ ). **E** Higher magnification of crater formation at location B of Fig. 4D (Bar 3  $\mu\text{m}$ ). **F** Higher magnification of craters from another slab showing exposure of deeper enamel layers (Bar 10  $\mu\text{m}$ ).









**Fig. 6** Indentation length ( $\mu\text{m}$ ) of the enamel slabs in irradiated patients ( $n=7$ ) and control subjects ( $n=6$ ) as a function of time of demineralization (weeks).

tudinal microradiography (LMR), scanning optical monitoring (OM) and hardness measurements showed a significant increase in indentation length before any significant change in mineral composition could be observed with LMR and OM.<sup>13</sup> SEM observations only showed accentuation of prisms at that point of time. Although hardness measurements are not reliable on severely damaged enamel surfaces, they can be utilized as an indicator of the initial softening of the enamel slabs and were added to the model to characterize the onset of the caries process.

In this study it has been shown that in situ induced radiation caries resembled natural radiation caries. In all patients, the induced radiation caries showed the same typical patterns of decay and the same sequence of events. The in situ model may offer an outstanding opportunity to study preventive regimens, for example fluoride applications, in preserving the natural dentition in subjects who have undergone head and neck radiotherapy.

**Fig. 5** Advanced stages of induced radiation caries. **A** Overview of enamel slab after three weeks with loss of large parts of surface enamel (Bar 1 mm). **B** Detail (area A) of subsurface enamel showing a characteristic prismatic pattern of demineralization with preferential dissolution of prisms and remnants of interprismatic substance (Bar 30  $\mu\text{m}$ ). **C** Volcano aspect of hollowed out prism cores, detail of Fig. 5B. (Bar 3  $\mu\text{m}$ ). **D** Higher magnification of location B with generalized porosity and starting crater formation (Bar 3  $\mu\text{m}$ ). **E** Overview of enamel slab after six weeks with evidence of loss of full enamel coverage at location D and relatively intact surface enamel at location C (Bar 1 mm). **F** Higher magnification of exposed dentin at location B with characteristic precipitation of calcium phosphate salts (Bar 30  $\mu\text{m}$ ).

## REFERENCES

- 1 del Regato JA. Dental lesions observed after roentgen therapy in cancer of the buccal cavity, pharynx and larynx. *Am J Roentgenol* 1939;42:404-410.
- 2 Frank RM, Herdly J, Philippe E. Acquired dental defects and salivary gland lesions after irradiation for carcinoma. *J Am Dent Assoc* 1965;70:868-883.
- 3 Karmiol M, Walsh RF. Dental caries after radiotherapy of the oral regions. *J Am Dent Assoc* 1975;91:838-845.
- 4 Ben-Aryeh H, Gutman D, Szargel R, Laufer D. Effects of irradiation on saliva in cancer patients. *Int J Oral Surg* 1975;4:205-210.
- 5 Brown LR, Dreizen S, Handler S, Johnston DA. Effect of radiation-induced xerostomia on human microflora. *J Dent Res* 1975;54:740-750.
- 6 Brown LR, Dreizen S, Rider LJ, Johnston DA. The effect of radiation-induced xerostomia on saliva and serum lysozyme and immunoglobulin levels. *Oral Surg Oral Med Oral Pathol* 1976;41:83-92.
- 7 Brown LR, Dreizen S, Daly TE, Drane JB, Handler S, Riggan LJ, Johnston DA. Interrelations of microorganisms, immunoglobulins and dental caries following radiotherapy. *J Dent Res* 1978;57:882-893.
- 8 Dreizen S, Brown LR, Handler S, Levy BM. Radiation-induced xerostomia in cancer patients. Effects on saliva and serum electrolytes. *Cancer* 1976;39:273-278.
- 9 Shannon IL, Starcke EN, Wescott WB. Effect of radiotherapy on whole saliva flow. *J Dent Res* 1977;56:693.
- 10 Shannon IL, Wescott WB, Starcke EN, Mira J. Laboratory study of cobalt-60-irradiated human dental enamel. *J Oral Med* 1978;33:23-27.
- 11 Cowman RA, Baron SS, Glassman AH, Davis ME, Strosberg AM. Changes in protein composition of saliva from irradiation-induced xerostomia patients and its effect on growth of oral streptococci. *J Dent Res* 1983;62:336-340.
- 12 Joyston-Bechal S. The effect of X-radiation on the susceptibility of enamel to an artificial caries-like attack in vitro. *J Dent* 1985;13:41-44.
- 13 Jansma J, Buskes JAKM, Vissink A, Mehta DM, 's-Gravenmade EJ. The effect of X-ray irradiation on the demineralization of bovine dental enamel. A constant composition study. *Caries Res* 1988;22:199-203.
- 14 Markitziu A, Weshler R, Grajover M, Avital M, Gedalia A. Solubility, wear and microhardness in irradiated rat molars. *J Dent Res* 1989;68:876.
- 15 Silverman S, Chierici A. Radiation therapy of oral carcinoma. Effects on oral tissues and management of the periodontium. *J Periodontol* 1965;36:478-484.
- 16 Dreizen S, Brown LR, Daly E, Drane JB. Prevention of xerostomia related dental caries in irradiated cancer patients. *J Dent Res* 1977;56:99-104.
- 17 Anneroth G, Holm LE, Karlsson G. The effect of radiation on teeth. A clinical, histological and microradiographic study. *Int J Oral Surg* 1985;14:269-274.
- 18 Jongebloed WL, 's-Gravenmade EJ, Retief DH. Radiation caries. A review and SEM study. *Am J Dent* 1988;4:139-146.
- 19 Vissink A, 's-Gravenmade, Panders AK, Vermey A, Petersen JK, Visch LL, Schaub RMH. A clinical comparison between commercially available mucin- and CMC-containing saliva substitutes. *Int J Oral Surg* 1983;12:132-138.
- 20 Jansma J, Vissink A, 's-Gravenmade EJ, de Josselin de Jong E, Jongebloed WL, Retief DH. A model to investigate xerostomia-related dental caries. *Caries Res* 1988;22:357-361.
- 21 Haikel J, Frank RM, Voegel JC. Scanning electron microscopy of the human enamel surface layer of incipient carious lesions. *Caries Res* 1983;17:1-13.
- 22 Holmen L, Thylstrup A, Ogaard B, Kragh F. A scanning electron microscopic study of progressive stages of enamel caries in vivo. *Caries Res* 1985;19:355-367.
- 23 Jansma J, Borggreven JMPM, Driessens FCM, 's-Gravenmade EJ. Effect of X-ray irradiation on the permeability of bovine dental enamel. *Caries Res* 1990;24:164-168.
- 24 Benediktsson S, Retief DH, Bradley EL, Switzer P. The effect of contact time of acidulated phosphate fluoride on fluoride concentration in human enamel. *Archs Oral Biol* 1982;27:567-572.
- 25 Jongebloed WL. An ultrastructural study of the caries process; thesis Groningen, 1976.
- 26 Weerkamp AH, Wagner K, Vissink A, 's-Gravenmade EJ. Effect of the application of a mucin-based saliva substitute on the oral microflora of xerostomic patients. *J Oral Pathol* 1987;16:474-478.

## IN SITU STUDY ON THE PREVENTION OF RADIATION CARIES

### INTRODUCTION

Radiation caries, a rapidly progressing highly destructive type of dental caries, is a common side effect of radiation treatment.<sup>1-3</sup> According to Dreizen et al.,<sup>4</sup> carious lesions can be seen within three months and extreme damage of the dentition within one year after the start of radiotherapy. In several clinical studies it has been shown that almost complete caries prevention can be achieved in irradiated patients by the daily application of topical fluoride (F) agents combined with a program of strict oral hygiene.<sup>4-9</sup>

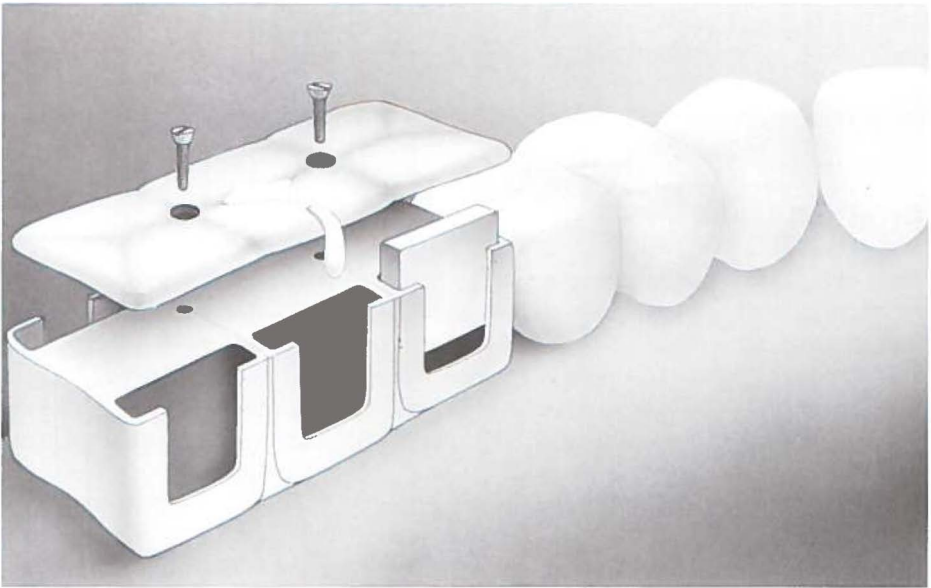
The aim of this study was to develop an optimal preventive program for radiation caries by evaluating the effects of F concentration and application procedures in subjects who have had irradiation treatment for malignant tumors of the head and neck.

### MATERIALS AND METHODS

*Subjects.* Seven edentulous subjects (3 women and 4 men) suffering from radiation-related xerostomia participated in this study. The subjects received an average radiation dose of 55 Gy (range 50–66 Gy) at a level of 2 Gy/day, 5 days/week from a <sup>60</sup>Co source. The mean age of the subjects was 67.3 years (range 55–73 yrs). All subjects wore full dentures. The severity of xerostomia was measured by wiping the oral cavity after swallowing with a water-absorbent gauze, which was weighed before and after saliva collection. The tests were performed on three different days between 10.00 and 10.30 a.m., and the subjects were not allowed to take food or beverages for 2 h before the test.<sup>10</sup>

*Experimental design.* In this study a recently developed in situ model for the investigation of xerostomia-related dental caries was used.<sup>11</sup> Both the left and right molars of the lower denture of each subject were replaced by a metal sample holder.<sup>12</sup> Each holder contained six human enamel slabs. The slabs could be removed and replaced by unscrewing the occlusal part of the holder (Fig. 1). About 9 mm<sup>2</sup> of each slab was exposed to the oral environment.

In all subjects four experiments were performed: procedure A: no F therapy (control); procedure B: 1% neutral NaF gel applied for 5 min every 2nd day; procedure C: 1% neutral NaF gel applied for 5 min once a week, and procedure D: rinsing with 10 ml of a F containing mouthwash (0.05% NaF, Prodent, Amersfoort, The Netherlands) for 1 min once daily. The subjects received information sheets with instructions for each of the four procedures. The NaF gel was applied with a squeeze



**Fig. 1** Sample holder mounted in a lower denture. The slabs can be removed and replaced by unscrewing the occlusal part of the holder.

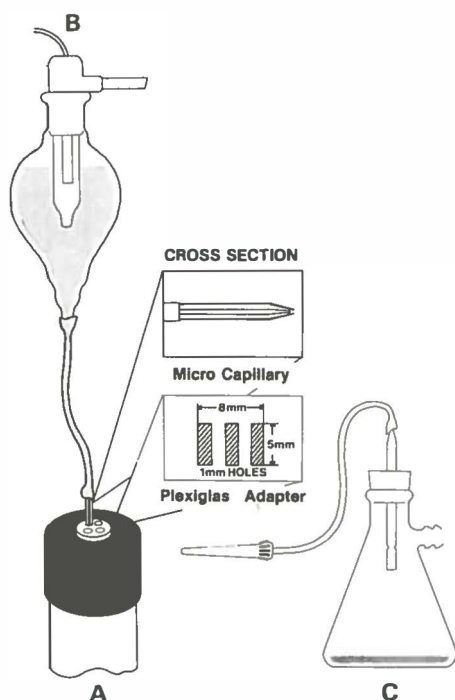
bottle (one drop per enamel specimen). The subjects were not allowed to clean the enamel slabs. They were instructed to keep their dentures in tap water during the night.

The enamel slabs were analyzed at weekly intervals using longitudinal microradiography (LMR), scanning optical monitoring (OM), scanning electron microscopy (SEM) and hardness measurements (HM). F analyses of the enamel slabs were done prior to their insertion in the appliances and after 6 weeks intraoral exposure. Each experiment extended over 6 weeks and the next was started after an interval of 2 weeks. In each experiment 12 enamel slabs per subject were examined: 4 for LMR and OM, 6 for HM and SEM and 2 for F analyses. Slabs used for SEM were replaced by acrylic blocks.

*Enamel slab preparation.* The facial enamel surfaces of noncarious human mandibular permanent incisors were partially ground flat on 1,200 grit silicon carbide paper, polished on a Kent Mark II polisher (Engis, Maidstone, England) using Hypres diamond compounds (Engis) and cut in rectangular slabs ( $3 \times 4 \times 1.5$  mm) by means of a water-cooled diamond saw (Horico, Berlin, FRG). For LMR and OM the lingual aspects of the enamel slabs were ground on 220 grit silicon carbide paper to obtain planoparallel slabs with a thickness of  $340 \pm 20 \mu\text{m}$ . All enamel slabs were embedded in cold-cure polymethylmethacrylate (de Trey, Wiesbaden, FRG) and ultrasonically cleaned in tap water for 10 min. Care was taken to keep the experimental facial sides free from acrylic resin.

*LMR and scanning OM.* By means of dental impression paste (President Regular Body; Coltène, Altstätten, Switzerland) the enamel slabs for LMR and OM were

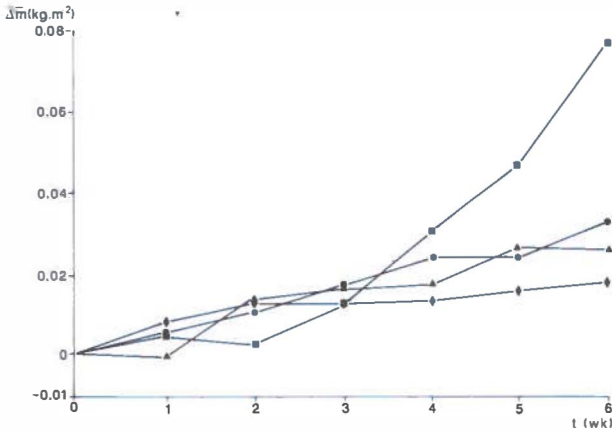
embedded in polymethylmethacrylate sample holders which fitted in both the LMR and OM experimental setup. In this manner an enamel slab could exactly be repositioned in its individual holder at each measuring interval to be scanned with LMR and OM at the same discrete surface position. LMR was performed as described by de Josselin de Jong<sup>13</sup> and de Josselin de Jong et al.<sup>14,15</sup> For OM the optical caries monitor as described by ten Bosch et al.<sup>16,17</sup> and Borsboom and ten Bosch<sup>18</sup> was applied. Both methods were performed before the start of each experiment and at weekly intervals for the duration of the investigation.



**Fig. 2** Apparatus for the measurement of F. **A** Selective F electrode, **B** reference calomel electrode, **C** suction apparatus.

*Scanning electron microscopy.* The enamel slabs were washed in running tap water to remove surface debris, and glued on aluminum stubs with fast-curing epoxy resin. When transverse examinations were required, these enamel slabs were also fractured. A thin Au layer (approximately 15 nm) was sputtered on the slabs. Scanning electron micrographs were taken at weekly intervals with a JEOL Type 35C (JEOL, Tokyo, Japan) scanning electron microscope operated at 25 kV.

*Hardness measurements.* Microhardness measurements were performed with a Leitz Durimet miniload hardness tester with a Knoop diamond (Leitz, Wetzlar, FRG) at a load of 100 g, applied for 20 s. Five indentations were made in a definite



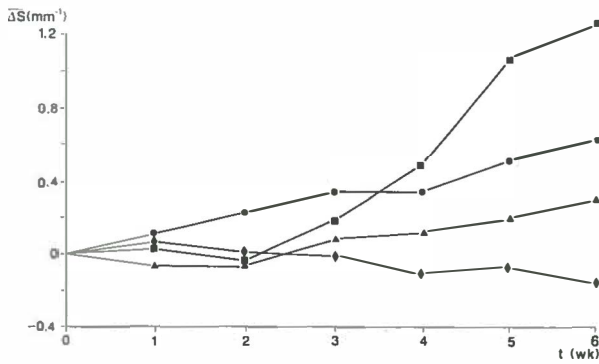
**Fig. 3** Mineral loss,  $\overline{\Delta m}$  ( $\text{kg.m}^{-2}$ ), of the enamel samples as a function of the time of demineralization (weeks) in the four experiments. Median values ( $n=7$ ). ■ = No F therapy; ◆ = F gel 1/2 days; ● = F gel 1/week; ▲ = F mouthrinse 1/day.

pattern in the central area of each enamel slab. The measurements were performed at weekly intervals.

**Biopsy procedures and F analysis.** Three successive acid etch biopsies were performed on the ground enamel surface of each enamel slab prior to insertion in the intraoral device. Biopsy sites were demarcated by placing an adhesive tape with a circular hole of 1 mm diameter on the enamel surface. Then  $0.4 \mu\text{l}$  of 1 M perchloric acid was deposited on the demarcated biopsy site, and absorbed after 5 s with a filter paper disc which was placed in a polyethylene tube containing  $25 \mu\text{l}$  total ionic strength adjustment buffer (TISAB) (Orion Research, Cambridge, Mass., USA). The etched area was washed twice in quick succession with  $0.4 \mu\text{l}$  TISAB and the washings transferred to the polyethylene tube.

The F concentrations in  $5\text{-}\mu\text{l}$  volumes of the etching solutions were determined by a microanalytical technique developed by Vogel et al.<sup>19</sup> The apparatus consists of a F selective electrode (Orion Research; Fig. 2,A) and a calomel reference electrode (Fig. 2,B) linked by a microcapillary tube. The phosphorus concentrations were determined in  $10 \mu\text{l}$  volumes by the analytical technique developed by Chen et al.<sup>20</sup> using a Spectronic 2000 spectrophotometer (Bausch and Lomb, Rochester, N. Y., USA). The mass enamel in the etching solutions was calculated by assuming that enamel contains 18.0% P,<sup>21</sup> and expressed in micrograms. The enamel F concentrations were adjusted to standardized depths of  $5 \mu\text{m}$ .<sup>22</sup> After the enamel slabs were exposed to the intraoral environment for 6 weeks, three successive acid etch biopsies were again carried out on demarcated biopsy sites immediately adjacent to the initial biopsy sites, and the enamel F concentrations were again adjusted to standardized depths of  $5 \mu\text{m}$ .

**Statistical analysis.** As a result of the deterioration of the enamel blocks in the oral environment of the xerostomic patients, exact measurements for LMR, OM and



**Fig. 4** Change in optical scattering,  $\Delta S$  ( $\text{mm}^{-1}$ ), as a function of the time of demineralization (weeks) in the four experiments. Median values ( $n=7$ ). ■ = No F therapy; ◆ = F gel 1/2 days; ● = F gel 1/week; ▲ = F mouthrinse 1/day.

HM were sometimes not possible. These measurements were not omitted, but were considered as being extreme in an untoward direction. The median was used as the summary statistic for measurements from a single subject in a given week. An overall comparison of the results obtained after 6 weeks was accomplished by the generalized signed-rank test.<sup>23</sup> When the results were significant at the 5% level, this test was followed by a pairwise signed-rank test (one-tailed at the 1% level). At a one-tailed 5% level, the latter was used to compare per experiment the results after 6 weeks to those prior to the exposure of the enamel blocks to the oral environment.

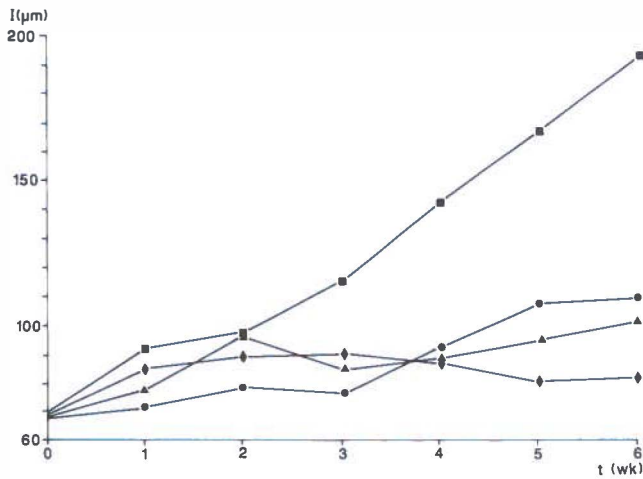
Logarithms of the adjusted enamel F concentrations were used in the statistical analysis. For each enamel block and for each etch depth (0–5, 5–10, 10–15  $\mu\text{m}$ ) the F acquired by the enamel was calculated by subtracting the adjusted baseline enamel F concentration (week 0) from the adjusted experimental enamel F concentration (week 6). The data were analyzed by means of a multivariate analysis of variance using the SYSTAT statistical package.<sup>24</sup>

## RESULTS

The subjects participating in this study suffered from moderate to severe xerostomia with the mean  $\pm$  SD of the amount of saliva in the oral cavities being 414  $\pm$  218 mg. Healthy subjects who do not use drugs and who have not been exposed to radiation therapy have 1,800–3,000 mg saliva in their oral cavities.<sup>10</sup>

Plaque accumulation on the enamel slabs was observed within 1 day. The composition of the oral flora was comparable to the flora in postradiation subjects with natural teeth.<sup>25</sup> The mineral loss in  $\overline{\Delta m}$  ( $\text{kg}\cdot\text{m}^{-2}$ ) of the slabs exposed to the control and experimental disciplines is shown in figure 3. The changes in optical scattering  $\Delta S$  ( $\text{mm}^{-1}$ ) are depicted in figure 4, and the results of the microhardness tests are presented in figure 5. The ranges of variations of the median obtained with





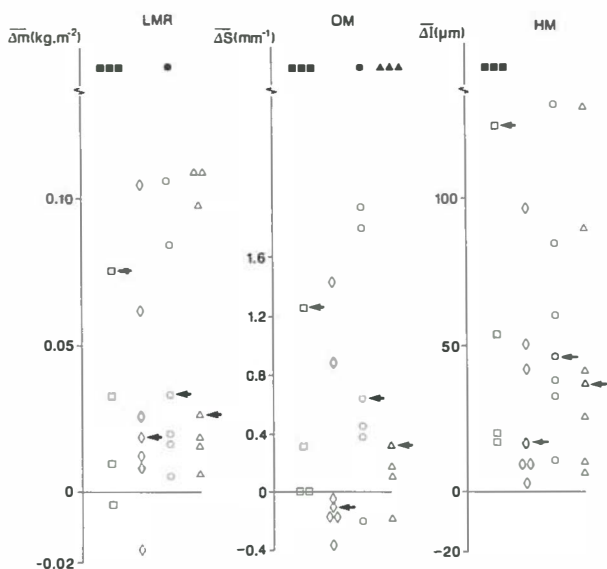
**Fig. 5** Indentation length ( $I$ ,  $\mu\text{m}$ ) as a function of the time of demineralization (weeks) in the four experiments. Median values ( $n=7$ ). ■ = No F therapy; ◆ = F gel 1/2 days; ● = F gel 1/week; ▲ = F mouthrinse 1/day.

the LMR, OM and HM are shown in figure 6. In the control experiment (procedure A), significant demineralization of the slabs was measured with LMR, OM and HM. Application of F for 6 weeks (procedures B-D) resulted in significant inhibition of the demineralization. Evaluation by LMR and OM showed that the application of F gel every second day was significantly more effective in reducing the demineralization process than the other F therapies (Table 1). Hardness measurements (HM) showed no significant differences among the three F therapies (Table 1).

**Table 1** Treatment differences (p values; one-tailed signed-rank test)

Evaluation method	F-gel 1/2 days vs. F-gel 1/week	F-gel 1/2 days vs. F-mouthrinse 1/day	F-gel 1/week vs. F-mouthrinse 1/day
LMR	0.02	0.05	>0.20
OM	0.01	0.01	>0.20
HM	0.11	0.08	>0.20

Great variations in the surface morphology of the enamel slabs were observed by SEM. After 3 weeks porous enamel surfaces, starting crater formation and hollowing out of prism cores were observed in most of the control enamel slabs after exposure to the oral environment. The caries process proceeded progressively resulting in severely demineralized slabs after 6 weeks (Fig. 7). In some of the slabs loss of enamel resulted in the exposure of dentin. Enamel slabs exposed to the F therapies showed a reduction in enamel demineralization when compared with the control slabs, but no clear differences were seen between the applied F therapies. In most




**Fig. 6** Range of median values as obtained with LMR, OM and HM at week 6 ( $n=7$ ).  $\overline{\Delta m}$  ( $\text{kg.m}^{-2}$ ),  $\overline{\Delta S}$  ( $\text{mm}^{-1}$ ) and  $\overline{\Delta I}$  ( $\mu\text{m}$ ) indicate the change in, respectively, mineral content, optical scattering and indentation length. □, ■ = No F therapy; ◇ = F gel 1/2 days; ○, ● = F gel 1/week; △, ▲ = F mouthrinse 1/day. Arrows point to the median values as shown in figure 3-5; ■, ● and ▲ = severely damaged enamel slabs.

slabs only the initial stage of enamel demineralization was observed (Fig. 8).

The median adjusted F concentration of the enamel slabs at the three depths studied prior to the insertion in the intraoral device (week 0) is given in Table 2. The adjusted baseline enamel F concentrations at the three etch depths were not significantly different ( $p>0.10$ ). The adjusted experimental enamel F concentrations increased in the 44 enamel slabs exposed to the control and F therapies for 6 weeks ( $p<0.01$ ). Enamel demineralization was so severe in 5 of the enamel slabs that acid etch biopsies could not be performed. This increase varied significantly among subjects ( $p<0.001$ ), among the various procedures ( $p<0.001$ ), and at different depths ( $p<0.05$ ), but the interactions between the three parameters, subjects, procedures and etch depths were not significant ( $p>0.10$ ).

The increase of enamel F concentration at the first etch depth was estimated to be 1.2 times greater than the increase at the third etch depth. The increase in enamel F concentration depends only slightly on etch depths and can conveniently be described by one number. The 'median increase per enamel slab' observed in the different treatment procedures is presented in Table 3. In the control slabs the enamel F concentration increased by a factor of 1.5; on exposure to the F therapies the factors ranged from 3.1 to 4.1. The differences between the control and F procedures were significant ( $p<0.001$ ). The factor obtained for the application of F gel every 2nd day was significantly different from the factor for the weekly application of the F gel ( $p<0.05$ ).



**Fig. 7** Overall view of an untreated enamel slab after 6 weeks. Presence of a 'relatively' unaffected enamel layer at location A, which seems to be loosening of the deeper part of the slab. Complete absence of enamel and the exposure of the underlying dentin at location B. The cracks in the slabs are artefacts (Bar 1 mm).



**Fig. 8** F-treated enamel slab after 6 weeks. Porosity of enamel surface and starting crater formation (double arrow) can be observed. Single arrows mark the border line of the exposed part of the slab. Cracks are artefacts in the sample (Bar 1 mm).

## DISCUSSION

Previous studies carried out in our laboratory showed that the enamel F concentrations in adjacent sites on unground surfaces varied significantly.<sup>26</sup> Removal of the surface enamel by grinding resulted in the enamel F concentrations in adjacent sites being not significantly different. This was the reason that ground enamel slabs were used in the present study. Intradental control was therefore possible and the

**Table 2** Median F concentration (ppm F) of the enamel slabs at week 0 (n = 49)

Etch depth $\mu\text{m}$	Minimum value	Percentile			Maximum value
		25th	50th	75th	
0- 5	106	263	303	350	662
5-10	189	247	275	339	656
10-15	189	266	299	329	592

**Table 3** Median F uptake per enamel block,  $[F^-_{6w}]/[F^-_{0w}]$ , under the different experimental conditions

Experiment	$[F^-_{6w}]/[F^-_{0w}]$	95% confidence limits
No F	1.5*	1.2 - 2.0
F-gel 1/2 days	4.1**	3.5 - 5.0
F-gel 1/week	3.1	2.6 - 3.7
F-mouthrinse	3.7	3.1 - 4.4

\*  $p < 0.001$ : (no F vs. F experiments);

\*\*  $p < 0.05$ : (F-gel 1/2 days vs. F-gel 1/week).

F acquired at each etch depth was obtained by subtracting the adjusted baseline enamel F concentrations (0 weeks) from the corresponding adjusted experimental F concentrations (6 weeks).

It is apparent from the results that application of F resulted in significant reduction of demineralization. With both LMR and OM it was shown that F gel applied every second day was significantly more effective than the other F therapies. The differences in the LMR and OM values (positive versus negative values; F gel 1/2 days, Figs. 3, 4 and 6) may be interpreted as slight depositions of organic material on the surface. This translucent layer did not influence the LMR data, while it diminished optical scattering  $\bar{S}$ . F analysis demonstrated a significantly higher F uptake after F gel applied every 2nd day compared to the weekly gel therapy. Hardness measurements, however, did not show significant differences between all therapies, although there was a tendency which indicated a greater inhibitory effect of F gel applied every 2nd day. This may be explained by the fact that indentation length on whole samples is mainly a qualitative parameter for the outer enamel region. In case of subsurface lesions, indentation length does not give details of the hardness changes below the surface nor in different regions of the lesion.<sup>27</sup>

Although F gel applied every 2nd day was the most effective therapy in this study, slight demineralization of enamel was still observed. The necessity for additional oral hygiene measures is stressed by this observation. This is in accordance with reported data that complete radiation caries prevention can be accomplished with the use of high-dose F therapies and strict adherence to oral hygiene procedures.<sup>4,6,7,9,28</sup> F mouthrinses used once daily, which are easy to per-

form, could result in a much higher degree of patient compliance.<sup>6</sup> In the present study the daily use of fluoride mouthrinses was only effective in the subjects with moderate demineralization of the enamel slabs. In all other subjects the use of F mouthrinses once daily was inadequate to prevent demineralization. It is, however, difficult to define the caries susceptibility at the onset of the preventive treatment. Therefore, the application of a F gel every 2nd day and a strict oral hygiene regimen are recommended as an optimal procedure to inhibit the onset of radiation caries.

From this study it may be concluded that F gel applied every 2nd day was the method of choice among those tested for preventing the onset of radiation caries.

## REFERENCES

- 1 del Regato JA. Dental lesions observed after roentgen therapy in cancer of the buccal cavity, pharynx and larynx. *Am J Roentgenol* 1939;42:404–410.
- 2 Frank RM, Herdly J, Philippe E. Acquired dental defects and salivary gland lesions after irradiation for carcinoma. *J Am Dent Assoc* 1965;70:868–883.
- 3 Karmiol M, Walsh RF. Dental caries after radiotherapy of the oral regions. *J Am Dent Assoc* 1975;91:838–845.
- 4 Dreizen S, Brown LR, Thomas TE, Drane JB. Prevention of xerostomia-related dental caries in irradiated cancer patients. *J Dent Res* 1977;56:99–104.
- 5 Wescott WM, Starcke EN, Shannon IL. Chemical protection against postirradiation dental caries. *Oral Surg Oral Med Oral Pathol* 1975;40:709–719.
- 6 Katz S. The use of fluoride and chlorhexidine for the prevention of radiation caries. *J Am Dent Assoc* 1982;104:164–170.
- 7 Markitziu A, Gedalia I, Stabholz A, Shuval J. Prevention of caries progress in xerostomic patients by topical fluoride applications: a study in vivo and in vitro. *J Dent* 1982;10:248–253.
- 8 Horiot JC, Schraub S, Bone MC, Bain Y, Ramadier J, Chaplain G, Nabid N, Thevenot B, Bransfield D. Dental preservation in patients irradiated for head and neck tumours: A 10-year experience with topical fluoride and a randomized trial between two fluoridation methods. *Radiother Oncol* 1983;1:77–82.
- 9 Meyerowitz C, Featherstone JDB, Shariati M, Eisenberg AD. Radiation-induced hyposalivation and caries. *J Dent Res* 1986;65:831.
- 10 Vissink A, 's-Gravenmade EJ, Panders AK, Vermey A, Petersen JK, Visch LL, Schaub RMH. A clinical comparison between commercially available mucin- and CMC-containing saliva substitutes. *Int J Oral Surg* 1983;12:132–138.
- 11 Jansma J, Vissink A, 's-Gravenmade EJ, de Josselin de Jong E, Jongebloed WL, Retief DH. A model to investigate xerostomia-related dental caries. *Caries Res* 1988;22:357–361.
- 12 de Bruyn H, Hummel M, Arends J. In vivo effect of a fluoridating varnish with various fluoride contents on human enamel. *Caries Res* 1985;19:407–413.
- 13 de Josselin de Jong E. Comparison of methods in caries research; thesis Groningen, 1986.
- 14 de Josselin de Jong E, van der Linden AHIM, Borsboom PCF, ten Bosch JJ. Determination of mineral changes in human dental enamel by longitudinal microradiography and scanning optical monitoring and their correlation with chemical analysis. *Caries Res* 1988;22:153–159.
- 15 de Josselin de Jong E, van der Linden AHIM, ten Bosch JJ. Longitudinal microradiography: A new nondestructive quantitative method to follow mineral changes in mineralized tissue slices. *Phys Med Biol* 1987;32:1209–1220.
- 16 ten Bosch JJ, Borsboom PCF, ten Cate JM. A nondestructive method for monitoring de- and remineralization of enamel. *Caries Res* 1980;14:90–95.
- 17 ten Bosch JJ, van der Mei HC, Borsboom PCF. Optical monitor of in vitro caries. A comparison with chemical and microradiographical determination of mineral loss in early caries lesions. *Caries Res* 1984;18:540–547.
- 18 Borsboom PCF, ten Bosch JJ. Fiber-optic scattering monitor for use with bulk opaque material. *Appl Opt* 1982;21:3531–3535.

- 19 Vogel GL, Chow LC, Brown WE. A microanalytical procedure for the determination of calcium, phosphate and fluoride in enamel biopsy samples. *Caries Res* 1983;17:23–31.
- 20 Chen PS, Toribara TY, Warner H. Microdetermination of phosphorus. *Anal Chem* 1956;28:1756–1758.
- 21 Söremark R, Samsahl K. Gamma-ray spectrometric analysis of elements in normal human enamel. *Arch Oral Biol* 1961;6:275–283.
- 22 Retief DH, Sorvas P, Bradley E, Taylor R, Walker A. In vitro fluoride uptake, distribution and retention by human enamel after 1- and 24-hour application of various topical fluoride agents. *J Dent Res* 1980;59:573–582.
- 23 Fidler V, Nagelkerke NJD. A generalized signed-rank test for comparison of p treatments. *Statistica Neerlandica* 1986; 40:145–155.
- 24 Wilkinson L. SYSTAT: The system for statistics. (SYSTAT Inc., Illinois 1986).
- 25 Weerkamp AH, Wagner K, Vissink A, 's-Gravenmade EJ. Effect of the application of a mucin-based saliva substitute on the oral microflora of xerostomic patients. *J Oral Pathol* 1987;16:474–478.
- 26 Benediktsson S, Retief DH, Bradley EL, Switzer P. The effect of contact time of acidulated phosphate fluoride on fluoride concentration in human enamel. *Archs Oral Biol* 1982;27:567–572.
- 27 Featherstone JDB, ten Cate JM, Shariati M, Arends J. Comparison of artificial caries-like lesions by quantitative microradiography and microhardness profiles. *Caries Res* 1983;17:385–391.
- 28 Reynolds WR, Hickey A, Feldman MI. Dental management of the cancer patient receiving radiation therapy. *Clin Prev Dent* 1980;2:5–9.





## Chapter 4

### **A SURVEY OF THE PREVENTION AND TREATMENT REGIMENS OF ORAL SEQUELAE RESULTING FROM HEAD AND NECK RADIOTHERAPY USED IN DUTCH RADIOTHERAPY INSTITUTES**

---

This chapter is based on the following publication:

Jansma J, Vissink A, Bouma J, Vermey A, Panders AK, 's-Gravenmade EJ. A survey of the prevention and treatment regimens of oral sequelae resulting from head and neck radiotherapy used in Dutch radiotherapy institutes. *Int J Radiat Oncol Biol Phys* (submitted, 1991).

## INTRODUCTION

The incidence of malignant head and neck tumors (skin cancer excluded) in the Netherlands is about 23/100,000 inhabitants, i.e. circa 3500 new cases per year.<sup>1</sup> Radiation treatment plays an important role in the management of head and neck cancer. According to Rothwell<sup>2</sup> approximately 50% of all new cases of invasive head and neck cancer will need radiotherapy as a primary treatment, as an adjunct to surgery or chemotherapy or as palliation. The radiation dose needed for curative treatment is based on the location and the type of malignancy and whether or not radiotherapy will be used alone or as a pre- or post-surgical aid. Most patients who suffer from head and neck carcinomas receive between 50 and 70 Gy as a curative dose, which is usually given over a 5–7 week period, once a day, five days a week, with a daily tumor dose of about 2 Gy. Due to the location of the primary tumor and the regional lymph nodes, the oral cavity, salivary glands and jaws are in the field of radiation in most head and neck cancer patients, resulting in unwanted irradiation-induced changes in these tissues.

The major side effects that may occur during or after radiotherapy in the head and neck region are mucositis, hyposalivation, taste loss, radiation caries and osteoradionecrosis (ORN). These side effects may form a heavy burden for the patient, cause a lot of distress and have a tremendous impact on the quality of life. Mucositis is a transient complication, but it is an integral part of the radiation therapy in terms of morbidity. Mucositis causes local discomfort and pain as well as difficulties in drinking, eating, swallowing and speech during a period of about seven weeks. As a consequence nutritional problems can arise causing a bad nutritional condition and in severe cases nasogastric tube feeding may become necessary, which is very uncomfortable.<sup>3,4</sup> Severe mucositis may even necessitate a break in the course of radiation treatment and can thus become a dose-limiting factor, with all its risks.<sup>2,5</sup> Hyposalivation leads to distressing, longlasting, often irreversible complaints, such as oral dryness, hampered oral functioning, nocturnal oral discomfort, burning mouth, impeded social activities, reduced taste and high susceptibility to oral infections and dental caries.<sup>6,7</sup> The effects of irradiation on the jaws lead to a lifelong risk for the development of ORN.<sup>8-10</sup>

Fortunately, it is generally accepted nowadays that most oral complications of head and neck irradiation can be prevented or reduced in severity.<sup>11</sup> Prevention regimens are, however, mainly based on clinical experience. The result is a great diversity in procedures,<sup>2,5,12-16</sup> which may lead to a variety in the preventive approach in daily practice. No studies on the existence of such variety in our, or any other country have been published to date.

The purpose of the present investigation was to survey the prevention and treatment regimens applied in all radiotherapy institutes in the Netherlands, and to evaluate the differences in these regimens. For practical reasons, this survey was not intended to evaluate the effects of the various regimens in the patient situ-

ation. Therefore no value judgements about specific care programs can be given other than by comparison with data from the literature.

## MATERIALS AND METHODS

*Dutch radiotherapy institutes.* All centers in which irradiation for head and neck cancer is performed (n=20) were included in the study. They were all willing to cooperate and to make the study a success. According to the patient numbers reported by these centers, a total of about 2200 patients were treated with radiotherapy to the head and neck region in 1989. In this number, patients treated for laryngeal carcinoma and patients treated for (non) Hodgkin lymphoma in the head and neck region are included, patients with skin cancer are excluded. The participating institutes are listed in Table 1.

**Table 1** Dutch radiotherapy institutes in which head and neck radiotherapy is performed

---

Institute
Academisch Medisch Centrum, Amsterdam
Academisch Ziekenhuis Rotterdam Dijkzigt, Rotterdam
Academisch Ziekenhuis Groningen, Groningen
Academisch Ziekenhuis Leiden, Leiden
Academisch Ziekenhuis Nijmegen St Radboud, Nijmegen
Academisch Ziekenhuis Utrecht, Utrecht
Academisch Ziekenhuis Vrije Universiteit, Amsterdam
Antoni Van Leeuwenhoek Ziekenhuis, Amsterdam
Arnhems Radiotherapeutisch Instituut, Arnhem
Catharina Ziekenhuis, Eindhoven
Dr Bernard Verbeeten Instituut, Tilburg
Dr Daniel den Hoed Kliniek, Rotterdam*
Medisch Spectrum Twente, Enschede
Radiotherapeutisch Instituut Friesland, Leeuwarden
Radiotherapeutisch Instituut Limburg, Heerlen
Radiotherapeutisch Instituut Stedendriehoek en Omstreken, Deventer
Rode Kruis Ziekenhuis, 's-Gravenhage**
St Sophia Ziekenhuis, Zwolle
Westeinde Ziekenhuis, 's-Gravenhage**
Ziekenhuis Leyenburg, 's-Gravenhage

---

\* Including patients of Radiotherapeutisch Instituut Zeeland, Vlissingen

\*\* These institutes use the same radiotherapeutic unit, but were evaluated separately because of different preventive programs

*Survey.* All centers were visited in the period June-October 1990 and at least two members of the staff responsible for the prevention and treatment of the oral side effects of head and neck irradiation were interviewed, i.e. radiotherapist and/or dental team (oral and maxillofacial surgeon, hospital dentist, oral hygienist). In centers without a dental team or dentist, only the radiotherapist was interviewed.

**Table 2** Composition of dental teams in 20 radiotherapy institutes. In several centers more than one oral and maxillofacial surgeon, hospital dentist and/or oral hygienist were part of the team

Oral and maxillofacial surgeon, hospital dentist and oral hygienist	5/20*
Oral and maxillofacial surgeon and oral hygienist	8/20
Oral and maxillofacial surgeon	1/20
Hospital dentist and oral hygienist	3/20
No dental team	3/20

\* 5 out of 20 centers etc.

**Table 3** Percentage of patients in 20 radiotherapy institutes, in whom the oral cavity and/or the salivary glands were included in the field of radiation, referred to a dental team prior to radiotherapy

	Dentulous patients	Edentulous patients
All patients (100%)	9/20	7/20
75–100% of the patients	4/20	4/20
50–75% of the patients	3/20	2/20
< 50% of the patients	1/20	4/20
Only family dentist	3/20	0/20
No screening for foci	0/20	3/20

All interviews were performed by the same interviewer (J.J.) using a list of open questions. The answers were scored by the interviewer according to predefined response categories. New categories were added when the response did not match the predefined ones (see appendix). In the result section ‘n’ always refers to the number of centers in which the respondents positively answered a certain item. Questions referred to:

- a composition of the team responsible for the prevention and treatment of radiation-related oral side effects
- b screening and care pre-irradiation:
  - moment of first contact of the patient with the team
  - dental assessment and screening on foci of infection
  - extraction protocol
  - instructions for oral hygiene and fluoride application
- c care during irradiation:
  - oral hygiene and mucositis protocol
  - fluoride protocol
  - denture wearing
- d care post-irradiation:
  - oral hygiene and fluoride protocol
  - denture wearing
  - extraction protocol
  - treatment of hyposalivation
  - follow-up

## RESULTS

*Composition of the dental team.* In the majority of centers at least one oral and maxillofacial surgeon (n=14) or one oral hygienist (n=16) were part of the team, occasionally supplemented by a hospital dentist (n=8)(Table 2). A team consisting of an oral and maxillofacial surgeon, an oral hygienist and a hospital dentist was only present in five centers. In three centers the pre-irradiation screening and pre- and post-irradiation care of the patients was left to their family dentist because of the absence of a dental team. In all centers a radiotherapist screened the patients on the development of oral side effects, particularly mucositis, at least once a week during radiation treatment.

*Screening and care pre-irradiation.* A considerable number of patients in whom the oral cavity and/or salivary glands were included in the field of radiation, was not screened prior to radiotherapy by a dental team (Table 3). The centers in which no dental team was involved in counseling of at least 50% of the edentulous (n=7) and dentulous (n=4) patients were not the centers with the lowest patient numbers (569 patients in total, range 30–214 patients). If patients were screened, they were always referred to the dental team prior to the onset of radiotherapy, and about fifty percent of them was screened more than two weeks before irradiation. The standard pre-irradiation dental assessments and instructions are presented in Table 4. In centers with a dental team (n=17), a panoramic X-ray was always made for screening on foci of infection in dentulous patients. Two of these centers made no X-rays in edentulous patients. No information was obtained in case patients were referred to their family dentist. Baseline data on composition of oral flora (n=0) and mouth opening (n=0) were not collected. In two centers the salivary flow rate was measured. Professional tooth cleansing was performed only in centers with an oral hygienist.

Periodontal disease was occasionally treated with rootplaning and curettage in stead of extraction (n=11), particularly when an oral hygienist was a member of the team (n=10). If extraction or surgical removal of teeth or root tips was indicated, a minimum interval of 0–1, 1–2 or 2–4 weeks between extraction and the onset of radiotherapy was considered necessary in one, nine and ten centers, respectively. Wound healing was routinely checked in 12 centers before irradiation was started.

In the majority of the centers dentulous patients were instructed on toothbrushing (n=16) and interdental cleansing (n=15). In edentulous patients oral hygiene and denture hygiene were instructed only in ten and twelve centers, respectively.

Standard fluoride usage, other than by brushing with fluoridated toothpaste, was instructed in 18 centers. In two of them fluoride was prescribed by the radiotherapist. The fluoride preparations used are listed in Table 5. Self-application of the fluoride gel was prescribed in 11 centers, while in another four centers the gel was applied by an oral hygienist. Custommade carriers (n=12) and commercially available carriers (n=3) for the application of fluoride gel were used. Fluoride-

**Table 4** General overview of the standard dental assessments and instructions in dentulous and edentulous patients prior to radiation treatment in 20 radiotherapy institutes

	Dentulous patients	Edentulous patients
<b>Oral assessments:</b>		
Plaquescore	4/20	–
Bleeding index/record of pocket depths	13/20	–
Vitality testing	4/20	–
Restoration of carious teeth	16/20	–
Panoramic X-ray	17/20	15/20
Checking fit of dentures	–	14/20
Inspection oral mucosa	–	14/20
Surveillance culture of oral flora	0/20	0/20
Measurement of mouth opening	0/20	0/20
Assessment of salivary flow rate	2/20	2/20
<b>Prophylactic care:</b>		
Professional tooth cleansing	16/20	–
Rootplaning and curettage	11/20	–
Oral hygiene instructions:		
– toothbrushing	16/20	–
– interdental cleansing	15/20	–
– use of disclosing agents	1/20	–
– cleansing of mucosal surfaces	–	10/20
– denture hygiene	–	12/20
– massage of oral mucosa	–	7/20
– discouraging denture wearing during radiation	–	7/20
Instruction of fluoride application	18/20	–
Consult with dietitian	11/20	11/20

**Table 5** Evaluation of fluoride usage in 20 radiotherapy institutes

Preparations	standard	on indication	total
Neutral NaF gel, 1%	6/20	1/20 <sup>a</sup>	7/20
Acidulated NaF gel, 1%	4/20	2/20 <sup>b</sup>	6/20
Aminfluoride gel, 0.4%	5/20	2/20 <sup>b</sup>	7/20
Neutral NaF mouthwash, 0.05%	3/20	1/20 <sup>c</sup> 1/20 <sup>d</sup>	5/20
Only fluoride containing toothpaste	1/20		1/20
Unknown*	1/20		1/20

\* in one center it was unknown whether or not fluoride was routinely prescribed

a in case of inability to rinse, b commercial availability, c elderly, d initial lesions

containing mouthwashes were used in three centers.

The standard frequency of fluoride application differed between the various centers. Daily application was prescribed in all centers in which fluoride-containing mouthwashes were used routinely (n=3) and in nine centers in the case of gels, while in the other centers in which gels were used, the application frequency was



**Table 6** General overview of the standard oral care during radiotherapy in 20 radiotherapy institutes

---

Rinsing of the oral cavity with*:	
– water	1/20
– camomile	11/20
– saline	5/20
– salt-soda	2/20
– Emser salt	1/20
– old brown ale	1/20
– blueberry juice	1/20
– no rinsing prescribed	5/20
Professional spraying of the oral cavity with:	
– saline	4/20
– chlorhexidine 0.1%	0/20
– saline/chlorhexidine	0/20
– no professional spraying	16/20
Professional tooth cleansing	6/20
Fluoride application	18/20
Discouraging of denture wearing	7/20
PTA lozenges (polymyxin E, tobramycin, amphotericin B)	2/20
Weekly inspection of the oral mucosa	20/20

---

\* In some centers more than one rinse was used

twice (n=2) or once (n=4) a week.

*Care during irradiation.* An overview of the standard oral care in the different centers during radiotherapy is presented in Table 6. From the onset of radiotherapy, the majority of centers (n=15) prescribed daily frequent rinsing of the oral cavity as baseline care. The most commonly used oral rinses were camomile (n=11) and saline (n=5). In only four centers frequent spraying of the oral cavity with saline was routinely performed by an oral hygienist. Pharmacological prevention of mucositis with PTA lozenges (polymyxin E, tobramycin, amphotericin B) was performed in two centers.

If the oral cavity was included in the field of radiation, in seven centers the wearing of partial and full dentures was discouraged from the onset of radiotherapy for preventive reasons. In all other centers, denture wearing was no longer allowed in case of complaints, mostly due to mucositis. In three centers dentulous patients with large metal restorations were instructed to wear their custommade fluoride carriers during irradiation to reduce scattering. In five centers the only care during radiotherapy consisted of weekly checking the clinical situation.

When mucositis had developed, most centers increased the frequency of oral rinsing and added extra rinsing agents, and in all centers the wearing of dentures was prohibited. Camomile (n=14), saline (n=6) and salt-soda (n=3) were frequently prescribed. Chlorhexidine solutions were added for oral rinsing (n=6) and for professional spraying (n=2). Frequently spraying with hydrogen peroxide and water was started in one center and four centers continued spraying with saline. Viscous xylocaine (lidocaine) or sucralfate was prescribed for pain relief in three centers. For pharmacological treatment of mucositis, four centers used PTA lozenges

and another four centers prescribed Nystatin®. The starting of mucositis therapy was based on patients' complaints (discomfort, pain)(n=12), on the occurrence of mucosal erythema (n=2) or pseudomembranes (n=6). Culturing of the oral flora during the course of radiotherapy was performed in cases of mucositis in two centers. When oral candidiasis was suspected the oral flora was cultured in half the centers (n=10). Thirteen centers stated that, in exceptional cases, severe mucositis necessitated a break in the course of radiotherapy.

**Table 7** Reported schedules for reduction of fluoride applications after radiotherapy in 10 radiotherapy institutes\*

Type of fluoride	During	Reduction schedule
Neutral NaF gel, 1%:	weekly	weeks 1, 3, 8, 15, 24; subsequently once per three months during the first two years; thereafter twice per year
	daily	the first year once per two days; thereafter once per week or once per month
	weekly	< 40 Gy: once per month during the first year; thereafter once per six months > 40 Gy: 0–3 months once per week; 3–12 months once per month; thereafter once per three or six months
	daily**	> 40 Gy: 0–3 months twice per week; 3–6 months once per two weeks; subsequently every three months
Acidulated NaF gel, 1%:	daily	daily during the first two years; thereafter stepwise reduction with 50% every six months until minimal frequency of once per month
	daily	0–3 months once or twice per week; thereafter gradual reduction to once per six months
Aminfluoride gel, 0.4%:	daily	immediately after irradiation once per week; discontinuing fluoride usage if patients experience recovery of salivary gland function
	weekly**	< 40 Gy: 0–3 months once per 2–4 weeks; subsequently once per three months
	weekly	0–6 months once per month; thereafter discontinuing fluoride usage
	twice/week	0–6 months once per week; thereafter once per two weeks
Neutral NaF mouthwash, 0.05%:	daily	reduction to zero in seven weeks, starting from the moment the patient experiences recovery of salivary gland function

\* In the other ten centers reduction of fluoride usage was strictly patient dependent

\*\* In this center the fluoride preparation of choice was based on the expected total radiation dose (<40 and >40 Gy)

The frequency of checking the oral condition during radiotherapy by a member of the dental team differed between centers. A distinction between dentulous and edentulous patients was also made. In three centers with a dental team, the *dentulous* patients were seen at least once per two to three weeks, while in most centers these patients had check-ups once a week (n=8), twice a week (n=4) or even every day (n=1). The highest frequencies were reported in centers with an oral hygienist. In four centers dentulous patients were seen only by a radiotherapist. In 11 centers *edentulous* patients were not seen by a dental team during radiotherapy. In the other centers check-ups were performed daily (n=1), weekly (n=5) or once per two to three weeks (n=3). When patients were hospitalized during radiotherapy, which seemed to occur rarely, the check-up frequency for dentulous patients was increased to several times a week in eight centers. Check-up schedules were not changed for edentulous patients in these cases.

*Care post-irradiation.* In 18 centers patients were allowed to wear dentures immediately after the full course of radiotherapy had been completed and/or mucositis had resolved. Only in two centers the wearing of dentures was prohibited during a period of two or three months post-irradiation.

The frequency of application of fluoride preparations was reduced in 17 centers. Instructions for reduction were standard in ten centers (Table 7), in the other centers the instructions were patient dependent. Reduction of application frequency was started immediately after irradiation (n=9), after three months (n=5), after one to two years (n=2), or was strictly patient dependent (n=1). In two centers the frequency of fluoride application was not reduced post-irradiation. The fluoride usage and reduction could not be evaluated in one of the centers in which patients were referred to their family dentist.

In most centers (n=12) fluoride usage was reduced to a minimal standard application frequency. This frequency differed between the various centers, and ranged from twice a week (n=1), once per week (n=1), once per two weeks (n=2), once per month (n=2), once per three months (n=1) to one time per six months (n=4). Five other centers gradually reduced the fluoride applications to zero, and in one center the reduction was strictly patient dependent.

The fluoride protocols in most centers were based on the literature (n=10), clinical experience (n=8), own research (n=1) and/or had been adopted from other centers (n=11) or predecessors (n=4). The main factors on which fluoride reduction was based, were severity of oral dryness according to the clinician (n=11) or patient (n=15), level of oral hygiene (n=14) and dental status (initial lesions, cavities)(n=13). Measurement of salivary flow rate (n=1) and information on radiation dosage (n=1) and field (n=1) were rarely mentioned as important factors.

Salivary gland function after radiotherapy was determined only by clinical inspection of the oral cavity in 18 centers. In one center the response to citric acid stimulation was measured and in another center the actual salivary flow rate was measured prior to and six and twelve months after radiotherapy. Treatment for hyposalivation and related oral phenomena was not started until patients complained about oral dryness. Home remedies such as old brown ale and cold tea were advised

**Table 8** Post-irradiation protocol for removal of teeth from irradiated jaw segments in 20 radiotherapy institutes. Unless stated otherwise removal is performed under high dose antibiotic coverage

Independent of the time after irradiation	6/20
Only in exceptional cases	2/20
Not within the first year post-irradiation	7/20
Not within the first six months post-irradiation*	4/20
Not within the first six months post-irradiation**	1/20

\* In two centers primary closure of wounds is performed as a standard

\*\* No antibiotics prescribed

in 13 centers. Gustatory and tactile stimulation with, for example, vitamin C tablets or chewing gum was instructed by half the centers (n=10). Systemic sialogogues like pilocarpine were occasionally prescribed in two centers. The use of artificial saliva was advised in 18 centers. This was a carboxymethylcellulose (CMC)-based saliva substitute (n=9), a mucin-containing one (n=3), or both types without preference (n=8).

Post-irradiation protocols for removal of teeth from irradiated jaw segments are presented in Table 8. In twelve centers extractions were deferred to at least six months after irradiation. Extractions were performed under high dose antibiotic coverage in 19 centers. Only two centers stated that they always performed primary wound closure after extraction. Eleven centers stated that the dental team spontaneously received information about radiation dosages and fields of more than fifty percent of their patients after completion of radiotherapy.

**Table 9** Length of the period during which *dentulous* patients are regularly screened by the dental team post-irradiation in 20 radiotherapy institutes

Period	Dental team	Oncologic follow up*
0-3 months	3/20	1/20
3-6 months	2/20	2/20
6-12 months	3/20	0/20
1-2 years	2/20	1/20
2-3 years	0/20	0/20
3-5 years	2/20	0/20
> 5 years	2/20	2/20
No follow-up by dental team or oral and maxillofacial surgeon	6/20	

\* Oral and maxillofacial surgeon participates in oncologic follow up which is continued after follow-up by dental team has been completed

In the early post-irradiation period (i.e. 3-6 months), the frequency of checking the oral condition by the dental team differed between the centers. Also a difference between dentulous and edentulous patients was made. *Dentulous* patients had checkups every month during this period in 11 centers, while there was no post-

irradiation recall for them in six centers. In the other three centers the checkup frequency was once per three (n=2) or six months (n=1) during this period. In most centers these checkups with dentulous patients were performed by an oral hygienist (n=15) and/or an oral and maxillofacial surgeon (n=10). The length of the period during which dentulous patients are regularly screened by the dental team is presented in Table 9. For *edentulous* patients 13 centers arranged no checkups with the dental team. In three centers the oral condition of the edentulous patients was screened only once or twice by an oral hygienist in the early post-irradiation period. In four centers the oral condition of the dentulous and edentulous patients was screened by an oral and maxillofacial surgeon who participated in the oncologic follow-up.

## DISCUSSION

A great variety in the prevention and treatment of oral sequelae resulting from head and neck radiotherapy in Dutch radiotherapy institutes is shown. There is no consensus on mucositis prevention, its treatment and the prophylaxis of radiation caries. Furthermore, there is great diversity in the frequency of checkups and length of the follow-up by the dental teams. The most comprehensive counseling of the head and neck cancer patient was observed in those centers in which an oral hygienist participated in the dental team. Because the approach of the survey was such that the effects of the various regimens in the patient situation were not studied, no conclusions other than by comparison with the literature can be drawn.

*Screening and care pre-irradiation.* Clinical experience has indicated that foci such as impacted teeth and root tips, periapical infection and especially periodontal infection frequently precede ORN.<sup>10,17,18</sup> Therefore, pre-irradiation evaluation of the periodontal status with special attention to furcation involvement is of utmost importance.<sup>12,13,16,19,20</sup> Nevertheless, from our survey it appears that many dentulous and edentulous patients to be treated with radiotherapy in the head and neck region are not screened on dental foci. This may be a result of absence of a dental team in some centers, lack of personnel in many teams and underestimation of sequelae such as caries and periodontal disease that may precede ORN by radiotherapists.

Adequate time for treatment, fabrication of fluoride carriers and wound healing after pre-irradiation extractions and other surgical procedures must be allowed to maximize the impact of screening.<sup>21</sup> Notwithstanding the fact that the interval between tooth removal and onset of radiotherapy should be at least two<sup>16,22</sup> to three<sup>10</sup> weeks and the presence of waiting lists for radiotherapy in some centers, a period of less than two weeks was still regarded by ten centers. Short periods were often connected with a late referral of patients to the dental team. In such cases the start of radiotherapy should be postponed if extractions are indicated.

Radiation caries prevention can almost completely be achieved by the daily application of fluoride in conjunction with a strict oral hygiene regimen.<sup>23-26</sup> For rea-

sons of commercial availability, nine Dutch centers prescribed an acidulated fluoride gel. Although these gels have a higher effectivity than neutral preparations,<sup>27</sup> they may cause significant mucosal irritation with burning pain, erythema and even ulceration in irradiated patients.<sup>13,16</sup> Because the success of a preventive regimen depends on the level of patient compliance, neutral fluoride preparations are mostly preferred.<sup>2,11,25</sup>

*Care during irradiation.* It appears that there is no consensus on wearing dentures. No studies on denture wearing during the course of radiotherapy have been reported. The information provided is mainly empiric and based on clinical experience. To prevent irritation of the irradiated oral mucosa, some authors advise not to wear dentures during the radiation treatment.<sup>28-30</sup> Others recommend meticulous denture hygiene and removal of the appliance at least at night.<sup>2,5,31</sup> Thirteen centers allowed denture wearing as long as patients did not suffer from mucositis. In these centers denture wearing was not considered to be a causative or aggravating factor of mucositis or it was allowed on social grounds.

Daily frequent oral rinses as routine oral care are advocated for reduction of the incidence and severity of mucositis. The primary goal of oral rinsing seems to be mechanical cleansing of the oral cavity and wetting of mucosal surfaces.<sup>32</sup> The major cleansing agents reported are saline and sodium (bi)carbonate solutions.<sup>14,33</sup> Despite these recommendations mouthrinses were not prescribed before the first signs of mucositis occurred or before the patients developed complaints in five centers. Camomile was the most frequently prescribed rinsing agent, but the scientific grounds are missing.

Seven centers added chlorhexidine solution for rinsing or spraying when mucositis was observed, but in recent studies it was shown that chlorhexidine has no benefit for mucositis prevention in these patients.<sup>34,35</sup> The only rationale for the application of chlorhexidine is to reduce plaque accumulation,<sup>36</sup> which assists oral hygiene once toothbrushing has become too painful due to irradiation.

*Care post-irradiation.* To prevent radiation caries and periodontal disease oral hygiene has to be maintained at a high level, as instructed prior to radiotherapy, and fluoride application has to be continued as long as hyposalivation exists, i.e. in many cases lifelong.<sup>24,26</sup> Some authors mention the possibility of reducing fluoride application frequency guided by factors such as the level of oral hygiene and the salivary flow rate, but no schedules for reduction have been reported.<sup>13,15,37</sup> Reduction of fluoride usage is, however, general practice in the centers but is not based on scientific data. The rapid reduction of fluoride application frequency, especially in combination with the relatively short follow-up performed by most dental teams, seems to bear a considerable risk and is inconsistent with publications on the irreversibility of salivary gland damage.<sup>38,39</sup> When reducing fluoride usage while salivary flow has insufficiently recovered, caries prevention becomes totally dependent on the level of patient compliance with the prescribed oral hygiene measures. It seems reasonable to assume that the risk of compliance failure increases with time after radiotherapy. Short follow up periods will deprive the dental team of its possibility to evaluate the effect of rapid fluoride reduction and to encourage

patients to adhere to the strict oral hygiene program. Thus, the role of the patient's family dentist after radiotherapy is very important in these cases.

Controversy exists regarding the duration of the non-wearing period of dentures after radiotherapy. Dependent on radiation dosage and field, trauma to the thin, atrophic and relatively avascular irradiated mucosa may result in soft-tissue necrosis and ORN.<sup>40,41</sup> Waiting periods of one month,<sup>42</sup> six to eight months,<sup>40,41</sup> and one to two years<sup>43</sup> before placement of dentures have been advocated. Because a relation between ORN and denture wearing was not considered to be significant, patients were allowed to wear dentures immediately after radiotherapy in most centers.

In this survey it is shown that there is variety in the preventive and treatment approach of oral sequelae in head and neck cancer patients in Dutch radiotherapy institutes. In our opinion this variety is among others based on: the lack of well defined guidelines in many centers, the spread of a relatively small patient group over a rather large number of centers, the absence of a dental team in some centers, the absence of an oral hygienist in some dental teams and the observation that a rather large part of the patients was not referred or not timely referred to the dental team.

To reach consensus in the preventive approach to head and neck cancer patients in the Netherlands it seems necessary that all centers have a dental team at their disposal be it at least part-time, which in our opinion should ideally consist of an oral and maxillofacial surgeon, an oral hygienist and a hospital dentist. This team should always be involved at the time of initial cancer diagnosis, so that dental treatment can be included as an integral part of the overall treatment regimen. We are aware of the fact that the presence and composition of a dental team is not only dictated by clinical interest but also by priorities, politics and financial aspects. During the various interviews it was felt that in several centers the problem of prevention in head and neck radiotherapy has gained more attention and interest over the last few years.

It seems necessary to perform further research to develop a general preventive protocol that is applicable in all centers. Such a protocol is of utmost importance to prevent oral sequelae of head and neck radiotherapy optimally, thereby increasing the patient's quality of life and to convince radiotherapists and surgical oncologists of the importance to refer all dentulous and edentulous patients at risk to the dental team.

The role of a family dentist both prior to and during the radiation treatment period is questionable because of the complexity of oral screening and oral care, the possible complications during radiotherapy and the fact that most family dentists will only be confronted rarely with this type of patients. In our opinion his role is limited to the post-irradiation phase in uncomplicated cases. When instructed properly, the family dentist can have an important task in controlling radiation caries and preventing periodontal disease and thus in minimizing the risk of ORN.

Similar survey studies from other countries are not available, but it may be assumed that analogous to the situation in the Netherlands prevention is still not optimal in many other countries. Due to implementation of new irradiation schedules



in head and neck cancer therapy (more early effects in case of hyperfractionation and accelerated treatment) and the increasing number of aged dentulous patients, adequate preventive and treatment protocols for head and neck cancer patients are a matter of increasing significance.

## REFERENCES

- 1 Vermey A, Oldhoff J, Panders AK. Hoofd-hals oncologie. In: de Boer J, Derom F, Gruwez JA, Kuijjer PJ, den Otter G, Zwaveling A, eds. *Leerboek chirurgie* 3rd ed. Bohn, Scheltema & Holkema, Utrecht/Antwerpen 1988, 556–570.
- 2 Rothwell BR. Prevention and treatment of the orofacial complications of radiotherapy. *J Am Dent Assoc* 1987;114:316–322.
- 3 Donaldson SS. Nutritional consequences of radiotherapy. *Cancer Res* 1977;37:2407–2413.
- 4 Spijkervet FKL, van Saene HKF, Panders AK, Vermey A, Mehta DM. Scoring irradiation mucositis in head and neck cancer patients. *J Oral Pathol Med* 1989;18:167–171.
- 5 Lockhart PB. Oral complications of radiotherapy. In: Peterson DE, Elias EC, Sonis SY, eds. *Head and neck management of the cancer patient*. Martinus Nijhoff, Boston 1986, 429–449.
- 6 Frank RM, Herdly J, Philippe E. Acquired dental defects and salivary gland lesions after irradiation for carcinoma. *J Am Dent Assoc* 1965;70:868–883.
- 7 Vissink A, Schaub RMH, van Rijn LJ, 's-Gravenmade EJ, Panders AK, Vermey A. The efficacy of mucin-containing artificial saliva in alleviating symptoms of xerostomia. *Gerodontology* 1987;6: 95–101.
- 8 Marx RE. Osteoradionecrosis. A new concept of its pathophysiology. *J Oral Maxillofac Surg* 1983; 41:283–288.
- 9 Epstein JB, Rea G, Wong FLW, Spinelli J, Stevenson-Moore P. Osteoradionecrosis: Study of the relationship of dental extractions in patients receiving radiotherapy. *Head Neck Surg* 1987;10:48–54.
- 10 Marx RE, Johnson RP. Studies in the radiobiology of osteoradionecrosis and their clinical significance. *Oral Surg Oral Med Oral Pathol* 1987;64:379–390.
- 11 National Institutes of Health Consensus Development Panel. Consensus statement: oral complications of cancer therapies. *NCI Monogr* 1990;9:3–8.
- 12 Beumer J, Curtis TA, Harrison RE. Radiation therapy of the oral cavity: Sequelae and management, Part 1. *Head Neck Surg* 1979;1:301–312.
- 13 Beumer J, Curtis TA, Harrison RE. Radiation therapy of the oral cavity: Sequelae and management, Part 2. *Head Neck Surg* 1979;1:392–408.
- 14 Ritchie JR, Brown JR, Guerra LR, Mason G. Dental care for the irradiated cancer patient. *Quintessence Int* 1985;12:837–842.
- 15 Wright WE, Haller M, Harlow SA, Pizzo PA. An oral disease prevention program for patients receiving radiation and chemotherapy. *J Am Dent Assoc* 1985;110:43–47.
- 16 Lowe O. Pretreatment dental assessment and management of patients undergoing head and neck irradiation. *Clin Prevent Dent* 1986;8:24–30.
- 17 Murray CG, Herson J, Daly TE, Zimmerman S. Radiation necrosis of the mandible: a 10-year study. Part I. Factors influencing the onset of necrosis. *Int J Radiat Oncol Biol Physic* 1980;6:543–548.
- 18 Murray CG, Daly TE, Zimmerman S. The relationship between dental disease and radiation necrosis of the mandible. *Oral Surg Oral Med Oral Pathol* 1980;49:99–104.
- 19 Beumer J, Harrison RE, Sanders B, Kurrash M. Osteoradionecrosis: predisposing factors and outcomes of therapy. *Head Neck Surg* 1984;6:819–827.
- 20 Stevenson-Moore P. Essential aspects of a pretreatment oral examination. *NCI Monogr* 1990;9:33–36.
- 21 Sonis ST, Woods PD, White A. Pretreatment oral assessment. *NCI Monogr* 1990;9:29–32.
- 22 Starcke EN, Shannon IL. How critical is the interval between extractions and irradiation in patients with head and neck malignancy? *Oral Surg Oral Med Oral Pathol* 1977;43:333–337.
- 23 Wescott WB, Starcke EN, Shannon IL. Chemical protection against postirradiation dental caries. *Oral Surg* 1975;40:709–719.
- 24 Dreizen SA, Brown LR, Daly TE, Drane JB. Prevention of xerostomia-related dental caries in irradiated cancer patients. *J Dent Res* 1977;56:99–104.

- 25 Keene HJ, Daly T, Brown LR, Dreizen S, Drane JB, Horton IM, Handler SF, Perkins DH. Dental caries and *Streptococcus mutans* prevalence in cancer patients with irradiation-induced xerostomia: 1–13 years after radiotherapy. *Caries Res* 1981;15:416–427.
- 26 Horiot JC, Schraub S, Bone MC, Bain Y, Ramadier J, Chaplain G, Nabid N, Thevenot B, Bransfield D. Dental preservation in patients irradiated for head and neck tumours: A 10-year experience with topical fluoride and a randomized trial between two fluoridation methods. *Radiother Oncol* 1983;1:77–82.
- 27 Fleming TJ. The use of topical fluorides by patients receiving cancer therapy. *Curr Probl Cancer* 1983;7:37–41.
- 28 Dodson WS. Irradiation osteomyelitis of the jaws. *J Oral Surg* 1962;20:467–474.
- 29 Beumer J, Brady FA. Dental management of the irradiated patient. *Int J Oral Surg* 1978;7:208–220.
- 30 Spijkervet FKL. Irradiation mucositis. Prevention and treatment. Munksgaard, Copenhagen, 1991.
- 31 Epstein JB. Infection prevention in bone marrow transplantation and radiation patients. *NCI Monogr* 1990;9:73–85.
- 32 Miaskowski C. Management of mucositis during therapy. *NCI Monogr* 1990;9:95–98.
- 33 Daeffler R. Oral hygiene measures for patients with cancer (I). *Cancer Nurs* 1980;3:347–356.
- 34 Spijkervet FKL, van Saene HKF, Panders AK, Vermey A, van Saene JJM, Mehta DM, Fidler V. Effect of chlorhexidine rinsing on the oropharyngeal ecology in patients with head and neck cancer who have irradiation mucositis. *Oral Surg Oral Med Oral Pathol* 1989;67:154–161.
- 35 Ferretti GA, Raybould TP, Brown AT, Macdonald JS, Greenwood M, Maruyama Y, Geil J, Lillich TT, Ash RC. Chlorhexidine prophylaxis for chemotherapy- and radiotherapy-induced stomatitis: A randomized double-blind trial. *Oral Surg Oral Med Oral Pathol* 1990;69:331–338.
- 36 Epstein JB, McBride BC, Stevenson-Moore P, Merilees H, Spinelli J. The effect of chlorhexidine gel in reduction of *Streptococcus mutans* and *Lactobacillus* species in patients with radiation therapy. *Oral Surg Oral Med Oral Pathol* 1991;71:172–178.
- 37 Mignon H, Labayle J, Dahan S, Lachman M. Preparation des bouches avant irradiation pour cancers cervicofaciaux. Prophylaxie fluorée des lésions dentaires. *Ann Otolaryngol* 1980;97:501–504.
- 38 Vissink A, Panders AK, 's-Gravenmade EJ, Vermey A. The causes and consequences of hyposalivation. *Ear Nose Throat J* 1988;67:166–176.
- 39 Liu RP, Fleming TJ, Toth BB, Keene HJ. Salivary flow rates in patients with head and neck cancer 0.5 to 25 years after radiotherapy. *Oral Surg Oral Med Oral Pathol* 1990;70:724–729.
- 40 Beumer J, Curtis TA, Morrish RB. Radiation complications in edentulous patients. *J Prosthet Dent* 1976;36:193–203.
- 41 Murray CG, Herson J, Daly TE, Zimmerman S. Radiation necrosis of the mandible: a 10-year study. Part II. Dental factors, onset, duration and management of necrosis. *Int J Radiat Oncol Biol Phys* 1980;6:549–553.
- 42 Carl W. Oral and dental care for the irradiated patient. *Quintessence Int* 1974;10:55–62.
- 43 Rahn AO, Matalon V, Drane JB. Prosthetic evaluation of patients who have received irradiation to the head and neck region. *J Prosthet Dent* 1968;19:174–179.



## Chapter 5

### **PROTOCOL FOR THE PREVENTION AND TREATMENT OF ORAL SEQUELAE RESULTING FROM HEAD AND NECK RADIOTHERAPY**

---

This chapter is based on the following publication:

Jansma J, Vissink A, Spijkervet FKL, Roodenburg JLN, Panders AK, Vermey A, Szabó BG, 's-Gravenmade EJ. Protocol for prevention and treatment of oral sequelae resulting from head and neck radiotherapy. *Cancer* (submitted, 1991).

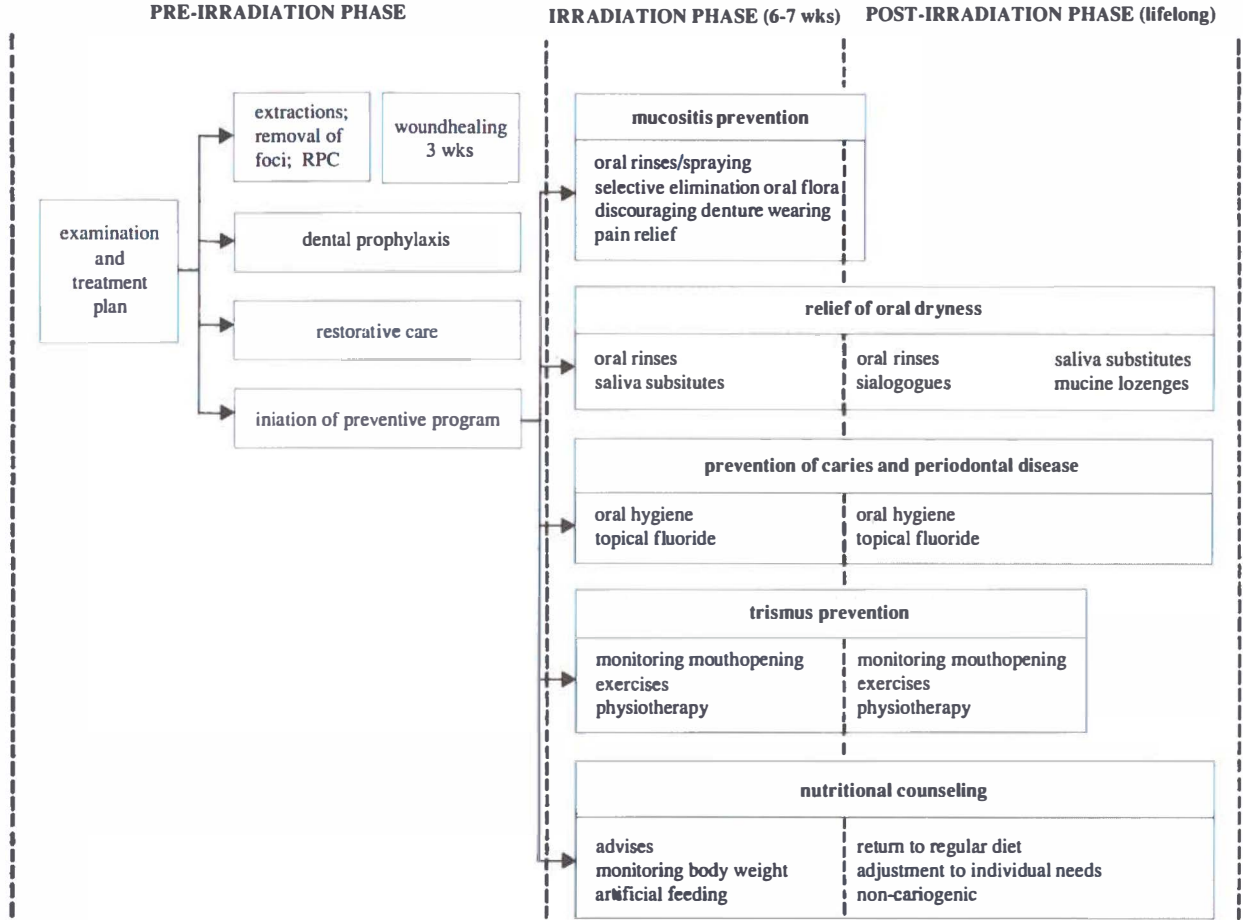


Fig. 1 Schematic diagram of the main issues of patient management in the pre-irradiation, during irradiation and post-irradiation phase.

## INTRODUCTION

Radiation therapy plays an important role in the management of patients with head and neck cancer.<sup>1,2</sup> Due to the location of the primary tumor or the lymph node metastases, the salivary glands, oral cavity and jaws are often included in the treatment portals.<sup>3</sup> As a result, irradiation induced changes will occur in these tissues that can lead to mucositis, hyposalivation, radiation caries, taste loss, trismus, soft-tissue necrosis and osteoradionecrosis (ORN).<sup>4,5</sup> These oral sequelae may cause significant problems during and after radiotherapy and are major factors determining the patient's quality of life. Acute exacerbation of focal infection (e.g. periapical and periodontal infection) and severe mucositis may occasionally necessitate an adjustment or even an interruption of the radiation treatment schedule. For these reasons it is important that oral complications are prevented or reduced to a minimum.<sup>6</sup>

Most prevention procedures described in the literature are based on clinical experience. The result is a great diversity in treatment policies,<sup>2,4,5,7-10</sup> and a variety in the preventive approach in daily practice.<sup>11</sup> Many publications in this field only deal with one specific sequela. Overall protocols are hardly available, or are very concise. In this chapter, a new overall protocol for the prevention and treatment of oral sequelae resulting from head and neck radiotherapy is proposed, of which the scientific basis is formed by the hyposalivation studies of Vissink,<sup>12</sup> the mucositis studies of Spijkervet<sup>13</sup> and the radiation caries studies described in this thesis, supplemented with data derived from the literature. The protocol is especially applicable in centers operating with a dental team, ideally consisting of an oral and maxillofacial surgeon, a hospital dentist and an oral hygienist, to cover the wide range of preventive and treatment measures.

## PREVENTION AND TREATMENT OF ORAL SEQUELAE

With regard to differences in patient management, the protocol can be divided in three phases, namely pre-irradiation (Table 1), during irradiation (Table 2) and post-irradiation (Table 3). The main issues of pre-irradiation patient management are screening, consequential treatment, explication and patient motivation, and initiation of preventive measures. Management during radiotherapy is characterized by prevention and treatment of acute irradiation-induced complications together with comprehensive counseling. After radiotherapy the prevention and treatment of chronic and late complications in conjunction with close follow-up are main issues of patient management. The protocol is schematically depicted in figure 1.

**Table 1 PRE-IRRADIATION PATIENT MANAGEMENT**

**Physical and radiographic examination**

- 1 Dentition (caries, restorations, calculus, vitality).
- 2 Periodontium (bleeding index, pocket depth, furcation involvement).
- 3 Oral hygiene (plaque, bleeding index, denture hygiene).
- 4 Dental awareness and motivation.
- 5 Oral mucosa and alveolar process (infection, irritation fibroma, hyperplasia, exostosis).
- 6 Dentures (fit of partial or full dentures).
- 7 Mouthopening (on indication).
- 8 Radiographic examination
  - a Panoramic radiograph (intraoral radiographs when indicated).
  - b Detection of foci (periapical infections, periodontal disease, unerupted or partially erupted teeth, residual root tips, cysts).

**Treatment and prophylaxis**

- 1 Extraction of nonsalvageable teeth and surgical removal of foci (alveolotomy, primary wound closure, 3 weeks of wound healing necessary).
- 2 Dental prophylaxis (polishing, scaling, rootplaning, curettage).
- 3 Restorative dental procedures (restorations, endodontics).
- 4 Dentures (correction of ill-fitting dentures, no soft lining).
- 5 Initiation of preventive regimen
  - a Plaque removal (toothbrushing, interdental plaque removal).
  - b Topical fluoride (application of neutral 1% NaF gel every second day, custommade fluoride carriers).
  - c Oral rinses (salt-soda rinses at least 8-10 times daily).
  - d Selective oral flora elimination (PTA-lozenges four times daily).
  - e Denture wearing discouraged from the start of radiotherapy.
- 6 Trismus prevention (exercises from the start of radiotherapy when indicated).
- 7 Nutritional advises (instructions, counseling, ideally by a dietitian).



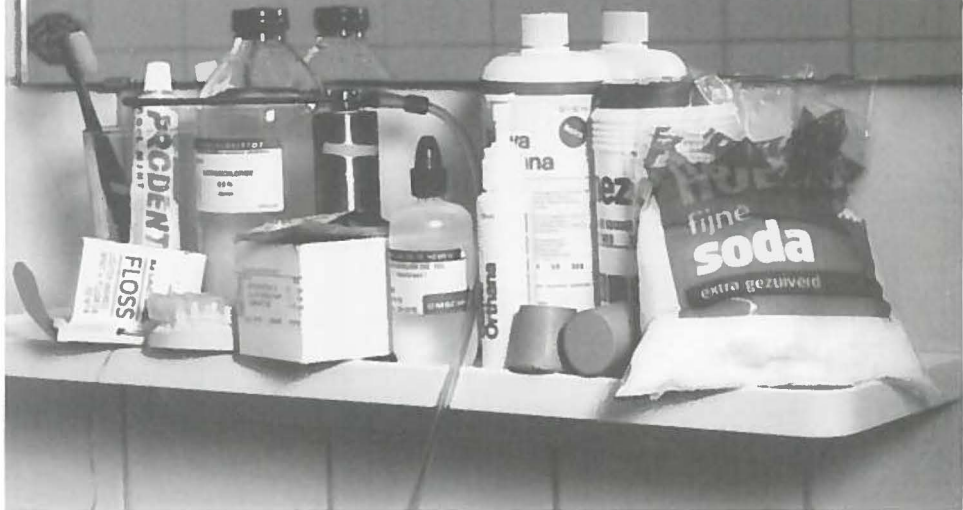**Table 2 PATIENT MANAGEMENT DURING RADIOTHERAPY**

**Standard oral hygiene and preventive care**

- 1 Plaque removal (toothbrushing, interdental plaque removal).
- 2 Topical fluoride (1% NaF gel application every second day).
- 3 Oral rinses (salt-soda rinses at least 8-10 times daily).
- 4 Selective oral flora elimination (PTA-lozenges four times daily).
- 5 Discouraging denture wearing.
- 6 Nutritional counseling (monitoring body weight, instructions, artificial feeding).
- 7 Visits with dental team at least once a week.

**Additional measures (on indication)**

- 1 Professional daily spraying with saline (mucositis, insufficient oral rinsing).
- 2 0.1% chlorhexidine rinses (plaque removal).
- 3 Sucralfate suspensions or viscous xylocaine (pain relief).
- 4 Saliva substitutes (relief of oral dryness).
- 5 Trismus prevention (exercises, measuring mouth opening).



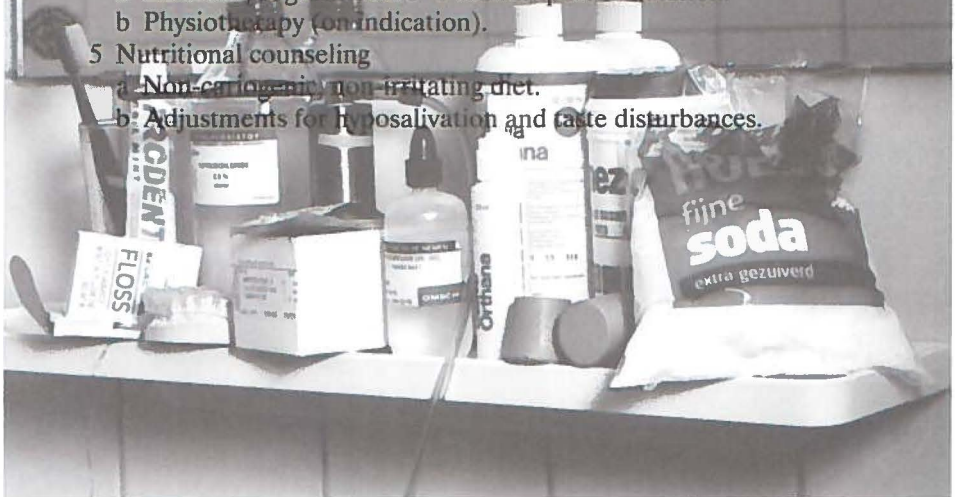
**Table 3 POST-IRRADIATION PATIENT MANAGEMENT**

**Follow-up**

- 1 Frequent dental checkups preferably coordinated with oncology recall.

**Examination, prevention and treatment**

- 1 Oral mucosa
  - a Treatment of mucositis or recall mucositis (salt-soda rinses, PTA-lozenges).
  - b Waiting period of 3 months before (re)placement of dentures.
  - c Careful examination of oral mucosa and denture hygiene.
- 2 Oral dryness
  - a Clinical assessment of salivary secretion (inspection, stimulation).
  - b Relief of oral dryness (gustatory and tactile sialogogues, oral rinses, saliva substitutes, mucin-containing lozenges).
- 3 Dentition and periodontium
  - a Evaluation and reinforcement of oral hygiene regimen.
  - b 1% NaF gel application every second day lifelong. Reduction guided by salivary function and oral hygiene.
  - c Physical and radiographic examination (caries, calculus, vitality, pocket depth).
  - d Restorative and prophylactic dental procedures as needed.
  - e Post-irradiation extractions and other surgical procedures under high dose antibiotic coverage. Prophylactic hyperbaric oxygen treatment on indication.
- 4 Trismus prevention
  - a Exercise program until 3–6 months post-irradiation.
  - b Physiotherapy (on indication).
- 5 Nutritional counseling
  - a Non-cariogenic, non-irritating diet.
  - b Adjustments for hyposalivation and taste disturbances.



## PRE-IRRADIATION PATIENT MANAGEMENT

Prior to the onset of radiotherapy, all dentulous and edentulous patients of whom parts of the jaws, the major salivary glands or the oral cavity will be located in the field of radiation should receive a comprehensive dental evaluation (Table 1). The objectives of pre-irradiation evaluation are:

- identification of risk factors for the development of oral complications, in particular those (e.g. exacerbation of periapical and periodontal infections) that may interfere with the radiation treatment;
- performance of necessary treatment and prophylaxis to reduce the likelihood of oral complications during and after radiotherapy;
- initiation of a comprehensive preventive care program.

To maximize the impact of this screening, adequate time for dental treatment, fabrication of fluoride carriers and wound healing after extractions or other surgical procedures is necessary. That is why the initial appointment for dental evaluation must be made shortly after initial cancer diagnosis and at least three weeks before the onset of radiotherapy.

### Physical and radiographic examination

*Dentition.* The patient's dentition should be inspected carefully. Teeth must be checked for carious lesions, defective restorations, sources of potential irritation of the oral mucosa and periodontium (e.g. sharp or rough fillings, calculus) and vitality of the pulp.

*Periodontium.* The periodontal status is a major dental consideration and should be thoroughly screened by measuring pocket depths and assessment of furcation involvement.

*Oral hygiene.* The level of oral hygiene should be checked carefully. Plaque- and bleeding index are helpful parameters. The hygiene of partial or full dentures should also be checked.

*Dental awareness and motivation.* The patient's dental awareness is an important consideration in the dental evaluation and should be carefully assessed. The protocol aims at preventing or reducing oral sequelae of which some often have a lifelong duration (hyposalivation) or risk (radiation caries, ORN). Patients must therefore possess the motivation and physical ability to maintain their dentition properly and to comply completely with the prescribed oral hygiene and preventive regimen. Both oral hygiene and dental status may be indicative of what can be expected in this respect.

*Oral mucosa and alveolar process.* The oral mucosa and alveolar process have to be checked, especially for conditions that may interfere with future denture wearing such as ulcerations, fibromas, irritation hyperplasia, bony spicules and tori.

*Dentures.* The fit of dentures should be checked, because ill-fitting dentures are a potential source of irritation and trauma of the irradiated mucosal surfaces and underlying bone.

*Mouth opening.* The maximum mouth opening (interarch distance) should be recorded prior to irradiation when development of trismus is anticipated, i.e. when masticatory muscles and/or other soft tissues surrounding the temporomandibular joint are included in the field of radiation, particularly in case of tumor invasion and pre-irradiation surgical resections in these regions.<sup>2,7</sup>

*Oral flora.* Gram-negative bacilli and their endotoxins were found to play a significant role in the development of serious forms of mucositis.<sup>14,15</sup> Therefore all patients of whom a substantial part of the oral mucosa will be located in the field of irradiation will receive selective oral flora elimination. Because of the long-term administration of antibiotics and antimycotics it is preferable to take baseline cultures, with the oral washing method described by Spijkervet et al.,<sup>16</sup> in these patients.

*Radiographic examination.* Besides the physical examination radiographic screening must be done in all patients. A panoramic radiograph, when necessary supplemented by intraoral radiographs, is most suitable for the detection of risk factors such as periodontal and periapical infections, cysts, third molar pathology, unerupted or partially erupted teeth and residual root tips. Furthermore, this radiograph is of baseline value for future suspicion of developing ORN.

## **Treatment and prophylaxis**

After oral examination a dental treatment plan is made. In principle, maintenance of as many teeth as possible, prevention of the necessity of post-irradiation extractions and prevention of acute complications that may interfere with the radiation treatment itself are the primary goals. All teeth with a questionable prognosis should be extracted before radiotherapy. For the decision of pre-irradiation extraction or maintenance of teeth, several factors are of importance, e.g. the patient's motivation and his or her ability to comply with the preventive regimen. The lesser motivated the patient, the sooner one should decide to extract teeth prior to radiotherapy. This means that teeth that are maintainable in normal cases are now extracted in these insufficiently motivated patients. Irradiation type, field and dose are also important. The risk of development of ORN is maximal after cumulative doses exceeding 65 Gy, to the bone, in particular to the molar region of the mandible.<sup>3,17,18</sup> Other factors to consider are age and general health of the patient and prognosis of cancer treatment (curative or palliative).

*Pre-irradiation extractions and surgical removal of other foci.* Taking into account the factors mentioned above, extraction or surgical removal of teeth is generally indicated in case of:

- advanced carious lesions with questionable pulpal status or pulpal involvement;
- extensive periapical lesions;
- moderate to advanced periodontal disease (pocket-depth in excess of 5 mm), especially with advanced bone loss, mobility or furcation involvement;
- residual root tips not fully covered by alveolar bone or showing radiolucency;

- impacted or incompletely erupted teeth, in particular third molars, that are not fully covered by alveolar bone or that are in contact with the oral environment;
- teeth in close proximity to tumor.

Deeply impacted teeth which are covered completely by bone and mucosa can usually be left in place without risk of late problems.<sup>2,9</sup> Extraction of healthy teeth located in the field of radiation to prevent radiation caries is not indicated because there seems to be no direct negative effect of irradiation on dental enamel.<sup>19,20</sup>

Extractions and surgical removal of residual root tips, impacted teeth and other foci such as cysts, should be performed atraumatically with regard to tissue handling. Alveolotomy (lowering and smoothing the bony alveolar margins) and primary wound closure are necessary to speed healing and to eliminate sharp ridges and bony spicules, which may project into the overlying soft tissues.<sup>18,21</sup> This is particularly important for prosthetic considerations, because negligible bone remodeling can be expected after radiotherapy and sharp ridges may increase the risk of bony exposure in a patient wearing dentures.<sup>22</sup>

Non-vital teeth located in the field of radiation without periapical radiolucency and not causing complaints can be treated endodontically. In case of mandibular molars apicoectomies with orthograde filling are preferred because of the high ORN risk in this region and the often experienced problems with endodontic treatment on multi-rooted teeth. Teeth with small or moderate periapical granulomas without periodontal involvement that are important for oral functioning or rehabilitation purposes should be treated with apicoectomies. Apicoectomies should be performed with atraumatic surgical technique. Extraction is indicated in case of extensive periapical radiolucency, simultaneous periodontal involvement and lack of functioning.

Irritation hyperplasia, fibromas, bony spicules and tori should be removed when they interfere with denture wearing or construction of new dentures. The latter because the thin overlying mucosa is easily perforated resulting in exposure of bone.

Adequate time for wound healing prior to the onset of radiotherapy is essential, as it is related to the development of ORN.<sup>23</sup> Healing times of three weeks are generally considered to be safe and should be aimed for as a rule.<sup>10,24,25</sup> In case of removal of impacted teeth, multiple extractions and planned cumulative radiation doses exceeding 65 Gy, this period is of great importance because of higher risk of ORN. Routinely antibiotic coverage is not recommended because there is no evidence that antibiotics influence healing in the absence of infection.<sup>2</sup> Careful examination of the extraction sites must always be performed prior to the onset of radiation treatment. This enables the clinician to adjust the healing period for each patient.

*Dental prophylaxis and restorative care.* It is crucial to bring the periodontium into optimal condition before the start of radiotherapy because of the lowered potential for healing afterwards.<sup>26,27</sup> Thorough oral hygiene procedures, including scaling and polishing or subgingival rootplaning and curettage, should be performed as needed. Overhanging restorations should be recontoured or renewed to



remove plaque and food retention factors. Extensive scaling and subgingival curettage should be completed at least three weeks prior to the onset of radiotherapy to allow for sufficient wound healing. In case of advanced periodontitis (pocket-depth of more than 5 mm) extraction is inevitable both because of the risk of ORN and the lack of time for sufficient periodontal treatment such as flap operations. The importance of motivation, radiation field and dose in this respect has been mentioned before.

Restorative care, including restoration of carious lesions and replacement of defective restorations, should be performed as needed.

Ill-fitting partial or full dentures should be corrected. Temporary soft liners exhibit increased friction which is increased by the irradiation-induced hyposalivation. Furthermore they may easily become colonized with yeasts due to porosity. Soft liners are therefore contraindicated in head and neck irradiation patients. Construction of new dentures should be postponed until three months after radiotherapy.

### Initiation of a new preventive regimen

A protocol aiming at prevention and relief of mucositis, prevention of hyposalivation-related dental caries and periodontal disease and thereby ORN, relief of oral dryness and prevention of weight loss and trismus has to be instituted in all patients at risk. Because most preventive measures have to be continued lifelong, patient and family education, counseling and motivation are critical to the success of the preventive regimen. The patient must be aware of the potential side effects of radiotherapy and must be encouraged to adhere to the care program.

*Oral hygiene.* Patients must be instructed about an effective daily plaque removal. The use of a soft toothbrush with a fluoride-containing toothpaste and the Bass-technique of sulcular brushing are instructed. For removal of interdental plaque the use of dental floss or soft wooden tooth-picks is imperative. Interproximal brushes, irrigating devices and plaque disclosing tablets can be helpful. Proper oral hygiene cannot be overemphasized and patients efforts should be evaluated before radiotherapy is started. Instructions about denture hygiene should also be provided.

**Table 4** Composition of 1% neutral sodium fluoride gel

Sodium Fluoride	1 g
Disodium Hydrogen Orthophosphate ( $\text{Na}_2 \text{HPO}_4 \cdot 12 \text{H}_2\text{O}$ )	380 mg
Potassium Dihydrogen Orthophosphate ( $\text{KH}_2\text{PO}_4$ )	180 mg
Methylhydroxypropylcellulose (viscosity 3000–5600 mPa.s)	2 g
Methylparaben	100 mg
DeminerIALIZED water	ad 100 ml

*Caries prevention and topical fluorides.* Although oral hygiene measures are imperative in the prevention of radiation caries, it has been shown that oral hygiene alone

is inadequate as a safeguard against radiation caries.<sup>28-30</sup> Topical fluoride applications are needed to prevent radiation caries. A neutral 1% sodium fluoride gel (Table 4), self-applied every second day using custommade carriers, in conjunction with strict oral hygiene measures is an effective preventive regimen.<sup>29,30</sup> Acidulated gels are not indicated in irradiated patients because they may lead to significant decalcification without sufficient remineralization potential in the presence of hyposalivation. They may also cause mucosal irritation with burning pain, erythema and even ulceration.<sup>5,10</sup> Furthermore, sodium fluoride preparations are preferred to stannous fluoride, because the latter has unpleasant side effects such as bad taste, sensitivity of teeth and gingiva and staining of arrested lesions.<sup>31</sup>

At the initial dental appointment impressions are taken to fabricate flexible fluoride carriers that extend about 3 mm beyond the free margin of gingiva and fit the teeth closely to allow for adequate fluoride coverage. They must be delivered before the onset of radiotherapy and their use should be instructed to the patient. Following thorough brushing and flossing, the patients apply the 1% NaF gel for 5–10 minutes every second day, preferably just before bedtime. The carriers must not be overfilled, a few drops of gel are sufficient. After removing the carriers, the patients spit out the excess gel without rinsing and have to refrain from drinking, brushing, or eating for 30 minutes. Patients with an extreme gag-reflex can apply the fluoride gel using a toothbrush in stead of a carrier.

In patients with large metal restorations or crowns located in the field of radiation, carriers of double thickness are fabricated that have to be worn during irradiation to prevent tissue injury by scattering, thereby preventing localized mucositis especially of the buccal mucosa.

*Oral rinse instructions.* For relief of oral discomfort during radiotherapy, cleansing agents are recommended to reduce mucosal irritation, to remove thickened secretions and debris from both mucosa and dentition and to moisture and lubricate the mucosa.<sup>32</sup> It is recommended to rinse the mouth at least eight to ten times a day for one minute with a salt-soda solution (one liter lukewarm water with one teaspoon each of NaCl and Na<sub>2</sub>CO<sub>3</sub>), from the onset of radiotherapy. This solution is preferred because of its ability to dissolve mucus and loosen debris.

Besides rinsing with cleansing agents, daily professional spraying of the oral cavity with saline using a spraying device (Ritterspray model 152, Devilbis, Somerset, U.S.A.) is a good supplement for thorough mechanical cleansing.<sup>33-35</sup> Professional spraying should be especially performed in those patients who develop serious complaints due to mucositis and/or are unable to rinse their mouth sufficiently, e.g. in case of changed anatomy after tumor surgery.

*Saliva substitutes.* Besides multiple salt-soda rinses, additional symptomatic relief of oral dryness can be accomplished with saliva substitutes. Although mucin-containing substitutes seem to be more effective,<sup>34,36,37</sup> carboxymethylcellulose-containing substitutes may also be beneficial. The success of using saliva substitutes is strictly dependent on the instructions delivered with their prescription. The saliva substitute can be easily applied with an atomizer. The patient should moisten the oral cavity abundantly, spread the substitute all over the oral cavity and swallow or



expectorate the surplus. As soon as the sensation of dryness returns, the treatment should be repeated. The substitute can be used ad libitum. If patients object to the viscosity of saliva substitutes they can dilute them with water. Difficulty in speech and nocturnal oral discomfort are the most useful indices for their use.

*Selective oral flora elimination.* Selective elimination of gram-negative bacilli from the oral flora during radiotherapy has resulted in prevention of the more severe stages of mucositis (pseudomembranes, ulcers).<sup>14,15</sup> Four times daily administration of 1 gram PTA-lozenges containing 2 mg polymyxin E, 1.8 mg tobramycin and 10 mg amphotericin B is prescribed to all patients of whom a substantial part of the oral mucosa will be located in the field of radiation. The PTA-lozenges should be used from the onset of radiotherapy, during its full course until mucositis signs have disappeared. Although unrelated to the pathogenesis of mucositis, the preventive administration of the topical antifungal amphotericin B is indicated in this population to prevent yeast stomatitis.<sup>38-40</sup>

*Denture wearing.* Especially the wearing of ill-fitting but also of correctly fitting dentures during radiotherapy may cause mucosal irritation that may aggravate mucosal pain and mucositis. The policy must be to discourage the wearing of partial and full dentures from the start of radiotherapy in all patients in whom a substantial area of the oral mucosa is located in the field of radiation and will receive a curative radiation dose. An exception must be made for patients wearing resection prostheses and obturators which are needed for closure of the surgical defect and for prevention of tissue retraction into this defect.

*Trismus prevention.* Prevention of trismus, rather than its treatment, is a most desirable objective. Patients at risk of developing trismus need daily exercises, such as properly instructed stretching, to maintain maximum opening and jaw mobility as soon as radiotherapy begins. The additional use of tongue blades or rubber stops of increasing size is helpful and stimulating because they act as a measuring device. Dynamic bite openers<sup>3</sup> containing springs and bands, designed to restretch muscles can also be used for prevention in pediatric patients.<sup>41</sup>

## **Nutritional instructions**

The oral intake of food during radiotherapy may be impeded due to taste loss, changes in amount and viscosity of saliva and pain on eating and swallowing due to mucositis.<sup>4,42</sup> Resulting weight loss leads to weakness, inactivity, discouragement and susceptibility to infection.

Nutritional counseling and dietary instructions are important to minimize weight loss and prevent the necessity of nasogastric feeding. All patients should receive dietary instructions prior to radiotherapy, ideally by a dietitian. Patients may try to compensate for their altered taste sensation by eating foods with a high sucrose content, or by using increased amounts of spices.<sup>7</sup> Foodstuffs high in sucrose will enhance the cariogenic activity and should be avoided. Spicy and acidic foods are intolerable to the sensitive oral mucosa and should also be avoided. To ease mastication in case of hyposalivation and mucositis, patients are encouraged to eat

moistened foods served at room temperature together with increased fluid intake. Small frequent feedings are recommended when appetite is poor and when swallowing is difficult. The use of tobacco and alcohol is strongly discouraged to prevent mucosal irritation. Adequacy of oral intake should be monitored by regularly measuring the body weight.

## **PATIENT MANAGEMENT DURING RADIATION TREATMENT**

Maintenance of optimal oral hygiene and preventive measures together with relief of oral discomfort are the main issues during the radiation treatment period (Table 2). To accomplish this, patients must be screened by a member of the dental team at least once a week, apart from the checkups by the radiotherapist. During these screening visits the oral situation, the oral hygiene and preventive measures are checked and evaluated and if necessary reinforced. Additional measures can be initiated depending on the oral status and complaints. Furthermore, the frequent checkups offer the possibility to continuously encourage the patient to adhere to the protocol.

*Oral hygiene.* The efficacy of toothbrushing and interdental cleansing must be checked. If toothbrushing has become painful due to mucositis, one or more of the following additional measures need to be initiated: professional cleansing of the dentition by an oral hygienist during the weekly visits, 0.1% aqueous chlorhexidine rinses three to four times daily for additional plaque control and rinses with a topical anesthetic such as viscous xylocaine shortly before toothbrushing to relief pain from brushing. Patients may also be advised to further soften their toothbrush with hot tap water before use.

*Topical fluorides.* The neutral 1% NaF gel must be applied every second day by the patient himself using the custommade carriers. Use of fluoride and fluoride carriers should be evaluated.

*Mucositis prevention and therapy.* Patients should rinse their mouths at least eight to ten times daily with the salt-soda solution and use the PTA-lozenges four times daily, during the full course of radiotherapy. When patients have difficulties in dissolving the PTA-lozenges due to hyposalivation, they should be instructed to moisten their mouths and to remove the remnants of the lozenge after 30 minutes of sucking. Oral flora monitoring is useful in the evaluation of the oral hygiene and mucositis prevention program. Surveillance cultures should be taken weekly in all patients using PTA-lozenges.<sup>35</sup> When considered too time-consuming in daily practice, they should at least be taken in case of clinical suspicion of yeast stomatitis, so that further measures can be taken when indicated. The signs and symptoms of this infectious process can easily be confused with irradiation mucositis.<sup>10</sup>

Denture wearing is discouraged from the start of radiotherapy. In case of large metal restorations or crowns located in the field of radiation, patients need to wear their double thickness carriers during irradiation. In patients with severe complaints from mucositis or unable to rinse their mouths sufficiently, additional daily

spraying with saline should be performed by the oral hygienist or nursing staff. Once mucositis has developed, a sucralfate suspension (1gm/15ml) can be prescribed for pain relief as a rinsing agent.<sup>43</sup>

*Relief of oral dryness.* Oral rinses with salt-soda are primarily important for mechanical cleansing during radiotherapy but will also sufficiently relieve oral dryness in most patients. If not, their frequency can be increased and patients can be encouraged to increase their fluid intake, provided the beverages are non-cariogenic and non-irritating to the oral mucosa. Saliva substitutes can be prescribed in addition.

*Trismus prevention.* All patients at risk of developing trismus should perform the instructed exercises. Maintenance of the pre-irradiation maximum mouth opening needs to be checked weekly by measuring the interarch distance. When this distance decreases, the exercise program should be intensified, occasionally in combination with physiotherapy, to regain the lost interarch distance.

*Nutritional counseling.* Food intake and nutritional status must be checked at least weekly and the diet should be modified depending on specific patient needs. A simple and indicative method is to weigh the patient weekly. When weight loss exceeds 1 kg per week, enriched dietary supplements are recommended. Nasogastric feeding is indicated when a loss of 10% of the pre-irradiation body weight is observed in the third or fourth week of radiotherapy.<sup>44</sup>

## **POST-IRRADIATION PATIENT MANAGEMENT**

In addition to relief of oral dryness and discomfort, the main purpose of the protocol in the post-irradiation phase is prevention of radiation caries, periodontal disease, post-irradiation extractions and thus ORN (Table 3). Oral hygiene has to be maintained at a high level indefinitely in all patients, whereas topical fluoride applications need to be continued lifelong in most dentulous patients. The risk of noncompliance increases with time after radiotherapy. The patients need to be placed on a regular dental recall schedule and to be judiciously followed for the rest of their lives. This is necessary to check, evaluate and reinforce the oral hygiene regimen, as well as to encourage the patients to adhere to the protocol and counsel a possible reduction of the fluoride usage. As a general rule, follow-up is weekly during the first month, three monthly during the first year and less frequently thereafter, but may differ per subject depending on the level of oral hygiene, degree of hyposalivation and whether the patient is dentulous or edentulous. For reasons of efficacy, the follow-up visits are preferably combined with the oncology recall. When instructed properly, the patient's family dentist may play an important role in the post-irradiation period, by taking over these visits or performance together with the dental team.

## Oral mucosa

*Mucositis.* Frequent rinsing with salt-soda solutions, the use of PTA-lozenges and other initiated additional preventive or therapeutic measures should be continued until mucositis signs have disappeared. In case of recall mucositis the basic regimen of mucositis prevention should be reinstated.

*Dentures.* The irradiated oral mucosa is very vulnerable and easily damaged, a condition which is aggravated by hyposalivation.<sup>45</sup> Trauma to the edentulous alveolar ridge may result in soft-tissue necrosis and lead to ORN. Dentures are considered to be a potential source of such trauma.<sup>21,46</sup> Timing of their (re)placement is controversial. Factors such as compliance, amount and consistency of saliva, presence of recent extraction sites and pre-irradiation experience in wearing dentures are important decisive parameters. Our guideline is to wait three months before (re)placing dentures, so that initial mucosal changes have subsided. This waiting period is extended to six months in patients who had pre-irradiation extractions in the field of radiation. An exception is made for resection prostheses.

After replacement of dentures or construction of new ones, preferably by an experienced hospital dentist, the rule is to remove the dentures at night. Their hygiene should be stressed. Because of increased friction, porosity and accumulation of debris soft liners are not indicated in this group of patients.

If any irritation develops, dentures need to be removed immediately and the mouth must be examined by the dental team. Stringent continuous aftercare is essential in denture wearing irradiated patients. The fit of their dentures should be checked every year by their family dentist or by the dental team.

## Oral dryness

The degree of hyposalivation and return of salivary gland function mainly depend upon the total radiation dose and the volume of salivary gland tissue located in the field of radiation, whereas the initial salivary flow is also of importance.<sup>47,48</sup> Studies have indicated that there is no significant recovery of salivary flow when the major salivary glands are situated in the treatment portals and receive a cumulative radiation dose in excess of 40 Gy and occasionally even after lower cumulative doses.<sup>48</sup> This despite the fact that some of the xerostomic patients experience subjective improvement in mouth dryness.<sup>28,49</sup> Because in many head and neck cancer patients cumulative radiation dosages of 60–70 Gy are delivered to one or more of the salivary glands, hyposalivation is irreversible in most cases. This has a tremendous impact on caries challenge and quality of life.

*Relief of oral dryness.* The management of hyposalivation involves a combination of strategies: stimulation of residual capacity of salivary glands and symptomatic relief of oral dryness. Most patients experience symptomatic improvement from frequent moistening of the mouth by drinking or rinsing with water, tea, salt-soda solutions, extracts of camomile and home remedies such as old brown ale and blueberry juice. Further treatment of oral dryness should be instituted depending upon the

subjective complaints of the patient. During each follow-up visit questions about such complaints should be asked and verified by clinical assessment. For this assessment of the degree of hyposalivation a few parameters are of interest, namely: appearance of the oral mucosa (dry, atrophic, fissured), aspect of the oral fluid (more viscous) and level of salivary secretion in rest and after stimulation.

When stimulation of salivary glands shows some residual capacity, sialogogues can be used to relieve oral dryness. Good results can be obtained with gustatory and tactile sialogogues such as sugar free chewing gum and acidulated sweets. The latter, however, can only be used in limited amounts because they are often intolerable to the irradiated mucosa. Although their usefulness seems limited due to their potential side-effects, pharmacological sialogogues, such as pilocarpine have been reported to be successful in stimulating additional secretion.<sup>50,51</sup>

In addition to drinking, rinsing with non-cariogenic beverages and sialogogues mucin- and CMC-containing saliva substitutes can be prescribed of which mucin-containing ones seem to be the most effective.<sup>36,37</sup> Construction of a saliva substitute reservoir in a denture has been helpful in a number of selected patients,<sup>52,53</sup> but application of the substitute with an atomizer, provided it is instructed correctly, is sufficient in most patients. Recently, promising results were obtained with the use of mucin-containing lozenges in the treatment of oral symptoms of xerostomia.<sup>54</sup> These lozenges are particularly useful when combined with mucin-containing saliva substitutes.

## **Dentition**

*Oral hygiene.* A high level of oral hygiene has to be maintained lifelong and should be checked carefully during follow-up visits. Oral hygiene measures should be reinforced and patients motivated if necessary.

*Topical fluoride.* Topical fluoride application has to be continued as long as hyposalivation exists, which is lifelong in most patients.<sup>28,55</sup> Although some authors mention the possibility of reducing the frequency of fluoride application guided by factors such as level of oral hygiene and salivary flow rate<sup>5,8</sup> and despite the fact that reduction of the application frequency is common practice in Dutch radiotherapy institutes,<sup>11</sup> no studies on fluoride reduction have been reported to justify this measure. Because of the irreversibility of hyposalivation in many patients and the aggressiveness and high cariogenicity of the xerostomic oral environment as observed in in situ studies,<sup>29,30,56</sup> the application of a 1% neutral NaF gel every second day has to be continued lifelong. Reduction of the application frequency is only justified in cases with objective indications of recovery of salivary flow in combination with a high level of oral hygiene. Furthermore, reduction must be guided by close follow-up for evaluation and possibility of individual adjustment and quick intervention. Should initial carious lesions appear, duration and frequency of fluoride applications can be increased temporary for remineralization and caries arrest. Topical fluoride should at least be applied twice a year and not be reduced to zero. Applications can be performed by a dentist or an oral hygienist during follow-up

visits.

*Physical and radiographic examination.* The patient's dentition should be checked carefully for carious lesions, calculus, etc. Periapical radiographs and bitewings should be made to examine teeth previously treated by endodontics or apicoectomies and for caries detection. The periodontium should be thoroughly screened by measuring pocket depths.

*Restorative and prophylactic care.* If carious lesions develop, they should be treated immediately, because of the rapid progression in xerostomic patients. Teeth with nonvital pulps located in irradiated jaw segments should be treated endodontically rather than by apicoectomy because of the amount of wounding. Removal of calculus by scaling and rootplaning and curettage should also be performed to optimize periodontal health. Chronic periodontal disease may induce ORN and should by all means be prevented.

*Post-irradiation extractions.* Post-irradiation extraction of teeth from irradiated jaw segments is a significant factor predisposing to ORN.<sup>18</sup> Pre-irradiation screening, treatment and the institution of a preventive regimen aimed at preventing the necessity of these extractions. The necessity for post-irradiation extraction is mostly due to insufficient pre-irradiation screening and noncompliance. Several investigators have shown that the time elapsed between radiotherapy and tooth removal has little direct bearing on the occurrence of ORN,<sup>18,57</sup> while others reported the risk to increase with time.<sup>25</sup> It seems, however, that limited extractions can be done successfully when necessary, provided adequate preventive measures are taken.

Extractions are performed with careful soft-tissue handling, alveolotomies, smoothing of the alveolar ridge and primary wound closure. This is important to speed up healing and for future prosthetic considerations. Prophylactic high dose broad spectrum antibiotic coverage (e.g. cephalosporines) is started a few days before extraction and continued for two weeks to prevent wound infection. Preventive hyperbaric oxygen (HBO) treatment has been proven to be more beneficial than antibiotic prophylaxis in preventing ORN,<sup>58,59</sup> but is not widely available in most countries. Prophylactic HBO treatment has to be used in those patients who require extractions or excessive wounding in previously irradiated segments and who are considered to be at the highest risk of developing ORN, i.e. cumulative radiation doses in excess of 65 Gy to mandibular segments in combination with risk factors such as impeded blood supply due to tumor surgery, abuse of alcohol and tobacco and compromised general health. Wound healing should be checked regularly after post-irradiation extractions.

### **Trismus prevention**

Trismus (muscular cause) may develop until three to six months after completion of radiotherapy.<sup>9,21</sup> Patients at risk of developing trismus are therefore advised to continue exercises during this period, assisted with physiotherapy when indicated. The interarch distance needs to be measured during follow-up visits and be compared with the pre-irradiation value.



## Nutritional counseling

After mucositis signs have subsided patients may generally progress to a regular diet. Because of the irradiation-induced hyposalivation and related taste disturbances foods may have to be moistened and served with liquids for an indefinite period of time and smell and taste may have to be adapted to individual needs. The importance of non-cariogenic foods in the prevention of radiation caries has already been addressed.

## EPILOGUE

A protocol for the prevention and reduction of most oral sequelae resulting from head and neck radiotherapy has been proposed of which the scientific basis is formed by the hyposalivation studies of Vissink,<sup>12</sup> the mucositis studies of Spijker-vet<sup>13</sup> and the radiation caries studies described in this thesis in combination with data derived from the literature. It is especially applicable in centers operating with a dental team, ideally consisting of an oral and maxillofacial surgeon, a hospital dentist and an oral hygienist, to cover the wide range of preventive and treatment measures. This team should always be involved at the time of initial cancer diagnosis, so that a preventive regimen is an integral part of the overall cancer treatment regimen. The role of a family dentist both prior to and during radiotherapy is questionable because of the complexity of oral screening and oral care, the possible complications during radiotherapy and the fact that most family dentists will be confronted rarely with this type of patients. In our opinion the family dentist's role is limited to the post-irradiation phase in uncomplicated cases.

With the implementation of new irradiation schedules in head and neck radiotherapy (more early side effects in case of hyperfractionation and accelerated treatment) and the increasing number of aged dentulous patients, adequate prevention is a matter of increasing importance.

## REFERENCES

- 1 Al-Sarraf M. Chemotherapeutic management of head and neck neoplasia. In: Peterson DE, Elias EG, Sonis ST, eds. Head and neck management of the cancer patient. Martinus Nijhoff, Boston 1986,299-330.
- 2 Rothwell BR. Prevention and treatment of the orofacial complications of radiotherapy. *J Am Dent Assoc* 1987;114:316-322.
- 3 Engelmeier RL, King GE. Complications of head and neck radiation therapy and their management. *J Prosthet Dent* 1983;49:514-522.
- 4 Beumer J, Curtis TA, Harrison RE. Radiation therapy of the oral cavity: Sequelae and management, Part 1. *Head Neck Surg* 1979;1:301-312.
- 5 Beumer J, Curtis TA, Harrison RE. Radiation therapy of the oral cavity: Sequelae and management, Part 2. *Head Neck Surg* 1979;1:392-408.
- 6 National Institutes of Health Consensus Development Panel. Consensus statement: Oral complications of cancer therapies. *NCI Monogr* 1990;9:3-8.
- 7 Ritchie JR, Brown JR, Guerra LR, Mason G. Dental care for the irradiated cancer patient. *Quintessence International* 1985;12:87-842.



- 8 Wright WE, Haller M, Harlow SA, Pizzo PA. An oral disease prevention program for patients receiving radiation and chemotherapy. *J Am Dent Assoc* 1985;110:43-47.
- 9 Lockhart PB. Oral complications of radiation therapy. In: Peterson DE, Elias EG, Sonis ST, eds. *Head and neck management of the cancer patient*. Martinus Nijhoff, Boston 1986,429-449.
- 10 Lowe O. Pretreatment dental assessment and management of patients undergoing head and neck irradiation. *Clinical Preventive Dentistry* 1986;8:24-30.
- 11 Jansma J, Vissink A, Bouma J, Panders AK, Vermey A, 's-Gravenmade EJ. A survey of the prevention and treatment regimens of oral sequelae resulting from head and neck radiotherapy used in Dutch radiotherapy institutes. *Int J Radiat Oncol Biol Phys* (submitted, 1991).
- 12 Vissink A. Xerostomia. Development, properties and application of a mucin containing saliva substitute; thesis Groningen, 1985.
- 13 Spijkervet FKL. Irradiation mucositis and oral flora. Reduction of mucositis by selective elimination of oral flora; thesis Groningen, 1989.
- 14 Spijkervet FKL, van Saene HKF, van Saene JJM, Panders AK, Vermey A, Mehta DM. Mucositis prevention by selective elimination of oral flora in irradiated head and neck cancer patients. *J Oral Pathol Med* 1990;19:486-489.
- 15 Spijkervet FKL, van Saene HKF, van Saene JJM, Panders AK, Vermey A, Mehta DM, Fidler V. Effect of selective elimination of oral flora on mucositis in irradiated head and neck cancer patients. *J Surg Oncol* 1991;46:167-173.
- 16 Spijkervet FKL, van Saene HKF, Panders AK, Vermey A. Colonisation index of the oral cavity: a novel technique for monitoring colonisation defence. *Microb Ecol Health Dis* 1989;2:145-151.
- 17 Murray CG, Herson J, Daly TE, Zimmerman S. Radiation necrosis of the mandible: a 10-year study. Part I. Factors influencing the onset of necrosis. *Int J Radiat Oncol Biol Phys* 1980;6:543-548.
- 18 Friedman RB. Osteoradionecrosis: causes and prevention. *NCI Monogr* 1990;9:145-149.
- 19 Jansma J, Buskes JAKM, Vissink A, Mehta DM, 's-Gravenmade EJ. The effect of X-ray irradiation on the demineralization of bovine dental enamel. A constant composition study. *Caries Res* 1988;22:199-203.
- 20 Jansma J, Borggreven JMPM, Driessens FCM, 's-Gravenmade EJ. Effect of X-ray irradiation on the permeability of bovine dental enamel. *Caries Res* 1990;24:164-168.
- 21 Toljanic JA, Saunders VW. Radiation therapy and management of the irradiated patient. *J Prosthet Dent* 1984;52:852-858.
- 22 Beumer J, Brady FA. Dental management of the irradiated patient. *Int J Oral Surg* 1978;7:208-220.
- 23 Beumer J, Harrison R, Sanders B, Kurrasch M. Preradiation dental extractions and the incidence of bone necrosis. *Head Neck Surg* 1983;5:514-521.
- 24 Starcke EN, Shannon IL. How critical is the interval between extractions and irradiation in patients with head and neck malignancy. *Oral Surg Oral Med Oral Pathol* 1977;43:333-337.
- 25 Marx RE, Johnson RP. Studies in the radiobiology of osteoradionecrosis and their clinical significance. *Oral Surg Oral Med Oral Pathol* 1987;64:379-390.
- 26 Silverman S, Chierici G. Radiation therapy of oral carcinoma. I. Effects on oral tissues and management of the periodontium. *J Periodontol* 1965;36:478-484.
- 27 Bennett J. Oral care of cancer patients undergoing head and neck irradiation. *Dent Hyg (Chic)* 1979;53:209-212.
- 28 Dreizen S, Brown LR, Daly TE, Drane JB. Prevention of xerostomia-related dental caries in irradiated cancer patient. *J Dent Res* 1977;56:99-104.
- 29 Jansma J, Vissink A, 's-Gravenmade EJ, de Josselin de Jong E, Jongebloed WL, Retief DH. A model to investigate xerostomia-related dental caries. *Caries Res* 1988;22:357-361.
- 30 Jansma J, Vissink A, 's-Gravenmade EJ, Visch LL, Fidler V, Retief DH. In vivo study on the prevention of postirradiation caries. *Caries Res* 1989;23:172-178.
- 31 Myers RE, Mitchell DL. Fluoride for the head and neck radiation patient. *Military Medicine* 1988;153:411-413.
- 32 Miaskowski C. Management of mucositis during therapy. *NCI Monogr* 1990;9:95-98.
- 33 Stalman M, van Dijk HA, Buiting-Hazelaar HG. Hebben kinderen die met cytostatica worden behandeld extra mondverzorging nodig? *Ned Tijdschr Geneesk* 1985;129:2060-2062.
- 34 Vissink A, 's-Gravenmade EJ, Panders AK, Vermey A. Treatment of hyposalivation. *Ear Nose Throat J* 1988;67:179-185.
- 35 Spijkervet FKL. Irradiation mucositis. Prevention and treatment. Munksgaard, Copenhagen 1991.

- 36 Vissink A, 's-Gravenmade EJ, Panders AK, Petersen JK, Visch LL, Schaub RMH. A clinical comparison between commercially available mucin- and CMC-containing saliva substitutes. *Int J Oral Surg* 1983;12:232-238.
- 37 Visch LL, 's-Gravenmade EJ, Schaub RMH, van Putten WLJ, Vissink A. A double-blind crossover trial of CMC- and mucin-containing saliva substitutes. *Int J Oral Maxillofac Surg* 1986;15:395-400.
- 38 Chen TY, Webster JH. Oral monilia study on patients with head and neck cancer during radiotherapy. *Cancer* 1974;34:246-249.
- 39 Martin MV, Al-Tikriti U, Bramley PA. Yeast flora of the mouth and skin during and after irradiation for oral and laryngeal cancer. *J Med Microbiol* 1981;14:457-467.
- 40 Pau HW, Straehler-Pohl HJ, Exner M. Untersuchungen zur Sproßpilzflora während Tumor-Bestrahlungen im oberen Aerodigestivtrakt. *HNO* 1985;33:485-488.
- 41 Kropmans ThJB, Dijkstra PU, Tamminga RYJ. Modified use of a dynamic bite opener: Treatment and prevention of trismus in a child with head and neck cancer. A case report. *J Craniomand Pract* (submitted, 1991).
- 42 Donaldson SS. Nutritional consequences of radiotherapy. *Cancer Res* 1977;37:2407-2413.
- 43 Barker G, Loftus L, Cuddy P, Barker B. The effects of sucralfate suspension and diphenhydramine syrup plus kaolin-pectin on radiotherapy-induced mucositis. *Oral Surg Oral Med Oral Pathol* 1991;71:288-293.
- 44 Johnson HC. Nutritional care of cancer patients receiving radiotherapy. In: Fletcher GH, ed. *Textbook of radiotherapy*. 3rd ed. Lea and Febiger, Philadelphia 1980,92-102.
- 45 Baker DG. The radiobiological basis for tissue reactions in the oral cavity following therapeutic X-irradiation. *Arch Otolaryngol* 1982;108:21-24.
- 46 Rubin RI, Doku HC. Therapeutic radiology - the modalities and their effects on oral tissues. *J Am Dent Assoc* 1976;92:71-739.
- 47 Mira JG, Fullerton GD, Wescott WB. Correlation between initial salivary flow rate and radiation dose in production of xerostomia. *Acta Radiol Oncol* 1982;21:151-154.
- 48 Liu RP, Fleming TJ, Toth BB, Keene HJ. Salivary flow rates in patients with head and neck cancer 0.5 to 25 years after radiotherapy. *Oral Surg Oral Med Oral Pathol* 1990;70:724-729.
- 49 Vissink A, Panders AK, 's-Gravenmade EJ, Vermey A. The causes and consequences of hyposalivation. *Ear Nose Throat J* 1988;67:166-176.
- 50 Fox PC, van der Ven PF, Baum BJ, Mandel D. Pilocarpine for the treatment of xerostomia associated with salivary gland dysfunction. *Oral Surg Oral Med Oral Pathol* 1986;61:243-245.
- 51 Greenspan D, Daniels TE. Effectiveness of pilocarpine in postradiation xerostomia. *Cancer* 1987;59:1123-1125.
- 52 Vissink A, 's-Gravenmade EJ, Panders AK, Olthof A, Vermey A, Huisman MC, Visch LL. Artificial saliva reservoirs. *J Prosthet Dent* 1984;52:710-715.
- 53 Vissink A, Huisman MC, 's-Gravenmade EJ. Construction of an artificial saliva reservoir in an existing maxillary denture. *J Prosthet Dent* 1986;56:70-74.
- 54 's-Gravenmade EJ, Vissink A. Mucin-containing lozenges in the treatment of intra-oral problems associated with Sjögren's syndrome. *Oral Surg Oral Med Oral Pathol* (submitted, 1991).
- 55 Horiot JC, Schraub S, Bone MC, Bain Y, Ramadier J, Chaplain G, Nabid N, Thevenot B, Bransfield D. Dental preservation in patients irradiated for head and neck tumors: a 10-year experience with topical fluoride and a randomized trial between two fluoridation methods. *Radiother Oncol* 1983;1:77-82.
- 56 Jansma J, Vissink A, Jongebloed WL, Retief DH, 's-Gravenmade EJ. A SEM study of natural and induced radiation caries. *Am J Dent* (submitted, 1991).
- 57 Beumer J, Harrison R, Sanders B, Kurrasch M. Postradiation dental extractions: A review of the literature and a report of 72 episodes. *Head Neck Surg* 1983;6:581-586.
- 58 Marx RE, Johnson RP, Kline SN. Prevention of osteoradionecrosis: A randomized prospective clinical trial of hyperbaric oxygen versus penicillin. *J Am Dent Assoc* 1985;111:49-54.
- 59 Myers RAM, Marx RE. Use of hyperbaric oxygen in postradiation head and neck surgery. *NCI Monogr* 1990;9:151-157.

## SUMMARY

Radiation treatment plays an important role in the management of patients suffering from head and neck cancer. In addition to anti-tumor effects, head and neck radiotherapy induces damage in normal tissues which may result in oral sequelae such as mucositis, hyposalivation, radiation caries, taste loss, trismus, soft-tissue necrosis and osteoradionecrosis. These unwanted side effects and complications may be dose-limiting and have a tremendous impact on the patient's quality of life. Prevention is therefore of utmost importance.

Recently, in our research group modalities for the prevention and treatment of irradiation mucositis and hyposalivation were developed. Concerning the prevention of radiation caries, only a few of the approaches reported in the literature are based on fundamental research. These caries prophylactic regimens are inconvenient for the patient because of the lifelong need for daily fluoride applications. This implies a risk of compliance failure leading to an increased risk of caries activity. Preservation of a healthy dentition is a matter of increasing significance since the number of (elderly) dentulous patients and the dental mindedness in developed countries is increasing considerably. Cariostatic regimens should thus be optimized.

The aim of this thesis was to study the course and prevention of radiation caries and to propose an overall protocol for the prevention and treatment of oral sequelae resulting from head and neck radiotherapy. These goals, as described in **chapter 1**, were achieved by:

- a review of the literature regarding the effects of ionizing irradiation on normal tissues in the head and neck region, the resulting sequelae and their prevention and treatment (chapter 2);
- studies on the direct effects of irradiation on the acid solubility and permeability of dental enamel (chapter 3);
- the development of an in situ model for studying the onset, progression and prevention of radiation caries as a function of time (chapter 3);
- a comparison of the initiation and onset, progression of induced radiation caries with those of natural radiation caries (chapter 3);
- a study on the prevention of radiation caries by evaluating the effects of different fluoride concentrations and application frequencies, procedures (chapter 3);
- a survey of the prevention and treatment regimens of oral sequelae resulting from head and neck radiotherapy applied in all radiotherapy institutes in the Netherlands (chapter 4);
- the development of an overall protocol for the prevention and treatment of oral sequelae resulting from head and neck radiotherapy (chapter 5).

In **chapter 2**, the literature on the effects of ionizing irradiation on oral mucosa, salivary glands, dentition, periodontium, bone, masticatory muscles and temporomandibular joints is reviewed. Subsequently the resulting oral sequelae such as mucositis, taste loss, radiation caries, periodontal disease, soft-tissue necrosis, osteoradionecrosis and trismus are described. These oral side effects and complications vary in pattern, duration and intensity and do not occur in all patients. They are strongly related to irradiation type, techniques, fields and dosages. Oral sequelae can be prevented or reduced to a minimum with appropriate prophylaxis and/or treatment in many cases. Some of these measures e.g. oral hygiene measures, fluoride applications and procedures for relief of oral dryness have to be continued lifelong.

**Chapter 3** describes a series of *in vitro* and *in situ* experiments in which the course and prevention of radiation caries are studied. Hyposalivation, the changes in composition of saliva and oral flora and the altered dietary habits are all agreed upon *indirect* etiologic factors of radiation caries. The *direct* effect of ionizing irradiation on dental enamel is, however, still unclear. Furthermore, no proper model suitable for studying the development and prevention of radiation caries is known in the literature. Studies to elucidate these missing data were performed.

As a first step, a study on the direct effect of ionizing irradiation on the demineralization of bovine dental enamel *in vitro* was performed. Enamel specimens were irradiated to a total dose of 72 Gy (fractionated irradiation, 2×2 Gy/day) and subsequently demineralized (140 h) under reproducible constant composition conditions at pH 5, in some experiments after adding methylhydroxydiphosphonate (MHDP) as a demineralization inhibitor. After demineralization without MHDP, the hardness of irradiated enamel specimens was significantly less decreased ( $p < 0.001$ ) than the hardness of non-irradiated ones. No significant differences were found with hardness measurements after demineralization in the presence of MHDP which is due to the formation of a surface layer. In the presence of MHDP, quantitative micro-radiography showed that, in contrast to what was expected, both mineral loss and lesion depth were significantly *lower* ( $p < 0.001$ ) for the irradiated enamel specimens compared with the non-irradiated ones. It was concluded that ionizing irradiation *decreased* the enamel acid solubility *in vitro*.

To estimate permeability properties of bovine dental enamel before and after irradiation (single dose, 72 Gy), complex impedance measurements and radioisotope diffusion experiments were carried out. Neither impedance measurements nor diffusion experiments showed significant changes in permeability. It was concluded that ionizing irradiation of dental enamel at a therapeutic level has no influence on its permeability and thus on the organic component of enamel.

To study the onset, progression and prevention of xerostomia-related dental caries an *in situ* model was developed. The progress of the caries process was investigated on ground and polished human enamel blocks placed in sample holders mounted in the lower dentures of seven edentulous subjects suffering from irradiation-induced xerostomia. The enamel samples could easily be removed and

replaced by unscrewing the occlusal part of the holder. During a period of six weeks the samples were analyzed at weekly intervals by means of scanning optical monitoring, scanning longitudinal microradiography, scanning electron microscopy and hardness measurements. Although with the latter the indentation length increased significantly within two weeks, no demineralization could yet be observed with the other measuring techniques in most samples. Starting from the third week a progressive demineralization could be observed by all methods. The mineral loss (hydroxyapatite) in the third week was  $0.0126 \text{ kg.m}^{-2}$  (median), which increased to  $0.0761 \text{ kg.m}^{-2}$  after six weeks. Scanning electron microscopy showed an enamel destruction which resembled that of natural xerostomia-related dental caries. It was concluded that the in situ model is suitable for studying the onset, progression and prevention of xerostomia-related dental caries. The model offers an excellent opportunity to study the effect of different preventive fluoride regimens, because of the rapid induction of radiation caries and its similarity with the natural form.

Using the developed in situ model, the morphology of induced radiation carious lesions was compared with that of natural radiation caries in extracted human permanent teeth. Both natural and induced radiation caries showed the same patterns of decay, successively widespread areas with porosity of enamel, crater formation with exposure of subsurface enamel, preferential dissolution of prisms with hollowing out of prism cores, loss of large parts of surface enamel and loss of full enamel coverage exposing the underlying dentin. The sequence of these stadia was derived from the in situ model.

Finally, a study is described aiming at the development of an optimal preventive program for radiation caries by evaluating the effects of different fluoride concentrations, application frequencies and application procedures in subjects with irradiation-induced xerostomia using the in situ model. Four procedures were used: no fluoride exposure (control), neutral NaF gel applied every second day, neutral NaF gel applied once a week and a daily rinse with a fluoride-containing mouthwash, all for a period of 6 weeks. Application of NaF gel and the use of the fluoride-containing mouthwash resulted in significant inhibition of the demineralization process. Of the procedures evaluated, NaF gel applied every second day was the most effective in preventing the onset of radiation caries. Because the irradiation-induced changes in the oral environment are permanent in most patients, this regimen has to be continued lifelong in these patients.

In **chapter 4**, a survey of the prevention and treatment regimens of oral sequelae resulting from head and neck radiotherapy applied in all radiotherapy institutes in the Netherlands is presented. The differences in these regimens are evaluated. The survey was not intended to evaluate the various regimens in the patient situation. In all Dutch institutes ( $n=20$ ) in which irradiation of head and neck cancer is performed, members of the staff responsible for the prevention and treatment of oral side effects were interviewed. The questions referred to composition of the dental team, screening and pre-irradiation care, care during irradiation and post-irradiation care (see appendix). There appeared to be a great diversity in the pre-

ventive and treatment approach of the head and neck cancer patient. Probably, this diversity is mainly based on the lack of well defined guidelines in many centers, the spread of a relatively small patient group over a rather large number of centers, the absence of a dental team in some centers, the absence of an oral hygienist in some dental teams and the observation that a rather large part of the patients was not referred, or not timely referred to the dental team. There seemed to be a need for the development of an overall protocol for the prevention and treatment of oral sequelae applicable in all centers.

In **chapter 5**, such an overall protocol for the prevention and treatment of oral sequelae resulting from head and neck radiotherapy is presented. The scientific basis of this protocol is formed by the hyposalivation and mucositis studies recently performed by our research group, the radiation caries studies described in this thesis and data derived from the literature. The protocol is particularly applicable in centers operating with a dental team, ideally consisting of an oral and maxillofacial surgeon, a hospital dentist and an oral hygienist, to cover the wide range of preventive and treatment measures. This team should always be involved at the time of initial cancer diagnosis, so that a preventive regimen forms an integral part of the cancer treatment regimen. Finally, the success of the protocol is directly related to the level of patient compliance. Without the patient's cooperation, the best intentions of the dental team may still result in severe mucositis, rapidly progressive radiation caries, periodontal disease, osteoradionecrosis or soft-tissue necrosis. A close follow-up is mandatory to be able to repeatedly motivate and support the patients to adhere to the protocol. Checklists summarizing the pre-, during- and post-irradiation care are given on pages 120–122.

As shown in this thesis, head and neck radiotherapy may result in a number of unwanted early (mucositis, taste loss, hyposalivation) and late (hyposalivation, radiation caries, trismus, osteoradionecrosis) effects. These sequelae may be dose-limiting and have a tremendous impact on the patient's quality of life. Prevention or reduction to a minimum of these effects is possible and should be an integral part of head and neck cancer treatment. With the implementation of new irradiation schedules such as hyperfractionation and accelerated treatment in head and neck radiotherapy that enhance the early side effects, and with the increasing number of (aged) dentulous patients, adequate prevention and treatment of oral sequelae is a matter of increasing importance.



## SAMENVATTING

Radiotherapie neemt een belangrijke plaats in bij de behandeling van patiënten met een kwaadaardige tumor in het hoofd-halsgebied. Naast een gunstige werking, namelijk het vernietigen van tumorcellen, heeft bestraling ook schadelijke effecten op de omringende gezonde weefsels. De gevolgen hiervan zijn o.a. mucositis, hyposalie, bestralingscariës, smaakverlies, trismus, necrose van de weke delen en osteoradionecrose van het kaakbot. Deze neven-effecten kunnen dosis-beperkend zijn en hebben, zowel tijdens als na de bestralingsbehandeling, een sterk negatieve invloed op de kwaliteit van het leven van de patiënt. Preventie van deze neven-effecten is van groot belang.

Binnen de Groningse onderzoeksgroep zijn de laatste jaren belangrijke bijdragen geleverd aan de behandeling van hyposalie en de preventie van mucositis. Met betrekking tot de preventie van bestralingscariës zijn slechts enkele van de in de literatuur beschreven methoden op fundamenteel wetenschappelijk onderzoek gebaseerd. Vanwege de levenslange noodzaak van dagelijkse fluoride applicaties zijn deze cariës preventieve maatregelen zeer belastend voor de patiënt. Dit verhoogt het risico van therapie-ontrouw en daarmee de kans op een verhoogde cariës-activiteit.

Gebitsbehoud wordt steeds belangrijker. Dit komt doordat de gebitsbewustheid van de bevolking groter is geworden en doordat het aantal (oudere) patiënten met nog een natuurlijk gebit toeneemt. Optimalisering van de preventie van bestralingscariës is hierdoor noodzakelijk.

Het doel van dit proefschrift was het bestuderen van het ontstaan, het verloop en de preventie van bestralingscariës en het ontwikkelen van een zo volledig mogelijk protocol voor de preventie en behandeling van de neven-effecten van bestraling in het hoofd-halsgebied. Dit doel, zoals beschreven in **hoofdstuk 1**, werd nagestreefd door:

- het inventariseren van de literatuur over de effecten van bestraling op de gezonde weefsels in het hoofd-halsgebied, over de hieruit voortvloeiende neven-effecten en over hun preventie en behandeling (hoofdstuk 2);
- het bestuderen van de directe effecten van bestraling op de zuuroplosbaarheid en de permeabiliteit van tandglazuur (hoofdstuk 3);
- het ontwikkelen van een in situ model, waarmee het ontstaan, het verloop en de preventie van bestralingscariës als een functie van de tijd kan worden bestudeerd (hoofdstuk 3);
- het vergelijken van het ontstaan en het verloop van geïnduceerde bestralingscariës met die van natuurlijke bestralingscariës (hoofdstuk 3);
- het bestuderen van de preventie van bestralingscariës door de effecten van verschillende fluoride concentraties, applicatie-frequenties en toepassingsvormen

- te vergelijken (hoofdstuk 3);
- het inventariseren van de maatregelen ter preventie en behandeling van neven-effecten van hoofd-halsbestraling zoals die worden toegepast in de verschillende Nederlandse radiotherapeutische afdelingen (hoofdstuk 4);
  - het ontwikkelen van een uitgebreid protocol voor de preventie en behandeling van de belangrijkste neven-effecten van bestraling in het hoofd-halsgebied (hoofdstuk 5).

In **hoofdstuk 2** wordt een overzicht gegeven van de literatuur betreffende de effecten van ioniserende straling op mondslijmvlies (orale mucosa), speekselklieren, gebitselementen, parodontium, kaakbot, kauwspieren en het kaakgewricht. Verder worden de hierdoor veroorzaakte neven-effecten beschreven zoals mucositis, hyposalie, smaakverlies, bestralingscariës, parodontitis, necrose van de weke delen, osteoradionecrose en trismus. Deze neven-effecten variëren in ernst en duur en komen niet bij alle patiënten voor. Ze zijn sterk gerelateerd aan bestralingsstype, -techniek, -veld en -dosis. In veel gevallen kunnen de neven-effecten tot een minimum worden beperkt of voorkomen worden met behulp van een adequate profylaxe en/of behandeling. Een aantal preventieve maatregelen zoals optimale mondhygiëne, fluoride gebruik en middelen ter bestrijding van een droge mond dient vaak levenslang te worden voortgezet.

In **hoofdstuk 3** wordt een aantal *in vitro* en *in situ* experimenten beschreven, waarin het verloop en de preventie van bestralingscariës werden bestudeerd. De *indirecte* etiologische factoren die een rol spelen bij het optreden van bestralingscariës zijn algemeen aanvaard. Dit zijn hyposalie en de hiermee samenhangende veranderingen in de samenstelling van speeksel en mondfloor in combinatie met een veranderd voedingspatroon. Het *directe* effect van bestraling op het tandglazuur zelf is echter nog steeds onopgehelderd. Verder is uit de literatuur geen geschikt model bekend, waarmee het verloop en de preventie van bestralingscariës kan worden bestudeerd. Diverse onderzoeken om deze ontbrekende gegevens te verkrijgen werden uitgevoerd.

Met een onderzoek naar het directe effect van ioniserende straling op de zuuroplosbaarheid van runderglazuur *in vitro* werd begonnen. Glazuurblokjes werden gefractioneerd bestraald tot een cumulatieve dosis van 72 Gy (2x2 Gy/dag) en vervolgens gedemineraliseerd (140 uur) onder reproduceerbare omstandigheden in een zuur milieu (pH=5). In een aantal gevallen werd als demineraliserend middel methylhydroxydifosfaat (MHDP) toegevoegd. Na demineralisatie zonder MHDP was de hardheid van bestraald glazuur significant minder afgenomen dan de hardheid van niet bestraald glazuur ( $p < 0.001$ ). In aanwezigheid van MHDP werden geen significante hardheidsverschillen gevonden, hetgeen kan worden verklaard door de vorming van een oppervlaktelaag. Kwantitatieve microradiografie toonde aan dat, in tegenstelling tot wat men zou verwachten, zowel het mineraalverlies als de diepte van geïnduceerde laesies significant *lager* waren ( $p < 0.001$ ) in bestraald glazuur dan in niet bestraald glazuur. Uit het onderzoek werd geconcludeerd, dat ionise-

rende straling een *afnem*ing veroorzaakt van de zuuroplosbaarheid van glazuur in vitro en dus een stabiliserend effect heeft.

Met behulp van impedantiemetingen en diffusie-experimenten met radioactieve isotopen werd een onderzoek verricht naar mogelijke verschillen in de permeabiliteit van runderglazuur vóór en na bestraling (enkelvoudige dosis, 72 Gy). Met geen van deze twee zeer gevoelige meetmethodieken werden significante verschillen in permeabiliteit gevonden. Uit het onderzoek werd geconcludeerd dat bestraling van glazuur met een therapeutische dosis geen invloed heeft op de permeabiliteit en dus geen invloed heeft op de organische component van tandglazuur.

Voor het bestuderen van het ontstaan, het verloop en de preventie van aan xerostomie gerelateerde cariës werd een *in situ* model ontwikkeld. Het verloop van het cariës-proces werd onderzocht met behulp van vlak geschuurde en gepolijste humane glazuurpreparaten. Deze werden in glazuurhouders in daartoe aangepaste onderprothesen van proefpersonen met door bestraling geïnduceerde xerostomie geplaatst. De glazuurmonsters konden gemakkelijk uit de houders worden gehaald en worden herplaatst. Het was daardoor mogelijk om gedurende een periode van zes weken de preparaten wekelijks te analyseren met behulp van lichtverstrooiing, longitudinale microradiografie, scanning elektronenmicroscopie en hardheidsmetingen. Hoewel bij deze laatste metingen de indentatielengte binnen twee weken was toegenomen, werd in dezelfde periode met de andere meetmethoden in de meeste preparaten nog geen demineralisatie waargenomen. Beginnend in de derde week werd met alle methoden een voortschrijdende demineralisatie manifest. Het mineraalverlies (hydroxylapatiet) was in de derde week  $0,0126 \text{ kg.m}^{-2}$  (mediaan waarde) en nam toe tot  $0,0761 \text{ kg.m}^{-2}$  na zes weken. Elektronenmicroscopisch onderzoek liet een patroon van glazuuraantasting zien dat overeenstemde met natuurlijke, aan xerostomie gerelateerde cariës. Geconcludeerd mag worden dat het *in situ* model zeer geschikt is voor het bestuderen van het ontstaan, het verloop en de preventie van aan xerostomie gerelateerde cariës. Vanwege de snelle inductie van bestralingscariës in het model en de overeenkomst daarvan met de natuurlijke vorm, biedt het model een uitstekende gelegenheid om het effect van verschillende preventieve fluoride regimes te onderzoeken.

De morfologie van de laesies die waren geïnduceerd met behulp van dit *in situ* model werd vergeleken met de morfologie van natuurlijke bestralingscariës in geëxtraheerde gebitselementen. Beide cariësvormen vertoonden hetzelfde aantastingspatroon, namelijk achtereenvolgens het optreden van porositeit in grote glazuurgebieden, kratervorming met blootlegging van het 'subsurface' glazuur, uitholling van glazuurprismata, verlies van grote delen van het oppervlakte glazuur en uiteindelijk verlies van delen van de glazuurkap met als gevolg het bloot komen te liggen van het dentine. De volgorde van deze stadia kon worden bepaald met behulp van het *in situ* model.

Tenslotte werd een onderzoek verricht dat het ontwikkelen van een optimale preventie van bestralingscariës tot doel had. De effecten van verschillende fluoride concentraties, applicatie-frequenties en toepassingsvormen werden, gebruik makend van het *in situ* model, met elkaar vergeleken. Vier procedures werden

onderzocht: geen fluoride gebruik (controle groep), neutrale NaF gel applicatie eens per twee dagen, neutrale NaF gel applicatie eens per week en een dagelijkse spoeling met een fluoride houdend mondwater. Alle experimenten duurden zes weken. Applicatie van NaF gel en gebruik van de fluoride houdende mondspoeling resulteerden in een significante vermindering van de demineralisatie. Van de onderzochte procedures was de applicatie van een neutrale NaF gel eens per twee dagen het meest effectief voor de preventie van bestralingscariës. Doordat de veranderingen in het orale milieu als gevolg van de bestraling meestal blijvend zijn, zal dit fluoridebeleid vaak het hele verdere leven moeten worden voortgezet.

In **hoofdstuk 4** wordt een inventarisatie beschreven van de gebruikte maatregelen ter preventie en behandeling van de neven-effecten van hoofd-halsbestraling onder alle Nederlandse afdelingen voor Radiotherapie. De verschillen tussen de maatregelen werden geëvalueerd. Om praktische redenen had de inventarisatie niet tot doel de verschillende maatregelen ook in de patiënt-situatie te evalueren. In genoemde instituten (n=20) werden enkele leden van het team, dat verantwoordelijk was voor de preventie en behandeling van bijwerkingen in de mond, geïnterviewd. De vragen hadden betrekking op de samenstelling van het tandheelkundig team, het onderzoek voorafgaand aan de bestraling en de zorg vóór, tijdens en na de bestraling (zie appendix). Er bleek een grote pluriformiteit te bestaan in de preventieve zorg voor de bestralingspatiënt. Deze pluriformiteit is waarschijnlijk vooral te wijten aan het ontbreken van voldoende duidelijke richtlijnen in een aantal centra, de verdeling van een relatief kleine patiëntengroep over een relatief groot aantal centra, het ontbreken van een tandheelkundig team in sommige centra, het ontbreken van een mondhygiënist in sommige tandheelkundige teams en het feit dat een aanzienlijk deel van de patiënten te laat of in het geheel niet werd verwezen naar een tandheelkundig team. Er lijkt een behoefte te bestaan aan de ontwikkeling van een protocol voor de preventie en behandeling van de neven-effecten van bestraling in het hoofd-halsgebied, dat toepasbaar is in alle centra.

In **hoofdstuk 5** wordt een voorstel voor een dergelijk, zo volledig mogelijk, protocol voor de preventie en behandeling van de neven-effecten van hoofd-halsbestraling gepresenteerd. De wetenschappelijke basis voor dit protocol wordt gevormd door de hyposalie en mucositis onderzoeken die binnen de Groningse onderzoeksgroep zijn uitgevoerd, de bestralingscariës onderzoeken die beschreven zijn in dit proefschrift en gegevens uit de literatuur. Het protocol is met name toepasbaar in instituten die de beschikking hebben over een tandheelkundig team bij voorkeur samengesteld uit een kaakchirurg, een centrum-tandarts en een mondhygiënist. Dit team hoort zo spoedig mogelijk na het stellen van de diagnose bij de behandeling te worden ingeschakeld, zodat de preventie een integraal onderdeel vormt van de kankerbehandeling en er dus voldoende tijd is om de verschillende maatregelen uit te voeren. De resultaten van de preventieve maatregelen zijn direct gerelateerd aan de mate van medewerking van de patiënt. Zonder deze coöperatie zullen de inspanningen van het tandheelkundig team toch vaak resulteren in het optreden

van ernstige mucositis, een zeer progressieve vorm van cariës, parodontitis, osteoradionecrose of necrose van de weke delen. Om de patiënt optimaal te kunnen begeleiden en te motiveren om zich te houden aan het protocol is een strikte follow-up een absolute voorwaarde. De belangrijkste punten van het protocol zijn samengevat in 'checklists'. Deze behandelen de noodzakelijke zorg voorafgaand aan, tijdens en na de bestraling (blz. 120–122).

Zoals beschreven in dit proefschrift, kan bestraling in het hoofd-halsgebied aanleiding geven tot een aantal vroege (mucositis, smaakverlies, hyposialie) en late (hyposialie, bestralingscariës, trismus, osteoradionecrose) neven-effecten. Deze effecten kunnen dosis-beperkend zijn en hebben een grote invloed op de kwaliteit van het leven van de patiënt. Preventie van de neven-effecten, dan wel het tot een minimum beperken ervan, is goed mogelijk en behoort een integraal onderdeel van de radiotherapeutische behandeling van kwaadaardige tumoren in het hoofd-halsgebied te zijn. Toepassing van nieuwe bestralingstechnieken zoals hyperfractionering en versnelde fractionering leidt tot een toename van vroege effecten zoals mucositis. Deze nieuwe bestralingstechnieken en de toename van het aantal patiënten in de bevolking met nog een natuurlijk gebit dat prijs stelt op behoud daarvan, maken dat adequate preventie en behandeling van de neven-effecten van bestraling in het hoofd-halsgebied van steeds groter belang worden.



## APPENDIX: QUESTIONNAIRE

In the period June-October 1990 all radiotherapy institutes in the Netherlands in which irradiation for head and neck cancer is performed (n=20) were visited (chapter 4). Members of the staff (radiotherapist, oral and maxillofacial surgeon, hospital dentist, oral hygienist) responsible for the management of the oral sequelae resulting from head and neck radiotherapy were interviewed using the questions listed below as a guideline. All questions were scored in predefined categories.

- 1 Who are responsible for the dental care and the management of oral side effects in patients receiving radiotherapy in the head and neck region?

	yes	no
hospital dentist	8 (40%)	12 (60%)
oral hygienist	16 (80%)	4 (20%)
oral surgeon	14 (70%)	6 (30%)
family dentist	5 (25%)	15 (75%)

- 2 Which percentage of patients of whom the oral cavity, the jaws, or the major salivary glands will be in the field of radiation is screened prior to the onset of radiotherapy by the dental team (oral surgeon, hospital dentist, oral hygienist)?

**dentulous patients:**

- 9 (45%) all patients
- 4 (20%) 75%–100% of the patients
- 3 (15%) 50%–75% of the patients
- 1 ( 5%) less than 50% of the patients
- 3 (15%) family dentist

**edentulous patients:**

- 7 (35%) all patients
- 4 (20%) 75%–100% of the patients
- 2 (10%) 50%–75% of the patients
- 4 (20%) less than 50% of the patients
- 0 ( 0%) family dentist
- 3 (15%) no screening on foci of infection

- 3 When are patients usually screened by the dental team?

**dentulous patients:**

- 9 (45%) more than 2 weeks before onset of radiotherapy
- 8 (40%) less than 2 weeks before onset of radiotherapy
- 3 (15%) no screening

**edentulous patients:**

- 8 (40%) more than 2 weeks before onset of radiotherapy
- 8 (40%) less than 2 weeks before onset of radiotherapy
- 1 ( 5%) in case of complaints during radiotherapy
- 3 (15%) no screening



4 What are the standard pre-irradiation dental assessments and instructions?

	yes	no	unknown
<b>dentulous patients:</b>			
plaque score	4 (20%)	13 (65%)	3 (15%)
bleeding index	13 (65%)	4 (20%)	3 (15%)
record of pocket depths	13 (65%)	4 (20%)	3 (15%)
vitality testing	4 (20%)	13 (65%)	3 (15%)
X-rays	17 (85%)	0 ( 0%)	3 (15%)
oral hygiene instructions	16 (80%)	1 ( 5%)	3 (15%)
professional tooth cleansing	16 (80%)	1 ( 5%)	3 (15%)
rootplaning and curettage	11 (55%)	6 (30%)	3 (15%)
removal of caries	16 (80%)	1 ( 5%)	3 (15%)
measuring mouth opening	0 ( 0%)	17 (85%)	3 (15%)
measuring salivary flow rate	2 (10%)	15 (75%)	3 (15%)
<b>edentulous patients:</b>			
checking denture fit	14 (70%)	3 (15%)	3 (15%)
checking oral mucosa	14 (70%)	3 (15%)	3 (15%)
X-rays	15 (75%)	2 (10%)	3 (15%)
oral hygiene instructions	12 (60%)	5 (25%)	3 (15%)
measuring mouth opening	0 ( 0%)	17 (85%)	3 (15%)
measuring salivary flow rate	2 (10%)	15 (75%)	3 (15%)

5 How is the pre-irradiation level of salivary secretion measured?

18 (90%)	salivary secretion is not measured
1 ( 5%)	by measuring parotid flow rate
1 ( 5%)	by clinical impression after citric acid stimulation

6 Are surveillance cultures of the oral flora routinely performed prior to radiotherapy?

0 ( 0%)	yes
20 (100%)	no

7 When pre-irradiation extractions are indicated, what is the minimal healing time considered necessary in this center?

1 ( 5%)	0–1 weeks
9 (45%)	1–2 weeks
10 (50%)	2–4 weeks

8 Is wound healing routinely checked before radiotherapy is started in case of pre-irradiation extractions?

12 (60%)	yes
4 (20%)	no
4 (20%)	unknown

9 What are the standard oral hygiene instructions?

	yes	no	unknown
<b>dentulous patients:</b>			
toothbrushing	16 (80%)	1 ( 5%)	3 (15%)

interdental cleansing	15 (75%)	2 (10%)	3 (15%)
disclosing agents	1 ( 5%)	16 (80%)	3 (15%)
fluoride usage other than fluoride containing toothpaste	18 (90%)	1 ( 5%)	1 ( 5%)
<b>edentulous patients:</b>			
cleansing oral cavity	10 (50%)	10 (50%)	
denture hygiene	12 (60%)	8 (40%)	
massage of oral mucosa	7 (35%)	13 (65%)	
discouraging denture wearing during therapy	7 (35%)	13 (65%)	

10 Are patients allowed to wear full or partial dentures during the radiation treatment period, when their oral cavity is in the field of radiation?

13 (65%)    yes, until complaints appear  
7 (35%)    no

11 What is the rationale behind wearing or not wearing dentures during radiotherapy?

wearing permitted:	9 (45%)	no difference between wearing and non wearing is assumed by the dental team
	3 (15%)	psychologic/social reasons
	1 ( 5%)	to facilitate food intake
wearing discouraged:	7 (35%)	to prevent mucosal irritation

12 Are patients routinely referred to a dietitian prior to radiotherapy?

11 (55%)    yes  
9 (45%)    no

13 Does the dental team receive information about radiation dosage and field prior to radiotherapy?

4 (20%)    always  
5 (25%)    mostly  
6 (30%)    seldom  
2 (10%)    never  
3 (15%)    unknown

14 Which fluoride preparation do you prescribe as a standard and which preparations on special indication?

	standard	on indication
neutral NaF gel	6 (30%)	1 ( 5%)
acidulated NaF gel	4 (20%)	2 (10%)
aminfluoride gel	5 (25%)	2 (10%)
neutral NaF mouthwash	3 (15%)	2 (10%)
only fluoride containing toothpaste	1 ( 5%)	
unknown	1 ( 5%)	

15 Who applies the fluoride preparation?

	during therapy	after therapy
oral hygienist	3 (15%)	1 ( 5%)
patient	16 (80%)	18 (90%)
total dose <40 Gy: oral hygienist*	1 ( 5%)	1 ( 5%)
total dose >40 Gy: patient*	1 ( 5%)	1 ( 5%)

\* same center

16 When a fluoride gel is used, how is this gel applied?

	during therapy	after therapy
custommade fluoride carrier	13 (65%)	14 (70%)
total dose >40 Gy: custommade carrier*	1 ( 5%)	1 ( 5%)
commercial fluoride carrier	3 (15%)	2 (10%)
total dose <40 Gy: commercial carrier*	1 ( 5%)	1 ( 5%)
no gel	3 (15%)	3 (15%)

\* same center

17 What is the standard fluoride application frequency during radiotherapy?

1 ( 5%)	more than one time per day
12 (60%)	one time per day
1 ( 5%)*	total dose >40 Gy: one time per day
2 (10%)	twice a week
3 (15%)	one time per week
1 ( 5%)*	total dose <40 Gy: one time per week
1 ( 5%)	unknown

\* same center

18 What is the standard oral care during radiotherapy?

20 (100%)	weekly inspection of the oral mucosa
5 (25%)	intervention only in case of complaints
15 (75%)	frequent rinsing of the oral cavity with*:
1 ( 5%)	water
11 (55%)	camomile
5 (25%)	saline
2 (10%)	salt-soda
1 ( 5%)	Emser salt
1 ( 5%)	old brown ale
1 ( 5%)	blueberry juice
4 (20%)	frequent professional spraying with saline
2 (10%)	medicinal mucositis prevention with PTA lozenges (polymyxin E, tobramycin, amphotericin B)
6 (30%)	professional tooth cleansing
18 (90%)	fluoride application
3 (15%)	wearing of fluoride carriers during irradiation
7 (35%)	discouraging denture wearing

\* more than one rinse was used in some centers

19 What is the therapy after mucositis related complaints have developed?

- 20 (100%) frequent rinsing of the oral cavity with\*:
  - 1 ( 5%) water
  - 14 (70%) camomile
  - 6 (30%) saline
  - 2 (10%) salt-soda
  - 1 ( 5%) Emser salt
  - 5 (25%) chlorhexidine
- 7 (35%) frequent professional spraying with:
  - 4 (20%) saline
  - 2 (10%) chlorhexidine
  - 1 ( 5%) hydrogen peroxide
- 4 (20%) PTA lozenges
- 4 (20%) Nystatin®
- 20 (100%) discouraging denture wearing
- 1 ( 5%) viscous lidocaine
- 2 (10%) sucralfate

\* more than one rinse was used in some centers

20 Is the oral flora routinely cultured in case of mucositis?

- 2 (10%) yes
- 18 (90%) no

21 Is the oral flora cultured when there is clinical suspicion of candidiasis?

- 10 (50%) yes
- 10 (50%) no

22 How frequent are the hospitalized patients seen by the dental team during the radiation treatment period?

**dentulous patients:**

- 2 (10%) daily
- 1 ( 5%) three times per week
- 5 (25%) twice a week
- 5 (25%) one time per week
- 1 ( 5%) one time per two weeks
- 1 ( 5%) one time per three weeks
- 5 (25%) not seen

**edentulous patients:**

- 2 (10%) daily
- 1 ( 5%) twice a week
- 4 (20%) one time per week
- 1 ( 5%) one time per three weeks
- 3 (15%) in case of problems
- 9 (45%) not seen

23 How frequent are the ambulant patients seen by the dental team during the radiation treatment period?

**dentulous patients:**

- 1 ( 5%) daily
- 4 (20%) twice a week
- 8 (40%) one time per week
- 2 (10%) one time per two weeks
- 1 ( 5%) one time per three weeks
- 4 (20%) not seen

**edentulous patients:**

- 1 ( 5%) daily
- 1 ( 5%) twice a week
- 4 (20%) one time per week
- 2 (10%) one time per two weeks
- 1 ( 5%) one time per three weeks
- 2 (10%) in case of problems
- 9 (45%) not seen

24 Does it occur that the radiation treatment has to be stopped temporarily because of severe mucositis?

- 13 (65%) yes
- 7 (35%) no

25 Is the frequency of fluoride applications reduced after radiotherapy?

- 17 (85%) yes
- 2 (10%) no
- 1 ( 5%) unknown

26 Is the frequency of fluoride applications reduced using a standard schedule?

- 10 (50%) yes (for reduction schedules see chapter 4, Table 7, pg. 108)
- 9 (45%) no
- 1 ( 5%) unknown

27 On what factors is the reduction of the fluoride application frequency based?\*

	yes	no
total radiation dose	1 ( 5%)	16 (80%)
field of radiation	1 ( 5%)	16 (80%)
oral dryness according to patient	15 (75%)	2 (10%)
oral dryness according to clinician	11 (55%)	6 (30%)
measured oral dryness	1 ( 5%)	16 (80%)
level of oral hygiene	14 (70%)	3 (15%)
dental status	13 (65%)	4 (20%)

\* only centers in which the fluoride application frequency is reduced are recorded

- 28 At what moment after radiotherapy is fluoride reduction usually started?
- 2 (10%) no reduction
  - 9 (45%) immediately after radiotherapy
  - 5 (25%) three months after radiotherapy
  - 1 ( 5%) one year after radiotherapy
  - 1 ( 5%) two years after radiotherapy
  - 1 ( 5%) strictly individual
  - 1 ( 5%) unknown
- 29 Is the frequency of fluoride applications reduced to zero or to a minimal frequency?
- 5 (25%) to zero
  - 12 (60%) to a minimal application frequency:
    - 1 ( 5%) twice a week
    - 1 ( 5%) one time per week
    - 2 (10%) one time per two weeks
    - 2 (10%) one time per month
    - 1 ( 5%) one time per three months
    - 4 (20%) one time per six months
    - 1 ( 5%) strictly individual
  - 2 (10%) no reduction
  - 1 ( 5%) unknown
- 30 How frequent are the patients seen by the dental team during the early post-irradiation period?
- dentulous patients:**
- 1 ( 5%) screening weekly during the first month, thereafter discontinued
  - 11 (55%) every month
  - 2 (10%) every three months
  - 1 ( 5%) every six months
  - 5 (25%) not seen
- edentulous patients:**
- 1 ( 5%) screening weekly during the first month, thereafter discontinued
  - 1 ( 5%) every month
  - 1 ( 5%) every three months
  - 4 (20%) by oral and maxillofacial surgeon during oncologic follow-up
  - 13 (65%) not seen
- 31 Is this frequency directly related to the oncologic follow-up?
- dentulous patients:**
- 8 (40%) yes
  - 12 (60%) no
- edentulous patients:**
- 5 (25%) yes
  - 15 (75%) no

32 By whom is the patient checked during the post-irradiation visits?

	yes	no
<b>dentulous patients:</b>		
oral hygienist	15 (75%)	5 ( 25%)
hospital dentist	2 (10%)	18 ( 90%)
family dentist	7 (35%)	13 ( 65%)
oral and maxillofacial surgeon	10 (50%)	10 ( 50%)
<b>edentulous patients:</b>		
oral hygienist	3 (15%)	17 ( 85%)
hospital dentist	0 ( 0%)	20 (100%)
family dentist	0 ( 0%)	20 (100%)
oral and maxillofacial surgeon	8 (40%)	12 ( 60%)

33 What are the standard dental procedures for dentulous patients during post-irradiation control visits?\*

	yes	no
plaque score	3 (15%)	12 (60%)
bleeding index	9 (45%)	6 (30%)
record of pocket depths	10 (50%)	5 (25%)
X-rays	0 ( 0%)	15 (75%)
measuring mouth opening	0 ( 0%)	15 (75%)
measuring salivary flow rate	1 ( 5%)	14 (70%)
oral hygiene instructions	15 (80%)	0 ( 0%)
professional tooth cleansing	13 (65%)	2 (10%)
fluoride application	2 (10%)	13 (65%)

\* in five centers dentulous patients are not seen by the dental team after radiotherapy

34 At what moment after radiotherapy are patients allowed to wear their dentures?

18 (90%)	immediately after therapy, or as soon as mucositis signs have disappeared
1 ( 5%)	two months after therapy
1 ( 5%)	three months after therapy

35 What is the post-irradiation extraction protocol in case of removal of teeth from irradiated jaw segments?

2 (10%)	only in exceptional cases + antibiotics
6 (30%)	independent of time after radiotherapy + antibiotics
2 (10%)	not within first six months after radiotherapy + antibiotics
2 (10%)	not within first six months after radiotherapy + primary wound closure + antibiotics
1 ( 5%)	not within first six months after radiotherapy, no antibiotics prescribed
7 (35%)	not within first year after radiotherapy + antibiotics

36 Is there a substantial role for the family dentist pre-, during-, and post-irradiation?

7 (35%)	yes
13 (65%)	no



37 At what moment after radiotherapy is the patient no longer screened by the dental team, and thus dental care left to the family dentist only?\*

**dentulous patients:**

- 3 (15%) 0–3 months after radiotherapy
- 2 (10%) 3–6 months after radiotherapy
- 3 (15%) 6–12 months after radiotherapy
- 2 (10%) 1–2 years after radiotherapy
- 2 (10%) 3–5 years after radiotherapy
- 2 (10%) more than 5 years after radiotherapy
- 1 ( 5%) only screening on foci of infection, dental care left to family dentist
- 3 (15%) screening and care left to family dentist
- 2 (10%) unknown

**edentulous patients:**

- 1 ( 5%) patient stays with dental team
- 5 (25%) immediately after radiotherapy
- 3 (15%) 0–3 months after radiotherapy
- 1 ( 5%) 6–12 months after radiotherapy
- 1 ( 5%) 1–2 years after radiotherapy
- 6 (30%) only screening on foci of infection, dental care left to family dentist
- 3 (15%) screening and care left to family dentist

\* in four centers oral and maxillofacial surgeons who participated in the oncologic follow-up screened the patients after visits with the dental team had stopped.

38 Are patients routinely instructed about foods that should be avoided during or after radiotherapy?

- 11 (55%) yes
- 1 ( 5%) only in case of complaints
- 8 (40%) no

39 How do you determine the residual capacity of the salivary glands after radiotherapy?

	yes	no
anamnesic	3 (15%)	17 (85%)
clinical impression	18 (90%)	2 (10%)
response on stimulus (citric acid)	1 ( 5%)	19 (95%)
measuring parotid salivary flow rate	1 ( 5%)	19 (95%)

40 When is a therapy for relief of oral dryness initiated?

- 19 (95%) in patients with subjective complaints
- 1 ( 5%) in patients with objective and subjective complaints

41 What is usually the therapy in case of oral dryness?\*

	yes	no
no therapy	1 ( 5%)	19 (95%)
household remedies (e.g. old brown ale, cold tea)	13 (65%)	7 (35%)
gustatory stimulation (e.g. vitamin C tablets)	10 (50%)	10 (50%)

sialogogues (e.g. pilocarpine)	2 (10%)	18 (90%)
artificial saliva	18 (90%)	2 (10%)
artificial saliva reservoirs	2 (10%)	18 (90%)

\* more than one therapy was used by some centers

42 When an artificial saliva is prescribed, is this carboxymethylcellulose (CMC)-, or mucin-based?\*

17 (85%)	CMC-based
11 (55%)	mucin-based

\* in eight centers both types were prescribed without preference.

43 What are the instructions about frequency of usage of the artificial saliva?

18 (90%)	ad libitum
2 (10%)	with definite intervals

44 Does the dental team receive information about the radiation dosage and field after radiotherapy has been completed?

7 (35%)	always
4 (20%)	mostly
6 (30%)	seldom
3 (15%)	unknown

45 What is the basis of the fluoride regimen used in this center?

	yes	no	unknown
literature	10 (50%)	9 (45%)	1 (5%)
clinical experience	8 (40%)	11 (55%)	1 (5%)
protocol adopted from other center	11 (55%)	8 (40%)	1 (5%)
protocol adopted from predecessor	4 (20%)	15 (75%)	1 (5%)
own research	1 (5%)	18 (90%)	1 (5%)

## **CURRICULUM VITAE**

Johan Jansma werd geboren op 24 januari 1962 te Leeuwarden. In 1980 behaalde hij het atheneum B diploma aan het Wessel Gansfort College te Groningen. In hetzelfde jaar begon hij met de studie Tandheelkunde aan de Rijksuniversiteit Groningen, waar hij in maart 1986 het tandartsdiploma behaalde. Van september 1987 tot september 1991 werd hij opgeleid tot specialist in de Mondziekten en Kaakchirurgie aan de Afdeling Mondziekten, Kaakchirurgie en Bijzondere Tandheelkunde (Hoofd: Prof. Dr. G. Boering) van het Academisch Ziekenhuis Groningen. Vanaf september 1991 is hij als kaakchirurg verbonden aan deze Afdeling, waar hij zich in het bijzonder zal toeleggen op de operatieve kaakorthopedie en de secundaire schisischirurgie.

Address for correspondence:

Johan Jansma  
Dept. of Oral and Maxillofacial Surgery  
University Hospital Groningen  
Oostersingel 59  
P.O. Box 30.001  
9700 RB Groningen  
The Netherlands  
Tel: 050-613840  
Fax: 050-696724

