

University of Groningen

Implant-supported maxillary overdentures

Slot, Jan Willem André

IMPORTANT NOTE: You are advised to consult the publisher's version (publisher's PDF) if you wish to cite from it. Please check the document version below.

Document Version

Publisher's PDF, also known as Version of record

Publication date:

2013

[Link to publication in University of Groningen/UMCG research database](#)

Citation for published version (APA):

Slot, J. W. A. (2013). *Implant-supported maxillary overdentures*. s.n.

Copyright

Other than for strictly personal use, it is not permitted to download or to forward/distribute the text or part of it without the consent of the author(s) and/or copyright holder(s), unless the work is under an open content license (like Creative Commons).

The publication may also be distributed here under the terms of Article 25fa of the Dutch Copyright Act, indicated by the "Taverne" license. More information can be found on the University of Groningen website: <https://www.rug.nl/library/open-access/self-archiving-pure/taverne-amendment>.

Take-down policy

If you believe that this document breaches copyright please contact us providing details, and we will remove access to the work immediately and investigate your claim.

Downloaded from the University of Groningen/UMCG research database (Pure): <http://www.rug.nl/research/portal>. For technical reasons the number of authors shown on this cover page is limited to 10 maximum.

Implant-supported maxillary overdentures

Wim Slot

ISSMOC

Rijksuniversiteit Groningen

The research presented in this thesis was performed at the Department of Fixed and Removable Prosthodontics, Center for Dentistry and Oral Health, and at the Department of Oral and Maxillofacial Surgery, University Medical Center Groningen, University of Groningen, the Netherlands.

This research was supported by

Institut Straumann AG, Basel, Switzerland
DENTSPLY implants (formerly known as; Astra Tech AB, Mölndal, Sweden)

Publication of this thesis was more than generously supported by

Tandtechnisch en Maxillofaciaal Laboratorium Gerrit van Dijk, Groningen

Further funding was generously provided by

Dentaid BeNeLux B.V. (Perio•Aid, Chloorhexidine) (www.dentaid.nl)
Dent-Med Materials b.v., importeur Geistlich Bio-Oss® en Geistlich Bio-Gide® (www.dent-medmaterials.nl)
Dental Union (www.dentalunion.nl)
DENTSPLY implants (www.dentsplyimplants.nl)
ExamVision Benelux (www.examvision.nl)
Geistlich Pharma (www.geistlich.com)
Huisartsen Ossenmarkt (www.huisartsen-ossenmarkt.nl)
KLS Martin Group (www.klsmartin.com)
Nederlandse Vereniging voor Gnathologie en Prothetische Tandheelkunde (www.nvgpt.nl)
Nederlandse Vereniging voor Mondziekten, Kaak- en Aangezichtschirurgie (www.nvmka.nl)
Nederlandse Vereniging voor Orale Implantologie (www.nvoi.nl)
Neobiotech, official distributor; Wim van Uum (www.neobiotech.nl)
Nobel Biocare Nederland B.V. (www.nobelbiocare.nl)
Raadsheeren B.V., de financiële coach voor medici (www.raadsheeren.nl)
REIN Advocaten & Adviseurs (www.rein.nl)
Robouw Medical (www.robouwmedical.nl)
Sweden & Martina, official distributor; E&M Dental Implant Solutions (www.emdis.nl)
Straumann B.V. (www.straumann.nl)
Tandtechnisch laboratorium Oosterwijk (www.elyseedentalgroup.nl/ttloosterwijk)
TIPTandartsen (www.tiptandartsen.nl)
University Medical Center Groningen (www.umcg.nl)
University of Groningen (www.rug.nl)

Grafic design Monique Dijkman, Leeuwarden (www.moniquedijkman.nl)

Printing Hellinga Grafische Specialisten, Leeuwarden (www.hellinga.nl)

Publisher Wim Slot, Groningen (www.mondarts.nl)

ISBN 978-90-367-6078-2

© Wim Slot, 2013

All rights reserved. No part of this publication may be reported or transmitted, in any form or by any means, without prior permission of the author.

Implant-supported maxillary overdentures Proefschrift

Ter verkrijging van het doctoraat in de
Medische Wetenschappen
aan de Rijksuniversiteit Groningen
op gezag van de
Rector Magnificus, dr. E. Sterken,
in het openbaar te verdedigen op
maandag 22 april 2013
om 16.15 uur
door

Jan Willem André Slot

geboren op 1 juli 1960
te Coevorden.

Promotores

Prof. dr. H.J.A. Meijer
Prof. dr. G.M. Raghoobar
Prof. dr. A. Vissink

Paranimfen

Mr. J.P. Loopstra
Drs. W.R.J. van der Velde

Beoordelingscommissie

Prof. dr. C.M. ten Bruggenkate
Prof. dr. J.M.A. de Lange
Prof. dr. C. de Putter

Contents

Chapter 1 Introduction	11
Chapter 2 A systematic review of implant-supported maxillary overdentures after a mean observation period of at least 1 year	21
Chapter 3 Maxillary overdentures supported by 4 or 6 implants in the anterior region; 1-year results from a randomized controlled trial	63
Chapter 4 A comparison between 4 and 6 implants in the maxillary posterior region to support an overdenture; 1-year results from a randomized controlled trial	89
Chapter 5 Maxillary overdentures supported by anteriorly or posteriorly placed implants opposed by a natural dentition in the mandible: a 1-year prospective case series study	115
Chapter 6 Attachment of clips in a bar-supported maxillary implant overdenture: a clinical report	145
Chapter 7 General discussion and conclusions	161
Chapter 8 Summary/samenvatting	171
Dankwoord	187
Curriculum vitae	195

Chapter I
Introduction

Introduction

Oral implantology is a fast growing treatment procedure. Increasing numbers of dental professionals perform oral implant treatment and are in need for recommendations to improve and manage the quality of implant therapy.

Mandibular overdentures have been extensively studied with respect to the number of implants, clinical items (including implant survival) and patients' satisfaction (Timmerman et al. 2004, Visser et al. 2005, Stoker et al. 2007, Meijer et al. 2009). Currently, a mandibular overdenture on two dental implants has evolved to the first choice of treatment for patients complaining about lack and stability of their mandibular denture (Feine et al. 2002, Raghoebar et al. 2011).

In contrast to the proven use of dental implants for mandibular overdentures, a consensus or treatment concept for implant-supported maxillary overdentures is lacking. It has been shown, however, that maxillary implant-supported overdentures can be considered a favourable treatment in cases of complaints about retention and stability of the upper denture (Visser et al. 2009). Next to a sufficient retention and stability of the maxillary overdenture, also proper phonetics, aesthetics and hygiene access can be reached with this approach. Such a favourable result often cannot be achieved in full with a fixed maxillary prosthesis (Naert et al. 1998). Amongst others, quality and volume of remaining maxillary bone, and number and position of implants have been reported as factors influencing success of implants and overdenture in the upper jaw (Esposito et al. 1998, Rodriguez et al. 2000), but there is a lack of randomized controlled trials to compare the outcome of specific questions related to number of implants and design of the superstructure (Payne et al. 2004, Roccuzzo et al. 2012). The various variables that might affect implant-survival combined with maxillary overdentures are not yet assessed in well-designed randomized controlled trials. So, with regard to implant-supported maxillary overdentures, there is a lack of evidence regarding which occlusion concept and which number of implants to apply as well as where to place the implants. Therefore, as part of the PhD research presented in this thesis, a number of randomized controlled trials was developed

assessing parameters as the number of dental implants (4 versus 6) and where to place the implants (anterior versus posterior) in the edentulous maxilla for implant-supported maxillary overdentures. Furthermore, as no research on implant-supported maxillary overdentures with an opposing natural dentition has been reported in the literature, a descriptive study was designed to assess the treatment outcome of maxillary overdentures supported by 6 dental implants, connected with a bar, either placed in the anterior or posterior maxilla.

With regard to implant-supported maxillary overdenture therapy, it is presumed that there is an advantage of placing implants in the anterior region when there is sufficient bone in this region for implant placement and enough space in the overdenture to cover the attachment system. Such an approach reduces treatment time and morbidity when compared to placement of implants in the posterior region. Furthermore, implants in the anterior maxillary region have a better access for oral hygiene maintenance. Unfortunately, the circumstances for implant placement are often not as favourable as described in the previous paragraph, because patients with problems of lack of retention and stability of their conventional maxillary overdenture often already have been edentulous for a long period. As a result, due to physiological resorption, there is often not enough bone to place implants in the anterior region. Thus, implants have to be placed in the posterior part of the maxilla in a considerable group of patients. This approach is often in need of being combined with or preceded by a bone augmentation procedure (maxillary sinus elevation surgery with, e.g., iliac crest bone). This treatment procedure means higher morbidity, hospitalization and treatment costs (Kalk et al. 1996, Raghoebar et al. 2001).

In other words, it has to be assessed which approach (implants in the anterior or posterior region) is most suitable for selected cases as well as which number of implants is needed for optimal treatment results. The latter is an important issue to study as it is presumed that the 6 bar-connected implants and 4 bar-connected implants approach to support a maxillary overdenture are equally effective (Sadowsky 2007).

Another issue that needs further study is whether antagonistic natural teeth pose a risk factor for implant-supported maxillary overdentures, which is

presumed, but not proven, in the limited number of studies addressing this issue (Ohkubu et al. 2010). The thought reason for antagonistic teeth being a risk factor for implant loss and denture problems is the greater mastication force and harmful lateral forces to implants exerted by the patients' antagonistic teeth (Chan et al. 1996, Åstrand et al. 1996, Kahnberg et al. 1999). The bilateral balanced occlusion concept of conventional removable dentures is commonly used in overdenture therapy (Carlsson 2009), but has to be adapted when antagonistic teeth are present. In the latter case, the occlusion is dictated by the anatomic form and (compromised) position of the natural teeth. As a general rule, it is advocated to apply an occlusal situation that is comfortable to the patient, stable and without interferences, rather than an occlusion guided by a preconceived philosophy of occlusion (Taylor et al. 2000).

General aim and outline of the thesis

The general aim of the research described in this thesis was to assess the performance of maxillary overdentures, supported by 4 or 6 dental implants in the anterior region of the maxilla with enough bone to place implants without or with a partial sinus elevation procedure with intra-oral bone or in the posterior region of the extremely resorbed maxilla after bone augmentation with bone harvested from the iliac crest, with regard to implant survival, overdenture survival, clinical scores, peri-implant bone height changes and patients' satisfaction. The specific aims were:

- to assess, by a systematic review of the literature on implant-supported maxillary overdentures, factors that determine the survival of implants and overdentures, and the condition of peri-implant soft and hard tissues (chapter 2);
- to assess, in a randomized controlled trial, the one year implant survival, overdenture survival, peri-implant health, peri-implant bone height changes and patients' satisfaction of maxillary overdentures supported by either 4 dental implants or 6 dental implants placed in the anterior part of the maxilla with enough bone to place implants without or combined with a partial sinus elevation procedure with intra-oral bone (chapter 3);
- to assess, in a randomized controlled trial, the one year implant survival, overdenture survival, peri-implant health, peri-implant bone height changes

and patients' satisfaction of maxillary overdentures supported by either 4 dental implants or 6 dental implants in the posterior part of the extremely resorbed maxilla preceded by a sinus elevation surgery procedure with bone harvested from the iliac crest (chapter 4);

- to assess, in a prospective case series study, implant survival, overdenture survival, peri-implant health, peri-implant bone height changes and patients' satisfaction of maxillary overdentures supported by 6 anteriorly placed without or combined with a partial sinus elevation surgery procedure with intra-oral bone or 6 posteriorly placed implants preceded by a sinus elevation surgery procedure with bone harvested from the iliac crest, opposed by natural antagonistic teeth in the mandible (chapter 5);
- to demonstrate a technique for the attachment of small clips to an overdenture base with metal reinforcement to prevent fracture and loosening of clips (chapter 6).

In chapter 7, the results of the various studies are interlinked and discussed in a broader perspective as well as that directions for future research are given.

References

- Åstrand, P., Nord, P.G., Brånemark, P.I. (1996) Titanium implants and onlay bone graft to the atrophic maxilla: a 3-year longitudinal study. *International Journal of Oral and Maxillofacial Surgery* 25, 25-29.
- Carlsson, G.E. (2009) Dental occlusion: modern concepts and their application in implant prosthodontics. *Odontology* 97, 8-17.
- Cehreli, M.C., Karasoy, D., Kokat, A.M., Akca, K., Eckert, S.E. (2010) Systematic review of prosthetic maintenance requirements for implant-supported overdentures. *International Journal of Oral and Maxillofacial Implants* 25, 163-180.
- Chan, M.F., Howell, R.A., Cawood, J.I. (1996) Prosthetic rehabilitation of the atrophic maxilla using pre-implant surgery and endosseous implants. *British Dental Journal* 181, 51-58.
- Esposito, M., Hirsch, J.M., Lekholm, U., Thomsen, P. (1998) Biological factors contributing to failures of osseointegrated oral implants. (I). Success criteria and epidemiology. *European Journal of Oral Sciences* 106, 527-551.
- Feine, J.S., Carlsson, G.E., Awad, M.A., Chehade A., Duncan W.J., Gizani S., Head T., Lund J.P., MacEntee M., Mericske-Stern R., Mojon P., Morais J., Naert I., Payne A.G., Penrod J., Stoker G.T. Jr., Tawse-Smith A., Taylor T.D., Thomason J.M., Thomson W.M., Wismeijer D. (2002) The McGill Consensus Statement on Overdentures. Montreal, Quebec, Canada. May 24-25, 2002. *International Journal of Prosthodontics* 15, 413-414.
- Kahnberg, K.E., Nilsson, P., Rasmusson, L. (1999) Le Fort I osteotomy with interpositional bone grafts and implants for rehabilitation of the severely resorbed maxilla: a 2-stage procedure. *International Journal of Oral and Maxillofacial Implants* 14, 571-578.
- Kalk, W.W., Raghoobar, G.M., Jansma, J., Boering, G. (1996) Morbidity from iliac crest bone harvesting. *Journal of Oral and Maxillofacial Surgery* 54, 1424-1429.
- Meijer, H.J., Raghoobar, G.M., Batenburg, R.H., Visser, A., Vissink, A. (2009) Mandibular overdentures supported by two or four endosseous implants: a 10-year clinical trial. *Clinical Oral Implants Research* 20, 722-728.
- Naert, I., Gizani, S. & Van Steenberghe, D. (1998) Rigidly splinted implants in the resorbed maxilla to retain a hinging overdenture: a series of clinical reports for up to 4 years. *Journal of Prosthetic Dentistry* 79, 156-164.
- Ohkubo, C., Baek, K.W. (2010) Does the presence of antagonistic remaining teeth affect implant overdenture success? A systematic review. *Journal of Oral Rehabilitation* 37, 306-312.
- Payne, A.G.T., Tawse-Smith, A., Thomson, W.M., Duncan W.D., Kumara R. (2004) One-stage surgery and early loading of three implants for maxillary overdentures: a 1-year report. *Clinical Implant Dentistry and Related Research* 6, 61-74.
- Raghoobar, G.M., Timmenga, N.M., Reintsema, H., Stegenga, B., Vissink, A. (2001) Maxillary bone grafting for the insertion of endosseous implants: results after 12-124 months. *Clinical Oral Implants Research* 12, 279-286.
- Raghoobar, G.M., Meijer, H.J., Stellingsma, K., Vissink, A. (2011) Addressing the atrophied mandible: a proposal for a treatment approach involving endosseous implants. *International Journal of Oral and Maxillofacial Implants* 26, 607-17.

Roccuzzo, M., Bonino, F., Gaudioso, L., Zwahlen, M., Meijer, H.J. (2012) What is the optimal number of implants for removable reconstructions? A systematic review on implant-supported overdentures. *Clinical Oral Implants Research* 23 (suppl. 6), 229-237.

Rodriguez, A.M., Orenstein, I.H., Morris, H.F. & Ochi, S. (2000) Survival of various implant-supported prosthesis designs following 36 months of clinical function. *Annals of Periodontology* 5, 101-108.

Sadowsky, S.J. (2007) Treatment considerations for maxillary implant overdentures: a systematic review. *Journal of Prosthetic Dentistry* 97, 340-348.

Stoker, G.T., Wismeijer, D. & Van Waas, M.A.J. (2007) An eight-year follow-up to a clinical trial of aftercare and cost-analysis with three types of mandibular implant-retained overdentures. *Journal of Dental Research* 86, 276-280.

Taylor, T.D., Belser, U., Merickske-Stern, R. (2000) Prosthodontic considerations. *Clinical Oral Implants Research* 11 (Suppl. 1), 101-107.

Timmerman, R., Stoker, G.T., Wismeijer, D., Oosterveld, P., Vermeeren, J.I., Van Waas, M.A. (2004) Patient satisfaction with implant-supported mandibular overdentures: a comparison of three different treatment strategies with ITI-dental implants in a randomized controlled clinical trial 8 years after treatment. *Journal of Dental Research* 83, 630-633.

Visser, A., Raghoobar, G.M., Meijer, H.J., Batenburg, R.H., Vissink, A. (2005) Mandibular overdentures supported by two or four endosseous implants. A 5-year prospective study. *Clinical Oral Implants Research* 16, 19-25.

Visser, A., Raghoobar, G.M., Meijer, H.J.A., Vissink, A. (2009) Implant-retained maxillary overdentures on milled bar suprastructures: a 10-year follow-up of surgical and prosthetic care and aftercare. *International Journal of Prosthodontics* 22, 181-192.

Chapter 2

**A systematic review
of implant-supported
maxillary overdentures
after a mean observation
period of at least 1 year**

This chapter is an edited version of the manuscript.

Slot, W., Raghoobar, G.M., Vissink, A., Huddleston Slater, J.J., Meijer, H.J. (2010).

A systematic review of implant-supported maxillary overdentures after a mean observation period of at least 1 year.

Journal of Clinical Periodontology 37, 98-110.

Abstract

Aim

The aim of the present systematic review of implant-supported maxillary overdentures is to assess survival of implants, survival of maxillary overdentures and condition of surrounding hard and soft tissues after a mean observation period of at least one year.

Materials and methods

Medline (1950-August 2009), EMBASE (1966-August 2009) and CENTRAL (1800-August 2009) were searched to identify eligible studies. Two reviewers independently assessed the articles.

Results

Out of 147 primarily selected articles, 31 studies fulfilled the inclusion criteria. A meta-analysis showed an implant survival rate of 98.2% per year in case of 6 implants and a bar anchorage. In case of 4 implants and a bar anchorage the implant survival rate was 96.3% per person. In case of 4 implants and a ball anchorage the implant survival rate was 95.2% per year.

Conclusion

In all three treatment options the survival rate of the implants is more than 95%. The included studies reveal that a maxillary overdenture, supported by 6 dental implants, which are connected with a bar, is the most successful treatment regarding survival of both the implants and overdenture. Second in line is the treatment option with 4 implants and a bar. The treatment option with 4 or less implants and a ball attachment system is the least successful.

Introduction

Mandibular overdentures have been extensively studied with respect to number of implants, a variety of clinical items (including implant survival) and patient satisfaction (Meijer et al. 2003, Timmerman et al. 2004, Visser et al. 2005, Stoker et al. 2007). For the majority of patients an overdenture on two implants is the first choice of treatment when complaining about lack and stability of their mandibular denture (Batenburg et al. 1998, Feine et al. 2002). However, on implant-supported maxillary overdentures consensus or a treatment concept is lacking, although maxillary overdentures can be considered a favourable treatment in cases of insufficient bone volume and complaints about retention and stability of the full denture (Visser et al. 2009). Next to sufficient retention and stability, also proper phonetics, aesthetics and hygiene access can be reached with an implant-supported maxillary overdenture. The latter is often not possible with a fixed maxillary prosthesis (Naert et al. 1998). Different numbers of implants to support the maxillary overdenture and different designs of used anchorage systems are reported (Rodriquez et al. 2000). In addition, there is a lack of randomized controlled trials to compare the outcome of specific questions related to number of implants or design of the superstructure (Payne et al. 2004). Systematic reviews are an appropriate method to explore the outcome of studies (Egger et al. 2001). In a recent systematic review, Sadowsky (2007) evaluated maxillary implant-supported overdentures with emphasis on number of implants and anchorage design. He concluded that a number of 4 implants was the minimum to support a maxillary overdenture and recommended 6 implants in case of compromised bone. Moreover, he could not detect a difference between the treatment outcome of splinted and unsplinted implants in the literature he assessed. There was no explicit search on performed bone graft procedures, implant systems, opposing dentition, survival rates of the overdentures, radiographic bone loss and several clinical items. Finally, a meta-analysis has never been reported on study results concerning implant-supported maxillary overdentures. Therefore, the aim of the present systematic review of implant-supported maxillary overdentures is to assess survival of implants, survival of maxillary overdentures and condition of surrounding hard and soft tissues after a mean observation period of at least one year.

Material and methods

Design of the study and search strategy

Although randomized controlled trials (RCTs) provide high evidence in comparing effectiveness of different therapies, relevant information is not exclusively provided by RCTs. Well-designed cohort-studies and case series may also provide valuable information. Therefore, these types of studies were considered for evaluation too. Moreover, no time restrictions were implemented with respect to year of publication.

A thorough search of the literature was conducted in databases of MEDLINE (1950- August 2009) (via PUBMED) and EMBASE (1966- August 2009). The search was supplemented with a systematic search in the Cochrane Central Register of Controlled Trials' (CENTRAL) (1800-August 2009). The search strategy was a combination of MeSH terms (table 1). The search was completed by checking references of the relevant review articles and eligible studies for additional useful publications. Full-text documents were obtained for all articles meeting the inclusion criteria. Full text analysis was performed by two reviewers (WS, HM) independently. Methodological quality was assessed independently by the reviewers using specific study-design related modified forms designed by the Dutch Cochrane Collaboration (Den Hartog et al. 2008). In case of disagreement, consensus was reached by discussion, if necessary in consultation with a third reviewer (GR).

Criteria for a paper to be included in the study selection were:

- publications must be reporting in the English dental literature
- detailed information on maxillary overdentures supported by root-form endosseous implants; in case of combined data for implant-supported removable overdentures and implant-supported fixed full dentures extraction of data for the overdenture must be eligible;
- treatment of the patients has to be initially planned for an overdenture;
- at least five patients should be described in a paper
- the follow-up period should be at least one year

Table I Search strategy.

#1 Search “Denture, Overlay” [MeSH]
#2 Search “Dental Prosthesis, Implant supported” [MeSH]
#3 Search “Dental Implants” [MeSH]
#4 Search “Dental Implantation, Endosseous” [MeSH]
#5 Search “Mouth, Edentulous” [MeSH]
#6 Search “Jaw, Edentulous” [MeSH]
#7 Search “Maxilla” [MeSH]
#8 Search #2 or #3 or #4
#9 Search #5 or #6
#10 Search #1 and #7 and #8 and #9
Run data search: August 1, 2009

Outcome measures

The following outcome measures were assessed:

- survival of implants
- survival of maxillary overdentures
- condition of surrounding hard and soft tissues surrounding the implants

Data extraction

Outcome measures were extracted by two reviewers (WS, HM) independently and recorded in a data sheet. Agreement was reached by consensus discussion and if necessary a third reviewer (GR) was consulted. A meta-analysis was carried out for outcome measures that could be meaningfully combined.

Statistical analysis

For the meta-analysis the statistical software package “Meta-analysis” was used (Comprehensive Meta-analysis Version 2.2, Biostat, Englewood, NJ 2005). For the calculation of the overall effects for the included studies, weighted rates together with random effect models were used.

Results

Description of the studies

The MEDLINE search provided 92 hits, the EMBASE search 7 hits and the CENTRAL search 38 hits. Seven articles appeared to be double. After scanning of titles and abstracts, it was decided to select them all for evaluation as full text article, as the abstracts did not always give a clear insight in the method of the study and the number of hits was reasonable to assess. This way no article was excluded on beforehand. Reference-checking of relevant reviews and included studies revealed 17 additional articles to be screened. This approach resulted in 147 articles to be evaluated by full text analysis. Three articles of these 147 were excluded because they were not in the English language. Next, 46 articles were excluded because no patients at all or less than 5 patients were described in those studies. In addition, 62 articles were excluded because there was no detailed information available on maxillary overdentures as a separate treatment. Two articles were excluded because the treatment with implants was not initially planned for an overdenture. Finally, three articles were excluded because the follow-up was less than one year. In the study of Palmqvist et al. (1994) a planned group and an emergency group were described. The patients in the emergency group were not originally planned for an overdenture but a fixed prosthesis was not possible anymore due to loss of implants. It was decided to include the planned group in the review and to remove the results from the emergency group. The studies of Watson et al. (1997) and Jemt et al. (1996) were suspect to present the same study population. This was however not clearly stated and for this reason doubtful. These studies would deliver the same data for the meta-analysis. For this reason it was decided to keep the most recent manuscript (Watson et al. 1997). However, both studies were saved for the tables, because, next to survival, the focus was on different evaluation items. A total of 31 articles fulfilled the inclusion criteria and passed the quality assessment. Figure 1 outlines the algorithm of the study selection procedure. Characteristics of the included studies are depicted in table 2. Two studies were randomized controlled trials (RCTs). In the study of Payne et al. (2004) two different implant systems were analyzed and in the article of Bergendal & Engquist (1998)

Figure 1 Algorithm of study selection procedure.

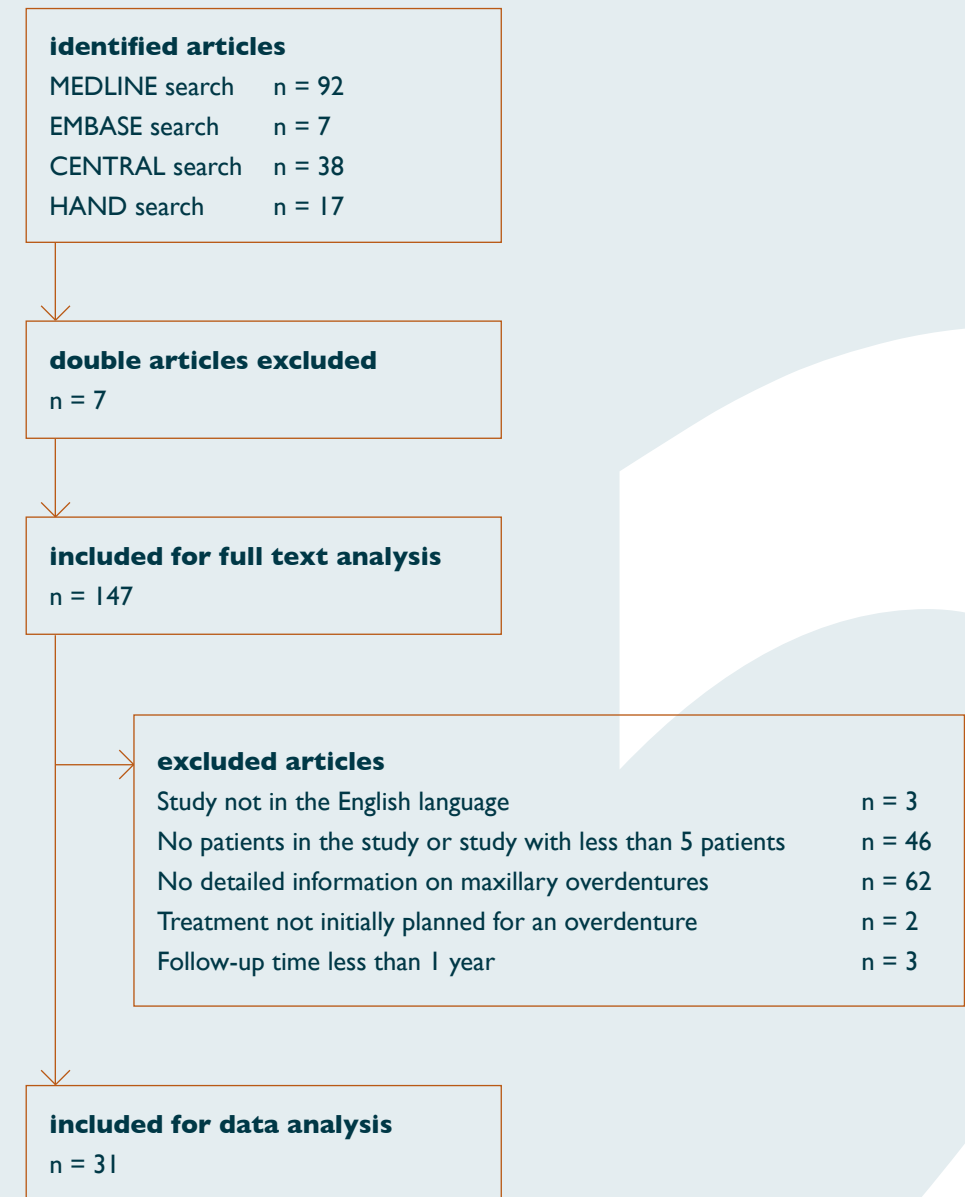


Table 2 Characteristics of included studies.

study	year of publication	study design	follow-up in months	no. of patients in study
Sanna et al.	2009	Retrospective bar group 4-6 implants	84	32
		Retrospective ball group 2 implants	180	8
Visser et al.	2009	Retrospective	120	39
Raghoobar et al.	2006	Prospective	22	8
Raghoobar et al.	2005	Prospective	20	5
Widbom et al.	2005	Retrospective	60	13
Payne et al.	2004	Randomized Controlled Trial Brånemark	12	20
		Randomized Controlled Trial Southern	12	19
Raghoobar et al.	2003	Prospective	12	10
Ferrigno et al.	2002	Prospective	120	35
Fortin et al.	2002	Retrospective	60	45
Mericske-Stern et al.	2002	Retrospective	49	41
Kiener et al.	2001	Retrospective	38	41
Närhi et al.	2001	Retrospective	27	16
Rodriguez et al.	2000	Retrospective	36	100
Zitzmann & Marinello	2000	Prospective	12	10
Zitzmann & Marinello	2000	Prospective	27	10
Keller et al.	1999	Retrospective	81	13
Smedberg et al.	1999	Retrospective pilot group	82	20
		Retrospective routine group	35	14
Bergendal & Engquist	1998	Randomized Controlled Trial bar group	60	10
		Randomized Controlled Trial ball group	50	8
Kaptein et al.	1998	Retrospective	70	35
Naert et al.	1998	Prospective	48	13
Watzek et al.	1998	Retrospective	39	15
Eckfeldt et al.	1997	Retrospective	30	7
Watson et al.	1997	Prospective	60	30
Jemt et al.	1996	Prospective	60	30
Hutton et al.	1995	Prospective	36	30
Jemt & Lekholm	1995	Retrospective	60	33
Jemt et al.	1994	Prospective	12	6
Palmqvist et al.	1994	Retrospective	40	19
Smedberg et al.	1993	Retrospective	24	20
Johns et al.	1992	Prospective	12	30
Krämer et al.	1992	Retrospective	19	11

the difference between a bar and a ball anchorage design was studied. The remaining 29 studies described in fact retrospectively or prospectively analyzed case series. The number of patients in the studies varied from five patients (Raghoobar et al. 2005) to 100 patients (Rodriguez et al. 2000). The follow-up period varied from 12 months (Johns et al. 1992, Jemt et al. 1994, Zitzmann & Marinello 2000a, Raghoobar et al. 2003, Payne et al. 2004) to 180 months (Sanna et al. 2009). Table 3 summarizes the treatment procedures of the included studies. The number of implants placed to support the overdenture varied from one implant to eight implants. Onlay block graft procedures and elevation of the floor of the maxillary sinus were carried out in some studies, but also implant insertion without bone graft procedures was described. The position of the implants, in relation with the availability of a bone volume sufficient to reliably insert endosseous implants was often not well described. Different implant systems were used; the majority were Brånemark implants. As anchorage system both splinted (bar) and unsplinted (ball) designs were used. With 6 and more implants the anchorage design was splinted in all cases. With 4 or less implants both designs were used. In the majority of the studies the kind of opposing dentition was not described; other studies described that there were all kinds of opposing dentition. Only in the RCT of Payne et al. (2004), it was mentioned that all patients had a two-implant overdenture in the mandible. Table 4 gives the outcomes of the included studies. Because of the methodological diversity of the studies only number of implants, anchorage design, survival of implants and survival of the overdenture could be meaningfully combined in a meta-analysis. It was chosen to include 6 or more implants and 4 or less implants in the meta-analysis to have a clear distinction between these two groups. Statistical heterogeneity of the group with 6 or more implants and a bar is Cochran's $Q = 9.77$ ($df = 6$), $I^2 = 38.611$. For 4 implants or less and a bar it is Cochran's $Q = 6.15$ ($df = 3$), $I^2 = 51.237$. For 4 implants or less and a ball it is Cochran's $Q = 4.27$ ($df = 2$), $I^2 = 53.167$. In table 5 and figures 2, 3 and 4 the results of the weighted meta-analysis, expressed as event rates per year, are presented. Event rates were used to describe failures and were calculated by the ratio of the number of failures or complications (e.g. events) to the total exposure time of the construction.

Table 3 Treatment procedures in included studies.

= no (detailed) information provided

study	year of publication	implants per patient	bone graft procedure	implant system	anchorage design	opposing dentition
Sanna et al.	2009	4–6	yes/no	Brånemark	Bar	All kinds of opposing dentition
Visser et al.	2009	2	no	Brånemark	Ball	All kinds of opposing dentition
		6	sinusfloor augmentation	Brånemark	Bar	Complete denture, implant supported overdenture or natural dentition
Raghoobar et al.	2006	6–8	sinusfloor augmentation and onlay block	Brånemark	Bar	#
Raghoobar et al.	2005	6	sinusfloor augmentation	Brånemark	Bar	#
Widbom et al.	2005	4	no	Brånemark	Bar	#
Payne et al.	2004	3	no	Brånemark	Ball	Two implant overdenture
		3	no	Southern implant system	Ball	Two implant overdenture
Raghoobar et al.	2003	6–8	sinusfloor augmentation	Osseotite (3i)	Ball	Complete denture, implant supported overdenture or removable partial denture
Ferrigno et al.	2002	4–6	some	ITI	Bar	#
Fortin et al.	2002	3–7	no graft procedures	Brånemark	Bar	#
Mericske-Stern et al.	2002	4–6	no graft procedures	ITI	Bar	All kinds of opposing dentition
Kiener et al.	2001	4–6	none	ITI	Bar and Ball	All kinds of opposing dentition
Närhi et al.	2001	2–6	yes/no	Brånemark and IMZ	Bar and Ball	All kinds of opposing dentition
Rodriguez et al.	2000	5–6	#	#	Bar	#
					Bar	#
Zitzmann & Marinello	2000 a	6–8	#	#	Bar	#
Zitzmann & Marinello	2000 b	6–8	no graft procedures	Brånemark	Bar	#
Keller et al.	1999	3–6	onlay block bone graft	Brånemark	Bar and Ball	All kinds of opposing dentition
Smedberg et al.	1999	#	no	Brånemark	Bar	#
		#	partly bone grafts	Brånemark	Bar	#
Bergendal & Engquist	1998	2–5	no	Brånemark	Bar	All kinds of opposing dentition
		2–3	no	Brånemark	Ball	All kinds of opposing dentition
Kaptein et al.	1998	#	yes	IMZ	#	#
Naert et al.	1998	4	no	Brånemark	Bar	All kinds of opposing dentition
Watzek et al.	1998	6–8	sinusfloor augmentation	Frialen and IMZ	Bar	All kinds of opposing dentition
Ekfeldt et al.	1997	1–4	no	Brånemark	Bar and Ball	#
Watson et al.	1997	3–4	#	Brånemark	Bar	Natural teeth or implant supported prosthesis
Jemt et al.	1996	3–4	#	Brånemark	Bar	Natural teeth, implant supported prosthesis or conventional denture
Hutton et al.	1995	#	no	Brånemark	Bar	All kinds of opposing dentition
Jemt & Lekholm	1995	#	no	Brånemark	Bar	#
Jemt et al.	1994	4–6	#	Brånemark	Bar	#
Palmqvist et al.	1994	2–4	no	Brånemark	Bar	All kinds of opposing dentition
Smedberg et al.	1993	2–6	no	Brånemark	Bar	#
Johns et al.	1992	#	no	Brånemark	Bar	All kinds of opposing dentition
Krämer et al.	1992	6	#	IMZ	Bar	#

Table 4 Outcomes in included studies.

= no (detailed) information provided

study	year of publication	number of implants in study	number of lost implants	number of lost patients in study	survivalrate implants (%)	survivalrates overdentures (%)	change in mean marginal bonelevel ± SD (mm)	gingival index (mean (SD))	bleeding index (mean (SD))	Probing depth (mm) (mean (SD))
Sanna et al.	2009	138	1	0	99.2	#	#	#	#	3.3
		16	3	0	73.5	#	#	#	#	3.6
Visser et al.	2009	252	35	0	86.1	74.4	#	#	#	#
Raghoobar et al.	2006	56	0	0	100	100	#	#	#	#
Raghoobar et al.	2005	30	1	0	96.7	100	#	#	#	#
Widbom et al.	2005	53	13	0	77	100	#	#	#	#
Payne et al.	2004	60	5	0	92	#	#	#	#	#
		57	10	1	82	#	#	#	#	#
Raghoobar et al.	2003	68	3	0	95.6	100	0.3 (0.7)	0.5 (0.7)	0.7 (0.9)	3.4 (1.3)
Ferrigno et al.	2002	114	3	#	92.2 Milled bar	94.7 Milled bar	#	#	#	#
		64	6	#	86.9 Dolder bar	87.5 Dolder bar	#	#	#	#
Fortin et al.	2002	245	7	6	97.0	100	#	#	#	#
Mericske-Stern et al.	2002	173	9	0	94.2	97.6	0.7	#	#	2.9 (0.8)
Kiener et al.	2001	173	8	0	95.5	95	#	#	#	#
Närhi et al.	2001	88	8	#	90	#	0.23	#	0.7	2.8
Rodriguez et al.	2000	#	#	#	94.6	#	#	#	#	#
		#	#	#	86.7	#	#	#	#	#
		#	#	#	81.8	#	#	#	#	#
Zitzmann & Marinello	2000 a	#	#	0	#	#	#	#	#	#
Zitzmann & Marinello	2000 b	71	4	0	94.4	100	0.92	54% (SD 26%)	#	#
Keller et al.	1999	70	17	2	76	77	#	#	#	#
Smedberg et al.	1999	86	14	6	83.7	75	0.97	#	4%	#
		68	10	0	85.3	100	1.29	#	6%	#
Bergendal & Engquist	1998	29	6	#	79	90	1.25	#	#	#
		18	7	#	61	88	1.0	#	#	#
Kaptein et al.	1998	162	29	0	82.1	#	#	#	#	#
Naert et al.	1998	53	6	6	88.6	85	0.5	#	0.2 (0.7)	3.6 (0.9)
Watzek et al.	1998	115	6	0	95	100	#	#	#	#
Eckfeldt et al.	1997	19	2	0	84.3	85.7	#	#	#	#
Watson et al.	1997	117	30	14	72.4	77.9	#	#	#	#
Jemt et al.	1996	117	30	14	72.4	77.9	0.8 (0.8)	#	#	#
Hutton et al.	1995	117	29	#	72.4	72.4	#	#	#	#
Jemt & Lekholm	1995	127	36	3	71.6	81.2	0.89	#	#	#
Jemt et al.	1994	32	0	0	100	100	Mesial side 0.30 (0.25) Distal side 0.34 (0.11)	#	#	#
Palmqvist et al.	1994	59	4	0	93.2	100	#	#	#	#
Smedberg et al.	1993	86	7	0	86	90	0.71	#	#	#
Johns et al.	1992	117	21	5	82.2	86.3	0.5	#	#	#
Krämer et al.	1992	66	4	#	94	100	2.45	#	#	0.21

Table 5 Stratified meta-analysis of implant survival and overdenture survival.

* in only one study the loss of overdentures was reported; not possible to carry out a meta-analysis

treatment	number of studies included	number of patients/ implants	mean follow-up in years	number of implants that not survived	calculated loss of implants per year per person (event rate; 95% CI)	number of overdentures that not survived	calculated loss of overdentures per year (event rate; 95% CI)
6 or more implants with a bar anchorage design	7	98/ 658	4.5	53	0.018 (0.014 – 0.023)	10	0.026 (0.015 – 0.044)
6 or more implants with a ball anchorage design	0	-	-	-	-	-	-
4 or less implants with a bar anchorage design	4	75/ 934	4.4	53	0.037 (0.030 – 0.046)	9	0.035 (0.022 – 0.069)
4 or less implants with a ball anchorage design	3	55/ 151	3.7	23	0.048 (0.032 – 0.070)	-	not possible*

Figure 2 Meta-analysis of implant loss in case of 6 implants and bar superstructure.

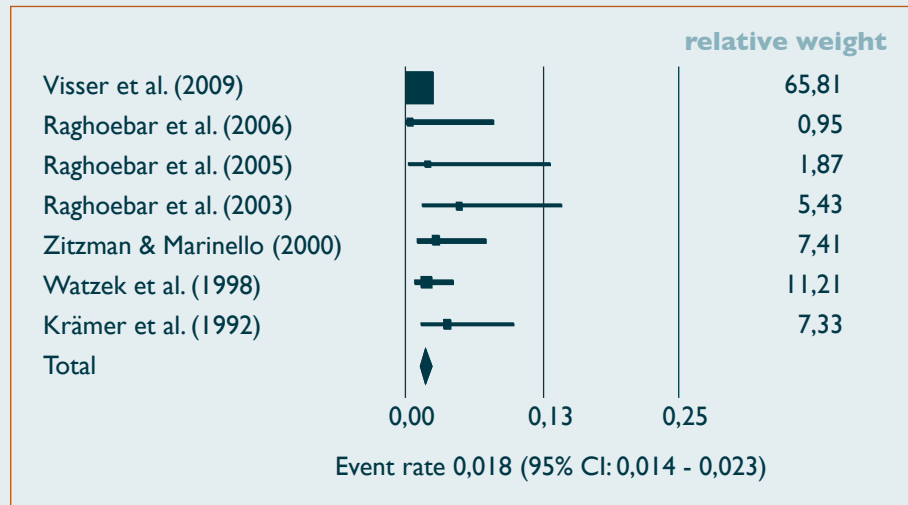


Figure 4 Meta-analysis of implant loss in case of 4 implants and ball superstructure.

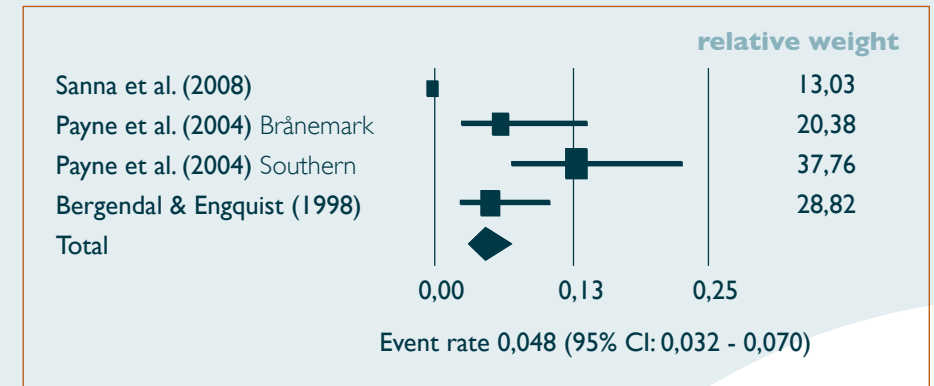
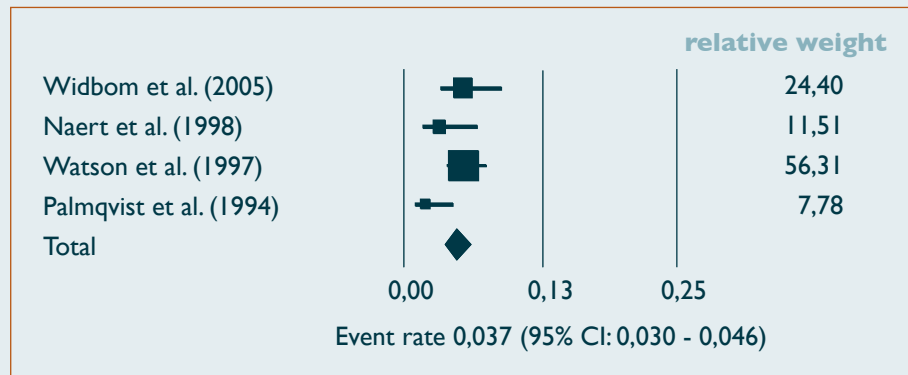


Figure 3 Meta-analysis of implant loss in case of 4 implants and bar superstructure.



The exposure time was the time the implants or the overdenture was followed. Distinct event rates were calculated for both implants and dentures. In case of a failure of implants or dentures that were lost during the observation time, time to the event was used for the analysis. The survival rate (SR) is the complement of the event rate (ER), and was calculated as $SR=1-ER$.

Survival of implants

Implant survival was defined as the percentage of implants initially placed that was still present at follow-up. In total, 3116 implants were placed in 796 patients, whereas in two studies (Rodríguez et al. 2000, Zitzmann & Marinello 2000) the number of implants was not mentioned (in totally 110 patients). The survival rate of the implants varied from 100% (Jemt et al. 1994 and Raghoobar et al. 2006) to 61% (Bergendal & Engquist 1998). Results of the weighted meta-analysis of implant loss, expressed as event rates, are shown in table 5. The event rate for implant loss in case of 6 or more implants and a bar anchorage was 0.018, which can be expressed as a survival rate of 98.2% per year. The event rate for implant loss in case of 4 or less implants and a bar anchorage was 0.037, which can be expressed as a survival rate of 96.3% per year. The event rate for implant loss in case of 4 or less implants and a ball anchorage was 0.048, which can be expressed as a survival rate of 95.2% per year.

Survival of maxillary overdentures

Survival of maxillary overdentures was defined as the percentage of overdentures initially placed that was still present at follow-up. The survival rate of the overdentures varied from 100% (Krämer et al. 1992, Palmqvist et al. 1994, Jemt et al. 1994, Watzek et al. 1998, Smedberg et al. 1999, Zitzmann & Marinello 2000b, Fortin et al. 2002, Raghoobar et al. 2003, Widbom et al. 2005, Raghoobar et al. 2005 and Raghoobar et al. 2006) to 72.4% (Hutton et al. 1995). Results of the weighted meta-analysis (for person-years and for study size) of overdenture loss, expressed as event rates, are shown in table 5. The event rate for overdenture loss in case of 6 or more implants and a bar anchorage was 0.026, which can be expressed as a survival rate of 97.4% per year. The event rate for overdenture loss in case of

4 or less implants and a bar anchorage was 0.035, which can be expressed as a survival rate of 96.5% per year. The event rate for overdenture loss in case of 4 or less implants and a ball anchorage could not be calculated because only in one study the survival rate of the overdentures was mentioned (Bergendal & Engquist 1998: survival rate overdentures 88%).

Condition of surrounding hard and soft tissues

In 14 out of the 31 studies a change in mean marginal bone level was mentioned. Measurements were done on either non-standardized rotational panoramic radiographs and intra-oral radiographs, or on standardized intra-oral radiographs. The loss of marginal bone varied from 0.23 mm in 27 months to 2.45 mm in 19 months. In two studies the condition of the peri-implant mucosa was mentioned, both with a different index. In 4 studies bleeding on probing was noted. Finally, in 6 studies probing depth was mentioned, varying from 0.21 mm in the study of Krämer et al. (1992) to 3.6 mm in the studies of Naert et al. (1998) and Sanna et al. (2009).

Discussion

This systematic review assessed the outcome of implant-supported maxillary overdentures in terms of survival of implants, survival of maxillary overdentures, condition of surrounding hard and soft tissues, technical complications and patient satisfaction. “Success” is a better outcome measure (if the same criteria are used) than “survival”. However, only “survival” has been reported in the analysed literature. Despite of this shortcoming, it has been chosen to perform the analysis with the “survival” data. On basis of these outcome parameters, it was tried to select the treatment concept for the edentulous upper jaw with implant-supported overdentures that is in favour over other concepts published in the literature with respect to number of implants and the kind of attachment system. Unfortunately, we could not draw firm conclusions regarding the most preferable treatment strategy, due to lack of controlled clinical trials and the limited number of studies suitable for the meta-analysis.

Due to different implant systems used, different number of implants placed in the maxilla to support the overdenture, different surgical procedures applied, different anchorage designs used and differences in opposing dentition it is hard to calculate reliable figures for survival of implants. E.g., the survival rate might be related to the type of endosseous implant placed as both implants with a machined surface (especially in the studies from the early ninety's) and implants with a roughened surface were used. Also the number of implants used to support the maxillary overdenture could affect the survival rate because forces on the overdenture have to be carried by the bone surrounding the implants. With more implants, the forces are distributed on more bone. Moreover, a variety of surgical procedures was used either with or without bone grafts and/or bone substitutes. Not only the number of implants placed, but also the design of the anchorage system might affect the survival rate because the loading of surrounding bone is dependent on the anchorage system used. If a bar between implants is loaded, the load is mainly distributed to the bone surrounding the two neighbouring implants. In case of solitary attachments (ball attachments), the load is distributed to the surrounding bone of that one implant (Meijer et al. 1992). Finally, the kind of opposing dentition could have an effect

on survival of implants because the kind of occlusion is different. With an edentulous occlusion concept, there is a balanced tooth contact and evenly distributed forces on the overdenture, while with a (partially) dentate mandible, an occlusion concept with evenly distribution of the forces on the overdenture is often not possible to achieve. This means that there is also no evenly distribution of forces on the bone surrounding the implants.

It is striking that there is such a wide range in survival rates between studies. The study with the lowest survival rate used 2-3 implants to support the overdenture and the implants were not splinted with a bar, while studies reporting high survival rates commonly used 4 or more implants per patient and the implants were splinted with a bar. Comparison with the survival rates of implants to support an overdenture in the mandible shows much better data for the mandibular overdenture, most studies reporting survival rates of implants of 95% and higher (Feine et al. 2002). Most of these studies report survival rates of implants of 95% or higher. These higher rates can be addressed to the much better bone quality in the lower jaw compared to the upper jaw.

For the meta-analysis, it was chosen to include 6 or more implants and 4 or less implants to have a clear distinction between two groups. The event rate for implant loss in case of 6 or more implants and a bar anchorage was 0.018, which can be expressed as a survival rate of 98.2% per year. The event rate for implant loss in case of 4 or less implants and a bar anchorage was 0.037, which can be expressed as a survival rate of 96.3% per year. The event rate for implant loss in case of 4 or less implants and a ball anchorage was 0.048, which can be expressed as a survival rate of 95.2% per year. It must be noted that the total number of patients is not that much in this meta-analysis. Also, kind of implant system, surgical procedure and kind of opposing dentition were not accounted for. In the group of 6 implants and more in the majority of cases 6 implants were present. In the groups with 4 implants or less in the majority of cases 4 implants were present. Therefore, it was chosen to present the conclusions in terms of 6 implants and 4 implants. The survival rate is more than 95% for all three treatment options. Although there is a small difference in survival rates, one could conclude that a maxillary overdenture, supported by 6 dental implants, which are connected with a bar, is the most successful treatment regarding survival of

both the implants and overdenture. Second in line is the treatment option with 4 implants and a bar. The treatment option with 4 or less implants and a ball attachment system is the least successful.

Survival of the overdenture is a very important item for the patient. One of the implants may get lost, but as long as the overdenture functions there is no acute problem. This is understandable from the patients view. The patient asks for help because of a denture with lack of retention and stability; as long as the overdenture functions and gives no pain, the treatment is a success. Survival rate of overdentures was measured in 25 of the 31 selected studies. The survival rate varied from 100% to 72.4%. In 15 of the studies the survival rate was 90% or more. Of course there are more reasons to decide to make a new overdenture, but loss of implants is certainly an important one. There is a rationale that with less inserted implants, in case of loss, the overdenture is more prone to large revisions or remake than with more inserted implants. Analyzing the studies this is confirmed: there seemed to be a correlation between loss of overdentures and the number of implants per patient. The weighted meta-analysis (for person-years and for study size) of overdenture loss revealed a low event rate for both groups with a bar anchorage. It must be noted, however, that the total number of patients is not that much in this meta-analysis. Again, the results of the meta-analysis seem to be in favour from a perspective of cost-effectiveness to use 4 implants and a bar to support a maxillary overdenture. The condition of hard tissues can be analyzed with radiographs. As progressive marginal bone loss is a predictor for future implant loss, it is very important to analyze this marginal bone level in a standardized and reliable way. Changes are small and depiction of implant and surrounding bone is often very difficult. Only in the two RCTs (Bergendal & Engquist 1998, Payne et al. 2004) an attempt was made to standardize the intra-oral radiographs. In the other studies it was not uncommon to use panoramic radiographs, whilst it is known that a clear depiction of bone in the (frontal part of the) maxilla is very difficult on these type of radiographs. Due to the different kind of radiographs it was not possible to give an overall insight in marginal bone stability or progressive bone loss. Mucosa indices, bleeding indices and pocket probing depth gave insight into the health of the peri-implant soft tissues. In the studies covering this aspect, the soft tissues

appear relatively healthy.

Finally, besides of the low number of RCTs yet available in the literature, a major drawback of the reviewed literature is the variety in methods used to analyze a patient population. Guidelines should be developed (perhaps through a consensus meeting), published and recommended to investigators who are involved in clinical implant-related dentistry.

Conclusion

In all three treatment options the survival rate of the implants is more than 95%. The included studies reveal that a maxillary overdenture, supported by 6 dental implants, which are connected with a bar, is the most successful treatment regarding survival of both the implants and overdenture. Second in line is the treatment option with 4 implants and a bar. The treatment option with 4 or less implants and a ball attachment system is the least successful.

References

- Batenburg, R.H., Meijer, H.J., Raghoobar, G.M. & Vissink A. (1998) Treatment concept for mandibular overdentures supported by endosseous implants: a literature review. *International Journal of Oral and Maxillofacial Implants* 13, 539-545.
- Bergendal, T. & Engquist, B. (1998) Implant-supported overdentures: a longitudinal prospective study. *International Journal of Oral and Maxillofacial Implants* 13, 253-262.
- Den Hartog, L., Huddleston Slater, J.J.R., Vissink, A., Meijer, H.J.A. & Raghoobar, G.M. (2008) Treatment outcome of immediate, early and conventional single-tooth implants in the aesthetic zone: a systematic review to survival, bone level, soft tissue, aesthetics and patient satisfaction. *Journal of Clinical Periodontology* 35, 1073-1086.
- Egger, M., Smith, G.D. & Sterne, J.A. (2001) Uses and abuses of meta-analysis. *Clinical Medicine* 1, 478-484.
- Ekfeldt, A., Johansson, L.A. & Isaksson, S. (1997) Implant-supported overdenture therapy: a retrospective study. *International Journal of Prosthodontics* 10, 366-374.
- Feine, J.S., Carlsson, G.E., Awad, M.A., Chehade A., Duncan W.J., Gizani S., Head T., Lund J.P., MacEntee M., Mericske-Stern R., Mojon P., Morais J., Naert I., Payne A.G., Penrod J., Stoker G.T. Jr., Tawse-Smith A., Taylor T.D., Thomason J.M., Thomson W.M., Wismeijer D. (2002) The McGill Consensus Statement on Overdentures. Montreal, Quebec, Canada. May 24-25, 2002. *International Journal of Prosthodontics* 15, 413-414.
- Ferrigno, N., Laureti, M., Fanali, S. & Grippaudo G. (2002) A long-term follow-up study of non-submerged ITI implants in the treatment of totally edentulous jaws. Part I: Ten-year life table analysis of a prospective multicenter study with 1286 implants. *Clinical Oral Implants Research* 13, 260-273.
- Fortin, Y., Sullivan, R.M. & Rangert, B.R. (2002) The Marius implant bridge: surgical and prosthetic rehabilitation for the completely edentulous upper jaw with moderate to severe resorption: a 5-year retrospective clinical study. *Clinical Implant Dentistry and Related Research* 4, 69-77.
- Hutton, J.E., Heath, M.R., Chai, J.Y., Harnett, J., Jemt, T., Johns, R.B., McKenna, S., McNamara, D.C., Van Steenberghe, D., Taylor, R., (1995) Factors related to success and failure rates at 3-year follow-up in a multicenter study of overdentures supported by Brånemark implants. *International Journal of Oral and Maxillofacial Implants* 10, 33-42.
- Jemt, T., Book, K., Lie, A. & Börjesson, T. (1994) Mucosal topography around implants in edentulous upper jaws. Photogrammetric three-dimensional measurements of the effect of replacement of a removable prosthesis with a fixed prosthesis. *Clinical Oral Implants Research* 5, 220-228.
- Jemt, T. & Lekholm U. (1995) Implant treatment in edentulous maxillae: a 5-year follow-up report on patients with different degrees of jaw resorption. *International Journal of Oral and Maxillofacial Implants* 10, 303-11.
- Jemt, T., Chai, J., Harnett, J., Heath, M.R., Hutton, J.E., Johns, R.B., McKenna, S., McNamara, D.C., Van Steenberghe, D., Taylor, R., Watson, R.M. & Herrmann I. (1996) http://www.ncbi.nlm.nih.gov/pubmed/8752550?ordinalpos=673&itool=EntrezSystem2.PEntrez.Pubmed.Pubmed_ResultsPanel.Pubmed_RVDocSum A 5-year prospective multicenter follow-up report on overdentures

supported by osseointegrated implants. *International Journal of Oral and Maxillofacial Implants* 11, 291-298.

Johns, R.B., Jemt, T., Heath, M.R., Hutton, J.E., McKenna, S., McNamara, D.C., Van Steenberghe, D., Taylor, R., Watson, R.M. & Herrmann, I. (1992) A multicenter study of overdentures supported by Brånemark implants. *International Journal of Oral and Maxillofacial Implants* 7, 513-522.

Kaptein, M.L., De Putter, C., De Lange, G.L. & Blijdorp, P.A. (1998) Survival of cylindrical implants in composite grafted maxillary sinuses. *Journal of Oral Maxillofacial Surgery* 56, 1376-1380.

Keller, E.E., Tolman, D.E. & Eckert, S. (1999) Surgical-prosthetic reconstruction of advanced maxillary bone compromise with autogenous onlay block bone grafts and osseointegrated endosseous implants: a 12-year study of 32 consecutive patients. *International Journal of Oral and Maxillofacial Implants* 14, 197-209.

Kiener, P., Oetterli, M., Mericske, E. & Mericske-Stern R. (2001) Effectiveness of maxillary overdentures supported by implants: maintenance and prosthetic complications. *International Journal of Prosthodontics* 14, 133-140.

Krämer, A., Weber, H. & Benzing, U. (1992) Implant and prosthetic treatment of the edentulous maxilla using a bar-supported prosthesis. *International Journal of Oral and Maxillofacial Implants* 7, 251-255.

Meijer, H.J., Kuiper, J.H., Starmans, F.J. & Bosman, F. (1992) Stress distribution around dental implants: influence of superstructure, length of implants, and height of mandible. *Journal of Prosthetic Dentistry* 68, 96-102.

Meijer, H.J.A., Raghoobar, G.M. & Van 't Hof, M.A. (2003) Comparison of implant-retained mandibular overdentures and conventional complete dentures: a 10-year prospective study of clinical aspects and patient satisfaction. *International Journal of Oral and Maxillofacial Implants* 18, 879-885.

Mericske-Stern, R., Oetterli, M., Kiener, P. & Mericske E. (2002) A follow-up study of maxillary implants supporting an overdenture: clinical and radiographic results. *International Journal of Oral and Maxillofacial Implants* 2002 17, 678-686.

Naert, I., Gizani, S. & Van Steenberghe, D. (1998) Rigidly splinted implants in the resorbed maxilla to retain a hinging overdenture: a series of clinical reports for up to 4 years. *Journal of Prosthetic Dentistry* 79, 156-164.

Närhi, T.O., Hevinga, M., Voorsmit, R.A. & Kalk, W. (2001) Maxillary overdentures retained by splinted and unsplinted implants: a retrospective study. *International Journal of Oral and Maxillofacial Implants* 16, 259-266.

Palmqvist, S., Sondell, K. & Swartz, B. (1994) Implant-supported maxillary overdentures: outcome in planned and emergency cases. *International Journal of Oral and Maxillofacial Implants* 9, 184-190.

Payne, A.G.T., Tawse-Smith, A., Thomson, W.M., Duncan W.D., Kumara R. (2004) One-stage surgery and early loading of three implants for maxillary overdentures: a 1-year report. *Clinical Implant Dentistry and Related Research* 6, 61-74.

Raghoobar, G.M., Schoen, P., Meijer, H.J., Stellingsma, K. & Vissink A. (2003) Early loading of endosseous implants in the augmented maxilla: a 1-year prospective study. *Clinical Oral Implants Research* 14, 697-702.

Raghoobar, G.M., Schortinghuis, J., Liem, R.S., Ruben, J.L., Van der Wal, J.E. & Vissink A. (2005) Does platelet-rich plasma promote remodeling of autologous bone grafts used for augmentation of the maxillary sinus floor? *Clinical Oral Implants Research* 16, 349-356.

Raghoobar, G.M., Liem, R.S., Bos, R.R., Van der Wal, J.E. & Vissink A. (2006) Resorbable screws for fixation of autologous bone grafts. *Clinical Oral Implants Research* 17, 288-293.

Rodriguez, A.M., Orenstein, I.H., Morris, H.F. & Ochi, S. (2000) Survival of various implant-supported prosthesis designs following 36 months of clinical function. *Annals of Periodontology* 5, 101-108.

Sadowsky, S.J. (2007) Treatment considerations for maxillary implant overdentures: a systematic review. *Journal of Prosthetic Dentistry* 97, 340-348.

Sanna, A., Nuytens, P., Naert, I. & Quirynen, M. (2009) Successful outcome of splinted implants supporting a 'planned' maxillary overdenture: a retrospective evaluation and comparison with fixed full dental prosthesis. *Clinical Oral Implants Research* 20, 406-413.

Smedberg, J.I., Lothigius, E., Bodin, I., Frykholm, A. & Nilner K. (1993) A clinical and radiological two-year follow-up study of maxillary overdentures on osseointegrated implants. *Clinical Oral Implants Research* 4, 39-46.

Smedberg, J.I., Nilner, K. & Frykholm, A. (1999) A six-year follow-up study of maxillary overdentures on osseointegrated implants. *European Journal of Prosthodontics and Restorative Dentistry* 7, 51-56.

Stoker, G.T., Wismeijer, D. & Van Waas, M.A.J. (2007) An eight-year follow-up to a clinical trial of aftercare and cost-analysis with three types of mandibular implant-retained overdentures. *Journal of Dental Research* 86, 276-280.

Timmerman, R., Stoker, G.T., Wismeijer, D., Oosterveld P., Vermeeren J.I., Van Waas M.A. (2004) Patient satisfaction with implant-supported mandibular overdentures: a comparison of three different treatment strategies with ITI-dental implants in a randomized controlled clinical trial 8 years after treatment. *Journal of Dental Research* 83, 630-633.

Visser, A., Raghoobar, G.M., Meijer, H.J., Batenburg, R.H. & Vissink A. (2005) Mandibular overdentures supported by two or four endosseous implants. A 5-year prospective study. *Clinical Oral Implants Research* 16, 19-25.

Visser, A., Meijer, H.J., Raghoobar, G.M. & Vissink, A. (2006) Implant-retained mandibular overdentures versus conventional dentures: 10 years of care and aftercare. *International Journal of Prosthodontics* 19, 271-278.

Visser, A., Raghoobar, G.M., Meijer, H.J.A. & Vissink, A. (2009) Implant-retained maxillary overdentures on milled bar suprastructures: a 10-year follow-up of surgical and prosthetic care and aftercare. *International Journal of Prosthodontics* 22, 181-192.

Watson, R.M., Jemt, T., Chai, J., Harnett, J., Heath, M.R., Hutton, J.E., Johns, R.B., Lithner B., McKenna, S., McNamara, D.C., Naert, I. & Taylor R. (1997) Prosthetic treatment, patient response, and the need for maintenance of complete implant-supported overdentures: an appraisal of 5 years of prospective study. *International Journal of Prosthodontics* 10, 345-354.

Watzek, G., Weber, R., Bernhart, T., Ulm, C. & Haas, R. (1998) Treatment of patients with extreme maxillary atrophy using sinus floor augmentation and implants: preliminary results. *International Journal of Oral and Maxillofacial Surgery* 27, 428-434.

Widbom, C., Söderfeldt, B. & Kronström, M. (2005) A retrospective evaluation of treatments with implant-supported maxillary overdentures. *Clinical Implant Dentistry and Related Research* 7, 166-172.

Zitzmann, N.U. & Marinello, C.P. (2000a) Treatment outcomes of fixed or removable implant-supported prostheses in the edentulous maxilla. Part I: patients' assessments. *Journal of Prosthetic Dentistry* 83, 424-433.

Zitzmann, N.U. & Marinello, C.P. (2000b) Treatment outcomes of fixed or removable implant-supported prostheses in the edentulous maxilla. Part II: clinical findings. *Journal of Prosthetic Dentistry* 83, 434-442.

List of excluded full-text articles and the reason for exclusion

Andrei, O.C. & Pauna, M. (2006) Using porcelain-fused-to-metal restorations combined with precision attachment-supported partial denture in esthetic rehabilitations. *Acta Medica Bulgarica* 33, 52-59. Exclusion criteria: no detailed information on maxillary overdentures.

Åstrand, P., Nord, P.G. & Brånemark, P.I. (1996) Titanium implants and onlay bone graft to the atrophic edentulous maxilla: a 3-year longitudinal study. *International Journal of Oral and Maxillofacial Surgery* 25, 25-29. Exclusion criteria: no patients in the study or study less than 5 patients.

Åstrand, P., Engquist, B., Anzén, B., Bergendal, T., Hallman, M., Karlsson, U., Kvint, S., Lysell, L. & Rundcrantz, T. (2002) Nonsubmerged and submerged implants in the treatment of the partially edentulous maxilla. *Clinical implant dentistry and related research* 4, 115-127. Exclusion criteria: no detailed information on maxillary overdentures.

Åstrand, P., Billström, C., Feldmann, H., Fischer, K., Henricsson, V., Johansson, B., Nyström, E. & Sunzel, B. (2003) Tapered implants in jaws with soft bone quality: a clinical and radiographic 1-year study of the Brånemark System Mark IV fixture. *Clinical implant dentistry and related research* 5, 213-218. Exclusion criteria: no detailed information on maxillary overdentures.

Åstrand, P., Engquist, B., Anzén, B., Bergendal, T., Hallman, M., Karlsson, U., Kvint, S., Lysell, L. & Rundcrantz, T. (2004) A three-year follow-up report of a comparative study of ITI Dental Implants and Brånemark System implants in the treatment of the partially edentulous maxilla. *Clinical implant dentistry and related research*

6, 130-141. Exclusion criteria: no detailed information on maxillary overdentures.

Bartee, B.K. & Perkins, C.E. (1995) Reconstruction of an atrophic edentulous maxilla with unilateral cleft lip and palate (UCLP) using sub-antral augmentation and osseointegrated implants: case report and 3-year follow-up. *Texas Dental Journal* 112, 35-41. Exclusion criteria: no patients in the study or study less than 5 patients.

Batenburg, R.H., Meijer, H.J., Raghoobar, G.M. & Vissink A. (1998) Treatment concept for mandibular overdentures supported by endosseous implants: a literature review. *International Journal of Oral and Maxillofacial Implants* 13, 539-545. Exclusion criteria: no detailed information on maxillary overdentures.

Berson, P.J. (2002) The functionally fixed restoration: a third modality of treatment. *Compendium of Continuous Education in Dentistry* 23, 157-162, 164, 166. Exclusion criteria: no detailed information on maxillary overdentures.

Bilhan, H. (2008) An alternative method to treat a case with severe maxillary atrophy by the use of angled implants instead of complicated augmentation procedures: a case report. *Journal of Oral Implantology* 34, 47-51. Exclusion criteria: no patients in the study or study less than 5 patients.

Binger, T., Rucker, M. & Spitzer, W.J. (2006) Dentofacial rehabilitation by osteodistraction, augmentation and implantation despite osteogenesis imperfecta. *International Journal of Oral and Maxillofacial Surgery* 35, 559-562. Exclusion criteria: no patients in the study or study less than 5 patients.

Binon, P.P. & Fowler, C.N. (1995) Clinical application of custom machined angled abutments. *Journal of Esthetic Dentistry* 7, 118-124. Exclusion criteria: no detailed information on maxillary overdentures.

Blair, F.M. (1997) Restoration of the edentulous maxilla. *British Dental Journal* 183, 138-140. Exclusion criteria: no patients in the study or study less than 5 patients.

Cannizzaro, G., Leone, M. & Esposito, M. (2007) Immediate functional loading of implants placed with flapless surgery in the edentulous maxilla: 1-year follow-up of a single cohort study. *International Journal of Oral and Maxillofacial Implants* 22, 87-95. Exclusion criteria: no detailed information on maxillary overdentures.

Cecchinato, D., Olsson, C. & Lindhe, J. (2004) Submerged or non-submerged healing of endosseous implants to be used in the rehabilitation of partially dentate patients. *Journal of clinical periodontology* 31, 299-308. Exclusion criteria: no detailed information on maxillary overdentures.

Cecchinato, D., Bengazi, F., Blasi, G., Botticelli, D., Cardarelli, I. & Gualini, F. (2008) Bone level alterations at implants placed in the posterior segments of the dentition: outcome of submerged/non-submerged healing. A 5-year multicenter, randomized, controlled clinical trial. *Clinical oral implants research* 19, 429-431. Exclusion criteria: no detailed information on maxillary overdentures.

Chan, M.F., Närhi, T.O., De Baat, C. & Kalk W. (1998) Treatment of the atrophic edentulous maxilla with implant-supported overdentures: a review of the literature. *International Journal of Prosthodontics* 11, 7-15. Exclusion criteria: no patients in the study or study less than 5 patients.

Chee, W.W. (2005) Treatment planning: implant-supported partial overdentures. *Journal of the Californian Dental Association* 33, 313-316. Exclusion criteria: no detailed information on maxillary overdentures.

Cheng, A.C., Tee-Khin, N., Siew-Luen, C., Lee, H., & Wee, A.G. (2008) The management of a severely resorbed edentulous maxilla using a bone graft and a CAD/CAM-guided immediately loaded definitive implant prosthesis: a clinical report. *Journal of Prosthetic Dentistry* 99, 85-90. Exclusion criteria: no detailed information on maxillary overdentures.

Chiapasco, M. (2004) Early and immediate restoration and loading of implants in completely edentulous patients. *International Journal of Oral and Maxillofacial Implants* 19, 76-91. Exclusion criteria: no detailed information on maxillary overdentures.

Cune, M.S., De Putter, C. & Hoogstraten, J. (1994) Treatment outcome with implant-retained overdentures: Part II--Patient satisfaction and predictability of subjective treatment outcome. *Journal of Prosthetic Dentistry* 72, 152-158. Exclusion criteria: no detailed information on maxillary overdentures.

Cune, M.S. & De Putter, C. (1996) A single dimension statistical evaluation of predictors in implant-overdenture treatment. *Journal of Clinical Periodontology* 23, 425-431. Exclusion criteria: no detailed information on maxillary overdentures.

Davodi, A., Nishimura, R. & Beumer, J. 3rd. (1997) An implant-supported fixed-removable prosthesis with a milled tissue bar and Hader clip retention as a restorative option for the edentulous maxilla. *Journal of Prosthetic Dentistry* 78, 212-217. Exclusion criteria: no patients in the study or study less than 5 patients.

DeBoer, J. (1993) Edentulous implants: overdenture versus fixed. *Journal of Prosthetic Dentistry* 69, 386-390. Exclusion criteria: no patients in the study or study less than 5 patients.

Degidi, M. & Piattelli, A. (2003) Immediate functional and non-functional loading of dental implants: a 2- to 60-month follow-up study of 646 titanium implants. *Journal of periodontology* 74, 225-241. Exclusion criteria: no detailed information on maxillary overdentures.

Desjardins, R.P. (1992) Prosthesis design for osseointegrated implants in the edentulous maxilla. *International Journal of Oral and Maxillofacial Implants* 7, 311-320. Exclusion criteria: no patients in the study or study less than 5 patients.

Desjardins, R.P. (1996) Implants for the edentulous patient. *Dental Clinics of North America* 40, 195-215. Exclusion criteria: no patients in the study or study less than 5 patients.

Ekkfeldt, A., Christiansson, U., Eriksson, T., Lindén, U., Lundqvist, S., Rundcrantz, T., Johansson, L.A., Nilner, K. & Billström, C. (2001) A retrospective analysis of factors associated with multiple implant failures in maxillae. *Clinical Oral Implants Research* 12, 462-467. Exclusion criteria: no detailed information on maxillary overdentures. Exclusion criteria: no detailed information on maxillary overdentures.

Ellis, E. 3rd & McFadden, D. (2007) The value of a diagnostic setup for full fixed maxillary implant prosthetics. *Journal of Oral and Maxillofacial Surgery* 65, 1764-1771. Exclusion criteria: no detailed information on maxillary overdentures.

Emami, E., De Grandmont, P., Rompré, P.H., Barbeau, J., Pan, S. & Feine, J.S. (2008) Favoring trauma as an etiological factor in denture

stomatitis. *Journal of Dental Research* 87, 440-444. Exclusion criteria: no detailed information on maxillary overdentures.

Ercoli, C., Graser, G.N., Tallents, R.H. & Hagan, M.E. (1998) Alternative procedure for making a metal suprastructure in a milled bar implant-supported overdenture. *Journal of Prosthetic Dentistry* 80, 253-258. Exclusion criteria: no patients in the study or study less than 5 patients.

Finley, J.M. (1998) Palatal extension of removable prostheses related to implant positions. *Implant Dentistry* 7, 29-33. Exclusion criteria: no patients in the study or study less than 5 patients.

Fischer, K. & Stenberg, T. (2004) Early loading of ITI implants supporting a maxillary full-arch prosthesis: 1-year data of a prospective, randomized study. *The International journal of oral and maxillofacial implants* 19, 374-81. Exclusion criteria: no detailed information on maxillary overdentures.

Fischer, K., Stenberg, T., Hedin, M. & Sennerby, L. (2008) Five-year results from a randomized, controlled trial on early and delayed loading of implants supporting full-arch prosthesis in the edentulous maxilla. *Clinical oral implants research* 19, 433-441. Exclusion criteria: no detailed information on maxillary overdentures.

Flanagan, D. (2008) Screwless fixed detachable partial overdenture treatment for atrophic partial edentulism of the anterior maxilla. *Journal of Oral Implantology* 34, 230-235. Exclusion criteria: no detailed information on maxillary overdentures.

Fritz, M.E. (1999) Two-stage implant systems. *Advances in Dental Research* 13, 162-169. Exclusion criteria: no detailed information on maxillary overdentures.

Fujimoto, T., Niimi, A., Murakami, I. & Ueda, M. (1998) Use of new magnetic attachments for implant-supported overdentures. *Journal of Oral Implantology* 24, 147-151. Exclusion criteria: no patients in the study or study less than 5 patients.

Ganeles, J., Zöllner, A., Jackowski, J., Ten Bruggenkate, C., Beagle, J. & Guerra, F. (2008) Immediate and early loading of Straumann implants with a chemically modified surface (SLActive) in the posterior mandible and maxilla: 1-year results from a prospective multicenter study. *Clinical oral implants research* 19, 1119-1128. Exclusion criteria: no detailed information on maxillary overdentures.

Gonshor, A., Goveia, G. & Sotirakis, E. (2003) A prospective, multicenter, 4-year study of the ACE Surgical resorbable blast media implant. *The journal of oral implantology* 29, 174-180. Exclusion criteria: no patients in the study or study less than 5 patients.

Grossmann, Y. & Pasciuta, M. (2007) Rehabilitation of the edentulous maxilla after the failure of an implant-supported bar. *Journal of Prosthodontics* 16, 319-323. Exclusion criteria: no patients in the study or study less than 5 patients.

Henry, P.J. (1998) Future therapeutic directions for management of the edentulous predicament. *Journal of Prosthetic Dentistry* 79, 100-106. Exclusion criteria: no patients in the study or study less than 5 patients.

Heydecke, G., Boudrias, P., Awad, M.A., De Albuquerque, R.F., Lund, J.P. & Feine, J.S. (2003) Within-subject comparisons of maxillary fixed and removable implant prostheses: Patient satisfaction and choice of prosthesis. *Clinical Oral Implants Research* 14, 125-130. Exclusion criteria: mean follow-up time less than 1 year.

Heydecke, G., McFarland, D.H., Feine, J.S. & Lund, J.P. (2004) Speech with maxillary implant prostheses: ratings of articulation. *Journal of Dental Research* 83, 236-240. Exclusion criteria: mean follow-up time less than 1 year.

Hildestad, P. (1973) Prosthetic reconstruction following maxillectomy. *Journal of Prosthetic Dentistry* 30, 637-640. Exclusion criteria: no detailed information on maxillary overdentures

Hotta, Y. (2004) Use of cephalometric analysis for implant placement in a patient with an edentulous maxilla with a severe Class III intermaxillary relationship. *Journal of Oral Implantology* 30, 7-13. Exclusion criteria: no detailed information on maxillary overdentures.

Hum, S.K. (1994) Implants and the maxillary spark-erosion overdenture. *Oral Health* 84, 9-12. Exclusion criteria: no patients in the study or study less than 5 patients.

Inversini, M. (2006) Prosthetic implant treatment of the edentulous maxilla with overdenture. *Minerva Stomatology* 55, 567-586. Exclusion criteria: no patients in the study or study less than 5 patients.

Isaksson, S., Ekfeldt, A., Alberius, P. & Blomqvist, J.E. (1993) Early results from reconstruction of severely atrophic (Class VI) maxillas by immediate endosseous implants in conjunction with bone grafting and Le Fort I osteotomy. *International Journal of Oral and Maxillofacial Surgery* 22, 144-148. Exclusion criteria: no patients in the study or study less than 5 patients.

Jemt, T., Bergendal, B., Arvidsson, K., Bergendal, T., Karlsson, U., Linden, B., Palmqvist, S., Rundcrantz, T. & Bergström, C. (1998) Laser-welded titanium frameworks supported by implants in the edentulous maxilla: a 2-year prospective

multicenter study. *The international journal of prosthodontics* 11, 551-557. Exclusion criteria: no detailed information on maxillary overdentures.

Jemt, T., Henry, P., Lindén, B., Naert, I., Weber, H. & Bergström, C. (2000) A comparison of laser-welded titanium and conventional cast frameworks supported by implants in the partially edentulous jaw: a 3-year prospective multicenter study. *The international journal of prosthodontics* 13, 282-288. Exclusion criteria: no detailed information on maxillary overdentures.

Jemt, T., Bergendal, B., Arvidson, K., Bergendal, T., Karlsson, L.D., Linden, B., Rundcrantz, T. & Wendelhag, I. (2002) Implant-supported welded titanium frameworks in the edentulous maxilla: a 5-year prospective multicenter study. *The international journal of prosthodontics* 15, 544-548. Exclusion criteria: no detailed information on maxillary overdentures.

Jemt, T., Henry, P., Lindén, B., Naert, I., Weber, H. & Wendelhag, I. (2003) Implant-supported laser-welded titanium and conventional cast frameworks in the partially edentulous jaw: a 5-year prospective multicenter study. *The international journal of prosthodontics* 16, 415-421. Exclusion criteria: no detailed information on maxillary overdentures.

Jivraj, S., Chee, W. & Corrado, P. (2006) Treatment planning of the edentulous maxilla. *British Dental Journal* 201, 261-279. Exclusion criteria: no patients in the study or study less than 5 patients.

Khatami, A.H., Smith & C.R. (2008) "All-on-Four" immediate function concept and clinical report of treatment of an edentulous mandible with a fixed complete denture and milled titanium framework. *Journal of Prosthodontics* 17, 47-51. Exclusion criteria: no detailed information on maxillary overdentures.

Klemetti, E., Chehade, A., Takashi, Y. & Feine, J.S. (2003) Two-implant mandibular overdentures: simple to fabricate and easy to wear. *Journal of the Canadian Dental Association* 69, 29-33. Exclusion criteria: no detailed information on maxillary overdentures.

Krennmair, G., Weinländer, M. & Schmidinger, S. (2003) Provisional implants for anchoring removable interim prostheses in edentulous jaws: a clinical study. *International Journal of Oral and Maxillofacial Implants* 18, 582-588. Exclusion criteria: mean follow-up time less than 1 year.

Krennmair, G., Fürhauser, R., Weinländer, M. & Piehslinger, E. (2005) Maxillary interim overdentures retained by splinted or unsplinted provisional implants. *The international journal of prosthodontics* 18, 195-200. Exclusion criteria: no detailed information on maxillary overdentures.

Krennmair, G., Krainhöfner, M., Waldenberger, O. & Piehslinger, E. (2007) Dental implants as strategic supplementary abutments for implant-tooth-supported telescopic crown-retained maxillary dentures: a retrospective follow-up study for up to 9 years. *International Journal of Prosthodontics* 20, 617-622. Exclusion criteria: no detailed information on maxillary overdentures.

Kupeyan, H.K., Shaffner, M. & Armstrong, J. (2006) Definitive CAD/CAM-guided prosthesis for immediate loading of bone-grafted maxilla: a case report. *Clinical Implant Dentistry & Related Research* 8, 161-167. Exclusion criteria: no detailed information on maxillary overdentures.

Kurita, H., Sakai, H., Uehara, S. & Kurashina, K. (2008) Dental rehabilitation using an implant-carrying plate system in a severely resorbed edentulous maxilla: a case report. *International Journal of Oral and Maxillofacial Implants* 23, 117-120. Exclusion criteria: no detailed information on maxillary overdentures.

Lefkove, M.D. & Beals, R. (1992) Spark erosion fixed/detachable prosthesis for the completely edentulous maxilla. *Journal of Oral Implantology* 18, 386-393. Exclusion criteria: no patients in the study or study less than 5 patients.

Lewis, S., Sharma, A. & Nishimura, R. (1992) Treatment of edentulous maxillae with osseointegrated implants. *Journal of Prosthetic Dentistry* 68, 503-508. Exclusion criteria: no patients in the study or study less than 5 patients.

Lund, T.W. & Wade, M. (1993) Use of osseointegrated implants to support a maxillary denture for a patient with repaired cleft lip and palate. *The Cleft Palate – Craniofacial Journal* 30, 418-420. Exclusion criteria: no detailed information on maxillary overdentures

Lundqvist, S., Lohmander-Agerskov, A. & Haraldson, T. (1992) Speech before and after treatment with bridges on osseointegrated implants in the edentulous upper jaw. *Clinical oral implants research* 3, 57-62. Exclusion criteria: no detailed information on maxillary overdentures.

Lundquist, S., Haraldson, T. & Lindblad, P. (1992) Speech in connection with maxillary fixed prostheses on osseointegrated implants: a three-year follow-up study. *Clinical oral implants research* 3, 176-180. Exclusion criteria: no detailed information on maxillary overdentures.

Makila, E. & Hopsu Havu, V.K. (1977) Mycotic growth and soft denture lining materials. *Acta Odontologica Scandinavica* 35, 197-205. Exclusion criteria: no detailed information on maxillary overdentures.

Malmstrom, H.S., Fritz, M.E., Timmis, D.P. & Van Dyke, T.E. (1990) Osseo-integrated implant treatment of a patient with rapidly progressive periodontitis. A case report. *Journal of*

Periodontology 61, 300-304. Exclusion criteria: no patients in the study or study less than 5 patients.

Marker, P., Svane-Knudsen, V., Jorgensen, K.E., Nielsen A. & Hansen O. (1997) Immediate obturation of the surgical defect after partial maxillectomy in the edentulous patient. Acta Odontologica 36, 41-44. Exclusion criteria: no detailed information on maxillary overdentures.

Markt, J.C. (2003) Implant prosthodontic rehabilitation of a patient with nevoid basal cell carcinoma syndrome: a clinical report. Journal of Prosthetic Dentistry 89, 436-442. Exclusion criteria: no patients in the study or study less than 5 patients.

Meijer, H.J.A., Reintsema, H. & Slot, J.W.A. (2008) [Prosthetic dilemmas. Choice of superstructure for the edentulous maxilla] Nederlands Tijdschrift voor Tandheelkunde 115, 599-604. Exclusion criteria: publication not in the English language.

Mericske-Stern, R., Schaffner, G.S. & Mericske, E. (1994) [Implant prosthetics. The use of the Octa System for single crowns or bridge reconstructions with ITI implants. Internationales Team für Implantologie] Schweizerisches Monatsschrift für Zahnmedizin 104, 864-877. Exclusion criteria: publication not in the English language.

Mericske-Stern, R. (1998) Treatment outcomes with implant-supported overdentures: clinical considerations. Journal of Prosthetic Dentistry 79, 66-73. Exclusion criteria: no patients in the study or study less than 5 patients.

Mericske-Stern, R.D., Taylor, T.D. & Belsler, U. (2000) Management of the edentulous patient. Clinical Oral Implants Research 11, 108-125. Exclusion criteria: no patients in the study or study less than 5 patients.

Merickse-Stern, R., Aerni, D., Geering, A.H. & Buser, D. (2001) Long-term evaluation of non-submerged hollow cylinder implants. Clinical and radiographic results. Clinical Oral Implants Research 12, 252-259. Exclusion criteria: no patients in the study or study less than 5 patients.

Närhi, T.O., Geertman, M.E., Hevinga, M., Abdo, H. & Kalk, W. (2000) Changes in the edentulous maxilla in persons wearing implant-retained mandibular overdentures. The journal of prosthetic dentistry 84, 43-49. Exclusion criteria: no detailed information on maxillary overdentures.

Ochiai, K.T., Williams, B.H., Hojo, S., Nishimura, R. & Caputo, A.A. (2004) Photoelastic analysis of the effect of palatal support on various implant-supported overdenture designs. Journal of Prosthetic Dentistry 91, 421-427. Exclusion criteria: no patients in the study or study less than 5 patients.

Olson, J.W., Dent, C.D., Morris, H.F. & Ochi, S. (2000) Long-term assessment (5 to 71 months) of endosseous dental implants placed in the augmented maxillary sinus. Annals of periodontology 5, 152-156. Exclusion criteria: no detailed information on maxillary overdentures.

Ortorp, A. & Jemt, T. (2002) Clinical experience of CNC-milled titanium frameworks supported by implants in the edentulous jaw: a 3-year interim report. Clinical implant dentistry and related research 4, 104-109. Exclusion criteria: no detailed information on maxillary overdentures.

Ostman, P.O., Hellman, M. & Sennerby, L. (2005) Direct implant loading in the edentulous maxilla using a bone density-adapted surgical protocol and primary implant stability criteria for inclusion. Clinical implant dentistry and related research 7 (Suppl. 1), S60-S69. Exclusion criteria: no detailed information on maxillary overdentures.

Ostman, P.O., Hellman, M., Albrektsson, T. & Sennerby, L. (2007) Direct loading of Nobel Direct and Nobel Perfect one-piece implants: a 1-year prospective clinical and radiographic study. Clinical oral implants research 18, 409-418. Exclusion criteria: no detailed information on maxillary overdentures.

Payne, A.G., Lownie, J.F. & Van Der Linden, W.J. (1997) Implant-supported prostheses in patients with Sjögren's syndrome: a clinical report on three patients. International Journal of Oral and Maxillofacial Implants 12, 679-685. Exclusion criteria: no patients in the study or study less than 5 patients.

Peñarrocha, M., Sanchis, J.M., Rambla, J. & Sánchez, M.A. (2001) Oral rehabilitation with osseointegrated implants in a patient with oromandibular dystonia with blepharospasm (Brueghel's syndrome): a patient history. International Journal of Oral and Maxillofacial Implants 16, 115-117. Exclusion criteria: no detailed information on maxillary overdentures.

Peñarrocha, M., Larrazábal, C., Balaguer, J., Serrano, C., Silvestre, J. & Bagán JV. (2007) Restoration with implants in patients with recessive dystrophic epidermolysis bullosa and patient satisfaction with the implant-supported superstructure. International Journal of Oral and Maxillofacial Implants 22, 651-655. Exclusion criteria: no patients in the study or study less than 5 patients.

Peñarrocha, M., Boronat, A., Carrillo, C. & Albalat, S. (2008) Computer-guided implant placement in a patient with severe atrophy. Journal of Oral Implantology 34, 203-207. Exclusion criteria: no detailed information on maxillary overdentures.

Preiskel, H.W. & Tsolka, P. (1997) The DIA anatomic abutment system and telescopic

prostheses: a clinical report. International Journal of Oral and Maxillofacial Implants 12, 628-633. Exclusion criteria: no detailed information on maxillary overdentures.

Prosper, L., Gherlone, E.F., Redaelli, S. & Quaranta M (2003) Four-year follow-up of larger-diameter implants placed in fresh extraction sockets using a resorbable membrane or a resorbable alloplastic material. The international journal of oral and maxillofacial implants 18, 856-864. Exclusion criteria: no detailed information on maxillary overdentures.

Raghoobar, G.M., Meijer, H.J., Van 't Hof, M., Stegenga, B. & Vissink, A. (2003) A randomized prospective clinical trial on the effectiveness of three treatment modalities for patients with lower denture problems. A 10 year follow-up study on patient satisfaction. International Journal of Oral and Maxillofacial Surgery 32, 498-503. Exclusion criteria: no detailed information on maxillary overdentures.

Reintsema, H., Van Oort, R.P. & Raghoobar, G.M. (1997) [A prosthodontic concept using implants in the resorbed edentulous maxilla] Nederlands Tijdschrift voor Tandheelkunde 104, 277-279. Exclusion criteria: publication not in the English language.

Rocci, A., Martignoni, M. & Gottlow, J. (2003) Immediate loading of Brånemark System TiUnite and machined-surface implants in the posterior mandible: a randomized open-ended clinical trial. Clinical implant dentistry and related research 5 (Suppl. 1), 57-63. Exclusion criteria: no detailed information on maxillary overdentures.

Sadowsky, S.J. (2003) Implant-retained removable prosthetic designs for patients with maxillary posterior edentulism. Journal of the Californian Dental Association 31, 333-335. Exclusion criteria:

no patients in the study or study less than 5 patients.

Schneider, A.L. (1998) Use of guide planes and implant supported bar overdentures: a case report. *Implant Dentistry* 7, 45-49. Exclusion criteria: no patients in the study or study less than 5 patients.

Semsch, R. & Muche, R. (2005) Implant-supported bar-latch overdenture for the severely atrophied, edentulous jaw: a case report. *Quintessence International* 36, 565-576. Exclusion criteria: no patients in the study or study less than 5 patients.

Strong, S.M. & Callan, D.P. (2001) Combining maxillary bar overdenture attachment systems: a case report. *Dentistry Today* 20, 78-80, 82-84. Exclusion criteria: no patients in the study or study less than 5 patients.

Shackleton, J.L., Solomons, Y.F. & Lownie, M.A. (1996) Experience with the Brånemark implant system: 1985-1995. *Journal of the Dental Association of South Africa* 51, 810-814. Exclusion criteria: no patients in the study or study less than 5 patients.

Simons, A.M. & Campbell, Z. (1993) The implant-supported overdenture prosthesis for the edentulous maxilla. *Journal of Oral Implantology* 19, 39-42. Exclusion criteria: no patients in the study or study less than 5 patients.

Smedberg, J.I., Johansson, P., Ekenbäck, D. & Wannfors D. (2001) Implants and sinus-inlay graft in a 1-stage procedure in severely atrophied maxillae: prosthodontic aspects in a 3-year follow-up study. *International Journal of Oral and Maxillofacial Implants* 16, 668-674. Exclusion criteria: no detailed information on maxillary overdentures.

Spauwen, P.H.M., Hardjowasito, W., Boersma, J. & Latief, B.S. (1993) Dental cast study of adult patients with untreated unilateral cleft lip or cleft lip and palate in Indonesia compared with surgically treated patients in the Netherlands. *The Cleft Palate-Craniofacial Journal* 30, 313-319. Exclusion criteria: no detailed information on maxillary overdentures

Straiato, F.G., De Azevedo, A.M., Do Prado, C.J., Das Neves, F.D. & Neto, A.J. (2006) Rehabilitation of maxillary edentulism with implant-supported milled-bar prostheses. *Implant Dentistry* 15, 366-371. Exclusion criteria: no patients in the study or study less than 5 patients.

Svenson, B. & Palmqvist, S. (1996) Imaging of dental implants in severely resorbed maxillae using detailed narrow-beam radiography. A methodological study. *Dentomaxillofacial Radiology* 25, 67-70. Exclusion criteria: no detailed information on maxillary overdentures.

Ten Bruggenkate, C.M., Oosterbeek, H.S., Krekeler, G. & Asikainen, P.J. (1991) The placement of angled implants in the edentulous maxillae for the use of overdentures. *Journal of Prosthetic Dentistry* 66, 807-809. Exclusion criteria: no patients in the study or study less than 5 patients.

Ten Bruggenkate, C.M., Sutter, F., Oosterbeek, H.S. & Schroeder, A. (1992) Indications for angled implants. *Journal of Prosthetic Dentistry* 67, 85-93. Exclusion criteria: no patients in the study or study less than 5 patients.

Testori, T., Del Fabbro, M., Capelli, M., Zuffetti, F., Francetti, L. & Weinstein, R.L. (2008) Immediate occlusal loading and tilted implants for the rehabilitation of the atrophic edentulous maxilla: 1-year interim results of a multicenter prospective study. *Clinical oral implants research* 19, 227-232.

Exclusion criteria: no detailed information on maxillary overdentures.

Uludag, B., Sahin, V. & Celik, G. (2007) Fabrication of a maxillary implant-supported overdenture retained by two cemented bars: a clinical report. *Journal of Prosthetic Dentistry* 97, 249-251. Exclusion criteria: no patients in the study or study less than 5 patients.

Uludag, B., Sahin, V. & Celic, G. (2008) Technical tips for constructing a maxillary implant-supported overdenture by using a double-impression technique. *Journal of Oral Implantology* 34, 142-144. Exclusion criteria: study less than 5 patients

Watson, C.J., Tinsley, D. & Sharma, S. (2001) Implant complications and failures: the complete overdenture. *Dentistry Update* 28, 234-238, 240. Exclusion criteria: no patients in the study or study less than 5 patients.

Wennström, J.L., Ekestubbe, A., Gröndahl, K., Karlsson, S. & Lindhe, J. (2004) Oral rehabilitation with implant-supported fixed partial dentures in periodontitis-susceptible subjects. A 5-year prospective study. *Journal of clinical periodontology* 31, 713-724. Exclusion criteria: no detailed information on maxillary overdentures.

West, R.A. & Burk, J.L. (1974) Maxillary osteotomies for preprosthetic surgery. *Journal of Oral Surgery* 32, 13-22. Exclusion criteria: no detailed information on maxillary overdentures.

Whitehouse, J. (2008) Technology helps an "amateur" place implants. *Dentistry Today* 27, 120-124. Exclusion criteria: no patients in the study or study less than 5 patients.

Widmark, G., Andersson, B., Andrup, B., Carlsson, G.E., Ivanoff, C.J. & Lindvall, A.M. (1998) Rehabilitation of patients with severely resorbed maxillae by means of implants with or without bone grafts. A 1-year follow-up study. *International journal of oral and maxillofacial implants* 13, 474-82. Exclusion criteria: treatment not initially planned for an overdenture.

Widmark, G., Andersson, B., Carlsson, G.E., Lindvall, A.M. & Ivanoff, C.J. (2001) Rehabilitation of patients with severely resorbed maxillae by means of implants with or without bone grafts: a 3- to 5-year follow-up clinical report. *The international journal of oral and maxillofacial implants* 16, 73-79. Exclusion criteria: treatment not initially planned for an overdenture.

Winkler, S. & Monasky, G.E. (1993) The edentulous mandible opposing maxillary natural teeth: treatment considerations utilizing implant overdentures. *Implant Dentistry* 2, 44-47. Exclusion criteria: no detailed information on maxillary overdentures.

Winkler, S., Piermatti, J., Rothman, A. & Siamos, G. (2002) An overview of the O-ring implant overdenture attachment: clinical reports. *Journal of Oral Implantology* 28, 82-86. Exclusion criteria: no detailed information on maxillary overdentures.

Wismeijer, D., Van Waas, M.A. & Kalk, W. (1995) Factors to consider in selecting an occlusal concept for patients with implants in the edentulous mandible. *Journal of Prosthetic Dentistry* 74, 380-384. Exclusion criteria: no detailed information on maxillary overdentures.

Zarb, J.P. & Zarb, G.A. (2002) Implant prosthodontic management of anterior partial edentulism: long-term follow-up of a prospective

study. *Journal of the Canadian Dental Association* 68, 92-96. Exclusion criteria: no detailed information on maxillary overdentures.

Zitzmann, N.U. & Marinello, C.P. (1999) Treatment plan for restoring the edentulous maxilla with implant-supported restorations: removable overdenture versus fixed partial denture design. *Journal of Prosthetic Dentistry* 82, 188-196. Exclusion criteria: no patients in the study or study less than 5 patients.

Zitzmann, N.U. & Marinello, C.P. (1999) Implant-supported removable overdentures in the edentulous maxilla: clinical and technical aspects. *International Journal of Prosthodontics* 12, 385-390. Exclusion criteria: no patients in the study or study less than 5 patients.

Zitzmann, N.U. & Marinello, C.P. (2000) Fixed or removable implant-supported restorations in the edentulous maxilla: literature review. *Practical Periodontics and Aesthetic Dentistry* 12, 599-608. Exclusion criteria: no patients in the study or study less than 5 patients.

Chapter 3

Maxillary overdentures supported by 4 or 6 implants in the anterior region; 1-year results from a randomized controlled trial

This chapter is an edited version of the manuscript.

Slot, W., Raghoobar, G.M., Vissink, A., Meijer, H.J. (2013).

Maxillary overdentures supported by four or six implants in the anterior region; 1-year results from a randomized controlled trial.

Journal of Clinical Periodontology 40, 303-310.

Abstract

Objective

Comparing treatment outcome of four and six bar-connected implants in the anterior maxillary region to support an overdenture during a 1-year follow-up period.

Materials and methods

Fifty edentulous patients with lack of retention and stability of the upper denture, but with sufficient bone volume to place implants in the anterior maxillary region, were selected. Randomization assigned patients to either 4 or 6 implants. Implant survival, overdenture survival, clinical scores, radiographic bone height changes and patients' satisfaction were assessed.

Results

Forty-nine patients (one drop out) completed the one-year follow-up. After 1 year, implant survival was 100% in the four implants group and 99.3% in the six implants group (1 implant lost). Overdenture survival was 100% in both groups. Mean clinical scores were low and did not differ between groups (independent Student's t-test). Mean marginal bone resorption was 0.24 ± 0.32 mm in the four implants group and 0.25 ± 0.29 mm in the six implants group. Patients' satisfaction had improved in both groups (paired Student's t-test).

Conclusion

Bar-supported overdentures on 4 implants in the anterior maxillary region are not inferior to overdentures supported by six bar-connected implants. Implant survival was high, peri-implant conditions were healthy and patients' satisfaction had increased significantly in both groups.

Introduction

Edentulous patients often experience problems with their complete dentures. A lack of stability and retention of their denture, together with a decreased chewing ability, are the main complaints of these patients (Van Waas 1990). The increase in comfort for patients wearing an implant-supported overdenture versus a conventional denture is striking, especially for those who suffer from lack of stability and retention (Van Assche et al. 2012).

Implant overdenture therapy has been widely demonstrated to improve function, diet and patients' satisfaction (Fromentin et al. 2010).

Furthermore, ability to speak, ease of cleaning, aesthetics and general satisfaction were shown to be the factors with the most influence on the choice between a fixed full prosthesis and an implant-supported overdenture in favour of an overdenture (Heydecke et al. 2003). Quality and volume of remaining bone, and number and position of implants are factors which influence success of implants and prosthesis in the upper jaw (Esposito et al. 1998). In a systematic review of maxillary overdentures, Slot et al. (2010) stated a survival rate of 98.2% in case of 6 implants and a bar anchorage, a survival rate of 96.3% in case of 4 implants and a bar anchorage and a survival rate of 95.2% in case of 4 implants and a ball anchorage, after 1-year of treatment. When comparing survival of prostheses in the maxilla, it is important to make the distinction between "planned" and "unplanned" maxillary overdentures. An "unplanned" overdenture is an emergency situation, in which the placement of an insufficient number and/or previous implant failures made a fixed full dental prosthesis an unfeasible option. A "planned" overdenture, instead, is the result of a planned treatment protocol (Krennmair et al. 2008; Sanna et al. 2009; Mangano et al. 2011). The literature describes a better survival rate for planned cases than for unplanned cases (Palmqvist et al. 1994, Widbom et al. 2005, Sanna et al. 2009). The survival rates mentioned in the study of Slot et al. (2010) were on planned cases.

For the edentulous mandible there are evidence-based treatment guidelines involving stage of resorption and number of implants (Thomason et al. 2009, Raghoobar et al. 2011) as well as that long-term results are available

(Meijer et al. 2009a, b, Vercruyssen et al. 2010). For maxillary overdenture therapy treatment guidelines are missing (Sadowsky 2007, Slot et al. 2010, Andreiotelli et al. 2010, Rocuzzo et al. 2012). Since results of six bar-connected implants and four bar-connected seems both favourable and resembles each other, the question raises if 6 implants are necessary for maxillary overdenture treatment. In maxillary implant therapy there are no treatment guidelines in what position the implants are preferably placed. In case of implant-supported overdenture therapy in the maxilla it seems that, when sufficient bone in the anterior region in combination with enough space in the overdenture is available to cover an attachment system, there is an advantage in placing implants in the anterior region, because of less morbidity and treatment time. In the posterior region of the edentulous maxilla there is often not enough bone volume to place implants, meaning that a separate bone augmentation procedure is needed. In severe cases this bone augmentation procedure (maxillary sinus floor elevation surgery) is often done with bone from the iliac crest, meaning extended treatment time, more morbidity, hospitalization and more treatment costs (Kalk et al. 1996). Another advantage is that implants in the anterior maxillary region are better accessible for the patient and oral hygiene should be easier maintained. Therefore, it is worthwhile to explore the possibilities of anterior implant placement in the treatment planning of a maxillary implant-supported overdenture. Randomized controlled trials with standardized outcome measurement are considered the best proof to estimate the efficacy of a therapy (Cairo et al. 2012, Needleman et al. 2012).

The purpose of this 1-year randomized controlled trial was to assess the treatment outcome (implant survival, overdenture survival, peri-implant health, radiographic bone height changes, patients' satisfaction) of "planned" maxillary overdentures supported by 4 or 6 dental implants in patients in the anterior part of the maxilla.

Material and methods

Patient selection

Between January 2006 and December 2009 a total of 50 consecutive patients fulfilling the inclusion criteria were included in this trial. These fully edentulous patients referred to the Department of Oral and Maxillofacial Surgery (University Medical Center Groningen, the Netherlands) suffering from lack of retention and stability of the upper denture and lower denture, were considered for inclusion if they fulfilled the following criteria: at least 18 years of age, capable of understanding and giving informed consent, at least one year edentulous in the maxilla and mandible, sufficient volume of bone to place implants in the anterior maxillary and mandibular region, bone dimensions in the region between the bicuspids in the anterior area of the maxilla had to be at least 12 mm in height, at least 5 mm in width and sufficient interocclusal space for a bar-supported attachment system in this region must be present. Excluded were patients with American Society of Anesthesiologists score (ASA score) \geq III (Smeets et al. 1998), who were smoking, with a history of radiotherapy in the head and neck region or a history of pre-prosthetic surgery or previous implant placement. The patients were informed about the study on overdenture treatment with insertion of 4 or 6 dental implants in the maxilla and about the extra efforts associated with the study (questionnaires, evaluation visits) before they signed an informed consent. The study was approved by the Medical Ethical Committee of the University Medical Center Groningen (ABR NL32503.042.11).

Orthopantomograms, lateral cephalograms and postero-anterior oblique radiographs were made to assess the volume of the maxillary alveolar bone, the dimensions of the maxillary sinus, and the anteroposterior relationship of the maxilla to the mandible. The radiographs were also screened for sinus pathology. In addition to assess the bone volume of the maxillary processus a ridge mapping procedure was performed as described by ten Bruggenkate et al. (1994). In all cases a diagnostic setup of the planned overdenture was made to get more insight in the available dimensions for the bar-supported attachment system and overdenture.

Treatment procedure

All surgical procedures were performed by one experienced oral and maxillofacial surgeon. The prosthetic procedures were accomplished by three experienced prosthodontists and manufacturing of the superstructure was done by a single experienced dental laboratory.

Surgical procedures

4 or 6 dental implants with a length of at least 11 mm and a diameter of 4 mm were inserted in the maxillary anterior region (OsseoSpeed™ 4.0 S dental implants, Astra Tech AB, Mölndal, Sweden). The implants were placed at crestal bone level in predefined positions (positions 15, 13, 11, 21, 23, 25 in the six implants group and positions 13, 11, 21, 23 in the four implants group) with help of a surgical template in a two-stage procedure. Neither 3-dimensional sinus diagnosis nor 3-dimensional pre-surgical treatment planning was performed in the study. In all cases there was enough bone volume to insert implants with primary stability in the predefined positions. Small dehiscence's or fenestrations were covered with bone harvested from the maxillary tuberosity and organic bovine bone (Bio-Oss®, Geistlich Pharma AG, Wolhusen, Switzerland), and subsequently with a resorbable membrane (Bio-Gide®, Geistlich Pharma AG, Wolhusen, Switzerland). If the most distally placed implants (usually in the six implants group) were partially placed in the anterior part of the maxillary sinus, a small sinus floor elevation surgery was performed in that region to prevent a perforation of the sinus membrane by the implant. An osteotomy was prepared in the lateral wall of the maxillary sinus with a conventional rotative bur and the bone fragment positioned upward; the sinus membrane was carefully raised. The alveolar defect was filled with bone harvested from maxillary tuberosity and organic bovine bone (Bio-Oss®, Geistlich Pharma AG, Wolhusen, Switzerland), and subsequently covered with a resorbable membrane (Bio-Gide®, Geistlich Pharma AG, Wolhusen, Switzerland). Because all the patients were fully edentulous, 4 implants for overdenture treatment were placed simultaneously in the mandible. Patients received amoxicillin, starting one hour preoperatively (3 g Clamoxyl®, GlaxoSmithKline, Utrecht, the Netherlands) orally and continued (500 mg Clamoxyl®; GlaxoSmithKline, Utrecht, the Netherlands) for seven

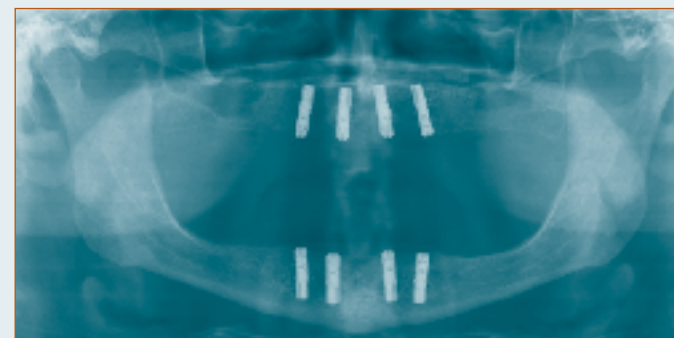
days 3 times daily after surgery. Postoperatively the patient received a 0.2% chlorhexidine mouth rinse (Corsodyl®; GlaxoSmithKline, Utrecht, the Netherlands) 1 minute, 2 times daily for 2 weeks.

Two weeks after implant placement, the patient was allowed to wear his or her dentures again after adjustment of the prostheses with a resilient lining material (Soft liner; GC Corporation, Tokyo, Japan). After a 3-months osseointegration period, second stage surgery was performed and healing abutments (Uni Healing Abutments, Astra Tech AB, Mölndal, Sweden) were placed. The denture was adjusted in the area of the healing abutments and relined again with a resilient lining material. The patient was given oral hygiene instructions to clean the healing abutments.

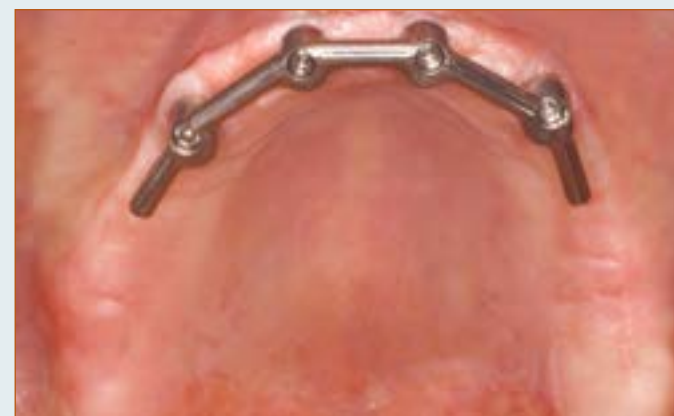Prosthetic procedure

After second stage surgery, prosthetic procedures were initiated. Custom acrylic resin impression trays (Lightplast base plates; Dreve Dentamid GmbH, Unna, Germany) were fabricated with openings for screw-retained impression copings. The healing abutments were replaced by 20° Uni Abutments (Astra Tech AB, Mölndal, Sweden). Impression copings were attached to the abutments with the integral positioning screw. The final complete arch impression was made with polyether material (Impregum F; 3M ESPE, St. Paul, Minn). A composite resin record base (Lightplast base plates; Dreve Dentamid GmbH, Unna, Germany) with a wax occlusion rim was used to determine the occlusal vertical dimension and to record the maxillo-mandibular relationship. Acrylic resin artificial teeth (Ivoclar SR Orthotyp DCL and Ivoclar Vivodent PE, Ivoclar Vivadent AG, Schaan, Liechtenstein) were selected and arranged on the record base for a trial arrangement. A bilateral balanced occlusion concept was followed. The final superstructure consisted of a milled titanium egg-shaped bar with distal extensions, screw-retained to abutments, and an overdenture with built-in cobalt chromium reinforcement structure and gold retentive clips attached to it (Slot et al. 2012). The design of the overdentures was with full coverage of the alveolar process, but without palatal coverage in the maxilla. All implants were splinted with a bar. The patient was instructed in hygiene procedures associated with the dentures and the bars and scheduled for routine maintenance recalls (figures 1-2).

Figure I The four implants group

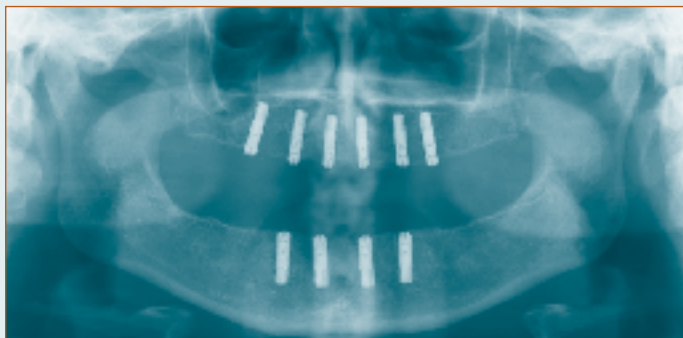


Ia Panoramic radiograph of a patient with 4 implants in the maxillary anterior region.

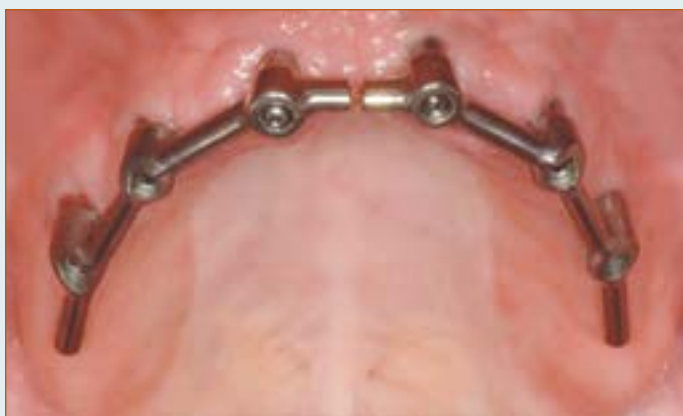

Ib Intra-oral view on bar-superstructure on 4 implants in the anterior region.

Figure 2 The six implants group



2a Panoramic radiograph of a patient with 6 implants in the anterior maxillary region.



2b Intra-oral view on bar-superstructure on 6 implants in the anterior region.

Outcome measures

Primary outcome measure was change of radiographic bone level. Secondary outcome measures were implant survival, overdenture survival and soft tissue conditions (plaque index, presence of calculus, gingiva index, sulcus bleeding index and pocket probing depth). These parameters were scored at placement of the overdenture and after 12 months of loading. Patients' satisfaction was scored before treatment and at 12 months after placement of the overdenture.

Change of radiographic bone level

Standardized intraoral radiographs were taken after placement of the overdenture and 12 months thereafter. The radiographs were taken according to a long-cone paralleling technique with an individualized X-ray holder described by Meijndert et al. (2004). For each patient an acrylic film holder was fabricated which was designed to fit in a unique position, with the aid of retentive clips, on the bar superstructure. In this way standardization was secured. The digital images were analyzed using computer software (Biomedical Engineering, University Medical Center Groningen, the Netherlands) to perform linear measurements on digital radiographs. Reference line for bone level evaluation was the outer border of the neck of the implant. Mesial and distal bone changes in this region were considered as radiographic bone height change and were defined as the difference in bone height between the photograph taken at overdenture placement and the photograph taken 12 months after placement of the overdenture.

Implant survival

Implant survival was defined as the percentage of implants initially placed that was still present and not mobile at follow-up. Lost implants were scored any time after placement. Mobile implants were scored by percussion after removal of the bar.

Overdenture survival

Survival of maxillary overdentures was defined as the percentage of overdentures initially placed that was still present at follow-up. During the

follow-up period the prosthodontist rated the overdenture. When it did not meet the standard criteria, a correction was performed. Remake of the maxillary overdenture was scored any time after placement.

Clinical parameters

For presence of plaque, the index according to Mombelli et al. (1987) was used (score 0: no detection of plaque, score 1: plaque can be detected by running a probe across the smooth marginal surface of the abutment and implant, score 2: plaque can be seen by the naked eye, score 3: abundance amount of plaque). The presence of calculus (score 1) or the absence of calculus (score 0) was scored. To qualify the degree of peri-implant inflammation, the modified Löe and Silness index (1963) was used (score 0: normal peri-implant mucosa, score 1: mild inflammation; slight change in colour, slight oedema, score 2: moderate inflammation; redness, oedema and glazing, score 3: severe inflammation; marked redness and oedema, ulceration). For bleeding, the bleeding index according to Mombelli et al. (1987) was used (score 0: no bleeding when using a periodontal probe, score 1: isolated bleeding spots visible, score 2: a confluent red line of blood along the mucosa margin, score 3: heavy or profuse bleeding). Probing depth was measured at four sites of each implant (mesial, labial, distal, and lingual) by using a manual periodontal probe (Williams Colour-Coded Probe; Hu-Friedy, Chicago, IL, USA) after removal of the bar; the distance between the marginal border of the mucosa and the tip of the periodontal probe was scored as the probing depth.

Patients' satisfaction

Patients' satisfaction with their overdenture was assessed using a validated questionnaire (Vervoorn et al. 1988). This questionnaire focused on complaints and consisted of 54 questions. Each question could be addressed to one out of six specific scales.

The six scales are:

- a. Nine items concerning functional problems of the lower denture
- b. Nine items concerning functional problems of the upper denture
- c. Eighteen items concerning functional problems complaints in general
- d. Three items concerning facial aesthetics

e. Three items concerning accidental lip, cheek, and tongue biting ("neutral space")

f. Twelve items concerning esthetics of the denture

The extent of each specific complaint could be expressed on a four-point rating (0 = no complaints, 1 = little, 2 = moderate, 3 = severe complaints).

All patients were requested to fill out a "Chewing ability" questionnaire (Stellingsma et al. 2005). In this questionnaire patients gave their opinion about the ability to chew nine different kinds of food on a three-point rating scale (0 = good, 1 = moderate, 2 = bad). The items were grouped into three scales, being soft food, tough food and hard food. Next to these questionnaires, the patients' overall denture satisfaction was expressed on a 10-point rating scale (1 = very bad to 10 = excellent).

Patients' satisfaction was scored before treatment and 12 months after placement of the overdenture.

Statistical analysis

Study analysis was performed according a non-inferiority design. It was assumed that an implant-supported overdenture on 4 implants was not inferior to one supported by 6 implants. The sample size was calculated with the program G*power version 2 (Erdfelder et al. 1996). A difference of at least 0.4 mm in bone height (measured on standardized radiographs, with a standard deviation of 0.5 mm) between the four implants group and six implants group after twelve months was expected to differentiate between the two groups, based on the findings of a study on maxillary implant supported overdentures (Raghoobar et al. 2003a). A t-test given $\alpha = 0.05$ with a power 80% combined with the expected effect size for 2 independent means gives a sample size of 21 persons in each group. To deal with withdrawal of individuals in the study, the number of participants was determined to be 25 persons per group. Patients were randomly allocated to one of the treatment groups by lot with the use of sealed envelopes. Twenty-five notes with the words "four implants" and 25 notes with the words "six implants" were put into 50 identical, sequentially numbered, non-transparent envelopes. No stratification was performed. All envelopes were irreversibly sealed, only to be opened prior to fabrication of the surgical stent.

Data collection and analysis of the radiographs were done by the same observer. The worst score per implant of the clinical and radiographic parameters were used in the data analysis. Data were analyzed using the Statistical Package for Social sciences (version 18.0; SPSS Inc.: An IBM Company, IBM Corporation, Chicago, IL, USA). In all tests a significance level of 0.05 was chosen. To see whether the data were normally distributed the frequency distribution was plotted in a histogram. To test whether the result from the frequency analyses differed significantly from a normally distribution Kolmogorov-Smirnov and Shapiro-Wilk test were carried out. Data were normally distributed. The potential effects of imbalances between the studies groups on the outcomes of this study were analyzed by regression analysis. As no such effects were observed, differences between study groups were tested with an independent Student's t-test and between evaluation periods were tested with a paired Student's t-test.

Results

Baseline characteristics of the study groups are listed in table 1. One patient died, not related to the implant therapy, during the first year of evaluation. The other 49 patients completed the 1-year evaluation period and wound healing was uneventful and no complications occurred during the osseointegration period. As can be read from table 1, there is an imbalance in gender ($p < 0.05$). Therefore we checked by regression analysis whether this imbalance in gender predicted changes in response variables. As no significant gender related changes were observed, we reported the effect of both treatments on the various response variables on a group level.

No implants were lost in the four implants group, while 1 implant placed in the anterior maxilla of the six implants group (position 23) was lost during the osseointegration period of three months. The implant was lost probably because it was one of the implants with a dehiscence buccally due to an inadequate bone volume at time of placement. Because a bar-supported overdenture could still be made on the remaining five implants, there was no need to replace the implant. Survival rate of implants was 100% in the four implants group, 99.3% in the six implants group. Survival rate of overdentures was 100% in both groups.

The mean loss of marginal bone between baseline (placement of the overdenture, T0) and the 1-year evaluation (T12) was 0.24 ± 0.32 mm in the four implants group and 0.25 ± 0.29 in the six implants group. No difference in bone loss at the 1-year evaluation was observed between the groups (table 2). Mean scores of the indices for plaque, calculus, gingiva and bleeding were very low, both at placement of the overdenture and after 1 year of loading, and did not differ between the groups (table 1). While the probing depth scores showed a statistical significant difference at T0 and T12 for the four and six implants group, no time-dependent significant change in probing depth was observed between the groups (table 3).

Mean scores of the questionnaires focusing on the complaints of the patients and chewing different kind of foods, together with the overall satisfaction score, are listed in table 4. In both groups, all scores had improved significantly ($p < 0.05$) between pre-treatment and post-treatment assessment (table 4), but the scores did not differ between the groups (table 5).

Table 1 Baseline characteristics of the study group with 4 implants (four implants group) and the study group with 6 implants (six implants group).

baseline characteristics	four implants group (n=25)		six implants group (n=25)	
	Mean	(sd, range)	Mean	(sd, range)
Mean age in years (sd, range)	59.7	(8.0, 46-80)	57.4	(8.7, 39-71)
Gender (number male/ female)	15/10		8/17	
Mean edentulous period upper jaw in years (sd, range)	12.6	(11.7, 1-40)	15.8	(14.4, 1-45)
Number of maxillary dentures (sd, range)	2.5	(1.6, 1-8)	2.7	(1.7, 1-8)
Age present maxillary denture (sd, range)	3.4	(2.5, 1-10)	3.7	(3.0, 1-10)
Implant dehiscence or fenestration (patients/implants)	14/32		13/33	
Sinus floor elevation surgery (patients/sinuses)	0/0		9/18	
Mean plaque-index (sd)	0.1	(0.3)	0.2	(0.5)
Mean calculus-index (sd)	0.0	(0.0)	0.0	(0.0)
Mean gingival-index (sd)	0.0	(0.0)	0.1	(0.3)
Mean bleeding-index (sd)	0.3	(0.5)	0.2	(0.4)
Mean probing depth in mm (sd)	4.3	(1.0)	3.4*	(0.9)

Differences between study groups were tested with the independent Student's t-test ($p < 0.05$)

Table 2 Mean values and standard deviations of radiographic bone loss in mm, and frequency distribution of bone loss 1 year after placement of the overdenture of the four implants group and the six implants group. The mean bone loss did not differ significantly between the groups.

mean (sd)	four implants group (n=96)	mean (sd)	six implants group (n=149)
0-0.5 mm	0.24 mm (0.32)	86%	0.25 mm (0.29)
>0.5-1.0 mm	11%		83%
>1.0-1.5 mm	2%		14%
>1.5-2.0 mm	1%		3%
>2.0 mm	0%		0%

Differences between study groups were tested with the independent Student's t-test ($p < 0.05$)

Table 3 Mean change from baseline (T12-T0) for plaque-index, calculus-index, gingival index, bleeding-index and probing depth. No time-dependent significant changes in these indices were observed between the groups.

	four implants group (n=24)	six implants group (n=25)
Plaque-index (sd)	0.2 (0.5)	0.1 (0.4)
Score 0-3		
Calculus-index (sd)	0.0 (0.0)	0.0 (0.0)
Score 0-1		
Gingival-index (sd)	0.2 (0.4)	0.2 (0.5)
Score 0-3		
Bleeding-index (sd)	0.1 (0.6)	0.2 (0.5)
Score 0-3		
Probing depth in mm (sd)	0.3 (0.8)	0.2 (0.6)

Differences between study groups were tested with the independent Student's t-test ($p < 0.05$)

Table 4 Mean score of 5 scales concerning denture complaints (possible range 0-3), mean scores of chewing ability of soft, tough and hard food (possible range 0-2), overall satisfaction score (possible range 1-10) before and 1 year after treatment. Significance level for changes between the pre-treatment and 1 year post treatment data are given.

	<i>four implants group</i>			<i>six implants group</i>		
	<i>pre-treatment (n=25)</i>	<i>1 year (n=24)</i>	<i>significance</i>	<i>pre-treatment (n=25)</i>	<i>1 year (n=25)</i>	<i>significance</i>
Functional complaints about upper denture (sd)	1.3 (0.7)	0.1 (0.1)	p<0.001	1.5 (0.5)	0.1 (0.1)	p<0.001
Functional complaints in general (sd)	1.1 (0.6)	0.1 (0.2)	p<0.001	1.2 (0.4)	0.2 (0.2)	p<0.001
Facial aesthetics (sd)	1.1 (0.9)	0.2 (0.3)	p<0.001	1.4 (0.8)	0.1 (0.2)	p<0.001
“Neutral Space” (sd)	0.6 (0.6)	0.2 (0.4)	p=0.005	0.5 (0.6)	0.2 (0.3)	p=0.005
Aesthetics (sd)	0.4 (0.4)	0.1 (0.1)	p=0.002	0.3 (0.3)	0.0 (0.1)	p<0.001
Soft food (sd)	0.4 (0.5)	0.0 (0.2)	p=0.004	0.5 (0.4)	0.0 (0.0)	p<0.001
Tough food (sd)	1.2 (0.6)	0.2 (0.4)	p<0.001	1.5 (0.4)	0.1 (0.2)	p<0.001
Hard food (sd)	1.8 (0.6)	0.3 (0.5)	p<0.001	1.9 (0.3)	0.2 (0.4)	p<0.001
Overall satisfaction score (sd)	4.3 (1.9)	8.9 (1.3)	p<0.001	4.1 (1.6)	8.9 (0.8)	p<0.001

Differences between study groups were tested with the independent Student's t-test (p<0.05)

Table 5 Mean score of 5 scales concerning the denture complaints (possible range 0-3), mean scores of chewing ability of soft, tough and hard food (possible range 0-2) and overall satisfaction score (possible range 1-10) before and 1 year after treatment. No significant differences between the four and six implants group were observed.

ns = not significant

	<i>pre-treatment</i>		<i>1 year</i>	
	<i>four implants group (n=25)</i>	<i>six implants group (n=25)</i>	<i>four implants group (n=24)</i>	<i>six implants group (n=25)</i>
Functional complaints about upper denture (sd)	1.3 (0.7)	1.5 (0.5)	0.1 (0.1)	0.1 (0.1)
Functional complaints in general (sd)	1.1 (0.6)	1.2 (0.4)	0.1 (0.2)	0.2 (0.2)
Facial aesthetics (sd)	1.1 (0.9)	1.4 (0.8)	0.2 (0.3)	1.1 (0.2)
“Neutral Space” (sd)	0.6 (0.6)	0.5 (0.6)	0.2 (0.4)	0.2 (0.3)
Aesthetics (sd)	0.4 (0.4)	0.3 (0.3)	0.1 (0.1)	0.0 (0.1)
Soft food (sd)	0.4 (0.5)	0.5 (0.4)	0.0 (0.2)	0.0 (0.0)
Tough food (sd)	1.2 (0.6)	1.5 (0.4)	0.2 (0.4)	0.1 (0.2)
Hard food (sd)	1.8 (0.6)	1.9 (0.3)	0.3 (0.5)	0.2 (0.4)
Overall satisfaction score (sd)	4.3 (1.9)	4.1 (1.6)	8.9 (1.3)	8.9 (0.8)

Differences between study groups were tested with the independent Student's t-test (p<0.05)

Discussion

Analysis of the data of this study revealed that both 4 and 6 dental implants placed in the anterior region of the edentulous maxilla, connected with a bar, supply a proper base for the support of an overdenture. In none of the parameters studied significant differences were observed between the four and six implants group.

At time of the start of the trial cone beam computer tomography (CBCT) was not available at our Medical Center and therefore the bone volume was measured by ridge mapping. Nowadays the bone volume of the maxilla would have been measured by CBCT, because it is more accurate than ridge mapping, especially in the anterior maxilla where concavities often are found (Allen and Smith 2000, Luk et al. 2011). It seems that lack of a CBCT as a diagnostic planning tool not influenced the 1-year implant survival rate which was comparable to the survival rates for implants placed in the maxilla as derived from the systematic review of Slot et al. (2010) as well as reported by Krennmair et al (2008) in a retrospective analysis for implants placed in the anterior maxilla.

Although there were several fenestrations and dehiscences buccally of the implants due to an inadequate bone volume in the maxilla and several sinus elevation surgery procedures were performed this did not affect the survival rate of the implants. Only one implant with a dehiscence was lost in the six implant group. It must be acknowledged that losing one implant in a treatment strategy with 4 implants has more consequences than in a treatment strategy with 6 implants. An extra surgical treatment procedure is usually not needed in the latter case. But, given the high implant survival rate in maxillary overdenture treatment, it can be considered as overtreatment to insert extra implants (more than 4). The mean marginal bone loss between baseline (placement of the overdenture) and the 1-year evaluation was in both groups well within the limits as formulated by Albrektsson et al. (1986). The very limited radiographic bone loss observed in our study (~0.25 mm) could be due to the neck design of the implants used (Van De Velde et al. 2010, Hermann et al. 1997, Brogгинi et al. 2003). Features of bone level implants such as platform switching and surface roughness up to the neck of the implant (OsseoSpeed™ 4.0 S dental

implants) could lead to a minimum of bone loss. Furthermore, the mean indices for plaque, calculus, gingiva and bleeding were also very low at the 1-year evaluation. They are comparable to clinical outcome of implants placed in the mandible (Guljé et al 2012; Meijer et al 2009a, b). In the latter studies the same criteria were used as in the current study. Finally, the mean peri-implant probing depths were comparable to those reported by Raghoobar et al. (2003a). The implants were surrounded with healthy peri-implant soft tissues, probably due to the strict oral hygiene regime to which patients were subjected. The significant difference in the probing depth scores between the four implants group and six implants group could not be explained by analyzing the position of the implants. Patients' satisfaction improved when wearing an implant-supported maxillary overdenture. These results were comparable to the improvement in patients' satisfaction when wearing an implant-supported mandibular overdenture (Raghoobar et al. 2003b, Stellingsma et al. 2005). Unfortunately, there are no other prospective trials in which patients' satisfaction with wearing an implant-retained maxillary overdenture was assessed. However, in a retrospective design, favourable improvements in patients' satisfaction with wearing an implant-retained maxillary overdenture were also reported for a 4 year follow up by Krennmair et al. (2008) and for a 10 year follow up by Visser et al. (2009). Krennmair et al. (2008) also mentioned that patients with an overdenture on 4 or 6 implants in the anterior maxilla are equally satisfied. In other words, patients' satisfaction seems to be irrespective of whether the bar is supported by 4 or 6 implants in the anterior maxillary region. An explanation might be that the overdenture is supported by a bar, which gives similar stability in both treatment options. This study reports on short-term results which gives limitations in drawing general conclusions. Longer follow-up periods are needed to confirm the findings of this study.

Conclusion

From this one year follow up study, it is concluded that a bar-connected maxillary overdenture on 4 or 6 implants result in a comparable treatment outcome with high implant survival, healthy peri-implant tissues and high patients' satisfaction. For reason of cost-effectiveness, the treatment with 4 implant bar-connected implants to support a maxillary overdenture is in favour of an overdenture on 6 implants connected with a bar.

References

- Albrektsson, T., Zarb, G., Worthington, P., Eriksson, A.R. (1986) The long-term efficacy of currently used dental implants: a review and proposed criteria for success. *The International Journal of Oral & Maxillofacial Implants* 1, 11-25.
- Allen, F., Smith, D.G. (2000) An assessment of the accuracy of ridge-mapping in planning implant therapy for the anterior maxilla. *Clinical Oral Implants Research* 11, 34-38.
- Andreiotelli, M., Att, W., Strub, J.R. (2010) Prosthodontic complications with implant overdentures: a systematic literature review. *The International Journal of Prosthodontics* 23, 195-203.
- Broggini, N., McManus, L.M., Hermann, J.S., Medina, R.U., Oates, T.W., Schenk, R.K., Buser, D., Mellonig, J.T., Cochran, D.L. (2003) Persistent acute inflammation at the implant-abutment interface. *Journal of Dental Research* 82, 232-237.
- Cairo, F., Sanz, I., Matesanz, P., Nieri, M., Pagliaro, U. (2012) Quality of reporting of randomized clinical trials in implant dentistry. A systematic review on critical aspects in design, outcome assessment and clinical relevance. *Journal of Clinical Periodontology* 39 (suppl. 12), 81-107.
- Esposito, M., Hirsch, J.M., Lekholm, U., Thomsen, P. (1998) Biological factors contributing to failures of osseointegrated oral implants. (I). Success criteria and epidemiology. *European Journal of Oral Sciences* 106, 527-551.
- Erdfelder, E., Faul, F., & Buchner, A. (1996). GPOWER: A general power analysis program. *Behavior Research Methods, Instruments, & Computers*, 28, 1-11.
- Fromentin, O., Lassauzay, C., Abi Nader, S., Feine, J., de Albuquerque Junior, R.F. (2010) Testing the retention of attachments for implant overdentures - validation of an original force measurement system. *Journal of Oral Rehabilitation* 37, 54-62.
- Guljé, F., Raghoobar, G.M., Ter Meulen, J.W., Vissink, A., Meijer, H.J.A. (2012) Mandibular Overdentures Supported by 6-mm Dental Implants: A 1-Year Prospective Cohort Study. *Clinical Implant Dentistry and Related Research* 14 (Suppl. 1), e59-e66.
- Hermann, J.S., Cochran, D.L., Nummikoski, P.V., Buser, D. (1997) Crestal bone changes around titanium implants. A radiographic evaluation of unloaded nonsubmerged and submerged implants in the canine mandible. *Journal of Periodontology* 68, 1117-1130.
- Heydecke, G., Boudrias, P., Awad, M.A., De Albuquerque, R.F., Lund, J.P. & Feine, J.S. (2003) Within-subject comparisons of maxillary fixed and removable implant prostheses: Patient satisfaction and choice of prosthesis. *Clinical Oral Implants Research* 14, 125-130.
- Kalk, W.W., Raghoobar, G.M., Jansma, J., Boering, G. (1996) Morbidity from iliac crest bone harvesting. *Journal of Oral and Maxillofacial Surgery* 54, 1424-1429
- Krennmair, G., Krainhöfner, M., Piehslinger, E. (2008) Implant-supported maxillary overdentures retained with milled bars: maxillary anterior versus maxillary posterior concept. A retrospective study. *The International Journal of Oral & Maxillofacial Implants* 23, 343-352.
- Löe, H., Silness, J. (1963) Periodontal disease in pregnancy. II: correlation between oral hygiene and periodontal condition. *Acta Odontologica Scandinavica* 21, 533-551.

Luk, L.C., Pow, E.H., Li, T.K., Chow, T.W. (2011) Comparison of ridge mapping and cone beam computed tomography for planning dental implant therapy. *The International Journal of Oral & Maxillofacial Implants* 26, 70-74

Mangano, C., Mangano, F., Shibli, J.A., Ricci, M., Sammons, R.L., Figliuzzi, M. (2011) Morse taper connection implants supporting "planned" maxillary and mandibular bar-retained overdentures: a 5-year prospective multicenter study. *Clinical Oral Implants Research* 22, 1117-1124.

Meijer, H.J.A., Raghoobar, G.M., Batenburg, R.H.K., Visser, A., Vissink, A. (2009a) Mandibular overdentures supported by two or four endosseous implants: a 10-year clinical trial. *Clinical Oral Implants Research* 20, 722-728.

Meijer, H.J.A., Raghoobar, G.M., Batenburg, R.H., Vissink, A. (2009b) Mandibular overdentures supported by two Brånemark, IMZ or ITI implants: a ten-year prospective randomized study. *Journal of Clinical Periodontology* 36, 799-806.

Meijndert, L., Meijer, H.J.A., Raghoobar, G.M., Vissink, A. (2004) A technique for standardized evaluation of soft and hard peri-implant tissues in partially edentulous patients. *Journal of Periodontology* 75, 646-651.

Mombelli, A., Van Oosten, M.A.C., Schürch, E., Lang, N. (1987) The microbiota associated with successful or failing osseointegrated titanium implants. *Oral Microbiology and Immunology* 2, 145-151.

Needleman, I., Chin, S., O'Brien, T., Petrie, A., Donos, N. (2012) Systematic review of outcome measurements and reference group(s) to evaluate and compare implant success and failure. *Journal of Clinical Periodontology* 39 (suppl. 12), 122-132.

Palmqvist, S., Sondell, K. & Swartz, B. (1994) Implant-supported maxillary overdentures: outcome in planned and emergency cases. *International Journal of Oral and Maxillofacial Implants* 9, 184-190.

Raghoobar, G.M., Schoen, P., Meijer, H.J., Stellingsma, K. & Vissink, A. (2003a) Early loading of endosseous implants in the augmented maxilla: a 1-year prospective study. *Clinical Oral Implants Research* 14, 697-702.

Raghoobar, G.M., Meijer, H.J.A., Van 't Hof, M.A., Stegenga, B., Vissink, A. (2003b) A randomized prospective clinical trial on the effectiveness of three treatment modalities for patients with lower denture problems. A 10 year follow-up study on patient satisfaction. *The International Journal of Oral & Maxillofacial Surgery* 32, 498-503.

Raghoobar, G.M., Meijer, H.J., Stellingsma, K., Vissink, A. (2011) Addressing the atrophied mandible: a proposal for a treatment approach involving endosseous implants. *The International Journal of Oral and Maxillofacial Implants* 26, 607-617.

Rocuzzo, M., Bonino, F., Gaudio, L., Zwahlen, M., Meijer, H.J. (2012) What is the optimal number of implants for removable reconstructions? A systematic review on implant-supported overdentures. *Clinical Oral Implants Research* 23 (suppl. 6), 229-237.

Sadowsky, S.J. (2007) Treatment consideration for maxillary implant overdentures: a systematic review. *Journal of Prosthetic Dentistry* 97, 340-348.

Sanna, A., Nuytens, P., Naert, I. & Quirynen, M. (2009) Successful outcome of splinted implants supporting a 'planned' maxillary overdenture: a retrospective evaluation and comparison with fixed full dental prosthesis. *Clinical Oral Implants Research* 20, 406-413.

Slot, W., Raghoobar, G.M., Vissink, A., Huddleston Slater, J.J., Meijer, H.J. (2010) A systematic review of implant-supported maxillary overdentures after a mean observation period of at least 1 year. *Journal of Clinical Periodontology* 37, 98-110.

Slot, W., Raghoobar, G.M., Van Dijk, G., Meijer, H.J.A. (2012) Attachment of clips in a bar-retained maxillary implant overdenture: A clinical report. *Journal of Prosthetic Dentistry* 105, 359-364

Smeets, E.C., De Jong, K.J., Abraham-Inpijn, L. (1998) Detecting the medically compromised patient in dentistry by means of the medical risk-related history. A survey of 29,424 dental patients in The Netherlands. *Preventive Medicine* 27, 530-535.

Stellingsma, K., Slagter, A.P., Stegenga, B., Raghoobar, G.M., Meijer, H.J.A. (2005) Masticatory function in patients with an extremely resorbed mandible restored with mandibular implant-retained overdentures: comparison of three types of treatment protocols. *Journal of Oral Rehabilitation* 32, 403-410.

Ten Bruggenkate, C.M., de Rijke, T.B., Kraaijenhagen, H.A., Oosterbeek, H.S. (1994) Ridge mapping. *Implant Dentistry* 3, 179-182.

Thomason, J.M., Feine, J., Exley, C., Moynihan, P., Müller, F., Naert, I., Ellis, J.S., Barclay, C., Butterworth, C., Scott, B., Lynch, C., Stewardson, D., Smith, P., Welfare, R., Hyde, P., McAndrew, R., Fenlon, M., Barclay, S., Barker, D. (2009) Mandibular two implant-supported overdentures as the first choice standard of care for edentulous patients. *The York Consensus Statement. British Dental Journal* 207, 185-186.

Van Assche, N., Michels, S., Quirynen, M., Naert, I. (2012) Extra short dental implants supporting an overdenture in the edentulous maxilla: a proof

of concept. *Clinical Oral Implants Research* 23, 567-576

Van de Velde, T., Collaert, B., Sennerby, L., De Bruyn, H. (2010) Effect of implant design on preservation of marginal bone in the mandible. *Clinical Implant Dentistry and Related Research* 12, 134-141.

Van Waas, M.A.J. (1990) The influence of clinical variables on patients' satisfaction with complete dentures. *Journal of Prosthetic Dentistry* 63, 307-310.

Vercruyssen, M., Marcelis, K., Coucke, W., Naert, I., Quirynen, M. (2010) Long-term, retrospective evaluation (implant and patient-centred outcome) of the two-implants-supported overdenture in the mandible. Part 1: survival rate. *Clinical Oral Implants Research* 21, 357-365.

Vervoorn, J.M., Duinkerke, A.S.H., Luteijn, F., Van Der Poel, A.C.M. (1988) Assessment of denture satisfaction. *Community Dentistry and Oral Epidemiology* 16, 364-367.

Visser, A., Raghoobar, G.M., Meijer, H.J., Vissink, A. (2009) Implant-retained maxillary overdentures on milled bar suprastructures: a 10-year follow-up of surgical and prosthetic care and aftercare. *The International Journal of Prosthodontics* 22, 181-192.

Widbom, C., Söderfeldt, B., & Kronström, M. (2005) A retrospective evaluation of treatments with implant-supported maxillary overdentures. *Clinical Implant Dentistry and Related Research* 7, 166-172.

Chapter 4

**A comparison between
4 and 6 implants in the
maxillary posterior region
to support an overdenture;
1-year results from a
randomized controlled
trial**

This chapter is an edited version of the manuscript.

Slot, W., Raghoobar, G.M., Vissink, A., Meijer, H.J. (2013).

A comparison between four and six implants in the maxillary posterior region to support an overdenture; 1-year results from a randomized controlled trial.

Clinical Oral Implant Research. [Epub ahead of print].

Abstract

Objective

To compare the treatment outcome of four versus six bar-connected implants in the posterior region of the maxilla to support an overdenture during a 1-year follow-up period.

Materials and methods

Sixty-six edentulous patients with an insufficient amount of bone volume in the maxilla to place implants were asked to participate in this study. Randomization assigned patients to either 4 or 6 implants. In all patients a maxillary sinus floor elevation procedure with bone from the iliac crest was performed and after a 3 month healing period 4 or 6 dental implants were inserted in the maxillary posterior region in a one-stage procedure. After 3 months of osseointegration, a bar-supported overdenture was constructed. Implant survival, overdenture survival, clinical scores, peri-implant bone height changes and patients' satisfaction were assessed. Study analysis was performed according a non-inferiority design.

Results

All patients completed the one-year follow-up. After a functional period of 1 year, implant survival was 100% in the four implants group and 99.5% in the six implants group. Overdenture survival was 100% in both groups. Mean clinical scores were very low and did not significantly differ between groups. Mean marginal bone resorption was 0.35 ± 0.31 mm and 0.46 ± 0.34 mm in the four and six implants group, respectively. Patients' satisfaction improved significantly in both groups, but did not differ between groups.

Conclusion

A bar-supported overdenture on 4 implants in the posterior maxillary region is not inferior to an overdenture supported by six bar-connected dental implants.

Introduction

Edentulous patients often experience problems with their complete dentures. A lack of stability and retention of the denture, together with a decreased chewing ability, are the main complaints of these patients (Van Waas 1990). Compared to conventional dentures, implant overdenture therapy has been widely demonstrated to improve function, comfort, diet and patients' satisfaction (Fromentin et al. 2010, Van Assche et al. 2012). Furthermore, comparing a fixed full prosthesis with an implant-supported overdenture, ability to speak, ease of cleaning, aesthetics and general satisfaction were shown to be the factors with the most influence on the choice in favour of an implant-supported overdenture (Heydecke et al. 2003).

With respect to the overdenture in the maxilla, quality and volume of remaining bone, and number and position of implants are factors which influence success of implants and prostheses (Esposito et al. 1998). In a systematic review of maxillary overdentures, Slot et al. (2010) stated a survival rate of 98.2% in case of 6 implants and a bar anchorage, a survival rate of 96.3% in case of 4 implants and a bar anchorage, and a survival rate of 95.2% in case of 4 implants and a ball anchorage, after 1-year of treatment.

When comparing survival of implant-supported maxillary overdentures, it is important to make the distinction between "planned" and "unplanned" maxillary overdentures. An "unplanned" overdenture is an emergency situation, in which the placement of an insufficient number and/or previous implant failures made a fixed full dental prosthesis an unfeasible option. A "planned" overdenture, instead, is the result of a planned treatment protocol, including an accurate pre-operative radiographic assessment of the residual edentulous ridges, and the use of pre-defined operative criteria such as a minimum number implants with sufficient length and diameter inserted with the correct position/inclination (Krennmair et al. 2008; Sanna et al. 2009; Mangano et al. 2010). The literature describes a better survival rate for planned cases than for unplanned cases (Palmqvist et al. 1994, Widbom et al. 2005, Sanna et al. 2009). The survival rates mentioned in the study of Slot et al. (2010) were on planned cases.

For the edentulous mandible there are evidence-based treatment guidelines involving stage of resorption and number of implants (Thomason et al. 2009, Raghoobar et al. 2011) as well as that long-term results are available (Meijer et al. 2009a, b, Vercruyssen et al. 2010). For maxillary overdenture therapy treatment guidelines are missing (Sadowsky 2007, Slot et al. 2010, Andreiotelli et al. 2010). Since results of six bar-connected and four bar-connected implants seem both favourable and resemble each other, the question raises if 6 implants are necessary for maxillary implant-supported overdenture treatment.

There are no treatment guidelines in which position the implants are preferably placed. In case of implant-supported overdenture therapy in the maxilla it seems that, when sufficient bone in the anterior region in combination with enough space in the overdenture to cover an attachment system, there seems to be an advantage in placing implants in the anterior region, because of less morbidity and treatment time (Slot et al. 2012b). However, patients with problems of lack of retention and stability of their conventional overdenture in the maxilla are often edentulous for a long period and most of the time there is, due to resorption, not enough bone to place implants anteriorly. Therefore in a considerable group of patients the implants have to be placed in the posterior part of the maxilla after a bone augmentation procedure. This augmentation (maxillary sinus floor elevation surgery) is mostly done with iliac crest bone (Raghoobar et al. 2001). The purpose of this 1-year randomized controlled trial was to compare the treatment outcome (implant survival, overdenture survival, peri-implant health, peri-implant bone loss, patients' satisfaction) of "planned" maxillary overdentures on four versus six bar-connected implants in the posterior region of the maxilla. To control the experiment, the comparison of the number of implants was done in the same region of the maxilla and with the same type of occlusion for all participants. It was chosen for the posterior region in need of a sinus elevation procedure to insert implants of conventional length and for a balanced occlusion with an implant-supported overdenture in the lower jaw.

Material and methods

Patient selection

Consecutive fully edentulous patients referred to the Department of Oral and Maxillofacial Surgery (University Medical Center Groningen, the Netherlands) suffering from lack of retention and stability of both upper denture and lower denture, were considered for inclusion if they fulfilled the following criteria: at least 18 years of age, capable of understanding and giving informed consent, at least one year edentulous in the maxilla and mandible, insufficient volume of bone of the maxilla (< 3 mm in width, and < 5 mm in height). Next to this, enough bone to place implants in the mandibular interforaminal region and sufficient interocclusal space for a bar-supported attachment system in this region had to be present for a patient to be eligible to be included in this study. Excluded were patients with American Society of Anaesthesiologists score (ASA) \geq III (Smeets et al. 1998), who were smoking, with a history of radiotherapy in the head and neck region or a history of pre-prosthetic surgery or previous implant placement. Baseline characteristics of included patients are listed in table 1. The patients were informed about the study on overdenture treatment with insertion of 4 or 6 dental implants in the maxilla and about the extra efforts associated with the study (questionnaires, evaluation visits) before they signed an informed consent. The study was approved by the Medical Ethical Committee of the University Medical Center Groningen (ABR NL32503.042.11). Of all patients, orthopantomograms, lateral cephalograms and postero-anterior oblique radiographs were made to assess the volume of the maxillary alveolar bone, the dimensions of the maxillary sinus, and the anteroposterior relationship of the maxilla to the mandible. The radiographs were also screened for sinus pathology. In all cases a diagnostic setup of the planned overdenture was made to get more insight in the available dimensions for the bar-supported attachment system and overdenture. At time of the start of the trial cone beam computer tomography (CBCT) was not available at our Medical Center and therefore the bone volume was estimated in the posterior region. Nowadays, pre-surgical bone volume of the maxilla would have been measured with the aid of a CBCT. It could be that in a small number of patients a sinus elevation procedure would not have been necessary or that implants could have been placed in the anterior region, resulting in less morbidity for the patient.

Table 1 Baseline characteristics of the study group with 4 implants (four implants group) and the study group with 6 implants (six implants group).

baseline characteristics	four implants group (n=33)	six implants group (n=33)
	Mean age in years (sd, range)	61.6 (7.1, 43-74)
Gender (number male/ female)	23/10	10/23
Mean edentulous period upper jaw in years (sd, range)	23.5 (12.8, 1-45)	21.3 (13.5, 1-50)
Number of maxillary dentures (sd, range)	2.9 (1.3, 1-7)	3.0 (1.4, 1-6)
Age present maxillary denture (sd, range)	5.7 (4.5, 1-16)	5.5 (6.0, 1-25)

Treatment procedure

All surgical procedures were performed by one experienced oral and maxillofacial surgeon. The prosthetic procedures were accomplished by three experienced prosthodontists and manufacturing of the superstructure was done by a single experienced dental laboratory.

Surgical procedures

An augmentation procedure of the maxillary sinus was performed under general anesthesia. Large autogenous cancellous bone grafts were harvested from the superior anterior medial part of the iliac crest. The palatal mucosa was incised horizontally, just below the top of the alveolar crest. After vertical releasing incisions had been made in the buccal mucosa, a mucoperiosteal flap was raised to expose the alveolar crest and the lateral aspect of the maxilla. The lateral wall of the maxillary sinus was fenestrated with a round bur. Subsequently, the sinus membrane was raised and the mobilized part of the lateral sinus wall, together with the raised sinus membrane, was rotated medially and upwards. A monocortical iliac bone block was placed in the sinus with the cortical layer upwards. The remaining space between the iliac bone block and the alveolar crest was filled with cancellous bone. Finally, the wound was closed with horizontal mattress sutures, and a bone graft was harvested from the anterior iliac crest (Raghoobar et al. 1997, 2001).

For 2 weeks after surgery, the patient was not allowed to wear the denture. Then, acrylic resin was removed from the denture in those areas which could contact the grafted sites, where after the denture was relined with a resilient liner (Soft liner; GC Corporation, Tokyo, Japan).

After a 3-months healing period, 4 or 6 dental implants (Straumann Standard SLA® implants; Ø 4.1 mm, length 12 mm, RN, Institut Straumann AG, Basel, Switzerland) were inserted in the maxilla in a one-stage procedure. The implants were placed into the grafted sites in predefined positions (positions 16, middle of 15/14, 13, 23, middle of 24/25, 26 in the six implants group and positions 16, 13, 23, 26 in the four implants group) with a surgical template in a one-stage procedure. None of the implants were placed in the anterior region of the maxilla. Neither 3-dimensional sinus diagnosis nor 3-dimensional pre-surgical treatment planning was performed in the study. Because all the patients

were fully edentulous, 4 implants for overdenture treatment were placed simultaneously in the mandible.

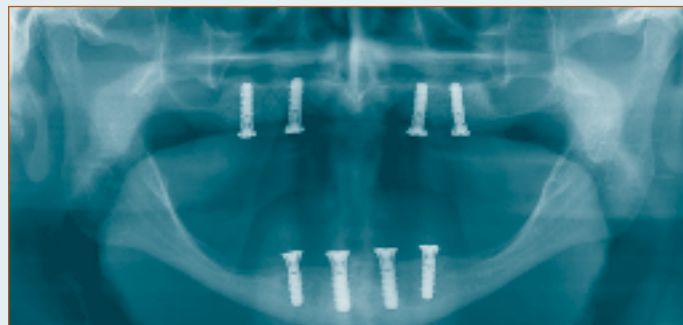
Two weeks after implant placement, the patient was allowed to wear the dentures again after adjustment of the denture in the area of the implants and relining with a resilient lining material. The patient was given oral hygiene instructions to clean the healing abutments.

Patients received amoxicillin for both the sinus elevation procedure and the implant placement procedure, starting one hour preoperatively (3 g Clamoxyl®, GlaxoSmithKline, Utrecht, the Netherlands) orally and continued (500 mg Clamoxyl®; GlaxoSmithKline, Utrecht, the Netherlands) for seven days 3 times daily after surgery. Postoperatively the patient received a 0.2% chlorhexidine mouth rinse (Corsodyl®; GlaxoSmithKline, Utrecht, the Netherlands) 1 minute, 2 times daily for 2 weeks.

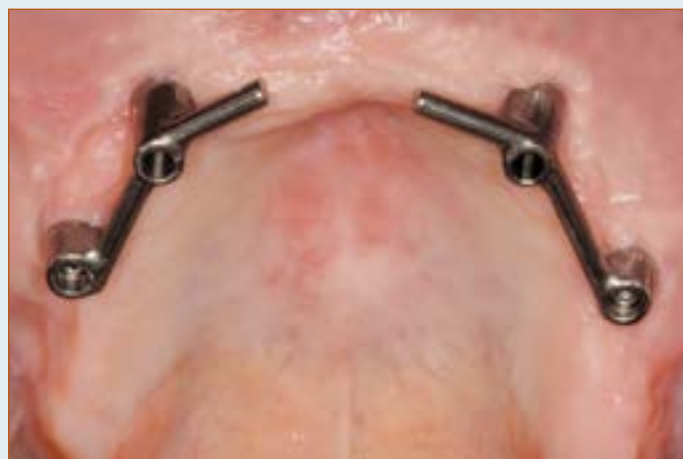Prosthetic procedure

After a three-months osseointegration period, prosthetic procedures were initiated. Custom acrylic resin impression trays (Lightplast base plates; Dreve Dentamid GmbH, Unna, Germany) were fabricated with openings for screw-retained impression copings. Impression copings were attached to the abutments with the integral positioning screw. The final complete arch impression was made with polyether material (Impregum F; 3M ESPE, St. Paul, Minn). A composite resin record base (Lightplast base plates; Dreve Dentamid GmbH, Unna, Germany) with a wax occlusion rim was used to determine the occlusal vertical dimension and to record the maxillo-mandibular relationship. Acrylic resin artificial teeth (Ivoclar SR Orthotyp DCL and Ivoclar Vivodent PE, Ivoclar Vivadent AG, Schaan, Liechtenstein) were selected and arranged on the record base for a trial arrangement. A bilateral balanced occlusion concept was followed. The final superstructure consisted of a milled titanium bar, screw-retained to abutments, and an overdenture with built-in cobalt chromium reinforcement structure and gold retentive clips attached to it (Slot et al. 2012a). The design of the overdentures was with full coverage of the alveolar process, but without palatal coverage in the maxilla. All implants were splinted with a bar. The patient was instructed in hygiene procedures associated with the dentures and the bars and scheduled for routine maintenance recalls (figures 1-2).

Figure 1 The four implants group

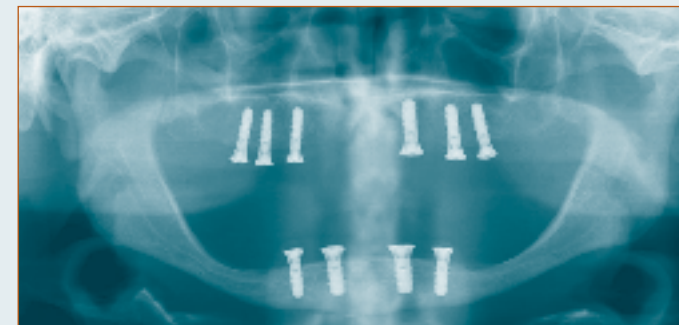


1a Panoramic radiograph of a patient with 4 implants in the maxillary posterior region.

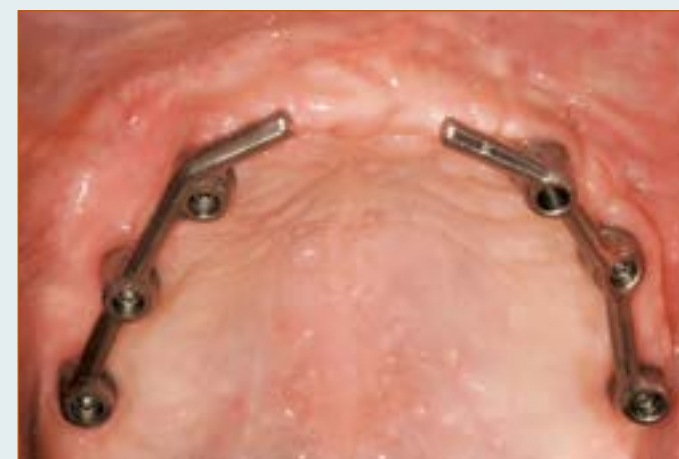

1b Intra-oral view on bar-superstructure on 4 implants in the posterior region.

Figure 2 The six implants group



2a Panoramic radiograph of a patient with 6 implants in the posterior maxillary region.



2b Intra-oral view on bar-superstructure on 6 implants in the posterior region.

Outcome measures

Primary outcome measure was change of peri-implant bone level. Secondary outcome measures were implant survival, overdenture survival, soft tissue conditions (plaque index, presence of calculus, gingiva index, sulcus bleeding index and pocket probing depth). These parameters were scored at placement of the overdenture and after 12 months of loading. Patients' satisfaction was scored before treatment and at 12 months after placement of the overdenture.

Change of peri-implant bone level

Standardized intraoral radiographs were taken after placement of the overdenture and 12 months thereafter. The radiographs were taken according to a long-cone paralleling technique with an individualized X-ray holder described by Meijndert et al. (2004). The custom made X-ray holder could be attached on the bar to secure standardized depiction of the peri-implant marginal bone level. The digital images were analyzed using computer software (Biomedical Engineering, University Medical Center Groningen, the Netherlands) to perform linear measurements on digital radiographs. The known implant dimension was used as a reference to transform the linear measurements into mm. Reference line for bone level evaluation was the outer border of the neck of the implant. Mesial and distal bone changes in this region were considered as peri-implant bone change and were defined as the difference in bone height between the photograph taken at overdenture placement and the photograph taken 12 months after placement of the overdenture.

Implant survival

Implant survival was defined as the percentage of implants initially placed that was still present at follow-up. Loose and lost implants were scored any time after placement.

Overdenture survival

Survival of maxillary overdentures was defined as the percentage of overdentures initially placed that was still present at follow-up. Remake of the maxillary overdenture was scored any time after placement.

Clinical parameters

For presence of plaque, the index according to Mombelli et al. (1987) was used (score 0: no detection of plaque, score 1: plaque can be detected by running a probe across the smooth marginal surface of the abutment and implant, score 2: plaque can be seen by the naked eye, score 3: abundance amount of plaque). The presence of calculus (score 1) or the absence of calculus (score 0) was scored. To qualify the degree of peri-implant inflammation, the modified Löe and Silness index (1963) was used (score 0: normal peri-implant mucosa, score 1: mild inflammation; slight change in colour, slight oedema, score 2: moderate inflammation; redness, oedema and glazing, score 3: severe inflammation; marked redness and oedema, ulceration). For bleeding, the bleeding index according to Mombelli et al. (1987) was used (score 0: no bleeding when using a periodontal probe, score 1: isolated bleeding spots visible, score 2: a confluent red line of blood along the mucosa margin, score 3: heavy or profuse bleeding). Probing depth was measured at four sites of each implant (mesial, labial, distal, and lingual) by using a manual periodontal probe (Williams Colour-Coded Probe; Hu-Friedy, Chicago, IL, USA) after removal of the bar; the distance between the marginal border of the mucosa and the tip of the periodontal probe was scored as the probing depth.

Patients' satisfaction

Patients' satisfaction with their overdenture was assessed using a validated questionnaire (Vervoorn et al. 1988). This questionnaire focused on complaints and consisted of 54 questions. Each question could be addressed to one out of six specific scales.

The six scales are:

- a. Nine items concerning functional problems of the lower denture
- b. Nine items concerning functional problems of the upper denture
- c. Eighteen items concerning functional problems complaints in general
- d. Three items concerning facial aesthetics
- e. Three items concerning accidental lip, cheek, and tongue biting ("neutral space")
- f. Twelve items concerning esthetics of the denture

The extent of each specific complaint could be expressed on a four-point rating scale (0 = no complaints, 1 = little, 2 = moderate, 3 = severe complaints). Because functional complaints of the lower denture were not the aim of the study, results of scale A were not analyzed.

All patients were requested to fill out a “Chewing ability” questionnaire (Stellingsma et al. 2005). In this questionnaire patients gave their opinion about the ability to chew nine different kinds of food on a three-point rating scale (0 = good, 1 = moderate, 2 = bad). The items were grouped into three scales, being soft food, tough food and hard food. Next to these questionnaires, the patients’ overall denture satisfaction was expressed on a 10-point rating scale (1 = very bad to 10 = excellent).

Patients’ satisfaction was scored before treatment and 12 months after placement of the overdenture.

Statistical analysis

It was assumed that an implant-supported overdenture on 4 implants was not inferior to one supported by 6 implants (non-inferiority hypothesis). The sample size was calculated with the program G*power version 2 (Erdfelder et al. 1996). Peri-implant bone changes have a major predictive value with respect to success and survival of the implants. If the same functional loading is exerted on 4 implants instead of on 6 implants, bone loss could be a possible result. For this reason peri-implant bone changes is regarded as primary outcome for the power analysis. A difference of at least 0.4 mm in bone height (measured on standardized radiographs, with a standard deviation of 0.5 mm) between the four implants group and six implants group after twelve months was expected to differentiate between the two groups, based on the findings of a study on maxillary implant supported overdentures (Raghoobar et al. 2003). A t-test given $\alpha = 0.05$ with a power of 90% combined with the expected effect size for 2 independent means gives a sample size of 28 persons in each group. To deal with withdrawal of individuals in the study, the number of participants was determined to be 33 persons per group. Patients were randomly allocated to one of the treatment groups by lot with the use of sealed envelopes. Thirty-three notes with the words “four implants” and 33 notes with the words “six implants” were put into 66 identical, sequentially numbered, non-

transparent envelopes. No stratification was performed. All envelopes were irreversibly sealed, only to be opened prior to the fabrication of the surgical stent.

Data collection and analysis of the radiographs were done by the same observer. The worst score per implant of the clinical and radiographic parameters were used in the data analysis. Data were analyzed using the Statistical Package for Social sciences (version 18.0, SPSS, IBM Corporation, Chicago, IL, USA). In all tests a significance level of 0.05 was chosen. To see whether the data were normally distributed the frequency analyses plotted in a histogram. To test whether the result from the frequency analyses differed significantly from a normal distribution qq-normal plots and Shapiro-Wilk test were carried out. Data were normally distributed. Differences between study groups were tested with an independent Student’s t-test and between evaluation periods were tested with a paired Student’s t-test.

Results

Between January 2006 and December 2009 a total of 66 consecutive patients (33 in each group) fulfilling the inclusion criteria was included in this trial. There was no randomization on gender, what makes the difference in male female ratio between the groups. Baseline characteristics of the study groups are listed in table 1. All 66 patients completed the 1-year evaluation period.

Wound healing was uneventful and no complications occurred during the osseointegration period.

No implants were lost in the four implants group, while 1 implant of the six implants group (position 16) was lost during the osseointegration period. Because a bar-supported overdenture could still be made on the remaining five implants, there was no need to replace this implant. Survival rate of implants was 100% and 99.5% in the four and six implants group, respectively. Survival rate of overdentures was 100% in both groups. Mean loss of marginal bone between baseline (placement of the overdenture) and the 1-year evaluation was 0.35 ± 0.31 mm and 0.46 ± 0.34 in the four and six implants group, respectively, and did not significantly differ between the groups (table 2). Mean scores of indices for plaque, calculus, gingiva and bleeding were very low, both at placement of the overdenture and after 1 year of loading, and again did not significantly differ between the groups, neither did the pocket probing depth (table 3). Although no significant changes were observed in indices for plaque, calculus, gingiva and bleeding in the four implants group, at the 1 year evaluation period indices for plaque ($p=0.034$), gingiva ($p=0.010$) and bleeding ($p=0.018$) had significantly increased in the six implants group..

Mean scores of the questionnaires focusing on denture complaints, chewing ability and overall satisfaction score of patients are listed in table 4 and showed that these scores had improved significantly between pre-treatment and 1 year evaluation in both groups. These scores did not differ significantly between the groups (table 5).

Table 2 Mean values and standard deviations of radiographic bone loss in mm, and frequency distribution of bone loss 1 year after placement of the overdenture of the four implants group and the 6 implants group. The mean bone loss did not differ significantly between the groups.

	four implants group (n=132)	six implants group (n=197)
mean (sd)	0.35 mm (0.31)	0.46 mm (0.34)
0-0.5 mm	79%	91%
>0.5-1.0 mm	15%	6%
>1.0-1.5 mm	6%	3%
>1.5-2.0 mm	0%	0%

Table 3 Mean values and standard deviations of plaque-index (possible score 0-3), calculus-index (possible score 0-1), gingival-index (possible score 0-3), bleeding-index (possible score 0-3) and probing depth in mm at placement of the overdenture (T0) and 1 year after placement of the overdenture (T12). No significant differences were observed between the two groups.

	T0		T12	
	four implants group (n=33)	six implants group (n=33)	four implants group (n=33)	six implants group (n=33)
Plaque-index (sd)	0.1 (0.3)	0.1 (0.3)	0.2 (0.4)	0.3 (0.5)
Calculus-index (sd)	0.0 (0.0)	0.0 (0.0)	0.1 (0.2)	0.0 (0.0)
Gingival-index (sd)	0.1 (0.3)	0.0 (0.2)	0.2 (0.4)	0.3 (0.5)
Bleeding-index (sd)	0.3 (0.5)	0.3 (0.5)	0.5 (0.5)	0.6 (0.6)
Probing depth in mm (sd)	4.5 (0.8)	4.1 (1.1)	4.8 (0.9)	4.4 (1.2)

Table 4 Mean score of 5 scales concerning denture complaints (possible range 0-3), mean scores of chewing ability of soft, tough and hard food (possible range 0-2), overall satisfaction score (possible range 1-10) before and 1 year after treatment. Significance level for changes between the pre-treatment and 1 year post treatment data are given.

	four implants group				six implants group		
	pre-treatment (n=33)	1 year (n=33)	significance		pre-treatment (n=33)	1 year (n=33)	significance
Functional complaints about upper denture (sd)	1.5 (0.6)	0.2 (0.2)	p<0.001		1.7 (0.5)	0.2 (0.2)	p<0.001
Functional complaints in general (sd)	1.0 (0.5)	0.1 (0.1)	p<0.001		1.1 (0.5)	0.2 (0.2)	p<0.001
Facial aesthetics (sd)	1.1 (0.9)	0.2 (0.5)	p<0.001		1.1 (1.0)	0.2 (0.4)	p<0.001
“Neutral Space” (sd)	0.6 (0.6)	0.3 (0.4)	p=0.004		0.5 (0.7)	0.5 (0.5)	ns
Aesthetics (sd)	0.4 (0.3)	0.1 (0.2)	p<0.001		0.4 (0.4)	0.1 (0.2)	p=0.001
Soft food (sd)	0.4 (0.4)	0.0 (0.1)	p<0.001		0.4 (0.4)	0.0 (0.1)	p<0.001
Tough food (sd)	1.0 (0.5)	0.1 (0.2)	p<0.001		1.2 (0.6)	0.1 (0.3)	p<0.001
Hard food (sd)	1.8 (0.4)	0.2 (0.5)	p<0.001		1.8 (0.5)	0.4 (0.7)	p<0.001
Overall satisfaction score (sd)	4.4 (1.7)	9.0 (0.8)	p<0.001		3.9 (1.5)	8.7 (1.0)	p<0.001

Table 5 Mean score of 5 scales concerning the denture complaints (possible range 0-3), mean scores of chewing ability of soft, tough and hard food (possible range 0-2) and overall satisfaction score (possible range 1-10) before and 1 year after treatment. No significant differences between the four and six implants group were observed.

ns = not significant

	pre-treatment			1 year		
	four implants group (n=33)	six implants group (n=33)	significance	four implants group (n=33)	six implants group (n=33)	significance
Functional complaints about upper denture (sd)	1.5 (0.6)	1.7 (0.5)	ns	0.2 (0.2)	0.2 (0.2)	ns
Functional complaints in general (sd)	1.0 (0.5)	1.1 (0.5)	ns	0.1 (0.1)	0.2 (0.2)	ns
Facial aesthetics (sd)	1.1 (0.9)	1.1 (1.0)	ns	0.2 (0.5)	0.2 (0.4)	ns
“Neutral Space” (sd)	0.6 (0.6)	0.5 (0.7)	ns	0.3 (0.4)	0.5 (0.5)	ns
Aesthetics (sd)	0.4 (0.3)	0.4 (0.4)	ns	0.1 (0.2)	0.1 (0.2)	ns
Soft food (sd)	0.4 (0.4)	0.4 (0.4)	ns	0.0 (0.1)	0.0 (0.1)	ns
Tough food (sd)	1.0 (0.5)	1.2 (0.6)	ns	0.1 (0.2)	0.1 (0.3)	ns
Hard food (sd)	1.8 (0.4)	1.8 (0.5)	ns	0.2 (0.5)	0.4 (0.7)	ns
Overall satisfaction score (sd)	4.4 (1.7)	3.9 (1.5)	ns	9.0 (0.8)	8.7 (1.0)	ns

Discussion

Analysis of the data of this study revealed that both 4 and 6 dental implants placed in the posterior region of the edentulous maxilla, connected with a bar, were shown to supply a proper base for the support of an overdenture. Both concepts scored equally with regard to implant survival, overdenture survival, hard and soft tissue peri-implant parameters, denture complaints, chewing ability and overall patients' satisfaction.

The implant survival of 100% and 99.5% is comparable with the numbers in the systematic review of Slot et al (2010) and in the prospective study of Slot et al. (2012b), although in the latter study a natural dentition in the mandible was present. It must be acknowledged that losing one implant in a treatment strategy with 4 implants has more consequences than in a treatment strategy with 6 implants. An extra surgical treatment procedure is usually not needed in the latter case. But, given the high implant survival rate in maxillary overdenture treatment, it can be considered as overtreatment to insert extra implants (more than 4) and based on cost effectiveness is also advantageous to place 4 implants.

Mean marginal bone loss between baseline (placement of the overdenture) and the 1-year evaluation was in both groups well within the limits as formulated by Albrektsson et al. (1986). Furthermore, the mean indices for plaque, calculus, gingiva and bleeding were also very low at the 1-year evaluation and comparable to bone loss observed after implants placed in the mandible (Meijer et al 2009a, b, Guljé et al 2012a, b). In these studies the same criteria were used as in the current study. Most of the implants were surrounded with healthy peri-implant soft tissues at the 1-year evaluation, probably because of the strict oral hygiene regime to which patients were subjected and the mean peri-implant probing depths were comparable to those reported by Raghoobar et al. (2003) and Slot et al. (2012b). At the 1-year evaluation there is no difference between 4 and 6 implants with respect to the radiographical outcome. However, it might be possible that over time 6 implants are more difficult to clean if the implants are placed without sufficient inter-implant distance as is in line with the observed, although minor, increase of the scores on the plaque, gingival and bleeding indices in the six implants group. This could result in peri-implant

mucositis and peri-implantitis. With 4 implants inserted in the same available location, there is less such a risk.

Patients' satisfaction improved in both groups when wearing an implant-supported maxillary overdenture. Results are comparable with the improvement in patients' satisfaction in the prospective study of Slot et al. (2012b), in which the same questionnaires were used. In a retrospective design, favorable improvements in patients' satisfaction with wearing an implant-retained maxillary overdenture were also reported for a 4 year follow-up by Krennmair et al. (2008) and for a 10 year follow up by Visser et al. (2009). In their retrospective study, Krennmair et al. (2008) also mentioned that patients with an overdenture on 4 or 6 implants in the posterior maxilla are equally satisfied. In other words, patients' satisfaction seems to be irrespective of whether the bar is supported by 4 or 6 implants in the posterior maxillary region. An explanation might be that the overdenture is supported by a bar, which gives similar stability in both treatment options. This study reports on short-term results, which gives limitations in drawing general conclusions. Longer follow-up periods are needed to confirm the findings of this study.

There is increasing evidence that short implants in the posterior region of the maxilla reveal a survival and success rate which is comparable to implants of conventional length (Guljé et al. 2012). It can be assumed that for a number of patients a sinus elevation procedure can be avoided by the use of short implants, leading to less discomfort and a shortened treatment procedure.

From this one-year follow-up study, it is concluded that a bar-connected maxillary overdenture on 4 or 6 implants result in a comparable treatment outcome with high implant survival, healthy peri-implant tissues and high patients' satisfaction. For reason of cost-effectiveness, the treatment with four bar-connected implants to support a maxillary overdenture is in favour of an overdenture on 6 implants connected with a bar.

Acknowledgements

We would like to thank all the participants of this study. We also like to thank Maxillofacial Dental Laboratory G. van Dijk, Groningen, the Netherlands, for the accurateness the implant supported-overdentures were manufactured.

Conflict of interest and sources of funding statement

The authors declare that there are no conflicts of interest in this study. External funding was obtained by an unrestricted grant from Institut Straumann AG, Basel, Switzerland.

References

- Albrektsson, T., Zarb, G., Worthington, P., Eriksson, A.R. (1986) The long-term efficacy of currently used dental implants: a review and proposed criteria for success. *The International Journal of Oral & Maxillofacial Implants* 1, 11-25.
- Andreiotelli, M., Att, W., Strub, J.R. (2010) Prosthodontic complications with implant overdentures: a systematic literature review. *The International Journal of Prosthodontics* 23, 195-203.
- Esposito, M., Hirsch, J.M., Lekholm, U., Thomsen, P. (1998) Biological factors contributing to failures of osseointegrated oral implants. (I). Success criteria and epidemiology. *European Journal of Oral Sciences* 106, 527-551.
- Erdfelder, E., Faul, F., & Buchner, A. (1996). GPOWER: A general power analysis program. *Behavior Research Methods, Instruments, & Computers*, 28, 1-11.
- Fromentin, O., Lassauzay, C., Abi Nader, S., Feine, J., de Albuquerque Junior, R.F. (2010) Testing the retention of attachments for implant overdentures - validation of an original force measurement system. *Journal of Oral Rehabilitation* 37, 54-62.
- Guljé, F., Raghoebar, G.M., Ter Meulen, J.W., Vissink, A., Meijer, H.J.A. (2012) Mandibular Overdentures Supported by 6-mm Dental Implants: A 1-Year Prospective Cohort Study. *Clinical Implant Dentistry and Related Research* 14 (Suppl. 1), e59-66.
- Guljé, F., Abrahamsson, I., Chen, S., Stanford, C., Zadeh, H., Palmer, R. (2012) Implants of 6 mm vs. 11 mm lengths in the posterior maxilla and mandible: a 1-year multicenter randomized controlled trial. *Clinical Oral Implants Research* doi: 10.1111/clr.12001. [Epub ahead of print].
- Heydecke, G., Boudrias, P., Awad, M.A., De Albuquerque, R.F., Lund, J.P. & Feine, J.S. (2003) Within-subject comparisons of maxillary fixed and removable implant prostheses: Patient satisfaction and choice of prosthesis. *Clinical Oral Implants Research* 14, 125-130.
- Krennmair, G., Krainhöfner, M., Piehslinger, E. (2008) Implant-supported maxillary overdentures retained with milled bars: maxillary anterior versus maxillary posterior concept. A retrospective study. *The International Journal of Oral & Maxillofacial Implants* 23, 343-352.
- Löe, H., Silness, J. (1963) Periodontal disease in pregnancy. II: correlation between oral hygiene and periodontal condition. *Acta Odontologica Scandinavica* 21, 533-551.
- Mangano, C., Mangano, F., Shibli, J.A., Ricci, M., Sammons, R.L., Figliuzzi, M. (2011) Morse taper connection implants supporting "planned" maxillary and mandibular bar-retained overdentures: a 5-year prospective multicenter study. *Clinical Oral Implants Research* 22, 1117-1124.
- Meijer, H.J.A., Raghoebar, G.M., Batenburg, R.H.K., Visser, A., Vissink, A. (2009a) Mandibular overdentures supported by two or four endosseous implants: a 10-year clinical trial. *Clinical Oral Implants Research* 20, 722-728.
- Meijer, H.J.A., Raghoebar, G.M., Batenburg, R.H., Vissink, A. (2009b) Mandibular overdentures supported by two Brånemark, IMZ or ITI implants: a ten-year prospective randomized study. *Journal of Clinical Periodontology* 36, 799-806.

Meijndert, L., Meijer, H.J.A., Raghoobar, G.M., Vissink, A. (2004) A technique for standardized evaluation of soft and hard peri-implant tissues in partially edentulous patients. *Journal of Periodontology* 75, 646-651.

Mombelli, A., Van Oosten, M.A.C., Schürch, E., Lang, N. (1987) The microbiota associated with successful or failing osseointegrated titanium implants. *Oral Microbiology and Immunology* 2, 145-151.

Palmqvist, S., Sondell, K. & Swartz, B. (1994) Implant-supported maxillary overdentures: outcome in planned and emergency cases. *International Journal of Oral and Maxillofacial Implants* 9, 184-190.

Raghoobar, G.M., Vissink, A., Reintsema, H., Batenburg, R.H. (1997) Bone grafting of the floor of the maxillary sinus for the placement of endosseous implants. *British Journal of Oral and Maxillofacial Surgery* 35, 119-125.

Raghoobar, G.M., Timmenga, N.M., Reintsema, H., Stegenga, B., Vissink, A. (2001) Maxillary bone grafting for the insertion of endosseous implants: results after 12-124 months. *Clinical Oral Implants Research* 12, 279-286

Raghoobar, G.M., Schoen, P., Meijer, H.J., Stellingsma, K. & Vissink A. (2003) Early loading of endosseous implants in the augmented maxilla: a 1-year prospective study. *Clinical Oral Implants Research* 14, 697-702.

Raghoobar, G.M., Meijer, H.J., Stellingsma, K., Vissink, A. (2011) Addressing the atrophied mandible: a proposal for a treatment approach involving endosseous implants. *The International Journal of Oral and Maxillofacial Implants* 26, 607-617.

Sadowsky, S.J. (2007) Treatment consideration for maxillary implant overdentures: a systematic review. *Journal of Prosthetic Dentistry* 97, 340-348.

Sanna, A., Nuytens, P., Naert, I. & Quirynen, M. (2009) Successful outcome of splinted implants supporting a 'planned' maxillary overdenture: a retrospective evaluation and comparison with fixed full dental prosthesis. *Clinical Oral Implants Research* 20, 406-413.

Slot, W., Raghoobar, G.M., Vissink, A., Huddleston Slater, J.J., Meijer, H.J. (2010) A systematic review of implant-supported maxillary overdentures after a mean observation period of at least 1 year. *Journal of Clinical Periodontology* 37, 98-110.

Slot, W., Raghoobar, G.M., Van Dijk, G., Meijer, H.J.A. (2012a) Attachment of clips in a bar-retained maxillary implant overdenture: a clinical report. *Journal of Prosthetic Dentistry* 107, 353-357

Slot, W., Raghoobar, G.M., Vissink, A., Meijer, H.J. (2012b) Maxillary Overdentures Supported by Anteriorly or Posteriorly Placed Implants Opposed by a Natural Dentition in the Mandible: a 1-Year Prospective Case Series Study. *Clinical Implant Dentistry and Related Research* doi: 10.1111/j.1708-8208.2012.00459.x. [Epub ahead of print]

Smeets, E.C., De Jong, K.J., Abraham-Inpijn, L. (1998) Detecting the medically compromised patient in dentistry by means of the medical risk-related history. A survey of 29,424 dental patients in The Netherlands. *Preventive Medicine* 27, 530-535.

Stellingsma, K., Slagter, A.P., Stegenga, B., Raghoobar, G.M., Meijer, H.J.A. (2005) Masticatory function

in patients with an extremely resorbed mandible restored with mandibular implant-retained overdentures: comparison of three types of treatment protocols. *Journal of Oral Rehabilitation* 32, 403-410.

Thomason, J.M., Feine, J., Exley, C., Moynihan, P., Müller, F., Naert, I., Ellis, J.S., Barclay, C., Butterworth, C., Scott, B., Lynch, C., Stewardson, D., Smith, P., Welfare, R., Hyde, P., McAndrew, R., Fenlon, M., Barclay, S., Barker, D. (2009) Mandibular two implant-supported overdentures as the first choice standard of care for edentulous patients. *The York Consensus Statement. British Dental Journal* 207, 185-186.

Van Assche, N., Michels, S., Quirynen, M., Naert, I. (2012) Extra short dental implants supporting an overdenture in the edentulous maxilla: a proof of concept. *Clinical Oral Implants Research* 23, 567-576.

Van Waas, M.A.J. (1990) The influence of clinical variables on patients' satisfaction with complete dentures. *Journal of Prosthetic Dentistry* 63, 307-310.

Vercruyssen, M., Marcelis, K., Coucke, W., Naert, I., Quirynen, M. (2010) Long-term, retrospective evaluation (implant and patient-centred outcome) of the two-implants-supported overdenture in the mandible. Part 1: survival rate. *Clinical Oral Implants Research* 21, 357-365.

Vervoorn, J.M., Duinkerke, A.S.H., Luteijn, F., Van Der Poel, A.C.M. (1988) Assessment of denture satisfaction. *Community Dentistry and Oral Epidemiology* 16, 364-367.

Visser, A., Raghoobar, G.M., Meijer, H.J., Vissink, A. (2009) Implant-retained maxillary overdentures on milled bar suprastructures: a 10-year follow-up

of surgical and prosthetic care and aftercare. *The International Journal of Prosthodontics* 22, 181-192.

Widbom, C., Söderfeldt, B. & Kronström, M. (2005) A retrospective evaluation of treatments with implant-supported maxillary overdentures. *Clinical Implant Dentistry and Related Research* 7, 166-172.

Chapter 5

Maxillary overdentures supported by anteriorly or posteriorly placed implants opposed by a natural dentition in the mandible: a 1-year prospective case series study

This chapter is an edited version of the manuscript.

Slot, W., Raghoobar, G.M., Vissink, A., Meijer, H.J. (2012).

Maxillary overdentures supported by anteriorly or posteriorly placed implants opposed by a natural dentition in the mandible: a 1-year prospective case series study.

Clinical Implant Dentistry and Related Research. [Epub ahead of print].

Abstract

Background

For maxillary overdenture therapy, treatment guidelines are missing. There is a need for longitudinal studies.

Purpose

The purpose of this 1-year prospective case series study was to assess the treatment outcome of maxillary overdentures supported by 6 dental implants opposed by natural antagonistic teeth in the mandible.

Materials and methods

Fifty patients were treated with a maxillary overdenture supported by 6 dental implants, either placed in the anterior region (n=25 patients) or in the posterior region (n=25 patients). Items of evaluation were: survival of implants, condition of hard and soft peri-implant tissues and patients' satisfaction.

Results

One year implant survival rate was 98% in the Anterior-group and 99.3% in the Posterior-group. Mean radiographic bone loss in the Anterior- and Posterior group after one year of loading was 0.22 mm and 0.50 mm, respectively. Mean scores for plaque, calculus, gingiva, bleeding and pocket probing depth were low, and patients' satisfaction was high, with no differences between the groups.

Conclusion

6 dental implants placed in either the anterior region or the posterior region of the edentulous maxilla, connected with a bar, and opposed by antagonistic teeth in the mandible, supply a proper base for the support of an overdenture.

Introduction

Edentulous patients often experience problems with their complete dentures. Lack of stability and retention of their denture, together with a decreased chewing ability are the main complaints of these patients (van Waas, 1990). Implant-supported overdentures are a successful therapy. Currently, there are evidence-based treatment guidelines for the edentulous mandible involving stage of resorption and number of implants (Raghoebar et al. 2011, Thomason et al. 2012) as well as that long-term results are available of mandibular overdenture therapy (Meijer et al. 2009, Vercruyssen et al. 2010). For maxillary overdenture therapy, however, treatment guidelines are missing and there is still a need for longitudinal studies with clear and standardized evaluation criteria to establish evidence-based treatment planning principles (Sadowsky, 2007, Slot et al. 2010, Andreiotelli et al. 2010).

Quality and volume of remaining bone, and number and position of implants are factors which influence success of implants and prosthesis in the upper jaw (Esposito et al. 1998). In a systematic review with meta analysis on maxillary overdentures (Slot et al. 2010) the authors stated a survival rate of 98.2% per year in case of 6 implants and a bar anchorage, a survival rate of 96.3% in case of 4 implants and a bar anchorage, and a survival rate of 95.2% in case of 4 implants and a ball anchorage. However, no distinction was made between positions of implants in the various studies reviewed in that systematic review. A retrospective study by Krennmair et al. (2008), that compared anterior with posterior implants in the edentulous maxilla, did not find differences in implant outcome. Sanna et al. (2009) performed a retrospective evaluation of implant-supported overdentures in the maxilla. A number of these patients had a full or partial dentition in the mandible. The cumulative survival rate after 10 years of function was 99.3% if 4 to 6 interconnected implants supported the overdenture.

Antagonistic natural teeth might be a risk factor for maxillary overdentures, but is not a contraindication. A limited number of studies stated a relationship between antagonistic natural teeth and a maxillary overdenture, but could not find a significant difference (Ohkubo et al. 2010). The reason

for being a risk factor might be a greater mastication force and harmful lateral forces to implants, due to an altered occlusion concept (Chan et al. 1996, Åstrand et al. 1996, Kahnberg et al. 1999). A bilateral balanced occlusion concept of conventional removable dentures is often used in overdenture therapy (Carlsson, 2009). In case of natural teeth in the antagonistic jaw, this is however often not possible because the occlusion is dictated by the anatomic form and (compromised) position of the natural teeth. It is advocated to apply an occlusal situation which is comfortable to the patient, stable and without interferences in that case, rather than any preconceived philosophy of occlusion (Taylor et al. 2000).

The purpose of this 1-year prospective case series study was to assess the treatment outcome (survival of implants, condition of hard and soft peri-implant tissues, patients' satisfaction) of maxillary overdentures supported by 6 anteriorly or 6 posteriorly placed implants opposed by natural antagonistic teeth in the mandible.

Material and methods

Patient Selection

Between January 2006 and December 2009 consecutive patients were selected with an edentulous maxilla and with natural antagonistic teeth in the mandible (minimum of 6 teeth present from left lower cuspid to right lower cuspid) from the Department of Oral and Maxillofacial Surgery, University Medical Center Groningen, Groningen, the Netherlands. The patients had been referred by their general dental practitioner because of a reduced stability and insufficient retention of their maxillary conventional denture. Inclusion criteria for the study were an edentulous period in the upper jaw of at least one year, presence of healthy mandibular teeth, and a healthy periodontium. Excluded were patients with ASA score \geq III, Smeets et al. (1998) who were smoking, with a history of radiotherapy in the head and neck region, with a history of preprosthetic surgery or previous implant placement. The patients were informed about the treatment option of overdenture treatment with placing 6 implants in the maxilla and about the extra efforts associated with the study (questionnaires, evaluation visits) before they gave their written consent to participate. The study was approved by the Medical Ethical Committee of the University Medical Center Groningen.

Allocation to Study Groups

Orthopantomograms, lateral cephalograms, and postero-anterior oblique radiographs were made to assess the height of the maxillary alveolar bone, the dimensions of the maxillary sinus, and the anteroposterior relationship of the maxilla to the mandible. The radiographs were also screened for sinus pathology. In all cases, a diagnostic setup of the planned overdenture was made to get more insight in the available dimensions for the bar-supported attachment system and overdenture. If there was an adequate bone volume in the region between the first premolars in the anterior area of the maxilla (height at least 12 mm, measured on a radiograph; width at least 3 mm, estimated by manual palpation) to place the implants and a sufficient intermaxillary space for a bar-supported attachment system in this region, patients were assigned to the so-called “Anterior-group”. If there was not an

adequate bone volume in the anterior area of the maxilla or not a sufficient intermaxillary space for a bar-retained attachment system in this region, patients were assigned to the so-called “Posterior-group”.

Treatment Procedures

All surgical procedures were performed by one experienced oral and maxillofacial surgeon. The prosthetic procedure was accomplished by three experienced prosthodontists and manufacturing of the superstructure was done by a single experienced dental laboratory.

Surgical Procedure in the Anterior-group

6 dental implants with a length of at least 11 mm and a diameter of 4 mm were inserted in the anterior region of the maxilla in a two-stage procedure (OsseoSpeed™ 4.0 S dental implants, Astra Tech AB, Mölndal, Sweden). The implants were placed in predefined positions with a surgical template in a two-stage procedure. Small dehiscences were covered with bone harvested from the mandibular retromolar area and anorganic bovine bone (Geistlich Bio-Oss®, Geistlich Pharma AG, Wolhusen, Switzerland) and subsequently with a resorbable membrane (Geistlich Bio-Gide®, Geistlich Pharma AG, Wolhusen, Switzerland). If the most distally implants had to be placed in an anterior extension of the maxillary sinus, local sinus floor elevation surgery was performed in that region with bone harvested from the mandibular retromolar area. Two weeks after implant placement, the patient was allowed to wear the dentures again after adjustment of the prostheses in the area of the implants and relining with a resilient lining material (Soft liner; GC Corporation, Tokyo, Japan). After a 3-months osseointegration period, second stage surgery was performed and healing abutments (Uni Healing Abutments, Astra Tech AB, Mölndal, Sweden) were placed. The denture was adjusted again in the area of the healing abutments and relined with a resilient lining material. The patient was given oral hygiene instructions.

Surgical Procedure in the Posterior-group

An augmentation procedure was performed under general anesthesia, and a bone graft was harvested from the anterior iliac crest (Raghoobar et al. 1997, 2001). For 2 weeks, the patient was not allowed to wear the denture.

Then, acrylic resin was removed from the denture in those areas which could contact the grafted sites. Furthermore, the denture was relined with a resilient liner (Soft liner; GC Corporation, Tokyo, Japan). After a 3-months healing period, 6 dental implants were inserted in the maxilla in a one-stage procedure (Straumann Standard SLA® implants; Ø 4.1 mm, length 12 mm, RN, Institut Straumann AG, Basel, Switzerland). The implants were placed into the grafted sites in the posterior area with a surgical template in a one-stage procedure. Two weeks after implant placement, the patient was allowed to wear the dentures again after adjustment of the denture in the area of the implants and relining with a resilient lining material. The patient was given oral hygiene instructions.

In the anterior region bone-level implants were used. The reason for this is because small dehiscences could occur. These had to be covered with bone harvested from the mandibular retromolar area and anorganic bovine bone and subsequently with a resorbable membrane. In the posterior region soft tissue-level implants were used. Because of the already performed augmentation procedure with a bone graft harvested from the anterior iliac crest, the assumption was made that there would be enough bone at implant placement.

Prosthetic Procedure

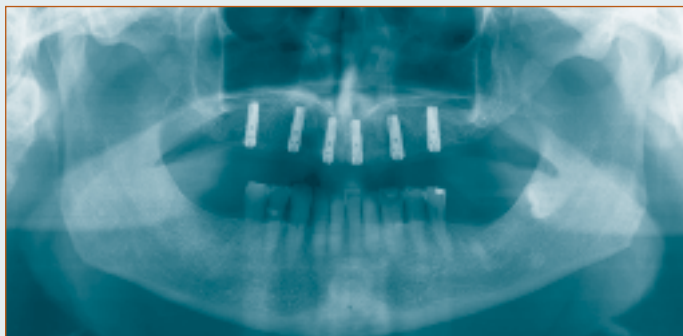
In both groups, after a 3-months osseointegration period of the implants, the prosthesis fabrication procedures were initiated. Custom acrylic resin impression trays (Lightplast base plates; Dreve Dentamid GmbH, Unna, Germany) were fabricated with openings for screw-retained impression copings. In the Anterior-group, the healing abutments were replaced by 20° Uni Abutments (Astra Tech AB, Mölndal, Sweden). Impression copings were attached to the abutments (Anterior-group) or directly to the implants (Posterior-group) with the integral positioning screw. The final complete arch impression was made with polyether material (Impregum F; 3M ESPE, St. Paul, Minn). A composite resin record base (Lightplast base plates; Dreve Dentamid GmbH, Unna, Germany) with a wax occlusion rim was used to determine the occlusal vertical dimension and to record the maxillomandibular relationship. Acrylic resin artificial teeth

(Ivoclar SR Orthotyp DCL and Ivoclar Vivodent PE, Ivoclar Vivadent AG, Schaan, Liechtenstein) were selected and arranged on the record base for a trial arrangement. A predefined occlusion concept was not followed; the artificial teeth were occluding the antagonistic posterior natural teeth without disturbing interferences with lateral or protrusive excursions. The final superstructure consisted of a milled titanium bar, screw-retained to abutments or implants, and an overdenture with built-in cobalt chromium reinforcement structure and gold retentive clips attached to it (Slot et al. 2012). A partial mandibular denture was made simultaneously with the maxillary overdenture in case of a shortened dental arch and when desired by the patient. The patient was instructed in hygiene procedures associated with the dentures and the bars and scheduled for routine maintenance recalls (figures 1-2).

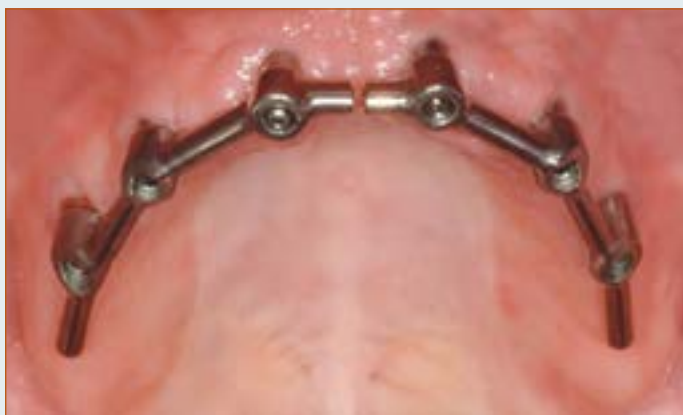Analysis

Outcome measures were implant survival and the change of peri-implant bone-level from loading of the implants by the overdenture to 12 months follow-up. Next to this, soft tissue conditions (plaque index, presence of calculus, gingiva index, sulcus bleeding index and pocket probing depth) were scored after placement of the overdenture and 12 months thereafter. Differences in patients' satisfaction between before treatment and 12 months after placement of the overdenture were scored. Occlusal parameters were scored at the 12-months' evaluation period.

Figure 1 The anterior group

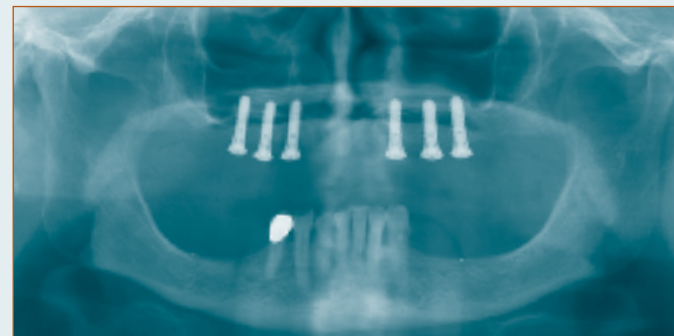


1a Panoramic radiograph of a patient with 6 dental implants in the anterior region of the maxilla.

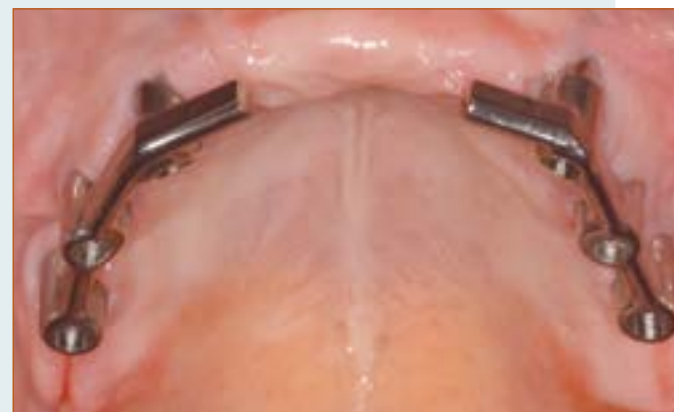

1b Intra-oral view of a bar-superstructure on 6 dental implants in the anterior region.

Figure 2 The posterior group



2a Panoramic radiograph of a patient with 6 dental implants in the posterior region of the maxilla.



2b Intra-oral view of a bar-superstructure on 6 dental implants in the posterior region.

Implant Survival

Loose and lost implants were scored any time after placement. Mobility of implants was checked at each evaluation period after removing of the bar.

Change of Peri-Implant Bone-Level

Standardized intraoral radiographs were taken after placement of the overdenture and 12 months thereafter. The radiographs were taken according to a long-cone paralleling technique with a custom made standardized x-ray device (Meijndert et al. 2004). This device could be attached on the bar to secure standardized depiction of the peri-implant marginal bone level. The digital images were analyzed using computer software to perform linear measurements on digital radiographs. The known implant dimension was used as a reference to transform the linear measurements into mm. Mesial and distal bone changes in this region were considered as peri-implant bone changes and were defined as the difference in bone height between the radiograph taken immediate after loading of the implants with the overdenture and the radiograph 12 months later.

Clinical Parameters

For presence of plaque, the index according to Mombelli et al. (1987) was used (score 0: no detection of plaque, score 1: plaque can be detected by running a probe across the smooth marginal surface of the abutment and implant, score 2: plaque can be seen by the naked eye, score 3: abundance amount of plaque). The presence of calculus (score 1) or the absence of calculus (score 0) was scored. To qualify the degree of peri-implant inflammation, the modified Löe and Silness index (1963) was used (score 0: normal peri-implant mucosa, score 1: mild inflammation; slight change in colour, slight oedema, score 2: moderate inflammation; redness, oedema and glazing, score 3: severe inflammation; marked redness and oedema, ulceration). For bleeding, the bleeding index according to Mombelli et al. (1987) was used (score 0: no bleeding when using a periodontal probe, score 1: isolated bleeding spots visible, score 2: a confluent red line of blood along the mucosa margin, score 3: heavy or profuse bleeding). Probing depth was measured at 4 sites of each implant (mesially, labially, distally, lingually) by using a periodontal probe (Merit B, Hu Friedy, Chicago, USA) after

removal of the bar; the distance between the marginal border of the mucosa and the tip of the periodontal probe was scored as the probing depth.

Patients' Satisfaction

Patients' satisfaction with their overdenture was assessed using a validated questionnaire (Vervoorn et al. 1988). This questionnaire focused on complaints and consisted of 54 items.

It was originally divided into six scales:

- a. Nine items concerning functional problems of the lower denture
- b. Nine items concerning functional problems of the upper denture
- c. Eighteen items concerning functional problems complaints in general
- d. Three items concerning facial aesthetics
- e. Three items concerning accidental lip, cheek, and tongue biting ("neutral space")
- f. Twelve items concerning esthetics of the denture

The extent of each specific complaint could be expressed on a four-point rating scale (0 = no complaints, 1 = little, 2 = moderate, 3 = severe complaints). Because there was no lower denture present, scale A was left out of the questionnaire.

All patients were requested to fill out a "Chewing ability" questionnaire (Stellingsma et al. 2005). In this questionnaire patients gave their opinion about the ability to chew nine different kinds of food on a three-point rating scale (0 = good, 1 = moderate, 2 = bad). The items were grouped into three scales, being soft food, tough food and hard food. Next to these questionnaires, the patient's overall denture satisfaction was expressed on a 10-point rating scale (1 = very bad to 10 = excellent).

Patients' satisfaction was scored before start of the treatment and 12 months after placement of the overdenture.

Occlusal Parameters

Occlusion of each patient was scored at the 12-months' evaluation period. The following subdivisions were made:

- presence or absence of a complete natural dentition in the mandible (a complete natural dentition was defined as presence of at least a mandibular arch of first left mandibular molar to first right mandibular molar)

- presence or absence of at least three occluding pairs on each side
- presence or absence of a bilaterally balanced occlusion

Data Collection and Statistical Analysis

Data collection and analysis of the radiographs was done by the same observer. The worst score per implant of the clinical and radiographic parameters were used in the data analysis. Survival was presented at implant level. Differences between evaluation periods were tested with a paired Student's *t*-test. Differences between study groups were tested with an independent Student's *t*-test. Analysis was done with PASW Statistics 18.0 (SPSS Inc.: An IBM Company, IBM Corporation, Chicago, IL, USA). In all tests a significance level of 0.05 was chosen.

Results

Fifty patients were included in the study during the selection period, of which 25 in the Anterior-group and 25 in the Posterior-group. All patients originally included in the Anterior-group could be treated in the anterior region; this means that there appeared to be enough bone after reflection of the soft tissues for initial stability of the implants. Baseline characteristics of the study groups are depicted in table 1. All these patients completed the one-year' evaluation period. Post surgery, no complications were reported related to insertion of the implants or to the donor site of bone. Three implants were lost in two patients of the Anterior-group, both during the osseointegration period. Because a bar-superstructure could still be made, it was decided not to replace the implants. One implant was lost during the osseointegration period in the Posterior-group. Also in this case, the lost implant was not replaced. One year post loading survival rate of implants was 98% in the Anterior-group and 99.3% in the Posterior-group. Survival rate of overdentures was 100% in both groups. The mean loss of marginal bone between base-line (loading of the implants) and the one-year evaluation was 0.22 mm (sd = 0.29) in the Anterior-group and 0.50 mm (sd = 0.68) in the Posterior-group (table 2). The mean scores of the indices for plaque, calculus, gingiva and bleeding were very low (table 3). The mean probing depth (table 3) was 4.3 mm at the one-year' evaluation period in both groups. Mean scores of the questionnaires focusing on the complaints of the patients and chewing different kind of foods, together with the overall satisfaction score, are listed in table 4. All scores improved significantly between pre-treatment and post-treatment assessment, except for "Aesthetics" in the Anterior-group and "Neutral space" in the Posterior group. Differences in patients' satisfaction between the study groups at the pre-treatment and the post-treatment evaluation period are listed in table 5. After one year there were no significant differences between the groups. Mean score of functional complaints upper denture, mean scores of chewing ability of soft, tough and hard food and the overall satisfaction score, 1 year after loading of the implants, of the different subdivisions of occlusal state of the combined study groups are listed in table 6. There were no significant differences in patients' satisfaction in any of the subdivisions.

Table 1 Baseline characteristics of the study group with anterior implants (Anterior-group) and the study group with posterior implants (Posterior-group).

baseline characteristics	anterior-group (n=25)		posterior-group (n=25)	
	Mean age in years (sd, range)	58.4	(8.3, 42-73)	59.1
Gender (number male/ female)	14/11		10/15	
Mean edentulous period upper jaw in years (sd, range)	11.1	(11.7, 1-40)	20.6	(12.3, 2-40)
Number of maxillary dentures (sd, range)	2.4	(2.0, 1-10)	3.3	(1.7, 1-8)
Age present maxillary denture (sd, range)	2.4	(2.0, 1-10)	3.3	(1.7, 1-8)
State of natural dentition lower jaw (no. of patients)				
- presence of complete natural dentition: yes/no	9/16		7/18	
- presence of at least 3 occluding pairs on each side: yes/no	14/11		13/12	
- presence of bilaterally balanced occlusion: yes/no	3/22		2/23	

Table 3 Mean values and standard deviations of plaque-index (possible score 0-3), calculus-index (possible score 0-1), gingival-index (possible score 0-3), bleeding-index (possible score 0-3) and probing depth in mm after placement of the overdenture (T0), 1 year after placement of the overdenture (T12) and possible significant differences between the time periods of the study group with anterior implants (Anterior-group) and the study group with posterior implants (Posterior-group).

	anterior-group		posterior-group		significance
	T0 (n=25)	T12 (n=25)	T0 (n=25)	T12 (n=25)	
Plaque-index (sd)	0.2 (0.5)	0.2 (0.4)	0.1 (0.3)	0.2 (0.4)	ns
Calculus-index (sd)	0.0 (0.0)	0.0 (0.0)	0.0 (0.0)	0.0 (0.0)	ns
Gingival-index (sd)	0.1 (0.2)	0.2 (0.4)	0.1 (0.3)	0.1 (0.3)	ns
Bleeding-index (sd)	0.4 (0.6)	0.3 (0.5)	0.7 (0.6)	0.6 (0.6)	ns
Probing depth in mm (sd)	4.2 (1.0)	4.3 (1.0)	4.2 (0.9)	4.3 (1.0)	ns

Table 2 Mean values (standard deviations) of bone loss in mm with frequency distribution 1 year after loading of the implants of the study group with anterior implants (Anterior-group) and the study group with posterior implants (Posterior-group).

mean (sd)	anterior-group (n=147 implants)	posterior-group (n=149 implants)
0-0.5 mm	0.22 mm (0.29)	0.50 mm (0.68)
>0.5-1.0 mm	79%	91%
>1.0-1.5 mm	15%	6%
>1.5-2.0 mm	6%	3%
>2.0 mm	0%	0%
	1%	4%

ns = not significant

Table 4 Mean score of 5 scales concerning the denture complaints (possible range 0-3), mean scores of chewing ability of soft, tough and hard food (possible range 0-2), the overall satisfaction score (possible range 1-10) before and 1 year after treatment and possible significant differences between the time periods of the study group with anterior implants (Anterior-group) and the study group with posterior implants (Posterior-group).

ns = not significant

	<i>anterior-group</i>			<i>posterior-group</i>		
	<i>pre-treatment (n=25)</i>	<i>1 year (n=25)</i>	<i>significance</i>	<i>pre-treatment (n=25)</i>	<i>1 year (n=25)</i>	<i>significance</i>
Functional complaints about upper denture (sd)	1.2 (0.5)	0.1 (0.1)	p<0.001	1.6 (0.4)	0.2 (0.2)	p<0.001
Functional complaints in general (sd)	0.9 (0.5)	0.1 (0.1)	p<0.001	1.1 (0.6)	0.1 (0.1)	p<0.001
Facial aesthetics (sd)	0.7 (0.8)	0.1 (0.2)	p<0.001	1.2 (1.0)	0.2 (0.5)	p<0.001
“Neutral Space” (sd)	0.7 (0.6)	0.2 (0.3)	p=0.001	0.5 (0.9)	0.4 (0.5)	ns
Aesthetics (sd)	0.2 (0.3)	0.1 (0.3)	ns	0.4 (0.4)	0.1 (0.2)	p=0.001
Soft food (sd)	0.2 (0.3)	0.0 (0.0)	p=0.003	0.5 (0.5)	0.0 (0.0)	p<0.001
Tough food (sd)	1.1 (0.6)	0.1 (0.3)	p<0.001	1.1 (0.6)	0.1 (0.2)	p<0.001
Hard food (sd)	1.8 (0.4)	0.2 (0.5)	p<0.001	1.7 (0.4)	0.3 (0.4)	p<0.001
Overall satisfaction score (sd)	4.3 (1.4)	8.8 (0.9)	p<0.001	3.6 (1.6)	8.6 (0.9)	p<0.001

Table 5 . Mean score of 5 scales concerning the denture complaints (possible range 0-3), mean scores of chewing ability of soft, tough and hard food (possible range 0-2), the overall satisfaction score (possible range 1-10) before and 1 year after treatment and possible significant differences between the study group with anterior implants (Anterior-group) and the study group with posterior implants (Posterior-group) before treatment and at 1 year.

ns = not significant

	<i>pre-treatment</i>			<i>1 year</i>		
	<i>anterior-group (n=25)</i>	<i>posterior-group (n=25)</i>	<i>significance</i>	<i>anterior-group (n=25)</i>	<i>posterior-group (n=25)</i>	<i>significance</i>
Functional complaints about upper denture (sd)	1.2 (0.5)	1.6 (0.4)	p=0.012	0.1 (0.1)	0.2 (0.2)	ns
Functional complaints in general (sd)	0.9 (0.5)	1.1 (0.6)	ns	0.1 (0.1)	0.1 (0.1)	ns
Facial aesthetics (sd)	0.7 (0.8)	1.2 (1.0)	ns	0.1 (0.2)	0.2 (0.5)	ns
“Neutral Space” (sd)	0.7 (0.6)	0.5 (0.9)	ns	0.2 (0.3)	0.4 (0.5)	ns
Aesthetics (sd)	0.2 (0.3)	0.4 (0.4)	p=0.036	0.1 (0.3)	0.1 (0.2)	ns
Soft food (sd)	0.2 (0.3)	0.5 (0.5)	p=0.023	0.0 (0.0)	0.0 (0.0)	ns
Tough food (sd)	1.1 (0.6)	1.1 (0.6)	ns	0.1 (0.3)	0.1 (0.2)	ns
Hard food (sd)	1.8 (0.4)	1.7 (0.4)	ns	0.2 (0.5)	0.3 (0.4)	ns
Overall satisfaction score (sd)	4.3 (1.4)	3.6 (1.6)	ns	8.8 (0.9)	8.6 (0.9)	ns

Table 6 Mean score of functional complaints upper denture (possible range 0-3), mean scores of chewing ability of soft, tough and hard food (possible range 0-2), the overall satisfaction score (possible range 1-10) 1 year after treatment of participants with complete or incomplete natural dentition in the mandible, 6 occluding pairs or less than 6 occluding pairs, and a bilaterally balanced occlusion or not an bilaterally balanced occlusion and possible significant differences of the combined study groups with anterior implants and posterior implants.

ns = not significant

	<i>state of natural dentition in the lower jaw</i>				<i>number of occluding pairs</i>				<i>occlusal concept</i>				
	<i>complete (n=16)</i>		<i>incomplete (n=34)</i>		<i>six (n=27)</i>		<i>less than six (n=23)</i>		<i>balanced (n=5)</i>		<i>not balanced (n=45)</i>		
				<i>significance</i>				<i>significance</i>					<i>significance</i>
Functional complaints about upper denture (sd)	0.2 (0.2)		0.2 (0.1)	ns	0.1 (0.1)		0.2 (0.1)	ns	0.2 (0.1)		0.2 (0.1)		ns
Soft food (sd)	0.0 (0.0)		0.0 (0.0)	ns	0.0 (0.0)		0.0 (0.0)	ns	0.0 (0.0)		0.0 (0.0)		ns
Tough food (sd)	0.1 (0.6)		0.1 (0.6)	ns	0.1 (0.1)		0.0 (0.0)	ns	0.1 (0.1)		0.1 (0.2)		ns
Hard food (sd)	0.1 (0.2)		0.3 (0.5)	ns	0.3 (0.1)		0.2 (0.1)	ns	0.4 (0.5)		0.2 (0.4)		ns
Overall satisfaction score (sd)	8.7 (0.9)		8.8 (0.9)	ns	9.0 (0.9)		8.5 (0.8)	ns	9.0 (0.7)		8.7 (0.9)		ns

Discussion

This study demonstrated that 6 dental implants placed in either the anterior region or posterior region of the edentulous maxilla, connected with a bar, and opposed to antagonistic natural teeth in the mandible, supply a proper base for the support of a maxillary implant-supported overdenture. The one-year implant survival rate was high in both regions, peri-implant health was high, peri-implant bone loss was low and patients were very satisfied.

The systematic review with meta-analysis of Slot et al. (2010), stated there are no studies specifically addressing survival rate of implants in the edentulous maxilla opposed by natural antagonistic teeth in the mandible as most studies do not reveal the state of opposing dentition or it is just mentioned that all kinds of opposing dentition are present. The same systematic review reported a one-year implant survival rate of 98.2% for 6 implants with a bar-supported overdenture with all kinds of opposing dentitions. The one-year implant survival rates of the present study are comparable. Sanna et al. (2009) reported a cumulative survival rate of 99.3% after 10 years of function. This survival rate is comparable with the one-years' results of the present study. Krennmair et al. (2008) compared survival rates of implants placed in anterior regions (4 implants) and implants placed in posterior regions (6 to 8 implants) in a retrospective study. One-year survival rates were 98.4% for the anterior region and 97.4% for the posterior region. Again, these numbers are comparable to the results of the present study. This outcome suggests that the type of antagonistic dentition does not have influence on the outcome of implants in the maxilla.

Due to the different position of the implants in the study groups and the different implant systems used, it was decided not to compare survival rates, and clinical and radiographic scores of the different groups with each other. Comparison of patients' satisfaction, on the other hand, seems justified, because overdenture therapy as such is evaluated.

The mean loss of marginal bone between base-line (loading of the implants) and the one-year evaluation was 0.22 mm (sd = 0.29) in the Anterior-group and 0.50 mm (sd = 0.68) in the Posterior-group. This is well within the limits as formulated by Albrektsson et al. (1986) being 1 mm bone loss

during the first year and subsequent annually 0.1 mm. This phenomenon of up to one mm bone loss has been described by Adell et al. (1981) and is thought to be related to maturation of bone after implant placement and adaptation of bone to withstand functional forces. In the present study bone loss during the first year was very small which could be due to the neck design of the implants used (van de Velde et al. 2010, Hermann et al. 1997, Brogini et al. 2003). OsseoSpeed™ 4.0 S dental implants have a platform switch and surface roughness up to the neck of the implant and Straumann Standard SLA® implants have no implant-abutment connection, thus avoiding a possible microgap at the bone level.

The mean indices for plaque, calculus, gingiva and bleeding were shown to be very low at the one-year evaluation. The scores are comparable to those reported by Gulje et al. (2011) and Meijer et al. (2009) in which the same criteria were used, and in which also OsseoSpeed™ 4.0 S dental implants and Straumann Standard SLA® implants were used, although applied in the mandible. The mean probing depth was 4.3 mm at the one-year' evaluation period in both groups. This depth is not much different as reported in other studies and is accompanied with healthy peri-implant soft tissues. The strict oral hygiene regime to which patients were subjected to, resulted in healthy peri-implant tissues. Although compared with results of patients who are edentulous in both jaws, it seems that the presence of natural antagonistic teeth does not have a negative influence on the outcome of implants. It must be noted, however, that patients could only be included in the study if healthy natural antagonistic teeth and a healthy periodontium were present. The mean scores of the two questionnaires and the overall satisfaction score improved significantly from before implant treatment to the 1-year evaluation in both groups (table 4). Studies on patients' satisfaction with maxillary overdentures, evaluated with validated questionnaires, are not known. So, results of the present study cannot be compared with other studies on implant-supported maxillary overdentures, although it has been mentioned in general terms in other studies that patients' satisfaction is high (Krennmair et al. 2008, Visser et al. 2009). The same questions as used in the current study were asked for mandibular implant overdentures and showed comparable results (Stellingsma et al. 2005, Raghoobar et al. 2003). It seems that with maxillary overdenture treatment comparable successful

results can be achieved as with mandibular overdenture treatment. There were no significant differences in patients' satisfaction between the Anterior- and Posterior-group at the post-treatment evaluation period (table 5).

In the retrospective study of Krennmair et al. (2008), it was stated that after a mean evaluation period of 42 months no significant differences in subjective satisfaction scores could be found between a group with implants in the anterior maxillary region and a group with implants in the posterior maxillary region. Patients seem to be equally satisfied, irrespective of the region where the implants are placed. The reason could be that the overdenture is supported by a bar on 6 implants in both regions, which gives comparable stability. It is striking that no significant differences in patients' satisfaction were noted with respect to the number of antagonistic teeth, the number of occluding pairs and the presence or absence of a bilaterally balanced occlusion (table 6). It could be that the impact of a stable denture, with good support and retention, has such a high impact on satisfaction that other factors are rated as minor inconveniences. It does not seem to be of influence if there are less remaining antagonistic teeth, a lower number of occluding pairs and the absence of a bilaterally balanced occlusion. A longer follow-up period is, however, needed to confirm the findings in this short-term study.

This treatment strategy of first exploring the anterior maxillary region for implant placement reduces treatment time and morbidity for a number of patients. Next to this, the insertion of 4 implants could be analyzed, for reasons of further cost-effectiveness.

Conclusion

From this one-year study, it is concluded that 6 dental implants placed in either the anterior region or the posterior region of the edentulous maxilla, connected with a bar, and opposed to natural antagonistic teeth in the mandible, supply a proper base for the support of an overdenture.

References

- Adell, R., Lekholm, U., Rockler, B. & Brånemark, P.I. (1981) A 15-year study of osseointegrated implants in the treatment of the edentulous jaw. *International Journal of Oral Surgery* 10, 387-416.
- Albrektsson, T., Zarb, G., Worthington, P. & Eriksson, A.R. (1986) The long-term efficacy of currently used dental implants: a review and proposed criteria for success. *The International Journal of Oral and Maxillofacial Implants* 1, 11-25.
- Andriotti, M., Att, W. & Strub, J.R. (2010) Prosthodontic complications with implant overdentures: a systematic literature review. *The International Journal of Prosthodontics* 23, 195-203.
- Åstrand, P., Nord, P.G. & Brånemark, P.I. (1996) Titanium implants and onlay bone graft to the atrophic maxilla: a 3-year longitudinal study. *International Journal of Oral and Maxillofacial Surgery* 25, 25-29.
- Broggini, N., McManus, L.M. & Hermann, J.S et al. (2003) Persistent acute inflammation at the implant-abutment interface. *Journal of Dental Research* 82, 232-237.
- Carlsson, G.E. (2009) Dental occlusion: modern concepts and their application in implant prosthodontics. *Odontology* 97, 8-17.
- Chan, M.F., Howell, R.A. & Cawood, J.I. (1996) Prosthetic rehabilitation of the atrophic maxilla using pre-implant surgery and endosseous implants. *British Dental Journal* 181, 51-58.
- Esposito, M., Hirsch, J.M., Lekholm, U. & Thomsen, P. (1998) Biological factors contributing to failures of osseointegrated oral implants. (I). Success criteria and epidemiology. *European Journal of Oral Sciences* 106, 527-551.
- Guljé, F., Raghoebar, G.M., Ter Meulen, J.W., Vissink, A. & Meijer, H.J.A. (2012) Mandibular Overdentures Supported by 6-mm Dental Implants: a 1-Year Prospective Cohort Study. *Clinical Implant Dentistry and Related Research* 14(Suppl. 1), e59-66.
- Hermann, J.S., Cochran, D.L., Nummikoski, P.V. & Buser, D. (1997) Crestal bone changes around titanium implants. A radiographic evaluation of unloaded nonsubmerged and submerged implants in the canine mandible. *Journal of Periodontology* 68, 1117-1130.
- Kahnberg, K.E., Nilsson, P. & Rasmusson, L. (1999) Le Fort I osteotomy with interpositional bone grafts and implants for rehabilitation of the severely resorbed maxilla: a 2-stage procedure. *The International Journal of Oral and Maxillofacial Implants* 14, 571-578.
- Krennmair, G., Krainhöfner, M. & Piehslinger, E. (2008) Implant-supported maxillary overdentures retained with milled bars: maxillary anterior versus maxillary posterior concept: a retrospective study. *The International Journal of Oral and Maxillofacial Implants* 23, 343-352.
- Löe, H. & Silness, J. (1963) Periodontal disease in pregnancy. II: correlation between oral hygiene and periodontal condition. *Acta Odontologica Scandinavica* 21, 533-551.
- Meijer, H.J.A., Raghoebar, G.M., Batenburg, R.H. & Vissink, A. (2009) Mandibular overdentures supported by two Brånemark, IMZ or ITI implants: a ten-year prospective randomized study. *Journal Clinical Periodontology* 36, 799-806.
- Meijer, H.J.A., Raghoebar, G.M., Batenburg, R.H.K., Visser, A. & Vissink, A. (2009) Mandibular overdentures supported by two or four endosseous implants: a 10-year clinical trial. *Clinical Oral Implants Research* 20, 722-728.
- Meijndert, L., Meijer, H.J.A., Raghoebar, G.M. & Vissink, A. (2004) A technique for standardized evaluation of soft and hard peri-implant tissues in partially edentulous patients. *Journal of Periodontology* 75, 646-651.
- Mombelli, A., Van Oosten, M.A.C., Schürch, E. & Lang, N. (1989) The microbiota associated with successful or failing osseointegrated titanium implants. *Journal of Oral Microbiology and Immunology* 2, 145-151.
- Ohkubo, C. & Baek, K.W. (2010) Does the presence of antagonistic remaining teeth affect implant overdenture success? A systematic review. *Journal of Oral Rehabilitation* 37, 306-312.
- Raghoebar, G.M., Meijer, H.J.A., Van 't Hof, M.A., Stegenga, B. & Vissink, A. (2003) A randomized prospective clinical trial on the effectiveness of three treatment modalities for patients with lower denture problems. A 10 year follow-up study on patient satisfaction. *The International Journal of Oral and Maxillofacial Surgery* 32, 498-503.
- Raghoebar, G.M., Meijer, H.J., Stellingsma, K. & Vissink, A. (2011) Addressing the atrophied mandible: a proposal for a treatment approach involving endosseous implants. *International Journal of Oral Maxillofacial Implants* 26, 607-617.
- Raghoebar, G.M., Timmenga, N.M., Reintsema, H., Stegenga, B. & Vissink, A. (2001) Maxillary bone grafting for the insertion of endosseous implants: results after 12-124 months. *Clinical Oral Implants Research* 12, 279-86.
- Raghoebar, G.M., Vissink, A., Reintsema, H. & Batenburg, R.H. (1997) Bone grafting of the floor of the maxillary sinus for the placement of endosseous implants. *The British Journal of Oral & Maxillofacial Surgery* 35, 119-125.
- Sadowsky, S.J. (2007) Treatment consideration for maxillary implant overdentures: a systematic review. *The Journal of Prosthetic Dentistry* 97, 340-348.
- Sanna, A., Nuytens, P., Naert, I. & Quirynen, M. (2009) Successful outcome of splinted implants supporting a 'planned' maxillary overdenture: a retrospective evaluation and comparison with fixed full dental prostheses. *Clinical Oral Implants Research* 20, 406-413.
- Slot, W., Raghoebar, G.M., Van Dijk, G. & Meijer, H.J.A. (2012) Attachment of clips in a bar-retained maxillary implant overdenture: a clinical report. *The Journal of Prosthetic Dentistry* 107, 353-357.
- Slot, W., Raghoebar, G.M., Vissink, A., Huddleston Slater, J.J. & Meijer, H.J. (2010) A systematic review of implant-supported maxillary overdentures after a mean observation period of at least 1 year. *Journal of Clinical Periodontology* 37, 98-110.
- Smeets, E.C., De Jong, K.J. & Abraham-Inpijn, L. (1998) Detecting the medically compromised patient in dentistry by means of the medical risk-related history. A survey of 29,424 dental patients in The Netherlands. *Preventive Medicine* 27, 530-535.
- Stellingsma, K., Slagter, A.P., Stegenga, B., Raghoebar, G.M. & Meijer, H.J.A. (2005) Masticatory function in patients with an extremely resorbed mandible restored with mandibular implant-retained overdentures: comparison of three types of treatment protocols. *Journal of Oral Rehabilitation* 32, 403-410.

Taylor, T.D., Belser, U. & Merickske-Stern, R. (2000) Prosthodontic considerations. *Clinical Oral Implants Research* 11 (Suppl. 1), 101-107.

Thomason, J.M., Kelly, S.A., Bendkowski, A. & Ellis, J.S. (2012) Two implant retained overdentures: a review of the literature supporting the McGill and York consensus statements. *Journal of Dentistry* 40, 22-34.

Van de Velde, T., Collaert, B., Sennerby, L. & De Bruyn, H. (2010) Effect of implant design on preservation of marginal bone in the mandible. *Clinical Implant Dentistry and Related Research* 12, 134-141.

Van Waas, M.A.J. (1990) The influence of clinical variables on patients' satisfaction with complete dentures. *The Journal Prosthetic Dentistry* 63, 307-310.

Vercruyssen, M., Marcelis, K., Coucke, W., Naert, I. & Quirynen, M. (2010) Long-term, retrospective evaluation (implant and patient-centered outcome) of the two-implants-supported overdenture in the mandible. Part 1: survival rate. *Clinical Oral Implants Research* 21, 357-365.

Visser, A., Raghoobar, G.M., Meijer, H.J. & Vissink, A. (2009) Implant-retained maxillary overdentures on milled bar suprastructures: a 10-year follow-up of surgical and prosthetic care and aftercare. *The International Journal of Prosthodontics* 22, 181-192.

Vervoorn, J.M., Duinkerke, A.S.H., Luteijn, F. & Van Der Poel, A.C.M. (1988) Assessment of denture satisfaction. *Community Dentistry and Oral Epidemiology* 16, 364-367.

Chapter 6

**Attachments of clips in a
bar-supported maxillary
implant overdenture:
a clinical report**

This chapter is an edited version of the manuscript.

Slot, W., Raghoobar, G.M., van Dijk, G., Meijer, H.J. (2012).

Attachments of clips in a bar-supported maxillary implant overdenture: a clinical report.

Journal of Prosthetic Dentistry. 107, 353-357.

Abstract

Implant-supported overdentures are a good alternative for patients with conventional dentures that lack retention and stability. The most common prosthetic complications in mandibular and maxillary implant-supported overdentures are fracture and loosening of the attachment system. This clinical report describes the treatment of a completely edentulous patient with sinus floor elevation by using bone from the iliac crest and the insertion of 4 implants in the maxilla and mandible followed by implant-supported overdentures. The technical procedure for the attachment of clips to an acrylic resin overdenture base with the use of metal reinforcement is described. The advantage of this attachment procedure is an improved attachment system with less fracture and less loosening of the clips.

Introduction

Mandibular and maxillary implant-retained overdentures have been shown to be a successful prosthetic treatment (Sadowsky, 2001, Slot et al. 2010). In a systematic review, Andreiotelli et al. (2010) reported a higher frequency of prosthetic complications for maxillary implant-retained overdentures than for mandibular implant-retained overdentures. Cehreli et al. (2010), stated in a another systematic review that prosthetic maintenance requirements for overdentures on both jaws seem to be comparable.

Fracture and loosening of the attachment system in the overdenture is said to be the most common prosthetic complication with mandibular and maxillary overdenture treatment (Meijer et al. 2009, Visser et al. 2009). These retentive elements must withstand the high forces exerted on the overdenture during mastication (Mericske-Stern et al. 2000, Fontijn-Tekamp et al. 2000). The use of small retentive anchors for the attachment system in the acrylic resin is often the reason for fracture and loosening (Meijer et al. 2009). To be cost-effective, it is important that postinsertion care of implants is minimized.

Large retentive anchors with more contact in the acrylic resin seem to be less subject to complications. However, it is not always possible to use large retentive anchors because of small interimplant space and restricted interocclusal space. Specifically, a bar superstructure supported by 4 anteriorly placed dental implants in the mandible does not allow for large clips. Additionally there may not be sufficient bulk of acrylic resin in some areas of a maxillary overdenture to accommodate clips. Maxillary overdentures are often too thin to cover both a bar superstructure and clips with adequate acrylic resin. Unconnected attachment systems, such as ball-socket attachments, take less space in the overdenture but are considered inferior to bar attachment systems because of increased postinsertion care in the mandible (Stoker et al. 2007) and reduced survival rate of implants in the maxilla (Slot et al. 2010). Some authors have stated that the implant survival and overdenture survival rates are better for a milled bar design than for a resilient bar design (Ferrigno et al. 2002, Goodacre et al. 2003, Krennmair et al. 2009). A rigid attachment system for the overdenture seems to give better results than a structure with some micromovement

(Visser et al. 2009, Jemt et al. 1992, Smedberg et al. 1993).

The reinforcement of implant overdenture bases with chromium alloys makes the denture base more fracture resistant (Rodrigues, 2000, Gonda et al. 2007). Also, because of the increased strength, the thickness of the acrylic resin may be reduced. The technique of attaching clips to the metal reinforcement structure rather than to the acrylic resin is recommended. The advantage of this attachment procedure is improved anchorage, resulting in less fracture and less loosening of clips. The disadvantage is the initial higher cost because the metal reinforcement and the laser welding needed to attach the clips are extra components in the overdenture. This, however, may be offset by fewer repairs and less discomfort for the patient. The purpose of this clinical report is to demonstrate a technique for the attachment of small clips to an overdenture base with metal reinforcement to prevent fracture and loosening of clips.

Clinical Report

A 59-year-old edentulous man was referred by his dentist to the Department of Oral and Maxillofacial Surgery (University Medical Center Groningen, University of Groningen, Groningen, The Netherlands) with complaints concerning his removable prostheses in the mandible and maxilla. The patient had functional problems with both dentures because of poor retention and stability, was not confident about his prosthesis, and suffered from loss of self-esteem. The patient had previously been edentulous for 12 years in the maxilla and 2 years in the mandible. The patient was healthy and did not smoke. An attempt by the general dentist to solve these problems by relining the maxillary and mandibular prosthesis was not successful. Clinical and radiographic examination revealed an extremely resorbed maxilla and a moderately resorbed mandible. Implant-supported prostheses seemed to be reliable options to fulfill the patient's demands. There was inadequate bone volume in the maxilla to place implants due to resorption of bone in the anterior area and extension of the maxillary sinus in the posterior area; however, the patient was willing to undergo a bone augmentation procedure. In the mandible there was adequate bone to insert implants.

The patient provided informed consent for the following treatment plan:

- 1) maxillary sinus floor elevation surgery with bone grafts from the iliac crest;
- 2) the placement of 4 implants in the maxilla and 4 implants in the mandible after a 3-month healing period;
- 3) fabrication of implant-supported overdentures after a 3-month osseointegration period.

Maxillary sinus floor elevation surgery was performed under general anesthesia, and the bone graft was harvested from the anterior iliac crest as described by Raghoobar et al. (1997, 2001). For 2 weeks after the surgery, the patient was not allowed to wear dentures. Then, acrylic resin was removed from the maxillary prosthesis in those areas which could contact the grafted sites. Furthermore, the prosthesis was relined with a resilient liner (Soft liner; GC Corporation, Tokyo, Japan). Healing was uneventful and the patient had no complaints.

After a 3-month healing period, 4 dental implants were inserted in the maxilla, and 4 dental implants were inserted in the mandible (Straumann

Standard SLA® implants; Ø 4.1 mm, length 12 mm, RN, Institut Straumann AG, Basel, Switzerland). In the maxilla, the implants were placed into the grafted sites in the posterior area with a surgical template. In the mandible the implants were placed in the interforaminal region as described by Weingart and ten Bruggenkate (Weingart & ten Bruggenkate, 2000) (figures 1 and 2). Two weeks after implant placement, the patient was allowed to wear the dentures again after adjustment of the prostheses in the area of the implants and relining with the resilient lining material. The patient was given oral hygiene instructions.

After a 3-month healing period, the prosthetic procedures were initiated. Preliminary impressions were made by using stock metal trays (Schreinemakers, Clan Dental Products, Maarheeze, The Netherlands) and irreversible hydrocolloid (Cavex CA 37, Cavex Holland BV, Haarlem, The Netherlands). The impressions were poured with Type IV stone (GC Fujirock EP, GC Europe NV, Leuven, Belgium), and custom acrylic resin impression trays (Lightplast base plates; Dreve Dentamid GmbH, Unna, Germany) were fabricated with openings for screw-retained impression copings (RN synOcta impression cap; Institut Straumann AG, Basel, Switzerland). These were placed on the implants and were attached with the integral positioning screw. The tray was placed over the impression copings and any contact between the copings and the tray was eliminated to allow the tray to rest firmly on the denturebearing mucosa with the positioning screw exiting through an opening in the tray. The final complete arch impression in both jaws was made with polyether material (Impregum F; 3M ESPE, St. Paul, Minn). The impression material around the impression copings was placed with a syringe. The tray was filled with impression material and placed on the alveolar process. During polymerization, the positioning screws of the impression copings were uncovered to facilitate removal of the impression. After removal of the tray, the copings were connected to implant analogs (RN synOcta analog; Institut Straumann AG), and the definitive cast was poured with Type IV stone (GC Fujirock EP; GC Europe NV, Leuven, Belgium). In this way the implant location and the denture bearing area were reproduced. Composite resin record bases (Lightplast base plates; Dreve Dentamid GmbH, Unna, Germany) with wax occlusion rims were used to determine the occlusal vertical dimension

and to record the maxillomandibular relationship. The position of wax rims was stabilized with addition silicone paste (Futar D; Kettenbach GmbH, Eschenburg, Germany) and transferred to an articulator (Artex; Girschbach Dental GMBH, Pforzheim, Germany). Ceramic artificial teeth (SR Vivodent PE; Ivoclar Vivadent, Schaan, Liechtenstein) were selected and arranged on the record bases for a trial arrangement. After completion of the tooth arrangement, the trial dentures were evaluated and corrected, as needed. A balanced lingualized occlusion was developed with the ceramic teeth. The esthetics, phonetics, centric relation, occlusion, and occlusal vertical dimension were verified and the final arrangement was approved by the patient. The dental laboratory technician digitized the casts and arrangement, and designed an ovoid bar on the implant analogs with a computer. The file was sent to a superstructure milling company (ES Healthcare NV, Hasselt, Belgium) to mill the maxillary and mandibular bars from titanium. After receiving the milled titanium bar, it was placed on the original cast (figure 3). Gold retentive clips (Cendres +Métaux, Biel/Bienne, Switzerland) were selected to fit on the bars (figure 4). A refractory duplicate cast was made by using a silicone template material (Elite Double 22; Zhermack SpA, Badio Polesine, Italy). The framework pattern was waxed on the refractory cast. Retention beads (0.6 mm) (Renfert GmbH and Co Ltd, Hilzingen, Germany) were applied to the wax framework. The modeled framework was cast in cobalt chromium (Vitalium PH2; Elephant-Dental BV, Hoorn, The Netherlands). The retention clips were laser welded under direct vision onto the reinforcement structure (figures 5 and 6). The reinforcement structure was integrated in the acrylic resin (MegaCRYL N, Megadental GmbH, Bidingen, Germany) of the overdenture. The prostheses were processed and finished. The milled bars were placed onto the implants (figures 7 and 8), the abutment screws were tightened to 35 Ncm, and the prostheses were inserted (figure 9). The patient was instructed in hygiene procedures associated with the dentures and the bars and scheduled for routine maintenance recalls. After two years the patient remained satisfied with his implant support prosthesis.

Figure 1 4 dental implants with cover screws in edentulous maxilla.

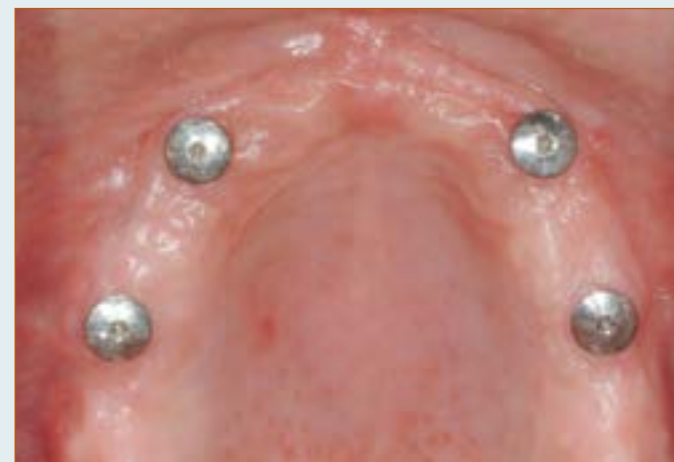

Figure 2 Panoramic radiograph of edentulous maxilla and mandible after implant placement.

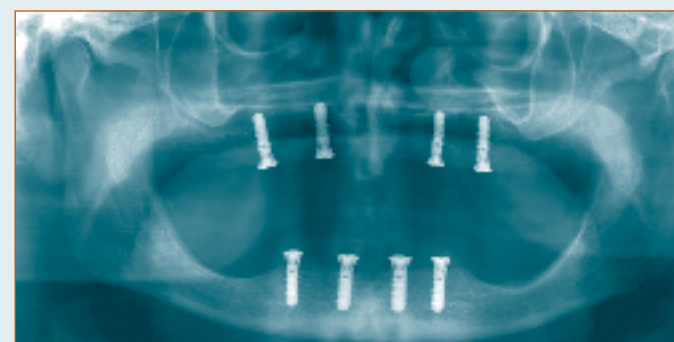


Figure 3 Milled bars on maxillary cast.



Figure 4 Selection of gold retentive clips to fit on milled bars.



Figure 5 Reinforced chromium alloy structure with gold retentive clips and bar.



Figure 6 Laser welded attachment of clip to chromium alloy structure.



Figure 7 Intraoral view of milled titanium bar fastened to dental implants in maxilla.

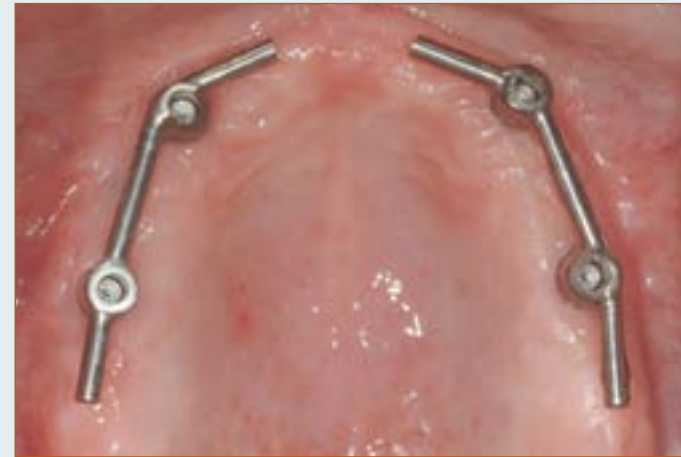

Figure 8 View of intaglio surface of maxillary overdenture with chromium alloy structure and clips.

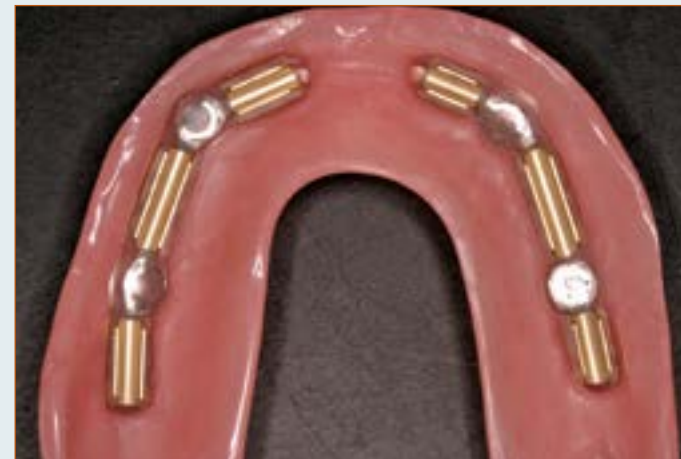
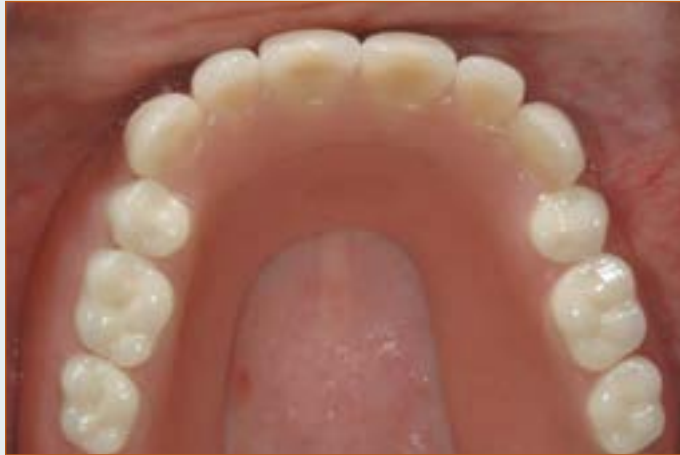
Figure 9 View of the definitive prosthesis intraorally.



Summary

This clinical report describes an edentulous patient treated with dental implants and removable bar-retained overdentures. The implant overdentures are reinforced with a chromium alloy structure. The attachment clips are laser welded to the metal reinforcement to reduce fracture and loosening.

References

- Andriotelli, M., Att, W. & Strub, J.R. (2010) Prosthodontic complications with implant overdentures: a systematic literature review. *The International Journal of Prosthodontics* 23, 195-203.
- Cehreli, M.C., Karasoy, D., Kokat, A.M., Akca, K. & Eckert, S.E. (2010) Systematic review of prosthetic maintenance requirements for implant-supported overdentures. *The International Journal of Oral Maxillofacial Implants* 25, 163-80.
- Ferrigno, N., Laureti, M., Fanali, S. & Grippaudo, G. (2002) A long-term follow-up study of non-submerged ITI implants in the treatment of totally edentulous jaws. Part I: Ten-year life table analysis of a prospective multicenter study with 1286 implants. *Clinical Oral Implants Research* 13, 260-73.
- Fontijn-Tekamp, F.A., Slagter, A.P., Van Der Bilt, A., Van 'T Hof, M.A., Witter, D.J. & Kalk, W et al. (2000) Biting and chewing in overdentures, full dentures, and natural dentitions. *Journal of Dental Research* 79, 1519-24.
- Gonda, T., Ikebe, K., Dong, J. & Nokubi, T. (2007) Effect of reinforcement on overdenture strain. *Journal of Dental Research* 86, 667-71.
- Goodacre, C.J., Bernal, G., Rungcharassaeng, K. & Kan, J.Y. Clinical complications with implants and implant prostheses. *The Journal of Prosthetic Dentistry* 90, 121-32.
- Jemt, T., Book, K., Lindén, B. & Urde, G. (1992) Failures and complications in 92 consecutively inserted overdentures supported by Brånemark implants in severely resorbed edentulous maxillae: a study from prosthetic treatment to first annual check-up. *The International Journal of Oral & Maxillofacial Implants* 7, 162-7.
- Krennmaier, G. & Piehslinger, E. (2009) Removable implant-supported maxillary prostheses anchored on milled bars: a retrospective evaluation of two concepts. *The International Journal of Prosthodontics* 22, 576-8.
- Meijer, H.J., Raghoobar, G.M., Batenburg, R.H., Visser, A. & Vissink, A. (2009) Mandibular overdentures supported by two or four endosseous implants: a 10-year clinical trial. *Clinical Oral Implants Research* 20, 722-8.
- Mericske-Stern, R., Venetz, E., Fahrlander, F. & Bürgin, W. (2000) In vivo force measurements on maxillary implants supporting a fixed prosthesis or an overdenture: a pilot study. *The Journal of Prosthetic Dentistry* 84, 535-47.
- Raghoobar, G.M., Vissink, A., Reintsema, H. & Batenburg, R.H. (1997) Bone grafting of the floor of the maxillary sinus for the placement of endosseous implants. *The British Journal of Oral & Maxillofacial Surgery* 35, 119-25.
- Raghoobar, G.M., Timmenga, N.M., Reintsema, H., Stegenga, B. & Vissink, A. (2001) Maxillary bone grafting for the insertion of endosseous implants: results after 12-124 months. *Clinical Oral Implants Research* 12, 279-86.
- Rodrigues, A.H. (2000) Metal reinforcement for implant-supported mandibular overdentures. *The Journal of Prosthetic Dentistry* 83, 511-3.
- Sadowsky, S.J. (2001) Mandibular implant-retained overdentures: a literature review. *The Journal of Prosthetic Dentistry* 86, 468-73.
- Slot, W., Raghoobar, G.M., Vissink, A., Huddleston Slater, J.J. & Meijer, H.J. (2010) A systematic review of implant-supported maxillary overdentures after a mean observation period of at least 1 year. *Journal of Clinical Periodontology* 37, 98-110.
- Smedberg, J.I., Lothigius, E., Bodin, I., Frykholm, A. & Nilner, K. (1993) A clinical and radiological two-year follow-up study of maxillary overdentures on osseointegrated implants. *Clinical Oral Implants Research* 4, 39-46.
- Stoker, G.T., Wismeijer, D. & van Waas, M.A. (2007) An eight-year follow-up to a randomized clinical trial of aftercare and cost-analysis with three types of mandibular implant-retained overdentures. *Journal of Dental Research* 86, 276-80.
- Visser, A., Raghoobar, G.M., Meijer, H.J. & Vissink, A. (2009) Implant-retained maxillary overdentures on milled bar suprastructures: a 10-year follow-up of surgical and prosthetic care and aftercare. *The International Journal of Prosthodontics* 22, 181-92.
- Weingart, D. & ten Bruggenkate, C.M. (2000) Treatment of fully edentulous patients with ITI implants. *Clinical Oral Implants Research* 11 (Suppl. 1), 69-82.

Chapter 7
**General discussion and
conclusions**

Introduction

Analysis of the data of studies described in this thesis revealed that both 4 and 6 dental implants placed in the anterior region or posterior of the edentulous maxilla, connected with a bar, supply a proper base for the support of a maxillary overdenture after 1 year. No differences between the four and six implants groups were observed in complete edentulous patients, both with regard to peri-implant parameters and patients' satisfaction. With regard to patients with antagonistic natural teeth in the mandible, the peri-implant parameters and patients' satisfaction were comparable for implant-supported maxillary overdentures on 6 dental implants placed in either the anterior region or posterior region of the edentulous maxilla, connected with a bar.

Study design

It was assumed that the number of implants used to support the maxillary overdenture could affect the implant survival rate because forces on the overdenture have to be carried by the bone surrounding the implants which has a lower quality as mandibular bone. With more implants, the forces are distributed over a larger implant-bone area. This assumption is also in line from the results of the systematic review described in chapter 2 showing that the 1-year survival rate for implants in case of 6 or more implants connected with a bar was 98.2%, while the 1-year survival rate for 4 or less implants connected with an bar 96.3%. However, not only the number of implants placed might affect the implant survival rate, but also the design of the anchorage system as loading of the bone surrounding the implants is dependent on the anchorage system used. When applying a bar between implants, the load on the maxillary denture is distributed to the bone surrounding the neighbouring implants. When applying solitary attachments (ball attachments), the load is distributed to the surrounding bone of the implant that is loaded (Meijer et al. 1992). As shown in the systematic review, the 1-year survival rate for 4 or less implants and a ball anchorage was 95.2%, which supports this presumption.

Another factor that might affect implant-survival rates is the kind of opposing dentition. The opposing dentition is an important factor in

determining the occlusion concept to be applied. With regard to edentulous patients, commonly an occlusion concept is used providing a balanced tooth contact and evenly distributed forces on the overdenture. In case of a (partially) dentate mandible, an occlusion concept with evenly distribution of the forces on the maxillary overdenture is often not possible. The non evenly distributed forces on the upper denture will result in not equally distributed forces on the bone surrounding the implants.

Implant survival rate

The 1-year survival rate of implants placed to support a maxillary overdenture in the various clinical studies described in this thesis varied from 98% to 100%. In other words, the 1-year survival rates are irrespective of placing 4 or 6 implants to support a maxillary overdenture, irrespective whether the implants are placed in the anterior or posterior maxilla, and irrespective of the opposing dentition (either a lower implant supported overdenture or an antagonistic natural dentition). Furthermore, the implant survival rates match the 1-year implant survival rates reported in the systematic review (chapter 2). Although the survival rates are very favourable, it has to be mentioned that losing one implant in a treatment strategy with 4 implants has clinically more consequences than in a treatment strategy with 6 implants. Usually, a well functioning maxillary overdenture can be made on the remaining 5 implants, while in case of 3 remaining often an extra surgical treatment procedure is needed to replace the failing implant. Notwithstanding this inherent disadvantage of placing 4 implants, the four implants approach, given the high implant survival rate in maxillary overdenture treatment, is considered a reasonable approach from both a clinical and cost-effectiveness perspective.

Clinical outcome

Mean indices for plaque, calculus, gingiva and bleeding were very low at the 1-year evaluation for all groups and in all protocols applied. The values of these indices are comparable to clinical outcome of studies on implants placed in the mandible applying the same criteria (Guljé et al. 2012; Meijer et al. 2009a, b). Mean peri-implant probing depths varied between 3.6 mm and 4.8 mm for the various study approaches; again values that are

comparable to those reported by Raghoobar et al. (2003a) for implants placed in the maxilla. On the other hand, mean probing depths are higher than reported after 1 year for implants of the same dental implant system in the mandible (Meijer et al. 2009b). These higher values are not related to peri-implant mucositis and/or peri-implantitis, but are caused by a thicker mucosa in the maxilla. Implants were surrounded with healthy peri-implant soft tissues, probably due to the strict oral hygiene regime to which patients were subjected.

Radiographic outcome

Mean marginal bone loss between baseline (placement of the overdenture) and the 1-year evaluation was in all study groups well within the limits as formulated by Albrektsson et al. (1986). Very limited radiographic bone loss was observed, ranging from 0.22 mm to 0.50 mm. Besides very strict oral hygiene instructions, this favourable outcome could also be due to the neck design of the implants used (Hermann et al. 1997, Brogini et al. 2003, van de Velde et al. 2010). The applied OsseoSpeed™ 4.0 S dental implants have a platform switch and surface roughness up to the neck of the implant; the applied Straumann Standard SLA® implants have an implant-abutment connection, and thus microgap, above bone level. In the systematic review in this thesis a change in mean marginal bone level was mentioned in 14 out of the 31 studies. The loss of marginal bone showed a large range and varied from 0.23 mm in 27 months to 2.45 mm in 19 months. It must be noted however, that in the review also implant designs were evaluated which were familiar with more marginal bone loss.

Patients' satisfaction

At the 1-year evaluation the patients of all groups were satisfied with their implant-supported maxillary overdenture. Studies on patients' satisfaction with maxillary overdentures, preferably evaluated with validated questionnaires or otherwise comparable questionnaires, are not known. So, results of the studies described in this thesis cannot one to one be compared with the satisfaction scores of other studies on implant-supported maxillary overdentures. The fact that our patients in the presented studies were satisfied is in line with the high patients' satisfaction reported in

other studies (Krennmair et al. 2008, Visser et al. 2009). Studies using the same approach as in this PhD research for implants-supported mandibular overdentures reported comparable satisfaction results (Raghoobar et al. 2003b, Stellingsma et al. 2005). Probably, the impact of a stable mandibular and/or maxillary overdenture, i.e. an overdenture with good support and retention, has such a high impact on patients' satisfaction that the position of implants (anterior or posterior) and the state of antagonistic dentition are of minor importance in this respect.

Recommendation for further research

The studies described in this thesis report on short-term results. To confirm the findings longer follow-up is needed. Furthermore, it has to be assessed whether the aftercare of the various approaches also will be comparable on the long run. In a systematic review, it was stated that prosthetic maintenance requirements for implant-supported overdentures is an important issue (Cehreli et al. 2010). Fracture and loosening of the attachment system in the overdenture and fracture of the acrylic base of the overdenture base are said to be the most common prosthetic complications with mandibular and maxillary overdenture treatment (Meijer et al. 2009, Visser et al. 2009). Retentive elements and acrylic must withstand high forces exerted on the overdenture during mastication. To be cost-effective, it is important that post-insertion care of implants is minimized. Treatment procedures should be explored aiming at reduction of prosthetic complications.

As mentioned, when the bone volume allows, implant placement in the anterior maxilla is preferred. Unfortunately, at time of the start of the trial cone beam computer tomography (CBCT) was not available at the University Medical Center Groningen and thus the bone volume was measured by ridge mapping. Nowadays, as CBCT is a facility commonly available in the Western world, thus volume of the anterior (and also the posterior) maxilla can be assessed with higher reliability, it is advised to make a CBCT in those cases where a sufficient bone volume for implant placement in this area might be present (Allen and Smith 2000, Luk et al. 2011). This aspect needs further study.

Besides the bar attachment system, amongst others solitary Locator® abutments are also applied to retain the maxillary overdenture. Advantages of Locator® abutments are an uncomplicated oral hygiene and easy laboratory procedures. A study comparing the treatment outcome of the bar/clip attachment system with the solitary Locator® abutments for maxillary overdentures has not yet been published and should be explored. Besides peri-implant parameters and patients' satisfaction, such studies should also look into the need for care and aftercare over a period of at least 10 years.

Practical implications

When treating a patient with problems with lack of retention and stability of the upper denture or a patient who experience problems due to the palatal plate of the denture, the origin of the problem should be carefully examined and evaluated. When it is decided that placement of implants to support an overdenture in the maxilla is the treatment of choice, it first has to be assessed whether implant placement in the anterior maxillary region is possible, eventual combined with a bone augmentation surgery with intra-oral bone. Such a treatment procedure reduces treatment time and morbidity compared to implants placement in the posterior region preceded by a bone augmentation surgery with bone harvested from the iliac crest. Furthermore, as the treatment outcome of a bar-connected maxillary overdenture on 4 implants is comparable to that of an overdenture by 6 implants, the four-bar-connected implant approach is the preferred approach from a perspective of morbidity, the prosthetic procedure and cost-effectiveness.

References

- Albrektsson, T., Zarb, G., Worthington, P., Eriksson, A.R. (1986) The long-term efficacy of currently used dental implants: a review and proposed criteria for success. *The International Journal of Oral & Maxillofacial Implants* 1, 11-25.
- Allen, F., Smith, D.G. (2000) An assessment of the accuracy of ridge-mapping in planning implant therapy for the anterior maxilla. *Clinical Oral Implants Research* 11, 34-38.
- Broggini, N., McManus, L.M., Hermann, J.S., et al. (2003) Persistent acute inflammation at the implant-abutment interface. *Journal of Dental Research* 82, 232-237.
- Guljé, F., Raghoobar, G.M., Ter Meulen, J.W., Vissink, A., Meijer, H.J.A. (2012) Mandibular Overdentures Supported by 6-mm Dental Implants: a 1-Year Prospective Cohort Study. *Clinical Implant Dentistry and Related Research* 14 (Suppl. 1), e59-e66.
- Hermann, J.S., Cochran, D.L., Nummikoski, P.V., Buser, D. (1997) Crestal bone changes around titanium implants. A radiographic evaluation of unloaded nonsubmerged and submerged implants in the canine mandible. *Journal of Periodontology* 68, 1117-1130.
- Krennmair, G., Krainhöfner, M., Piehslinger, E. (2008) Implant-supported maxillary overdentures retained with milled bars: maxillary anterior versus maxillary posterior concept-a retrospective study. *The International Journal of Oral and Maxillofacial Implants* 23, 343-352.
- Luk, L.C., Pow, E.H., Li, T.K., Chow, T.W. (2011) Comparison of ridge mapping and cone beam computed tomography for planning dental implant therapy. *The International Journal of Oral and Maxillofacial Implants* 26, 70-74.
- Meijer, H.J., Kuiper, J.H., Starmans, F.J. & Bosman, F. (1992) Stress distribution around dental implants: influence of superstructure, length of implants, and height of mandible. *Journal of Prosthetic Dentistry* 68, 96-102.
- Meijer, H.J.A., Raghoobar, G.M., Batenburg, R.H.K., Visser, A., Vissink, A. (2009a) Mandibular overdentures supported by two or four endosseous implants: a 10-year clinical trial. *Clinical Oral Implants Research* 20, 722-728.
- Meijer, H.J.A., Raghoobar, G.M., Batenburg, R.H., Vissink, A. (2009b) Mandibular overdentures supported by two Brånemark, IMZ or ITI implants: a ten-year prospective randomized study. *Journal of Clinical Periodontology* 36, 799-806.
- Raghoobar, G.M., Schoen, P., Meijer, H.J., Stellingsma, K., Vissink, A. (2003a) Early loading of endosseous implants in the augmented maxilla: a 1-year prospective study. *Clinical Oral Implants Research* 14, 697-702.
- Raghoobar, G.M., Meijer, H.J.A., Van 't Hof, M.A., Stegenga, B., Vissink, A. (2003b) A randomized prospective clinical trial on the effectiveness of three treatment modalities for patients with lower denture problems. A 10 year follow-up study on patient satisfaction. *International Journal of Oral and Maxillofacial Surgery* 32, 498-503.
- Stellingsma, K., Slagter, A.P., Stegenga, B., Raghoobar, G.M., Meijer, H.J.A. (2005) Masticatory function in patients with an extremely resorbed mandible restored with mandibular implant-retained overdentures: comparison of three types of treatment protocols. *Journal of Oral Rehabilitation* 32, 403-410.
- Van de Velde, T., Collaert, B., Sennerby, L., De Bruyn, H. (2010) Effect of implant design on preservation of marginal bone in the mandible. *Clinical Implant Dentistry and Related Research* 12, 134-141.
- Visser, A., Raghoobar, G.M., Meijer, H.J., Vissink, A. (2009) Implant-retained maxillary overdentures on milled bar suprastructures: a 10-year follow-up of surgical and prosthetic care and aftercare. *International Journal of Prosthodontics* 22, 181-192.

Chapter 8
Summary
Samenvatting

Summary

In contrast to the proven benefit of dental implants to retain mandibular overdentures, a consensus or treatment concept for implant-supported maxillary overdentures is lacking. It is assumed, however, that maxillary implant-supported overdentures are a favourable treatment modality in cases of complaints regarding retention and stability of the upper denture. Next to a sufficient retention and stability of the maxillary overdenture, proper phonetics, aesthetics and hygiene access can be achieved by this approach too. The general aim of this PhD research was to assess the performance of maxillary overdentures in fully edentulous patients, supported by 4 or 6 dental implants, either placed in the anterior region or in the posterior region of the maxilla, with regard to implant survival, overdenture survival, clinical scores, peri-implant bone height changes and patients' satisfaction.

In the first part of this thesis, a systematic review of the literature is described. This review focussed on the treatment outcome of implant-supported overdentures in the maxilla. The objectives of this review were to assess the survival of implants, the survival of maxillary overdentures and the condition of surrounding hard and soft tissues after a mean observation period of at least one year (chapter 2). MEDLINE (1950-August 2009), EMBASE (1966-August 2009) and CENTRAL (1800-August 2009) were searched to identify eligible studies. Two reviewers independently assessed the articles. Out of 147 primarily selected articles, 31 studies fulfilled the inclusion criteria. A meta-analysis showed an implant survival rate of 98.2% per year in case of 6 implants and a bar anchorage. In case of 4 implants and either a bar or ball anchorage, the implant survival rate was 96.3% and 95.2% respectively. From this study it was concluded that all three treatment options were accompanied by a survival rate of the implants of at least 95%. The included studies revealed that a maxillary overdenture, supported by 6 dental implants, which are connected with a bar, is considered the most successful treatment regarding survival of the implants and the overdenture followed by 4 implants and a bar, and 4 or less implants and a ball attachment system.

In the second part of this thesis, the focus was on four versus six bar-connected implants to support an overdenture in the anterior (chapter 3) or posterior (chapter 4) region of the maxilla. The objectives of the randomized clinical described in chapter 3 were to compare the treatment outcome of four and six bar-connected implants in the anterior maxillary region to support an overdenture during a 1-year follow-up period. Fifty edentulous patients with lack of retention and stability of the upper denture, but with sufficient bone volume to place implants in the anterior maxillary region, were selected. Randomization assigned patients to either 4 or 6 implants. Implant survival, overdenture survival, clinical scores, radiographic bone height changes and patients' satisfaction were assessed. Forty-nine patients (one drop out) completed the one-year follow-up. After 1 year, implant survival was 100% in the four implants group and 99.3% in the six implants group (1 implant lost). Overdenture survival was 100% in both groups. Mean clinical scores were low and did not differ between groups (independent Student's t-test). Mean marginal bone resorption was 0.24 ± 0.32 mm in the four implants group and 0.25 ± 0.29 mm in the six implants group. Patients' satisfaction had improved in both groups (paired Student's t-test). Thus, the question can be raised whether 4 implants are enough for maxillary overdenture treatment in the anterior maxilla. We feel that when sufficient bone in the anterior region in combination with enough space in the overdenture is available to cover an attachment system, there is an advantage in placing implants in the anterior region above placement of implants in the posterior region of the maxilla, because of less morbidity and treatment time. Placement of implants in the posterior region of the edentulous maxilla is often compromised by insufficient bone volume to place implants. As a result a separate bone augmentation procedure is often needed; in case of severe resorption or extended pneumatization of the maxillary sinus this often is composed of maxillary sinus floor elevation surgery with iliac crest bone. Compared to placement of implants in the anterior region this means extended treatment time, more morbidity, hospitalization and higher treatment costs. Another advantage is that implants in the anterior maxillary region are more accessible for the patient and probably oral hygiene can be better maintained.

The objectives of the randomized clinical trial described in chapter 4 were to compare the treatment outcome of four versus six bar-connected implants in the posterior region of the maxilla to support an overdenture during a 1-year follow-up period. Sixty-six edentulous patients with an insufficient amount of bone volume in the maxilla to place implants were asked to participate in this study. Randomization assigned patients to either 4 or 6 implants. In all patients a maxillary sinus floor elevation procedure with bone from the iliac crest was performed and after a 3 month healing period 4 or 6 dental implants were inserted in the maxillary posterior region in a one-stage procedure. After 3 months of osseointegration, a bar-supported overdenture was constructed. Implant survival, overdenture survival, clinical scores, peri-implant bone height changes and patients' satisfaction were assessed. Study analysis was performed according a non-inferiority design. All patients completed the one-year follow-up. After a functional period of 1 year, implant survival was 100% in the four implants group and 99.5% in the six implants group. Overdenture survival was 100% in both groups. Mean clinical scores were very low and did not significantly differ between groups. Mean marginal bone resorption was 0.35 ± 0.31 mm and 0.46 ± 0.34 mm in the four and six implants group, respectively. Patients' satisfaction improved significantly in both groups, but did not differ between groups. Since results of six bar-connected and four bar-connected implants seem both favorable and result in a comparable treatment outcome, also for implants placed in the posterior maxilla to retain a maxillary overdenture the question raises whether 4 implants are enough for maxillary implant-supported overdenture treatment. As there are yet no treatment guidelines in which position the implants are preferably placed to retain a maxillary overdenture, we like to pose that in cases of sufficient bone in the anterior region and sufficient space in the overdenture to cover an attachment system, it is preferred to place implants in the anterior region, because of less morbidity and treatment time. In many patients, however, in particular in patients who have been edentulous for a long period, there is insufficient bone to place implants in the anterior region due to resorption. In these patients the implants have to be placed in the posterior part of the maxilla after a bone augmentation procedure.

In the third part of this thesis, a prospective 1-year case series study is described assessing the treatment outcome (survival of implants, condition of hard and soft peri-implant tissues, patients' satisfaction) of maxillary overdentures supported by 6 implants opposed by natural antagonistic teeth in the mandible (chapter 5). Fifty patients were treated with a maxillary overdenture supported by 6 dental implants, placed in the anterior region (n=25 patients) and in the posterior region (n= 25 patients). Items of evaluation were: survival of implants, condition of hard and soft peri-implant tissues and patients' satisfaction. One-year implant survival rate was 98% in the anterior-group and 99.3% in the posterior-group. Mean radiographic bone loss in the anterior- and posterior group after one year of loading was 0.22 mm and 0.50 mm, respectively. Mean scores for plaque, calculus, gingiva, bleeding and pocket probing depth were low, and patients' satisfaction was high, with no differences between the groups. This treatment outcome is very promising as antagonistic natural teeth have been considered a risk factor, but not a contraindication, for maxillary overdentures. The reason for being a risk factor might be a greater mastication force and harmful lateral forces to implants, due to a not so perfect occlusion concept. A bilateral balanced occlusion concept of conventional removable dentures is often used in overdenture therapy. In case of natural teeth in the antagonistic jaw, this is however often not possible because the occlusion is dictated by the anatomic form and (compromised) position of the natural teeth. It is advocated to apply an occlusal situation which is comfortable to the patient.

In fourth part of this thesis (chapter 6) a clinical report is described. The clinical report describes the treatment of a completely edentulous patient with sinus floor elevation by using bone from the iliac crest and the insertion of 4 implants in the maxilla and mandible followed by implant-supported overdentures. The technical procedure for the attachment of clips to an acrylic resin overdenture base with the use of metal reinforcement is described. The advantage of this attachment procedure is an improved attachment system with less fracture and less loosening of the clips.

The main research outcomes are discussed and general conclusions are drawn in chapter 7. From the systematic review of the literature it was concluded that all treatment procedures have an implant and overdenture survival of at least 95%. Analysis of the data of studies described in this thesis revealed that both 4 and 6 dental implants placed in the anterior region or posterior of the edentulous maxilla, connected with a bar, supply a proper base for the support of a maxillary overdenture after 1 year (chapters 3 and 4). Also in patients with antagonistic natural teeth in the mandible, the peri-implant parameters and patients' satisfaction were comparable for implant-supported maxillary overdentures on 6 dental implants placed in either the anterior region or posterior region of the edentulous maxilla, connected with a bar (chapter 5). Thus, when treating a patient with problems with lack of retention and stability of the upper denture or a patient who experience problems due to the palatal plate of the denture, first the origin of the problem should be carefully examined and evaluated. When it is decided that placement of implants to support an overdenture in the maxilla is the treatment of choice, it first has to be assessed whether implant placement in the anterior maxillary region is possible. Such a treatment procedure reduces treatment time and morbidity compared to implant placement in the posterior region preceded by a bone augmentation surgery with iliac crest bone in case of severe resorption. Furthermore, as the treatment outcome of a bar-connected maxillary overdenture on 4 implants is comparable to that of an overdenture by 6 implants, the four-bar-connected implant approach is the preferred approach from a perspective of morbidity, the prosthetic procedure and cost-effectiveness. It has to be mentioned, however, that studies described in this PhD thesis report on short-term results. To confirm the findings longer follow-up is needed.

Samenvatting

Er is voldoende wetenschappelijk bewijs dat de stabiliteit en retentie van een overkappingsprothese in de onderkaak sterk kan worden verbeterd door een combinatie van implantaten met een staaf-suprastructuur. Dit lijkt ook te gelden voor een overkappingsprothese op implantaten in de bovenkaak. Bovendien kan met een overkappingsprothese op implantaten een goede spraak en esthetiek worden verkregen en kan de suprastructuur ook zo worden vervaardigd dat deze goed is te reinigen. Echter het optimale behandelconcept van hoeveel en waar implantaten in de tandeloze bovenkaak te plaatsen en hoe de prothese te vervaardigen is in de wetenschappelijke literatuur nog niet beschreven. Derhalve was het primaire doel van het onderhavige promotieonderzoek te onderzoeken of een overkappingsprothese op 4 implantaten net zo goed functioneert als een overkappingsprothese op 6 implantaten. Daarnaast werd onderzocht wat de ideale plaats van de implantaten in de bovenkaak was, in het bijzonder of de implantaten in het voorste gedeelte of de zijdelingse delen van de bovenkaak moeten worden geplaatst. Uitkomst parameters waren de overleving van de implantaten, de overleving van de overkappingsprothese, de plaque-index, de conditie van de peri-implantaire mucosa, de pocketdiepte ter plaatse van de implantaten, de veranderingen in de peri-implantaire bothoogte en de tevredenheid van de patiënten.

In het eerste deel van dit promotie onderzoek wordt een systematische literatuurstudie beschreven betreffende het behandelingsresultaat van edentate (tandeloze) patiënten met een overkappingsprothese op implantaten in de bovenkaak. Beoordeeld werden de overleving van de implantaten en de overkappingsprothese, de conditie van de peri-implantaire mucosa en de veranderingen in het niveau van het peri-implantaire bot. De evaluatieperiode van de geïncludeerde onderzoeken was minimaal 1 jaar (hoofdstuk 2). De literatuur werd doorzocht met behulp van de internet zoekmachines MEDLINE (1950-augustus 2009), EMBASE (1966-augustus 2009) en Central (1800-augustus 2009). Twee onderzoekers beoordeelden onafhankelijk van elkaar de artikelen. Van de 147 primair geselecteerde artikelen, voldeden 31 studies aan de opgestelde criteria.

Een meta-analyse toonde aan dat de één jaars implantaatoverleving 98,2% per jaar was in het geval van zes implantaten in de bovenkaak in combinatie met een staaf-suprastructuur, 96,3% in geval van vier implantaten in combinatie met ofwel een staaf-suprastructuur en 95,2% in geval van vier of minder implantaten in combinatie met een knopverankering. Geconcludeerd werd dat de overlevingskans van de implantaten voor elk van deze behandelopties ten minste 95% was en de behandeloptie van een overkappingsprothese op implantaten in de bovenkaak op zes tandheelkundige implantaten, die zijn verbonden met een staaf-suprastructuur de meest succesvolle behandeling met betrekking tot de overleving van de implantaten en de overkappingsprothese was. Deze behandeloptie werd op de voet gevolgd door vier implantaten en met een staaf-suprastructuur en vier of minder implantaten met een knopverankering.

In het tweede deel van dit promotieonderzoek lag de nadruk van het onderzoek op de behandeluitkomst van een overkappingsprothese op vier of zes implantaten in combinatie met een staaf-suprastructuur en overkappingsprothese.

De doelstelling van de in hoofdstuk 3 beschreven gerandomiseerde klinische studie was het vergelijken van het resultaat van de behandeling van de tandeloze bovenkaak met vier of zes implantaten in het voorste gedeelte van de bovenkaak in combinatie met een staaf-suprastructuur en een overkappingsprothese gedurende een evaluatie periode van 1 jaar. Vijftig edentate patiënten met gebrek aan retentie en stabiliteit van het de prothese in de bovenkaak en met voldoende bot volume om implantaten te plaatsen in het voorste gedeelte van de bovenkaak werden geselecteerd. Het lot besliste of de patiënten werden toegewezen aan de groep met vier of zes implantaten. De implantaatoverleving, de overleving van de overkappingsprothese, klinische scores (plaquescore, bloeding van de gingiva bij sonderen, aanwezigheid van tandsteen en pocketdiepte), veranderingen in de peri-implantaire bothoogte en patiënttevredenheid werden beoordeeld. Negenenveertig patiënten (één patiënt overleed gedurende het eerste jaar) voltooiden de evaluatie periode van één jaar. Na 1 jaar was de implantaat overleving 100% in de groep met vier implantaten en 99,3% in de

groep met zes groep implantaten (1 implantaat was verloren gegaan). De overleving van de overkappingsprothese was 100% in beide groepen. De klinische scores waren laag (een lage score is gunstig) en er bestond geen significant verschil tussen de groepen. De gemiddelde marginale bot resorptie was $0,24 \pm 0,32$ mm $0,25 \pm 0,29$ mm in de groep met respectievelijk vier en zes implantaten. De tevredenheid van de patiënten was in beide groepen even sterk verbeterd.

De vraag is kan worden gesteld of vier implantaten voldoende zijn ter ondersteuning en verankering van een overkappingsprothese met een staaf-suprastructuur in het voorste gedeelte van de bovenkaak. Deze vraag kan positief worden beantwoord wanneer er voldoende bot in het voorste gedeelte van de bovenkaak aanwezig is en er bovendien voldoende ruimte is voor het aanbrengen van een staaf-suprastructuur in combinatie met een overkappingsprothese. Een belangrijk voordeel van het plaatsen van implantaten in het voorste gedeelte van de bovenkaak ten opzichte van het plaatsen van implantaten in de zijdelingse delen van de bovenkaak is dat deze behandeling minder tijd vergt en de nabezwaren voor de patiënt veelal geringer zijn. Een belangrijk probleem bij het plaatsen van implantaten in de zijdelingse delen van de edentate bovenkaak is immers dat vaak het botvolume onvoldoende is op de plaats waar men de implantaten wil plaatsen en derhalve vaak een afzonderlijke operatie nodig is om het benodigde bot aan te brengen. Meestal wordt hiervoor bot van de bekkenkam gebruikt waardoor de patiënt moet worden opgenomen in een ziekenhuis, de patiënt meer nabezwaren heeft (het lopen is de eerste weken na de operatie vaak pijnlijk). Bovendien brengt deze ingreep meer kosten met zich mee. Een ander voordeel is dat implantaten in het voorste gedeelte van de bovenkaak beter toegankelijk zijn voor de patiënt met als mogelijk gevolg een betere mondhygiëne.

De doelstelling van de in hoofdstuk 4 beschreven gerandomiseerde klinische studie was het vergelijken van het resultaat van de behandeling van de edentate bovenkaak met vier of zes implantaten in de zijdelingse delen van de bovenkaak in combinatie met een staaf-suprastructuur en een overkappingsprothese gedurende een evaluatie periode van 1 jaar. Zesenzestig edentate patiënten met een ontoereikend botvolume in de bovenkaak voor het plaatsen van implantaten werden gevraagd om deel

te nemen aan dit onderzoek. Het lot besliste of de patiënten werden toegewezen aan de groep met vier of met zes implantaten. Bij alle patiënten werd voorafgaande aan de ingreep waarbij de implantaten werden geplaatst een verhoging van de sinusbodem uitgevoerd met bot geogst van de bekkenkam. Vier of zes implantaten werden na een genezingsperiode van 3 maanden aangebracht in de zijdelingse delen (twee of drie aan iedere zijde) van de bovenkaak. Drie maanden na het aanbrengen van de implantaten werd begonnen met het vervaardigen van de overkappingsprothese in combinatie met een staaf-suprastructuur. De implantaatoverleving, de overleving van de overkappingsprothese, de plaquescore, de conditie van de peri-implantaire mucosa, de pocketdiepte, veranderingen in de peri-implantaire bothoogte en de patiënttevredenheid werden beoordeeld. Alle patiënten voltooiden de evaluatie periode van 1 jaar. Na een functionele periode van 1 jaar was de implantaat overleving 100% in de groep met vier implantaten en 99,5% in de groep met zes groep implantaten (1 implantaat was verloren gegaan). De overleving van de overkappingsprothese was 100% in beide groepen. De klinische scores waren laag en er bestonden geen significante verschillen tussen de groepen. De peri-implantaire bot resorptie bedroeg $0,35 \pm 0,31$ mm in de groep met 4 implantaten en $0,46 \pm 0,34$ mm in de groep met zes implantaten. De tevredenheid van de patiënten was in beide groepen aanzienlijk verbeterd en verschilde niet tussen de groepen. Omdat de behandelresultaten van een overkappingsprothese in combinatie met een staaf-suprastructuur op vier implantaten vergelijkbaar waren met die van een overkappingsprothese in combinatie met een staaf-suprastructuur op zes implantaten in de zijdelingse delen van de bovenkaak, reist ook hier de vraag of vier implantaten voldoende zijn voor een overkappingsprothese op implantaten. Voorts wordt op grond van de resultaten beschreven in hoofdstukken 3 en 4 voorgesteld om, zolang er nog geen duidelijke richtlijnen zijn ten aanzien van de plaats van de implantaten bij de behandeling van de edentate bovenkaak, te kiezen voor vier implantaten in combinatie met een staaf-suprastructuur als er voldoende bot in het voorste gedeelte van de bovenkaak in combinatie met voldoende ruimte voor de overkappingsprothese en een staaf-suprastructuur is. Deze ingreep heeft de kortste behandelduur en kent de minste nabezwaren. Bij veel patiënten, in het bijzonder bij patiënten die lang edentaat zijn,

is door resorptie het beschikbare botvolume in het voorste deel van de bovenkaak vaak onvoldoende. Bij deze patiënten moeten de implantaten in de zijdelingse delen van de bovenkaak worden aangebracht, vaak in combinatie met een verhoging van de bodem van de neusbijholte met een bottransplantaat.

In het derde deel van dit proefschrift wordt een prospectief beschreven naar het behandelresultaat van overkappingsprothesen in combinatie met zes implantaten in de bovenkaak en een (gedeeltelijk) betande onderkaak (hoofdstuk 5). De duur van het onderzoek was 1 jaar. Vijftig patiënten werden behandeld met een overkappingsprothese in de bovenkaak in combinatie met een staaf-suprastructuur. Bij 25 patiënten werden zes implantaten geplaatst in het voorste gedeelte van de bovenkaak en bij 25 patiënten zes implantaten (drie aan iedere zijde) in de zijdelingse delen van de bovenkaak. De implantaatoverleving, de overleving van de overkappingsprothese, de plaquescore, toestand van de peri-implantaire mucosa, pocketdiepte, veranderingen in de peri-implantaire bothoogte en de patiënttevredenheid werden beoordeeld. De 1-jaars implantaatoverleving bedroeg 98% (3 implantaten verloren in 2 patiënten) in de groep met implantaten in het voorste gedeelte en 99,3% (1 implantaat verloren) voor patiënten met implantaten in de zijdelingse delen van de bovenkaak. Het peri-implantair bot verlies gemeten op de röntgenfoto bedroeg $0,22 \pm 0,29$ en $0,50 \pm 0,68$ mm ter plaatse van respectievelijk de implantaten in het voorste deel en in de zijdelingse delen van de bovenkaak. De scores betreffende plaque, de conditie van de mucosa, de pocketdiepte en aanwezigheid van tandsteen waren laag en de patiënttevredenheid was hoog, en verschilde niet significant tussen de groepen.

Het resultaat van de in dit hoofdstuk beschreven behandeling is zeer veelbelovend wanneer in ogenschouw wordt genomen dat een betande onderkaak welliswaar geen contra-indicatie is voor het aanbrengen van implantaten, maar wel als risicofactor voor implantaatverlies wordt aangemerkt in combinatie met een overkappingsprothese op implantaten in de bovenkaak. De grote kracht van de kauwspieren en de schadelijke laterale krachten die op de implantaten worden uitgeoefend als gevolg van een minder ideaal occlusie concept worden namelijk als risicofactoren

gezien. Om dit risico te beheersen wordt vaak het bilateraal gebalanceerde occlusieconcept van een volledige conventionele prothese gebruikt bij de vervaardiging van een overkappingsprothese op implantaten. In het geval van natuurlijke gebitselementen in de betande onderkaak is dit vaak niet mogelijk, omdat de occlusie is ingegeven door de anatomische vorm en (soms minder ideale) positie van de natuurlijke gebitselementen. Aangeraden wordt de occlusie zo aan te passen dat deze comfortabel is voor de patiënt.

In het vierde deel van dit proefschrift (hoofdstuk 6) wordt verslag gedaan van de behandeling van een volledig edentate patiënt waarbij een overkappingsprothese op implantaten wordt vervaardigd. Bij deze edentate patiënt werd een sinus bodem elevatie procedure uitgevoerd met bot afkomstig uit de bekkenkam. Na een genezingsperiode van drie maanden werden vier implantaten geplaatst in de zijdelingse delen (twee aan iedere zijde) van de bovenkaak gevolgd door de vervaardiging van een overkappingsprothese met een staaf-suprastructuur. De technische procedure voor vervaardiging van een verstevigingsframe van cobalt-chroom waaraan de clips worden bevestigd, wordt beschreven. Het verstevigingsframe wordt vervolgens in het acryl van de overkappingsprothese geïntegreerd. Het voordeel van deze procedure is een overkappingsprothese met minder breuk en minder retentie verlies van de clips.

In het laatste deel van dit proefschrift worden de belangrijkste onderzoeksresultaten besproken en worden algemene conclusies getrokken (hoofdstuk 7). Zowel vier als zes tandheelkundige implantaten geplaatst in het voorste gedeelte of in de zijdelingse delen van de edentate bovenkaak, verbonden met een staaf-suprastructuur, vormen een goede basis voor de retentie ondersteuning van overkappingsprothese in de bovenkaak, gemeten na een functionele periode van 1 jaar (hoofdstukken 3 en 4). Deze uitkomsten komen overeen met de resultaten van de in hoofdstuk 2 beschreven systematische literatuurstudie Ook bij patiënten met natuurlijke gebitselementen in de onderkaak waren de uitkomsten van de peri-implantaire parameters en de tevredenheid van de patiënten vergelijkbaar voor wat betreft de overkappingsprothese in combinatie met een staaf-

suprastructuur op zes implantaten in het voorste gedeelte of in de zijdelingse delen van de bovenkaak (hoofdstuk 5). M.a.w. bij de behandeling van een patiënt met problemen betreffende gebrek aan retentie en stabiliteit van de prothese in de bovenkaak of bij een patiënt die problemen ervaart ten gevolge van de gehemelte plaat van de prothese, moet eerst de oorsprong van het probleem zorgvuldig worden bestudeerd en geëvalueerd. Wanneer vervolgens wordt besloten tot de plaatsing van implantaten ter retentie en ondersteuning van een overkappingsprothese, moet worden beoordeeld of de plaatsing van implantaten in het voorste gedeelte van de bovenkaak mogelijk is. Een dergelijke behandeling zorgt voor een kortere behandelduur en minder nabezwaren in vergelijking met het plaatsen van implantaten in de zijdelingse delen van de bovenkaak, wanneer deze wordt voorafgegaan door een operatieve vergroting van het botvolume in de bovenkaak met bot verkregen uit de bekkenkam. Voorts geniet plaatsing van vier implantaten, waarop een staaf-suprastructuur wordt vervaardigd, de voorkeur boven het plaatsen van zes implantaten vanuit een perspectief van nabezwaren, prothetische procedure en kosteneffectiviteit. Afsluitend moet worden opgemerkt dat de resultaten van de in dit proefschrift beschreven onderzoeken berusten op een evaluatieperiode van 1 jaar. Voor definitieve conclusies is een langere evaluatie periode nodig.

Dankwoord

Dankwoord

Het doen van onderzoek is teamsport. Alleen samen kun je successen behalen. Ik heb geluk gehad een zeer goed team om me heen te hebben. Helaas heb ik een keuzes moeten maken bij het schrijven van dit dankwoord. Ik hoop van harte dat ik daar niemand te kort mee doe.

Als eerste wil ik alle patiënten bedanken die hebben deelgenomen aan één van de onderzoeken. Zonder hun bijdrage, in de vorm van het invullen van vragenlijsten en het ondergaan van klinische metingen, was dit proefschrift niet mogelijk geweest.

Prof. dr. H.J.A. Meijer, hooggeleerde eerste promotor, beste Henny. Ik bewonder het gemak waarmee jij onderzoeksprojecten van de grond krijgt. Via jou ben ik aan het onderwerp van dit promotieonderzoek gekomen. Je hebt me overtuigd dat dit grote project haalbaar was. Met niet aflatende inzet heb je me geholpen het onderzoek tot een goed einde te brengen. Ik denk met plezier terug aan onze onderzoeksessies, met name die met mooi weer in jouw tuin en die op de golfbaan. Ik dank je hartelijk voor de prettige samenwerking.

Prof. dr. G.M. Raghoobar, hooggeleerde tweede promotor, beste Gerry. Door jou ben ik in mijn tijd op de kaakchirurgie geïnteresseerd geraakt in de tandheelkundige implantologie. Je zorgvuldige manier van opereren heeft ertoe geleid dat we tot nu toe uitermate weinig implantaat verlies heb geleden. Dat is wel eens lastig uit te leggen aan je collega's. Verder heb ik het zeer gewaardeerd dat je als ervaren spreker, op de grote podia over de gehele wereld, mijn presentaties van commentaar wilde voorzien. Hartelijk bedankt voor de fijne samenwerking.

Prof. dr. A. Vissink, hooggeleerde derde promotor, beste Arjan. Er is niemand die artikelen zo snel kan beoordelen als jij. Wanneer ik 's avonds een manuscript per mail aan je opstuurde, vond ik het de volgende ochtend keurig van commentaar voorzien in mijn email terug. Verder was het mij een genoegen om met je de statistiek van de klinische studies te doen. Ik wil je hartelijk bedanken voor de fijne samenwerking.

Leden van de beoordelingscommissie, prof. dr. C.M. ten Bruggenkate, prof. dr. J.M.A. de Lange en prof. dr. C. de Putter. Ik wil u graag bedanken voor de bereidheid om zitting te nemen in de leescommissie en voor de tijd die u heeft genomen om het manuscript te beoordelen.

Prof. dr. W. Kalk en prof. dr. F. Abbas, beste Warner en Frank. Hartelijk dank voor de mogelijkheid die ik heb gekregen om op het Centrum voor Tandheelkunde en Mondzorgkunde dit promotie-traject te doorlopen.

Dr. J.J.R. Huddleston Slater, beste James. Mede dankzij jouw statistische ondersteuning heb ik prijzen gewonnen met het artikel "A systematic review of implant-supported maxillary overdentures after a mean observation period of at least 1 year" gepubliceerd in the Journal of Clinical Periodontology in 2010.

Dr. D. Rickert, beste Daniela. Dank dat je mijn student-assistent wilde zijn. Dat je een organisatorisch wonder bent werd mij al snel duidelijk. Het doet me plezier dat je aan je student-assistentenschap zelf ook een promotie onderzoek hebt overgehouden. Dat je inmiddels ook al gepromoveerd bent maakt weer eens duidelijk wat voor een talenten je bezit.

Dr. L. den Hartog, dr. G. Telleman, drs Y.C.M. de Waal, drs. H.J. Sating, drs. C. Jensen, dr. N. Tymstra, dr. C. Stellingsma, drs. F.L. Guljé, beste Laurens, Gerdien, Yvonne, Eric, Charlotte, Nienke, Kees en Felix. Dank voor jullie interesse in mijn onderzoek en de vele gezellige momenten op het UMCG en natuurlijk tijdens de EAO.

Mw. D. Jannenga en mw. B. Brongers en mw. R.R. Pleijendal, Beste Diny, Bertina en Linda. Het maken van de afspraken met de patienten, de organisatie rond de gebitsmodellen en boormallen kon ik met een gerust hart aan jullie overlaten. Bedankt voor jullie ondersteuning bij het onderzoek.

Dhr. A.K. Wietsma, beste Anne. Ik wil je hartelijk bedanken voor het boren van de sjablonen, die in dit promotieonderzoek zijn gebruikt. Vaak moest dit op het laatste moment, maar dankzij jou was het altijd op tijd klaar.

Drs. H.M. de Winter, beste Marije. Jouw scriptie was een goede basis voor verder onderzoek naar het resultaat van de behandeling van patienten, met een tandeloze bovenkaak in combinatie met een (partieel) betande onderkaak, door middel van een implantaat gedragen bovenprothese. Bedankt voor al het werk dat je mij uit handen hebt genomen.

Drs. B. Zwarteveen en dr. F. Jüch, beste Bert en Frits. Ik heb het getroffen met jullie als opeenvolgende kamerogenoten. Dank dat jullie me dagelijks gesteund hebben bij mijn onderzoek. Ik kon altijd met vragen bij jullie terecht. Verder was het natuurlijk ook gewoon gezellig. Nu mijn promotieonderzoek is afgerond, zal ik de tijd nemen om de dozen met gebitsmodellen op te ruimen zodat Frits weer bij zijn kast kan.

Al mijn collega's en assistentes en overige medewerkers van het centrum voor tandheelkunde en mondzorgkunde wil ik bedanken voor de prettige werksfeer en hun interesse in het onderzoek.

De studenten tandheelkunde die belangeloos geholpen hebben bij de eerste screening van de patiënten voor mijn onderzoek wil ik hierbij graag bedanken.

Dhr. G van Dijk, beste Gerrit. Jij en je medewerkers van het Tandtechnisch Maxillofaciaal Laboratorium Gerrit van Dijk hebben zorg gedragen voor de vervaardiging van alle overkappingsprothesen in dit promotieonderzoek. Ik wil jullie graag bedanken voor de prettige manier van samenwerken. Ik waardeer het dat er nooit gemopperd werd wanneer er een prothese moest worden aangepast of gerepareerd, liefst dezelfde dag nog en onder garantie.

Mr. J.P. Loopstra en drs. W.R.J. van der Velde, Beste Jan Pieter en Wim.
We kennen elkaar sinds het begin van onze studie en we zijn vrienden voor het leven. Dat bestendigen we met ons jaarlijks weekendje Ameland. Ieder jaar precies hetzelfde schema, van de gehaktbal op de boot, het huren van de fietsen, tot het tafeltje bij het raam in het NesCafé. Ik verheug me er nu al weer op. Bedankt dat jullie mijn paranimfen willen zijn.

Lieve vader (†2007) en moeder. Bedankt dat ik de mogelijkheid heb gekregen om te studeren en dat jullie mij altijd hebben vrijgelaten in mijn keuzes, hoewel dat vast niet altijd gemakkelijk moet zijn geweest.

Dinand en Alma, Lieve broer en zus. We zien elkaar te weinig, maar als we bij elkaar zijn is het altijd weer gezellig.

Marjette en Wilbert. Ik ben blij dat ik zulke geweldig lieve kinderen heb. Dat jullie nu ook aan de R.U.G. studeren doet bij mij gouden herinneringen herleven. Ik ben trots op jullie.

Lieve schoonfamilie. Bedankt voor de interesse in mijn onderzoek. En speciaal wil ik jou bedanken Monique, voor de fijne en creatieve wijze waarop je me hebt geholpen met de lay-out en het drukken van het proefschrift.

En last but not least wil ik jou bedanken allerliefste Henny. Héél lang geleden heb je eens gezegd: "Wim, je moet nu kiezen: of je maakt je studie af óf je wordt maar postbode". Zonder deze dwingende mededeling was ik nooit gekomen waar ik nu ben. Ik waardeer je open manier van communiceren, je enthousiasme en je tomeloze energie. Bedankt dat je altijd voor mij en de kinderen klaar staat, naast je drukke huisartsenpraktijk.



Curriculum Vitae

Wim Slot was born on the first of July 1960 in Coevorden. A small city in the east of the Netherlands. After graduation from the University of Groningen (Netherlands) in 1991, he worked at the department of oral and maxillofacial surgery of the University Medical Center Groningen. Here he was trained in oral and dental implantology. Since 1997 he has held a position at the Center for Dentistry and Oral Health of the University Medical Center Groningen, where he teaches and practices oral and implant surgery. In September 2004 he started his PhD research on “Implant-supported Maxillary Overdentures” presented in this thesis. Wim is married to Henny Slot-van der Goot. Together they have two children, Marjette and Wilbert.

Address for correspondence

J.W.A. Slot
University Medical Center Groningen
Center for Dentistry and Oral Health
Ant. Deusinglaan 1
9713 AV Groningen
The Netherlands

j.w.a.slot@umcg.nl
www.mondarts.nl