

University of Groningen

Pelvic high-grade serous carcinoma in BRCA1 and BRCA2 mutation carriers

Reitsma, Welmoed

IMPORTANT NOTE: You are advised to consult the publisher's version (publisher's PDF) if you wish to cite from it. Please check the document version below.

Document Version

Publisher's PDF, also known as Version of record

Publication date:

2013

[Link to publication in University of Groningen/UMCG research database](#)

Citation for published version (APA):

Reitsma, W. (2013). *Pelvic high-grade serous carcinoma in BRCA1 and BRCA2 mutation carriers: carcinogenesis and early diagnosis*. [s.n.].

Copyright

Other than for strictly personal use, it is not permitted to download or to forward/distribute the text or part of it without the consent of the author(s) and/or copyright holder(s), unless the work is under an open content license (like Creative Commons).

The publication may also be distributed here under the terms of Article 25fa of the Dutch Copyright Act, indicated by the "Taverne" license. More information can be found on the University of Groningen website: <https://www.rug.nl/library/open-access/self-archiving-pure/taverne-amendment>.

Take-down policy

If you believe that this document breaches copyright please contact us providing details, and we will remove access to the work immediately and investigate your claim.

Downloaded from the University of Groningen/UMCG research database (Pure): <http://www.rug.nl/research/portal>. For technical reasons the number of authors shown on this cover page is limited to 10 maximum.

Chapter 5

SUPPORT OF THE 'FALLOPIAN TUBE HYPOTHESIS' IN A PROSPECTIVE SERIES OF RISK-REDUCING SALPINGO- OOPHORECTOMY SPECIMENS

WELMOED REITSMA, GEERTRUIDA H DE BOCK, JAN C OOSTERWIJK, JOOST
BART, HARRY HOLLEMA, MARIAN JE MOURITS

EUROPEAN JOURNAL OF CANCER 2013;49:132-141

ABSTRACT

OBJECTIVE

To determine the prevalence, localization and type of occult (non-)invasive cancer in risk-reducing salpingo-oophorectomy (RRSO) specimens in *BRCA*-mutation carriers and high-risk women from *BRCA*-negative families.

METHODS

A consecutive series of RRSO specimens of asymptomatic, screen-negative high-risk women were prospectively collected in our tertiary multidisciplinary cancer clinic from January 2000 until March 2012. All high-risk women in this study underwent genetic testing on *BRCA*-mutations. The surgico-pathological protocol comprised complete resection of ovaries and fallopian tubes, transverse sectioning at 2-3 mm (sectioning and extensively examining the fimbrial end [SEE-FIM] protocol from 2006) and double independent pathology review of morphologically deviant sections.

RESULTS

Three hundred and sixty RRSOs were performed in 188 *BRCA1*-carriers, 115 *BRCA2*-carriers and 57 *BRCA*-negative women at a median age of 44.0 years. Four occult invasive cancers were detected in *BRCA*-carriers (1.3%, 95%-confidence interval (CI) 0.03-2.61), all in *BRCA1*-carriers >40 years of age. All cancers, of which two tubal and two ovarian cancers, were FIGO-stage I/II. Three non-invasive serous intraepithelial carcinomas (STICs) were detected in *BRCA*-carriers (1.0%, 95%-CI 0.00-2.10). In *BRCA*-negative women one STIC was found (1.8%, 95%-CI 0.00-5.16), however she carried an unclassified variant in *BRCA2*. Total follow-up after RRSO was 1691 women years, in which one *BRCA1*-carrier developed peritoneal cancer (0.3%, 95%-CI 0.00-0.82).

CONCLUSIONS

A low prevalence of occult invasive cancer (1.1%) was found in young asymptomatic, screen-negative women at increased ovarian cancer risk undergoing RRSO. This study adds to the advice to perform RRSO in *BRCA1*-carriers before the age of 40. Our findings support the hypothesis of the fallopian tube as the primary site of origin of pelvic high-grade serous cancer.

INTRODUCTION

Epithelial ovarian cancer aggregates in families. A family history of ovarian cancer confers an increased risk for this disease: the lifetime risk for women with one first-degree relative affected by ovarian cancer is 3.5-7% and increases to 15% when two first-degree relatives are affected.¹ In approximately 10% of all ovarian cancer cases, a deleterious *BRCA1/2* germline mutation can be detected.^{2, 3} The lifetime risk of developing ovarian cancer in women with a proven *BRCA1*-mutation ranges from 18% to 54% and is 2.4-23% in *BRCA2*-mutation carriers by the age of 70 years.^{4, 5}

Since the proven ineffectiveness of gynecologic screening in detecting early-stage ovarian/tubal cancer,^{6, 7} *BRCA*-carriers are recommended to undergo risk-reducing salpingo-oophorectomy (RRSO). If performed at a young age, RRSO is associated with a statistically significant reduction of the risk of *BRCA*-associated ovarian/tubal cancer (hazard ratio (HR) 0.21; 95%-confidence interval (CI) 0.12-0.39).⁸ After RRSO, a residual risk may exist for 'primary' peritoneal cancer; although according to new insights peritoneal cancer is possibly metastatic from tubal intraepithelial carcinoma.^{9, 10}

Occult cancers have been reported in prophylactically removed ovaries and fallopian tubes in *BRCA*-carriers. Reported rates vary considerably from 2-12%^{11, 12} and seem to be influenced by patients' age at RRSO, symptoms, gynecologic screening prior to RRSO, the completeness of prophylactic surgery and the extent of histopathological examination. Non-invasive serous tubal intraepithelial carcinomas (STICs) have been identified in 3-12% of the prophylactically removed tubes of *BRCA*-carriers, especially in the fimbrial part.^{11, 13} No intraepithelial carcinomas have ever been found in ovaries so far, suggesting that ovarian cancer does not have its origin in the ovary itself.¹⁴ The fallopian tube is currently being suggested as the primary site of origin of pelvic high-grade serous cancer,¹⁵ which has recently been established in a mouse model.¹⁶

Aim of this study was to obtain an unbiased estimate of the prevalence, localization and type of occult (non-)invasive cancer in prophylactically removed ovaries and tubes in a consecutive series of *BRCA*-carriers and high-risk women from *BRCA*-negative families attending a tertiary multidisciplinary cancer clinic.

PATIENTS AND METHODS

The Family Cancer Clinic (FCC) at the University Medical Center Groningen (UMCG) is a tertiary level clinic for managing women at hereditary or familial high-risk for ovarian (and breast) cancer (H(B)OC). From 1996, clinical and genetic data of all high-risk families have been prospectively registered at the FCC in a combined setting by a clinical geneticist, a gynecologic oncologist and a surgical oncologist.¹⁷ Genetic testing for *BRCA*-mutations is available to women from H(B)OC families (see criteria in Figure 1).¹⁸ Women with a confirmed *BRCA*-mutation are being counseled to consider RRSO from the age of 35 (*BRCA1*) or 40 (*BRCA2*), or as soon as childbearing after this age is completed.¹⁸ Women from a H(B)OC family who tested negative for *BRCA*-mutations (further denoted 'BRCA-negative high-risk women') are also offered RRSO if the estimated lifetime risk of developing ovarian cancer is >10%. After RRSO, women still visit the FCC for breast cancer screening by a surgical oncologist.¹⁹

FIGURE 1. Definition of women at high-risk of breast and/or ovarian cancer: criteria for *BRCA* mutation testing established by the Netherlands Foundation for the Detection of Hereditary Tumours (STOET)¹⁸

Breast cancer	Ovarian cancer
One breast cancer case <35 years of age	Epithelial ovarian-/tubal cancer <50 years of age
Contralateral breast cancer with the first tumor <50 years of age	Ovarian-/tubal cancer and breast cancer in the same family of in one patient, with at least one tumor <50 years of age
One case of triple negative breast cancer <40 years of age	Two first-degree or one first- and one second-degree relative with ovarian-/tubal cancer
The occurrence of breast cancer <50 years of age and ovarian cancer in a first-degree relative	
The occurrence of a male breast cancer	
Two breast cancer cases in first-degree relatives with at least one case <50 years of age	
Three or more first-degree relatives with breast cancer in two successive generations with at least one case <50 years of age	
Breast or ovarian cancer <50 years of age and prostate cancer <60 years in the same family	

A consecutive series of RRSO specimens of *BRCA1*-carriers, *BRCA2*-carriers and *BRCA*-negative high-risk women was prospectively collected in the UMCG between 1st January 2000 and 1st March 2012. Included were asymptomatic women who had a negative gynecologic screening (pelvic examination, transvaginal ultrasound and serum CA125

measurement) within one year prior to RRSO.⁷ Excluded were women with ovarian/tubal cancer prior to RRSO and women who underwent salpingo-oophorectomy as part of breast cancer therapy. Main outcome measures were the prevalence and localization of occult cancer and STIC (primary outcomes), and of atypical hyperplasia (secondary outcome).²⁰ An anonymous, password-protected database was used to enter the data. Protection of the patients' identity was guaranteed by assigning study-specific, unique patient numbers and codes were only known to two dedicated data managers. According to Dutch law, no further Institutional Review Board approval was needed for this study.

A strict surgico-pathological protocol was applied consisting of complete resection of both tubes and ovaries that were transversely sectioned at 2-3 mm intervals and processed in their entirety.²¹ Since Madeiros et al.²² in 2006 published a protocol for sectioning and extensively examining the fimbrial end (SEE-FIM), this protocol was implemented in our study. From the ovaries and fallopian tubes a small part was snap frozen for the tissue bank, as according to the protocol, a haematoxylin and eosin (H&E) section was made to check for histological abnormalities and additional immunohistochemical staining of p53 and MIB-1 (Ki67) was performed. Histopathological examination was conducted by two expert gynecologic pathologists (H.H. and J.B.) who were aware of the woman's mutation status. The H&E sections showing morphologically atypical epithelium, STIC or occult cancer and a sample of normal sections, were independently revised by the other expert gynecologic pathologist without knowledge of the previous pathologic report.

Occult cancer was defined as a clinically unapparent invasive malignancy of the epithelium of the ovary or fallopian tube diagnosed at histopathological examination, according the guidelines of the International Federation of Gynecology and Obstetrics (FIGO). In this paper, occult cancer refers to an invasive malignancy and not to an in situ component. STIC was defined as an intraepithelial carcinoma that was in continuity with normal mucosal epithelium, with epithelial stratification, nuclear enlargement, prominent nucleoli, variable loss of epithelial polarity and mitotic activity (Figure 2D-F).²³ Cases with histological abnormalities not amounting to STIC, but showing some cellular crowding, stratification, loss of nuclear polarity and moderate to severe nuclear atypia, were defined as atypical hyperplasia (Figure 2A-C).²⁰ Positive staining for p53 was not required for diagnosing atypical hyperplasia. All *BRCA1*-mutation carriers presented in this paper had a proven pathogenic mutation (splice site mutations, nonsense mutations, frameshifts or exon deletions). Patients carrying an unclassified variant (UV) were incorporated in the group 'negative tested women'. The start of follow-up after RRSO was defined as the date of RRSO and the end of follow-up as the date of the last outpatient visit.

Statistical analysis was performed using SPSS 18.0 for Windows (SPSS, Chicago, IL, USA). Descriptive values of variables were expressed as frequencies and percentages for discrete data and as median and range for continuous data. Differences between the groups were investigated with the Chi-square test or Fisher's exact test for discrete variables and with the Mann Whitney U test or Kruskal-Wallis test for continuous data. For each woman, duration of follow-up was calculated. Confidence intervals for a single proportion were calculated and *P*-values <0.05 were considered to be statistically significant.

RESULTS

From January 2000 until March 2012, 641 women from high-risk families visited our FCC after referral by the clinical genetics department. In total, 360 women underwent RRSO, among whom were 188 *BRCA1*-carriers (52.2%) from 221 *BRCA1*-families, 115 *BRCA2*-carriers (31.9%) from 146 *BRCA2*-families, and 57 *BRCA*-negative high-risk women (15.8%) from 45 *BRCA*-negative high-risk families (reference date: 1st March 2012) (Table 1). Of the *BRCA*-negative women, five had a UV in one of the *BRCA*-genes.

TABLE 1. Characteristics of the study population

	<i>BRCA1</i> (n=188)	<i>BRCA2</i> (n=115)	<i>BRCA</i> -negative* (n=57)	Total† (n=360)	<i>P</i>
	n (% or range)	n (% or range)	n (% or range)	n (% or range)	
<i>At RRSO:</i>					
Age at RRSO, median	42.0 (30-72)	45.0 (33-66)	47.0 (36-66)	44.0 (30-72)	<0.001
Breast cancer prior to RRSO	73 (38.8)	33 (28.7)	31 (54.4)	137 (38.1)	0.005
Age at first breast cancer (n=139), median	39.0 (23-63)	45.0 (30-64)	41.0 (28-53)	41.0 (23-64)	0.08
Menopausal status					
Premenopausal	138 (73.4)	74 (64.3)	34 (59.6)	246 (68.3)	0.08
Postmenopausal	50 (26.6)	41 (35.7)	23 (40.4)	114 (31.7)	
Time from last screening to RRSO in months, median	3.0 (0-21)	2.0 (0-18)	2.0 (0-20)	2.0 (0-21)	0.55
Type of primary surgery					
Laparoscopy	185 (98.4)	115 (100.0)	57 (100.0)	357 (99.2)	0.25
Laparotomy	3 (1.6)	- -	- -	3 (0.8)	
Peritoneal lavage performed	141 (75.0)	95 (82.6)	51 (89.5)	287 (79.7)	0.04
Normal cells	141 (100.0)	94 (98.9)	51 (100.0)	286 99.7	
Atypical cells‡	- -	1 1.1	- -	- 0.3	
Malignant cells	- -	- -	- -	- -	
<i>Following RRSO:</i>					
Current age, median	48.0 (31-77)	50.0 (38-75)	53.0 (36-72)	49.0 (31-77)	0.02
Median follow-up, years	5.0 (0-12)	4.0 (0-9)	4.0 (0-9)	5.0 (0-12)	0.001
Total	1003	482	206	1691	
Deceased at the end of the study#	5 (2.7)	3 (2.6)	1 (1.8)	9 (2.5)	0.66

* Including 5 women with a UV mutation in one of the *BRCA* genes: two unlikely pathogenic (category 2 UV) and three possibly pathogenic (category 3 UV) (Bell's classification). † In 1 *BRCA1* en 3 *BRCA2* mutation carriers, RRSO was performed before mutation status was known. ‡ Atypical cells: this patient was diagnosed with endometrioid type endometrial cancer 7 months after RRSO (n=1). # *BRCA1* due to ovarian (n=1) and breast cancer (n=4); *BRCA2* due to breast cancer (n=1), pancreas cancer (n=1) and a non-malignant cause (n=1); negative tested due to breast cancer (n=1).

SUPPORT OF THE 'FALLOPIAN TUBE HYPOTHESIS' IN A PROSPECTIVE
SERIES OF RISK-REDUCING SALPINGO-OOPHORECTOMY SPECIMENS

Median age at RRSO was 44.0 (range, 30-72); *BRCA1*-carriers were significantly younger (42.0) than *BRCA2*-carriers (45.0) and *BRCA*-negative women (47.0; $P < 0.001$). Thirty-eight percent of the women had previously been diagnosed with breast cancer.

Histomorphological findings in RRSO specimens are presented in Table 2. Occult cancer was detected in four women: two fallopian tube and two ovarian cancers. All were *BRCA1*-carriers and above the age of 40 (median age, 55.0) (Table 3). The overall occult cancer rate was 1.1% (95%-CI 0.03-2.19), the rate in *BRCA*-carriers was 1.3% (95%-CI 0.03-2.61) and in *BRCA1*-carriers 2.2% (95%-CI 0.11-4.32). All four patients underwent a surgical staging procedure and all cancers appeared to be early stage (FIGO I/II). Patients were treated with adjuvant chemotherapy (six courses of paclitaxel and carboplatin). No slides or tissue blocks of distal tubes were available from both occult ovarian cancers, most probably because the tissue was used for other research properties; therefore a tubal origin could not be excluded nor proven with certainty.

TABLE 2. Histomorphological findings at RRSO

Histomorphology epithelium†	BRCA1 (n=188)		BRCA2 (n=115)		BRCA-negative* (n=57)		Total (n=360)		P
	Tubes n (%)	Ovaries n (%)	Tubes n (%)	Ovaries n (%)	Tubes n (%)	Ovaries n (%)	Tubes n (%)	Ovaries n (%)	
Occult carcinoma	2 (1.1)	2 (1.1)	-	-	-	-	2 (0.6)	2 (0.6)	0.16
STIC	1 (0.5)	-	2 (1.7)	-	1 (1.8)	-	4 (1.1)	-	0.55
Atypical hyperplasia	11 (5.9)	2 (1.1)	6 (5.2)	3 (2.6)	-	1 (1.8)	17 (4.7)	6 (1.7)	0.28
Reactive changes	2 (1.1)	9 (4.8)	2 (1.7)	8 (7.0)	-	2 (3.5)	4 (1.1)	19 (5.3)	0.53
Metaplasia	-	-	1	1	-	-	1	1	
Hyperplasia	1	7	-	7	-	2	1	16	
Proliferation	1	2	1	-	-	-	2	2	
Benign alterations	68 (36.2)	82 (43.6)	36 (31.3)	56 (48.7)	23 (40.4)	39 (68.4)	127 (35.3)	177 (49.2)	0.27
Epithelial inclusion cysts	-	46	-	31	-	17	-	94	
Para tubal cysts	37	-	22	-	13	-	72	-	
Papillomatosis	-	1	-	3	-	3	-	7	
Adenofibroma	2	4	-	6	-	3	2	13	
Serous cystadenoma	-	6	-	1	-	4	-	11	
Dermoid cyst	-	3	-	1	-	2	-	6	
Brenner tumor	-	4	-	1	-	1	-	6	
Hemangioma	-	1	-	1	-	-	-	2	
Endometriosis	-	2	1	5	1	5	2	12	
Endosalpingiosis	2	-	2	-	-	-	4	-	
Waltherd cell rest	17	1	11	1	7	2	35	4	
Mesonephric rests	10	7	-	3	2	2	12	12	
Ectopic adrenal tissue	-	1	-	2	-	-	-	3	
Leydig-cell hyperplasia	-	3	-	1	-	-	-	4	
Rete ovarii	-	3	-	-	-	-	-	3	

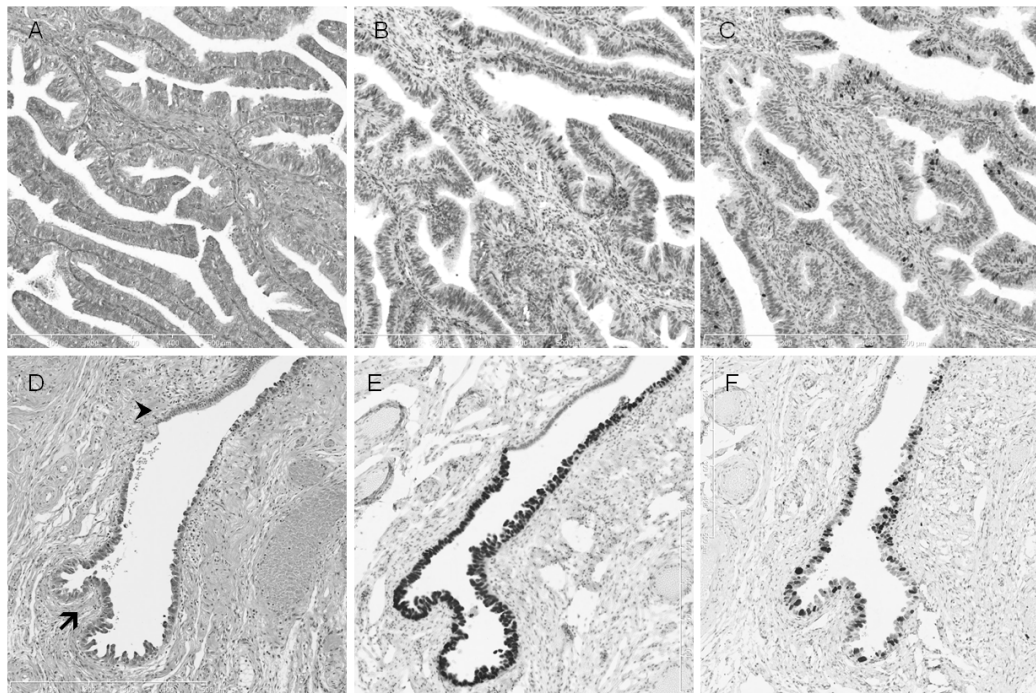
* Including 5 women with a UV mutation in one of the BRCA2 genes: two unlikely pathogenic (category 2 UV) and three possibly pathogenic (category 3 UV) (Bell's classification).

† Multiple abnormalities per woman: in 33.3% (120/360) women no histomorphological abnormalities were found; 35.8% (129/360) women had one lesion (carcinoma, STIC, atypical, reactive or benign); 20.8% (75/360) had two different lesions; 10.0% (36/360) had three or more different lesions.

SUPPORT OF THE 'FALLOPIAN TUBE HYPOTHESIS' IN A PROSPECTIVE SERIES OF RISK-REDUCING SALPINGO-OOPHORECTOMY SPECIMENS

Four cases of STIC (as shown in Figure 2D-F) were detected, all located in the fallopian tube (1.1%, 95%-CI 0.03-2.19): one in a *BRCA1*-carrier (aged 60 years), two in *BRCA2*-carriers (aged 50 and 57 years) and one in a *BRCA*-negative woman (aged 56 years; median age, 56.5) (Table 3). The STIC rate in *BRCA*-carriers was 1.0% (95%-CI 0.00-2.10) and was 1.8% (95%-CI 0.00-5.16) in *BRCA*-negative women.

FIGURE 2. Distal fallopian tube showing atypical hyperplasia (A, B, C) and STIC (D, E, F). A, Atypical hyperplasia in a *BRCA1* mutation carrier showing cellular crowding, stratification, loss of nuclear polarity and moderate nuclear atypia (H&E stain). P53 staining is not markedly increased (B) and proliferation (MIB-1) is not significantly elevated (C). D, Distinction between serous tubal intraepithelial carcinoma (STIC; arrow) and adjacent normal fimbrial mucosal epithelium (arrowhead) in a *BRCA1* carrier (H&E stain). STIC is associated with diffuse immunopositivity for p53 (E), with abrupt negativity of adjacent normal epithelium (arrowhead), and markedly elevated MIB-1 (Ki67) proliferation index (F) (magnification in all figures, x100).



See Appendices, C. Color figures.

TABLE 3. Occult carcinoma and STIC cases detected at RRSO

	Year RRSO, age	Previous breast cancer, age	Mutation status	Cyto- logy	Histology	FIGO stage	Localization	Follow- up, months	Patient status during last FCC visit
1	2002, 51	No	<i>BRCA1</i> c.3676_3679delTTCC	-	High-grade serous carcinoma	IA	Fallopian tube, unilateral	76	NED
2	2003, 62	Yes, bilateral, 23	<i>BRCA1</i> c.4305_5105del	-	High-grade serous carcinoma	IA	Ovary, unilateral	120	NED
3	2004, 41	Yes, unilateral, 39	<i>BRCA1</i> c.3676_3679delTTCC	-	High-grade serous carcinoma	IIC	Ovary, bilateral	89	AD, relapse after 66 months
4+5	2005, 60	Yes, bilateral, 48	<i>BRCA1</i> p.C61G	-	High-grade serous carcinoma and STIC	IC	Fallopian tube, unilateral	107	NED
6	2010, 57	No	<i>BRCA2</i> c.1310_1313del	-	STIC (and atypia)	0	Fallopian tube, bilateral	26	NED
7	2011, 50	No	<i>BRCA2</i> c.9672dupA	-	STIC	0	Fallopian tube, unilateral	8	NED
8	2012, 56	Yes, unilateral, 28	UV mutation in <i>BRCA2</i>	-	STIC	0	Fallopian tube, unilateral	2	NED

Abbreviations: NED, no evidence of disease (= ovarian/tubal/peritoneal cancer); AD, alive with disease. Cytology - = negative.

Atypical hyperplasia (as shown in Figure 2A-C) was present in 23 women (6.4%, 95%-CI 3.86-8.96): 13 *BRCA1*, nine *BRCA2* and one *BRCA*-negative woman (median age, 41.0) (Table 4). Rates were 7.2% (95%-CI 4.34-10.18) for *BRCA*-carriers and 1.8% (95%-CI 0.00-5.16) for *BRCA*-negative women. Seventeen out of 23 lesions were localized in the fimbrial end of the tube (73.9%). The other six atypical lesions also concerned tubal epithelium either located at the ovarian surface or lining epithelial ovarian inclusion cysts. The case of STIC and the case of atypia were found in two *BRCA*-negative high-risk women who however carried a suspected pathogenic (category III) and a possibly pathogenic (category II) UV in *BRCA*, respectively. The case of STIC concerned a 56-year-old woman with a maternal breast/ovarian cancer family, however with a (probably) paternal UV in *BRCA2* (ALA2306Pro) who was diagnosed with

SUPPORT OF THE 'FALLOPIAN TUBE HYPOTHESIS' IN A PROSPECTIVE SERIES OF RISK-REDUCING SALPINGO-OOPHORECTOMY SPECIMENS

breast cancer at the age of 28. The case of atypical hyperplasia concerned a 37-year-old woman with a UV in *BRCA1* (332-15A>G), from a maternal breast/ovarian cancer family. Incidental benign alterations were seen in approximately 40% of the women, without significant differences between *BRCA*-carriers and negative tested women.

TABLE 4. Atypical hyperplasia not amounting to STIC

	Year RRSO, age	Previous breast cancer, age	Mutation status	Cytology	Localization	Follow-up, Patient status months during last FCC visit
1	2007, 41	No	<i>BRCA2</i>	-	Ovarian surface	61 NED
2	2002, 38	No	<i>BRCA1</i>	-	Fallopian tube	120 NED
3	2002, 45	Yes, bilateral, 43	<i>BRCA1</i>	-	Ovarian inclusion cyst	113 NED
4	2002, 41	No	<i>BRCA1</i>	-	Fallopian tube	112 NED
5	2003, 39	No	<i>BRCA1</i>	-	Fallopian tube	109 NED
6	2003, 43	No	<i>BRCA1</i>	-	Fallopian tube	108 NED
7	2004, 37	No	<i>BRCA2</i>	-	Fallopian tube	90 NED
8	2005, 31	No	<i>BRCA1</i>	-	Fallopian tube	84 NED
9	2005, 42	No	<i>BRCA1</i>	-	Fallopian tube	83 NED
10	2005, 43	No	<i>BRCA1</i>	-	Fallopian tube	83 NED
11	2005, 45	No	<i>BRCA1</i>	-	Fallopian tube	82 NED
12	2006, 53	Yes, unilateral, 52	<i>BRCA2</i>	-	Ovarian surface	64 NED
13	2008, 41	No	<i>BRCA2</i>	-	Fallopian tube	42 NED
14	2008, 50	Yes, unilateral, 49	<i>BRCA1</i>	-	Fallopian tube	41 NED
15	2009, 41	No	<i>BRCA2</i>	-	Fallopian tube	32 NED
16	2010, 57	No	<i>BRCA2</i>	-	Ovarian inclusion cyst	26 NED
17	2010, 47	No	<i>BRCA1</i>	-	Fallopian tube	17 NED
18	2000, 48	Yes, unilateral, 44	<i>BRCA1</i>	-	Ovarian inclusion cyst	136 NED
19	2012, 41	Yes, unilateral, 41	<i>BRCA1</i>	-	Fallopian tube	0 NED
20	2012, 40	No	<i>BRCA2</i>	-	Fallopian tube	1 NED
21	2011, 58	No	<i>BRCA2</i>	-	Fallopian tube	9 NED
22	2006, 38	No	<i>BRCA2</i>	-	Fallopian tube	65 NED
23	2008, 37	No	UV mutation in <i>BRCA1</i>	-	Ovarian surface	41 NED

Abbreviation: NED, no evidence of disease (= ovarian/tubal/peritoneal cancer).

CHAPTER 5

The total follow-up after RRSO concerned 1691 women years, with a median follow-up of 5.0 years (range, 0-12) per woman. Specifically, the four patients with occult carcinoma had a median follow-up of 7.5 years (range, 6-10), the four patients with STIC had a median follow-up of 1.0 years (range, 0-6) and the 23 women with atypical hyperplasia had a median follow-up of 5.0 years (range, 0-11). None of the women with STIC or atypical hyperplasia developed peritoneal cancer. One patient, carrying a *BRCA1*-mutation, developed peritoneal cancer 4.2 years after a RRSO (0.3%, 95%-CI 0.00-0.82). Careful histological re-examination of the ovaries and tubes (including immunohistochemical staining of p53 and MIB-1) was performed, which assured the complete removal of both ovaries and tubes, and revealed atypical hyperplasia in the left distal fallopian tube.

DISCUSSION

To date, this is the largest consecutive series of prospectively collected RRSO specimens in *BRCA*-carriers and *BRCA*-negative high-risk women attending a tertiary multidisciplinary cancer clinic. Our study showed a low prevalence of occult cancer (1.1%) and STIC (1.1%), exclusively in *BRCA*-carriers or women with a UV. Two of the four cancers could be proven to originate from the fallopian tube, and all STICs and atypical hyperplastic lesions derived from tubal epithelium. Strengths of this study are the consecutive and uniform series of asymptomatic, screen-negative high-risk women, the independent histopathological revision of the morphologically deviant sections by another expert gynecologic pathologist, the clear distinction between *BRCA*-positive and *BRCA*-negative cases, the large sample-size, the prospective nature of the study and the long duration of follow-up. A limitation was the unavailability of two specimens for histopathological revision.

We found a low prevalence of occult cancer at RRSO of 1.3% in *BRCA*-carriers. Reported prevalence of occult cancer in *BRCA*-carriers varies considerably, from 2-3% in large, mainly multicenter series,^{9, 12, 13, 24, 25} to 7-12% in smaller, particularly single-center series.^{11, 26, 27} The lower cancer prevalence in our series might be explained by age at RRSO, which was 43 years in our series compared to approximately 48 years in the latter.^{11, 26-28} Furthermore, the majority of these studies did not select women on absence of symptoms for the presence of ovarian cancer, nor performed gynecological screening prior to RRSO routinely and advanced stage cancers were not uncommon.^{11, 26, 27} We believe that the selection of young, asymptomatic, screen-negative women for RRSO, contributes to the finding a low occult cancer frequency at RRSO.

Occult cancers in our series were exclusively found in *BRCA1*-carriers above age 40 (2.2%). This is consistent with literature and can be explained by the higher penetrance of ovarian cancer in *BRCA1*- as compared to *BRCA2*-carriers.^{9, 13, 25, 29}

Three STICs were detected in *BRCA*-carriers (1.0%): one in a *BRCA1*-carrier and two in *BRCA2*-carriers. STIC has been reported in 3-12% of the prophylactically removed ovaries and fallopian tubes in *BRCA*-carriers, mostly in the fimbrial end of the tube.^{11, 13, 28, 30-32} Our finding of 1.0% STICs in *BRCA*-carriers is at the lower end of the reported range, which could be explained by the consecutive series of asymptomatic carriers (no case-finding), the relatively young age at RRSO and the strict definitions used. Twenty-three atypical hyperplastic lesions (7.2%) were detected in *BRCA*-carriers. In a recent clinicopathological study of 117 RRSO-specimens of *BRCA*-carriers, atypia was reported in five cases.³¹

Limited data are available on the occult cancer rate in prophylactically removed ovaries and fallopian tubes in *BRCA*-negative high-risk women. Few clinicopathological RRSO studies included a small number of *BRCA*-negative women and none of them found occult cancer or STIC in these women.^{6, 11, 12, 28, 33, 34} We found one STIC (1.8%) and one atypical hyperplastic lesion (1.8%) in *BRCA*-negative women; however both women had a UV *BRCA*-mutation. UV mutations in the *BRCA*-genes are a frequently occurring problem in genetic counseling of breast and/or ovarian cancer families. Data about the cancer history of the

probands and their families are now being used to build a model for evaluating the clinical significance of UV mutations in the medical practice.³⁵

The tubal epithelium was the primary origin of half of the occult cancers, all cases of STIC and all atypical hyperplastic lesions. Other studies demonstrate at least ~40% of the occult cancers being located in the (distal) fallopian tube.^{9, 11, 25, 30, 32, 34, 36} In the two ovarian cancers in our series, a tubal origin could not be studied as no fallopian tube slides or tissue blocks were available anymore. Intraepithelial carcinoma (STIC) has only been described in the fimbrial end of the fallopian tube and never in the ovary.¹⁴ The atypical hyperplastic lesions were either located in the fallopian tube (17/23) or were most likely derived from the fallopian tube (6/23), concerning atypical tubal epithelium located at the ovarian surface or lining epithelial inclusion cysts. These findings might further designate the distal fallopian tube as the primary site of high grade serous cancer.

The diagnosis of atypical hyperplasia with cytological features that falls short of STIC remains controversial. The clinical significance of these lesions in the development of ovarian cancer is unclear; however none of the women diagnosed with atypia in our study developed cancer. More patients with this finding need to be studied to determine whether it has any relationship to the development of STIC. The presence of STIC on the other hand, has been linked as being a pre-invasive phase of ovarian and peritoneal cancer.^{10, 15, 23, 37} The likelihood of developing peritoneal cancer after RRSO has been estimated to be ~1%.^{24, 25, 32, 34, 38} During a total follow-up after RRSO of 1691 women years, one peritoneal cancer has been diagnosed in a *BRCA1*-carrier 4.2 years after RRSO. This low frequency of peritoneal cancer after RRSO makes it less likely that biologically significant lesions as occult cancer and STIC have been missed.

Although the fallopian tube is suggested to be the primary origin of tumorigenesis in *BRCA*-carriers, the ovary may be the preferred site for tumors to progress beyond the microscopic stage.²⁹ A bilateral salpingectomy per se has recently been put forward as a temporary risk-reducing surgical procedure for *BRCA*-carriers, removing the tissue with the greatest malignant potential and avoiding the estrogen deprivation symptoms of the bilateral oophorectomy.^{39, 40} However, caution is needed with translating the tubal hypothesis into clinical practice before it is proven. Besides, even if the fallopian tubes are removed, dysplastic cells may have already spread to the ovary earlier, still resulting in a risk of 'ovarian' cancer.²⁹

Our study, covering a 12-year period, shows a low prevalence of occult cancer and STIC in young asymptomatic, screen-negative women at increased ovarian cancer risk undergoing RRSO. As occult cancers were exclusively found in *BRCA1* above the age of 40, our findings add to the advice for *BRCA1*-carriers to undergo RRSO before the age of 40. In *BRCA*-negative high-risk women, STIC was only found in one woman with a *BRCA* UV. It is important that clinicians are made aware of these issues, as it has implications for counseling high-risk women. Our findings support the hypothesis of the fallopian tube as the primary site of origin of pelvic high-grade serous cancer. It also underscores the importance of complete removal and a strict histopathological sectioning protocol.

ACKNOWLEDGEMENTS

We wish to express our appreciation to Ms Annemieke H van der Hout for updating the mutational information.

REFERENCES

1. Gotlieb WH, Baruch GB, Friedman E. Prophylactic oophorectomy: clinical considerations. *Semin Surg Oncol.* 2000; **19**(1): 20-7.
2. Claus EB, Schildkraut JM, Thompson WD, Risch NJ. The genetic attributable risk of breast and ovarian cancer. *Cancer.* 1996; **77**(11): 2318-24.
3. Lynch HT, Casey MJ, Shaw TG, Lynch JF. Hereditary Factors in Gynecologic Cancer. *Oncologist.* 1998; **3**(5): 319-38.
4. Antoniou A, Pharoah PD, Narod S, Risch HA, Eyfjord JE, Hopper JL, et al. Average risks of breast and ovarian cancer associated with BRCA1 or BRCA2 mutations detected in case Series unselected for family history: a combined analysis of 22 studies. *Am J Hum Genet.* 2003; **72**(5): 1117-30.
5. Chen S, Parmigiani G. Meta-analysis of BRCA1 and BRCA2 penetrance. *J Clin Oncol.* 2007; **25**(11): 1329-33.
6. Hermsen BB, Olivier RI, Verheijen RH, van Beurden M, de Hullu JA, Massuger LF, et al. No efficacy of annual gynaecological screening in BRCA1/2 mutation carriers; an observational follow-up study. *Br J Cancer.* 2007; **96**(9): 1335-42.
7. van der Velde NM, Mourits MJ, Arts HJ, de Vries J, Leegte BK, Dijkhuis G, et al. Time to stop ovarian cancer screening in BRCA1/2 mutation carriers? *Int J Cancer.* 2009; **124**(4): 919-23.
8. Rebbeck TR, Kauff ND, Domchek SM. Meta-analysis of risk reduction estimates associated with risk-reducing salpingo-oophorectomy in BRCA1 or BRCA2 mutation carriers. *J Natl Cancer Inst.* 2009; **101**(2): 80-7.
9. Finch A, Beiner M, Lubinski J, Lynch HT, Moller P, Rosen B, et al. Salpingo-oophorectomy and the risk of ovarian, fallopian tube, and peritoneal cancers in women with a BRCA1 or BRCA2 Mutation. *JAMA.* 2006; **296**(2): 185-92.
10. Seidman JD, Zhao P, Yemelyanova A. "Primary peritoneal" high-grade serous carcinoma is very likely metastatic from serous tubal intraepithelial carcinoma: assessing the new paradigm of ovarian and pelvic serous carcinogenesis and its implications for screening for ovarian cancer. *Gynecol Oncol.* 2011; **120**(3): 470-3.
11. Leeper K, Garcia R, Swisher E, Goff B, Greer B, Paley P. Pathologic findings in prophylactic oophorectomy specimens in high-risk women. *Gynecol Oncol.* 2002; **87**(1): 52-6.
12. Evans DG, Clayton R, Donnai P, Shenton A, Lalloo F. Risk-reducing surgery for ovarian cancer: outcomes in 300 surgeries suggest a low peritoneal primary risk. *Eur J Hum Genet.* 2009; **17**(11): 1381-5.
13. Callahan MJ, Crum CP, Medeiros F, Kindelberger DW, Elvin JA, Garber JE, et al. Primary fallopian tube malignancies in BRCA-positive women undergoing surgery for ovarian cancer risk reduction. *J Clin Oncol.* 2007; **25**(25): 3985-90.
14. Reitsma W, Hollema H, Mourits MJ. Letter Commenting on "Risk-Reducing Salpingo-Oophorectomy (RRSO) in BRCA Mutation Carriers: Experience With a Consecutive Series of 111 Patients Using a Standardized Surgical-Pathological Protocol" in *Int J Gynecol Cancer* 2011;21:846-851 by C. Bethan Powell et al. *Int J Gynecol Cancer.* 2011.
15. Crum CP, Drapkin R, Kindelberger D, Medeiros F, Miron A, Lee Y. Lessons from BRCA: the tubal fimbria emerges as an origin for pelvic serous cancer. *Clin Med Res.* 2007; **5**(1): 35-44.
16. Kim J, Coffey DM, Creighton CJ, Yu Z, Hawkins SM, Matzuk MM. High-grade serous ovarian cancer arises from fallopian tube in a mouse model. *Proc Natl Acad Sci U S A.* 2012; **109**(10): 3921-6.
17. Mourits MJ, de Bock GH. Managing hereditary ovarian cancer. *Maturitas.* 2009; **64**(3): 172-6.
18. The Netherlands Foundation for the Detection of Hereditary Tumours (STOET): Guideline for diagnosis and prevention. Available at:


SUPPORT OF THE 'FALLOPIAN TUBE HYPOTHESIS' IN A PROSPECTIVE SERIES OF RISK-REDUCING SALPINGO-OOPHORECTOMY SPECIMENS

- <http://www.stoet.nl/uploads/richtlijnenboekje.pdf> (viewed on November 1st, 2011).
19. Fakkert IE, Jansen L, Meijer K, Kok T, Oosterwijk JC, Mourits MJ, et al. Breast cancer screening in BRCA1 and BRCA2 mutation carriers after risk reducing salpingo-oophorectomy. *Breast Cancer Res Treat.* 2011; **129**(1): 157-64.
 20. Yanai-Inbar I, Siriaunkgul S, Silverberg SG. Mucosal epithelial proliferation of the fallopian tube: a particular association with ovarian serous tumor of low malignant potential? *Int J Gynecol Pathol.* 1995; **14**(2): 107-13.
 21. Kenkhuis MJ, de Bock GH, Elferink PO, Arts HJ, Oosterwijk JC, Jansen L, et al. Short-term surgical outcome and safety of risk reducing salpingo-oophorectomy in BRCA1/2 mutation carriers. *Maturitas.* 2010; **66**(3): 310-4.
 22. Medeiros F, Muto MG, Lee Y, Elvin JA, Callahan MJ, Feltmate C, et al. The tubal fimbria is a preferred site for early adenocarcinoma in women with familial ovarian cancer syndrome. *Am J Surg Pathol.* 2006; **30**(2): 230-6.
 23. Roh MH, Kindelberger D, Crum CP. Serous tubal intraepithelial carcinoma and the dominant ovarian mass: clues to serous tumor origin? *Am J Surg Pathol.* 2009; **33**(3): 376-83.
 24. Rebbeck TR, Lynch HT, Neuhausen SL, Narod SA, Van't Veer L, Garber JE, et al. Prophylactic oophorectomy in carriers of BRCA1 or BRCA2 mutations. *N Engl J Med.* 2002; **346**(21): 1616-22.
 25. Domchek SM, Friebel TM, Garber JE, Isaacs C, Matloff E, Eeles R, et al. Occult ovarian cancers identified at risk-reducing salpingo-oophorectomy in a prospective cohort of BRCA1/2 mutation carriers. *Breast Cancer Res Treat.* 2010; **124**(1): 195-203.
 26. Powell CB, Kenley E, Chen LM, Crawford B, McLennan J, Zaloudek C, et al. Risk-reducing salpingo-oophorectomy in BRCA mutation carriers: role of serial sectioning in the detection of occult malignancy. *J Clin Oncol.* 2005; **23**(1): 127-32.
 27. Rabban JT, Barnes M, Chen LM, Powell CB, Crawford B, Zaloudek CJ. Ovarian pathology in risk-reducing salpingo-oophorectomies from women with BRCA mutations, emphasizing the differential diagnosis of occult primary and metastatic carcinoma. *Am J Surg Pathol.* 2009; **33**(8): 1125-36.
 28. Hirst JE, Gard GB, McIlroy K, Nevell D, Field M. High rates of occult fallopian tube cancer diagnosed at prophylactic bilateral salpingo-oophorectomy. *Int J Gynecol Cancer.* 2009; **19**(5): 826-9.
 29. Yates MS, Meyer LA, Deavers MT, Daniels MS, Keeler ER, Mok SC, et al. Microscopic and early-stage ovarian cancers in BRCA1/2 mutation carriers: building a model for early BRCA-associated tumorigenesis. *Cancer Prev Res (Phila).* 2011; **4**(3): 463-70.
 30. Carcangiu ML, Peissel B, Pasini B, Spatti G, Radice P, Manoukian S. Incidental carcinomas in prophylactic specimens in BRCA1 and BRCA2 germ-line mutation carriers, with emphasis on fallopian tube lesions: report of 6 cases and review of the literature. *Am J Surg Pathol.* 2006; **30**(10): 1222-30.
 31. Manchanda R, Abdelraheim A, Johnson M, Rosenthal AN, Benjamin E, Brunell C, et al. Outcome of risk-reducing salpingo-oophorectomy in BRCA carriers and women of unknown mutation status. *BJOG.* 2011; **118**(7): 814-24.
 32. Powell CB, Chen LM, McLennan J, Crawford B, Zaloudek C, Rabban JT, et al. Risk-reducing salpingo-oophorectomy (RRSO) in BRCA mutation carriers: experience with a consecutive series of 111 patients using a standardized surgical-pathological protocol. *Int J Gynecol Cancer.* 2011; **21**(5): 846-51.
 33. Colgan TJ, Murphy J, Cole DE, Narod S, Rosen B. Occult carcinoma in prophylactic oophorectomy specimens: prevalence and association with BRCA germline mutation status. *Am J Surg Pathol.* 2001; **25**(10): 1283-9.
 34. Meeuwissen PA, Seynaeve C, Brekelmans CT, Meijers-Heijboer HJ, Klijn JG, Burger CW. Outcome of surveillance and prophylactic salpingo-

CHAPTER 5

- oophorectomy in asymptomatic women at high risk for ovarian cancer. *Gynecol Oncol.* 2005; **97**(2): 476-82.
35. Gomez Garcia EB, Oosterwijk JC, Timmermans M, van Asperen CJ, Hogervorst FB, Hoogerbrugge N, et al. A method to assess the clinical significance of unclassified variants in the BRCA1 and BRCA2 genes based on cancer family history. *Breast Cancer Res.* 2009; **11**(1): R8.
36. Rabban JT, Krasik E, Chen LM, Powell CB, Crawford B, Zaloudek CJ. Multistep level sections to detect occult fallopian tube carcinoma in risk-reducing salpingo-oophorectomies from women with BRCA mutations: implications for defining an optimal specimen dissection protocol. *Am J Surg Pathol.* 2009; **33**(12): 1878-85.
37. Kindelberger DW, Lee Y, Miron A, Hirsch MS, Feltmate C, Medeiros F, et al. Intraepithelial carcinoma of the fimbria and pelvic serous carcinoma: Evidence for a causal relationship. *Am J Surg Pathol.* 2007; **31**(2): 161-9.
38. Rhiem K, Foth D, Wappenschmidt B, Gevensleben H, Buttner R, Ulrich U, et al. Risk-reducing salpingo-oophorectomy in BRCA1 and BRCA2 mutation carriers. *Arch Gynecol Obstet.* 2011; **283**(3): 623-7.
39. Collins IM, Domchek SM, Huntsman DG, Mitchell G. The tubal hypothesis of ovarian cancer: caution needed. *Lancet Oncol.* 2011; **12**(12): 1089-91.
40. Leblanc E, Narducci F, Farre I, Peyrat JP, Taieb S, Adenis C, et al. Radical fimbriectomy: a reasonable temporary risk-reducing surgery for selected women with a germ line mutation of BRCA 1 or 2 genes? Rationale and preliminary development. *Gynecol Oncol.* 2011; **121**(3): 472-6.

SUPPORT OF THE 'FALLOPIAN TUBE HYPOTHESIS' IN A PROSPECTIVE
SERIES OF RISK-REDUCING SALPINGO-OOPHORECTOMY SPECIMENS



Chapter 5.1

LETTER COMMENTING ON "Risk-reducing salpingo-oophorectomy (RRSO) in *BRCA* mutation carriers: experience with a consecutive series of 111 patients using a standardized surgical-pathological protocol" IN INT J GYNECOL CANCER 2011;21:846-851 BY C BETHAN POWELL ET AL

WELMOED REITSMA, HARRY HOLLEMA, MARIAN JE MOURITS

INTERNATIONAL JOURNAL OF GYNECOLOGICAL CANCER 2012 Jan;22(1):2

TO THE EDITOR

With great interest, we read the recent article of Powell et al.¹ on occult malignancy in risk-reducing salpingo-oophorectomy (RRSO) specimens in 111 *BRCA1/2* mutation carriers. The authors describe an overall detection rate of 9.1% (10/111) for occult ovarian/tubal carcinoma in prophylactically removed adnexa in *BRCA1/2* mutation carriers. Table 1 displays the pathological findings in 10 patients with occult carcinoma. Our attention was drawn to one of the patients in Table 1, no. 6. In this patient, an ovarian intraepithelial carcinoma was diagnosed. We would like to comment on this finding and on the detected prevalence of occult malignancy.

In prophylactically removed adnexa in *BRCA1/2* carriers, tubal carcinoma in situ (TCIS) has previously been described and is located in the fimbrial end of the fallopian tube.² Other than atypia and moderate dysplasia, the presence of TCIS is an officially recognized (International Federation of Gynecology and Obstetrics classification) precursor of tubal cancer.³ Furthermore, TCIS has been recognized as a precursor of ovarian and peritoneal cancer.⁴ However, to the best of our knowledge, an ovarian in situ carcinoma has never been reported, until now. Either this case no. 6 would be groundbreaking news in the field of adnexal carcinogenesis, which we doubt, or the diagnosis is incorrect.

Moreover, the reported prevalence of occult malignancy in this retrospective study is remarkably high (9.1%) compared with that in literature (2.2%).⁵ Powell et al. included a "clean" selection of screen-negative (106/111) women with a proven *BRCA1* or *BRCA2* germline mutation and used a surgical-pathological protocol to increase the ability of detecting occult cancer at RRSO. The median ages at time of RRSO were 46 years (range, 32–69 years) for the entire group and 51 years for women with carcinoma found at RRSO, both corresponding to previous studies.^{2–5} However, although the authors report "occult carcinoma," they included both premalignant lesions (n=5) as well as invasive carcinoma (n=5), resulting in a twice as high rate of occult carcinoma as is really present.

In conclusion, we believe that the finding of ovarian intraepithelial carcinoma should not go unnoticed, because it would be the first reported case to date. In addition, we suggest that the authors should only include invasive cancers in the prevalence of occult malignancies.

REFERENCES

1. Powell CB, Chen LM, McLennan J, Crawford B, Zaloudek C, Rabban JT, et al. Risk-reducing salpingo-oophorectomy (RRSO) in BRCA mutation carriers: experience with a consecutive series of 111 patients using a standardized surgical-pathological protocol. *Int J Gynecol Cancer*. 2011; **21**(5): 846-51.
2. Medeiros F, Muto MG, Lee Y, Elvin JA, Callahan MJ, Feltmate C, et al. The tubal fimbria is a preferred site for early adenocarcinoma in women with familial ovarian cancer syndrome. *Am J Surg Pathol*. 2006; **30**(2): 230-6.
3. Mehrad M, Ning G, Chen EY, Mehra KK, Crum CP. A pathologist's road map to benign, precancerous, and malignant intraepithelial proliferations in the fallopian tube. *Adv Anat Pathol*. 2010; **17**(5): 293-302.
4. Przybycin CG, Kurman RJ, Ronnett BM, Shih Ie M, Vang R. Are all pelvic (nonuterine) serous carcinomas of tubal origin? *Am J Surg Pathol*. 2010; **34**(10): 1407-16.
5. Finch A, Beiner M, Lubinski J, Lynch HT, Moller P, Rosen B, et al. Salpingo-oophorectomy and the risk of ovarian, fallopian tube, and peritoneal cancers in women with a BRCA1 or BRCA2 Mutation. *JAMA*. 2006; **296**(2): 185-92.

