

University of Groningen

Refractory Stage M Ganglioneuroblastoma With Bone Metastases and a Favorable, Chronic Course of Disease

Tas, Michelle L.; Molenaar, Jan J.; Peek, Annemarie M. L.; Lequin, Maarten H.; Verdijk, Rob M.; de Krijger, Ronald R.; Tytgat, Godelieve A. M.; van Noesel, Max M.

Published in:
Journal of pediatric hematology oncology

DOI:
[10.1097/MPH.0000000000002067](https://doi.org/10.1097/MPH.0000000000002067)

IMPORTANT NOTE: You are advised to consult the publisher's version (publisher's PDF) if you wish to cite from it. Please check the document version below.

Document Version
Publisher's PDF, also known as Version of record

Publication date:
2022

[Link to publication in University of Groningen/UMCG research database](#)

Citation for published version (APA):

Tas, M. L., Molenaar, J. J., Peek, A. M. L., Lequin, M. H., Verdijk, R. M., de Krijger, R. R., Tytgat, G. A. M., & van Noesel, M. M. (2022). Refractory Stage M Ganglioneuroblastoma With Bone Metastases and a Favorable, Chronic Course of Disease: Description of a Patient Cohort. *Journal of pediatric hematology oncology*, 44(1), E5-E13. <https://doi.org/10.1097/MPH.0000000000002067>

Copyright

Other than for strictly personal use, it is not permitted to download or to forward/distribute the text or part of it without the consent of the author(s) and/or copyright holder(s), unless the work is under an open content license (like Creative Commons).

The publication may also be distributed here under the terms of Article 25fa of the Dutch Copyright Act, indicated by the "Taverne" license. More information can be found on the University of Groningen website: <https://www.rug.nl/library/open-access/self-archiving-pure/taverne-amendment>.

Take-down policy

If you believe that this document breaches copyright please contact us providing details, and we will remove access to the work immediately and investigate your claim.

Downloaded from the University of Groningen/UMCG research database (Pure): <http://www.rug.nl/research/portal>. For technical reasons the number of authors shown on this cover page is limited to 10 maximum.

Refractory Stage M Ganglioneuroblastoma With Bone Metastases and a Favorable, Chronic Course of Disease: Description of a Patient Cohort

Michelle L. Tas, MD,* Jan J. Molenaar, MD, PhD,*
Annemarie M.L. Peek, MD,*† Maarten H. Lequin, MD, PhD,*‡
Rob M. Verdijk, MD, PhD,§ Ronald R. de Krijger, MD, PhD,||¶
Godelieve A.M. Tytgat, MD, PhD,* and Max M. van Noesel, MD, PhD*

Summary: Refractory stage M neuroblastoma (NB) is associated with a poor prognosis and a progressive course of disease. Here, we describe a unique group of patients with a discrepant clinical course. Seven histologically confirmed ganglioneuroblastoma (GNB) (n=6) and differentiating NB (n=1) patients were identified who were diagnosed with stage M disease based on iodine-123-metaiodobenzylguanidine avid bone metastases. Six patients started on high-risk treatment, without tumor response (stable disease). Treatment was discontinued before the start of consolidation treatment because of refractory response in all patients. Unexpectedly, after cessation of treatment no progression of disease occurred. In 2 patients, the primary tumors expanded (>25%) very slowly during 1.5 and 3 years, and remained stable thereafter. Metabolically, a slow decrease of urinary homovanillic acid and vanillylmandelic acid levels and iodine-123-metaiodobenzylguanidine avidity was observed. All patients are alive with presence of metastatic disease after a median follow-up of 17 years (range: 6.7 to 27 y). Interestingly, at diagnosis, 6 patients were asymptomatic, 6 patients had GNB morphology, and 5 patients had meningeal metastases. These are all features seen in only a small minority of stage M patients. This GNB entity illustrates the clinical heterogeneity of neuroblastic tumors and can be used to further study the developmental origin of different NB subtypes.

Key Words: neuroblastoma, ganglioneuroblastoma, meningeal, metastasis, prognosis, refractory

(*J Pediatr Hematol Oncol* 2022;44:e5–e13)

Received for publication November 8, 2020; accepted December 13, 2020.

From the Departments of *Solid Tumors; †Diagnostics and Pathology, Princess Máxima Center for Pediatric Oncology; Departments of ‡Radiology and Nuclear Medicine; ¶Pathology, University Medical Center Utrecht, Utrecht; †Department of Pediatric Oncology, Beatrix Children's Hospital, University Medical Center Groningen, Groningen; and §Department of Pathology, Section Neuro-pathology, Erasmus University Medical Center Rotterdam, Rotterdam, The Netherlands.

G.A.M.T. and M.M.v.N. shared last authorship.

This project was funded by the Villa Joep Foundation.

The authors declare no conflict of interest.

Reprints: Michelle L. Tas, MD, Princess Máxima Center for Pediatric Oncology, Heidelberglaan 25, Utrecht 3584 CS, the Netherlands (e-mail: m.tas@prinsesmaximacentrum.nl).

Supplemental Digital Content is available for this article. Direct URL citations appear in the printed text and are provided in the HTML and PDF versions of this article on the journal's website, www.jpheonline.com.

Copyright © 2021 The Author(s). Published by Wolters Kluwer Health, Inc. This is an open access article distributed under the terms of the Creative Commons Attribution-Non Commercial-No Derivatives License 4.0 (CCBY-NC-ND), where it is permissible to download and share the work provided it is properly cited. The work cannot be changed in any way or used commercially without permission from the journal.

Neuroblastoma (NB) is a pediatric malignancy with a variable clinical course. Even in metastatic disease, patient groups with good to dismal prognosis can be recognized based on histopathology, age, dissemination pattern, and genetic aberrations (eg, amplification of the *MYCN* oncogene).¹ High-risk tumors are characterized by stage M and age at diagnosis older than 18 months, or by amplification of *MYCN*.¹ Despite intensive multimodality treatment, the clinical course is unfavorable, with 5-year overall survival (OS) estimated around 50%.^{1,2} A rare phenotype of metastatic disease is the low-risk, stage MS (metastatic special) tumor, with the potential of spontaneous regression after limited or no treatment, and a 5-year event free survival of >85%.^{1,3} By definition stage MS is diagnosed in patients younger than 18 months old, with metastases limited to liver, skin and bone marrow (<10% infiltration), and lacking bone metastases.

Response to induction treatment is an important prognostic factor for patients with stage M NB. Patients who reach complete response or very good partial response at the end of induction have a better outcome than patients with a partial response or less (no response, mixed response, or progression).⁴ Patients with refractory disease to chemotherapeutic induction are considered ultra-high-risk patients.⁵ A retrospective study estimated the median time to progression of refractory patients at 23.5 months and the median OS at 30.3 months. The 5-year event free survival and OS were estimated at 0%.⁵

Here, we describe a cohort of patients with refractory stage M ganglioneuroblastoma (GNB) (n=6) and differentiating NB (n=1) with an unexpected chronic clinical course and excellent long-term outcome. From this cohort, we identified patient characteristics for future early clinical detection. In addition, we discuss the heterogeneous course of metastatic neuroblastic tumors from a cell-of-origin perspective.

PATIENTS AND METHODS

Patients

The clinical courses of disease of patient 1 and 2 were exceptional and based on these index patients we reviewed all Dutch patients diagnosed with a stage 4 [International Neuroblastoma Staging System (INSS) staging] or M [International Neuroblastoma Risk Group (INRG) staging] GNB and NB between 1990 and 2014. The criteria for retrospective inclusion in this cohort were (1) the presence of GNB or NB stage M disease, (2) refractory disease under treatment or stable disease without treatment, and (3) survival of at least 5 years. The following data were collected from the original medical records: symptoms at diagnosis, response to treatment, histologic, radiologic, nuclear

imaging [¹²³I-MIBG (metaiodobenzylguanidine) scans] and biochemical (urinary catecholamine excretion) characteristics. Patients were classified using the INRG staging system.¹

Metabolic and Radiologic Response

Urinary catecholamine excretion [homovanillic acid (HVA), vanillylmandelic acid (VMA), dopamine, epinephrine, norepinephrine, metanephrine, normetanephrine and 3-methoxytyramine (3MT)] were reported as fold change of the upper limit for age (defined as mean +2 SD) as described previously.⁶ Ultrasound, computed tomography (CT), and magnetic resonance imaging (MRI) scan reports, as well as ¹²³I-MIBG single photon emission computed tomography (SPECT) whole body/CT scan reports were reviewed retrospectively. Response to treatment at last follow-up was determined using the 2017 revision of the International Neuroblastoma Response Criteria.⁷

Pathology and Shallow Whole Genome Sequencing

All available tumor material was reviewed by an expert pediatric pathologist (R.v.D.). DNA was isolated from formalin-fixed paraffin-embedded archived pathology material of the primary tumors or lymph node metastases. Areas

with highest tumor cell percentage were selected for DNA isolation. Shallow whole genome sequencing was performed as described previously.⁸ Whole genome sequencing was performed in 2 tumors as described previously.⁹ (Shallow) whole genome sequencing was visualized in the R2: Genomics Analysis and Visualization Platform (<https://r2.amc.nl>). *MYCN* amplification status was determined by fluorescent in situ hybridization (FISH) or Southern blot.

RESULTS

Patient Characteristics and Outcome

Between 1990 and 2014, 306 patients with stage M GNB or NB were diagnosed.¹⁰ Seven patients were identified who met the inclusion criteria. The median age at diagnosis was 18 months (range: 5 to 47 mo). Dissemination was observed in bone (n = 7), bone marrow (n = 4), meninges (n = 5), lymph nodes (n = 4), liver (n = 1), skin (n = 1), pleura (n = 1), muscle (n = 1), and ovary (n = 1) (Table 1). Six patients had GNB morphology, 1 patient had differentiating NB morphology. At presentation, 6 patients were asymptomatic, 1 patient (#2) had a persistent fever without focus. Six patients were

TABLE 1. Patient Characteristics and Tumor Response

Patient Number	1	2	3	4	5	6	7
Diagnosis							
Age at Dx (mo)	26	14	11	5	18	47	18
Presenting symptoms	Cervical mass	Persistent fever	Raccoon eyes	Skin nodules	Swelling above the eye	Swelling frontal bone and above the eye	Abdominal mass
Primary tumor	Thorax	Adrenal left	Organ of Zuckerkandl	Adrenal bilateral	Adrenal right	Adrenal left	Thorax
Metastases	Bone, BM, LN, pleura	Bone, meninges, LN	Bone, BM	Bone, meninges, LN, liver, skin, ovary	Bone, meninges	Bone, meninges, muscle, LN	Bone, BM, meninges
Histology	GNBn	GNB NOS	GNB NOS	GNBi	GNBi	GNBi	NB diff.
DNA copy number	NA	NA	NCA and SCA	NCA	NCA	ND	ND
MNA	Neg	Neg	Neg	Neg	Neg	ND	Neg
Response							
Treatment	CT, MIBG	CT, MIBG, S, RA	CT, S	CT, S	CT, S	S	CT, MIBG, S
Urinary catecholamines							
HVA normalized	Yes	Yes	No	Yes	No	No	No
VMA normalized	Yes	Yes	Yes	Yes	Yes	Yes	Yes
INRC	PD	MR	PD	MR	PR	MR	MR
Primary tumor response	PD	CR	PD	PR	CR	CR	PR
Tumor Response at Metastatic Sites	PD	SD	PD	CR	PR	SD	SD
BM metastases response	SD	CR	CR	SD	CR	CR	CR
Follow-up (y)	16.9	20.1	26.8	24.2	10.2	11.7	6.7

BM indicates bone marrow; CR, complete response; CT, chemotherapy; diff., differentiating; Dx, diagnosis; GNB, ganglioneuroblastoma; i, intermixed; INRC, international neuroblastoma response criteria; LN, lymph nodes; MIBG, ¹²³I-MIBG treatment; MNA, MYCN amplification; mo, months; MR, minimal response; n, nodular; NA, not available; NB, neuroblastoma; NCA, numerical chromosomal aberrations; ND, not done; Neg, negative; NOS, not otherwise specified; PD, progressive disease; PR, partial response; RA, retinoic acid; S, surgery; SCA, structural chromosomal aberrations; SD, stable disease.

regarded as high-risk patients and 5 were initially treated according to high-risk protocols (Supplemental Table S1, Supplemental Digital Content 1, <http://links.lww.com/JPHO/A451>).^{11–15} For patient #2 (below) initial high-risk treatment was not available in her native country, but started in the Netherlands, after disease progression. Patient #6 was never treated with systemic therapy. At diagnosis, clinical history revealed indications of presence of the metastatic indolent NB for 2 years. In all 6 treated patients, high-risk treatment was discontinued before the start of consolidation because of refractory disease status and at the time limited alternative treatment available. After cessation of treatment, disease progression with fatal outcome was expected, but stable disease was observed. In the current INRG risk classification, patient #2, 3, and 4 would have been classified as intermediate risk, because of an age younger than 18 months, the other 4 patients would still classify as highrisk. After induction treatment, all patients had a refractory response. In current times they would subsequently continue treatment according to the VERITAS (NCT03165292), BEACON trial (NCT02308527) or equivalent trials. All patients are alive and well after a median follow-up of 17 years (range: 6.7 to 27 y). In the complete cohort of 306 stage M patients, the 5-year OS was 35 ± 3%. For patients with GNB morphology (n = 16) 5-year OS was 69 ± 12%, compared with 33 ± 3% for NB morphology (n = 287). Study patient characteristics are

summarized in Table 1 and the clinical course of 2 index patients is described in more detail below.

Patient 1

A 2-year-old male presented with a right-sided cervical lymph node mass. Chest radiograph, ¹²³I-MIBG and CT scans revealed a large thoracic neuroblastic tumor (Figs. 1A, B), multiple involved cervical lymph nodes, a pleural lesion, and multiple skeletal metastases. Urinary excretion of HVA, dopamine and 3MT was elevated, VMA excretion was normal (Supplemental Figure S1, Supplemental Digital Content 2, <http://links.lww.com/JPHO/A452>). Histology was defined as GNB nodular (GNBn), without *MYCN* amplification (Figs. 1C, D). High-risk treatment (Supplemental Table S1, Supplemental Digital Content 1, <http://links.lww.com/JPHO/A451>) was initiated, but no response was observed. On second-line chemotherapy, the disease remained stable and treatment was discontinued. During the first 2 years after diagnosis the primary tumor expanded slowly (> 25%), and remained stable over the following 15 years. A new ¹²³I-MIBG avid bone lesion was observed 1.5 years after diagnosis, but subsequently ¹²³I-MIBG avidity gradually decreased for all lesions, without reaching complete remission (Fig. 1A). Urinary HVA, dopamine and 3MT excretion slowly decreased and normalized 7, 10, and 7 years after diagnosis, respectively (Supplemental Figure S1, Supplemental Digital Content 2, <http://links.lww.com/JPHO/A452>).

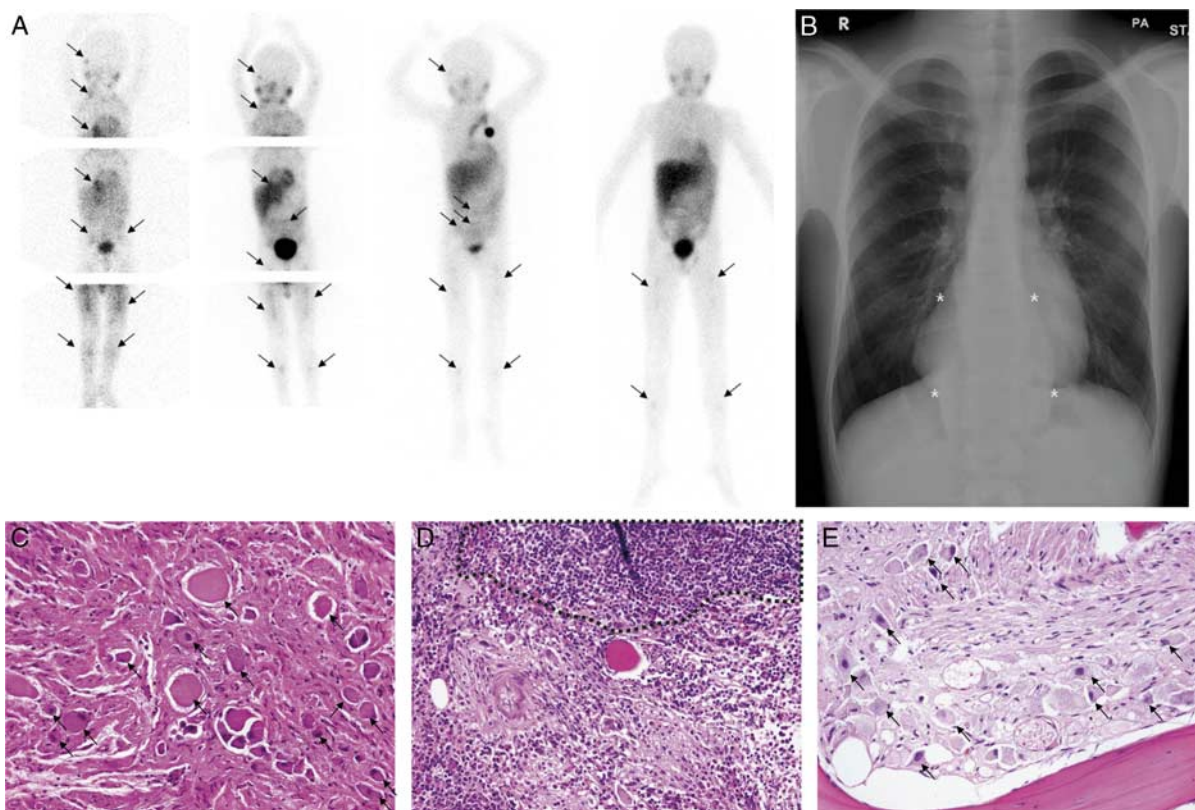


FIGURE 1. Imaging and pathologic follow-up of patient 1. A, ¹²³I-MIBG scans of patient 1 made 0, 1, 4, and 6 years after diagnosis. Pathologic uptake is marked by arrows. B, Chest radiograph made 17 years after diagnosis showing the large thoracic primary tumor, marked by 4 asterisks. C–E, Hematoxylin-Eosin staining of (C) the primary tumor at diagnosis showing large ganglion cells (arrows) with mature stroma, classified as ganglioneuroblastoma nodular subtype (without a nodule in this sample). D, Bone marrow at diagnosis show infiltration of neuroblasts (within dashed line) in a background of fibrotic bone marrow and (E) bone marrow at latest follow-up, 2 years after diagnosis, showing large ganglion cells (arrows) with mature Schwannian stroma. ¹²³I-MIBG indicates iodine-123-metaiodobenzylguanidine.

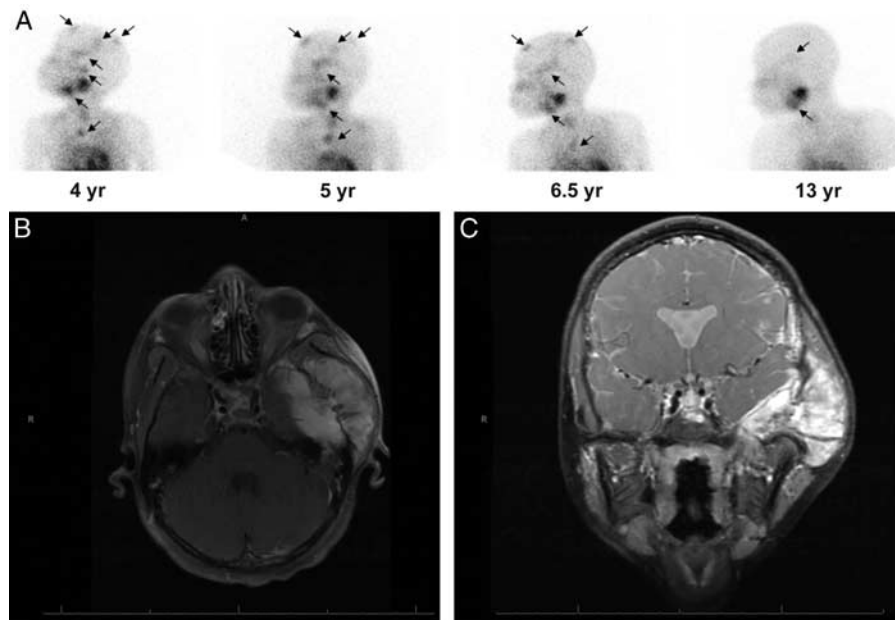


FIGURE 2. Imaging follow-up of patient 2. A, ^{123}I -MIBG scans of patient 2, performed 4, 5, 6.5, and 13 years after diagnosis. Pathologic uptake is marked by arrows. At the last ^{123}I -MIBG scan there was still pathologic uptake at the left temporal bone, right parietal bone, and both femora. Suspected uptake was seen at the right mandibular angle and at a rib. B and C, T1 (2B) and T2 (2C) weighted MRI with gadolinium contrast showing a large metastasis in the left temporal bone, 11.5 years after diagnosis. ^{123}I -MIBG indicates iodine-123-metaiodobenzylguanidine; MRI, magnetic resonance imaging.

Patient 2

A 1-year-old female was diagnosed with a metastatic neuroblastic tumor in the Democratic Republic of the Congo, and the primary adrenal tumor was resected. Three years later she immigrated to the Netherlands, with ^{123}I -MIBG avid metastases in bone, meninges, and lymph nodes (Fig. 2A). Biopsy of bone marrow and a lymph node revealed GNB, without *MYCN* amplification or loss of heterozygosity of chromosome 1p. During a year of follow-up the mass of the zygomatic bone and an asymptomatic meningeal mass at the level of C5-C7 progressed. This metastasis was exclusively located in the meninges and not intraspinal extension of a prevertebral tumor. She was subsequently treated with 4 courses of chemotherapy, 2 courses of ^{131}I -MIBG therapy, and 6 months of isotretinoin (Supplemental Table S1, Supplemental Digital Content 1, <http://links.lww.com/JPHO/A451>), without response to any of the treatment modalities. In the following 10 years, the meningeal metastasis remained stable. However, the zygomatic bone metastasis slowly expanded (Figs. 2B, C). ^{123}I -MIBG avidity slowly decreased (Fig. 2A). The patient developed a chondrosarcoma of the left distal fibula, which was completely resected and she is alive and well after a follow-up time of 23 years (4.3 y for the chondrosarcoma).

Meningeal Metastases

An unexpected number of rare metastatic sites was observed, including meningeal metastases in 5 patients, a muscle, a pleural and an ovarian metastasis. These metastases were diagnosed on MRI scans, none of these metastases have been histologically proven, but were radiologically suspect for meningeal involvement. These metastases are normally detected in <1% of patients.¹⁶ In addition to the meningeal metastases, all 7 patients had metastases in the facial bones, causing facial deformation in

patient #2 (Figs. 2B, C) and #5. In patient #2, the meningeal metastasis slowly expanded ~4 years after diagnosis, and remained stable thereafter (see above). In patient #4, a tentorial meningeal metastasis expanded during 4 months of treatment, and was detected as a cystic lesion with calcifications on MRI, 13 months after diagnosis. Her other meningeal metastases slowly regressed over the course of 5.5 years. In patient #5, the meningeal metastases showed

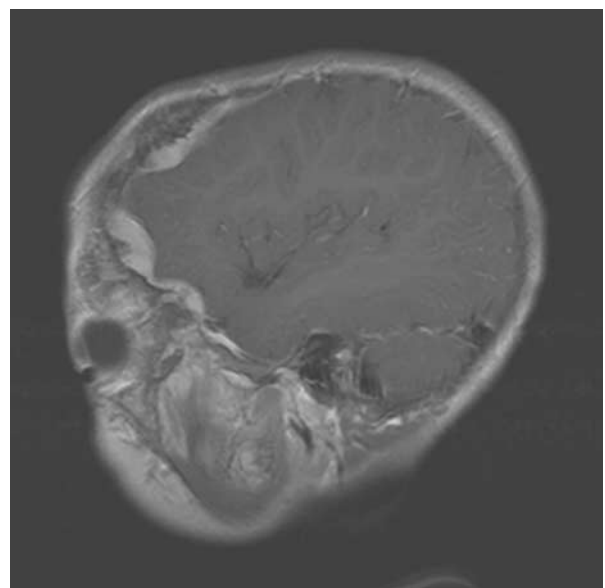


FIGURE 3. Meningeal metastases of patient 6. Sagittal T1 weighted MRI of patient 6 at diagnosis, showing meningeal and bone metastases. MRI indicates magnetic resonance imaging.

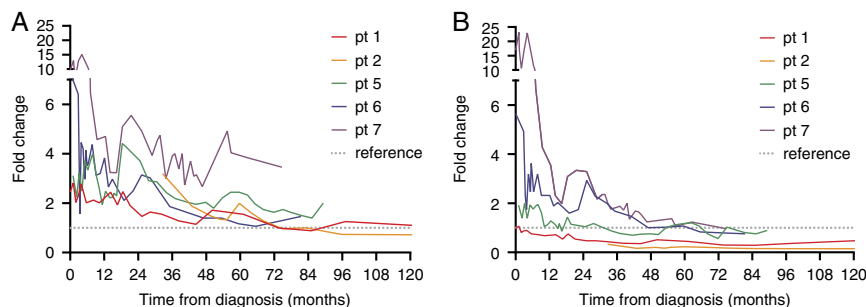


FIGURE 4. Fold change of homovanillic acid and vanillylmandelic acid over time. Homovanillic acid (A) and vanillylmandelic acid (B) per patient as fold change of age-related upper limit. On the x-axis, time from diagnosis is given.

very slow progression in the first 3.5 years after diagnosis and remained stable during the following 5 years. In patient #6, the meningeal metastases (Fig. 3) were not followed by imaging.

Histopathology and Genomic Patterns

The tumors were classified as differentiating NB (n = 1) and GNB (n = 6). In cohorts where histology is classified by the Shimada criteria, 13% of stage M are reported to be GNB.¹⁷ In the Dutch stage M cohort (n = 306) diagnosed between 1990 and 2014, only 16 patients (5%) were diagnosed with GNB morphology. Seven of these 16 patients are included in this study. This affects the difference in outcome between NB and GNB patient, of 69 ± 12%, compared with 33 ± 3% for NB morphology (n = 287). Of the GNBs, 3 were classified as the favorable GNB_i, 1 as unfavorable GNB_n, and 2 tumors could not be further classified. Differentiation towards ganglioneuroma (GN) was observed in patient #4: a tumor nodule resected 6 years after diagnosis revealed GN. Trepine biopsies remained positive in 2 patients (#1 and #4), with the most recent biopsy of patient #1 showing ganglion cells with mature stroma and no undifferentiated neuroblasts (Fig. 1E).

Genetically, no amplification of *MYCN* was detected in 6 tested tumors, for 1 patient no result was available. Loss of heterozygosity of chromosome 1p36 was determined in 4 patients, and absent in all. (Shallow) whole genome sequencing was performed on tumor formalin-fixed paraffin-embedded material of 5 patients. Two patients (#4 and 5) had a favorable profile with only numerical chromosomal aberrations, 1 patient (#3) had an unfavorable profile with both numerical and segmental chromosomal aberrations. In 2 patients (#1 and 2), no conclusions could be drawn, because of low tumor content. (Supplemental Figure S1, Supplemental Digital Content 2, <http://links.lww.com/JPHO/A452>).

Clinical Course and Long-term Follow-up

The clinical course was typical with main characteristics being chemotherapy insensitivity and long-term survival with stable disease. During long-term follow-up, the primary tumors of patients #1 and #3 expanded slowly (>25%). Patient #1 developed a new ¹²³I-MIBG avid metastasis 1.5 years after diagnosis, patient #3 developed new ¹²³I-MIBG avid lesions after 1, 3, and 5 years. Despite these new lesions, the long-term follow-up of all patients was characterized by a very slow decrease in ¹²³I-MIBG avidity (Figs 1A, 2A). Normalization of ¹²³I-MIBG uptake was seen in only 1 patient (#4), after resection of a remaining ¹²³I-MIBG avid skin lesion. Urinary excretion of the catecholamines HVA and VMA tended to decrease to (near)

normal levels over time (Fig. 4). HVA remained elevated in 4 patients after a follow-up of 6-14 years while VMA normalized in all patients after a median of 2.8 years (range: 0 to 6.2 y) (Table 1, Fig. 4). Dopamine and 3MT levels were measured in 2 patients (#1 and #7). Dopamine normalized 10 years after diagnosis in patient #1, in patient #7 it remained 3× elevated at last follow-up, 6.2 years after diagnosis. 3MT levels normalized after 7 years in patient #1, and remained 3× elevated at last follow-up of patient #7.

DISCUSSION

We present a cohort of patients with stage M GNB (n = 6) and differentiating NB (n = 1) with an unexpected chronic course of disease and an excellent outcome. The patients showed refractory disease after induction chemotherapy, but all remained alive with metastatic disease after a median follow-up of 17 years. The available histologic samples and metabolic changes strongly suggest that these tumors differentiated from NB to GNB and GN, without signs of regression.

GNB morphology was seen in 6 of 7 patients. GNBs are considered the more differentiated subgroup of NB. Nonetheless, morphology does not influence risk stratification of metastatic tumors.¹ GNBs can be further subclassified in the favorable GNB intermixed (GNB_i) and the unfavorable GNB nodular (GNB_n).¹⁷ In localized cases, GNB_i has a similar clinical course to GN.¹⁸⁻²¹ Metastatic GNB is almost exclusively classified as GNB_n, which has a similar clinical course to NB.²² In the literature, metastatic GNB_i was diagnosed in only 5 patients in four larger cohorts with a total of 443 GN/GNB_i patients, all 5 survived.¹⁸⁻²¹ In our cohort, 3 patients were diagnosed with metastatic GNB_i and 1 patient with metastatic GNB_n. In 2 patients differentiation to GN was observed, as has been described in a patient, similar to this cohort, but without bone metastases, who did not receive systemic treatment.²³

We identified 16 cases in literature, who match the description of a chronic stage M NB, GNB or GN with bone metastases as described in this paper (Table 2).²⁴⁻³⁵ As we observed differentiation to GN in patient #1 and 4, we included also patients with GN in this literature overview. We believe that these fall within the spectrum of this cohort, but are diagnosed after full differentiation of the neuroblastic tumor. In line with our patients, chemotherapy, given in 5/16 described patients, did not result in objective responses. Two patients developed new metastases over time, and 5 patients suffered expansive growth of tumors. None of these patients died of the (G)NB/GN. These and our data suggest a difference in clinical behavior compared

TABLE 2. Literature Cases

Sex	Age at Diagnosis	Morphology	Primary Tumor	Metastases at Diagnosis	Treatment	Response to Treatment	Clinical Course	Outcome	FU	References
NR	0 mo	NR	Unknown	Bone, orbit, skin	CT	No	SD	AWD	11 y	Hayes et al ²⁴
NR	1 mo	NB	Adrenal gland	Liver, skin, lung, LNs	CT, RT, BCG vaccine, injected irradiated tumor cells	No	New bone metastases after 8 mo, expansive growth during 4 y, 10 y SD, 2 new skin lesions after 14 y	AWD	15 y	Hayes et al ²⁴
f	4 mo	GN	Adrenal gland	Long bones, pelvic bones, vertebrae, LNs	S	NA	SD	AWD	2 y	Garvin et al ²⁵
m	6 mo	NB	Adrenal gland	Skull bones, vertebrae, LNs	RT	NA	SD, regression skull mets	DOC	21 y	Visfeldt ²⁶
f	9 mo	undiff NB	Abdominal	BM and mandible	CT	No	SD	AWD	15 y	Bhattacharyya et al ²⁷
f	2 y	GNB	Thoracic	Lung, multiple vertebrae and ribs	RT	NA	SD	DOC	6 y	Kissane and Ackerman ²⁸
m	3 y	NB	Abdominal	Os frontale, vertebrae, acetabulum, LNs	Vit. B12	NA	New bone mets	AWD	5 y	Goldman et al ²⁹
NR	3 y	GNB	Thoracic	Facial bones, vertebrae	No	NA	SD	AWD	6.5 y	Hayes et al ²⁴
NR	3 y	GN	Abdominal	Multiple bones, orbit, maxilla	CT, RT	No	Periods of growth during 7 y	DOC	8 y	Hayes et al ²⁴
m	3 y	GN?	Adrenal gland	Multiple bone metastases in skull and large bones	S, CT, RT	NR	Slow expansive growth	AWD	11 y	Mitcherling et al ³⁰
NR	4 y	NR	Abdominal	Facial bones, skull, vertebrae, pelvic bones, humerus	No	NA	Expansion skull lesions first two years of FU	AWD	23 y	Hayes et al ²⁴
f	12 y	GNB	Adrenal gland	Mandible, femurs	S	NA	SD	AWD	4 y	Patterson et al ³¹
f	15 y	GN	Unknown	Mandible	S	NA	SD	AWD	18 y	Chou and Hansen ³²
f	17 y	GN	Adrenal gland	long bones, ribs, vertebrae	No	NA	Short FU	AWD	2 mo	Mithofer et al ³³
m	21 y	GN	Unknown	Mandible	No	NA	Slow expansive growth	AWD	35 y	Oeppen et al ³⁴
f	82 y	GN	Unknown	Mandible, meningeal?	S	NA	SD/very slow progression	DOC	2 y	Hustin and Delire ³⁵

AWD indicates alive with disease; BCG, Bacillus Calmette-Guérin; BM, bone marrow; CT, chemotherapy; DOC, died of other causes; f, female; FU, follow-up; GN, ganglioneuroma; GNB, ganglioneuroblastoma; LNs, lymph nodes; m, male; mets, metastases; mo, months; NA, not applicable; NB, neuroblastoma; NR, not reported; RT, radiotherapy; S, surgery; SD, stable disease; undiff, undifferentiated; vit, vitamin.

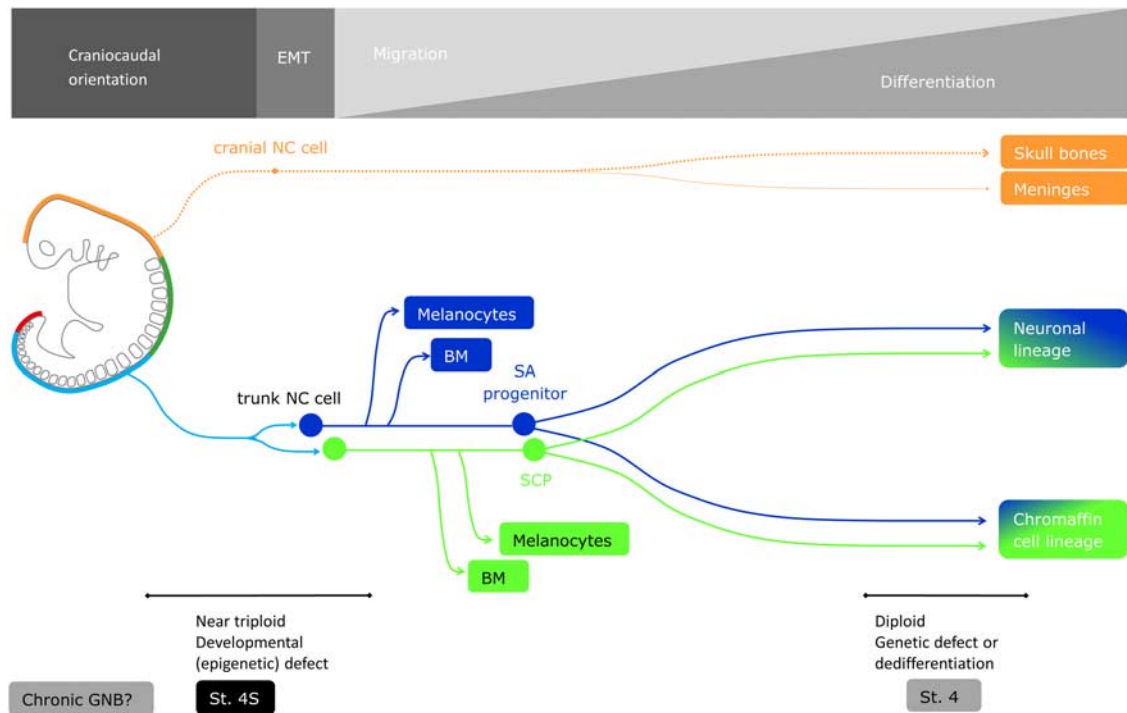


FIGURE 5. Metastatic neuroblastoma stages related to the embryonic development of neural crest (NC) cells. The upper bar indicates the relative role of craniocaudal orientation, epithelial to mesenchymal transition (EMT), migration and differentiation of the NC cells during embryonic development. In the center, the development of the cranial (orange) and trunk (light blue) NC cells is presented as a time line. In dark blue, the sympathoadrenal (SA) progenitor as a precursor cells is depicted. In green, the Schwann cell precursor (SCP). In the boxes below the graph, the origin of the different tumor entities are postulated. BM indicates bone marrow; GNB, ganglioneuroblastoma.

with true NB, although most high-risk treatment protocols will include GNB histology patients.

OS of Dutch stage M GNB patients was $69 \pm 12\%$ ($n = 16$), compared with $33 \pm 3\%$ for NB patients ($n = 287$). This challenges the current risk stratification, which does not take morphology into account for metastatic tumor patients. In addition, a recent publication by Tao and colleagues, suggest a different treatment strategy for GN than for NB. In their study GNs showed to be dependent on the AKT pathway and subsequently sensitive to mTOR inhibitors, while NBs are dependent on the well-defined adrenergic core regulatory circuit of PHOX2B, PHOX2a, TFAP2B, GATA3, and ISL1.³⁶ It could be discussed if the chemotherapy insensitivity of the tumors in this cohort is caused by being less dependent to the adrenergic core regulatory circuit and more dependent on the AKT pathway. For future patients, treatment with a mTOR inhibitor could be considered.

Of interest is the presence of suspected meningeal metastases in 5/7 patients in this cohort. Meningeal metastases are exceptionally rare in primary diagnosis and occur more often at relapse.^{16,37-39} In most studies, central nervous system (CNS) metastases (parenchymal and meningeal) are grouped together as ‘CNS metastases.’ The 5-year OS of NB patients with CNS metastases at diagnosis is 35%, little is known on the long-term outcome. The 5-year OS of patients with a CNS relapse is $< 5\%$.³⁷⁻³⁹ Since the outcome of patients with CNS disease is generally poor, the finding of suspected meningeal metastases in 5/7 patients is puzzling and unexplained. The high incidence and good outcome in the presented cohort

raises the question of this being a biologically different subgroup of metastatic disease. In addition, all patients in this cohort and at least 12/16 of the literature cases had metastases in the facial bones. Orbital metastases occur in around 25% of metastatic NB cases and is associated with decreased 5-year OS in patients > 18 months at diagnosis. Metastases to other facial bones are less common.⁴⁰ Both the facial bones and frontal meninges are of cranial neural crest (NC) origin.^{41,42} The origin of the spinal meninges remains elusive, but histology of human embryos suggests a NC origin for the pia mater, and a somitic mesoderm origin for the dura mater.⁴³

In general, NB tumors arise from trunk NC cells. During NC development, the trunk NC cells form the sympathoadrenal progenitor and Schwann cell precursor, subsequently these cells form the chromaffin cells in the adrenal medulla and neurons in sympathetic ganglia (Fig. 5).^{44,45}

Previously we hypothesized that stage MS tumors appear to be derived from very early (pre)migrating NC cells and should be considered a multifocal developmental disease rather than a true metastatic cancer.⁴⁶ In the patients presented here with meningeal involvement, a similar question could be raised. The meningeal tumor spread could be interpreted as the result of a very early genetic hit, before separation of the cranial and trunk NC (Fig. 5). Alternatively, the meningeal and facial sites could also be the result of metastases homing to NC tissues. The role of the NC development in NB-genesis remains elusive, but the cell-of-origin of the developing NC may define the variable clinical courses.

In hindsight it could be concluded that a wait-and-see policy was indicated in these patients. Antitumor treatment was not effective and the outcome was favorable. Recognition of this entity can help in making treatment decisions and providing information to parents and patients about the clinical course that can be expected. Recognition of the entity can be based on asymptomatic disease at diagnosis, a more mature morphology (GNB or differentiating NB), with meningeal and (facial) bone metastases and poor or absent chemotherapy response. In case of chemotherapy unresponsiveness, consecutive tumor sampling is advised to determine if the tumor has differentiated, treatment with a mTOR inhibitor could be considered or treatment could be stopped, to prevent from overtreatment.

ACKNOWLEDGMENTS

The authors thank Bauke Ylstra and Jan Koster for performing the shallow whole genome sequencing and data analysis.

REFERENCES

- Cohn SL, Pearson AD, London WB, et al. The International Neuroblastoma Risk Group (INRG) classification system: an INRG Task Force report. *J Clin Oncol*. 2009;27:289–297.
- Pinto NR, Applebaum MA, Volchenboum SL, et al. Advances in risk classification and treatment strategies for neuroblastoma. *J Clin Oncol*. 2015;33:3008–3017.
- Tas ML, Nagtegaal M, Kraal K, et al. Neuroblastoma stage 4S: tumor regression rate and risk factors of progressive disease. *Pediatr Blood Cancer*. 2020;67:e28061.
- Simon T, Hero B, Faldum A, et al. Long term outcome of high-risk neuroblastoma patients after immunotherapy with antibody ch14.18 or oral metronomic chemotherapy. *BMC Cancer*. 2011;11:21–28.
- Schrey D, Vaidya SJ, Levine D, et al. Additional therapies to improve metastatic response to induction therapy in children with high-risk neuroblastoma. *J Pediatr Hematol Oncol*. 2015;37:e150–e153.
- Abeling NG, van Gennip AH, Overmars H, et al. Simultaneous determination of catecholamines and metanephrines in urine by HPLC with fluorometric detection. *Clin Chim Acta*. 1984;137:211–226.
- Park JR, Bagatell R, Cohn SL, et al. Revisions to the International Neuroblastoma Response Criteria: a Consensus Statement From the National Cancer Institute Clinical Trials Planning Meeting. *J Clin Oncol*. 2017;35:2580–2587.
- Smeets SJ, Harjes U, van Wieringen WN, et al. To DNA or not to DNA? That is the question, when it comes to molecular subtyping for the clinic!. *Clin Cancer Res*. 2011;17:4959–4964.
- Elefeld TF, Oldridge DA, Bernard V, et al. Relapsed neuroblastomas show frequent RAS-MAPK pathway mutations. *Nat Genet*. 2015;47:864–871.
- Tas ML, Reedijk AMJ, Karim-Kos HE, et al. Neuroblastoma between 1990 and 2014 in the Netherlands: increased incidence and improved survival of high-risk neuroblastoma. *Eur J Cancer*. 2020;124:47–55.
- de Kraker J, Hoefnagel KA, Verschuur AC, et al. Iodine-131-metaiodobenzylguanidine as initial induction therapy in stage 4 neuroblastoma patients over 1 year of age. *Eur J Cancer*. 2008;44:551–556.
- Pearson AD, Pinkerton CR, Lewis IJ, et al. High-dose rapid and standard induction chemotherapy for patients aged over 1 year with stage 4 neuroblastoma: a randomised trial. *Lancet Oncol*. 2008;9:247–256.
- Bernard JL, Philip T, Zucker JM, et al. Sequential cisplatin/VM-26 and vincristine/cyclophosphamide/doxorubicin in metastatic neuroblastoma: an effective alternating non-cross-resistant regimen? *J Clin Oncol*. 1987;5:1952–1959.
- McWilliams NB, Hayes FA, Green AA, et al. Cyclophosphamide/doxorubicin vs. cisplatin/teniposide in the treatment of children older than 12 months of age with disseminated neuroblastoma: a Pediatric Oncology Group Randomized Phase II study. *Med Pediatr Oncol*. 1995;24:176–180.
- Granger M, Grupp SA, Kletzel M, et al. Feasibility of a tandem autologous peripheral blood stem cell transplant regimen for high risk neuroblastoma in a cooperative group setting: a Pediatric Oncology Group study: a report from the Children's Oncology Group. *Pediatr Blood Cancer*. 2012;59:902–907.
- DuBois SG, Kalika Y, Lukens JN, et al. Metastatic sites in stage IV and IVS neuroblastoma correlate with age, tumor biology, and survival. *J Pediatr Hematol Oncol*. 1999;21:181–189.
- Shimada H, Umehara S, Monobe Y, et al. International neuroblastoma pathology classification for prognostic evaluation of patients with peripheral neuroblastic tumors: a report from the Children's Cancer Group. *Cancer*. 2001;92:2451–2461.
- He WG, Yan Y, Tang W, et al. Clinical and biological features of neuroblastic tumors: a comparison of neuroblastoma and ganglioneuroblastoma. *Oncotarget*. 2017;8:37730–37739.
- Decarolis B, Simon T, Krug B, et al. Treatment and outcome of ganglioneuroma and ganglioneuroblastoma intermixed. *BMC Cancer*. 2016;16:542–553.
- De Bernardi B, Gambini C, Haupt R, et al. Retrospective study of childhood ganglioneuroma. *J Clin Oncol*. 2008;26:1710–1716.
- Geoerger B, Hero B, Harms D, et al. Metabolic activity and clinical features of primary ganglioneuromas. *Cancer*. 2001;91:1905–1913.
- Okamatsu C, London WB, Naranjo A, et al. Clinicopathological characteristics of ganglioneuroma and ganglioneuroblastoma: a report from the CCG and COG. *Pediatr Blood Cancer*. 2009;53:563–569.
- Rozmus J, Langer M, Murphy JJ, et al. Multiple persistent ganglioneuromas likely arising from the spontaneous maturation of metastatic neuroblastoma. *J Pediatr Hematol Oncol*. 2012;34:151–153.
- Hayes FA, Green AA, Rao BN. Clinical manifestations of ganglioneuroma. *Cancer*. 1989;63:1211–1214.
- Garvin JH Jr, Lack EE, Berenberg W, et al. Ganglioneuroma presenting with differentiated skeletal metastases. Report of a case. *Cancer*. 1984;54:357–360.
- Visfeldt J. Transformation of sympathicoblastoma into ganglioneuroma, with a case report. *Acta Pathol Microbiol Scand*. 1963;58:414–428.
- Bhattacharyya I, Williamson A, Cohen DM, et al. Metastatic neuroblastoma with ganglioneuromatous differentiation and mandibular involvement. *Oral Surg Oral Med Oral Pathol Oral Radiol Endod*. 1999;88:586–592.
- Kissane JM, Ackerman LV. Maturation of tumors of the sympathetic nervous system. *J Fac Radiol*. 1955;7:109–114.
- Goldman RL, Winterling AN, Winterling CC. Maturation of tumors of the sympathetic nervous system. Report of long-term survival in 2 patients, one with disseminated osseous metastases, and review of cases from the literature. *Cancer*. 1965;18:1510–1516.
- Mitcherling JJ, Greenwold WE, Keen RR, et al. Metastatic ganglioneuroblastoma: report of case and review of the literature. *J Oral Surg*. 1974;32:518–524.
- Patterson AR, Barker CS, Loukota RA, et al. Ganglioneuroma of the mandible resulting from metastasis of neuroblastoma. *Int J Oral Maxillofac Surg*. 2009;38:196–198.
- Chou LS, Hansen LS. Ganglioneuroma of the mandible. *Oral Surg Oral Med Oral Pathol*. 1989;68:201–205.
- Mithofer K, Grabowski EF, Rosenberg AE, et al. Symptomatic ganglioneuroma of bone. A case report. *J Bone Joint Surg Am*. 1999;81:1589–1595.
- Oeppen R, Brennan P, Stutley J. Ganglioneuroma of the mandible: radiologic and pathologic findings of a rare tumor. *Oral Surg Oral Med Oral Pathol Oral Radiol Endod*. 2000;89:259–262.
- Hustin J, Delire Y. Unusual intramandibular neural tumor. *Oral Surg Oral Med Oral Pathol*. 1991;71:593–596.
- Tao T, Shi H, Wang M, et al. Ganglioneuromas are driven by activated AKT and can be therapeutically targeted with mTOR inhibitors. *J Exp Med*. 2020;217:1–13.

37. Matthay KK, Brisse H, Couanet D, et al. Central nervous system metastases in neuroblastoma: radiologic, clinical, and biologic features in 23 patients. *Cancer*. 2003;98:155–165.
38. Kramer K, Kushner B, Heller G, et al. Neuroblastoma metastatic to the central nervous system. The Memorial Sloan-Kettering Cancer Center experience and a literature review. *Cancer*. 2001;91:1510–1519.
39. Morgenstern DA, London WB, Stephens D, et al. Prognostic significance of pattern and burden of metastatic disease in patients with stage 4 neuroblastoma: a study from the International Neuroblastoma Risk Group database. *Eur J Cancer*. 2016;65:1–10.
40. D'Ambrosio N, Lyo J, Young R, et al. Common and unusual craniofacial manifestations of metastatic neuroblastoma. *Neuroradiology*. 2010;52:549–553.
41. Couly GF, Le Douarin NM. Mapping of the early neural primordium in quail-chick chimeras. II. The prosencephalic neural plate and neural folds: implications for the genesis of cephalic human congenital abnormalities. *Dev Biol*. 1987;120:198–214.
42. Couly GF, Coltey PM, Le Douarin NM. The developmental fate of the cephalic mesoderm in quail-chick chimeras. *Development*. 1992;114:1–15.
43. O'Rahilly R, Muller F. The meninges in human development. *J Neuropathol Exp Neurol*. 1986;45:588–608.
44. Furlan A, Dyachuk V, Kastriti ME, et al. Multipotent peripheral glial cells generate neuroendocrine cells of the adrenal medulla. *Science*. 2017;357:3753–3762.
45. Lumb R, Schwarz Q. Sympathoadrenal neural crest cells: the known, unknown and forgotten? *Dev Growth Differ*. 2015;57:146–157.
46. van Noesel MM. Neuroblastoma stage 4S: a multifocal stem-cell disease of the developing neural crest. *Lancet Oncol*. 2012;13:229–230.