

University of Groningen

## A Case of Systemic Inflammatory Response Syndrome after Liposuction-assisted Abdominoplasty

Riesmeijer, Sophie; van der Lei, Berend

*Published in:*  
Plastic and Reconstructive Surgery. Global Open

*DOI:*  
[10.1097/GOX.0000000000003580](https://doi.org/10.1097/GOX.0000000000003580)

**IMPORTANT NOTE: You are advised to consult the publisher's version (publisher's PDF) if you wish to cite from it. Please check the document version below.**

*Document Version*  
Publisher's PDF, also known as Version of record

*Publication date:*  
2021

[Link to publication in University of Groningen/UMCG research database](#)

*Citation for published version (APA):*  
Riesmeijer, S., & van der Lei, B. (2021). A Case of Systemic Inflammatory Response Syndrome after Liposuction-assisted Abdominoplasty. *Plastic and Reconstructive Surgery. Global Open*, 9(5), [3580]. <https://doi.org/10.1097/GOX.0000000000003580>

### Copyright

Other than for strictly personal use, it is not permitted to download or to forward/distribute the text or part of it without the consent of the author(s) and/or copyright holder(s), unless the work is under an open content license (like Creative Commons).

The publication may also be distributed here under the terms of Article 25fa of the Dutch Copyright Act, indicated by the "Taverne" license. More information can be found on the University of Groningen website: <https://www.rug.nl/library/open-access/self-archiving-pure/taverne-amendment>.

### Take-down policy

If you believe that this document breaches copyright please contact us providing details, and we will remove access to the work immediately and investigate your claim.

Downloaded from the University of Groningen/UMCG research database (Pure): <http://www.rug.nl/research/portal>. For technical reasons the number of authors shown on this cover page is limited to 10 maximum.

# A Case of Systemic Inflammatory Response Syndrome after Liposuction-assisted Abdominoplasty

Sophie A. Riesmeijer, MD  
Berend van der Lei, MD, PhD

**Summary:** A 51-year-old woman underwent liposuction-abdominoplasty. After surgery, she developed hypotension and bradycardia, attributed to iatrogenic opioid-intoxication. After discontinuing opioids, the patient had several episodes of hypotension and tachycardia, responding well to fluid resuscitation. The initial differential diagnosis of postoperative bleeding was ruled out with a CT-scan. Other potential causes of hemodynamic instability, such as pulmonary embolism and fat embolism, were considered unlikely in absence of corresponding symptoms. Based on leukocytosis and tachycardia, the patient was diagnosed with systemic inflammatory response syndrome, a disproportional inflammatory reaction to surgery. The patient was managed expectantly with intravenous fluid administration and recovered without further treatment or complications. (*Plast Reconstr Surg Glob Open* 2021;9:e3580; doi: 10.1097/GOX.0000000000003580; Published online 18 May 2021.)

## CASE DESCRIPTION

A 51-year old woman with a history of hypertension underwent an elective liposuction-assisted abdominoplasty. First, liposuction of the entire circumference of the abdominal wall (flanks and abdomen) was performed with a 4-cm Mercedes liposuction cannula, subsequent to achieving sufficient vasoconstriction via infiltration of 3L of liposuction fluid [consisting of 3-L saline, 90 cc of 1% lidocaine (ie, 900 mg), and 1.5-mg adrenaline]. Thereafter abdominoplasty was performed. During liposuction, the patient experienced a short period of hypotension, which was ascribed to preoperative dehydration. On top of regular infusion with 1.5-L saline, 3-L saline was administered to restore adequate blood pressure.

Several hours after surgery, the patient developed significant nausea and pre-syncope with hypotension (59/35 mm Hg) and bradycardia (49 beats per minute), without fever (temperature 36.8°C). Her respiration rate was mildly increased (16/minute), with normal blood oxygen saturation (100%). Her abdomen was painless, without alarming signs of hematoma indicating postoperative bleeding. Because the patient had pinpoint pupils consistent with opioid overuse, an iatrogenic opioid-intoxication

was considered as a cause of the hypotension and bradycardia. Opioids were discontinued. Lidocaine overdose was shortly considered but immediately ruled out because the maximum dose of lidocaine was by far not reached during liposuction infiltration. Also, lidocaine allergy was considered, but the patient had reported previous lidocaine injections without complications. After intravenous fluid administration, the patient's blood pressure and heart rate restored (111/57 mm Hg and 88 beats per minute, respectively).

Hours later, the patient's blood pressure decreased again (95/69 mm Hg), accompanied by tachycardia (101 beats per minute) and diminished urine production (20 mL in 2 hours (the norm for this patient being 70 mL in 2 hours)). A small fluctuating swelling was observed caudal from the umbilicus. Palpation of the abdomen showed no signs of peritoneal irritation. The wound drains contained 50 mL serosanguineous fluid. Blood samples were analyzed for hemoglobin and hematocrit, and CT-angiography was performed to rule out significant or active intraabdominal, intramuscular, or subcutaneous bleeding (Fig. 1). To restore blood pressure, intravenous fluids were administered again. Urine production restored on fluid resuscitation and kidney function was monitored because of the transient oliguria.

Laboratory studies showed anemia with decreased hematocrit, indicating either blood dilution or blood loss (Table 1). The CT-angiography showed only a moderate fluid collection subcutaneously, suspect for a small hematoma without active bleeding. Because bleeding was ruled out as cause of the hemodynamic instability, we subsequently considered fat embolism as a possible cause as

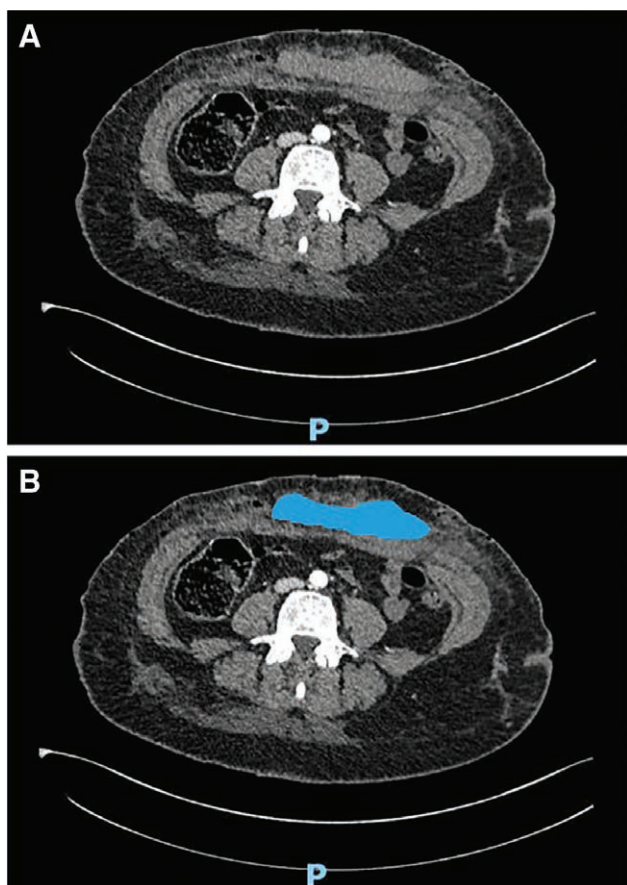
From the Department of Plastic Surgery, University Medical Center Groningen, Groningen, The Netherlands.

Received for publication January 19, 2021; accepted March 23, 2021.

Copyright © 2021 The Authors. Published by Wolters Kluwer Health, Inc. on behalf of The American Society of Plastic Surgeons. This is an open-access article distributed under the terms of the [Creative Commons Attribution-Non Commercial-No Derivatives License 4.0 \(CCBY-NC-ND\)](#), where it is permissible to download and share the work provided it is properly cited. The work cannot be changed in any way or used commercially without permission from the journal.

DOI: 10.1097/GOX.0000000000003580

**Disclosure:** The authors have no financial interest in relation to the content of this article.



**Fig. 1.** Transverse section of the CT-angiography of the abdomen. A, A fluid collection, moderate in size, can be observed caudal of the umbilicus. B, Said fluid collection indicated with the color blue.

well as pulmonary embolism after deep venous thrombosis. However, the patient lacked neurological symptoms, respiratory distress, thoracic pain during respiration, or swollen, painful calves, in addition to having a normal blood oxygen saturation; thus, we ruled these diagnoses unlikely.<sup>1,2</sup> In a very small percentage of cases, pulmonary embolism can present as hemodynamic collapse; thus, to completely rule out pulmonary embolism, a CT-scan of the lungs should have been performed, as D-dimer would not have been distinctive following surgery.

### DIAGNOSIS AND TREATMENT

After excluding above-mentioned diagnoses for postoperative hemodynamic instability, the patient was

diagnosed as having a systemic inflammatory response syndrome based on her leukocytosis (Table 1) and tachycardia. She was monitored closely and managed expectantly with intravenous fluid administration. She recovered within hours to a day without further treatments or complications.

### DISCUSSION

Surgery results in tissue damage, initiating local inflammatory response; the first stage of wound healing.<sup>3</sup> Inflammation is mediated by pro- and anti-inflammatory cytokines.<sup>3</sup> In systemic inflammatory response syndrome, inflammation becomes deregulated: patients develop excessive systemic immune responses, causing vasodilation resulting in arterial hypotension and tachycardia. In severe cases, systemic inflammatory response syndrome will lead to shock with subsequent increased morbidity and mortality.<sup>4</sup> The extent of the surgical procedure, among patient age, genetics, and comorbidities, influences individuals' inflammatory response to surgical stress.<sup>4</sup> Extensive intra-abdominal or trauma surgeries are known to often cause a systemic inflammatory response syndrome.<sup>4</sup> After a plastic surgical procedure, only 1 case has been described thus far, after abdominoplasty.<sup>5</sup>

Liposuction is known to cause a mild, transient inflammatory response. Systemic inflammatory response syndrome has not been linked directly to liposuction, but liposuction has severe potential complications, which in turn can lead to systemic inflammatory response syndrome, such as toxic shock syndrome, perforation of abdominal organs, deep venous thrombosis, and pulmonary embolisms.<sup>2</sup> One study reports 5 fatalities after liposuction, 3 of whom the cause of death was unexplained intraoperative hypotension and bradycardia.<sup>6</sup> Perhaps the explanation of these fatalities could be a severe systemic inflammatory response. Moreover, liposuction traumatizes subcutaneous microvasculature, leading to transudation and a fluid shift. Suction of this transudate during liposuction may lead to an intravascular fluid deficiency and systemic hypotension.<sup>7</sup> The intraoperative period of hypotension in our case might have indicated such a fluid shift or already the commencing systemic inflammatory response syndrome.

A systemic inflammatory response syndrome is a clinical diagnosis, defined by 2 or more criteria: abnormal temperature (<36°C or >38°C), tachycardia (>90 beats per minute), tachypnea (>20 respirations per minute), or an abnormal leukocyte count (<4 or >12 × 10<sup>9</sup>/L). Because it is a syndrome and not a disease, treatment should aim at resolving the underlying cause. When the cause is surgery,

**Table 1. Laboratory Studies**

Measure (Unit)	Result (Normal Value*)	Interpretation
Hemoglobin (mmol/L)	6.0 (7.5–10.0)	Decreased because of blood loss or blood dilution
Hematocrit (L/L)	0.29 (0.35–0.45)	Decreased because of blood loss or blood dilution
Leukocytes (*10 <sup>9</sup> /L)	27.1 (4.0–10.0)	Increased in reaction to operation or infection
C-reactive protein (mg/L)	4.4 (<5)	Normal, pleads against infection
Sodium (mmol/L)	136 (135–145)	Normal
Potassium (mmol/L)	4.8 (3.5–5.0)	Normal
Creatinine (µmol/L)	79 (50–90)	Normal
Estimated glomerular filtration rate (mL/min*1.73 m <sup>2</sup> )	75 (56–99)	Normal

\* Normal values as instated in our clinic.

it naturally cannot be resolved, but symptoms should be managed. Hypotension due to vasodilation can be treated with volume resuscitation via intravenous fluids. In case of impending shock, (nor)epinephrine should be administered. The application of steroids in sepsis and septic shock have been studied, but little research has been carried out on their effect on a systemic inflammatory response syndrome. Low dose steroids can be contemplated in case of insufficient effect of fluid resuscitation.<sup>8</sup> Additionally, antioxidants such as selenium, glutamine, and omega-3-fatty acid can complement the treatment of severe systemic inflammatory response syndrome, as well as vitamin E.<sup>9,10</sup>

In conclusion, when hemodynamic instability occurs after liposuction abdominoplasty, the most probable cause is bleeding. In this case report, we underline that a systemic inflammatory response syndrome can in rare cases also be the cause. In the latter case, surgical exploration should be omitted because additional physiological stress will worsen the inflammatory deregulation and ultimately the patient's condition.

**Sophie A. Riesmeijer, MD**

University Medical Center Groningen

Hanzeplein 1, 9713GZ Groningen

The Netherlands

E-mail address: [s.a.riesmeijer@umcg.nl](mailto:s.a.riesmeijer@umcg.nl)

## REFERENCES

1. Wang HD, Zheng JH, Deng CL, et al. Fat embolism syndromes following liposuction. *Aesthetic Plast Surg.* 2008;32:731–736.
2. Sattler G, Eichner S. [Complications of liposuction]. *Hautarzt.* 2013;64:171–179.
3. Kumar V, Abbas A, Fausto N, Aster J. *Robbins and Cotran Pathologic Basis of Disease.* 8th ed. Saunders, Elsevier inc.; 2010:102–104.
4. Alazawi W, Pirmadjid N, Lahiri R, et al. Inflammatory and immune responses to surgery and their clinical impact. *Ann Surg.* 2016;264:73–80.
5. Kargi E, Akduman D, Dokuzoğuz B, et al. Late complication of abdominoplasty in an obese patient: Systemic inflammatory response syndrome and seroma. *Plast Reconstr Surg.* 2003;111:1568–1571.
6. Rao RB, Ely SF, Hoffman RS. Deaths related to liposuction. *N Engl J Med.* 1999;340:1471–1475.
7. Kenkel JM, Lipschitz AH, Luby M, et al. Hemodynamic physiology and thermoregulation in liposuction. *Plast Reconstr Surg.* 2004;114:503–13; discussion 514.
8. Dellinger RP, Levy MM, Rhodes A, et al; Surviving Sepsis Campaign Guidelines Committee including the Pediatric Subgroup. Surviving sepsis campaign: International guidelines for management of severe sepsis and septic shock: 2012. *Crit Care Med.* 2013;41:580–637.
9. Berger MM, Chioloro RL. Antioxidant supplementation in sepsis and systemic inflammatory response syndrome. *Crit Care Med.* 2007;35(Suppl 9):S584–S590.
10. Bulger EM, Maier RV. An argument for vitamin E supplementation in the management of systemic inflammatory response syndrome. *Shock.* 2003;19:99–103.