

University of Groningen

Neuroinflammatory Disease as an Isolated Manifestation of Hemophagocytic Lymphohistiocytosis

Blincoe, Annaliesse; Heeg, Maximilian; Campbell, Patrick K.; Hines, Melissa; Khojah, Amer; Klein-Gitelman, Marisa; Talano, Julie-An; Speckmann, Carsten; Touzot, Fabien; Lankester, Arjan

Published in:
Journal of Clinical Immunology

DOI:
[10.1007/s10875-020-00814-6](https://doi.org/10.1007/s10875-020-00814-6)

IMPORTANT NOTE: You are advised to consult the publisher's version (publisher's PDF) if you wish to cite from it. Please check the document version below.

Document Version
Publisher's PDF, also known as Version of record

Publication date:
2020

[Link to publication in University of Groningen/UMCG research database](#)

Citation for published version (APA):

Blincoe, A., Heeg, M., Campbell, P. K., Hines, M., Khojah, A., Klein-Gitelman, M., Talano, J-A., Speckmann, C., Touzot, F., Lankester, A., Legger, G. E., Riviere, J. G., Garcia-Prat, M., Alonso, L., Putti, M. C., Lehmborg, K., Maier, S., El Chazli, Y., Elmaksoud, M. A., ... Haddad, E. (2020). Neuroinflammatory Disease as an Isolated Manifestation of Hemophagocytic Lymphohistiocytosis. *Journal of Clinical Immunology*, 40(6), 901-916. <https://doi.org/10.1007/s10875-020-00814-6>

Copyright

Other than for strictly personal use, it is not permitted to download or to forward/distribute the text or part of it without the consent of the author(s) and/or copyright holder(s), unless the work is under an open content license (like Creative Commons).

The publication may also be distributed here under the terms of Article 25fa of the Dutch Copyright Act, indicated by the "Taverne" license. More information can be found on the University of Groningen website: <https://www.rug.nl/library/open-access/self-archiving-pure/taverne-amendment>.

Take-down policy

If you believe that this document breaches copyright please contact us providing details, and we will remove access to the work immediately and investigate your claim.



Neuroinflammatory Disease as an Isolated Manifestation of Hemophagocytic Lymphohistiocytosis

Annaliese Blincoe^{1,2} · Maximilian Heeg^{3,4,5} · Patrick K. Campbell⁶ · Melissa Hines⁷ · Amer Khojah⁸ · Marisa Klein-Gitelman^{8,9} · Julie-An Talano¹⁰ · Carsten Speckmann^{3,11} · Fabien Touzot¹ · Arjan Lankester¹² · Geertje E. Legger¹³ · Jacques G. Rivière^{14,15} · Marina Garcia-Prat^{14,15} · Laura Alonso¹⁶ · Maria C. Putti¹⁷ · Kai Lehmborg¹⁸ · Sarah Maier¹⁸ · Yasmine El Chazli¹⁹ · Marwa Abd Elmaksoud²⁰ · Itziar Astigarraga²¹ · Natalja Kurjane^{22,23} · Inita Bulina^{22,24} · Viktorija Kenina^{23,25} · Yenan Bryceson²⁶ · Jelena Rascon^{27,28} · Anne Lortie²⁹ · Gal Goldstein³⁰ · Claire Booth³¹ · Austen Worth³¹ · Evangeline Wassmer³² · Erica G. Schmitt³³ · Julia T. Warren³³ · Jeffrey J. Bednarski³³ · Salah Ali³⁴ · Kuang-Yueh Chiang^{34,35} · Joerg Krueger^{34,35} · Michael M. Henry³⁶ · Steven M. Holland³⁷ · Rebecca A. Marsh³⁸ · Stephan Ehl³ · Elie Haddad¹

Received: 27 March 2020 / Accepted: 25 June 2020 / Published online: 7 July 2020
© Springer Science+Business Media, LLC, part of Springer Nature 2020

Abstract

Isolated neuroinflammatory disease has been described in case reports of familial hemophagocytic lymphohistiocytosis (FHL), but the clinical spectrum of disease manifestations, response to therapy and prognosis remain poorly defined. We combined an international survey with a literature search to identify FHL patients with (i) initial presentation with isolated neurological symptoms; (ii) absence of cytopenia and splenomegaly at presentation; and (iii) systemic HLH features no earlier than 3 months after neurological presentation. Thirty-eight (20 unreported) patients were identified with initial diagnoses including acute demyelinating encephalopathy, leukoencephalopathy, CNS vasculitis, multiple sclerosis, and encephalitis. Median age at presentation was 6.5 years, most commonly with ataxia/gait disturbance (75%) and seizures (53%). Diffuse multifocal white matter changes (79%) and cerebellar involvement (61%) were common MRI findings. CSF cell count and protein were increased in 22/29 and 15/29 patients, respectively. Fourteen patients progressed to systemic inflammatory disease fulfilling HLH-2004 criteria at a mean of 36.9 months after initial neurological presentation. Mutations were detected in *PRF1* in 23 patients (61%), *RAB27A* in 10 (26%), *UNC13D* in 3 (8%), *LYST* in 1 (3%), and *STXBP2* in 1 (3%) with a mean interval to diagnosis of 28.3 months. Among 19 patients who underwent HSCT, 11 neurologically improved, 4 were stable, one relapsed, and 3 died. Among 14 non-transplanted patients, only 3 improved or had stable disease, one relapsed, and 10 died. Isolated CNS-HLH is a rare and often overlooked cause of inflammatory brain disease. HLH-directed therapy followed by HSCT seems to improve survival and outcome.

Keywords Familial hemophagocytic lymphohistiocytosis · CNS disease · CNS inflammation · therapy

Annaliese Blincoe, Maximilian Heeg, Stephan Ehl and Elie Haddad contributed equally to this work.

Electronic supplementary material The online version of this article (<https://doi.org/10.1007/s10875-020-00814-6>) contains supplementary material, which is available to authorized users.

✉ Stephan Ehl
stephan.ehl@uniklinik-freiburg.de

✉ Elie Haddad
elie.haddad@umontreal.ca

Extended author information available on the last page of the article

Abbreviations

FHL	Familial hemophagocytic lymphohistiocytosis
NK	Natural killer cell
CNS	Central nervous system
CSF	Cerebrospinal fluid
HSCT	Hematopoietic stem cell transplant
MRI	Magnetic resonance imaging
EBV	Epstein-Barr virus
HSV	Herpes simplex virus
sIL2-R	Soluble interleukin-2 receptor
IT	Intrathecal
VP-16	Etoposide

CsA	Cyclosporine A
MTX	Methotrexate
IVIG	Intravenous immunoglobulin
MMF	Mycophenolate mofetil
ATG	Anti-thymocyte globulin
CTL	Cytotoxic T lymphocyte
APC	Antigen-presenting cells
TLR	Toll-like receptor

Introduction

Neuroinflammatory disorders are a heterogeneous group of severe diseases characterized by inflammation in the cerebrum or the spine. They can be grouped according to the putative primary immune mechanism, including cell-mediated, antibody-associated, and infection-associated CNS disease, genetically driven immune-mediated CNS disease, and paraneoplastic neurological disorders [1]. Much progress has been made in diagnosis and treatment of neuroinflammatory disorders, in particular with the increasing recognition of autoantibody-associated diseases; however, the disease mechanisms and therefore the appropriate treatment targets remain unclear in a relevant fraction of severely affected patients.

Familial hemophagocytic lymphohistiocytosis (FHL) is a rare, inherited syndrome of immune dysregulation that is caused by impairment of the cytotoxic function of NK and T cells leading to uncontrolled immune cell activation, excessive secretion of inflammatory cytokines, and subsequent multiorgan cell-mediated immunopathology [2, 3]. Multiple genetic defects responsible for FHL have been described including *PRF1*, *UNC13D*, *STX11*, *STXBP*, *LYST*, and *RAB27A*, all playing crucial roles in the granule exocytosis cytotoxicity pathway [4]. Patients with loss-of-function mutations in these genes usually present early in life with fevers, cytopenia, splenomegaly, and a combination of characteristic laboratory features, which are the basis of the HLH-2004 diagnostic criteria [5]. CNS involvement and inflammation is frequently observed as part of this systemic disease process [6, 7], but does not feature in the current criteria. Systemic hemophagocytic lymphohistiocytosis (HLH) is normally managed acutely with the use of immunosuppression, often including dexamethasone and etoposide [8]; however, long-term cure can only be achieved by allogeneic stem cell transplantation.

Notably, there are also case reports of isolated CNS disease in FHL patients, occurring in the absence of any systemic disease features, mostly in older patients with hypomorphic mutations [9–23]. Reported cases are rare and therefore the spectrum of clinical manifestations, response to therapy and prognosis remain poorly defined.

To better characterize this rare neuroinflammatory disorder, we present herein 20 new cases followed in North American, European, and other international centers together with a summary of all 18 cases we could identify in the literature. We describe the clinical presentation, treatment, and outcome of isolated CNS-HLH in the largest cohort reported to date.

Patients and Methods

Recruitment of Patients

In order to identify FHL patients who presented with isolated CNS manifestations, we performed a survey among centers involved in the diagnosis and treatment of HLH through the Histiocyte Society (HS), the European Society of Blood and Bone Marrow Transplantation's Inborn Errors Working Party (IEWP), and through North American collegial networks. These data were supplemented by a literature review based on a PubMed search for “hemophagocytic lymphohistiocytosis” or “HLH” or “FHL” and “CNS” or “encephalitis” and “isolated” or “presenting” including the “similar article” function, up to February 28, 2019. All potential cases were reviewed by AB, MH, RM, EH, and SE. Patients were only included if they fulfilled the following criteria: (1) confirmed diagnosis of FHL by genetic and/or functional testing; (2) any neurological clinical symptom at time of presentation; (3) absence of systemic HLH according to HLH-2004 criteria [5] at presentation and within the first 3 months after initial neurological presentation (in particular absence of bi-lineage cytopenia and absence of splenomegaly). Fever and increased ferritin level were permitted to allow capturing patients with an initial diagnosis of cerebral vasculitis.

From all patients, we recorded demographic data, clinical and neurological presentations, neuro-radiological imaging (MRI), CSF examination (total cell count, protein, cytospin), CNS biopsy or autopsy results, features of systemic HLH according to HLH-2004 criteria [5], genetic and functional diagnosis of FHL, microbiological data, data on treatment (including intrathecal therapy), HSCT data (donor source, conditioning regimen), and outcome including neurological outcomes and survival. For published patients, this information was extracted from the literature.

Statistical Analysis

Data for continuous variables is presented using medians and means with ranges as appropriate.

Results

Neurological Presentations in Isolated CNS-HLH

Twenty new patients from 16 centers in Europe, North America, Egypt, and Israel were eligible for inclusion in the study, and 18 patients were identified in the literature. Altogether we analyzed 38 patients from 37 unrelated families. The median age at time of onset of neurological symptoms was 6.5 years (mean 8.3 years, range 0.5–31 years). Neurological presentation was assessed both at initial presentation (Fig. 1a) and at FHL diagnosis (performed by molecular and/or functional testing) because in most cases, initial manifestations were not recognized as CNS-HLH. The most common neurological manifestations were ataxia and gait disturbance in 28/32 patients (74%), seizures in 19/38 (50%), headache in 18/38 (47%), limb weakness or motor impairment in 16/38 (42%), and visual abnormalities in 17/38 (45%). Progression/relapse of neurological symptoms from initial onset of symptoms to time of molecular/functional diagnosis was reported in 28/38 (74%) patients. The initial diagnoses included acute demyelinating encephalopathy, CNS vasculitis, leukodystrophy, multiple sclerosis and other demyelinating disorders, neuroinflammatory disorders, and encephalitis (Table 1). The mean interval from onset of neurological symptoms to confirmed molecular diagnosis of FHL was 28.3 months (median 19.5 months, range 1–108 months; timing not reported in 2 patients and diagnosis was confirmed post-mortem in 2 literature patients).

Imaging, CSF, and Brain Biopsy Findings in Isolated CNS-HLH

CNS MRI imaging was performed and showed abnormal findings in all patients (Fig. 1). Diffuse or multifocal white matter changes were the most common findings in 30/38 (79%). Cerebellar involvement was reported in 23/38 patients (61%), including cerebellar white matter changes (17), atrophy (5), edema (4), nodular changes (2), necrosis (1), masses (1), and hemorrhage (1). Further MRI findings were periventricular changes in 14/38 (37%), brainstem involvement in 14/38 (37%), edema or swelling in 10/38 (26%), and volume loss or atrophy in 8/38 (21%) (Fig. 1, Supplemental Table S1).

CSF cell count was not highly elevated, but abnormal ($> 5 \times 10^6/L$) in 22/29 patients. The median CSF cell count was $10.0 \times 10^6/L$ (range 0– $84 \times 10^6/L$). CSF protein level was elevated (> 45 mg/dL) in 15/29 patients. The median CSF protein was 43 mg/dL (range 4–874 mg/dL). CSF cytospin was performed in 9 patients and CSF hemophagocytosis was not observed. Two patients had evidence of activated T cells in the CSF (90% and 33% of cells being HLA-DR+, respectively). Importantly, the latter patient had HLA-DR expression on $< 5\%$ of T cells in peripheral blood analyzed in parallel.

Twenty-two brain biopsies were performed in 19 patients, with T cell-dominated lymphohistiocytic infiltration being the most common finding (Fig. 1, Supplemental Table S2).

Fig. 1 **a** Frequencies of neurological manifestations, neuroradiological findings, and histopathologic CNS biopsy results in 38 patients with isolated CNS HLH. **b** Examples of CNS MRI imaging in patients with isolated CNS-HLH. Upper panel: patient 1—T2 images in 2016 (left) and 2017 (right) demonstrate cerebral atrophy with diffuse white matter abnormalities. Lower panel: patient 4—T2 images reveal multiple nodular lesions in the pons, cerebellum, and white matter

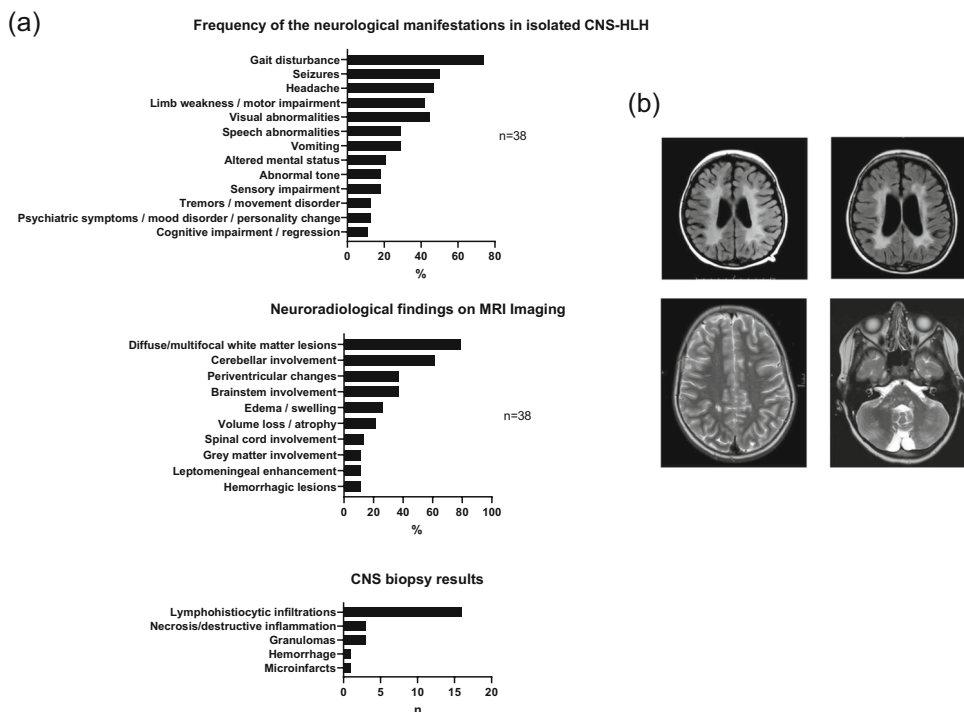


Table 1 Clinical findings in isolated CNS-HLH

Pt	Age/ onset	Initial clinical manifestations	Neurological manifestations at FHL diagnosis	CSF cell count × 10 ⁶ /L	CSF protein mg/dL	Initial diagnosis	Time from neuro onset to systemic HLH (if applicable)	Time from neuro onset to molecular FHL diagnosis
1	4 y	Acute loss of ability to walk	Spastic tetraplegia, dysphagia, dysphasia, exotropia, neurogenic bladder, seizures	19 (d)	41 (d)	ADEM Leukodystrophy	5 y	5 y
2	8 y	Headache, unsteady gait, somnolence	Gait disturbance. Non-responsiveness requiring intubation, seizures	26 (p)	250 (p)	CNS vasculitis	n.a.	5 mo
3	2 y	Ataxia, slurred speech	Ataxia, slurred speech, weakness	4 (d)	10 (d)	n.r.	n.a.	5 mo
4	10 y	Unilateral leg weakness, gait disturbance	Progression to inability to walk	7 (p)	35 (p)	ADEM	n.a.	4 mo
5	14 y	Headache, vomiting, dizziness, diplopia, dysphoria	Ataxia	21	220	n.r.	28 mo	28 mo
6	19 mo	Insecure gait, somnolence, irritability	Left hemiparesis, visual abnormalities	12	n.r.	n.r.	6 mo	6 mo
7	4 y	Headache, status epilepticus	Status epilepticus	0 (p)	47 (p)	n.r.	n.a.	1 mo
8	7 mo	*Gray hair Ataxia	Ataxia, poor balance, speech difficulties, urinary incontinence	4	41	Neuroinflammatory disorder	n.a.	24 mo
9	5 y	Gait disturbance, vomiting, unconsciousness, seizures	Vomiting, headache	36	76	Labyrinthitis ADEM	n.a.	3 mo
10	11 y	Vomiting, reduced consciousness, hypotonia, hyperreflexia, gray hair	Progressive weakness, inability to walk, speech disturbance, headache, seizures, reduced consciousness	0 (p) 26 (d)	27 (p)	ADEM Metachromatic leukodystrophy Griscelli neuropathology	n.a.	15 mo
11	14 y	Headache, diplopia, vertigo, fixation nystagmus*	Ataxia, slurred speech, diplopia, right hemiparesis	30	40	ADEM CNS vasculitis	7 y	7 y
12	8 y	Generalized seizures	Facial nerve palsy, mild ataxia and dysmetria	0	normal	ADEM	n.a.	4 mo
13	9 y	Headache, blurred vision, slurred speech, abnormal gait	Intermittent paresthesias	8	40.4	ADEM CNS vasculitis	n.a.	12 mo
14	9 y	Headache, vomiting, blurred vision, unsteadiness	Headache, generalized tonic clonic seizures	2 (d)	Normal (d)	CNS inflammatory disease	27 mo	14 mo
15	9 y	Ataxia, visual disturbance	Chorea, right upper limb hypertonia, ataxia, visual disturbance	13 (2 y post--d)	n.r.	Small vessel CNS vasculitis	4 y	9 y
16	14 y	Left sided paresthesias, headache, nausea, vomiting, difficulty walking, fatigue	Left-sided paresthesias, headache, nausea, vomiting, difficulty walking, fatigue	1	25	Brain mass	n.a.	2 mo
17	3 y	Seizures, left arm weakness	Seizures, left arm weakness	1	27	ADEM	n.a.	12 mo
18	13 y	Headache, ataxia, word finding difficulties, transient left arm and facial weakness, blurred vision in left eye	Headaches, flashing lights, paresthesia, right-sided weakness	13	58	ADEM	n.a.	3 y
19	4.5 y	Headache, fatigue, excessive crying, vomiting, weight loss	Headache, fatigue, convergent squint, personality change	14	43	EBV infection CLIPPERS	n.a.	2 y 8 mo
20	11 y	Ataxia	Diplopia, strabismus, nystagmus, ataxia	4	31	Atypical ADEM CLIPPERS	n.a.	2 y 1 mo
L1(10)	6 mo			30	119	Aseptic meningitis	27 mo	24 mo

Table 1 (continued)

Pt	Age/ onset	Initial clinical manifestations	Neurological manifestations at FHL diagnosis	CSF cell count × 10 ⁶ /L	CSF protein mg/dL	Initial diagnosis	Time from neuro onset to systemic HLH (if applicable)	Time from neuro onset to molecular FHL diagnosis
L2(11)	22 mo	Poor head control, seizures Ataxia, abnormal eye movements, dysarthria	Tetraplegia, cognitive impairment, seizures Seizures, meningism, dysphagia, progressive cognitive and motor loss	12	56	Metabolic neurodegeneration	22 mo	Post-mortem
L3(11) Sib of L2	6 y	Seizure	Ataxia, loss of ability to walk, progressive motor and sensory loss	4	30	Varicella meningitis Encephalomyelitis	n.a.	Post-mortem
L4(12)	13 y	Headache	Ataxia, vomiting, diplopia, 6th/7th cranial nerve palsy, papilloedema, absent reflexes in lower limbs, sensory loss	n.r.	48	CNS tumor ADEM/immune-mediated inflammatory disorder	n.a.	4 mo
L5(13)	16 y	Unilateral weakness, paresthesia	Intermittent sensory deficits, headache	n.r.	n.r.	Multiple sclerosis	24 mo	24 mo
L6(14)	2.5 y	Seizures, somnolence	Spasticity, unable to sit, speech impairment	n.r.	440	Encephalitis	n.a.	n.r.
L7(15)	14 y	Headache, dysarthria, abnormal gait, strabismus, hyperesthesia	Generalized seizure	20	4.1	Neuroinflammatory disorder	13 mo	13 mo
L8(16)	4 y	Visual disturbances, vomiting, vertigo, dizziness	Stumbling, falling, loss of hearing	n.r.	n.r.	CNS vasculitis	n.a.	14 mo
L9(17)	5 y	Headaches, vomiting, mild ataxia, speech difficulties, developmental regression	n.r.	10	45	Demyelinating clinically isolated syndrome	n.a.	5 y
L10(17)	6 y	Cognitive decline, psychiatric symptoms, headache, focal seizure, hemiparesis, dystonia	n.r.	3	33	ADEM	n.a.	2 y
L11(17)	7 y	Diplopia, ataxia, right hemiparesis, seizure, mood lability	n.r.	12	41	Demyelinating clinically isolated syndrome CLIPPERS	n.a.	6 y
L12(19)	5.5 y	Vomiting, fatigue, weakness, tremors, reduced consciousness, gray hair	Right hemiparesis, ataxia, spasticity, speech abnormalities	10 (d)	150 (d)	Metachromatic leukodystrophy	10 mo	10 mo
L13(20)	20 y	Bilateral loss of visual acuity, headache	Seizure, mood disturbance	8 (p) (cells/ m ³)	76 (p)	ADEM Multiple sclerosis	n.a.	8 mo
L14(21)	6 y	Vomiting, headache, weakness, ataxia, confusion*	Multiple relapses, ataxia, tremor	Minimal	normal	ADEM Multiple sclerosis	7y	7 y
L15(21)	5 y	Ataxia, strabismus, diplopia, papilloedema, somnolence*	n.r.	n.r.	n.r.	ADEM	4 y	4 y
L16(22)	15 y	Generalized tonic-clonic seizure, left sided hemiparesis	Generalized tonic-clonic seizure	1 (p)	29 (p)	n.r.	n.a.	n.r.
L17(23)	31 y	Paresthesia left arm, left-sided hemiparesis	Seizure	84	791	Combined immunodeficiency	3 y	3 y
L18(21)	2.5 y	Ataxia, gait disturbance, tremor*	Seizures, stopped walking, apraxia	6	874	Acute cerebellitis, chronic meningoencephalomye- litis	n.a.	5 y

y years, mo months, n.r. not reported, (p) presentation, (d) diagnosis, n.a. not applicable, ADEM acute demyelinating encephalomyelitis, CLIPPERS chronic lymphocytic inflammation with pontine enhancement responsive to steroids

*No hypopigmentation

Infectious Triggers in Isolated CNS-HLH

CSF and blood analysis for infectious triggers was positive in two of 15 unreported patients and revealed the presence of EBV in the blood and CSF in patient 3 and CMV in the blood but not CSF in patient 14. Among the published patients, L5, L7, L17, and L18 were reported to have EBV infection or reactivation, L2 developed symptoms immediately following gastrointestinal infection (no pathogen identified), and L3 and L18 developed symptoms in the context of varicella zoster infection.

Progression to Systemic HLH

As defined by the eligibility criteria, no patient fulfilled the clinical HLH-2004 diagnostic criteria for systemic HLH [5] (not considering reduced cytotoxicity or the genetic diagnosis of FHL) within 3 months of the onset of neurological symptoms. Three patients were reported as having elevated sIL2-R (mean 2746 U/mL, range 2030–3500 U/mL), 2 patients had mildly elevated ferritin (426 ng/mL and 599 ng/mL respectively), and 2 patients had fever. Most patients had no clinical sign of systemic HLH. However, a total of 14 patients (6 unreported, 8 published) progressed to fulfill the criteria for systemic HLH, with a mean latency of 36.9 months (median 27.5 months, range 6–84 months) from initial onset of neurological symptoms. Notably, 24/38 (63%) patients never developed systemic HLH before death, HSCT, or end of follow-up.

Rationale for Consideration of Isolated CNS HLH

The diagnosis of FHL was considered for the following reasons: (i) after eventual onset of systemic HLH in 8 patients; (ii) following genetic investigations for unexplained neurological disease in 8 patients (iii) when disease pattern, imaging, and response to therapy were felt to be atypical in 5 patients; (iv) following brain biopsy in 6 patients; (v) due to the presence of hair or skin abnormalities in 3 patients; (vi) due to similar cases or cases in the literature in 2 patients; (vii) due to a family history of isolated CNS-HLH in 1 patient and (viii) not reported in 7 patients (Table 2). Nine patients were reported to be from consanguineous families, and four patients had silvery gray hair or abnormal hair microscopy consistent with Griscelli syndrome type 2.

Genetic Diagnoses in FHL Patients with Isolated CNS-HLH

All 38 patients had a confirmed FHL genetic diagnosis (Fig. 2, Table S3). All mutations have either been previously reported in systemic HLH or their pathogenicity has been confirmed by perforin expression or functional testing, with the exception of L12 who has a novel mutation in *RAB27A* that has not yet

Table 2 Rationale for consideration/investigation of isolated CNS-HLH

Basis of investigation for FHL	Number of patients (n = 28)
Eventual onset of systemic HLH	8
Genetic investigation for unexplained neurological disease	8
Atypical disease pattern/response to therapy	5
Brain biopsy findings	6
Skin/hair abnormalities	3
Family history of isolated CNS-HLH	1
Similar case/cases in literature	2
Not reported	7

been functionally evaluated. However, this patient had abnormal hair pigmentation in keeping with the clinical syndrome. The majority of patients, 23/38 (61%), had biallelic mutations in *PRF1* (FHL2). All 23 FHL2 patients carried at least one missense mutation, 11 of them homozygous. All fourteen analyzed patients had reduced or absent perforin expression on flow cytometry. Notably, seven patients from 6 families carried the same p.R225W mutation, with 6 patients being homozygous. Ten patients (26%) had mutations in *RAB27A*, three of them without abnormal hair pigmentation had the recently described duplication-inversion mutation of the 5' untranslated region (2 homozygous). Finally, 3 patients had compound heterozygous mutations in *UNC13D*; P16 had compound heterozygous mutations in *LYST* in addition to a polymorphism in *PRF1* and P19 had compound heterozygous mutations in *STXBP2*, with one mutation at a splice site acceptor site.

Outcomes Following Systemic Therapy in Isolated CNS-HLH

Overall, reported therapy was highly variable. Nineteen previously unreported patients received systemic HLH-directed

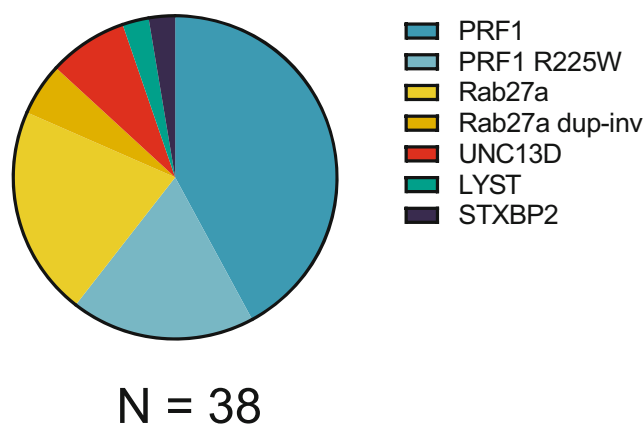


Fig. 2 Overview of genetic mutations found in isolated CNS HLH

therapy as detailed in Table 3. Outcome did not appear to correlate with intrathecal treatment. Five of them received VP-16 (etoposide)-based protocols, one improved, one had initial improvement then deteriorated, one was stable, two deteriorated, and response not reported in one. Two patients were treated with alemtuzumab and corticosteroids, with the addition of CSA in one patient. One patient improved significantly and rapidly resumed walking; the second one remained stable. Eleven patients were treated with various immunosuppressive agents, all in combination with steroids (detailed in Table 3). Seventeen literature patients received systemic chemo/immunotherapy, while treatment was not reported in 1 patient. Improvement occurred in 3 out of 8 reported patients who received VP-16 (etoposide)-based protocols. Four patients were managed with steroids alone with splenectomy in L5.

Neurological Outcomes and Survival Following HSCT

Eleven of the 20 unreported patients proceeded to HSCT as depicted in Table 3, while 3 patients died before transplantation, 1 patient is currently maintained with intermittent systemic therapy, and 3 are awaiting HSCT. Donor sources were heterogeneous. Conditioning regimen were mostly Bu/Flu (4) or Treo/Flu (3) based reduced toxicity regimen, the latter in combination with thiotepa. Nine of the eleven transplanted patients are currently alive and in remission from both acute CNS and systemic HLH manifestations, with a mean time post-HSCT of 24 months (median 17 months, range 4.9–51 months, not reported in 1). With the exception of one patient, all have permanent neurological deficits. HSCT was reported in 8 literature patients with all patients being alive at time of last follow-up. Progress post-HSCT and neurological outcomes are also summarized in Fig. 3. The overall mortality was 34%. Altogether, of the 19 patients treated with HSCT, 11 patients (59%) had improved neurological outcome with “normal” neurological status reported in 2 patients, 4 patients (21%) had stable neurological findings, including permanent deficits, one patient had relapse of his CNS disease requiring a second HSCT, one patient died 8 months post-HSCT due to brain hemorrhage and neurological deterioration, one patient died 33 days post-HSCT of idiopathic pneumonitis, and one patient died 5 months post-HSCT of sepsis. In contrast, only two of the 14 patients (13%) who did not receive HSCT had neurological improvement, 1 patient (P10) had neurological improvement followed by several CNS relapses, 1 (7%) had stable neurological outcome, 10 died (67%), and neurological outcome not reported in one. Four patients are currently awaiting HSCT.

Discussion

We provide here the first comprehensive review of clinical manifestations, diagnostic features, treatment, and outcome

of isolated CNS-HLH, a cell-mediated neuroinflammatory disease that can be the initial presenting manifestation in a group of rare monogenetic immunodeficiencies. An increased awareness of this clinical entity in the differential diagnosis of neuroinflammatory disease will allow more rapid diagnosis and treatment targeted to the specific disease pathophysiology.

Familial hemophagocytic lymphohistiocytosis (FHL) is a rare, inherited syndrome of immune dysregulation that is caused by impairment of the cytotoxic function of NK and T cells [4]. While FHL patients are usually asymptomatic at birth, immune activation (typically infections) trigger the severe systemic inflammation characteristic for hemophagocytic lymphohistiocytosis (HLH) [24]. The clinical presentation of HLH is dominated by fevers, cytopenias, and splenomegaly and a number of typical laboratory features including excessive elevation of ferritin and sIL2-R. If untreated, HLH rapidly leads to inflammation-associated multiorgan failure. CNS inflammation is frequently part of this systemic disease and has an important impact on long-term prognosis [25].

A number of case reports have pointed out that FHL can also present as a highly variable and non-specific neuroinflammatory disease [10–22] in the absence of any systemic features of HLH. This different clinical manifestation leads to initial presentation to the neurologist who is less familiar with this rare disease than the hemato-oncologist or immunologist who are usually confronted with FHL patients due to their systemic inflammatory and hematologic manifestations. Although the number of the worldwide collected patients presented in this paper may seem to be low, the true incidence of isolated CNS-HLH is likely to be higher, since we did not include patients without confirmed molecular diagnosis, shorter interval until systemic symptoms, or patients in whom the diagnosis FHL was never made. We expect that with the increased use of exome sequencing in rare disease presentations, the true incidence will become more obvious in the future.

Our large case collection identified ataxia and gait disturbance (74%), seizures (50%), headache (47%), visual abnormalities (45%), and limb weakness or motor impairment (42%) as the most common neurological manifestations. A predilection for cerebellar involvement was also evident in imaging studies as 61% of patients had cerebellar abnormalities detected on MRI. Indeed, all patients had abnormal MRI findings, with progression of changes reported in multiple patients from initial presentation to FHL diagnosis. In addition to predominant cerebellar involvement, we observed diffuse and multifocal white matter changes, atrophy, leptomeningeal enhancement, edema, and hemorrhage. Previous literature detailing radiological findings in systemic HLH with CNS involvement reports that the spectrum of findings in these patients is highly diverse and non-specific, with focal, diffuse, and mixed changes that can evolve with time. This is similar

Table 3 Treatment and outcome of patients with isolated CNS-HLH

Pt	Systemic HLH	Systemic therapy	IT therapy (doses)	Response to initial therapy	HSCt donor	Conditioning	Post-HSCT complications	Donor chimerism (time after HSCT)	Neurological outcome	Status (time at last f/u)
1	Yes	Alemtuz, steroids	MTX (5) Ara-C + steroids (3)	No neurological improvement	MMFD (mortality)	Bu (t), Flu, Alemtuz, Cyclophos d 3/4	ADV, CMV, HSV, respiratory deterioration	100% (10 mo)	Moderate improvement. Continued significant impairment	Alive (10 mo)
2	No	Cyclophos, steroids	None	Gradual but significant partial neurological improvement	MSD	Flu, Mel, Alemtuz	None	100%	Stable. Permanent neurocognitive deficits. Speech impairment	Alive (51 mo)
3	No	VP-16, steroids, RTX	RTX	n.r.	–	–	–	–	Initial improvement then deterioration. Permanent deficits	Dead Lost to follow-up
4	No	Alemtuz, steroids, CsA	None	Stable, partial neurological improvement	MUD	Treo, Flu, TT, Alemtuz	CMV	99% (d 238)	Improved. Subtle neurological symptoms	Alive (24 mo)
5	Yes	Steroids, CsA, IVIG	None	n.r.	MUD	Treo, Flu, TT, Alemtuz	ADV, HSV, cerebral HLH reactivation	99.9% (d 100)	Stable. Neurological deficits remaining	Alive
6	Yes	HLH-94	n.r.	Neurological deterioration	–	–	–	–	Neurological deterioration	Dead
7	No	HLH-94, IVIG	MTX + steroids (14)	Significant neurological improvement	MSD	Bu, Flu, ATG	None	82% (lymph)	Stable. Neurological sequelae	Alive (47 mo)
8	No	Steroids, Cyclophos, MTX, MMF	None	Initial improvement post-list Cyclophos then relapse	n.r.	Treo, Flu, TT	Pericardial effusion, autoimmune hypothyroidism, mild chronic GVHD, edema, lung disease	100% (9 mo)	Moderate improvement	Alive (10 mo)
9	No	HLH-94	MTX, steroids	n.r.	Cord	Bu (t), Flu, ATG	Cerebral hemorrhage	n.r.	Neurological deterioration	Dead (8 mo), CNS hemorrhage Alive (36 mo)
10	No	Steroids	MTX, steroids	Initial improvement	–	–	–	–	Neurological sequelae. Several CNS relapses while on intermittent maintenance tx	Neurological deterioration Dead, infection
11	Yes	Cyclophos, steroids, Rtx, IVIG, MTX, αIL-1 splenectomy	None	Initial improvement post-IVIG	–	–	–	–	Improvement	Alive. Awaiting HSCT
12	No	Steroids	MTX (4)	Improvement	MSD planned	–	–	–	Improvement	Alive. Awaiting HSCT
13	No	Steroids, IVIG, Rtx, Cyclophos, HLH-94	MTX	Stable	MUD	Flu, Mel, TT, Alemtuz	Hypertension, Noro, adrenal insufficiency, electrolyte abnormalities	78% lymph. 100% CD15 (d 100)	Improvement. Normal neurological status	Alive (150 days)
14	Yes	Steroids, IVIG, plasma exchange HLH-2004	MTX, steroids (5)	Partial response	MUD	Flu, Treo, Cyclophos, ATG	Idiopathic pneumonitis syndrome	n.r.	–	Dead (33 days, idiopathic pneumonitis syndrome)

Table 3 (continued)

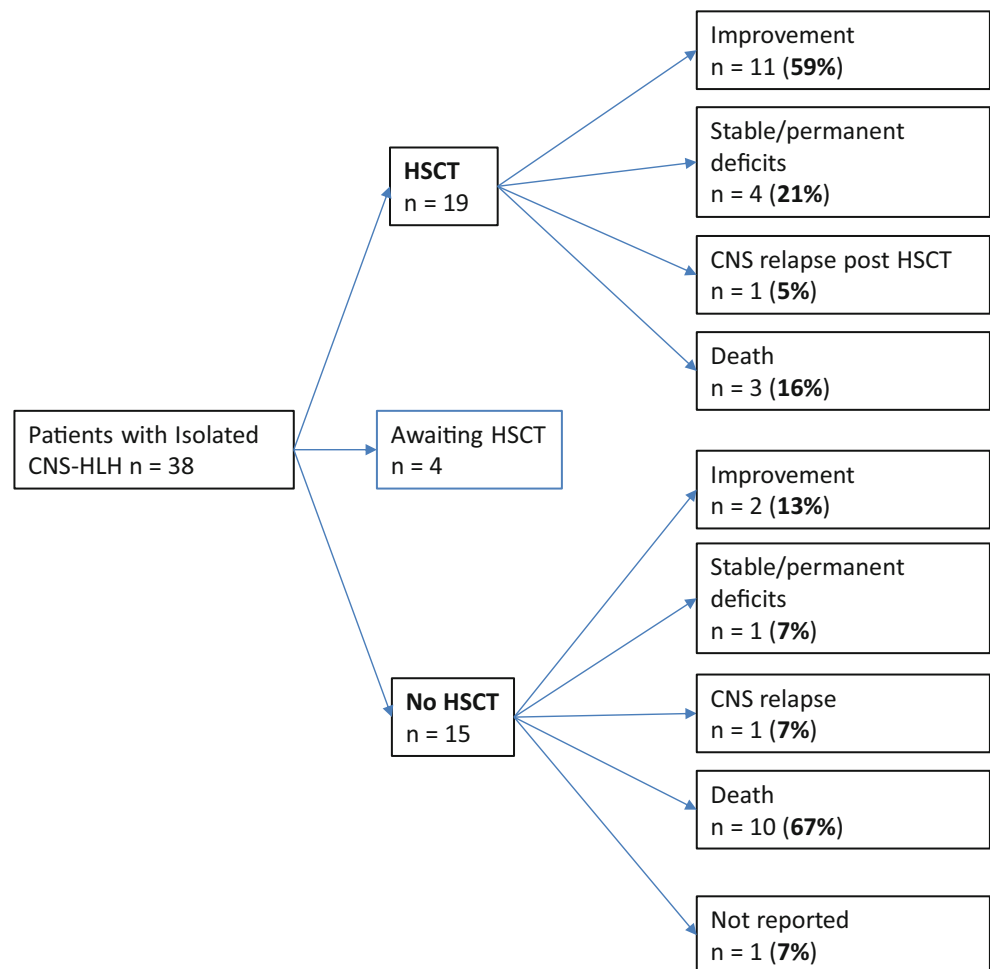
Pt	Systemic HLH	Systemic therapy	IT therapy (doses)	Response to initial therapy	HSCT donor	Conditioning	Post-HSCT complications	Donor chimerism (time after HSCT)	Neurological outcome	Status (time at last f/u)
15	Yes	Steroids, IVIG, Rtx, Cyclophos, Infix, Abat Steroids, CSA	None	Partial response	MUD	Flu, Treo, Cyclophos, ATG	ADV, EBV, E.Coli sepsis, GI candidiasis, upper GI GVHD, renal failure, capillary leak syndrome, CVL-related thrombosis	Full donor	Stable	Alive (288 days)
16	No	None	None	Improvement	—	—	—	—	Improvement. Seizures	Alive (36 mo)
17	No	Steroids	MTX, steroids (4)	Improvement	MMFD (mother)	Bu, Flu, TT, Alemtuz	HHV6/ADV enteritis, CMV reactivation, PCJ pneumonia, AIHA requiring splenectomy, iron overload, RSV pneumonitis, AKI	100% donor (day + 1060)	Improvement. Seizures	Alive (36 mo)
18	No	Steroids	MTX (4)	Complete remission	MUD planned	—	—	—	Improvement	Alive, awaiting HSCT
19	No	Steroids, MMF	None	Improvement	—	—	—	—	Improvement	Alive (3 y 2 mo)
20	No	Steroids, MMF	None (planned)	No improvement	Planned	—	—	—	Persistent neurological symptoms	Alive (2 y 9 mo)
L1(10)	Yes	Steroids, CsA	None	n.r.	—	—	—	—	Continued neurological deterioration	Dead (44 mo) systemic HLH
L2(11)	Yes	n.r.	n.r.	n.r.	—	—	—	—	n.r.	Dead, infection, cardiac failure
L3(11)	No	Steroids	None	n.r.	—	—	—	—	n.r.	Dead
Sib of L2	—	—	—	—	—	—	—	—	—	—
L4(12)	Yes	HLH-2004	n.r.	n.r.	MSD	n.r.	n.r.	100% (7 mo)	Improved. Normal neurological status	Alive (18 mo)
L5(13)	Yes	Steroids, splenectomy	None	Deterioration	—	—	—	—	—	Dead, cranial hemorrhage
L6(14)	No	HLH-2004	n.r.	No neurological improvement	—	—	—	—	Stable. Severe impairment	Alive (n.r.)
L7(15)	Yes	Steroids, RTX, MIMF	None	Neurological improvement	n.r.	n.r.	n.r.	n.r.	Neurological improvement	Alive (4 mo)
L8(16)	No	HLH-94, Cyclophos	n.r.	Neurological deterioration	MSD	Flu, Bu	n.r.	20–30%	Significant neurological improvement	Alive (n.r.)
L9(17)	No	Cyclophos, steroids, IVIG, MIMF, nata	MTX, steroids	Neurological deterioration	MUD	Flu, Melph, Alemtuz	Pericardial effusion, post-transplant microangiopathy	> 97% (37 mo)	Neurological improvement	Alive (39mo)
L10(17)	No	Cyclophos, steroids, IVIG, plasmapheresis	MTX, steroids	n.r.	1. MSD 2. MUD	Flu, Melph, Alemtuz Flu, Bu,	1. ADV, CMV, sepsis C.diff colitis 2. CMV, sepsis	1. 46% at relapse 2. 90% (14 mo)	Initial improvement. CNS relapse 13 months post-HSCT, second MUD HSCT	Alive (15 mo)
L11(17)	No	Cyclophos, steroids, RTX, IVIG, AZA, Infix	n.r.	n.r.	MUD	Flu, Melph, Alemtuz	ADV, parainfluenza virus, C.diff colitis	91% (27 mo)	Neurological improvement and reduced seizure frequency	Alive (32 mo)
L12(19)	Yes	HLH-2004	MTX, steroids (4)	Initial neurological stabilization	—	—	—	—	Initial improvement. CNS relapse	Dead (16 mo) Systemic HLH
L13(20)	No	HLH 2004, plasmapheresis	n.r.	n.r.	—	—	—	—	n.r.	Alive Awaiting HSCT

Table 3 (continued)

Pt	Systemic HLH	Systemic therapy	IT therapy (doses)	Response to initial therapy	HSCT donor	Conditioning	Post-HSCT complications	Donor chimerism (time after HSCT)	Neurological outcome	Status (time at last f/u)
L14(21)	Yes	HLH-2004	None	Initial improvement of systemic features	–	–	–	–	Neurological deterioration, massive CNS lesions	Dead, CNS EBV + <i>Aspergillus</i>
L15(21)	Yes	HLH-2004	None	Initial remission. Relapse 2 mo later	MSD	Flu, Mel	Acute + chronic GVHD	100% (10 mo)	Significant neurologic improvement	Alive (36 mo)
L16(22)	No	HLH-2004 + Alemtuz	MTX, steroids (4)	n.r.	MUD	Alemtuz, Flu, Mel	ADV, RSV, Noro, GVHD grade II, AIN	100% (2 y)	Significant neurological improvement	Alive (2 y)
L17(23)	Yes	Steroids, CsA, Cyclophos, MMF	None	Deterioration	–	–	–	–	Generalized seizures	Dead (age 37 y)
L18(21)	No	Steroids	None	Improvement, followed by episodes of relapse	MUD	Flu, Treo, Alemtuz	Diarrhea, CMV reactivation, hemorrhagic cystitis (BK-virus)	100% donor (d + 120)	Stable	Dead (5 mo). Sepsis, acute renal + respiratory failure

n.r. not reported, d day, mo months, IT intrathecal, HSCT hematopoietic stem cell transplant, IV intravenous, Alemtuz alemtuzumab, Cyclophos cyclophosphamide, VP-16 etoposide, RTX rituximab, CsA cyclosporine A, IVIG intravenous immunoglobulin, HLH-94 as per HLH-94 protocol, HLH-2004 as per HLH-2004 protocol, MMF mycophenolate mofetil, nata natalizumab, AZA azathioprine, Infix infliximab, MTX methotrexate, Abat abatacept, Ara-C cytarabine, MMFD mismatched familial donor, moth mother, MSD matched sibling donor, MUD matched unrelated donor, Bu busulfan, (t) targeted busulfan dosing, Flu fludarabine, Mel melphalan, Treo treosulfan, TT thiotepa, ATG anti-thymocyte globulin, lymph lymphocytes, ADV adenovirus, CMV cytomegalovirus, HSV herpes simplex virus, E.Coli *Escherichia coli*, GI gastrointestinal, WBC white blood cells, Staph *Staphylococcus*, Strep *Streptococcus*, C.diff *Clostridium difficile*, RSV respiratory syncytial virus, Noro norovirus, GVH graft versus host disease, AIN autoimmune neutropenia

Fig. 3 Survival and neurological outcome of transplanted and non-transplanted patient



to what we observed in our patient series [6, 26–33]. The majority had mild CSF pleocytosis (median 10×10^6 cells/L) and CSF protein elevation (median 43 mg/dL), which was less than previously reported in systemic CNS-HLH ($20\text{--}80 \times 10^6$ /L and 50–100 mg/dL, respectively) [6, 25]. Concomitant isolated CNS infection was not observed in any patient and only 7 patients had systemic infections reported during their neurological presentation.

The unspecific nature and the wide variety of neurological symptoms, CSF, and radiological findings of isolated CNS-HLH led to a mean delay from disease onset to molecular FHL diagnosis of 28.3 months, which had significant consequences for patient outcome. In many patients, CNS-HLH was not sufficiently controlled by the treatment directed against other suspected conditions and progressed over time. Moreover, 14 patients developed systemic HLH at intervals of up to 7 years after the initial neurological symptoms and 9 of these patients had a fatal outcome. One of the key questions is therefore how patients with neuroinflammatory disease as an isolated manifestation of FHL can be identified more rapidly.

Although there were individual patients with fever, moderate ferritin, or sIL2-R elevation (< 3500 U/mL) at neurological

presentation, there was no single “HLH marker” that was consistently abnormal to raise awareness for this differential diagnosis of neuroinflammatory disease and most patients did not fulfill a single systemic HLH criterion. Diffuse and multifocal white matter lesions on MRI are not specific and can be found in a variety of inflammatory CNS diseases. Differential diagnoses include multiple sclerosis, ADEM, especially in a pediatric population, encephalitis, but also metabolic diseases, infections, CNS vasculitis, and leukodystrophy [34]. Nevertheless, the presence of non-specific enhancing lesions on MRI, in particular with cerebellar involvement, should alert to CNS-HLH as a possible differential diagnosis. Clinically, the presence of seizures in a patient diagnosed with ADEM or MS should raise suspicion, as seizures would be uncommon in these two important differential diagnoses. Furthermore, CNS-HLH should be considered when the evolution of the proposed diagnosis is atypical, in either the response to treatment or the expected natural history of the disease. This includes acute deterioration in patients suspected as having a chronic disease such as a leukodystrophy or recurrent neurological symptoms 3 months after a diagnosis of ADEM. Diagnostic testing for FHL should therefore be performed

generously in the context of non-specific neuroinflammation with atypical presentation or clinical course, in particular in childhood, in patients from consanguineous families, in those with a family history of FHL, and in patients with hair pigmentation abnormalities characteristic for most (but not all) patients with Griscelli syndrome type 2. In addition, the presence of any single sign of systemic HLH should provide even more reason to test FHL, although this is not required, as shown in this study.

Flow cytometry for perforin expression and NK and T cell degranulation are excellent screening assays for FHL providing high positive and negative predictive values in experienced laboratories [35]. Since results can be available within 48 h, they can be rapidly incorporated into treatment decisions [36]. Functional testing also allows more targeted genetic analysis, which remains the gold standard. In our worldwide cohort, *PRF1* mutations were found most frequently (61% of patients), which is more than the 15 and 37% reported in two recent European systemic FHL series [36, 37]. The mean age of onset for patients with *PRF1* mutations in our cohort was 7.5 years. This is much higher than in cohorts of FHL2 patients with systemic HLH where disease onset is usually in the first year of life, although systemic HLH has manifested in an FHL2 patient as late as 62 years [38]. The spectrum of mutations in our cohort is different from the spectrum seen in systemic HLH. Interestingly, 7 patients from 6 families carried the p.R225W *PRF1* mutation, which has been associated with late-onset HLH in previous reports [39]. Most patients carried at least one point mutation and none of our patients carried biallelic mutations leading to a premature stop codon, compatible with the possible hypomorphic nature of these variants. In contrast, in a study from the Italian HLH registry including 69 patients with FHL2, W374X, Y219X, and R232H were the most frequent *PRF1* mutations, and these were associated with early manifestations of HLH [40]. None of these mutations was detected in our cohort. Nevertheless, it is important to point out that several of the mutations observed in our cohort have also been reported in association with systemic HLH (e.g., L17fs*, Q446P, V50M, D70Y*). Thus, the specific mutation does not predict the type of disease manifestation. However, the higher association of probably hypomorphic mutations with CNS-only disease could point towards pathogenetic differences as discussed below.

A further 26% of patients had Griscelli syndrome type 2 (found in 5 and 11% in the two recent systemic series) [36, 37], enriched for a particular genetic variant in the *RAB27A* 5' untranslated region which requires particular attention since it is not found upon exome sequencing [21]. Only 3 patients with *UNC13D* mutations and one patient each with a *LYST* and an *STXBP2* mutation were identified, while FHL3 represented 28 and 33% in recent FHL series [36, 37]. Notably, the spectrum of genotypes we observed was unexpected and does

not correlate with previous reports of CNS-HLH in systemic HLH, where CNS disease was observed in 36% of 124 FHL2 patients [41], while it was seen in 60% of 81 patients with FHL3 (*UNC13D*) [42], although these two diseases show a similar prevalence in cohorts focusing on systemic FHL [40]. Since about half of the patients in our cohort were taken from the literature, the earlier discovery of the genetic cause of FHL2 may play a role, but this may also indicate differences in pathogenesis. *MUNC13-4* is not only involved in the release of perforin, but also in other physiological processes involving lysosomal transport, including other immune functions [43]. It is possible that this may explain why the disease more frequently affects both compartments in FHL3, while it can remain limited to CNS or the systemic compartment in FHL2.

How should CNS-HLH be managed therapeutically? For CNS involvement in systemic FHL, Horne et al. recommend use of the full HLH-2004 protocol [5, 25] including IT methotrexate and corticosteroids as first-line and high-dose pulse corticosteroids or alemtuzumab as second-line therapy. Although the literature regarding the overall benefit of the additional IT therapy is not clear, Horne et al. suggest it as standard of care [25]. Our case collection suggests that this therapeutic concept can also improve neuroinflammatory disease in isolated CNS-HLH. The excellent response of a wheelchair-bound patient, who started walking again after monotherapy with alemtuzumab and steroids, may indicate an approach that is worth further exploration. In the future, it will be interesting to explore new agents such as anti-interferon- γ antibody or ruxolitinib [44–46], which are currently under study for systemic HLH.

An important question is whether diagnosis of isolated CNS-HLH also represents an indication for HSCT [47]. Although HSCT is curative for FHL, CNS involvement in systemic HLH is associated with a poorer outcome after HSCT [6, 48]. In systemic HLH patients with CNS involvement who survived post-HSCT, Deiva et al. found that 18% had severe and 21% intermediate neurological impairment [49]. Horne et al. observed that 15% of patients were left with neurological sequelae such as neurodevelopmental delay and seizures [7]. In our cohort, 59% of patients demonstrated neurological improvement post-HSCT, including the most severely affected patients; only one patient had CNS relapse and three patients died post-HSCT. A poor pre-HSCT neurological status was associated with a poor long-term neurological outcome. Patients who were not transplanted had a much poorer outcome, with 33% of patients alive at follow-up and only 2 surviving with reported neurological improvement. Although this retrospective case series does not allow for firm conclusions, our data strongly suggest that HSCT should also be rapidly performed in isolated CNS-HLH in the context of FHL.

The pathophysiological mechanism why neuroinflammation occurs in the absence of systemic HLH remains a matter of speculation. One possibility is that isolated CNS infection leads to immune activation limited to this compartment. Although isolated CNS infection was not reported in any patient in our cohort, one cannot exclude that the serological and PCR analysis for neurotropic viruses may have missed relevant pathogens. Alternatively, the apparently isolated neuroinflammation may in fact be part of a clinically unnoticed systemic immune response. It is conceivable that in the presence of hypomorphic mutations, residual cytotoxicity allows for the control of the systemic immune activation so it can remain clinically unnoticed. In contrast, CTL may (at least initially) have limited access to the CNS and allow more widespread APC and macrophage activation in this compartment, eventually resulting in apparently isolated CNS disease. Non-infectious localized immune stimulation also remains a possibility, for example, via TLR triggering [50]. In this respect, the observation of isolated CNS-HLH in FHL patients adds to observations of primary HLH manifestation in utero (with unlikely infectious exposure) and the lack of an obvious infectious trigger in many cases of early-onset FHL [51].

In summary, isolated CNS-HLH is a rare, severe but treatable cause of inflammatory brain disease. If considered early in the differential diagnosis, the availability of rapid, sensitive, and specific immunological and genetic tests allows a rapid diagnosis of this rare condition [35, 36, 52]. HLH-directed therapy followed by HSCT appears to be essential for survival and improved neurological outcome.

Author Contribution AB, MH, EH, and SE wrote the manuscript. All other authors provided clinical information. SE and EH supervised the project. All authors commented on the manuscript.

Funding Information This study was supported by the German Research Foundation (DFG SFB1160, TPA01), the Bundesministerium für Bildung und Forschung (01EO1303), the Deutsche Kinderkrebsstiftung (DKS 2016.04 and DKS 2018.11), and the Pediatric Immunology Research Chair, Bank of Montreal.

Compliance with Ethical Standards

The study was approved by the ethics committee of the University of Freiburg (EK No. 159/19).

Conflict of Interest SE was part of an Advisory Board at UCB and has received research support from UCB. EH is a consultant for Leadiant. KL is part of an Advisory Board at SOBI. AL is member of the advisory board at Neovii and has received research support from Medac. The remaining authors declare that they have no competing interests.

References

- Wells E, Hacohen Y, Waldman A, Tillema JM, Soldatos A, Ances B, et al. Neuroimmune disorders of the central nervous system in children in the molecular era. *Nat Rev Neurol*. 2018;14(7):433–45.
- Chinn IK, Eckstein OS, Peckham-Gregory EC, Goldberg BR, Forbes LR, Nicholas SK, et al. Genetic and mechanistic diversity in pediatric hemophagocytic lymphohistiocytosis. *Blood*. 2018;132(1):89–100.
- Janka GE, Lehmsberg K. Hemophagocytic syndromes—an update. *Blood Rev*. 2014;28(4):135–42.
- Schmid JP, Côte M, Ménager MM, Burgess A, Nehme N, Ménasché G, et al. Inherited defects in lymphocyte cytotoxic activity. *Immunol Rev*. 2010;235(1):10–23.
- Henter J-I, Horne A, Aricó M, Egeler RM, Filipovich AH, Imashuku S, et al. HLH-2004: diagnostic and therapeutic guidelines for hemophagocytic lymphohistiocytosis. *Pediatr Blood Cancer*. 2007;48(2):124–31.
- Haddad E, Sulis M-L, Jabado N, Blanche S, Fischer A, Tardieu M. Frequency and severity of central nervous system lesions in hemophagocytic lymphohistiocytosis. *Blood*. 1997;89(3):794–800.
- Horne A, Trottestam H, Aricó M, Egeler RM, Filipovich AH, Gadner H, et al. Frequency and spectrum of central nervous system involvement in 193 children with haemophagocytic lymphohistiocytosis. *Br J Haematol*. 2008;140(3):327–35.
- Ehl S, Astigarraga I, von Bahr GT, Hines M, Horne A, Ishii E, et al. Recommendations for the use of etoposide-based therapy and bone marrow transplantation for the treatment of HLH: consensus statements by the HLH Steering Committee of the Histiocyte Society. *J Allergy Clin Immunol Pract*. 2018;6(5):1508–17.
- Zhang K, Jordan MB, Marsh RA, Johnson JA, Kissell D, Meller J, et al. Hypomorphic mutations in PRF1, MUNC13-4, and STXBP2 are associated with adult-onset familial HLH. *Blood*. 2011;118(22):5794–8.
- Feldmann J. Severe and progressive encephalitis as a presenting manifestation of a novel missense perforin mutation and impaired cytolytic activity. *Blood*. 2005;105(7):2658–63.
- Dias C, McDonald A, Sincan M, Rupps R, Markello T, Salvarinova R, et al. Recurrent subacute post-viral onset of ataxia associated with a PRF1 mutation. *Eur J Hum Genet*. 2013;21(11):1232–9.
- Chiapparini L, Uziel G, Vallinoto C, Bruzzone MG, Rovelli A, Tricomi G, et al. Hemophagocytic lymphohistiocytosis with neurological presentation: MRI findings and a nearly miss diagnosis. *Neurol Sci*. 2011;32(3):473–7.
- Beatty AD, Weller C, Levy B, Vogler C, Ferguson WS, Bicknese A, et al. A teenage boy with late onset hemophagocytic lymphohistiocytosis with predominant neurologic disease and perforin deficiency. *Pediatr Blood Cancer*. 2008;50(5):1070–2.
- Tesi B, Chiang SCC, El-Ghoneimy D, Hussein AA, Langenskiöld C, Wali R, et al. Spectrum of atypical clinical presentations in patients with biallelic PRF1 missense mutations. *Pediatr Blood Cancer*. 2015;62(12):2094–100.
- Murphy C, Nanthapaisal S, Gilmour K, Laurent S, D'Arco F, Hemingway C, et al. Progressive neurologic disorder: initial manifestation of hemophagocytic lymphohistiocytosis. *Neurology*. 2016;86(22):2109–11.
- Moshous D, Feyen O, Lankisch P, Schwarz K, Schaper J, Schneider M, et al. Primary necrotizing lymphocytic central nervous system vasculitis due to perforin deficiency in a four-year-old girl. *Arthritis Rheum*. 2007;56(3):995–9.
- Solomon IH, Li H, Benson LA, Henderson LA, Degar BA, Gorman MP, et al. Histopathologic correlates of familial hemophagocytic lymphohistiocytosis isolated to the central nervous system. *J Neuropathol Exp Neurol*. 2018;77(12):1079–84.
- Li H, Benson LA, Henderson LA, Solomon IH, Kennedy AL, Soldatos A, et al. Central nervous system-restricted familial hemophagocytic lymphohistiocytosis responds to hematopoietic cell transplantation. *Blood Adv*. 2019;3(4):503–7.
- Lee JYW, Eldeeb MS, Hsu CK, Saito R, Abouzeid SA, McGrath JA. Further evidence for genotype-phenotype disparity in Griscelli syndrome. *Br J Dermatol*. 2017;176(4):1086–9.

20. Algahtani H, Absi A, Bassuni W, Shirah B. Adult-onset hemophagocytic lymphohistiocytosis type 2 presenting as a demyelinating disease. *Mult Scler Relat Disord*. 2018;25:77–82.
21. Tesi B, Rascon J, Chiang SCC, Burnyte B, Löfstedt A, Fasth A, et al. A RAB27A 5' untranslated region structural variant associated with late-onset hemophagocytic lymphohistiocytosis and normal pigmentation. *J Allergy Clin Immunol*. 2018;142(1):317–21.e8.
22. Khazal S, Polishchuk V, Soffer G, Prinzing S, Gill J, Mahadeo KM. Allogeneic hematopoietic stem cell transplantation is associated with cure and durable remission of late-onset primary isolated central nervous system hemophagocytic lymphohistiocytosis. *Pediatr Transplant*. 2017;22(1):e13101.
23. Rohr J, Beutel K, Maul-Pavicic A, Vraetz T, Thiel J, Warnatz K, et al. Atypical familial hemophagocytic lymphohistiocytosis due to mutations in UNC13D and STXBP2 overlaps with primary immunodeficiency diseases. *Haematologica*. 2010;95(12):2080–7.
24. Janka GE. Familial and acquired hemophagocytic lymphohistiocytosis. *Annu Rev Med*. 2012;63(1):233–46.
25. Home A, Wickström R, Jordan MB, Yeh EA, Naqvi A, Henter J-I, et al. How to treat involvement of the central nervous system in hemophagocytic lymphohistiocytosis? *Curr Treat Options Neurol*. 2017;19(1):3.
26. Jordan MB, Allen CE, Weitzman S, Filipovich AH, McClain KL. How I treat hemophagocytic lymphohistiocytosis. *Blood*. 2011;118(15):4041–52.
27. Turtzo LC, Lin DDM, Hartung H, Barker PB, Arceci R, Yohay K. A neurologic presentation of familial hemophagocytic lymphohistiocytosis which mimicked septic emboli to the brain. *J Child Neurol*. 2007;22(7):863–8.
28. Kieslich M, Vecchi M, Driever PH, Laverda AM, Schwabe D, Jacobi G. Acute encephalopathy as a primary manifestation of haemophagocytic lymphohistiocytosis. *Dev Med Child Neurol*. 2001;43(08):555.
29. Fitzgerald NE, McClain KL. Imaging characteristics of hemophagocytic lymphohistiocytosis. *Pediatr Radiol*. 2003;33(6):392–401.
30. Anderson TL, Carr CM, Kaufmann TJ. Central nervous system imaging findings of hemophagocytic syndrome. *Clin Imaging*. 2015;39(6):1090–4.
31. Decaminada N, Cappellini M, Mortilla M, Del Giudice E, Sieni E, Caselli D, et al. Familial hemophagocytic lymphohistiocytosis: clinical and neuroradiological findings and review of the literature. *Childs Nerv Syst*. 2009;26(1):121–7.
32. Goo HW, Weon YC. A spectrum of neuroradiological findings in children with haemophagocytic lymphohistiocytosis. *Pediatr Radiol*. 2007;37(11):1110–7.
33. Rooms L, Fitzgerald N, McClain KL. Hemophagocytic lymphohistiocytosis masquerading as child abuse: presentation of three cases and review of central nervous system findings in hemophagocytic lymphohistiocytosis. *Pediatrics*. 2003;111(5):e636–e40.
34. Wildner P, Stasiolek M, Matysiak M. Differential diagnosis of multiple sclerosis and other inflammatory CNS diseases. *Mult Scler Relat Disord*. 2020;37:101452.
35. Bryceson YT, Pende D, Maul-Pavicic A, Gilmour KC, Ufheil H, Vraetz T, et al. A prospective evaluation of degranulation assays in the rapid diagnosis of familial hemophagocytic syndromes. *Blood*. 2012;119(12):2754–63.
36. Ammann S, Lehmborg K, zur Stadt U, Klemann C, SFN B, Speckmann C, et al. Effective immunological guidance of genetic analyses including exome sequencing in patients evaluated for hemophagocytic lymphohistiocytosis. *J Clin Immunol*. 2017;37(8):770–80.
37. Cetica V, Pende D, Griffiths GM, Aricò M. Molecular basis of familial hemophagocytic lymphohistiocytosis. *Haematologica*. 2010;95(4):538–41.
38. Nagafuji K, Nonami A, Kumano T, Kikushige Y, Yoshimoto G, Takenaka K, et al. Perforin gene mutations in adult-onset hemophagocytic lymphohistiocytosis. *Haematologica*. 2007;92(7):978–81.
39. Madkaikar M, Gupta M, Dixit A, Patil V. Predominant neurologic manifestations seen in a patient with a biallelic perforin1 mutation (PRF1; p.R225W). *J Pediatr Hematol Oncol*. 2017;39(2):143–6.
40. Cetica V, Sieni E, Pende D, Danesino C, De Fusco C, Locatelli F, et al. Genetic predisposition to hemophagocytic lymphohistiocytosis: report on 500 patients from the Italian registry. *J Allergy Clin Immunol*. 2016;137(1):188–96.e4.
41. Trizzino A, Stadt U, Ueda I, Risma K, Janka G, Ishii E, et al. Genotype phenotype study of familial haemophagocytic lymphohistiocytosis due to perforin mutations. *J Med Genet*. 2007;45(1):15–21.
42. Sieni E, Cetica V, Santoro A, Beutel K, Mastrodicasa E, Meeths M, et al. Genotype-phenotype study of familial haemophagocytic lymphohistiocytosis type 3. *J Med Genet*. 2011;48(5):343–52.
43. Pivot-Pajot C, Varoqueaux F, de Saint BG, Bourgoin SG. Munc13-4 regulates granule secretion in human neutrophils. *J Immunol*. 2008;180(10):6786–97.
44. Broglie L, Pommert L, Rao S, Thakar M, Phelan R, Margolis D, et al. Ruxolitinib for treatment of refractory hemophagocytic lymphohistiocytosis. *Blood Adv*. 2017;1(19):1533–6.
45. Maschalidi S, Sepulveda FE, Garrigue A, Fischer A, de Saint Basile G. Therapeutic effect of JAK1/2 blockade on the manifestations of hemophagocytic lymphohistiocytosis in mice. *Blood*. 2016;128(1):60–71.
46. Das R, Guan P, Sprague L, Verbist K, Tedrick P, An QA, et al. Janus kinase inhibition lessens inflammation and ameliorates disease in murine models of hemophagocytic lymphohistiocytosis. *Blood*. 2016;127(13):1666–75.
47. Benson LA, Li H, Henderson LA, Solomon IH, Soldatos A, Murphy J, et al. Pediatric CNS-isolated hemophagocytic lymphohistiocytosis. *Neurol Neuroimmunol Neuroinflamm*. 2019;6(3):e560–e.
48. Jovanovic A, Kuzmanovic M, Kravljanc R, Micic D, Jovic M, Gazikalovic S, et al. Central nervous system involvement in hemophagocytic lymphohistiocytosis: a single-center experience. *Pediatr Neurol*. 2014;50(3):233–7.
49. Deiva K, Mahlaoui N, Beaudonnet F, de Saint BG, Caridade G, Moshous D, et al. CNS involvement at the onset of primary hemophagocytic lymphohistiocytosis. *Neurology*. 2012;78(15):1150–6.
50. Behrens EM, Canna SW, Slade K, Rao S, Kreiger PA, Paessler M, et al. Repeated TLR9 stimulation results in macrophage activation syndrome-like disease in mice. *J Clin Invest*. 2011;121(6):2264–77.
51. Heeg M, Ammann S, Klemann C, Panning M, Falcone V, Hengel H, et al. Is an infectious trigger always required for primary hemophagocytic lymphohistiocytosis? Lessons from in utero and neonatal disease. *Pediatr Blood Cancer*. 2018;65(11):e27344.
52. Rubin TS, Zhang K, Gifford C, Lane A, Choo S, Blessing JJ, et al. Perforin and CD107a testing is superior to NK cell function testing for screening patients for genetic HLH. *Blood*. 2017;129(22):2993–9.

Publisher's Note Springer Nature remains neutral with regard to jurisdictional claims in published maps and institutional affiliations.

Affiliations

Annaliese Blincoe^{1,2}  · Maximilian Heeg^{3,4,5} · Patrick K. Campbell⁶ · Melissa Hines⁷ · Amer Khojah⁸ · Marisa Klein-Gitelman^{8,9} · Julie-An Talano¹⁰ · Carsten Speckmann^{3,11} · Fabien Touzot¹ · Arjan Lankester¹² · Geertje E. Legger¹³ · Jacques G. Rivière^{14,15} · Marina Garcia-Prat^{14,15} · Laura Alonso¹⁶ · Maria C. Putti¹⁷ · Kai Lehmborg¹⁸ · Sarah Maier¹⁸ · Yasmine El Chazli¹⁹ · Marwa Abd Elmaksoud²⁰ · Itziar Astigarraga²¹ · Natalja Kurjane^{22,23} · Inita Bulina^{22,24} · Viktorija Kenina^{23,25} · Yenan Bryceson²⁶ · Jelena Rascon^{27,28} · Anne Lortie²⁹ · Gal Goldstein³⁰ · Claire Booth³¹ · Austen Worth³¹ · Evangeline Wassmer³² · Erica G. Schmitt³³ · Julia T. Warren³³ · Jeffrey J. Bednarski³³ · Salah Ali³⁴ · Kuang-Yueh Chiang^{34,35} · Joerg Krueger^{34,35} · Michael M. Henry³⁶ · Steven M. Holland³⁷ · Rebecca A. Marsh³⁸ · Stephan Ehl³ · Elie Haddad¹

¹ CHU Sainte-Justine, Department of Pediatrics, Department of Microbiology, Infectious Diseases and Immunology, University of Montreal, Montreal, QC H3T 1C5, Canada

² Department of Paediatric Immunology and Allergy, Starship Children's Health, Auckland, New Zealand

³ Institute for Immunodeficiency, Center for Chronic Immunodeficiency, Medical Center, Faculty of Medicine, University of Freiburg, Breisacher Strasse 115, 79106 Freiburg, Germany

⁴ Center for Pediatrics, Medical Center - University of Freiburg, Faculty of Medicine, University of Freiburg, Freiburg, Germany

⁵ Berta-Ottenstein-Programme, Faculty of Medicine, University of Freiburg, Freiburg, Germany

⁶ Department of Oncology, St. Jude Children's Research Hospital, Memphis, TN, USA

⁷ Department of Pediatric Medicine, Division of Critical Care, St Jude Children's Research Hospital, Memphis, TN, USA

⁸ Department of Rheumatology, Ann and Robert H Lurie Children's Hospital and Children's Hospital of Chicago, Chicago, IL, USA

⁹ Department of Rheumatology, Northwestern University Feinberg School of Medicine, Chicago, IL, USA

¹⁰ Pediatric Hematology and Oncology, Children's Hospital of Wisconsin-Milwaukee Campus, Milwaukee, WI, USA

¹¹ Department of Pediatric and Adolescent Medicine, Division of Pediatric Hematology and Oncology, Faculty of Medicine, University of Freiburg, Freiburg, Germany

¹² Willem-Alexander Children's Hospital, Department of Pediatrics, Leiden University Medical Center, Leiden, Netherlands

¹³ Department of Pediatrics, University of Groningen, University Medical Centre Groningen, Groningen, The Netherlands

¹⁴ Pediatric Infectious Diseases and Immunodeficiencies Unit, Hospital Universitari Vall d'Hebron, Vall d'Hebron Research Institute, Universitat Autònoma de Barcelona, Barcelona, Spain

¹⁵ Jeffrey Modell Foundation Excellence Centre, Barcelona, Spain

¹⁶ Pediatric Hematology and Oncology Department, Hospital Universitari Vall d'Hebron, Vall d'Hebron Research Institute, Universitat Autònoma de Barcelona, Barcelona, Spain

¹⁷ Department of Pediatrics, University of Padua Medical School, Padua, Italy

¹⁸ Division of Pediatric Stem Cell Transplantation and Immunology, University Medical Center, Hamburg, Germany

¹⁹ Hematology and Oncology Unit, Alexandria University Children's Hospital, Department of Pediatrics, Faculty of Medicine, Alexandria University, Alexandria, Egypt

²⁰ Neurology Unit, Alexandria University Children's Hospital, Department of Pediatrics, Faculty of Medicine, Alexandria University, Alexandria, Egypt

²¹ Department of Pediatrics, Hospital Universitario Cruces, IIS BioCruces Bizkaia, Department of Pediatrics, Faculty of Medicine, UPV/EHU, Barakaldo, Bizkaia, Spain

²² Stradins Clinical University Hospital, Riga, Latvia

²³ Department of Biology and Microbiology, Rigas Stradins University, Riga, Latvia

²⁴ Department of Rheumatology, Stradins Clinical University Hospital, Riga, Latvia

²⁵ Department of Neurology, Hospital Gailezers, Riga, Latvia

²⁶ Center for Hematology and Regenerative Medicine, Department of Medicine Huddinge, Karolinska Institutet, Karolinska University Hospital, Stockholm, Sweden

²⁷ Center for Pediatric Oncology and Hematology, Vilnius University Hospital Santaros Klinikos, Vilnius, Lithuania

²⁸ Institute of Clinical Medicine, Vilnius University, Vilnius, Lithuania

²⁹ CHU Sainte Justine, Department of Neurology, Cerebral Electrophysiology Laboratory, Department of Neurosciences, University of Montreal, Montreal, QC, Canada

³⁰ Department of Pediatric Hematology-Oncology, Hadassah-Hebrew University Medical Center, Ein Kerem, Jerusalem, Israel

³¹ Department of Pediatric Immunology, Great Ormond Street Hospital, London WC1N 3JH, UK

³² Department of Neurology, Birmingham Women's and Children's Hospital, Birmingham, UK

³³ Department of Pediatrics, Washington University School of Medicine in St. Louis, St. Louis, MO, USA

³⁴ Division of Hematology/Oncology/BMT, The Hospital for Sick Children, Toronto, ON, Canada

³⁵ Department of Pediatrics, University of Toronto, Toronto, ON, Canada

³⁶ Centre for Cancer and Blood Disorders, Phoenix Children's Hospital, Phoenix, USA

³⁷ Division of Intramural Research, Laboratory of Clinical Immunology and Microbiology, National Institute of Allergy and Infectious Diseases, National Institutes of Health, Bethesda, USA

³⁸ Department of Pediatrics, University of Cincinnati, Division of Bone Marrow Transplantation and Immune Deficiency, Cincinnati Children's Medical Centre, Cincinnati, OH, USA