

University of Groningen

Checkpoint inhibition-induced sicca

Pringle, S.; Wang, X.; Vissink, A.; Bootsma, H.; Kroese, F. G. M.

Published in:
Clinical and Experimental Rheumatology

IMPORTANT NOTE: You are advised to consult the publisher's version (publisher's PDF) if you wish to cite from it. Please check the document version below.

Document Version
Publisher's PDF, also known as Version of record

Publication date:
2020

[Link to publication in University of Groningen/UMCG research database](#)

Citation for published version (APA):

Pringle, S., Wang, X., Vissink, A., Bootsma, H., & Kroese, F. G. M. (2020). Checkpoint inhibition-induced sicca: a type II interferonopathy? *Clinical and Experimental Rheumatology*, 38(4), S253-S260.
<https://www.clinexprheumatol.org/abstract.asp?a=16080>

Copyright

Other than for strictly personal use, it is not permitted to download or to forward/distribute the text or part of it without the consent of the author(s) and/or copyright holder(s), unless the work is under an open content license (like Creative Commons).

The publication may also be distributed here under the terms of Article 25fa of the Dutch Copyright Act, indicated by the "Taverne" license. More information can be found on the University of Groningen website: <https://www.rug.nl/library/open-access/self-archiving-pure/taverne-amendment>.

Take-down policy

If you believe that this document breaches copyright please contact us providing details, and we will remove access to the work immediately and investigate your claim.

Downloaded from the University of Groningen/UMCG research database (Pure): <http://www.rug.nl/research/portal>. For technical reasons the number of authors shown on this cover page is limited to 10 maximum.

Checkpoint inhibition-induced sicca: a type II interferonopathy?

S. Pringle¹, X. Wang¹, A. Vissink², H. Bootsma¹, F.G.M. Kroese¹

¹Department of Rheumatology and Clinical Immunology, University Medical Centre Groningen, University of Groningen;

²Department of Oral and Maxillofacial Surgery, University Medical Centre Groningen, University of Groningen, the Netherlands.

Sarah Pringle, PhD

Xiaoyan Wang, MSc

Arjan Vissink, DMD, MD, PhD

Hendrika Bootsma, MD, PhD

Frans G.M. Kroese, PhD

Please address correspondence to:

Sarah Pringle

Department of Rheumatology

and Clinical Immunology,

University Medical Centre Groningen,

University of Groningen,

Hanzeplein 1,

9800 RB Groningen, the Netherlands.

E-mail: s.a.pringle@umcg.nl

Received on June 30, 2020; accepted in revised form on July 27, 2020.

Clin Exp Rheumatol 2020; 38 (Suppl. 126): S253-S260.

© Copyright CLINICAL AND

EXPERIMENTAL RHEUMATOLOGY 2020.

Key words: primary Sjögren's syndrome, immune checkpoint inhibitors, salivary gland, sicca complaints, lymphocytic infiltration, interferon- γ

ABSTRACT

The advent of immune checkpoint inhibitor (ICI) therapy for treatment of cancers is unfortunately coupled with a broad panoply of side effects, related to non-specific activation of the immune system. One such side effect is the development of sicca complaints. This culminates in a proportion of patients who, according to the ACR-EULAR 2016 criteria, can be classified as suffering from the autoimmune disease primary Sjögren's syndrome (pSS). Although salivary gland (SG) loss of function is often seen after ICI therapy, the similarities with 'classical' pSS patients would appear to end there. Despite the presence of focal lymphocytic sialadenitis typical for SS in salivary gland biopsies from patients receiving ICI therapy, the nature of the immune infiltration (foci) following ICI use (T-cell dominated) is starkly different to that in pSS (B-cell dominated). The SG parenchyma post-ICI use does not present with germinal centres, lymphoepithelial lesions or IgG plasma cells, which are frequently found in the SG in pSS. Here we review the functional deterioration of SGs following ICI use, the SG parenchyma phenotype associated with this, and ultrasound abnormalities. We conclude by suggesting that ICI-induced SG dysfunction may represent a new interferonopathy, driven by IFN γ , and that this 'pSS' patient cohort may require a different management than classical pSS patients.

Immune checkpoint inhibitors, a double-edged sword

Cancer can be considered a 'hypimmune disease'. T-cell activation against tumor cells can be inhibited by T-cell expression of inhibitory signalling proteins CTLA-4 (inhibition at the level of T-cell activation in the lymphoid organs) and PD-1 (inhibition at the level of tumors expressing PD-L1). These proteins normally prevent T-cell over-activation during regular immune

responses against micro-organisms and are named 'immune checkpoints'. Blockade of these proteins inevitably results in enhanced activation of T-cells, and in the case of anti-tumour immune responses, in consequential enhanced tumor cell killing. Therapy exploiting monoclonal antibodies designed to perform exactly this function is termed immune checkpoint inhibitor (ICI) therapy. ICIs are efficacious in treatment of melanoma, lung cancer and head and neck cancer (1).

Whilst cancer is considered a 'hypimmune disease', ICI use results in a 'hyperimmune' state. Current literature suggests that in up to 60% of patients taking ICIs, autoimmune-like diseases such as colitis, pneumonitis, inflammatory arthritis, inflammatory myopathy, vasculitis, and lupus nephritis are observed (1-7). Also included in this list is the autoimmune disease Sjögren's syndrome, based on an amalgamation of manifestations including fatigue and presence of autoantibodies, together with dysfunction of the salivary and lacrimal glands. Sicca complaints (reduction in saliva production) are frequently reported after ICI use, although reports tend to stop short of any detailed consideration of mechanisms lying behind these complaints (2, 3, 8-14). Here we review the current literature concerning prevalence, functional data, pathology and potential causative mechanisms underlying development of sicca complaints following ICI use. We focus on the common ground and striking contrasts between classically presenting Sjögren's syndrome and the 'Sjögren's syndrome' developing when a patient receives ICI therapy. We also emphasise the importance of examining the histology of the major salivary glands, in contrast with the minor SGs reported by most studies, as an insight into the destruction of the glands that provide most of the saliva production after stimulation.

Competing interests: none declared.

Functional SG deterioration following checkpoint inhibitor therapy

In 2017 Cappelli *et al.* commented that the prevalence of sicca complaints following ICI use is unclear (5). Acknowledgement of the effects of ICIs on salivary gland (SG) function is lagging indeed somewhat behind compared to that of other organ systems, perhaps due to a perception that SG malfunction is less traumatic than intestinal manifestations, for example. Lack of SG function, however, reduces patients' quality of life dramatically, via a menagerie of symptoms ranging from loss of sleep, difficulty eating and dental complications (15).

SG dysfunction is often omitted from specific mention of ICI-induced organ pathologies and amalgamated presumably into the gastrointestinal tract category. When specifically stated, however, general reports of adverse events following ICI use quote prevalence of dry mouth complaints in 3–11% of patients (1, 11, 16–18). Severity of sicca complaints in the context of ICI use are graded using the common terminology criteria for adverse events (CTCAE) system, where according to secretion and subjective symptoms SG function is scored from 0 (no decrease in SG function) to 4 (extreme SG dysfunction). Incidence appears to be related to dosage of PD-1/PD-L1 inhibitors, whereby increasing the dosage of nivolumab (anti PD-1 ICI) from 0.3, to 2.0 and 10.0 mg/kg was reflected in dry mouth of CTCAE grade 1–4 prevalence of 3%, 6% and 11% respectively (17). Development of SG dysfunction appears to manifest abruptly, with patients reporting a sudden onset of dry mouth from one day to the next, (time range of 30–206 days, mean of 70 days) (3, 14, 19, 20). This is in contrast to the general clinical picture in classical pSS, where saliva production is widely accepted to deteriorate with time (21). A preliminary study of 4 patients with rheumatological complaints following ICI use (nivolumab, anti-PD-1 and ipilimumab, anti-CTLA4 mono- or combined-therapy) stated that the subjective sensation of dry mouth experienced by the patients could not be attributed to other medication use, and

hence laid the groundwork for the development of this field (2).

Although other studies state 'abnormal oral diagnostic tests' (22), only two studies at time of writing have objectively measured unstimulated whole saliva (UWS) production in patients with sicca complaints post ICI-use. Forty and 95 percent of patients demonstrated a UWS secretion rate under 0.1mL/min, the threshold used by both the 2016 ACR-EULAR criteria for classification of primary Sjögren's syndrome, and the CTCAE scoring system for Grade 3 SG dysfunction (3, 23). In the more detailed study by Warner *et al.* (3) 20 consecutive patients presenting with sicca complaints in the context of ICI therapy were examined. Eight out of these 20 patients were not capable of producing any UWS at all. Citric acid stimulated parotid SG saliva secretion was only possible in 6/20 patients, and in 10/20 and 12/20 respectively from the submandibular and sublingual SGs (3). Interestingly, patients prescribed only anti-PD-L1 ICIs (avelumab), compared to those taking PD-1 ICIs (nivolumab or pembrolizumab), could produce less UWS (0.025 mL/min vs. 0.059 mL/min) (3). A combination of nivolumab and ipilimumab, blocking PD-1 and CTLA-4, respectively, resulted in no UWS secretion capabilities in the 3 patients examined, reflecting presumably a summative effect of the two different sets of ICIs (no patients receiving anti-CTLA-4 therapy alone were examined in this study). We have also examined function of the SG of a patient with dry mouth complaints following 43 weeks of fortnightly treatment with 10mg/kg of anti-PD-L1 ICI durvalumab. At cycle 11 of treatment (22 weeks after initiation), the patient was not capable of producing any stimulated or unstimulated whole or parotid-specific saliva (12).

When patients present with sicca symptoms in the wake of ICI treatment, whether this be anti PD-1, PD-L1 or CTLA-4, it is clear that SG dysfunction can be total, fulfilling the most severe CTCAE grade levels. The most severe degrees of SG dysfunction appear to be related to anti PD-L1 ICI therapy, compared to anti-CTLA-4 or anti-PD-1 therapy.

Histological abnormalities of the glandular tissue following checkpoint inhibitor therapy

Lymphocytic infiltration

In addition to functional SG analysis, several studies have examined the nature of lymphocytic infiltration in minor SGs following ICI use. Minor SGs, contributing 10% to UWS and being important for lubrication of the oral cavity, are widely employed in pSS research as a proxy gland to reflect potential damage to larger SGs. Minor salivary glands of patients with pSS are characterised by the presence of focal lymphocytic sialadenitis (inflammation of the SG). In pSS, these foci are associated with striated ducts. A focus score is usually calculated, whereby the number of clusters of ≥ 50 lymphocytes per 4mm² tissue is used to reflect the degree of lymphocytic infiltration.

General descriptions of the morphology of minor SGs of patients on or having been treated with ICI therapy include interstitial sclerosis, mild-severe lymphocytic sialadenitis, and lymphohistiocytic infiltration (lymphocytes plus phagocytic cells found in connective tissue) (9–11, 14, 19, 22). To this end, two groups demonstrated presence of focal and dispersed CD3⁺ cell rich lymphocytic infiltration in minor SGs post-ICI use, with a tendency for predominance by CD3⁺ T-cells, and varying reports of either CD4⁺ and CD8⁺ T-cell dominance (3, 11, 14). Presence of CD20⁺ B-cells was minimal. The pathological profiles observed by Warner *et al.* (3) in the 20 patients examined could be grouped into 3 categories. Ten out of 20 patients demonstrated non-specific chronic sialadenitis, without foci. Nine out of 20 patients had focal lymphocytic sialadenitis with a positive focus score with respect to criteria for pSS. Of these 9 patients, 6 displayed mild-to-moderate focal lymphocytic sialadenitis and 3 severe, with more injury to the parenchyma. Interestingly, all 3 patients displaying severe focal lymphocytic sialadenitis were within the anti-PD-L1 (avelumab) treatment group, which was also associated with lower UWS production compared to anti-PD-1 and anti-CTLA-4 combination therapy.

Table I.

Authors	Number of patients	Proportion with hyposalivation	Minor SG biopsy infiltration	Minor SG biopsy parenchyma	Major SG biopsy infiltration	Major SG parenchyma	Hypoechoic regions	Results compared with other diseases
Cappelli (2)	4	4 / 4	ND	ND	ND	ND	1 / 4	ND
Calabrese (8)	15	5/15	ND	ND	ND	ND	ND	ND
Burel (9)	4	2 / 4	1 / 4 lymphocytic (CTCAE v4.0 ≥ 3)	ND sialadenitis (FS=1)	ND	ND	ND	ND
Takahashi (19)	1	1 / 1 ^{**}	lymphocytic inflammation. no focus score reported	'exfoliation of the epithelium, enlargement of glands with mucous retention, and disappearance of acini'	ND	ND	0 / 1	ND
Ghosn (10)	1	ND	interstitial sclerosis, FS=1, T-cell based	ND	ND	ND	ND	ND
Narváez (20)	2	2 / 2 ^{***}	ND	ND	ND	ND	ND	ND
Warner (3)	20	20 / 20	19 / 20 with either mild (FS=0), mild-moderate (FS=1-2) or severe sialadenitis (FS 8 & 12).	In mild-moderate ialadenitis: atrophy, fibrosis. In severe ialadenitis: injury to ducts and acinar s s cells, fibrosis, acinar cell atrophy	ND	ND	4 / 20	healthy volunteer, pSS
Ramos-Casal (22)	26	12 / 14 (ND for 12)	8/15 with mild chronic sialadenitis (FS=0), 7/15 with focal lymphocytic sialadenitis (FS1-4). (ND for 11)	ND	ND	ND	ND	pSS
Ortiz Brugués (11)	15	4 / 15 (CTCAE v5.0 ≥ 3)	1 / 15 with CD4 ⁺ T cell-rich infiltration	ND	ND	ND	ND	ND
Pringle (12)	1	1 / 1	ND	ND	T-cell rich infiltration, no clear CD4 ⁺ or CD8 ⁺ bias	Lack of acinar cells. Many ID cells.	0 / 1	sicca control, pSS
Mavragani (13)	1	ND	Mild lymphocytic sialadenitis	ND	ND	ND	ND	Yes [§]
Higashi (14)	1	1 / 1 ^{***}	CD8 ⁺ T cell-rich infiltration	ND	ND	ND	ND	ND

ND: no data; FS: focus score; ID: intercalated duct cells. SSA screening is described in more detail in Table II.

[#]Patient with parotid gland carcinoma; ^{**}Saxon test performed; ^{***}Salivary gland scintigraphy performed; *One biopsy not performed; [§]Clinical presentation compared with classical presentation in pSS, sarcoidosis, IgG4, chronic graft-vs-host disease, and HIV infection.

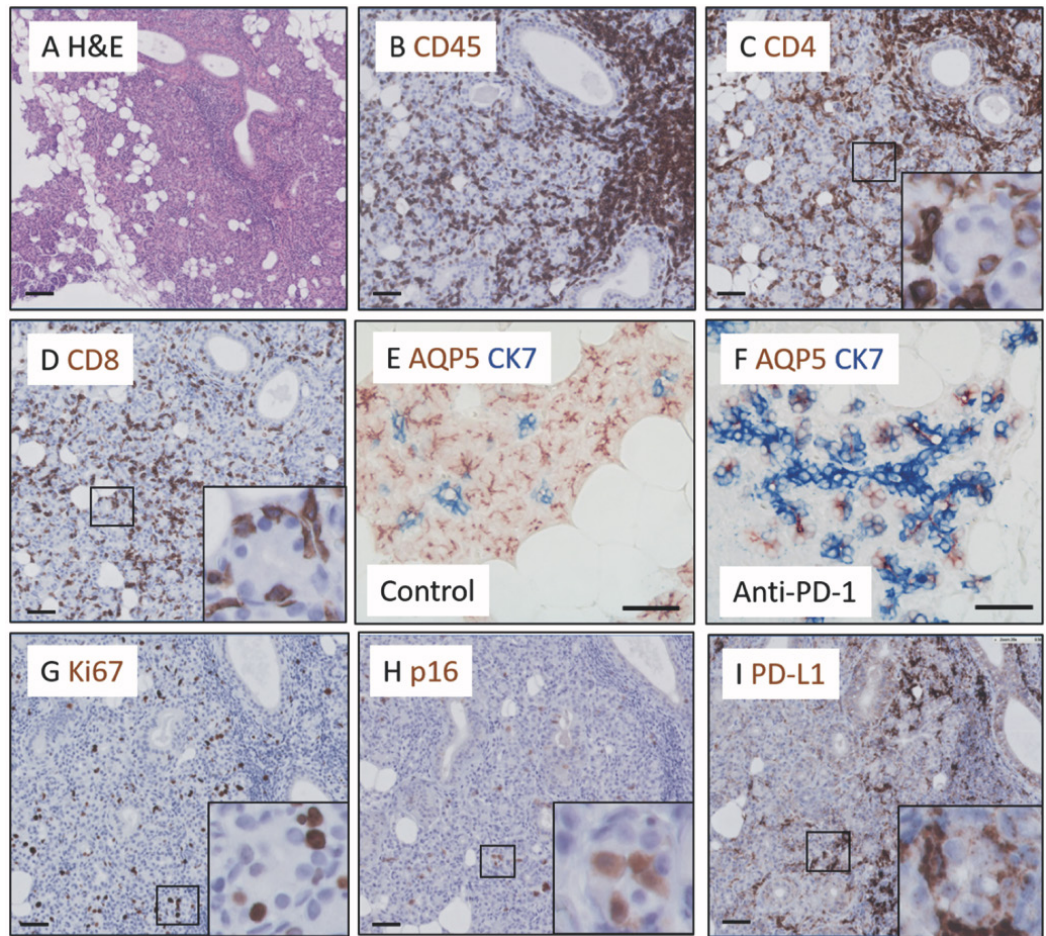
In our case following anti-PD-L1 ICI therapy, the parotid SG parenchyma also demonstrated both focal and dispersed lymphocytic sialadenitis. This infiltration was, similarly to Warner *et al.* (3), predominated by CD3⁺ cells. Focal infiltration tended to be localised periductally, in a similar manner to pSS. Dispersed CD4⁺ or CD8⁺ cells were also noted both between and inside parenchymal tissue. Only relatively few B-cells were present and intraepithelial B-cells, in pSS associated with forma-

tion of lymphoepithelial lesions, were not found (12). Also, other B-cell associated histopathological features seen in pSS glands, *i.e.* germinal centres and IgG plasma cells, were all absent in patients who developed sicca complaints on ICI therapy (12). Examination of a parotid SG following anti PD-1 therapy using pembrolizumab suggested a similar pattern of T-cell rich lymphocytic infiltration of the major SGs (Figure 1A-D). CD20⁺ B-cells were again only present in small numbers, in continued

contrast to what is commonly seen in pSS.

Summarising the basic observations until now, we can conclude that ICI therapy can induce extensive SG dysfunction, and that the affected minor or major SGs are likely to contain CD3⁺ cell rich (focal) lymphocytic infiltration, in differing graduations of pathology. In order to comprehend how this damage is manifest, we must also probe the functional parenchyma of the SG.

Fig. 1. Parotid SG parenchyma from patient with severe hyposalivation following anti PD-1 ICI therapy displays similar phenotype to that following PD-L1 therapy. **A:** H&E overview of SG morphology. **B:** CD45 Immunostaining. **C:** CD4 immunostaining. **D:** CD8 immunostaining. **E:** Ki67 immunostaining (marker of proliferation). **F:** p16 immunostaining (marker of senescence). **G:** PD-L1 immunostaining. **H:** Patterning of AQP5 and CK7 immunostaining in control parotid SG. **I:** AQP5 and CK7 immunostaining in parotid SG following anti PD-1 ICI therapy. Scale bars represent 50 μ m.



Lack of conventional acinar cells following checkpoint inhibitor use

SGs are comprised of several cell types. Acinar cells produce and secrete saliva. Secretion is facilitated by myoepithelial cells surrounding the acini and channeled through small intercalated ducts, larger striated ducts and finally through excretory ducts into the mouth. Complementing these cell types and critical for the SG function are resident SG progenitor cell populations (SGPCs) in the salivary gland parenchyma. SGPCs proliferate and differentiate into fresh acinar cells, to replenish exhausted ones, and have been suggested to reside in the basal layer of the striated duct and intercalated ducts, in addition to within the acinar cell compartment itself (24-32). If, therefore, substantial and persistent damage to the functionality of SGs is observed, logic may suggest that one of the progenitor cell populations of the SGs has been compromised. In pSS, for example, we suggest that the basal striated duct compartment, comprising

SGPCs, becomes senescent, diminishing the ability of the SG to regenerate its parenchyma, and ageing the SG prematurely (27, 33).

Although difficult to interpret due to the lack of high resolution microscopy in the article, Warner *et al.* (3) state that in that patients demonstrating severe sialadenitis of the minor SGs evidence of damaged epithelial cells ('injury to the ducts and acini, nuclear enlargement, anisonucleosis, and irregular distribution, apoptosis, fibrosis, luminal mucin inspissation, and rupture mucin extravasation') was observed (3). Latter the authors also stated that patients displaying non-specific chronic sialadenitis also showed evidence suggesting acinar cell atrophy (3). In our recent case report, and considering the more advanced knowledge about the progenitor populations of parotid SGs compared to minor SGs, we examined in detail the parenchyma of the parotid SG following ICI use, together with that of a sicca control and pSS patient (12). Strik-

ingly, we observed a total lack of conventional acinar cells, normally easily recognisable due to their characteristic large cytoplasmic to nuclear ratio and immunohistologically by apical membrane AQP5 positivity and absence of cytokeratin (CK) 7(12). CK7, under the correct conditions, can be used in a healthy parotid SG to demarcate intercalated ducts. The salivary gland parenchyma following anti-PD-L1 therapy was dominated by hybrid structures, composed of mixture of AQP5⁺ cells and CK7⁺ cells, with no classical acinar cell morphology. These hybrid structures also sometimes contained AQP5/CK7 double positive cells, appeared proliferative (Ki67⁺) and to some extent senescent, as reflected by their staining for p16. We also observed CD4⁺ T-cells and CD8⁺ T-cells within and in-between these unusual parenchyma organisations. Interestingly, expression of PD-L1 itself by the SG epithelium was upregulated following anti-PD-L1 immunotherapy, most noticeably

in the AQP5⁺CK7⁺ hybrid structures. No PD-L1 expression was observed in control sicca SG tissue and in SG tissue from a pSS patient, suggesting that PD-L1 expression is not upregulated in all inflammatory SG environments. Examination of a second SG biopsy, this time following PD-1 blockade using pembrolizumab, also showed a similar parenchyma phenotype, with a lack of recognisable acinar cells and a skewing of the parenchyma towards hybrid AQP5⁺, CK7⁺ mixed structures (Fig. 1E, F). Similar to the phenotype post PD-L1 ICI use, proliferative (Ki67⁺) and potentially senescent (p16⁺) epithelial cells were also observed, as was PD-L1 expression (Fig. 1G-I). Returning to minor SGs and upon closer examination of the histology as judged by H&E staining reported, two studies also suggest ‘disappearance’ of normal acinar cells following ICI use, suggesting perhaps a common mechanism for lack of saliva production between major and minor glands (10, 19).

Ultrasound SG abnormalities following ICI use

In recent years, ultrasound is increasingly used to detect abnormalities of SGs in pSS. Hypoechoic SG region presence correlates well with SG functional parameters and disease scores, although it remains unclear what these hypoechoic regions represent (34-36). A putative explanation may be loosening of inter-epithelial cell connections as a consequence of proinflammatory cytokine effect on tight junctions (33). This increase in permeability may result in leakage of liquid, causing less reflection of waves. Hypoechoic regions have also been detected in major SGs following ICI use, whereby in one study astonishingly up to 50% of the SG was occupied with such hypoechogenic lesions (2). Warner *et al.* (3) reported ‘consistent, generally mild ultrasonographic changes in 3 major SGs examined of anti-PD-L1 ICI receiving patients (no patients receiving anti-CTLA-4 were examined). These changes included hyperechogenic bands and scattered hypoechoic lesions. Takahashi *et al.* (3, 19) conversely did not observe any ultrasound abnormali-

Table II.

Authors	Number of patients	Pre-ICI SSA+	Post-ICI SSA+
Calabrese (8)	5	ND	1/5
Burel (9)	2	2/2	2/2
Takahashi (19)	1	ND	0/1
Ghosn (10)	1	0/1	1/1
Narvaez (20)	2	ND	0/2
Warner (3)	20	ND	2/20
Ramos-Casal (22)	26	ND	5/25
Ortiz Brugués (11)	15	ND	1/15
Pringle (12)	1	ND	1/1
Higashi (14)	1	ND	0/1

*Both patients SSA⁺ before ICI commencement. N/A: not assessed.

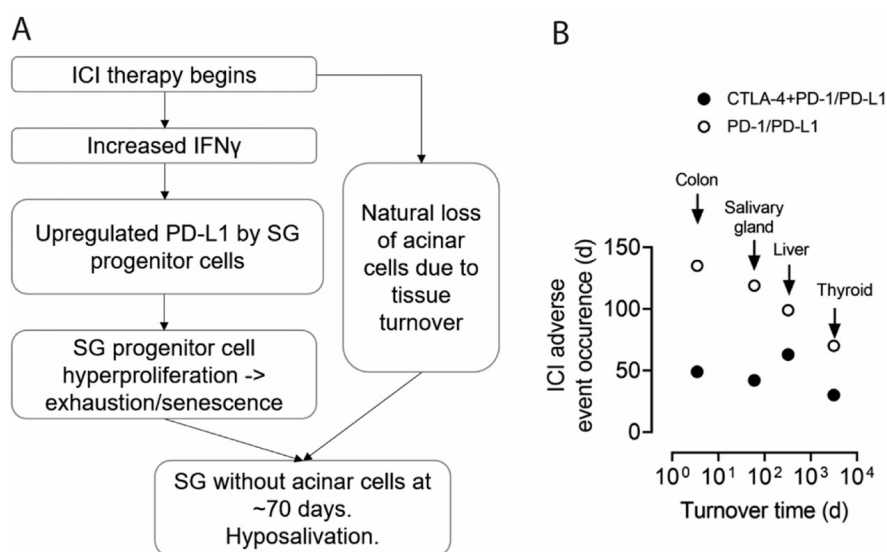


Fig. 2. Schematic of proposed mechanism underpinning SG dysfunction post-ICI therapy, and relation organ dysfunction following ICI therapy with turnover time of each organ.

A: Schematic; B: Data amalgamated from references (3, 54-59).

ties after ICI anti-PD-1 treatment. Our own observations following anti-PD-L1 therapy revealed a moderate change in SG topography (HOCEVAR score of 14/48), with a score just below the threshold of 15/48 for a positive result for pSS (34-36).

ICI-induced primary Sjögren’s syndrome

In 2016, the consensus reached by the scientific community led to the generation of the ACR-EULAR criteria for the classification of patients as suffering from pSS. Its advent was intended to minimise discrepancies in classification across research groups and countries, and permit valid, productive comparison of data sets. In order to fulfill the ACR-EULAR 2016 criteria for classification as pSS, a patient with (subjective) sicca complaints should demonstrate either SSA autoantibody presence in serum or a positive focus score in the salivary glands (SGs) (or indeed both), in addition to objectively measured loss of SG and/or tear gland function. The focus score as currently employed does not discriminate between lymphocytic cell types comprising it. In classical pSS, for example, lymphocytic infiltrate is comprised of a majority of B-cells, at least in its advanced stadia (37). As outlined previously, patients experiencing dry mouth following ICI use have been demonstrated to contain lymphocytic foci in their minor and major SGs. Although comprised of a majority of T-cells and not B-cells like we are familiar with in pSS, patients treated with ICIs do demonstrate a positive focus score and reduced saliva production and

fulfil therefore classification criteria for pSS. In a recent report probing of the International ImmunoCancer Registry, 10 /26 patients with sicca complaints following ICI therapy met the ACR/EULAR 2016 classification criteria for Sjögren's syndrome (22). These ICI-treated patients may also demonstrate ocular symptoms (3). There have also been varying reports of SSA autoantibody presence following ICI use. Proportions of anti-SSA positivity appear, however, to be much lower than in 'conventional' pSS, with a rough mean of 33% of patients with ICI-induced SG dysfunction compared to an approximation of 70% of pSS patients (studies summarised in Table II, excluding patients SSA⁺ previous to ICI use, and including all case studies). Other studies suggest that although ANA antibodies in general may be detected, they are mostly not SSA in subtype (2, 5, 18). ICI-induced SG dysfunction does also not appear to resemble clinical presentation observed following HIV infection, chronic graft-versus-host disease, sarcoidosis, or IgG4-related disease, when examined in minor SGs at least (13). SSA-positivity in a small proportion of patients may thus also, in addition to presence of immune foci, contribute to patient classification after ICI usage as pSS. As the number of patients fulfilling the 2016 ACR-EULAR criteria following ICI use gains mass, an additional consensus may be necessary by the pSS community as to whether these patients should be actively included or excluded from studies centering on pSS patients and treated with a different strategy.

ICI-induced sicca syndrome: a type II interferonopathy?

For the desired immune response against tumor cells in ICI therapy, cytotoxic CD8⁺ T-cells play a crucial role, supported by CD4⁺ T-cells. An important cytokine in these anti-tumor responses is IFN γ , secreted by CD4⁺ Th1 cells and CD8⁺ T-cells, amongst others. Serum levels of IFN γ following ICI therapy increase, presumably from activation of IFN γ -producing T-cells, and indeed a greater 'interferon-signature' post-ICI use has been suggested to pre-

dict response to ICI therapy (38–44). Considering that all SGs may be dysfunctional following ICI use, it seems unlikely that IFN γ is produced local to the SGs, and more likely systemically. Whether IFN γ is also elevated and/or produced in the SGs post-ICI use remains to be established. Here we summarise evidence for interactions between IFN γ , PD-L1, the SG epithelium, and consider the possibility that SG dysfunction following ICI use can be considered a type-II 'interferonopathy'.

Interferon- γ and salivary gland epithelial cell death

In pSS, the interferons IFN α and IFN β (type I IFNs) and IFN γ (type II IFN) play a critical role in the pathogenesis. Indeed, an 'interferon signature', referring to activation of genes in peripheral blood and SGs associated with interferon expression, such as MX1, IFIT3, IFI44, has been associated with pSS (45, 46). IFN γ , on which we focus now for its relevance to ICI therapy, has been demonstrated to induce epithelial cell death in intestines and kidney (47, 48). In epithelial cells cultured from minor SGs, IFN γ treatment-induced apoptosis in a dose dependent manner, but also increased expression of HLA-DR, cytoplasmic SSA/Ro, SSB/La, CD80, B-cell activating factor (BAFF), CXCL10 and ICAM-1 by epithelial cells (49–52). In the context of ICI therapy, the enhanced circulating levels of IFN γ , whether before or after immune cell influx into the SG, may potentially also exert the same effect on the SG, as seen in vitro, and contribute to its lack of function. Supporting this theory, the minor SGs following ICI therapy showed evidence of acinar and ductal cell apoptosis (12).

Interferon- γ and protective PD-L1 expression

There is limited literature examining PD-L1 expression in normal tissues. What is available suggests that PD-L1 expression via JAK-STAT signalling is under control of IFN γ , and functions to protect the cell from the apoptotic effects of IFN γ . In our case study, PD-L1 was not expressed in either sicca control or pSS tissues. Interestingly, hybrid

AQP5⁺CK7⁺ SG epithelial structures post-ICI therapy did show PD-L1 expression (12). Increased PD-L1 expression by the SG parenchyma post ICI therapy may thus represent an attempt at protection of the SG parenchyma from IFN γ -mediated damage and play no causative role in the deterioration observed.

Interferon- γ and PD-L1 as mechanism of SG epithelial dysregulation

Theoretically, (IFN γ -induced) PD-L1 expression may facilitate a direct interaction of SG epithelial cells with anti-PD-L1 ICIs. Binding of PD-L1 by its ligand PD-1, expressed by T-cells attracted into the SG has been demonstrated to induce a cascade of transcriptional effects in the PD-L1 expressing cell, albeit demonstrated to date mainly in cancerous cells. This phenomenon has been termed 'reverse signalling' (53). Downstream transcriptional effects include increased PD-L1⁺ cell survival and proliferation, leading to the aforementioned protective effects of PD-L1. These effects were reported to be facilitated via activation of the MAPK pathway and increased mitochondrial oxygen consumption (53). It is feasible that in the context of elevated IFN γ and PD-L1 expression levels in the SG epithelium post-ICI use, that the SG is ripened for binding interactions with anti-PD-L1 ICIs. Whether anti-PD-L1 ICIs are capable of inducing reverse signalling and thus contribute to epithelial proliferation, remains to be investigated. Some anti-PD-L1 ICIs, for example durvalumab, are engineered to be incapable of initiating antibody-dependent cytotoxicity, eliminating this in some cases as mechanism for epithelial cell damage. To our knowledge, no studies have yet examined PD-L1 expression in other affected tissues post-ICI use, for example the intestine or thyroid, as such there is no precedent to refer to.

A theory for ICI-induced SG dysfunction

We hypothesise that malfunction of SGs following ICI use may arise from a combination of the intrinsic turnover time of human SGs, and IFN γ /PD-L1

interference with this process (schematically represented Figure 2A). Increased IFN γ in the SG as a result of effector T-cell activation during ICI therapy may increase the PD-L1 expression in the SG parenchyma, including acinar cells but also SG progenitor cell compartments. According to the parenchymal phenotype we observed, this would most likely be the intercalated ductal (ID) progenitor cell compartment. Engagement of PD-L1 expressed on these ID-like cells may induce their proliferation ('reverse signalling'). Meanwhile, saliva-producing acinar cells reach the end of their natural approximate 60-70-day lifespan ('tissue turnover time') and die (54). In a healthy SG, fresh waves of acinar cells generated from progenitor cells replace these depleted stocks, and saliva production continues. Following ICI therapy, the hyper-proliferative state of the ID progenitor cell compartment may induce their premature exhaustion (senescence), and inability to fully differentiate into acinar cells. This theory agrees with the abrupt presentation of SG malfunction complaints clinically, usually around 60-70 days, falling neatly within the approximate turnover time of human SG parenchymal cells. Indeed, a negative trend between tissues turnover times and timing of ICI-induced organ dysfunction in the colon, SG, liver and thyroid can be observed when amalgamating previously published data (Fig. 2B) (3, 54-59). Defining a resemblance of order of events of organ dysfunction following ICI use, including a theory for the presence of lymphocytic infiltration which we have not addressed, will require either in vitro modelling, perhaps using organoids, or availability of biopsy samples at earlier time points following ICI therapy.

Aetiopathogenesis of sicca complaints after ICI usage: Sjögren's syndrome or not?

Considerable hope is vested in the application of ICIs for treatment of cancer. At the time of writing, more than 300 trials were registered on the clinicaltrials.gov website, employing ICIs to tackle their respective cancer types. Although meticulous attention is paid to the thorough inventorising of ICI-

induced adverse immune events, by no means as much energy has been driven into understanding how these pathologies are manifested. The question remains whether an ICI-induced hyposalivation should be considered as pSS or not, considering the substantial differences in clinical presentation between the two patient groups. Lymphocytic infiltration is T-cell predominated post-ICI use, as opposed to B-cell dominated in pSS in its advanced stages. The SG following ICI therapy does not appear to present with germinal centres, lymphoepithelial lesions, or antibody class switching, like those observed in classical pSS. SGs following ICI-therapy may also demonstrate a loss of conventional acinar cells, again opposed to SGs in classical pSS, where acinar cells remain clearly present (but not apparently functional). SSA autoantibody presence is also much more prevalent in classical pSS patients, compared to those following ICI administration. As it stands now, the data indicate that ICI-induced sicca complaints should be considered to represent a different disease entity. In order to envisage appropriate management strategies for these new and startling pathologies develop, we must first address the mechanisms underpinning them.

References

- MICHOT JM, BIGENWALD C, CHAMPIAT S *et al.*: Immune-related adverse events with immune checkpoint blockade: a comprehensive review. *Eur J Cancer* 2016; 54: 139-48.
- CAPPELLI LC, GUTIERREZ AK, BAER AN *et al.*: Inflammatory arthritis and sicca syndrome induced by nivolumab and ipilimumab. *Ann Rheum Dis* 2017; 76: 43-50.
- WARNER BM, BAER AN, LIPSON EJ *et al.*: Sicca syndrome associated with immune checkpoint inhibitor therapy. *Oncologist* 2019; 24: 1259-69.
- TOCUT M, BRENNER R, ZANDMAN-GODDARD G: Autoimmune phenomena and disease in cancer patients treated with immune checkpoint inhibitors. *Autoimmun Rev* 2018; 17: 610-6.
- CAPPELLI LC, GUTIERREZ AK, BINGHAM CO, SHAH AA: Rheumatic and musculoskeletal immune-related adverse events due to immune checkpoint inhibitors: a systematic review of the literature. *Arthritis Care Res* 2017; 69: 1751-63.
- BRAHMER JR, TYKODI SS, CHOW LQM *et al.*: Safety and activity of anti-PD-L1 antibody in patients with advanced cancer. *N Engl J Med* 2012; 366: 2455.
- BOUTROS C, TARHINI A, ROUTIER E *et al.*:

- Safety profiles of anti-CTLA-4 and anti-PD-1 antibodies alone and in combination. *Nat Rev Clin Oncol* 2016; 13: 473-86.
- CALABRESE C, KIRCHNER E, KONTZIAS K, VELCHETI V, CALABRESE LH: Rheumatic immune-related adverse events of checkpoint therapy for cancer: Case series of a new nosological entity. *RMD Open* 2017; 3.
- LE BUREL S, CHAMPIAT S, ROUTIER E *et al.*: Onset of connective tissue disease following anti-PD1/PD-L1 cancer immunotherapy. *Ann Rheum Dis* 2018; 77: 468-70.
- GHOSN J, VICINO A, MICHIELIN O, COUKOS G, KUNTZER T, OBEID M: A severe case of neuro-Sjögren's syndrome induced by pembrolizumab. *J Immunother Cancer* 2018; 6: 110.
- ORTIZ BRUGUÉS A, SIBAUD V, HERBAULT-BARRÉS B *et al.*: Sicca Syndrome Induced by Immune Checkpoint Inhibitor Therapy: Optimal Management Still Pending. *Oncologist* 2020; 25: e391-5.
- PRINGLE S, VAN DER VEGT B, WANG X *et al.*: Lack of conventional acinar cells in parotid salivary gland of patient taking an anti-PD-L1 immune checkpoint inhibitor. *Front Oncol* 2020; 10: 420.
- MAVRAGANI CP, MOUTSOPOULOS HM: Sicca syndrome following immune checkpoint inhibition. *Clin Immunol* 2020; 217: 108497.
- HIGASHI T, MIYAMOTO H, YOSHIDA R *et al.*: A case of Sjögren's syndrome as an immune-related adverse event of nivolumab treatment for gastric cancer. *Intern Med* 2020, Jun 23.
- SREEBNY LM: The causes of dry mouth: a broad panoply. In: SREEBNY LM, VISSINK A (Eds.): *Dry Mouth The Malevolent Symptom: A Clinical Guide*. First Ed., Iowa, USA, Blackwell Publishing; 2010.
- TOPALIAN SL, SZNOL M, MCDERMOTT DF *et al.*: Survival, durable tumor remission, and long-term safety in patients with advanced melanoma receiving nivolumab. *J Clin Oncol* 2014; 32: 1020-30.
- MOTZER RJ, RINI BI, MCDERMOTT DF *et al.*: Nivolumab for metastatic renal cell carcinoma: results of a randomized phase II trial. *J Clin Oncol* 2015; 33: 1430-7.
- CALABRESE LH, CALABRESE C, CAPPELLI LC: Rheumatic immune-related adverse events from cancer immunotherapy. *Nat Rev Rheumatol* 2018; 14: 569-79.
- TAKAHASHI S, CHIEKO X, SAKAI T, HIROSE S, NAKAMURA M: Nivolumab-induced sialadenitis. *Respirol Case Rep* 2018; 6: e00322.
- NARVÁEZ J, JUAREZ-LÓPEZ P, LLUCH J *et al.*: Rheumatic immune-related adverse events in patients on anti-PD-1 inhibitors: Fasciitis with myositis syndrome as a new complication of immunotherapy. *Autoimmun Rev* 2018; 17: 1040-5.
- PIJPE J, KALK WWI, BOOTSMA H, SPIJKER-ERVET FKL, KALLENBERG CGM, VISSINK A: Progression of salivary gland dysfunction in patients with Sjögren's syndrome. *Ann Rheum Dis* 2007; 66: 107-12.
- RAMOS-CASALS M, MARIA A, SUÁREZ-ALMAZOR ME *et al.*: Sicca/Sjögren's syndrome triggered by PD-1/PD-L1 checkpoint inhibitors. Data from the International Im-

- munoCancer Registry (ICIR). *Clin Exp Rheumatol* 2019; 37 (Suppl. 118): S114-22.
23. SHIBOSKI CH, SHIBOSKI SC, SEROR R *et al.*: 2016 American College of Rheumatology/European League Against Rheumatism classification criteria for primary Sjögren's syndrome: A consensus and data-driven methodology involving three international patient cohorts. *Ann Rheum Dis* 2017; 76: 9-16.
 24. PRINGLE S, NANDURI LSY, VAN DER ZWAAG M, VAN OS R, COPPES RP: Isolation of mouse salivary gland stem cells. *J Vis Exp*.2011; 48: 9-10.
 25. NANDURI LSY, MAIMETS M, PRINGLE SAA, VAN DER ZWAAG M, VAN OS RPP, COPPES RPP: Regeneration of irradiated salivary glands with stem cell marker expressing cells. *Radiother Oncol* 2011; 99: 367-72.
 26. PRINGLE S, MAIMETS M, VAN DER ZWAAG M *et al.*: Human salivary gland stem cells functionally restore radiation damaged salivary glands. *Stem Cells* 2016; 34: 640-52.
 27. PRINGLE S, WANG X, VERSTAPPEN GMPJ *et al.*: Salivary gland stem cells age prematurely in primary Sjögren's syndrome. *Arthritis Rheumatol* 2019; 71: 133-42.
 28. VAN LUIJK P, PRINGLE S, DEASY JO *et al.*: Sparing the region of the salivary gland containing stem cells preserves saliva production after radiotherapy for head and neck cancer. *Sci Transl Med* 2015; 7: 305ra147-305ra147.
 29. KNOX SM, LOMBAERT IMA, REED X, VITALE-CROSS L, GUTKIND JS, HOFFMAN MP: Parasympathetic innervation maintains epithelial progenitor cells during salivary organogenesis. *Science* 2010; 329: 1645-7.
 30. EMMERSON E, MAY A, NATHAN S *et al.*: SOX2 regulates acinar cell development in the salivary gland. *Elife* 2017; 6: e26620.
 31. AURE MH, KONIECZNY SF, OVITT CE: Salivary gland homeostasis is maintained through acinar cell self-duplication. *Dev Cell* 2015; 33: 231-7.
 32. WENG P-L, AURE MH, MARUYAMA T, OVITT CE: Limited regeneration of adult salivary glands after severe injury involves cellular plasticity. *Cell Rep* 2018;24(6):1464-1470. e3.
 33. WANG X, BOOTSMA H, TERPSTRA J *et al.*: Progenitor cell niche senescence reflects pathology of the parotid salivary gland in primary Sjögren's syndrome. *Rheumatology* 2020 Mar 11.
 34. VAN NIMWEGEN JF, MOSSEL E, DELLI K *et al.*: Incorporation of salivary gland ultrasonography into the ACR-EULAR criteria for primary Sjögren's syndrome. *Arthritis Care Res* 2020; 74: 583-90.
 35. MOSSEL E, DELLI K, VAN NIMWEGEN JF *et al.*: The parotid gland connection: ultrasound and biopsies in primary Sjögren's syndrome. *Ann Rheum Dis* 2018;77: 212331.
 36. MOSSEL E, DELLI K, VAN NIMWEGEN JF *et al.*: Ultrasonography of major salivary glands compared with parotid and labial gland biopsy and classification criteria in patients with clinically suspected primary Sjögren's syndrome. *Ann Rheum Dis* 2017; 76: 1883-9.
 37. KROESE FG, ABDULAHAD WH, HAACKE E, BOS NA, VISSINK A, BOOTSMA H: B-cell hyperactivity in primary Sjögren's syndrome. *Expert Rev Clin Immunol* 2014; 10: 483-99.
 38. HIGGS BW, MOREHOUSE CA, STREICHER K *et al.*: Interferon gamma messenger RNA signature in tumor biopsies predicts outcomes in patients with non-small-cell lung carcinoma or urothelial cancer treated with durvalumab. *Clin Canc Res* 2018; 17: 3451.
 39. DARVIN P, TOOR SM, SASIDHARAN NAIR V, ELKORD E: Immune checkpoint inhibitors: recent progress and potential biomarkers. *Exp Mol Med* 2018; 50: 1-11.
 40. KARACHALIOU N, GONZALEZ-CAO M, CRESPINO G *et al.*: Interferon gamma, an important marker of response to immune checkpoint blockade in non-small cell lung cancer and melanoma patients. *Ther Adv Med Oncol* 2018; 1: 10.
 41. CHEN H, LIAKOU CI, KAMAT A *et al.*: Anti-CTLA-4 therapy results in higher CD4+ICOS hi T cell frequency and IFN- γ levels in both nonmalignant and malignant prostate tissues. *Proc Natl Acad Sci USA* 2009; 106: 2729-34.
 42. LIAKOU CI, KAMAT A, TANG DN *et al.*: CTLA-4 blockade increases IFN γ -producing CD4+ICOS hi cells to shift the ratio of effector to regulatory T cells in cancer patients. *Proc Natl Acad Sci USA* 2008; 105: 14987-92.
 43. DULOS J, CARVEN GJ, VAN BOXTEL SJ *et al.*: PD-1 blockade augments Th1 and Th17 and suppresses Th2 responses in peripheral blood from patients with prostate and advanced melanoma cancer. *J Immunother* 2012; 35: 169-78.
 44. PENG W, LIU C, XU C *et al.*: PD-1 blockade enhances T-cell migration to tumors by elevating IFN- γ inducible chemokines. *Cancer Res* 2012; 72: 5209-18.
 45. IMGEBERG-KREUZ J, SANDLING JK, ALMLÖF JC *et al.*: Genome-wide DNA methylation analysis in multiple tissues in primary Sjögren's syndrome reveals regulatory effects at interferon-induced genes. *Ann Rheum Dis* 2016; 75: 2029-36.
 46. NEZOS A, GRAVANI F, TASSIDOU A *et al.*: Type I and II interferon signatures in Sjögren's syndrome pathogenesis: Contributions in distinct clinical phenotypes and Sjögren's related lymphomagenesis. *J Autoimmun* 2015; 63: 47-58.
 47. OSAKI LH, BOCKERSTETT KA, WONG CF *et al.*: Interferon- γ directly induces gastric epithelial cell death and is required for progression to metaplasia. *J Pathol* 2019; 247: 513-23.
 48. COERS W, VOS JTWM, MEIDE PH, HORST MLC, HUITEMA S, WEENING JJ: Interferon-gamma (IFN- γ) and IL-4 expressed during mercury-induced membranous nephropathy are toxic for cultured podocytes. *Clin Exp Immunol* 2008; 102: 297-307.
 49. ABU-HELU RF, DIMITRIOU ID, KAPSO-GEORGOU EK, MOUTSOPOULOS HM, MANOUSSAKIS MN: Induction of salivary gland epithelial cell injury in Sjögren's syndrome: in vitro assessment of T cell-derived cytokines and fas protein expression. *J Autoimmun* 2001; 17: 141-53.
 50. TSUNAWAKI S, NAKAMURA S, OHYAMA Y *et al.*: Possible function of salivary gland epithelial cells as nonprofessional antigen-presenting cells in the development of Sjögren's syndrome. *J Rheumatol* 2002; 29: 1884-96.
 51. BROOKES SM, PRICE EJ, VENABLES PJW, MAINI RN: Interferon-gamma and epithelial cell activation in Sjögren's syndrome. *Rheumatology* 1995; 34: 226-31.
 52. HA Y-J, CHOI YS, KANG EH *et al.*: Increased expression of interferon- λ in minor salivary glands of patients with primary Sjögren's syndrome and its synergic effect with interferon- α on salivary gland epithelial cells. *Clin Exp Rheumatol* 36 (Suppl. 112): S31-40.
 53. JALALI S, PRICE-TROSKA T, BOTHUN C *et al.*: Reverse signaling via PD-L1 supports malignant cell growth and survival in classical Hodgkin lymphoma. *Blood Cancer J* 2019; 9: 22.
 54. SEIMI MA S, GLADYSHEV VN: Gene expression signatures of human cell and tissue longevity. *Aging Mech Dis* 2016; 2: 16014.
 55. GEUKES FOPPEN MH, ROZEMAN EA, VAN WILPE S *et al.*: Immune checkpoint inhibition-related colitis: symptoms, endoscopic features, histology and response to management. *ESMO Open* 2018; 3: e000278.
 56. FERRARI SM, FALLAHI P, GALETTA F, CITI E, BENVENGA S, ANTONELLI A: Thyroid disorders induced by checkpoint inhibitors. *Rev Endocr Metab Disord* 2018; 19: 325-33.
 57. HAANEN JBAG, CARBONNEL F, ROBERT C *et al.*: Management of toxicities from immunotherapy: ESMO Clinical Practice Guidelines for diagnosis, treatment and follow-up. *Ann Oncol* 2017; 28: 119-42.
 58. SANJEEVAIAH A, KERR T, BEG MS: Approach and management of checkpoint inhibitor-related immune hepatitis. *J Gastrointest Oncol* 2018; 9: 220-4.
 59. EIGENTLER TK, HASSEL JC, BERKING C *et al.*: Diagnosis, monitoring and management of immune-related adverse drug reactions of anti-PD-1 antibody therapy. *Cancer Treat Rev* 2016; 45: 7-18.