

University of Groningen

## Afatinib in Osimertinib-Resistant EGFR ex19del / T790M / P794L mutated Non-Small Cell Lung Cancer

van Kempen, Léon C; Wang, Hangjun; Aguirre, Maria Leonor; Spatz, Alan; Kasymjanova, Goulnar; Vilacha, Juliana F; Groves, Matthew R; Agulnik, Jason; Small, David

*Published in:*  
Journal of Thoracic Oncology

*DOI:*  
[10.1016/j.jtho.2018.04.020](https://doi.org/10.1016/j.jtho.2018.04.020)

**IMPORTANT NOTE: You are advised to consult the publisher's version (publisher's PDF) if you wish to cite from it. Please check the document version below.**

*Document Version*  
Publisher's PDF, also known as Version of record

*Publication date:*  
2018

[Link to publication in University of Groningen/UMCG research database](#)

*Citation for published version (APA):*

van Kempen, L. C., Wang, H., Aguirre, M. L., Spatz, A., Kasymjanova, G., Vilacha, J. F., Groves, M. R., Agulnik, J., & Small, D. (2018). Afatinib in Osimertinib-Resistant EGFR ex19del / T790M / P794L mutated Non-Small Cell Lung Cancer. *Journal of Thoracic Oncology*, 13(9), E161-E163.  
<https://doi.org/10.1016/j.jtho.2018.04.020>

### Copyright

Other than for strictly personal use, it is not permitted to download or to forward/distribute the text or part of it without the consent of the author(s) and/or copyright holder(s), unless the work is under an open content license (like Creative Commons).

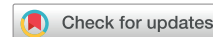The publication may also be distributed here under the terms of Article 25fa of the Dutch Copyright Act, indicated by the "Taverne" license. More information can be found on the University of Groningen website: <https://www.rug.nl/library/open-access/self-archiving-pure/taverne-amendment>.

### Take-down policy

If you believe that this document breaches copyright please contact us providing details, and we will remove access to the work immediately and investigate your claim.

Downloaded from the University of Groningen/UMCG research database (Pure): <http://www.rug.nl/research/portal>. For technical reasons the number of authors shown on this cover page is limited to 10 maximum.

# Afatinib in Osimertinib-Resistant *EGFR* ex19del/T790M/P794L Mutated NSCLC



Léon C. van Kempen, PhD,<sup>a,b,c</sup> Hangjun Wang, MD,<sup>a</sup> Maria Leonor Aguirre, BSc,<sup>b</sup> Alan Spatz, MD,<sup>a,b</sup> Goulnar Kasymjanova, MD,<sup>d,\*</sup> Juliana F. Vilacha, MSc,<sup>e</sup> Matthew R. Groves, PhD,<sup>e</sup> Jason Agulnik, MD,<sup>d</sup> David Small, MD<sup>d</sup>

<sup>a</sup>Department of Pathology, McGill University and OPTILAB-McGill University Health Center, Montreal, Quebec, Canada

<sup>b</sup>Lady Davis Institute for Medical Research, Jewish General Hospital, Montreal, Quebec, Canada

<sup>c</sup>Department of Pathology, Laboratory for Molecular Pathology, University Medical Center Groningen, Groningen, The Netherlands

<sup>d</sup>Peter Brojde Lung Cancer Centre, Segal Cancer Centre, Jewish General Hospital, Montreal, Quebec, Canada

<sup>e</sup>Department of Pharmacy, Structural Biology Unit Drug Design, University of Groningen, Groningen, The Netherlands

Received 12 January 2018; revised 13 April 2018; accepted 20 April 2018  
Available online - 25 April 2018

**Keywords:** Osimertinib; Afatinib; EGFR triple mutation; P794L mutation NSCLC

## Introduction

The *EGFR* p.(T790M) mutation is a frequent mechanism of resistance towards first- (gefitinib, erlotinib) and second- (afatinib) generation *EGFR* inhibitors. The third-generation inhibitor osimertinib requires binding to p.(C797) in the adenosine triphosphate (ATP) binding pocket. Resistance to osimertinib can occur via the mutation of this amino acid, for example, p.(C797S) in cis with p.(T790M). However, other osimertinib-induced *EGFR* mutations have been observed and guidelines for subsequent treatment are lacking.

## Case Report

A 36-year-old life-long nonsmoking Caucasian woman presented in July 2012 with a history of cough and dyspnea on exertion that had persisted for 2 years. She was diagnosed with a T4N2M0 non-small cell adenocarcinoma with an *EGFR* exon 19 deletion. The treatment trajectory and radiological images are shown in [Figures 1](#) and [2](#). After 2 months of treatment with gefitinib, the cancer was restaged as T2aN2M0. A pneumonectomy of the right lung was performed followed by adjuvant chemotherapy/radiation therapy and completed in August 2013. Two months after finishing radiation therapy, a chest computed tomographic (CT) scan revealed multiple small nodules in the left hemithorax. The patient restarted gefitinib until radiologic progression in September 2015. A re-biopsy revealed adenocarcinoma with an *EGFR* exon 19

deletion and a c.2369C>T p.(T790M) mutation. In November 2015 she was enrolled in an osimertinib compassionate-use program until July 2017 when a chest CT showed worsening of the coarse nodular parenchymal opacities. A liquid biopsy for circulating tumor DNA sequencing (TST-15, Illumina, San Diego, California) was obtained and revealed an *EGFR* triple mutation: p.(E746\_S752del) and p.(P794L) in cis with p.(T790M). The p.(P794L) mutation was found in approximately one-third of the reads containing p.(T790M).

The neutral p.(P794L) mutation is located in the hinge region of the ATP cleft and is a known mechanism of resistance towards the discontinued irreversible *EGFR* inhibitor cernetinib.<sup>1</sup> Afatinib is clinically active in many tyrosine kinase inhibitor-pretreated patients with NSCLC harboring uncommon *EGFR* mutations. Heigener et al.<sup>2</sup> have shown some activity of afatinib in patients with tumors carrying T790M and exon 20 insertion mutations. Protein modeling indicated that afatinib can bind the *EGFR* p.(T790M)/p.(P794L) ATP cleft ([Fig 3](#)). The calculated lower binding affinity and higher

\*Corresponding author.

**Disclosures:** The authors declare no conflict of interest.

Address for correspondence: Goulnar Kasymjanova, MD, Peter Brojde Lung Cancer Centre, Segal Cancer Centre, Jewish General Hospital, Montreal H3T 1E2, Quebec, Canada. E-mail: [gkasymja@jgh.mcgill.ca](mailto:gkasymja@jgh.mcgill.ca)

Crown Copyright © 2018 Published by Elsevier Inc. on behalf of International Association for the Study of Lung Cancer. All rights reserved.

ISSN: 1556-0864

<https://doi.org/10.1016/j.jtho.2018.04.020>

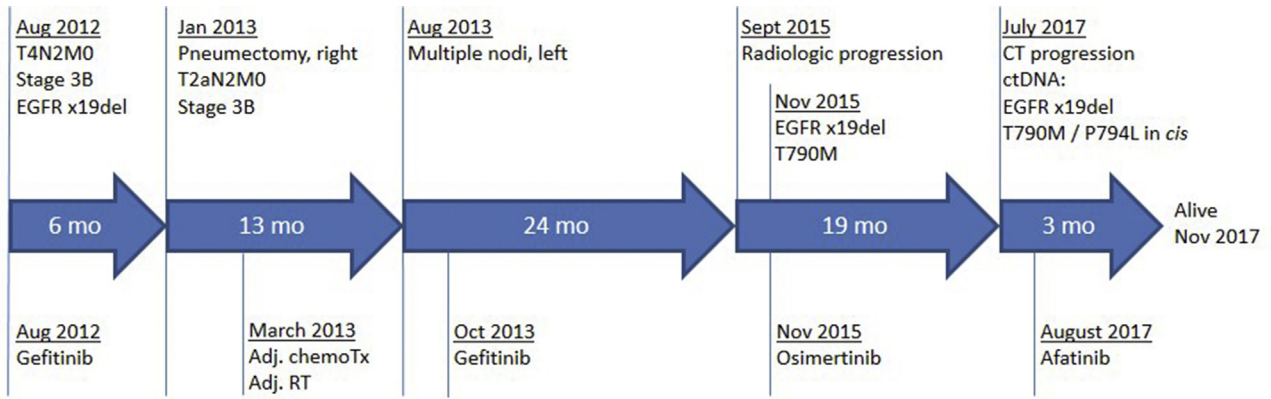


Figure 1. History of treatment. Timeline depicting diagnoses, duration, and changes of treatment.

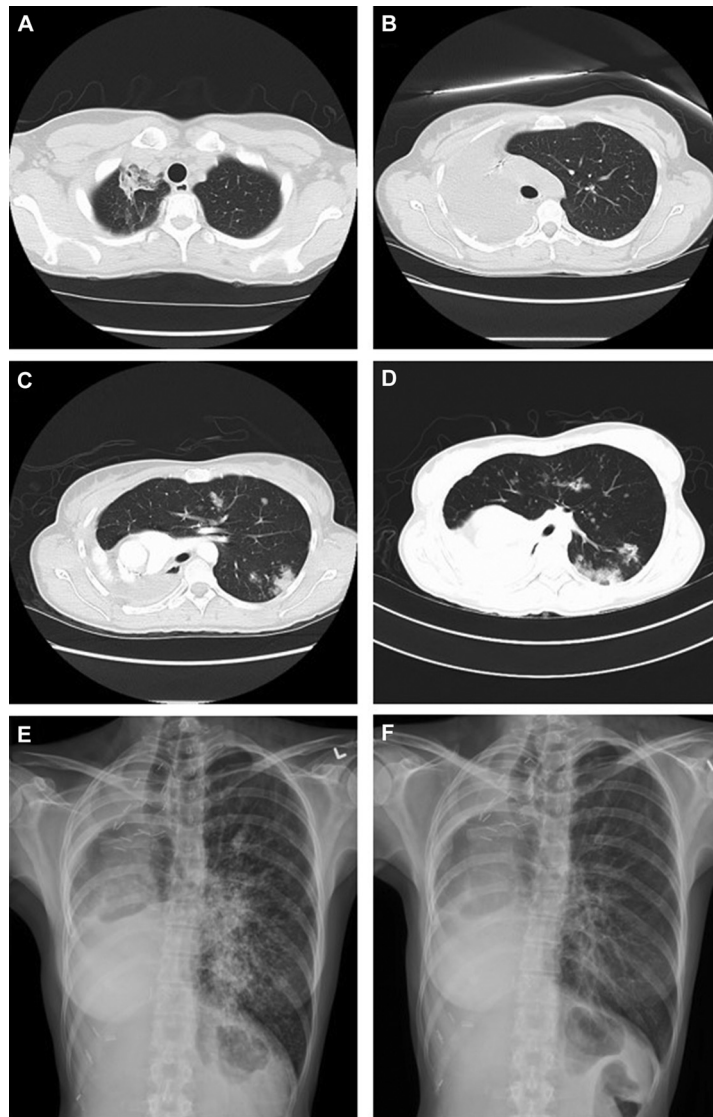
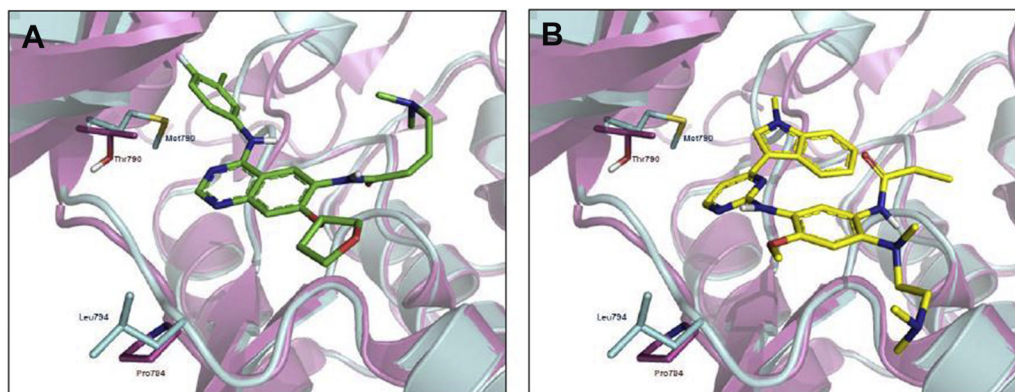


Figure 2. Medical imaging. (A) Computed tomography (CT) scan (November 2012) with a right upper lobe lung mass after 4 months of gefitinib treatment (partial response). Before right pneumonectomy. (B) CTscan (September 2013) after right pneumonectomy and before restarting gefitinib. Interval development of multiple small nodules in the left lung. (C) CT scan (August 2015) before start osimertinib. Multiple small and intermediate size nodules in left lung. (D) CTscan (March 2017) disease progression in left lung. (E) Chest radiograph (July 2017) before start of afatinib. Coarse nodular parenchymal opacities in left lung. (F) Chest radiograph (August 2017) at 1 month on afatinib. Nearly complete reduction of the nodular parenchymal opacities in left lung.



**Figure 3.** Modeling of afatinib and osimertinib binding to EGFR p.(T790M)/p.(P794L). EGFR p.(T790M)/p.(P794L) was built using the PDB file 4I24 structure as a template through the web-based SwissModel server.<sup>5</sup> Docking poses and binding affinity were obtained with Smina, a fork from Autodock Vina.<sup>6</sup> Scorpion score is obtained by the sum of atoms contribution for the network of interactions with the receptor.<sup>7</sup> (A) Afatinib (green) and (B) osimertinib (yellow) are shown to bind to the binding site of the mutant p.(T790M)/p.(P794L) (blue). For comparison, wild-type EGFR is shown in purple (protein data bank code 4WKQ).

**Table 1.** Modeling Calculations for Binding of Afatinib and Osimertinib to EGFR p.(T790M)/p.(P794L)

Compound	Binding Affinity (kcal/mol)	Scorpion Score
Afatinib	-8.5	12.8
Osimertinib	-7.0	9.2

Scorpion score (Table 1) suggests a stronger binding of afatinib to EGFR p.(T790M)/p.(P794L) than osimertinib. Therefore, we hypothesized that the p.(P794L) mutation may not interfere with afatinib binding. The patient started afatinib monotherapy 40 mg daily in August 2017 with a significant clinical and radiologic improvement after 1 month of therapy, and was still alive 6 months after starting on afatinib. There was no need for dose reduction and minimal irritated skin around toenails resolved by applying Emo Cort cream.

## Discussion

Plasma is a valuable source for mutation analysis when a tissue biopsy cannot be procured. The monitoring of circulating DNA can detect different mutations that are responsible for resistance to treatment. The presented case of the tertiary *EGFR* p.(P794L) mutation in cis with p.(T790M) shows a novel osimertinib-resistance mechanism. Strategies for managing osimertinib resistance in general are largely limited to chemotherapy, but combinations of osimertinib with gefitinib or erlotinib have been described for patients who progress under osimertinib because of p.(C797S).<sup>3,4</sup> For our patient who developed osimertinib-resistance via a non-p.(C797S) mechanism, we report a significant clinical and radiologic response to second-generation EGFR inhibitor afatinib, after failing gefitinib and osimertinib during the first and second line of treatment,

respectively. The treatment is well tolerated and continuous partial response to treatment is observed (last visit: 6 months after start of third-line treatment). Our results suggest that afatinib monotherapy has some clinical activity for patients who fail osimertinib due to a tertiary p.(P794L) mutation. However, we cannot exclude that the response might be due to heterogeneous resistance.

## References

- Avizienyte E, Ward RA, Garner AP. Comparison of the EGFR resistance mutation profiles generated by EGFR-targeted tyrosine kinase inhibitors and the impact of drug combinations. *Biochem J*. 2008;415:197-206.
- Heigener DF, Schumann C, Sebastian M, et al. Afatinib in non-small cell lung cancer harboring uncommon EGFR mutations pretreated with reversible EGFR inhibitors. *Oncologist*. 2015;20:1167-1174.
- Arulananda S, Do H, Musafar A, Mitchel P, Dobrovic A, John T. Combination osimertinib and gefitinib in C797S and T790M EGFR-mutated non-small cell lung cancer. *J Thorac Oncol*. 2017;12:1728-1732.
- Wang Z, Yang JJ, Huang J, et al. Lung adenocarcinoma harboring EGFR T790M and in trans C797S responds to combination therapy of first- and third-generation EGFR TKIs and shifts allelic configuration at resistance. *J Thorac Oncol*. 2017;12:1723-1727.
- Biasini M, Bienert S, Waterhouse A, et al. SWISS-MODEL: modelling protein tertiary and quaternary structure using evolutionary information. *Nucleic Acids Res*. 2014;42(Web Server issue):W252-W258.
- Koes DR, Baumgartner MP, Camacho CJ. Lessons learned in empirical scoring with smina from the CSAR 2011 benchmarking exercise. *J Chem Inf Model*. 2013;5:1893-1904.
- Kuhn B, Fuchs JE, Reutlinger M, Stahl M, Taylor NR. Rationalizing tight ligand binding through cooperative interaction networks. *J Chem Inf Model*. 2011;51:3180-3198.