

University of Groningen

**Germinal centres in diagnostic labial gland biopsies of patients with primary Sjogren's syndrome are not predictive for parotid MALT lymphoma development**

Haacke, Erlin A.; van der Vegt, Bert; Vissink, Arjan; Spijkervet, Fred K. L.; Bootsma, Hendrika; Kroese, Frans G. M.

*Published in:*  
Annals of the Rheumatic Diseases

*DOI:*  
[10.1136/annrheumdis-2017-211290](https://doi.org/10.1136/annrheumdis-2017-211290)

**IMPORTANT NOTE: You are advised to consult the publisher's version (publisher's PDF) if you wish to cite from it. Please check the document version below.**

*Document Version*  
Publisher's PDF, also known as Version of record

*Publication date:*  
2017

[Link to publication in University of Groningen/UMCG research database](#)

*Citation for published version (APA):*

Haacke, E. A., van der Vegt, B., Vissink, A., Spijkervet, F. K. L., Bootsma, H., & Kroese, F. G. M. (2017). Germinal centres in diagnostic labial gland biopsies of patients with primary Sjogren's syndrome are not predictive for parotid MALT lymphoma development. *Annals of the Rheumatic Diseases*, 76(10), 1783-1786. <https://doi.org/10.1136/annrheumdis-2017-211290>

**Copyright**

Other than for strictly personal use, it is not permitted to download or to forward/distribute the text or part of it without the consent of the author(s) and/or copyright holder(s), unless the work is under an open content license (like Creative Commons).

The publication may also be distributed here under the terms of Article 25fa of the Dutch Copyright Act, indicated by the "Taverne" license. More information can be found on the University of Groningen website: <https://www.rug.nl/library/open-access/self-archiving-pure/taverne-amendment>.

**Take-down policy**

If you believe that this document breaches copyright please contact us providing details, and we will remove access to the work immediately and investigate your claim.

Downloaded from the University of Groningen/UMCG research database (Pure): <http://www.rug.nl/research/portal>. For technical reasons the number of authors shown on this cover page is limited to 10 maximum.

## CONCISE REPORT

# Germinal centres in diagnostic labial gland biopsies of patients with primary Sjögren's syndrome are not predictive for parotid MALT lymphoma development

Erlin A Haacke,<sup>1,2</sup> Bert van der Vegt,<sup>2</sup> Arjan Vissink,<sup>3</sup> Fred K L Spijkervet,<sup>3</sup> Hendrika Bootsma,<sup>1</sup> Frans G M Kroese<sup>1</sup>

► Additional material is published online only. To view please visit the journal online (<http://dx.doi.org/10.1136/annrheumdis-2017-211290>).

<sup>1</sup>Department of Rheumatology & Clinical Immunology, University of Groningen, University Medical Center Groningen, Groningen, The Netherlands

<sup>2</sup>Department of Pathology and Medical Biology, University of Groningen, University Medical Center Groningen, Groningen, The Netherlands

<sup>3</sup>Department of Oral and Maxillofacial Surgery, University of Groningen, University Medical Center Groningen, Groningen, The Netherlands

## Correspondence to

Dr Erlin A Haacke, Department of Rheumatology & Clinical Immunology, University Medical Center Groningen, Hanzeplein 1 (AA21), 9713 GZ, Groningen, The Netherlands; [e.a.haacke@umcg.nl](mailto:e.a.haacke@umcg.nl)

Received 10 February 2017

Revised 1 June 2017

Accepted 10 June 2017

Published Online First

14 July 2017

## ABSTRACT

**Objective** Patients with primary Sjögren's syndrome (pSS) have an increased risk of developing non-Hodgkin's lymphoma (NHL), particularly parotid gland mucosa-associated lymphoid tissue (MALT) lymphomas. Presence of germinal centres (GCs) in labial gland biopsies has been suggested as predictive factor for NHL. We assessed whether presence of GCs is increased in labial gland biopsies from patients with pSS who developed parotid MALT lymphoma, the dominant NHL-subtype in pSS, compared with patients with pSS who did not develop lymphoma.

**Methods** Eleven labial gland biopsies from patients with pSS that were taken prior to parotid MALT lymphoma development were compared with biopsies of 22 matched pSS controls (1:2) who did not develop lymphoma. Biopsies were evaluated for GCs (H&E and Bcl6).

**Results** Labial gland biopsies of pSS MALT lymphoma patients, revealed GCs in 2/11 (18%) H&E sections and 3/11 (27%) Bcl6 stained sections. In controls, GCs were present in 4/22 (18%) of H&E sections and 5/22 (23%) of Bcl6 stained sections.

**Conclusion** Presence of GCs in labial gland biopsies does not differ between patients with pSS that develop parotid MALT lymphoma and patients with pSS who do not develop lymphoma. The presence of GCs in labial gland biopsies is therefore not a predictive factor for pSS-associated parotid MALT lymphomas.

## INTRODUCTION

Primary Sjögren's syndrome (pSS) is a systemic autoimmune disease, in which salivary and lacrimal glands are affected by a chronic inflammatory process, which leads to dryness of mouth and eyes.<sup>1</sup> Histopathologically, this inflammatory process is characterised by a periductal lymphoid infiltrate in the glandular parenchyma.<sup>2</sup> In roughly one quarter of the patients with pSS, germinal centres (GCs) can be found within these lymphoid infiltrates reflecting the B-cell hyperactivity that characterises the disease.<sup>3,4</sup> Although the clinical significance of these GCs remains to be elucidated, the presence of GCs in the glandular tissue of patients with pSS is generally associated with more severe clinical disease as reflected by a higher focus score (FS), increased presence of anti-SSA/Ro (52 kD + 60 kD) and anti-SSB/La autoantibodies and elevated levels of proinflammatory cytokines in the blood.<sup>3</sup>

A serious complication of pSS is the 5%–10% lifetime risk of developing non-Hodgkin's B-cell lymphomas

(NHL).<sup>5</sup> The most common subtype NHL in pSS is the mucosa-associated lymphoid tissue (MALT) lymphoma.<sup>5–7</sup> These MALT lymphomas preferentially arise in the parotid glands and account for >60% of the lymphomas arising in patients with pSS.<sup>6–8</sup> Which patients with pSS will develop NHL is largely unknown, but several predictors have been identified including disease activity, persistent glandular enlargement, lymphadenopathy, palpable purpura, anti-Ro/anti-La antibodies, rheumatoid factor, lymphopaenia, declined C3 or C4 levels, cryoglobulinaemia and an FS  $\geq 3$  in the labial gland biopsy.<sup>9–11</sup> Presence of GCs in diagnostic labial gland biopsies has also been proposed as a predictive factor for the development of NHL. However, in the study underlying this assumption, all subtypes of NHL were taken into account, including NHL subtypes not typically associated with pSS, such as follicular lymphoma and T-cell lymphoma.<sup>12</sup> For this reason, we explored the predictive role of GCs in labial gland biopsies from patients with pSS for parotid gland MALT lymphomas.

## MATERIALS AND METHODS

### Patients

From 56 patients with pSS diagnosed with parotid MALT lymphoma, we were able to acquire labial gland biopsies of 11 patients taken at diagnosis of pSS, before (median 4.0, IQR 1.5–6.1 years) lymphoma diagnosis (table 1). Labial gland biopsies from 22 pSS patients with an NHL free follow-up (median 12.0, IQR 6.3–16.8 years) served as controls (see online supplementary table S1). Matching of control pSS patients (1:2) was based on age at diagnosis of pSS and the presence of SSA autoantibodies. Patients were frequency-matched within three age groups: patients diagnosed with pSS at an age of  $\leq 40$ , between 40 and 60 and  $\geq 60$  years. All patients were clinically diagnosed as pSS and retrospectively fulfilled the ACR-EULAR (American College of Rheumatology - European League Against Rheumatism) classification criteria<sup>13</sup> at time of diagnosis. Of the 33 included patients, 32 also fulfilled the AECG-criteria at time of diagnosis. Of one pSS patient this is uncertain due to missing sialometry and ocular examination.

### Histopathological assessment of diagnostic salivary gland biopsies

Diagnostic labial salivary gland biopsies were formalin fixed, paraffin embedded and sectioned at 3  $\mu$ m thickness. Serial sections were stained



CrossMark

**To cite:** Haacke EA, van der Vegt B, Vissink A, et al. *Ann Rheum Dis* 2017;**76**:1783–1786.

**Table 1** Patient characteristics and histopathology results of patients with pSS (n=11) developing a parotid MALT lymphoma

Patient	Gender	Age pSS (year)	$\Delta^*$ lymph pSS (year)	Ann Arbor Musshoff	pSS biopsy	FS	CD45 (%)	GC H&E	GC Bcl6	LEL H&E	Anti-SSA	Anti-SSB
1	F	37	3.5	2	Labial	4.0	27.6		–	+	+	+
2	F	60	13.7	1	Labial	0.8	5.3	–	–	–	+	–
3	F	32	4.0	1	Labial	1.1	12.2	–	–	–	+	+
4	F	28	0.2*	1	Labial	0	7.4	–	–	–	+	+
5	F	63	6.1	2	Labial	4.7	38.8	+	+	+	+	–
6	F	47	3.2	2	Labial	1.8	23.4	–	–	+	+	+
7	F	45	0.3*	1	Labial	2.0	34.1	–	+	+	+	+
8	F	67	4.6	1	Labial	0	5.3	–	–	–	+	+
9	F	31	4.0	2	Labial	1.7	20.3	–	–	+	+	+
10	F	51	13.3	3	Labial	2.7	18.2	+	+	+	+	–
11	F	61	1.5	1	Labial	4.0	21.6	–	–	+	+	–

\*Biopsy taken shortly before lymphoma diagnosis. +present. -not present.

$\Delta^*$ Lymph pSS: time between diagnosis of pSS and parotid MALT lymphoma, Ann Arbor Musshoff: (1) localised disease: lymphoma located in one or more salivary glands, (2) locally disseminated: lymphoma localised in one or more salivary glands with one or more enlarged regional lymph nodes (>1 cm), (3) disseminated disease: localisation of lymphoma in one or more salivary glands, with one or more enlarged regional lymph nodes (>1 cm) and/or bone marrow, spleen, liver or other extra nodal site than the salivary gland, or localisation of lymphoma in multiple extra nodal sites.<sup>20</sup>

Bcl6, B cell lymphoma 6; FS, focus score; GC, germinal centre; LEL, lymphoepithelial lesions; MALT, mucosa-associated lymphoid tissue.

with H&E, and immunohistochemically for B-cell lymphoma six protein (Bcl6, clone GI191E/A8, Ventana, Illkirch, France) and CD45 (clone 2B11+PD7/26, Ventana, Illkirch, France). Staining was performed on a Ventana Benchmark platform as previously described.<sup>14</sup> In H&E stained sections, FS, lymphoepithelial lesions (LELs) and GCs were assessed. FS was based on the number of clusters of  $\geq 50$  lymphocytes (foci)/4 mm<sup>2</sup> parenchyma. In case of multiple large confluent foci, an arbitrary FS of 12 was used.<sup>15</sup> LELs were defined as a striated duct with lymphocytes within its basement membrane. GCs were defined as a clearly visible lighter area in a lymphocytic infiltrate containing cells usually present in classical GCs: follicular dendritic cells (FDCs), centrocytes, centroblasts and macrophages. Since detection of GCs is difficult in H&E stained sections, and small GCs may be overlooked,<sup>16</sup> we also evaluated GCs in Bcl6 stained sections. Bcl6 is a transcription factor highly expressed by all GC B-cells. A cluster of  $\geq 5$  adjacent Bcl6<sup>+</sup> cells within a focus was classified as a GC.

Besides FS, we also measured the extent of glandular inflammation as proposed.<sup>2</sup> This was assessed using CD45 staining. CD45 is expressed by all lymphoid and non-lymphoid cells of hematopoietic origin, allowing easy quantification of the relative area of the infiltrate. CD45 expression was measured using ImageScope V.12.0 (Aperio Technologies). Slides were blinded and independently scored by a trained resident (EH) and a dedicated head and neck pathologist (BvdV).

### Statistical analysis

Mann-Whitney U test and Fisher's exact test were used accordingly to test differences between groups (IBM-SPSS Statistics V.23).

### RESULTS

Analysis of H&E stained sections from diagnostic labial gland biopsies, taken prior to parotid MALT lymphoma development, revealed presence of GCs in 2/11 (18%) patients (table 2, online supplementary figure 1). Staining for Bcl6 revealed an extra (small) GC in a biopsy of one additional patient (figure 1, table 2). Thus, in patients with pSS who developed parotid MALT lymphoma, GCs were present in 3/11 (27%) prelymphoma labial gland biopsies. In the patients with pSS that did

not develop parotid MALT lymphomas (nor any other type of NHL), GCs were detected in 4/22 (18%) diagnostic labial gland biopsies in H&E stained sections and in 5/22 (23%) of Bcl6 stained sections (table 2). This proportion was comparable with that seen in patients with pSS who did develop parotid MALT lymphoma.

Since FS  $\geq 3$  has been suggested as predictive factor for NHL development,<sup>9</sup> we compared FS and relative area of CD45<sup>+</sup> infiltrate in prelymphoma labial gland biopsies and biopsies from control pSS patients. FS did not differ between both groups (Mann-Whitney U test,  $p=0.204$ ). The percentage of biopsies with FS  $\geq 3$  was even higher in the control group (36% vs 27%). The relative area of CD45<sup>+</sup> lymphocytic infiltrate, however, tended to be higher in the prelymphoma labial gland biopsies than in the controls (table 2, online supplementary figure 1).

### DISCUSSION

This study shows that the presence of GCs does not differ between diagnostic labial gland biopsies from patients with pSS who did develop parotid MALT lymphoma and patients with pSS who did not develop such lymphoma. In H&E stained sections, we observed an identical percentage of GCs in both categories of patients (18%). With a more sensitive and specific method to identify GCs, viz. staining for the GC B-cell associated transcription factor Bcl6,<sup>16</sup> a slightly higher incidence of GCs was seen in both groups: 27% for patients with prelymphoma and 23% for non-lymphoma pSS patients. Although the two groups of patients with pSS are rather small, the percentages of GCs are similar to those reported for labial gland biopsies among the general pSS population.<sup>3</sup> Based on a large number of studies, Risselada *et al* reported that the mean weighted percentage of GCs in labial gland biopsies of patients with pSS was 25.1% $\pm$ 5.0% (range 18.3%–33%) in H&E stained sections. Since there was no difference in the occurrence of GCs in labial gland biopsies of patients with pSS prior to parotid MALT lymphoma development and the matched pSS controls as well as with the general pSS population, we conclude that presence of GCs in labial biopsies is not likely predictive for parotid MALT lymphoma development.

Other studies that examined the predictive value of GCs in NHL development did not restrict themselves to MALT

**Table 2** Patient characteristics and histological results of diagnostic labial gland biopsies from pSS patients developing parotid MALT lymphomas and control labial gland biopsies

Variable	Labial biopsies prior to parotid MALT lymphoma (n=11)	Labial biopsies from patients with pSS without lymphoma (n=22)	p Value Mann-Whitney U test (MWU) or Fisher's exact test (FT)
Female n (%)	11/11 (100)	20/22 (91)	0.542 (FT)
Age (year), mean (SD)	47.5 (14.0)	48.7 (17.2)	0.638 (MWU)
Anti-SSA positive, n (%)	11/11 (100)	22/22 (100)	-
Anti-SSB positive, n (%)	7/11 (64)	13/22 (59)	1.000 (FT)
Anti-RF positive, n (%)	11/11 (100)	19/22 (86)	0.534 (FT)
Anti-ANA positive, n (%)	11/11 (100)	21/22 (96)	1.000 (FT)
Δ* pSS-lymph (year), median (IQR)	4.0 (1.5–6.1)	–	–
Δ* pSS-FU (year), median (IQR)	–	12.0 (6.3–16.8)	–
FS, median (IQR)	1.8 (0.8–4.0)	2.7 (1.4–3.5)	0.204 (MWU)
FS ≥3, n (%)	3/11 (27)	8/22 (36)	1.000 (FT)
Area CD45 (%), median (IQR)	20.3 (7.4–27.7)	12.7 (9.4–19.1)	0.143 (MWU)
LELs based on H&E, n (%)	7/11 (64)	13/22 (59)	1.000 (FT)
GC based on H&E, n (%)	2/11 (18)	4/22 (18)	1.000 (FT)
GC based on Bcl6, n (%)	3/11 (27)	5/22 (23)	1.000 (FT)

Δ\* Lymph-pSS: time between diagnosis of pSS and parotid MALT lymphoma.

Δ\* pSS-FU: time between diagnosis of pSS and last follow-up.

FU, follow up; Bcl6, B-cell lymphoma 6 protein; FS, focus score; GC, germinal centre; FT, Fisher's exact test; LEL, lymphoepithelial lesions; MALT, mucosa-associated lymphoid tissue; MWU, Mann-Whitney U test; pSS, primary Sjögren's syndrome; RF, rheumatoid factor.

lymphoma.<sup>9 12 17</sup> In a retrospective analysis of prelymphoma labial gland biopsies from 13 pSS patients with unspecified NHL lymphomas, Risselada *et al*<sup>9</sup> found that in H&E stained sections, GCs were present in only three (23%) of the patients. Johnsen *et al*<sup>17</sup> showed that in similarly stained labial gland biopsies of pSS NHL patients, 4 out of 12 biopsies (33%) exhibited GCs. The matched control group of pSS patients without malignant lymphoma development showed an even higher percentage of 46% (13/28) GCs in the biopsies. However, in Johnsen's study, biopsies were taken prior to NHL development and simultaneously or even after NHL development.

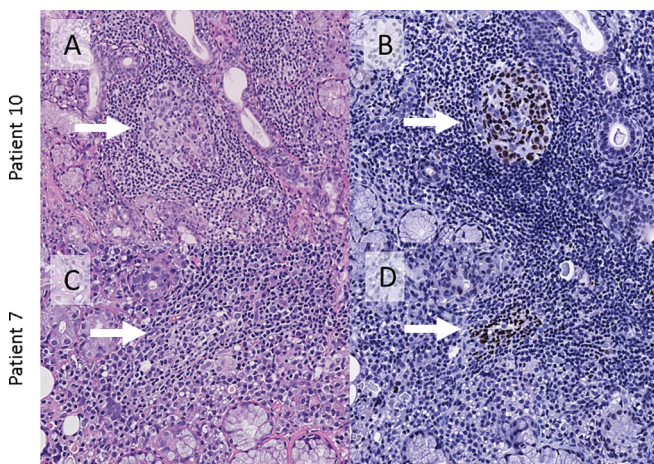
In contrast to our findings and the aforementioned reports, two earlier studies (Theander *et al*<sup>12</sup> and Bombardieri *et al*<sup>18</sup>) indicated an increased incidence of GCs in diagnostic biopsies preceding NHL development. Theander *et al* observed that

six out of seven patients had GCs in diagnostic labial salivary gland biopsies, prior to NHL development. Besides differences in patient cohorts, the most likely explanation for the apparent discrepancy between Theander's study and our findings might be the selection of patients with pSS that developed NHL. While Theander *et al* took all NHLs into account, we restricted ourselves to NHLs that are typically associated with pSS, namely parotid MALT lymphomas. Remarkably, only one out of seven pSS lymphomas in Theander's retrospective study represented a salivary gland (parotid) MALT lymphoma, making comparison with our study difficult. Bombardieri *et al*<sup>18</sup> found 'GC-like structures' in six out of eight (75%) of labial gland biopsies from pSS and patients with secondary Sjögren's syndrome preceding parotid MALT lymphoma. However, in this study, GC-like structures were determined by the presence of T-cells, B-cells and CD21<sup>+</sup> FDC networks. Although CD21<sup>+</sup> FDC networks are a prerequisite for GC development, their presence does not imply that GCs are indeed present. This may lead to a significant over-estimation of the number of GCs in the tissue compared with Bcl6 staining.<sup>16 19</sup>

In conclusion, there are no indications that the occurrence of GCs in diagnostic labial gland biopsies is increased in patients with pSS who developed parotid MALT lymphoma. Thus, in our opinion, labial salivary gland GCs of patients with pSS are not likely a predictive factor for parotid MALT lymphoma development. Nevertheless, their presence might be of clinical relevance for stratification of pSS patients regarding treatment options. For this reason, uniform histopathological criteria for the assessment of GCs are eagerly awaited.

**Acknowledgements** The authors would like to thank the following pathology departments from the Netherlands for providing residual biopsy material: Pathology Friesland (Leeuwarden), Pathology Gelre Hospital (Apeldoorn), Pathology Rijnstate (Arnhem), Pathology Martini Hospital (Groningen), Pathology University Medical Center Utrecht (Utrecht) and Laboratory Pathology and Medical Microbiology (Eindhoven).

**Contributors** Study concept and design: EAH, FGMK, BvdV, HB and AV. Patient recruitment: HB and EAH. Patient biopsy sampling: FKLS. Data collection: EAH and BvdV. Data analysis and interpretation: EAH, FGMK, BvdV, AV, FKLS and HB. The first manuscript was written by EAH and FGMK. All authors critically reviewed the manuscript and approved the final version to be published.



**Figure 1** GCs in diagnostic labial salivary gland biopsies of patients with pSS who developed a parotid MALT lymphoma later on. (A) Clearly visible GC in a periductal focus of the labial gland, H&E stain. (B) Bcl6 staining of serial section, showing the same GC. (C) Suspicious GC in a periductal focus of the labial gland, H&E stain. (D) Bcl6 staining of a serial section shows a small GC. Arrows point to GCs. GCs, germinal centres; pSS, primary Sjögren's syndrome.

**Competing interests** None declared.

**Ethics approval** METc (University Groningen). Study registration number: 2014/211.

**Provenance and peer review** Not commissioned; externally peer reviewed.

© Article author(s) (or their employer(s) unless otherwise stated in the text of the article) 2017. All rights reserved. No commercial use is permitted unless otherwise expressly granted.

## REFERENCES

- 1 Brito-Zerón P, Baldini C, Bootsma H, *et al.* Sjögren syndrome. *Nat Rev Dis Prim* 2016;2:1–20.
- 2 Fisher BA, Jonsson R, Daniels T, *et al.* Standardisation of labial salivary gland histopathology in clinical trials in primary Sjögren's syndrome. *Ann Rheum Dis* 2017;76:1161–8.
- 3 Risselada AP, Looije MF, Kruize AA, *et al.* The role of ectopic germinal centers in the immunopathology of primary Sjögren's syndrome: a systematic review. *Semin Arthritis Rheum* 2013;42:368–76.
- 4 Kroese FG, Abdulahad WH, Haacke E, *et al.* B-cell hyperactivity in primary Sjögren's syndrome. *Expert Rev Clin Immunol* 2014;10:483–99.
- 5 Giannouli S, Voulgarelis M. Predicting progression to lymphoma in Sjögren's syndrome patients. *Expert Rev Clin Immunol* 2014;10:501–12.
- 6 Voulgarelis M, Ziakas PD, Papageorgiou A, *et al.* Prognosis and outcome of non-Hodgkin lymphoma in primary Sjögren syndrome. *Medicine* 2012;91:1–9.
- 7 Nocturne G, Boudaoud S, Miceli-Richard C, *et al.* Germline and somatic genetic variations of TNFAIP3 in lymphoma complicating primary Sjögren's syndrome. *Blood* 2013;122:4068–76.
- 8 Keszler A, Adler LI, Gandolfo MS, *et al.* MALT lymphoma in labial salivary gland biopsy from Sjögren syndrome: importance of follow-up in early detection. *Oral Surg Oral Med Oral Pathol Oral Radiol* 2013;115:e28–e33.
- 9 Risselada AP, Kruize AA, Goldschmeding R, *et al.* The prognostic value of routinely performed minor salivary gland assessments in primary Sjögren's syndrome. *Ann Rheum Dis* 2014;73:1537–40.
- 10 Fragkioudaki S, Mavragani CP, Moutsopoulos HM. Predicting the risk for lymphoma development in Sjögren syndrome: an easy tool for clinical use. *Medicine* 2016;95:e3766.
- 11 Nocturne G, Virone A, Ng WF, W-f N, *et al.* Rheumatoid factor and disease activity are independent predictors of lymphoma in primary Sjögren's syndrome. *Arthritis Rheumatol* 2016;68:977–85.
- 12 Theander E, Vasaitis L, Baecklund E, *et al.* Lymphoid organisation in labial salivary gland biopsies is a possible predictor for the development of malignant lymphoma in primary Sjögren's syndrome. *Ann Rheum Dis* 2011;161:1363–8.
- 13 Shiboski CH, Shiboski SC, Seror R, *et al.* American College of Rheumatology/European League against Rheumatism classification criteria for primary Sjögren's syndrome A consensus and data-driven methodology involving three international patient cohorts. *Ann Rheum Dis* 2016;2017:9–16.
- 14 Delli K, Haacke EA, Kroese FG, *et al.* Towards personalised treatment in primary Sjögren's syndrome: baseline parotid histopathology predicts responsiveness to rituximab treatment. *Ann Rheum Dis* 2016;75:1933–8.
- 15 Greenspan JS, Daniels TE, Talal N, *et al.* The histopathology of Sjögren's syndrome in labial salivary gland biopsies. *Oral Surg Oral Med Oral Pathol* 1974;37:217–29.
- 16 Delli K, Haacke EA, Ihrler S, *et al.* Need for consensus guidelines to standardise the assessment of germinal centres and other histopathological parameters in salivary gland tissue of patients with primary Sjögren's syndrome. *Ann Rheum Dis* 2016;75:e32.
- 17 Johnsen SJ, Gudlaugsson E, Skaland I, *et al.* Low Protein A20 in Minor Salivary Glands is Associated with Lymphoma in Primary Sjögren's syndrome. *Scand J Immunol* 2016;83:181–7.
- 18 Bombardieri M, Barone F, Humby F, *et al.* Activation-induced cytidine deaminase expression in follicular dendritic cell networks and interfollicular large B cells supports functionality of ectopic lymphoid neogenesis in autoimmune sialoadenitis and MALT lymphoma in Sjögren's syndrome. *J Immunol* 2007;179:4929–38.
- 19 Jonsson MV, Skarstein K. Follicular dendritic cells confirm lymphoid organization in the minor salivary glands of primary Sjögren's syndrome. *J Oral Pathol Med* 2008;37:515–21.
- 20 Musshoff K. [Clinical staging classification of non-Hodgkin's lymphomas (author's transl)]. *Strahlentherapie* 1977;153:218–21.

## Correction: How common is clinically inactive disease in a prospective cohort of patients with juvenile idiopathic arthritis? The importance of definition

Dore M, Marlow C, Cares WM, *et al.* How common is clinically inactive disease in a prospective cohort of patients with juvenile idiopathic arthritis? The importance of definition. *Ann of Rheum Dis* 2017;76:1381–8.

Figure 1 was corrected online but the incorrect version appeared in the August print issue.



## OPEN ACCESS

**Open Access** This is an Open Access article distributed in accordance with the Creative Commons Attribution Non Commercial (CC BY-NC 4.0) license, which permits others to distribute, remix, adapt, build upon this work non-commercially, and license their derivative works on different terms, provided the original work is properly cited and the use is non-commercial. See: <http://creativecommons.org/licenses/by-nc/4.0/>

© Article author(s) (or their employer(s) unless otherwise stated in the text of the article) 2017. All rights reserved. No commercial use is permitted unless otherwise expressly granted.

*Ann Rheum Dis* 2017;76:1784. doi:10.1136/annrheumdis-2016-210511corr1



CrossMark



## Germinal centres in diagnostic labial gland biopsies of patients with primary Sjögren's syndrome are not predictive for parotid MALT lymphoma development

Erlin A Haacke, Bert van der Vegt, Arjan Vissink, Fred K L Spijkervet, Hendrika Bootsma and Frans G M Kroese

*Ann Rheum Dis* 2017 76: 1781-1784 originally published online July 14, 2017  
doi: 10.1136/annrheumdis-2017-211290

---

Updated information and services can be found at:  
<http://ard.bmj.com/content/76/10/1781>

---

*These include:*

### References

This article cites 20 articles, 6 of which you can access for free at:  
<http://ard.bmj.com/content/76/10/1781#BIBL>

### Email alerting service

Receive free email alerts when new articles cite this article. Sign up in the box at the top right corner of the online article.

---

### Notes

---

To request permissions go to:  
<http://group.bmj.com/group/rights-licensing/permissions>

To order reprints go to:  
<http://journals.bmj.com/cgi/reprintform>

To subscribe to BMJ go to:  
<http://group.bmj.com/subscribe/>