

University of Groningen

Abatacept treatment of patients with primary Sjögren's syndrome results in a decrease of germinal centres in salivary gland tissue

Haacke, E. A.; van der Vegt, B.; Meiners, P. M.; Vissink, A.; Spijkervet, F. K. L.; Bootsma, H.; Kroese, F. G. M.

Published in:
Clinical and Experimental Rheumatology

IMPORTANT NOTE: You are advised to consult the publisher's version (publisher's PDF) if you wish to cite from it. Please check the document version below.

Document Version
Final author's version (accepted by publisher, after peer review)

Publication date:
2017

[Link to publication in University of Groningen/UMCG research database](#)

Citation for published version (APA):

Haacke, E. A., van der Vegt, B., Meiners, P. M., Vissink, A., Spijkervet, F. K. L., Bootsma, H., & Kroese, F. G. M. (2017). Abatacept treatment of patients with primary Sjögren's syndrome results in a decrease of germinal centres in salivary gland tissue. *Clinical and Experimental Rheumatology*, 35(2), 317-320. <https://www.clinexprheumatol.org/abstract.asp?a=10742>

Copyright

Other than for strictly personal use, it is not permitted to download or to forward/distribute the text or part of it without the consent of the author(s) and/or copyright holder(s), unless the work is under an open content license (like Creative Commons).

The publication may also be distributed here under the terms of Article 25fa of the Dutch Copyright Act, indicated by the "Taverne" license. More information can be found on the University of Groningen website: <https://www.rug.nl/library/open-access/self-archiving-pure/taverne-amendment>.

Take-down policy

If you believe that this document breaches copyright please contact us providing details, and we will remove access to the work immediately and investigate your claim.

Downloaded from the University of Groningen/UMCG research database (Pure): <http://www.rug.nl/research/portal>. For technical reasons the number of authors shown on this cover page is limited to 10 maximum.

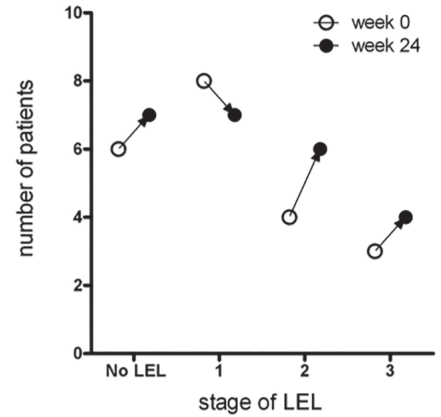
Supplementary Table I. Patient characteristics and laboratory assessments at baseline in pSS patients (n=15) treated with abatacept (6).

Variable	Baseline
Patient characteristics	
Age years, mean (SD)	43 (14)
Female gender, n(%)	12 (80)
Disease duration in months, median (IQR)	11 (7-36)
ESSDAI total, median (IQR)	11 (8-14)
ESSDAI glandular domain ≥ 1 , n(%)	11 (73) [#]
Laboratory assessments	
IgG (g/L), mean \pm SD	21.5 \pm 7.3
RF (kIU/L), mean \pm SD	89 \pm 94
SSA positive, n(%)	15 (100)
SSB positive, n(%)	12 (80)

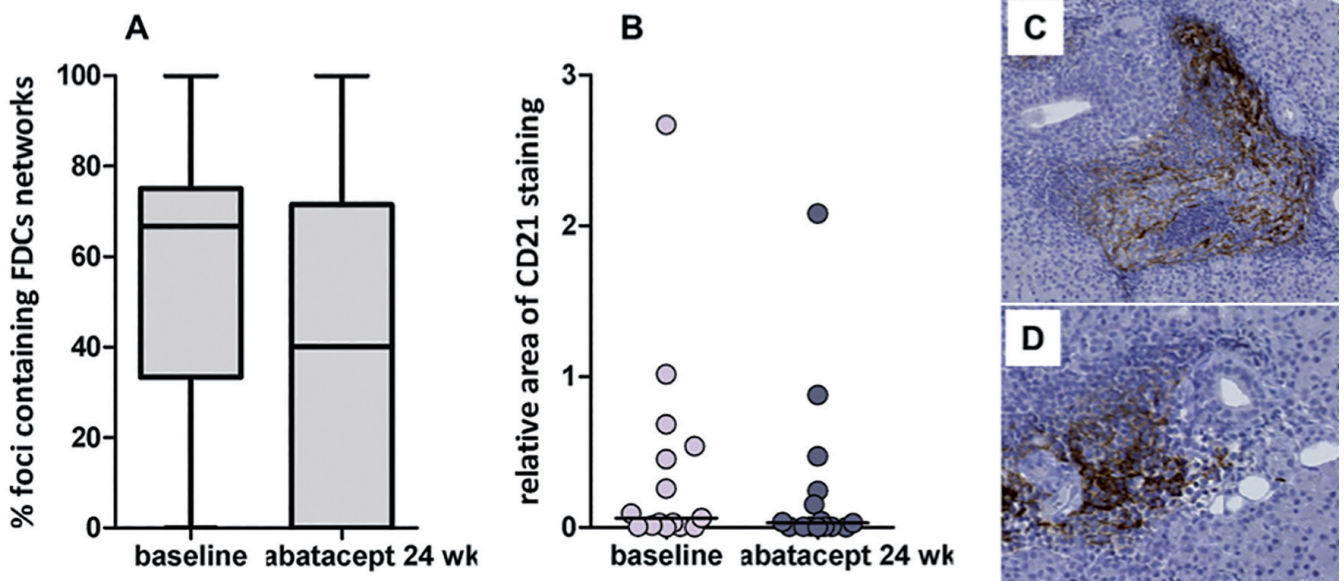
Values are presented as median (IQR) unless otherwise specified.

Supplementary Table II. Antibodies used for immunohistochemistry.

Antigen	Clone	Host	Company
CD20	L-26	Mouse	Ventana Roche
CD3	2GV6	Rabbit	Ventana Roche
CD45	2B11 + PD7/26	Mouse	Ventana Roche
CK8/18	B22.1 + B23.1	Mouse	Ventana Roche
CD21	2G9	Mouse	Ventana Roche
IgA	Polyclonal	Rabbit	Ventana Roche
IgG	Polyclonal	Rabbit	Ventana Roche
IgM	Polyclonal	Rabbit	Ventana Roche



Supplementary Fig. 1. Severity of LELs in pSS patients treated with abatacept. LELs are classified in three stages (9) as stained for CD20 + CK8/18. Stage 1: LEL affecting less than 50% of the epithelium of the striated duct (partial LEL), Stage 2: LEL affecting between 50% and 100% of the epithelium of the striated duct (developed LEL); Stage 3: LEL with fully circumferential affected epithelium without lumen (occluded LEL). Y-axis indicates the total number of patients before (open circles) of after (closed circles) treatment, while X-axis the presence of different stages of LELs. Of note patients can have various stages of LELs at the same time.



Supplementary Fig. 2. Network of follicular dendritic cells in parotid glands of pSS patients treated with abatacept. **A)** The proportion (in percentages) of foci containing networks of follicular dendritic cells (FDCs) per patient as visualised by CD21 staining. Boxes represent the interquartile range divided by the median with Tukey-style whiskers. Of the pSS patients, 87% (13/15) showed a CD21⁺ FDC network within at least one focus, and 73% (11/15) after treatment. **B)** Relative area of CD21 staining, measured by Aperio ImageScope. **C)** Example of a CD21⁺ FDC network with a morphologically recognisable germinal centre. **D)** Example of a CD21⁺ FDC network without a morphologically recognisable germinal centre.