

University of Groningen

Guided bone regeneration

Gielkens, Pepijn Frans Marie

IMPORTANT NOTE: You are advised to consult the publisher's version (publisher's PDF) if you wish to cite from it. Please check the document version below.

Document Version

Publisher's PDF, also known as Version of record

Publication date:

2008

[Link to publication in University of Groningen/UMCG research database](#)

Citation for published version (APA):

Gielkens, P. F. M. (2008). *Guided bone regeneration: the influence of barrier membranes on bone grafts and bone defects*. [s.n.].

Copyright

Other than for strictly personal use, it is not permitted to download or to forward/distribute the text or part of it without the consent of the author(s) and/or copyright holder(s), unless the work is under an open content license (like Creative Commons).

The publication may also be distributed here under the terms of Article 25fa of the Dutch Copyright Act, indicated by the "Taverne" license. More information can be found on the University of Groningen website: <https://www.rug.nl/library/open-access/self-archiving-pure/taverne-amendment>.

Take-down policy


If you believe that this document breaches copyright please contact us providing details, and we will remove access to the work immediately and investigate your claim.

Downloaded from the University of Groningen/UMCG research database (Pure): <http://www.rug.nl/research/portal>. For technical reasons the number of authors shown on this cover page is limited to 10 maximum.

Pepijn Gielkens

Guided bone regeneration

The influence of barrier membranes
on bone grafts and bone defects




Om tandheelkundige implantaten betrouwbaar te kunnen plaatsen, is op de beoogde plaats voldoende kaakbot nodig. Als er onvoldoende bot aanwezig is, bijvoorbeeld als gevolg van een botdefect, kan zich nieuw bot vormen, door het defect te bedekken met een barrière membraan. Het membraan houdt bindweefselingroei tegen, zodat eronder ongestoord nieuw bot kan worden gevormd. Dit wordt geleide bot regeneratie (GBR) genoemd. Ook kan het kaakbotdefect worden opgevuld met een bottransplantaat. Deze transplantaten worden eveneens vaak bedekt met een membraan. De gedachte is dat hierdoor het 'oplossen' (resorptie) van het transplantaat wordt voorkomen. Het eerste doel van dit proefschrift was na te gaan of dit daadwerkelijk zo is.

Het tweede doel was het evalueren van een nieuw ontwikkeld biodegradeerbaar synthetisch membraan, omdat de huidige klinisch toegepaste membranen nog niet ideaal zijn.

In een literatuurstudie werd geconcludeerd dat het beschikbare bewijs voor membraangebruik om transplantaatresorptie te voorkómen zwak is. Ook in de proefdierexperimenten die in dit proefschrift zijn beschreven kon hiervoor geen bewijs worden gevonden. Wel lijkt de voorspelbaarheid van de resorptie van het bottransplantaat bedekt met een membraan iets hoger te zijn.

In de defectstudies, waarbij een gat in de onderkaak van de rat werd bedekt met een membraan, werd meer botingroei gezien in de groepen behandeld met het nieuwe membraan vergeleken met de controlegroep waarin het defect niet werd bedekt. De referentie membranen bleken echter superieur, mogelijk doordat het nieuwe membraan vouwt of krult en zich niet makkelijk plooit. Het nieuwe membraan zal verder ontwikkeld moeten worden voordat het klinisch bruikbaar is.



GUIDED BONE REGENERATION

The influence of barrier membranes on bone grafts and bone defects

Stellingen

Behorende bij het proefschrift

GUIDED BONE REGENERATION

The influence of barrier membranes on bone grafts and bone defects

Groningen, 11 juni 2008

Pepijn Gielkens

Resorptie van autologe botblok transplantaten op de kaak wordt niet voorkomen door ze te bedekken met een membraan; evenmin wordt hun incorporatie hierdoor verbeterd. *dit proefschrift*

Poly(DL-lactide- ϵ -caprolacton) is weliswaar biocompatibel en degradeerbaar op de lange termijn, maar in de huidige vorm en samenstelling niet geschikt als klinisch toepasbaar barrière membraan. *dit proefschrift*

De biocompatibiliteit en degradatie-eigenschappen van biomaterialen kunnen subcutaan worden getest, ook als deze uiteindelijk superiostaal worden toegepast. *dit proefschrift*

Micro-CT is een betrouwbare en valide methode om botvorming en botresorptie te meten. *dit proefschrift*

Als toeval niet bestaat heeft statistisch toetsen geen betekenis.

Wanneer aan de correcte betekenis van 'preliminary results' voorbij wordt gegaan, worden ook voorbarige conclusies getrokken.

Het is een misvatting dat de naam 'unihockey' iets met de Universiteit van doen heeft.

Het blijkt een lastige opgave te zijn niet alleen een proefschrift, maar ook de daarmee verbonden kosten te laten drukken.

Het probleem met de toekomst is dat het verandert in het heden.
(Hobbes, In: Casper en Hobbes, De gestoorde bloeddorstige monsterlijke sneeuwzombies vallen aan. Bill Watterson, Haarlem, Big Balloon B.V., 2000).

De suggestie van P. Ball om onze planeet 'Water' in plaats van 'Aarde' te noemen, getuigt van oppervlakkigheid.
(P. Ball, In: Een kleine geschiedenis van bijna alles. Bill Bryson, Amsterdam/Antwerpen, Uitgeverij Atlas, 2004).

Degene die nooit van gedachten is veranderd, heeft nooit iets geleerd.
(vrij naar NRC Handelsblad, 23-24 februari 2008)

De uitspraak "Zeg nooit nooit" gaat niet altijd op.

Centrale	U
Medische	M
Bibliotheek	C
Groningen	G

Lay-out and cover: Jolien Meiberg (www.joli.nl)
Printing: Drukkerij van Denderen BV, Groningen
Publisher: P.F.M. Gielkens, Groningen

ISBN: 978-90-367-3433-2

©Pepijn F.M. Gielkens, 2008

All rights reserved. No part of this publication may be reproduced, stored in a retrieval system or transmitted in any form or by any means, electronically, mechanically, by photocopy, by recording or otherwise, without permission of the publisher.

RIJKSUNIVERSITEIT GRONINGEN

GUIDED BONE REGENERATION

The influence of barrier membranes on bone grafts and bone defects

Proefschrift

ter verkrijging van het doctoraat in de
Medische Wetenschappen
aan de Rijksuniversiteit Groningen
op gezag van de
Rector Magnificus, dr. F. Zwarts,
in het openbaar te verdedigen op
woensdag 11 juni 2008
om 16.15 uur

door

Pepijn Frans Marie Gielkens

geboren op 21 oktober 1977
te Kerkrade

Centrale	U
Medische	M
Bibliotheek	C
Groningen	G

Promotores:

Prof.dr. R.R.M. Bos
Prof.dr. B. Stegenga
Prof.dr. G.M. Raghoobar

Copromotor:

Dr. J. Schortinghuis

Beoordelingscommissie:

Prof.dr. C.M. ten Bruggenkate
Prof.dr. D.W. Grijpma
Prof.dr. M.A.W. Merkx



Paranimfen:

Drs. M. Hekkenberg

Drs. C.A. Krabbe

The research presented in this thesis was performed at:

The Department of Oral and Maxillofacial Surgery, University Medical Center Groningen, University of Groningen, The Netherlands

The Department of Biomedical Engineering, Section of Biocompatibility and Biomaterials, University Medical Center Groningen, University of Groningen, The Netherlands

The Department of Dentistry, University Medical Center Groningen, University of Groningen, The Netherlands

The Department of Nuclear Medicine and Molecular Imaging, University Medical Center Groningen, University of Groningen, The Netherlands

Publication of this thesis was supported by:

Astra Tech Benelux B.V. (www.astratechdental.nl)

B.Braun Medical B.V. (www.bbraun.nl)

BMSA, The Research Institute of Biomedical Engineering, Materials Science and Application, University Medical Center Groningen (www.rug.nl/umcg/onderzoek)

Carl Zeiss B.V. (www.zeiss.nl)

Dam Medical B.V. (www.dammedical.nl)

Dentaid Benelux B.V. (www.dentaid.nl)

Dental Union (www.dentalunion.nl)

Dent-Med Materials B.V. (importeur en exclusief distributeur Geistlich Biomaterials) (www.dent-medmaterials.nl)

Harlan Netherlands B.V. (www.harlaneurope.com)

Henry Schein Dental (www.henryschein.nl)

Johnson and Johnson Medical B.V. (www.jnjmedical.nl)

Kuijkhoven Adviesgroep V.O.F. (www.kuijkhoven.nl)

Lamoral B.V. (www.lamoral.nl)

Martin Nederland/Marned B.V. (www.klsmartin.com)

Memodent Dental Depot (www.memodent.nl)

MFP Laverman (www.ttlaverman.nl)

MIS Nederland B.V. (www.misimplants.com)

Nederlandse Vereniging voor Gnathologie en Prothetische Tandheelkunde (www.nvgpt.nl)

Nederlandse Vereniging voor Mondziekten, Kaak- en Aangezichts chirurgie (www.nvmka.nl)

Nederlandse Vereniging voor Orale Implantologie (www.nvoi.nl)

Nobel Biocare Benelux B.V. (www.nobelbiocare.com/nl)

Ortholab B.V. (www.ortholab.nl)

Polyganics B.V. (www.polyganics.nl)

Raadgevers Medische Beroepen (www.raadgevers.nl)

Rijksuniversiteit Groningen (www.rug.nl)

Sartorius Technologies B.V. (www.sartorius-technologies.nl)

Straumann B.V. (www.straumann.nl)

Synthes B.V. (www.synthes.com)

TTMFL Gerrit van Dijk (dijkgerritvan@home.nl)

Van Velthuysen Liebrecht Financiële Dienstverleners (www.velthuysenliebrecht.nl)

W.L. Gore & Associates (<http://nl.goremedical.com>)

Contents

1	Introduction and aim of the study	8
2	Is there evidence that barrier membranes prevent bone resorption in autologous bone grafts during the healing period? A systematic review	18
3	The subcutaneous and subperiosteal tissue reaction to poly(DL-lactide- ϵ -caprolactone) and ePTFE barrier membranes	32
4	A comparison of micro-CT, microradiography and histomorphometry in the evaluation of bone grafts and defects	46
5	Barrier membranes on bone grafts	
5.1	The influence of barrier membranes on autologous bone grafts. An evaluation with microradiography and micro-CT	62
5.2	The influence of three different barrier membranes on modeling and incorporation of autologous bone grafts. An evaluation by transversal microradiography	76
6	Barrier membranes over bone defects	
6.1	Vivosorb [®] , Geistlich Bio-Gide [®] and Gore-Tex [®] as barrier membranes in rat mandibular defects. An evaluation by microradiography and micro-CT	92
6.2	Vivosorb [®] as a barrier membrane in rat mandibular defects. An evaluation with transversal microradiography	106
7	General discussion	122
8	Summary/Samenvatting	
8.1	Summary	134
8.2	Samenvatting	140
	Dankwoord	146
	Curriculum Vitae	152

Introduction and aim of the study

Introduction

The origin and development of guided bone regeneration

Guided bone regeneration (GBR) can be defined as the use of a barrier membrane to provide for a space available for new bone formation in a bony defect. Although GBR receives much attention nowadays, the origins of this treatment modality date back to the 1940s. In 1947 Berg hypothesized that osteosynthesis between vertebrae (spinal fusion) was more predictable and rapidly achieved when a space was created between the vertebrae by elevation of the paraspinal muscles and placing a bone graft in between.

Hellstadius (1950) tested this theory by creating a space using a combination of stainless steel cups and rings on roughened cortex of rabbit's femur. He concluded that bone did not form in granulation tissue when the soft parts were held away. Almost a decade later, Hurley et al. (1959) used millipore membranes for the treatment of experimental spinal fusion in dogs. They found that the sites in which the barrier membrane was applied showed thicker and more uniform fusion plates than the non-covered controls. In the 1960s, Boyne (1969) introduced the application of barrier membranes in maxillofacial surgery. The barrier membranes were applied on large bony defects that resulted from casualties during the Vietnam War (Boyne 1969; Richter & Boyne 1969) and in reconstruction after ablative surgery (Boyne 1973). Metallic meshes of chrome cobalt or titanium were used to support microporous membranes. Although they reported favourable results, these findings did not lead to a broad clinical application. It was not until the 1980s that a technique of bone regeneration was developed using barrier membranes on periodontal defects. The purpose of these barrier membranes was to exclude epithelial in-growth into the sulcus (Gottlow et al. 1984; Gottlow et al. 1986). Numerous membranes have been developed since then (Zellin et al. 1995).

In the late 1980s, clinicians started to augment the jaw bone in conjunction with or prior to implantation (Breine & Branemark 1980; Listrom & Symington 1988, Buser et al. 1990). The membrane technique was applied in implant dentistry to cover implants with bony defects (Nyman et al. 1990). Managing bone deficits in these cases is a great

challenge to surgeons, because a significant part of these implants are inserted in regions where the gingival contour, dictated by the underlying bone contour, and crown angulation are of great importance (Meijndert et al. in press).

In the mid1990s, researchers tried to enhance the predictability of bone augmentation procedures by preventing bone graft resorption. To this end they covered the bone grafts with barrier membranes (Buser et al. 1996). Reported results were promising and the application of barrier membranes to cover bone grafts is now widespread among clinicians. However, there are disadvantages of applying barrier membranes. Non-degradable membranes, such as expanded polytetrafluoroethylene (ePTFE) may perforate the oral mucosa, serving as 'port d'entrée' and thereby inducing an inflammatory response (Clarizio 1999). To stop this inflammatory response, the membrane must be removed. Membrane exposure during healing has a major negative effect on GBR around dental implants (Machtei 2001). Thus, a closed situation is essential when an ePTFE membrane is used. Moreover, these barrier membranes account for a significant part of the costs in alveolar ridge augmentation in pre-implant surgery (Chiapasco et al. 1999).

Nowadays, as surgery for cosmetic reasons is widely accepted and eternal youth is aspired, more implants than ever are placed. Since 1989 the number of dental implants used, has increased by almost 2000% (Meijndert 2007). Especially the amount of single tooth replacements is increasing during the last decade. It is therefore of major importance that the indication to use the barrier membranes is correct and when used, the barrier membranes applied have ideal properties.

Basic principles of GBR

As early as in the 1950s, it was stated that the presence of a blood clot is necessary for new bone formation (Murray et al. 1957). Blood clot formation starts with tissue injury. This injury incites an inflammatory response with activation of complement. Damage to blood vessels causes extravasation and cell signalling. Monocytes and macrophages are directed towards the wound, producing growth factors and attracting other leucocytes. Platelets form a blood clot and discharge Platelet Derived Growth



Factor (PDGF), Transforming Growth Factor beta (TGF- β) and Fibroblast Growth Factor (FGF). Granulation tissue develops, consisting of new blood vessels, collagen and cells. The collagenous component presents modulating factors (TGF- β , FGF, bone morphogenetic proteins (BMPs)) to receptive cells. Furthermore, it serves as a matrix for cellular attachment of osteoprogenitor cells. These cells differentiate into chondrocytes and osteoblasts under the influence of BMPs. Eventually, the defect is filled with new bone (Hollinger et al. 1999).

In GBR a barrier membrane protects the defect from ingrowth of soft tissue cells and allows bone progenitor cells to develop bone within a blood clot that is formed beneath the barrier membrane. Furthermore, the membrane excludes inhibiting factors and preserves bone growth factors thereby facilitating bone development (Ogiso et al. 1991; Zellin & Linde 1997).

Barrier membranes and bone grafting

A considerable number of augmentation methods have been used in an attempt to solve the problem of bone deficits in reconstructive and implant surgery. The techniques available today, that are widely accepted to achieve good clinical outcome, include guided bone regeneration (Mundell et al. 1993), osteodistraction (Schortinghuis et al. 2005), transplantation of autologous bone grafts (Antoun et al. 2001; Von Arx et al. 2002; Donos et al. 2002), bone substitutes (Zitzmann et al. 2001), or a combination of techniques (Hallman et al. 2002).

Guided bone regeneration is merely suitable for local bony defects. A bone graft can be applied solely, or as space-maintainer underneath a barrier membrane. The bone functions as a scaffold and carrier for living cells (Burchardt 1983; Schenk 1994). A barrier membrane on an autologous bone graft is expected to prevent bone resorption, since a barrier membrane keeps the osteoinductive substances (e.g., growth factors) in place (Zellin & Linde 1997) and secludes the grafted area from inhibiting factors and connective tissue cells (Ogiso et al. 1991; Gordh et al. 1998). Even though the microporous ePTFE membranes (Gore-Tex[®]; W.L.Gore and Associates, Flagstaff, Arizona) are, presumably, initially permeable to tissue fluid and macromolecular flow, a certain local concentration of growth factors may occur (Linde et al. 1993). The concentration of

local growth factors might result in a more intensive modeling of bone, i.e., local bone formation and resorption at sites subjected to barrier membrane treatment (Gordh et al. 1998). Furthermore, barrier membrane coverage may primarily reduce resorption by enhanced incorporation (Alberius et al. 1992). Moreover, a barrier membrane serves as a space-maintainer, allowing bone regeneration in any remaining space and minimizing overall loss of bone volume (Antoun et al. 2001).

Although autologous bone serves as reference standard for bone grafting procedures (Merckx et al. 1999; Antoun et al. 2001), alternatives, such as demineralised bone and bovine porous bone mineral, have been extensively investigated with good clinical results (Zitzmann et al. 1997; Olson et al. 2000; Zitzmann et al. 2001). Reasons mentioned for using an alternative bone grafting material include the prevention of donor site morbidity, particularly in the iliac crest (Kalk et al. 1996; Joshi & Kostakis 2004), and insufficient volume of (intraorally) harvested autologous bone (Degidi et al. 2004). However, the disadvantages of autologous bone are outweighed by their safety in terms of disease transmission and immunologic responses (Cune 2003). Additionally, new surgical techniques and instruments, e.g., bone collectors, trephines, chisels and bone mills, have optimised the harvesting procedures of autologous bone (Von Arx et al. 2001), and have decreased donor site morbidity (Jansma 2002).

Most bone substitutes consist of small particles. These are applied alone or in combination with autologous bone chips. When used with autologous bone chips, the barrier membranes serve to secure these granules. A frequently applied barrier membrane for this purpose is a porcine bilayer collagen type I biodegradable membrane (Geistlich Bio-Gide[®], Geistlich Biomaterials, Wolhusen, Switzerland). This membrane was developed in the 1990s. Bony defects have successfully been treated (Zitzmann et al. 2001) and it is therefore considered the standard reference for biodegradable barrier membranes. Similarly, although complications may be observed when exposed to the oral environment due to perforation of the oral mucosa, ePTFE is frequently chosen as reference material for non-degradable membranes.

'Ideal' barrier membrane

The 'ideal' barrier membrane for alveolar ridge augmentation should have some specific properties. It is biocompatible, occlusive, space-maintaining, and clinically manageable. Furthermore, it should be biodegradable and synthetic (Kay et al. 1997; Von Arx et al. 2002).

An abundance of types of membranes has been tested, both in periodontal surgery and in implant surgery (Zellin et al. 1995). Nowadays, a porcine collagen type I membrane is the standard reference material for biodegradable membranes and the synthetic ePTFE membrane for non-degradables (Zitzmann et al. 1997; Von Arx et al. 2002). Although these materials are the standard references in membrane research because of established success, they have some disadvantages. Collagen has poor space making properties in wet conditions (Hutmacher et al. 2001) and its composition of animal derived collagen possibly leads to disease transmission from animal to people (Von Arx et al. 2002). The ePTFE is non-degradable, making it necessary to perform an additional surgical procedure to remove the membrane (Triplett et al. 2001). Furthermore, as mentioned before, when the membrane is exposed to the oral cavity, most of the times the membrane needs to be removed early to resolve the inflammatory reaction (Wang & Carroll 2001). This is not the case with collagen (Zitzmann et al. 1997).

An advantage of a synthetic membrane is the possibility to produce it in any required amount, and in a standardized controlled manner. One can influence the macrostructure, mechanical properties and degradation profile (Pêgo et al. 2003a,b). These advantages do not apply to the non-synthetic collagenous membranes. Thus, although collagen and ePTFE fulfil their duty as a barrier membrane, there is still need for an alternative that combines the advantages of both membranes. Attempts to produce a synthetic degradable membrane that has the same clinical qualities as the references have failed so far.

Poly(DL-lactide- ϵ -caprolactone) as barrier membrane

A Vivosorb® membrane (Polyganics, Groningen, The Netherlands) composed of poly(DL-lactide- ϵ -caprolactone) might have the required properties. The copolymer is obtained by ring-opening polymerization of the lactides

(L/D ratio 85/15) and ϵ -caprolactone monomers using stannous octoate (Sn(Oct)₂) as catalyst. The residual monomers are removed by precipitation chloroform in ethanol. The final lactide / ϵ -caprolactone ratio was determined at 67-69 / 33-31 using nuclear magnetic resonance imaging. The polymer is completely amorphous, which means that it does not contain a crystalline fraction, and exhibits rubber-like behaviour, as was confirmed by differential scanning calorimetry.

Poly(DL-lactide- ϵ -caprolactone) sheets with a thickness of 0.10 mm can be manufactured by pouring a chloroform - polymer solution in a stainless steel mould. The bottom of this mould is roughened by sandblasting to obtain 1 rough side in the barrier membrane. This rough side is applied facing the bone to facilitate positioning and integration.

Thereafter the polymer is condensed due to the evaporation of the chloroform. After complete condensation the 0.10 mm thick polymer sheets are washed in a mixture of ethanol and water and manually cut in membranes with a size of 45 x 15 mm. The membranes are completely transparent and flexible. The material is sterilized with ethylene oxide according to standard procedures.

The poly(DL-lactide- ϵ -caprolactone) barrier membrane may be an interesting alternative for collagen and ePTFE membranes. Based on its chemical composition it can be expected to be occlusive and with a thickness of 0.10 mm it is flexible enough to adapt to the contour of the cortical bone and at the same time stiff enough to bridge defects. This membrane is easily handled and cut and can be fixed with sutures, if necessary. Short-term *in vivo* and *in vitro* tests showed that this copolymer is biocompatible, degradable and non-cytotoxic (Meek et al. 2004). This polymer has extensively been tested in clinical practice as a nerve guide (Bertleff et al. 2005). However, long-term implantation studies in a subperiosteal environment have not been performed. Furthermore, it seems to be necessary to test the biocompatibility and degradation of biomaterials (e.g., polymers) in the eventual anatomic environment, in this case subperiosteally, instead of subcutaneously (Asikainen et al. 2008).



Micro-CT and transversal microradiography in the evaluation of new bone formation and bone resorption in autologous bone grafts

Traditionally, histomorphometry has been used to measure bone formation inside bony defects or bone modeling of onlay bone grafts (Nastri & Smith 1996). As histomorphometry is time consuming and, therefore, rather expensive, other techniques have been applied. For example, microradiography was successfully introduced for the quantitative evaluation of new bone formation of experimentally created defects (Schortinghuis et al. 2003). However, a disadvantage of microradiography is that only a 2 dimensional image is obtained, making 3 dimensional volumetric calculations impossible. An upcoming technique is micro-computed tomography (micro-CT), where both 3D and 2D reconstructions and volumetric measurements can be obtained (Lee et al. 2006). This micro-CT technique seems promising for the quantification of bone formation inside bony defects as well as the evaluation of bone modeling in bone grafts.

However, nor histomorphometry or micro-CT can measure the extent of bone mineralization and resulting bone density. Bone mineralization and bone density give an impression of the bone quality. Transversal microradiography (TMR) is an accurate method of measuring mineral content in a sample (Arends et al. 1997). This method has proven to be valid, precise and useful for measuring mineral loss in caries research (Kielbassa et al. 1999; Petersson & Kambara 2004). Therefore, it can be expected that accurate comparisons of bone mineralization in new bone and in a bone graft can be made with TMR.

Aim of the thesis

The first aim was to study the preventive effect of different barrier membranes on bone resorption of autologous onlay bone block grafts. The second aim was to evaluate a new synthetic degradable barrier membrane in animal experiments and compare it to the standard degradable and non-degradable reference membranes. For these purposes methods were developed to use micro-CT, microradiography and transversal microradiography in GBR experiments.

To obtain these goals we:

- » performed a systematic review of the available literature to find evidence for barrier membranes to prevent autologous bone graft resorption. (*Chapter 2*)
- » tested the biocompatibility of poly (DL-lactide-ε-caprolactone) in subcutaneous as well as subperiosteal sites in a long-term implantation study in rats. (*Chapter 3*)
- » evaluated new methods of measuring bone formation in rat mandibular defects and modeling with resorption of grafts by microradiography, micro-CT as well as histomorphometry. (*Chapter 4*)
- » tested the effect of poly(DL-lactide-ε-caprolactone), collagen and ePTFE membranes on graft resorption of autologous onlay bone block grafts in rats using microradiography, micro-CT and transversal microradiography. (*Chapter 5.1 and 5.2*)
- » evaluated qualitative and quantitative effects of the different types of membranes on bone formation in mandibular critical size defects in rats using microradiography, micro-CT and transversal microradiography. (*Chapter 6.1 and 6.2*)

References

- Alberius, P., Dahlin, C. & Linde, A. (1992) Role of osteopromotion in experimental bone grafting to the skull: a study in adult rats using a membrane technique. *J Oral Maxillofac Surg* 50: 829-834.
- Antoun, H., Sitbon, J.M., Martinez, H. & Missika, P. (2001) A prospective randomized study comparing two techniques of bone augmentation: onlay graft alone or associated with a membrane. *Clin Oral Implants Res* 12: 632-639.
- Arends, J., Ruben, J.L. & Inaba, D. (1997) Major topics in quantitative microradiography of enamel and dentin: R parameter, mineral distribution visualization, and hyper-remineralization. *Adv Dent Res* 11: 403-414.
- Asikainen, A.J., Pelto, M., Noponen, J., Kellomäki, M., Pihlajamäki, H., Lindqvist, C. & Suuronen, R. (2008) In vivo degradation of poly(DTE carbonate) membranes. Analysis of the tissue reactions and mechanical properties. *J Mater Sci Mater Med* 1: 53-58.
- Berg, A. (1947) Contribution to the technique in fusion operations on the spine. *Acta Orthop Scandinavica* 17: 1-30.
- Bertleff, M.J., Meek, M.F. & Nicolai, J.P. (2005) A prospective clinical evaluation of biodegradable neurolac nerve guides for sensory nerve repair in the hand. *J Hand Surg* 30: 513-518.
- Boyne, P.J. (1969) Restoration of osseous defects in maxillofacial casualties. *J Am Dent Assoc* 78: 767-776.
- Boyne, P.J. (1973) Methods of osseous reconstruction of the mandible following surgical resection. *J Biomed Mater Res* 4: 195-204.
- Breine, U. & Branemark, P.I. (1980) Reconstruction of alveolar jaw bone. An experimental and clinical study of immediate and preformed autologous bone grafts in combination with osseointegrated implants. *Scand J Plast Reconstr Surg* 14: 23-48.
- Burchardt, H. (1983) The biology of bone graft repair. *Clin Orthop* 174: 28-42.
- Buser, D., Brägger, U., Lang, N.P. & Nyman, S. (1990) Regeneration and enlargement of jaw bone using guided tissue regeneration. *Clin Oral Implants Res* 1: 22-32.
- Buser, D., Dula, K., Hirt, H.P. & Schenk, R.K. (1996) Lateral ridge augmentation using autografts and barrier membranes: a clinical study with 40 partially edentulous patients. *J Oral Maxillofac Surg* 54: 420-432.
- Chiapasco, M., Abati, S., Romeo, E. & Vogel, G. (1999) Clinical outcome of autogenous bone blocks or guided bone regeneration with e-PTFE membranes for the reconstruction of narrow edentulous ridges. *Clin Oral Implants Res* 10: 278-288.
- Clarizio, L.F. (1999) Successful implant restoration without the use of membrane barriers. *J Oral Maxillofac Surg* 57: 1117-1121.
- Cune, M.S. (2003) Prothetische en chirurgische achtergronden, voorbereiding en uitvoering. In: Cune, M.S. & Meijer, G.J., eds. *Implantologie in partieel dentate situaties*, p. 57-166. Houten: Bohn Stafleu Van Loghum.
- Degidi, M., Piattelli, M., Scarano, A., Iezzi, G. & Piattelli, A. (2004) Maxillary sinus augmentation with a synthetic cell-binding peptide: histological and histomorphometrical results in humans. *J Oral Implantol* 30: 376-383.
- Donos, N., Kostopoulos, L. & Karring, T. (2002) Augmentation of the rat jaw with autogeneic cortico-cancellous bone grafts and guided tissue regeneration. *Clin Oral Implants Res* 13: 192-202.
- Gordh, M., Alberius, P., Johnell, O., Lindberg, L. & Linde, A. (1998) Osteopromotive membranes enhance onlay integration and maintenance in the adult rat skull. *Int J Oral Maxillofac Surg* 27: 67-73.
- Gottlow, J., Nyman, S., Karring, T. & Lindhe, J. (1984) New attachment formation as the result of controlled tissue regeneration. *J Clin Periodontol* 11: 494-503.
- Gottlow, J., Nyman, S., Lindhe, J., Karring, T. & Wennstrom, J. (1986) New attachment formation in the human periodontium by guided tissue regeneration. Case reports. *J Clin Periodontol* 13: 604-616.
- Hallman, M., Sennerby, L. & Lundgren, S. (2002) A clinical and



histologic evaluation of implant integration in the posterior maxilla after sinus floor augmentation with autogenous bone, bovine hydroxyapatite, or a 20:80 mixture. *Int J Oral Maxillofac Implants* 17: 635-643.

Hellstadius, A. (1950) Study on the formation of new bone. *Acta Orthop Scandinavica* 20: 89-93.

Hollinger, J.O., Buck, D.C. & Bruder, S.P. (1999) Biology of bone healing: its impact on clinical therapy. In: Lynch, S.E., Genco, R.J. & Marx, R.E., eds. Tissue engineering. Applications in maxillofacial surgery and periodontics, p. 17-53. Chicago: Quintessence.

Hutmacher, D.W., Kirsch, A., Ackermann, K.L. & Hürzeler, M.B. (2001) A tissue engineered cell-occlusive device for hard tissue regeneration - a preliminary report. *Int J Periodontics Restorative Dent* 21: 49-59.

Hurley, L.A., Stinchfield, F.E., Bassett, A.L. & Lyon, W.H. (1959) The role of soft tissues in osteogenesis. An experimental study of canine spine fusions. *J Bone Joint Surg* 41-A: 1243-1254.

Jansma, J. (2002) Use of the trephine for harvesting bone from the iliac crest. *Ned Tijdschr Tandheelkd* 109: 88-90.

Joshi, A. & Kostakis, G.C. (2004) An investigation of post-operative morbidity following iliac crest graft harvesting. *Br Dent J* 196: 167-171.

Kalk, W.W., Raghoobar, G.M., Jansma, J. & Boering G. (1996) Morbidity from iliac crest bone harvesting. *J Oral Maxillofac Surg* 54: 1424-1429.

Kay, S.A., Wisner-Lynch, L., Marxer, M. & Lynch, S.E. (1997) Guided bone regeneration: integration of a resorbable membrane and a bone graft material. *Pract Periodontics Aesthet Dent* 9: 185-194.

Kielbassa, A.M., Wrbas, K.T., Schulte-Mönting, J. & Hellwig, E. (1999) Correlation of transversal microradiography and microhardness on in situ-induced demineralization in irradiated and nonirradiated human dental enamel. *Arch Oral Biol* 44: 243-251.

Lee, J.K., Ha, B.H., Choi, J.H., Heo, S.M. & Perinpanayagam, H. (2006) Quantitative three-dimensional analysis of root canal

curvature in maxillary first molars using micro-computed tomography. *J Endod* 32: 941-945.

Linde, A., Alberius, P., Dahlin, C., Bjurstam, K. & Sundin, Y. (1993) Osteopromotion: a soft-tissue exclusion principle using a membrane for bone healing and bone neogenesis. *J Periodontol* 64: 1116-1128.

Listrom, R.D. & Symington, J.M. (1988) Osseointegrated dental implants in conjunction with bone grafts. *Int J Oral Maxillofac Surg* 17: 116-118.

Machtei, E.E. (2001) The effect of membrane exposure on the outcome of regenerative procedures in humans: a meta-analysis. *J Periodontol* 72: 512-516.

Meek, M.F., Jansen, K., Steendam, R., van Oeveren, W., van Wachem, P.B. & van Luyn, M.J. (2004) In vitro degradation and biocompatibility of poly(DL-lactide-epsilon-caprolactone) nerve guides. *J Biomed Mater Res A* 68: 43-51.

Meijndert, L. (2007) Introduction and aim of the study. In: Meijndert, L., ed. Implant-supported single tooth replacement in the aesthetic zone. A prospective, randomized clinical trial comparing the treatment outcome of three augmentation strategies, p. 9-13. Noordhoorn: L. Meijndert.

Meijndert, L., Raghoobar, G.M., Meijer, H.J.A. & Vissink, A. Clinical and radiographic characteristics of single tooth replacements preceded by local ridge augmentation. *Clin Oral Impl Res*, in press.

Merkx, M.A., Maltha, J.C., Freihofer, H.P. & Kuijpers-Jagtman, A.M. (1999) Incorporation of particulated bone implants in the facial skeleton. *Biomaterials* 20: 2029-2035.

Mundell, R.D., Mooney, M.P., Siegel, M.I. & Losken, A. (1993) Osseous guided tissue regeneration using a collagen barrier membrane. *J Oral Maxillofac Surg* 51: 1004-1012.

Murray, G., Holden, R. & Roschlau, W. (1957) Experimental and clinical study of new growth of bone in a cavity. *Am J Surg* 93: 385-387.

Nastri, A.L. & Smith, A.C. (1996) Guided osteogenesis using syn-

- thetic membranes: an experimental pilot study. *J Craniomaxillofac Surg* 24: 163-167.
- Nyman, S., Lang, N.P., Buser, D. & Bragger, U. (1990) Bone regeneration adjacent to titanium dental implants using guided tissue regeneration: a report of two cases. *Int J Oral Maxillofac Implants* 5: 9-14.
- Ogiso, B., Hughes, F.J., Melcher, A.H. & McCulloch, C.A. (1991) Fibroblasts inhibit mineralised bone nodule formation by rat bone marrow stromal cells in vitro. *J Cell Physiol* 146: 442-450.
- Olson, J.W., Dent, C.D., Morris, H.F. & Ochi, S. (2000) Long-term assessment (5 to 71 months) of endosseous dental implants placed in the augmented maxillary sinus. *Ann Periodontol* 5: 152-156.
- Pêgo, A.P., Poot, A.A., Grijpma, D.W. & Feijen, J. (2003a) Biodegradable elastomeric scaffolds for soft tissue engineering. *J Control Release* 87: 69-79.
- Pêgo, A.P., Poot, A.A., Grijpma, D.W. & Feijen, J. (2003b) Physical properties of high molecular weight 1,3-trimethylene carbonate and D,L-lactide copolymers. *J Mater Sci Mater Med* 14: 767-773.
- Petersson, L.G. & Kambara, M. (2004) Remineralisation study of artificial root caries lesions after fluoride treatment. An in vitro study using electric caries monitor and transversal micro-radiography. *Gerodontology* 21: 85-92.
- Richter, H.E. & Boyne, P.J. (1969) New concepts in facial bone healing. *J Oral Surg* 27: 557-559.
- Schenk, R.K. (1994) Bone regeneration: biological basis. In: Buser, D., Dahlin, C., Schenk, R.K., eds. *Guided Bone Regeneration in Implant Dentistry*, p. 49-100. Chicago: Quintessence.
- Schortinghuis, J., Ruben, J.L., Meijer, H.J., Bronckers, A.L., Raghoobar, G.M. & Stegenga, B. (2003) Microradiography to evaluate bone growth into a rat mandibular defect. *Arch Oral Biol* 48: 155-160.
- Schortinghuis, J., Bronckers, A.L., Stegenga, B., Raghoobar, G.M. & de Bont, L.G. (2005) Ultrasound to stimulate early bone formation in a distraction gap: a double blind randomised clinical pilot trial in the edentulous mandible. *Arch Oral Biol* 50: 411-420.
- Triplett, R.G., Schow, S.R. & Fields, R.T. (2001) Bone augmentation with and without biodegradable and nonbiodegradable microporous membranes. In: Boyne, P.J., ed. *Alveolar ridge reconstruction / guided tissue regeneration and bone grafting*. Philadelphia: Saunders.
- Von Arx, T., Cochran, D.L., Schenk, R.K. & Buser, D. (2002) Evaluation of a prototype trilayer membrane (PTLM) for lateral ridge augmentation: an experimental study in the canine mandible. *Int J Oral Maxillofac Surg* 31: 190-199.
- Von Arx, T., Cochran, D.L., Hermann, J.S., Schenk, R.K. & Buser, D. (2001) Lateral ridge augmentation using different bone fillers and barrier membrane application. A histologic and histomorphometric pilot study in the canine mandible. *Clin Oral Implants Res* 12: 260-269.
- Wang, H.L. & Carroll, M.J. (2001) Guided bone regeneration using bone grafts and collagen membranes. *Quintessence Int* 32: 504-515.
- Zellin, G., Gritli-Linde, A. & Linde, A. (1995) Healing of mandibular defects with different biodegradable and non-biodegradable membranes: an experimental study in rats. *Biomaterials* 16: 601-609.
- Zellin, G. & Linde, A. (1997) Importance of delivery systems for growth-stimulatory factors in combination with osteopromotive membranes. An experimental study using rhBMP-2 in rat mandibular defects. *J Biomed Mater Res* 35: 181-190.
- Zitzmann, N.U., Naef, R. & Scharer, P. (1997) Resorbable versus nonresorbable membranes in combination with Bio-Oss for guided bone regeneration. *Int J Oral Maxillofac Implants* 12: 844-852.
- Zitzmann, N.U., Schärer, P. & Marinello, C.P. (2001) Long-term results of implants treated with guided bone regeneration: A 5-year prospective study. *Int J Oral Maxillofac Implants* 16: 355-366.



Is there evidence that barrier membranes prevent bone resorption in autologous bone grafts during the healing period? A systematic review

This chapter is an edited version of the manuscript:

Gielkens, P.F.M., Bos, R.R.M., Raghoobar, G.M. & Stegenga, B. (2007)

Is there evidence that barrier membranes prevent bone resorption in autologous bone grafts during the healing period? A systematic review.

Int J Oral Maxillofac Implants 22: 390-398.

Abstract

Objectives:

Autologous bone is considered the 'reference standard' for bone grafting procedures. A barrier membrane covering an autologous bone graft (guided bone regeneration (GBR)) is expected to prevent graft resorption. Good clinical results have been reported for GBR, although potential complications and relatively high costs have been implicated as disadvantages. However, most studies on the subject have been uncontrolled. The aim of this systematic review was to evaluate the available evidence that barrier membranes prevent bone resorption in autologous onlay bone grafts. The primary outcome measure was bone resorption.

Results:

The search yielded 182 articles. Two observers independently appraised 32 relevant studies methodologically, yielding 14 controlled studies.

The articles included human and animal experiments with heterogeneous objectives and outcome variables. Although most authors concluded that they had found evidence for the protective effect of barrier membranes on bone resorption in bone grafts, this systematic review reveals that the available evidence is too weak to support this.

Most included studies were animal experiments; thus, extrapolation to the human situation is difficult. Most studies also had a small number of test sites, and sample size justification was generally not reported. Furthermore, ambiguity and lack of significance were found in many studies, along with additional limitations such as implantation site, non-suitable designs, and varying outcome measures.

Conclusion:

Based on a systematic review of the literature, further evidence is needed to determine whether barrier membranes prevent bone resorption in autologous onlay bone grafts.

Introduction

The reconstruction of large skeletal deficiencies presents a major surgical challenge. In the facial skeleton, such defects may result from trauma, infection, congenital defects, or tumour resection. In the reconstructive process, there is usually a need for bone or a bone substitute (Buser et al. 1996). A specific, frequently occurring clinical situation that may cause significant problems for reconstruction is the atrophic (partially) edentulous jaw. Since the introduction of endosseous implants, partially or totally edentulous patients with severely resorbed jaws can be successfully treated with prosthetic restorations (Adell et al. 1985; Adell et al. 1990; Sulzer et al. 2004). A prerequisite for the placement of dental implants is the presence of sufficient bone to provide for stability and esthetics. Only with sufficient bone can osseointegration be expected.

A considerable number of augmentation methods have been used in attempts to solve the problem of bone deficiency. Widely accepted techniques include guided bone regeneration (GBR) (Mundell et al. 1993), transplantation of autologous bone grafts (Antoun et al. 2001; Von Arx et al. 2002; Donos et al. 2002c), augmentation with bone substitutes (Zitzmann et al. 2001), or a combination of these (Hallman et al. 2002).

The mechanism of GBR is similar to that of guided tissue regeneration (GTR). A barrier membrane prevents fibroblast mass action to allow osteogenesis within the blood clot that is formed beneath the barrier membrane covering the defect (Hollinger et al. 1999). Furthermore, the barrier membrane excludes inhibiting factors and preserves growth factors (Ogiso et al. 1991; Zellin et al. 1997). The major difference between the GBR and GTR techniques is the open connection of the wound with the oral cavity by means of the gingival sulcus in GTR. This allows oral microorganisms to penetrate the wound, which is an important factor in complications. When a GBR membrane covering a bony defect or bone graft is placed, the wound should ideally be primarily closed.

GBR is suitable only for local bony defects. In the case of a large defect, a bone graft can be applied with (i.e., underneath) or without a barrier membrane. The bone functions as a scaffold and carrier for living cells. The barrier

membrane is expected to prevent bone resorption, since it keeps the osteoinductive substances in place (Linde et al. 1993; Zellin et al. 1997) and secludes the grafted area from inhibiting factors and connective tissue cells (Gordh et al. 1998). Furthermore, the barrier membrane serves as a space-maintainer, allowing bone regeneration in any remaining space and thus minimizing overall loss of bone volume (Antoun et al. 2001). Membrane coverage may primarily reduce resorption by enhanced incorporation (Alberius et al. 1992).

Autologous bone serves as reference standard for bone grafting materials (Merckx et al. 1999; Antoun et al. 2001). However, alternatives, such as demineralised bone and porous bovine bone mineral have been extensively investigated with good outcomes (Zitzmann et al. 1997; Olson et al. 2000; Zitzmann et al. 2001).

Good clinical results regarding barrier membrane coverage have been reported, and many clinicians currently cover bone grafts with a barrier membrane (Buser et al. 1996). However, the advantages of barrier membrane application can be doubted, primarily because of the risk of complications caused by nonresorbable membranes perforating the oral mucosa (Clarizio 1999). Membrane exposure during healing has a major negative effect on GBR around dental implants (Machtei 2001). Thus, a closed situation is essential when a non-degradable membrane, such as an expanded polytetrafluoroethylene (ePTFE) membrane, is used. Moreover, barrier membranes account for a significant part of the costs in alveolar ridge augmentation prior to implant surgery (Chiapasco et al. 1999).

The aim of this systematic review was to appraise the available evidence that barrier membranes prevent the resorption of autologous bone grafts.

Material and Methods

Study selection

To identify studies related to artificial barrier membranes and resorption of onlay bone grafts, a sensitive search was conducted in the databases of MEDLINE (1966 to October 2005), OLDMEDLINE (1950 to 1965), EMBASE (1989 to October 2005) and Biological Abstracts (1990 to October 2005). The search was supplemented with a systematic

search in the Cochrane Central Register of Controlled Trials (CENTRAL) (1800 to October 2005). The search strategy included the use of MeSH terms from the applied thesaurus and free-text words in the aforementioned databases and is presented in Table 1. The search was completed by checking the references of relevant review articles and eligible studies for additional publications. No language restrictions were used throughout the study selection procedure.

Table 1. Search strategy.

1.	Bone resorption (MeSH)
2.	Bone transplantation (MeSH)
3.	Membrane, artificial (MeSH)
4.	1 AND 2 AND 3
5.	Bone resorption AND bone transplantation AND artificial membrane (free text)

Articles were deemed relevant to the topic under investigation (i.e., autologous bone and barrier membrane use) on the basis of their titles and abstracts. When agreement was reached, a full-text document of each relevant article was obtained to determine whether the study was eligible for methodological appraisal. The predetermined inclusion criteria were (1) application of autologous bone, (2) use of a barrier membrane covering the bone graft, (3) primary closure of the surgical wound, and (4) use of a control group in which no barrier membrane was applied. Studies handling barrier membranes in periodontal therapy (i.e., GTR) were excluded. Two researchers independently assessed eligible studies included for methodological appraisal. Items that were evaluated were the research question, study design (including randomization method where applicable), control group, and outcome measure. When necessary, agreement on these items was reached in a consensus meeting.

Results

The MEDLINE and OLDMEDLINE databases yielded 173 publications using MeSH-terms, and 175 publications when

using free text only. The search linking MEDLINE, EMBASE and Biological Abstracts yielded 32 hits, 28 of which had already been found with the previous search. The CENTRAL search yielded 17 articles, of which 3 had not already been found. The searches yielded 182 publications. Screening of titles and abstracts for relevance revealed 32 publications. After applying the inclusion criteria for methodological appraisal, 12 articles remained. Systematic reference checking yielded 2 additional articles matching the inclusion criteria (Fig. 1) (Lundgren et al. 1997; Gordh et al. 1998).

The 14 articles included 2 clinical trials and 12 animal experiments. The animal models used included dog, rat and rabbit models (Table 2).

Outcome variables and measures differed among the publications. Data were presented in absolute, relative, categorical or descriptive terms. In most studies, statistical analyses were reported; the remaining studies merely displayed their results qualitatively. Outcome variables included histologic parameters (e.g., resorption) and clinical factors (e.g., implant stability). Most authors used histology or histomorphometrics, but plaster casts and computerized tomographic (CT) scans were also used.

Because of the heterogeneity of the amassed articles, a meta-analysis could not be performed. For this reason the literature is presented as a conventional review (Table 2). All but 2 publications had the same objective (i.e., measurement of the effect of barrier membranes on autologous bone grafts) (Gordh et al. 1999; Salata et al. 2002). Gordh et al. (1999) concentrated on the influence of recombinant human bone morphogenetic protein-2 (rhBMP-2) on graft volumetric maintenance, and Salata et al. (2002) were interested in the factors involved in osseointegration in situations where a blood vessel source was unavailable. The latter concluded that membrane-covered grafts demonstrated delayed remodeling. Hindrance of the process of revascularization was probably the cause. Furthermore, the authors stated that resorption was more extensive in membrane-protected sites, although the total amount of bone was higher in these cases. Gordh et al. (1999) were interested in the effects of rhBMP-2. To this end, 8 different groups were used. Only the 2 control groups, 1 with and 1 without a barrier membrane applied, were relevant for the present review. Overall, better results were achieved

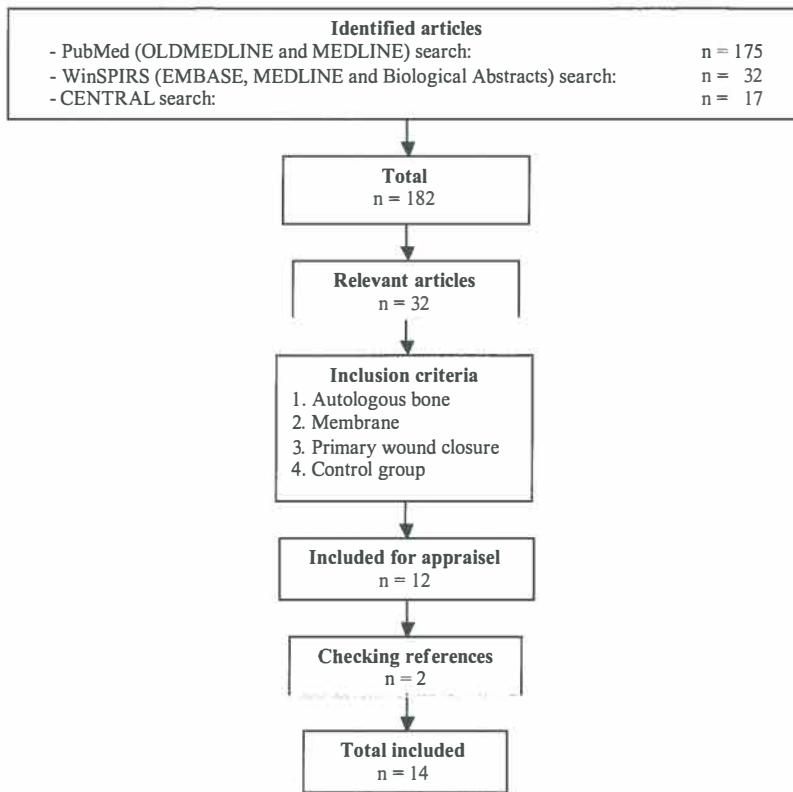


Fig. 1. Algorithm of study selection procedure.

with the use of a barrier membrane. In their second study (Gordh et al. 1998), the authors could not demonstrate definite differences concerning graft integration between grafts covered by a barrier membrane and those covered only by the muscle flap. However, minimal signs of graft resorption were found on the membrane side, while almost all control grafts showed signs of peripheral resorption. No significant differences between sides were registered regarding the measured variables. After 20 weeks a difference in graft incorporation was evident.

The number of experimental sites (ranging from 3 to 16), as well as the receptor site, type of bone, surgical access, and follow up differed between the studies (Table 2). Most authors placed bone grafts on intact bone or in freshly created spaces. Von Arx et al. (2001), however, introduced defects 2 months prior to the transplantation of bone into these defects. The results of that study demonstrated that

barrier membrane coverage was preferable. Augmented sites with membrane protection showed positive healing results with a preserved ridge profile. Nonprotected grafts underwent bucco-crestal resorption. Chiapasco et al. (1999) and Rasmusson et al. (1999) found no evidence that barrier membranes provided protection from bone graft resorption. Chiapasco et al. (1999) found both methods reliable for the reconstruction of narrow edentulous ridges. However, due to the increased costs and the risk of wound infection in case of membrane exposure, these authors prefer reconstruction without the use of barrier membranes in case of narrow ridges. The results of the other study (Rasmusson et al. 1999) showed an increase in volume of the bone grafts on the tested side as long as the barrier membrane was in place. After removal of the barrier membrane, the resorption rate was higher on the test side compared to the control side, resulting in similar

Table 2. Characteristics of included studies.

Study	Graft	Barrier membrane	Explantation site	Implantation site	Surgical access	Max. no. of test sites per group
Alberius et al. (1992)	Autologous bone, disc-shaped	ePTFE	Mandibular angle	Calvarial roof	Extraoral	16
Antoun et al. (2001)	Autologous bone	ePTFE	Mandible symphysis area	Maxilla and mandible	Intraoral approach	5
Chiapasco et al. (1999)	Autologous bone chips; corticocancellous bone blocks	ePTFE	Bone chips harvested intraorally; bone blocks from the chin, retromolar area, iliac crest and calvaria	Maxilla and mandible	Intraoral approach	15
Donos et al. (2002a)	Autologous cortical bone	ePTFE	Mandibular angle	Mandible, inferior border	Extraoral approach	6
Donos et al. (2002b)	Autologous cortical bone	ePTFE	Mandible	Maxilla	Intraoral	5
Donos et al. (2002c)	Autologous cortico-cancellous bone	ePTFE	Ischium	Maxilla and mandible	Intraoral (maxilla); extraoral approach (mandible)	6
Donos et al. (2005)	Autologous membranous, enchondral bone	ePTFE	Calvaria (membranous), ischium (enchondral)	Mandible, inferior border	Extraoral approach	8
Gordh et al. (1998)	Heterologous bone	ePTFE	Femur and tibia	Cranium under temporalis	Extraoral	7
Gordh et al. (1999)	Heterologous bone	ePTFE	Femur and tibia	Cranium under temporalis	Extraoral	6
Jensen et al. (1995)	Autologous bone	ePTFE	Iliac crest	Mandible	Extraoral approach	4
Lundgren et al. (1997)	Autologous bone	Poly (lactide-glycolide)	Skull	Skull	Extraoral	8
Rasmusson et al. (1999)	Autologous bone, disc-shaped	ePTFE	Calvarium	Proximal tibial metaphyses	Extraoral	6
Salata et al. (2002)	Autologous cortical bone	ePTFE	Radius	Mandibular inferior border	Extraoral approach	8
Von Arx et al. (2001)	Autologous bone	ePTFE	Molar area	Mandible	Intraoral approach	3

ePTFE = expanded polytetrafluoroethylene

NB = nota bene

No. and species	Follow-up	NB.	Limitations
28 rats	12 weeks	Inlay design also tested	Extra-oral implantation site; limited external validity; no data-assessment description
12 humans	6 months	Patients randomly allocated to membrane or graft-alone group	No split mouth design; follow up not long enough
30 humans	6 to 8 months	2 groups: bone blocks without barrier membrane (small and large defects); bone chips, membrane application (limited defects)	No statistical comparison because of bias resulting from treatment choice by clinician and differences in donor site and defect extension
30 rats	15, 30, 60, 120, 180 days		
20 rats	15, 30, 60, 90 days		Suitability of design doubtful: major parts of grafts was lost
51 rats	60, 120, 180 days	3 test groups: maxilla augmentation; mandible augmentation with gold-coated implant; mandible augmentation with titanium implants	Suitability of design doubtful: major parts of grafts was lost
25 rats	5 months, 11 months	4 test groups: membranous and enchondral bone transplanted to mandible (split-mouth) with or without membrane; animals sacrificed at 5 and 11 months; membrane removed after 5 months; 3 rats died during the experiments	Long follow-up considering faster metabolism
21 rats	12, 20 weeks	2 experiments: (1) membrane-covered and bare bone grafts; (2) both sides received barrier membranes. After 12 weeks membranes removed from 1 side	Extraoral implantation site; limited external validity
48 rats	4, 20 weeks	Aim of study was to measure the effect of rhBMP-2	Extraoral implantation site; limited external validity; different objective
4 dogs	6 months	Also augmentation with DFDB, irradiated DFDB, and controls injected with blood tested	Small number of test sites
8 rabbits	12 weeks	Round graft accompanied by particulate bone placed in circular defect	Extraoral implantation site; limited external validity; inlay design; particulate bone decisive factor
9 rabbits	8, 24 weeks	Barrier membrane removal after 8 weeks in all subjects, some followed for additional 16 weeks	Extraoral implantation site; limited external validity
14 rabbits	6, 24 weeks	Design in which implants were placed in 1 animal at different times on contra-lateral sides; implants examined at 6 and 24 weeks after placement	Different objective
3 dogs	6 months	Defects introduced 2 months before implantation	Inlay design

bone heights at the end of the experiment. Therefore, the authors concluded that barrier membranes do not have any preventive effect on bone resorption.

The studies performed by Jensen et al. (1995) and Antoun et al. (2001) revealed the opposite. They found significantly less bone resorption in the grafts covered with a barrier membrane. Jensen et al. (1995) stated that a barrier membrane improved both graft volume incorporated and bone-implant interface contact in fox hounds. The other study was performed on humans (Antoun et al. 2001). A positive effect of barrier membranes on bone resorption at 6 months following surgery was observed, and a longer follow-up was recommended.

All authors, except Alberius et al. (1992) and Gordh et al. (1998; 1999), used fixation screws or placed implants during the first surgery. Fixation screws can be applied in the GBR technique to secure the barrier membrane and/or graft. Alberius et al. (1992) stated that barrier membranes promote bone deposition in the freshly created defects. The onlay grafts generally resorbed, but the grafts covered by a barrier membrane seemed more active, developed an increased cancellous component, and showed less pronounced volumetric loss.

Donos et al. (2002a-c; 2005) experimented with different implants, implantation sites, and different types of bone. In 2 of these studies the rat maxilla was augmented in a split-mouth design (2002b,c). In both studies histologic analysis demonstrated that in situations where the barrier membrane was not exposed to the oral environment during healing, the grafts were in continuity or integrated with the bone at the recipient site. In the majority of cases, however, the barrier membrane became exposed or the graft and implant were lost. In these cases the grafts presented extensive resorption and there was lack of bone continuity. These findings correspond to those on the non-membrane-treated sites. The authors endorsed the importance of closure of the operated area.

In the other experiments mandibular augmentation procedures were tested (2002a,c; 2005). At the sites treated with barrier membranes, the grafts were integrated with the underlying or newly formed bone, and the dimensions of the alveolar ridge were increased. The grafts in the control groups presented significant gradual resorption and varying degrees of integration in the recipient bone.

The enchondral grafts showed more resorption than the membranous ones. No significant differences were found between groups treated with different types of micro-implants, except that the titanium implants demonstrated improved bone-implant contact. Removal of the membrane after a follow-up period of 5 months resulted in a decrease in dimensions at 11 months, with sizes similar to the baseline measurements (i.e., the measurement at implantation). At 5 months the dimensions were increased (Donos et al. 2005). The authors concluded that bone grafting in combination with barrier membrane application eliminates the risk of graft resorption and ensures integration. Furthermore, GBR improved the predictability of bone augmentation and provided long-term volume stability.

As shown in Table 2, all barrier membranes were composed of non-degradable ePTFE, except the degradable lactide-glycolide barrier membranes used by Lundgren et al. (1997). Statistically significant differences were found for height and volume of the augmented bone in favour of the covered transplants.

Discussion

In mandibular and maxillary augmentation procedures bio-degradable and non-degradable bone regenerating membranes are extensively applied for covering bone grafts and bone substitutes as part of pre-implant surgery. The rationale for this approach is that it may prevent resorption of onlay bone grafts and hold together granular bone substitutes or ground bone.

In a previous review, Nevins and Jovanovic (1997) concluded that large bone grafts used for ridge reconstruction purposes might benefit from barrier membranes because they reduce the inevitable resorption of bone grafts. However, their review included uncontrolled studies. More recently, clinical studies with sufficient numbers of patients have been performed; these studies have shown good results with barrier membranes in combination with autologous bone grafts. Nevertheless, most of these studies are uncontrolled (Lorenzoni et al. 2002) or used merely a barrier membrane or bone substitute combined with a barrier membrane as a control (Buser et al. 1998). Because

of this lack of adequate control groups, numerous articles were excluded from the present review, and this led to a minimal amount of useful data. Controlled trials comparing a degradable collagenous membrane/bone graft test group and an autologous graft control group were not found. Most studies on the use of a degradable collagenous membrane have focused on bone substitutes (Norton et al. 2003).

In this review, the prevention of bone resorption was chosen as the primary outcome variable, since the current method of choice is a staged approach (i.e., bone augmentation preceding implant placement) (Stellingsma et al. 2004). However, successful grafting is usually measured as a function of implant retention, despite significant resorption of the graft (Jensen et al. 1995).

It is difficult to draw a clinically relevant conclusion from the reviewed studies because of the small number of human studies and test sites, ambiguity, and lack of significant results. Because of major difference in outcome variables, measures, and study designs and lack of data-assessment description (Alberius et al. 1992), it was not possible to perform a meta-analysis. Therefore, the clustered effect size remains unknown. Consequently, the best available evidence supporting the use of barrier membranes to prevent bone resorption in autologous onlay bone grafts is weak. To actually answer the research question, randomised controlled trials should be performed and problems related to measuring bone volume must be solved.

In 12 articles, the authors stated that barrier membrane application was beneficial in the prevention of bone resorption; in 2 publications, it was not recommended that membranes be used to cover autologous onlay bone grafts (Chiapasco et al. 1999; Rasmusson et al. 1999).

Only 6 studies demonstrated statistically significant results (Jensen et al. 1995; Lundgren et al. 1997; Antoun et al. 2001; Donos et al. 2002a,c; Donos et al. 2005). However, the total number of test sites per group was rather small, i.e., 4-8 (Table 2). In contemporary science a minimum of 10 test sites has been proven necessary to gather reliable evidence in *in vivo* experiments (ISO, 1994). All reviewed studies use a marginal number of test-sites. None of the included studies reported sample size requirements. The required sample sizes are much larger than those that

have been generally used (Gunsolley et al. 1998). Three study designs (Table 2) performed measurements at only 1 time point in the follow-up, and no long-term follow-up was reported.

A general issue in animal experiments is interpretation of the data. According to Roberts et al. (1993) bone formation and remodeling is about 2 and 3 times faster in rabbits as compared to dogs and humans, respectively. It is hazardous to extrapolate the results to the human situation. Ideally, a human model is chosen, but it can be difficult to attain sufficient statistical power. Unfortunately, the included studies performed in humans have some additional drawbacks (Table 2) (Chiapasco et al. 1999; Antoun et al. 2001).

Donos et al. (2002a-c; 2005) used split-mouth designs. Overall, their experiments were well-designed (Table 2). Reproducibility was tested, and short- and long-term follow-up periods were applied. Their conclusions were based on objective measures. However, most of the designs of the included studies had some limitations that precluded a valid conclusion (Table 2).

Despite the paucity of data, it seems accepted that barrier membranes prevent bone resorption. Therefore, most research appears to be focused on the logical consequence of this (i.e., development of better membranes (Von Arx et al. 2002) or bone substitutes (Buser et al. 1998). Furthermore the studies yielded in this review show conclusions based on the assumption of a positive effect size. However, this review shows that the available evidence is weak. Some preventive effect may be expected (Donos et al. 2002a). Research should instead focus on the question 'Do barrier membranes prevent bone resorption in autologous onlay bone grafts?'

Thus, there is not sufficient evidence that barrier membranes prevent bone resorption in onlay bone grafts. This does not imply that this procedure is contraindicated in bone grafting, provided that (non-degradable) barrier membrane exposure is prevented during the healing period. Furthermore, most bone substitutes consist of small particles. These may be applied in combination with autologous bone chips or blocks, a situation that is often seen in clinical practice. When used with particulate bone products, barrier membrane application is necessary to secure these granules and not to prevent bone resorption.

In the authors' opinion, supported by the conclusions in the reviewed articles, the application of barrier membranes may have a positive effect; however, this conclusion remains to be firmly established. Future research with sufficient numbers of animals and test sites acquired by power-analysis, and, most importantly, randomised controlled trials should be executed to demonstrate clinical evidence in support of the use of barrier membranes.

In conclusion, drawn on the basis of the best available evidence, barrier membranes show some preventive effect on graft resorption. However, the evidence whereupon this conclusion is based is weak. Well-designed animal experiments and clinical randomized controlled trials are necessary to provide a definitive answer to the research question.

References

- Adell, R., Lekholm, U. & Branemark, P-I. (1985) Surgical procedures. In: Branemark, P-I., Zarb, G.A. & Albrektsson, T., eds. *Tissue-Integrated Prosthesis: Osseointegration in Clinical Dentistry*, p. 211-232. Chicago: Quintessence.
- Adell, R., Eriksson, B., Lekholm, U., Branemark, P-I. & Jemt, T. (1990) Long-term follow-up study of osseointegrated implants in the treatment of totally edentulous jaws. *Int J Oral Maxillofac Implants* 5: 347-359.
- Alberius, P., Dahlin, C. & Linde, A. (1992) Role of osteopromotion in experimental bone grafting to the skull: a study in adult rats using a membrane technique. *J Oral Maxillofac Surg* 50: 829-834.
- Antoun, H., Sitbon, J.M., Martinez, H. & Missika, P. (2001) A prospective randomized study comparing two techniques of bone augmentation: onlay graft alone or associated with a membrane. *Clin Oral Implants Res* 12: 632-639.
- Buser, D., Dula, K., Hirt, H.P. & Schenk, R.K. (1996) Lateral ridge augmentation using autografts and barrier membranes: a clinical study with 40 partially edentulous patients. *J Oral Maxillofac Surg* 54: 420-432.
- Buser, D., Hoffmann, B., Bernard, J.P., Lussi, A., Mettler, D. & Schenk, R.K. (1998) Evaluation of filling materials in membrane-protected bone defects. A comparative histomorphometric study in the mandible of miniature pigs. *Clin Oral Implants Res* 9: 137-150.
- Chiapasco, M., Abati, S., Romeo, E. & Vogel, G. (1999) Clinical outcome of autogenous bone blocks or guided bone regeneration with ePTFE membranes for the reconstruction of narrow edentulous ridges. *Clin Oral Implants Res* 10: 278-288.
- Clarizio, L.F. (1999) Successful implant restoration without the use of membrane barriers. *J Oral Maxillofac Surg* 57: 1117-1121.
- Donos, N., Kostopoulos, L. & Karring, T. (2002a) Augmentation of the mandible with GTR and onlay cortical bone grafting. An experimental study in the rat. *Clin Oral Implants Res* 13: 175-184.
- Donos, N., Kostopoulos, L. & Karring, T. (2002b). Alveolar ridge augmentation by combining autogenous mandibular bone grafts and non-resorbable membranes. An experimental study in the rat. *Clin Oral Implants Res* 13: 185-191.
- Donos, N., Kostopoulos, L. & Karring, T. (2002c) Augmentation of the rat jaw with autogeneic cortico cancellous bone grafts and guided tissue regeneration. *Clin Oral Implants Res* 13: 192-202.
- Donos, N., Kostopoulos, L., Tonetti, M. & Karring, T. (2005) Long-term stability of autogenous bone grafts following combined application with guided bone regeneration. *Clin Oral Implants Res* 16: 133-139.
- Gordh, M., Alberius, P., Johnell, O., Lindberg, L. & Linde, A. (1998) Osteopromotive membranes enhance onlay integration and maintenance in the adult rat skull. *Int J Oral Maxillofac Surg* 27: 67-73.
- Gordh, M., Alberius, P., Johnell, O., Lindberg, L. & Linde, A. (1999) Effects of rhBMP-2 and osteopromotive membranes on experimental bone grafting. *Plast Reconstr Surg* 103: 1909-1918.
- Gunsolley, J.C., Elswick, R.K. & Davenport, J.M. (1998) Equivalence and superiority testing in regeneration clinical trials. *J Periodontol* 69: 521-527.
- Hallman, M., Sennerby, L. & Lundgren, S. (2002) A clinical and histologic evaluation of implant integration in the posterior maxilla after sinus floor augmentation with autogenous bone, bovine hydroxyapatite, or a 20:80 mixture. *Int J Oral Maxillofac Implants* 17: 635-643.
- Hollinger, J.O., Buck, D.C. & Bruder, S.P. (1999) Biology of bone healing: its impact on clinical therapy. In: Lynch, S.E., Genco, R.J. & Marx, R.E., eds. *Tissue engineering. Applications in maxillofacial surgery and periodontics*, p. 17-53. Chicago: Quintessence.
- International Organisation for Standardization (ISO). (1994) Biological evaluation of medical devices-part 6: Tests for local effects after implantation (ISO 10993-6). Geneva, Switzerland: ISO.
- Jensen, O.T., Greer, R.O., Johnson, L. & Kassebaum, D. (1995)

Vertical guided bone-graft augmentation in a new canine mandibular model. *Int J Oral Maxillofac Implants* 10: 335-344.

Linde, A., Alberius, P., Dahlin, C., Bjurström, K. & Sundin, Y. (1993) Osteopromotion: a soft-tissue exclusion principle using a membrane for bone healing and bone neogenesis. *J Periodontol* 64: 1116-1128.

Lorenzoni, M., Pertl, C., Polansky, R.A., Jakse, N. & Wegscheider, W.A. (2002) Evaluation of implants placed with barrier membranes. A retrospective follow-up study up to five years. *Clin Oral Implants Res* 13: 274-280.

Lundgren, A.K., Lundgren, D., Sennerby, L., Taylor, A., Gottlow, J. & Nyman, S. (1997) Augmentation of skull bone using a bioresorbable barrier supported by autologous bone grafts. An intra-individual study in the rabbit. *Clin Oral Implants Res* 8: 90-95.

Machtej, E.E. (2001) The effect of membrane exposure on the outcome of regenerative procedures in humans: a meta-analysis. *J Periodontol* 72: 512-516.

Merx, M.A., Maltha, J.C., Freihofer, H.P. & Kuijpers-Jagtman, A.M. (1999) Incorporation of particulated bone implants in the facial skeleton. *Biomaterials* 20: 2029-2035.

Mundell, R.D., Mooney, M.P., Siegel, M.I. & Losken, A. (1993) Osseous guided tissue regeneration using a collagen barrier membrane. *J Oral Maxillofac Surg* 51: 1004-1012.

Nevins, M. & Jovanovic, S.A. (1997) Localized bone reconstruction as an adjunct to dental implant placement. *Curr Opin Periodontol* 4: 109-118.

Norton, M.R., Odell, E.W., Thompson, I.D. & Cook, R.J. (2003) Efficacy of bovine bone mineral for alveolar augmentation: a human histologic study. *Clin Oral Implants Res* 14: 775-783.

Ogiso, B., Hughes, F.J., Melcher, A.H. & McCulloch, C.A. (1991) Fibroblasts inhibit mineralised bone nodule formation by rat bone marrow stromal cells in vitro. *J Cell Physiol* 146: 442-450.

Olson, J.W., Dent, C.D., Morris, H.F. & Ochi, S. (2000) Long-term assessment (5 to 71 months) of endosseous dental implants placed

in the augmented maxillary sinus. *Ann Periodontol* 5: 152-156.

Rasmusson, L., Meredith, N., Kahnberg, K.E. & Sennerby, L. (1999) Effects of barrier membranes on bone resorption and implant stability in onlay bone grafts. An experimental study. *Clin Oral Implants Res* 267-277.

Roberts, E., Garetto, L. & Brezniak, N. (1993) Bone physiology and metabolism. In: Misch, C., ed. Contemporary implant dentistry, p. 327-353. St Louis: Mosby.

Salata, L.Z., Rasmusson, L. & Kahnberg, K.E. (2002) Effects of a mechanical barrier on the integration of cortical onlay bone grafts placed simultaneously with endosseous implant. *Clin Implant Dent Relat Res* 4: 60-68.

Stellingsma, C., Vissink, A., Meijer, H.J., Kuiper, C. & Raghoobar, G.M. (2004) Implantology and the severely resorbed edentulous mandible. *Crit Rev Oral Biol Med* 15: 240-248.

Sulzer, T.H., Bornstein, M.M. & Buser, D. (2004) Indications for oral implantology in a referral clinic. A three-year retrospective analysis of 737 patients with 1176 implants. *Schweiz Monatsschr Zahnmed* 114: 444-450.

Von Arx, T., Cochran, D.L., Schenk, R.K. & Buser, D. (2002) Evaluation of a prototype trilayer membrane (PTLM) for lateral ridge augmentation: an experimental study in the canine mandible. *Int J Oral Maxillofac Surg* 31: 190-199.

Von Arx, T., Cochran, D.L., Hermann, J.S., Schenk, R.K. & Buser, D. (2001) Lateral ridge augmentation using different bone fillers and barrier membrane application. A histologic and histomorphometric pilot study in the canine mandible. *Clin Oral Implants Res* 12: 260-269.

Zellin, G. & Linde, A. (1997) Importance of delivery systems for growth-stimulatory factors in combination with osteopromotive membranes. An experimental study using rhBMP-2 in rat mandibular defects. *J Biomed Mater Res* 35: 181-190

Zitzmann, N.U., Naef, R. & Scharer, P. (1997) Resorbable versus nonresorbable membranes in combination with Bio-Oss for guided bone regeneration. *Int J Oral Maxillofac Implants* 12: 844-852.

Zitzmann, N.U., Schärer, P. & Marinello, C.P. (2001) Long-term results of implants treated with guided bone regeneration: A 5-year prospective study. *Int J Oral Maxillofac Implants* 16: 355-366.

The subcutaneous and subperiosteal tissue reaction to poly(DL-lactide- ϵ -caprolactone) and ePTFE barrier membranes

3

This chapter is an edited version of the manuscript:

Gielkens, P.F.M., van Leeuwen, M.B.M., van Kooten, T.G., Stegenga, B. & Bos, R.R.M.

The subcutaneous and subperiosteal tissue reaction to poly(DL-lactide- ϵ -caprolactone) and ePTFE barrier membranes. *Submitted.*

Abstract

Objectives:

The tissue-biomaterial response of a new poly(DL-lactide- ϵ -caprolactone) (PDLLCL) barrier membrane was compared to that of an ePTFE membrane. Furthermore it was explored whether it is valid to test these biomaterials only subcutaneously, when in clinical practice the barrier membranes will be applied subperiosteally.

Material and Methods:

In each of 36 rats a total of 4 discs, 2 PDLLCL and 2 ePTFE, were implanted subcutaneously in the back and subperiosteally onto the mandible. Groups of 6 rats were sacrificed at 6, 12, 26, 48, 65 and 81 weeks after implantation. The samples were evaluated by light microscopy using a semi-quantitative scoring method.

Results:

No anomalies in tissue healing were seen except that ePTFE evoked a response of phagocytes and lymphocytes. Folding was predominantly seen in PDLLCL. Minor differences in the tissue reaction and degradation of PDLLCL were seen subcutaneously when compared to subperiosteally.

Conclusions:

PDLLCL tested to be degradable and biocompatible. Probably, the minor differences between both implant sites will not influence the clinical results of the final device. Less radical surgery, a simpler histological procedure, and a larger number of test sites appear more decisive than the implantation site. It therefore seems appropriate to evaluate a biomaterial for biocompatibility and degradation subcutaneously, when the final application is subperiosteally.

Introduction

Guided bone regeneration (GBR) is an applied modality in maxillofacial surgery to solve the problem of bone deficiency. In GBR a barrier membrane covers the defect, prevents in-growth of fibroblasts and provides a space for osteogenesis within a blood clot formed in the defect (Hollinger et al. 1999). Although different barrier membranes have been developed, the ideal barrier membrane is not yet available. An optimal barrier membrane should be, among other things, biocompatible, synthetic and degradable (Kay et al. 1997; von Arx et al. 2002).

Recently, a new synthetic degradable barrier membrane composed of poly(DL-lactide-ε-caprolactone) (PDLLCL) (Meek et al. 2004) has been developed for GBR. Short-term *in vivo* and *in vitro* research have shown that this copolymer is both degradable and biocompatible (Meek et al. 2004). In the 1980s, the necessity of long-term *in vivo*-experiments has been illustrated by the occurrence of harmful crystalline PLLA particles after long-term degradation of seemingly biodegradable materials (Bergsma et al. 1995). Long-term biocompatibility and degradation testing of PDLLCL should, therefore, be implemented.

The implantation site of the polymer influences the polymer behaviour *in vivo* (Kaminski et al. 1968). As a result the final device designs in maxillofacial surgery are usually evaluated in their eventual anatomic (i.e., subperiosteal) environment. Nevertheless the polymers are often implanted and evaluated subcutaneously (Williams et al. 1997). To our knowledge it has not been established that biocompatibility and degradation are similar at subcutaneous and subperiosteal implant sites. Therefore, subperiosteal rather than subcutaneous biocompatibility and degradation studies would be preferred for biomaterials that will eventually be applied subperiosteally.

All previous *in vivo* tests for the PDLLCL copolymer were short-term studies in a subcutaneous environment, and not subperiosteally. Furthermore, a commercially available nerve guide (Neurolac®, Polyganics, Groningen, The Netherlands) composed of an identical PDLLCL copolymer has also only been tested and applied in soft tissue (Bertleff et al. 2005). Thus, the copolymer PDLLCL has never been evaluated subperiosteally in the long term, whereas the

envisaged final device is a barrier membrane which will be applied subperiosteally.

Therefore, the aim of this long-term experiment was to compare PDLLCL to ePTFE, the latter being a standard reference membrane in GBR studies, in a subcutaneous as well as a subperiosteal environment. Furthermore it is explored whether it is valid to test biomaterials only subcutaneously, when the final device will be applied in a subperiosteal environment.

Material and Methods

Materials

A biodegradable poly(DL-lactide-ε-caprolactone) (PDLLCL) barrier membrane was used as test material. This customized copolymer sheet consists of 67-69% DL (15-85)-lactide and 31-33% ε-caprolactone (Vivosorb®, Polyganics, Groningen, The Netherlands). Circular discs with a diameter of 8.0 mm were taken from a sheet with an average thickness of 0.10 mm. The material was sterilized with ethylene oxide.

Commercially available expanded polytetrafluoroethylene barrier membranes (ePTFE, Gore-Tex®, W.L.Gore & Associates, Flagstaff, USA) served as a non-degradable synthetic, biocompatible control. Measurements and treatment of ePTFE discs corresponded with that of PDLLCL.

All the samples were marked with a polypropylene 4-0 suture (Prolene®, Ethicon, Johnson & Johnson, Amersfoort, The Netherlands).

Animals and study-design

Thirty-six male Sprague-Dawley rats were operated. The biomaterials were positioned subcutaneously in the back and subperiosteally to the mandible. A total of 4 discs, 2 PDLLCL and 2 ePTFE were implanted in each rat. The sample configuration of the implants was varied to exclude influences of the site of implantation.

Groups of 6 rats were sacrificed at 6, 12, 26, 48, 65 and 81 weeks after implantation. The biomaterial and surrounding tissue were dissected and processed for histological light microscopic evaluation.

The study protocol was approved by the animal study

review committee, and in accordance with Institutional Guidelines (University Medical Center Groningen, Groningen, The Netherlands).

Surgical procedure

The animals were anaesthetized with nitrous-oxygen-isoflurane. The mandibular hemicervical areas and the back were shaved and disinfected. At the submandibular sites incisions were made and the masseter muscle was exposed. At the buccal side the muscle was incised along the submandibular border and a muscle flap, including the periosteum, was raised to position the biomaterial subperiosteally. Care was taken not to injure the facial nerve, parotic duct and periosteum. The wound was closed in tissue layers using 4-0 resorbable sutures (Vicryl® Rapide 4-0, Ethicon, Johnson & Johnson, Amersfoort, The Netherlands). The contralateral side was implanted with the other biomaterial using the same operative procedures.

At the subcutaneous sites 2 pockets were created in the back at the left and right side. Both biomaterials were implanted and the wound was closed using 4-0 resorbable sutures. A single dose of Caprofen (4.0 mg/kg) and Temgesic (0.03 mg/kg) were administered for postoperative pain relieve. The rats were housed in groups and received softened standard laboratory food for 3 days prior to surgery up to 4 days postoperatively. Thereafter, the animals received pellets. Water was administered ad libitum.

At the different time intervals, the rats were anaesthetized with nitrous-oxygen-isoflurane and sacrificed by an intracardial injection of pentobarbital. The mandible including the masticatory muscles was explanted and fixed in 4% phosphatebuffered formaline solution. After fixation the masseter muscle region of both sides of the mandible was carefully explored for the reference polypropylene sutures. A frontal section of 0.5 cm thick was prepared yielding a section of the jawbone with surrounding soft tissue.

The skin of the back was carefully prepared and the samples were located with aid of the reference sutures and inspected macroscopically. The samples were then explanted and fixed in 4% phosphatebuffered formaline solution, awaiting histology.

Histology

The samples were embedded in GMA and sections of 2 μ m were obtained. The sections were stained with Toluidin Blue and Toluidin Blue in combination with Basic Fuchsin as counterstain. The tissue-biomaterial response was evaluated by light microscopy using a semi-quantitative scoring method.

All parameters were scored at an ordinal scale 0 to 4 (Tables 1 - 4). From each sample 1 section was evaluated by 2 observers. Both observers had to reach agreement for each sample.

Results

Thirty-six rats (mean weight 367 g \pm 15 g SD, range 333-393 g) were divided into 6 groups. No wound infection or dehiscence did occur postoperatively and all animals gained weight during this long-term study. One rat had to be euthanized prematurely at 74 weeks due to a tumour in the mandible.

Subcutaneous implants

By macroscopic evaluation of the subcutaneous samples no clinical signs of inflammation or necrosis were found. The PDLCL samples were rather difficult to retrieve at long-term intervals, due to the more degraded state of the biomaterial. In the 26 to 81 weeks samples only the non-degradable suture could be seen macroscopically. During this period the appearance of fat and degrading biomaterial was similar. No anomalies were observed. At all times the ePTFE samples were easily retrieved. The samples were found embedded in normal fibrous and fatty tissue. The results of the histological evaluation of the subcutaneous implants are summarized in Tables 1 and 2. Degradation and fragmentation increased from 6 to 81 weeks in the PDLCL samples. At 81 weeks the only degradation products of the biomaterial that could be recognized were some small particles inside macrophages. Also phagocytosis increased with time. Although the absolute number of phagocytes decreased in the long term, phagocyte activity as well as the number of phagocytes relative to the amount of biomaterial still present increased. At 81 weeks phagocytosis was therefore maximal. Vascularization had

Table 1. Histological results of subcutaneously implanted PDLLCL.

	6 weeks	12 weeks	26 weeks	48 weeks	65 weeks	81 weeks
Number of evaluated samples	5/6	4/6	5/6	6/6	5/6	4/5
Degradation*	0	0	1	2.2	2.5	>4
Fragmentation*	0.2	0.1	0.8	3	3	>4
Phagocytosis*	1.6	1.3	1.4	2.7	2.5	4
(Chronic) inflammatory response*	0.4	0	0	0	0.1	0
Vascularization*	1.9	1.5	1.3	1.1	1.3	1
Fibrous capsule*	1.1	1.1	1.6	1.3	1.1	0
Spatial configuration: folding*	3.2	4	4	4	-	-

Table 3. Histological results of subperiosteally implanted PDLLCL.

	6 weeks	12 weeks	26 weeks	48 weeks	65 weeks	81 weeks
Number of evaluated samples	6/6	6/6	6/6	5/6	6/6	5/5
Degradation*	0	0.6	1.8	1.7	3.9	>4
Fragmentation*	0.5	0.6	2.2	2.4	4	>4
Phagocytosis*	2	2	2	2.1	2.1	4
(Chronic) inflammatory response*	0	0	0	0	0	0
Vascularization*	2.1	2.3	1.8	1.4	1.9	1.2
Fibrous capsule*	2.2	2.4	2.3	3	0.2	0
Spatial configuration: folding*	2.3	2.8	1.8	1.2	-	-

Table 2. Histological results of subcutaneously implanted ePTFE.

	6 weeks	12 weeks	26 weeks	48 weeks	65 weeks	81 weeks
Number of evaluated samples	6/6	5/6	6/6	6/6	6/6	4/5
Degradation*	0	0	0	0	0	0
Fragmentation*	0	0	0	0	0	0
Phagocytosis*	1.3	0.5	0.8	0.9	1	1
(Chronic) inflammatory response*	1.5	0.5	0.6	0.3	0.1	0
Vascularization*	1.3	1	1	0.9	0.8	0.8
Fibrous capsule*	0.8	1.1	0.8	0.6	0.8	1
Spatial configuration: folding*	0.2	0	0.7	0.8	0.6	0.5

Table 4. Histological results of subperiosteally implanted ePTFE.

	6 weeks	12 weeks	26 weeks	48 weeks	65 weeks	81 weeks
Number of evaluated samples	5/6	6/6	6/6	6/6	6/6	5/5
Degradation*	0	0	0	0	0	0
Fragmentation*	0	0	0	0	0	0
Phagocytosis*	1	1.5	1.6	1.8	1.3	0.7
(Chronic) inflammatory response*	0.3	0	0	0.3	0	0
Vascularization*	1	1.2	1.1	0.8	0.8	0.9
Fibrous capsule*	0.9	1.3	0.8	0.8	0.7	1.5
Spatial configuration: folding*	1.4	0.5	0.3	0.2	0.3	0.4

* Each sample was scored on a 5 points scale 0 - 4 for each item. The means, the sum divided by the number of evaluated samples, is depicted for each item. *Degradation*: disintegration of the biomaterials from a solid to a dissolved state. *Fragmentation*: the falling apart of the biomaterial in different pieces. *Phagocytosis*: phagocyte activity as well as the number of phagocytes relative to the amount of degrading biomaterial. *(Chronic) inflammatory response*: presence of lymphocytes and monocytes relative to the amount of biomaterial.

increased and gradually returned to normal at 81 weeks. The fibrous capsule was similar during 6 to 65 weeks, whereas at 81 weeks a fibrous capsule was absent. The number of monocytes and lymphocytes was within a normal range, except at 6 and 65 weeks in 1 of 5 rats. All measurements were scored relatively to ePTFE. Vascularization, fibrous capsule and, surprisingly, phagocytosis of this non-degradable biomaterial remained stable at a lower level compared to PDLLCL. However, this did not apply to the number of monocytes and lymphocytes, which was more pronounced in more than half of the ePTFE samples, particularly in the first year. The spatial configuration of the PDLLCL samples were found to fold more easily than the ePTFE samples after insertion.

Subperiosteal implants

All subperiosteal samples were retrieved at the buccal part of the mandible. All ePTFE samples could be detected macroscopically. However, in most samples the polypropylene reference suture was needed to detect the location where the biomaterial was situated. In the PDLLCL samples no biomaterial was macroscopically seen after 26 weeks. No anomalies were observed in the tissue.

The histological results of the subperiosteal implants (Tables 3 and 4) showed an increasing degradation and fragmentation of the PDLLCL samples from 6 to 81 weeks. Phagocytosis of the PDLLCL samples increased during the total follow up. The fibrous capsule was stable until 48 weeks; subsequently it disappeared. Vascularization was increased and returned to normal levels at 81 weeks.

The fibrous capsule and vascularization of the ePTFE samples were constant throughout the experiment, whereas phagocytosis of small fragments was slightly increased during the first year. All parameters were on average at a lower level compared to PDLLCL, except for the raised amount of monocytes and lymphocytes in 3 of 5 and in 3 of 6 rats at 6 and 48 weeks, respectively. The spatial configuration of PDLLCL samples were found to fold more often than the ePTFE samples.

In a few cases new bone formed around the ePTFE membranes. New bone was also seen around the PDLLCL copolymer. Signs of increased resorption of the underlying bone were not seen.

Subcutaneous vs. subperiosteal implant sites

The results of the PDLLCL samples showed that the phagocytosis, inflammatory response, and vascularization were in the same range subcutaneously and subperiosteally. Subperiosteal implants tended to degrade and fragment somewhat earlier than subcutaneous implants (Fig. 1). Relatively to the ePTFE controls, thicker fibrous capsules were seen subperiosteally compared to subcutaneously.

The ePTFE samples showed more phagocytosis subperiosteally except for the 6 and 81 weeks samples, whereas a higher number of monocytes and lymphocytes was found in the subcutaneous implants during the first year. Vascularization and the fibrous capsule tended to be within the same range at both implant sites.

In regard to the spatial configuration more folds were seen in the subcutaneous compared to the subperiosteal PDLLCL samples, while this was hardly observed in the ePTFE samples.

Discussion

In this study PDLLCL samples demonstrated a normal tissue healing (Anderson 2004), which suggest biocompatibility. Furthermore the polymer showed to be degradable. More vascularization as well as thicker fibrous capsules were seen in the PDLLCL samples than in the ePTFE samples. PDLLCL implanted as foam demonstrated thinner capsules than in the present study and the capsules disappeared after 1 year (Van Minnen et al. 2007). Around the degradable copolymer poly(TMC-DLLA) thicker capsules similar to the presents study were found (Pêgo et al. 2003).

Both subcutaneous and subperiosteal samples showed fragmentation after 6 weeks. Further degradation was first observed at 12 weeks subperiosteally and at 26 weeks subcutaneously. It is well known that the maxillofacial area is well perfused (Schortinghuis et al. 2005), possibly causing the earlier degradation subperiosteally as seen (Fig. 1). However, in our study fewer vessels were observed subperiosteally in absolute numbers. Both *in vitro* (Meek et al. 2004) and *in vivo* (Den Dunnen et al. 1997) studies have also shown that PDLLCL is biocompatible and degradable. In these studies detectable degradation of the copolymers started at 10 to 12 weeks, respectively *in vitro* and *in vivo*.

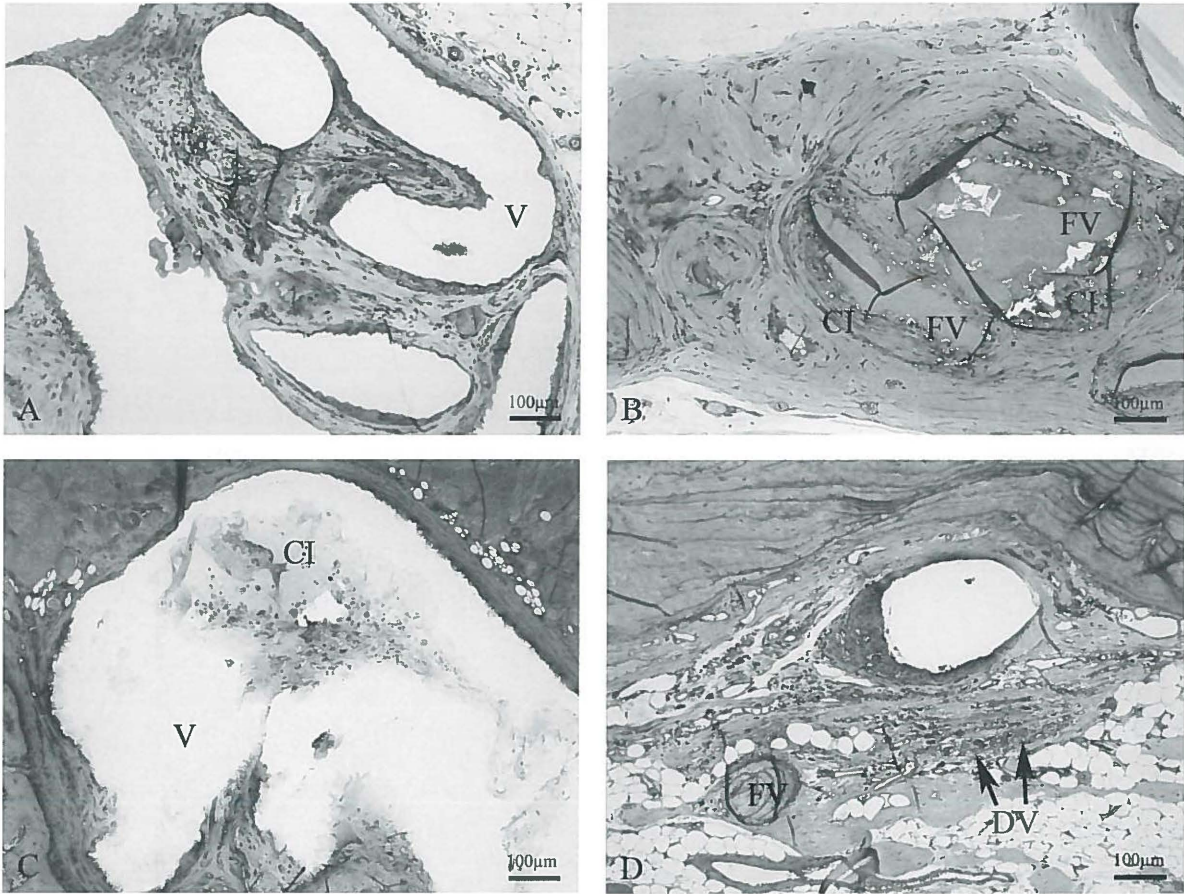


Fig. 1. Degradation of subcutaneous (A and B) and subperiosteal (C and D) implanted PDLLCL. Fig. A, PDLLCL (V) at 6 weeks subcutaneously, shows no degradation. Fig. B, PDLLCL at 65 weeks subcutaneously, demonstrates progressed fragmentation (FV) and cellular infiltration (CI), but no full degradation. A score of respectively 0 en 3, was assigned for degradation. Fig. C, PDLLCL (V) at 6 weeks subperiosteally, shows a limited infiltration (CI) and no fragmentation. No degradation is observed. Fig. D, PDLLCL at 65 weeks subperiosteally, shows an optimal cellular infiltration and a nearly complete fragmentation and degradation (DV). One remnant PDLLCL (FV) is still present. A score of respectively 0 and 3.5 was assigned. Overall, subperiosteal implants tended to degrade and fragment somewhat earlier than subcutaneous implants. (PDLLCL, 6 and 65 weeks, Toluidin Blue, bar = 100 µm)

Note that Den Dunnen et al. (1997) tested a nearly identical material during a longer follow-up of 12 months. At 12 months the biomaterial was still detected with light microscopy. In the present study, at 81 weeks the only PDLLCL biomaterials detectable by light microscopy were small remnants of the copolymer incorporated in macrophages. In a recent experiment the same copolymer as in the present study was implanted subcutaneously in rats

and rabbits (Van Minnen et al. 2007). Transmission electron microscopy in that study showed intracellular degradation products up to 3 years (in rabbits). In that study the PDLLCL was implanted as foams instead of sheets and, thus, degradation was faster since a larger surface area is accessible for hydrolysis and macrophage action (Agrawal et al. 1995). It is likely that the PDLLCL copolymer used in the present study will not be fully degraded after 3 years,

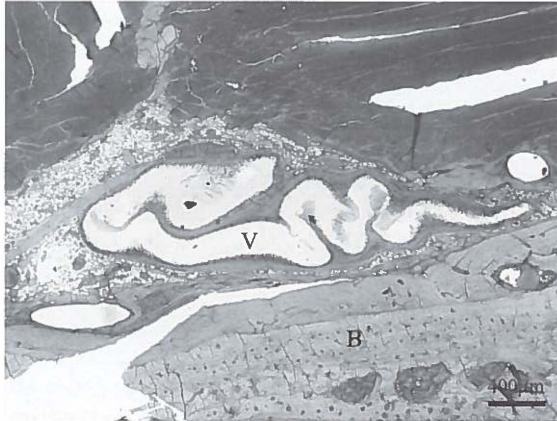


Fig. 2. The PDLLCL (V) membranes tended to fold easily after insertion, indicating potential problems when applied as a barrier membrane to bony (B) defects.
(PDLLCL, 12 weeks, Toluidin Blue/Basic Fuchsin, bar = 400 μm)

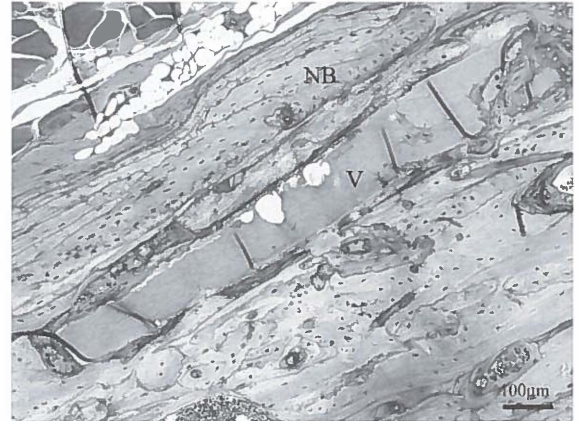


Fig. 4. New bone (NB) is formed around the PDLLCL (V) membrane.
(PDLLCL, 48 weeks, Toluidin Blue, bar = 100 μm)

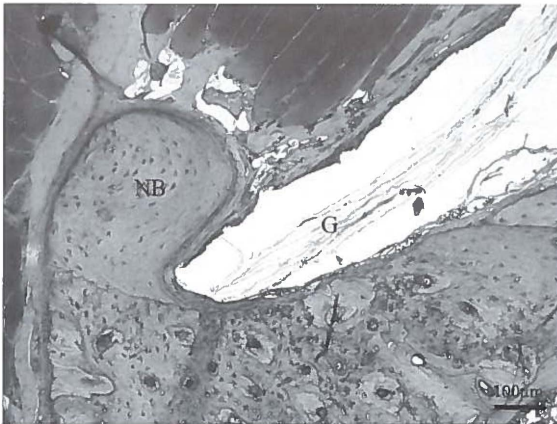


Fig. 3. New bone (NB) formation is observed around the ePTFE (G) membrane.
(ePTFE, 12 weeks, Toluidin Blue, bar = 100 μm)

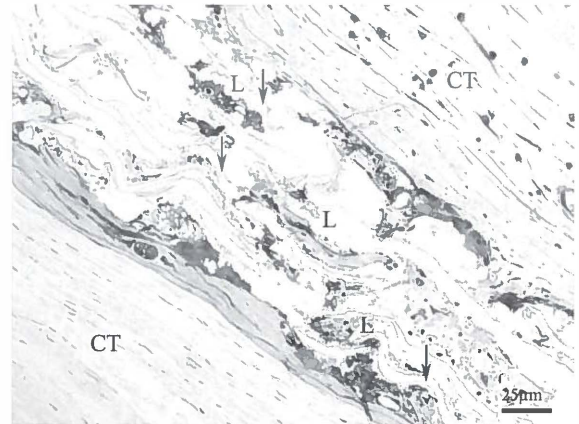


Fig. 5. In contrary to the assumption that ePTFE is inert, infiltration of cellular tissue is seen between the lamellar structures of the ePTFE membranes.
(ePTFE, 26 weeks, Toluidin Blue, bar = 25 μm, CT = connective tissue, ↓ = lamellar ePTFE, L = cellular tissue)

although most biomaterial degraded after 81 weeks. Some additionally evaluated parameters were spatial configuration of the biomaterials and the influence of the biomaterials on bone. It has been noted that PDLLCL tended to fold (Fig. 2), leading to a loss of surface contact of the membrane to bone. The contact loss was also seen in ePTFE samples, but folding was almost never seen. Contact between the barrier membrane and bone surrounding the defect is a necessity in GBR. The contact loss may have a negative effect on the application as a barrier membrane. However, the clinical consequences of the folding of this copolymer have to be evaluated in a final device design. The influence of the biomaterials on bone was also evaluated because past studies described that degradation products of barrier membranes might influence bone modeling (Mueller et al. 2005). No influence on bone modeling was seen in the present study except for some bone grown around ePTFE and PDLLCL samples (Fig. 3 and Fig. 4, respectively). This has been reported for ePTFE in other studies as well (Piattelli et al. 1996).

A remarkable finding was that, particularly at subcutaneous sites, phagocytes were present in ePTFE samples (Fig. 5), although the material is considered to be inert and non-degrading (Calisanellet al. 2004), with only a fibrous capsule formation as foreign body response. Moreover, monocytes and lymphocytes were seen in the present study. Liu et al. (2001) found a similar non-specific reaction with macrophages and lymphocytes with ePTFE and biodegradable poly(DL-lactide) membranes tested subcutaneously in rats. Problems with infected ePTFE membranes in the clinic have been encountered, due to tissue dehiscence of the oral mucosa (Wang & Carroll 2001; Machtei 2001). The textual and structural characteristics of ePTFE membranes contributes to bacterial adhesion (Zucchelli, 1998). Theoretically, the samples in the present study could be secondary infected. However, this is not plausible because no dehiscence was seen and the surgical procedure took place via an extra-oral and sterile approach. No clinical signs of inflammation were observed either. Therefore, in the present study it seemed that the material itself provokes some chronic inflammatory reaction in the subcutaneous samples. During the total implantation time this phenomenon decreased, possibly due to an increase of tissue tolerance to ePTFE.

At 74 weeks 1 rat developed a bone tumour in the jaw at the site where ePTFE was implanted. The cause is probably a spontaneously developed tumour, as is frequently seen in older laboratory animals (Altman & Goodman, 1979). Furthermore, the non-carcinogenicity of ePTFE was demonstrated in a subcutaneous implantation study in the flank of mice (Witherspoon et al. 2004). Moreover, in other larger series of rats where ePTFE is used to cover defects or grafts in the mandible no tumours were described (Schortinghuis et al. 2004; Gielkens et al. 2008).

An important factor that can affect biocompatibility and degradation is the site of implantation (Williams et al. 1997; Luttikhuisen et al. 2006). Aebischer et al. (1988) found differing responses to polymers when comparing subcutaneous and infrarenal position and Bergsma et al. (1995) found different tissue reactions with subcutaneous compared to intraosseous implants.

Contrary to these earlier studies, tissue reactions of subcutaneous and subperiosteal implants in the present study were quite similar. However, one must consider the fact that parameters are scored relatively to the control of each corresponding implant site as well as the normal histology of the site. In regard to vascularization, normal histological subperiosteal tissue expresses fewer vessels compared to subcutaneous tissue. However, at ePTFE implant sites a score of 1 (i.e., normal) was both given to the different implant sites. Thus the score was determined by the implant at the individual defined site. The vascularization in the subperiosteal samples would therefore in absolute numbers be lower when compared to subcutaneous samples. The same accounts for the size of fibrous capsules, which seemed thicker in the subperiosteal PDLLCL samples compared to the subcutaneous PDLLCL. Expressed in absolute values, the subperiosteal ePTFE samples evoke thinner fibrous capsules than subcutaneous. Therefore the fibrous capsules of the PDLLCL samples are, in absolute values, similar at both implant sites.

The subperiosteal degradation and fragmentation started at an earlier stage compared to subcutaneous, but the course of degradation and fragmentation was similar at both implant sites. In another study (Beumer et al. 1994) it was shown that the polymers tested degraded faster subcutaneously than intramuscular. In the same study most other parameters were similar at both sites.

Overall, in the present study only minor differences between both implant sites were observed and therefore the necessity of a subperiosteal study design in further biomaterial testing is questionable. Moreover, the frequently used subcutaneous study design means a simple and for the animal last drastic surgical procedure. Also the samples for histological evaluation can easily be obtained. Furthermore, the number of test sites in 1 animal should be as high as reasonably possible with respect to animal welfare. In the present study 6 rats per group were operated because only 2 samples could be placed subperiosteally. In a subcutaneous design 6 samples may be dorsally placed in rats. Because a subcutaneous design seems sufficient, fewer animals can be used.

Overall, PDLLCL tested to be biocompatible and degradable. Although minor differences were seen, the tissue reaction and degradation of PDLLCL were in the same range subcutaneously when compared to subperiosteally. We may assume that these minor differences between both implant sites will not influence the clinical results of the final device. Factors such as a less complex operation and a more simple histological procedure as well as a larger number of test sites appear decisive. Therefore, it seems appropriate to evaluate a biomaterial for biocompatibility and degradation subcutaneously, even when the final application is subperiosteally.

Acknowledgements

Gratitude is expressed to Mr. H. Bartels and Ms. Y. Heddemma for their assistance during the surgical procedures. We would like to thank Polyganics for the provision of the Vivosorb® membranes and W.L.Gore & Associates for the Gore-Tex® Regenerative Membranes.

References

- Aebischer, P., Goddard, M.B., Sassen, H.F., Hunter, T.J. & Galletti, P.M. (1988) Tissue reaction to fabrics coated with turbostratic carbon: subcutaneous versus vascular implants. *Biomaterials* 9: 80-85.
- Agrawal, C.M., Niederauer, G.G. & Athanasiou, K.A. (1995) Fabrication and characterization of PLA-PGA orthopaedic implants. *Tissue Eng* 1: 241-252.
- Altman, N.H. & Goodman, D.G. (1979) Neoplastic diseases. In: Baker, H.J., Lindsay, J.R. & Weisbroth, S.H., eds. *The laboratory rat. Biology and diseases*, p. 333-376. New York, London, Toronto, Sidney, San Francisco: Academic Press.
- Anderson, J.M. (2004) Inflammation, wound healing, and the foreign-body reaction. In: Ratner, B.D., Hoffman, A.S., Schoen, F.J. & Lemons, J.E., eds. *Biomaterials Science. An introduction to materials in medicine*, p. 296-304. San Diego: Elsevier Academic Press.
- Bergsma, J.E., de Bruijn, W.C., Rozema, F.R., Bos, R.R.M. & Boering, G. (1995) Late degradation tissue response to poly(L-lactide) bone plates and screws. *Biomaterials* 16: 25-31.
- Bertleff, M.J., Meek, M.F. & Nicolai, J.P. (2005) A prospective clinical evaluation of biodegradable neuroloc nerve guides for sensory nerve repair in the hand. *J Hand Surg* 30: 513-518.
- Beumer, G.J., van Blitterswijk, C.A. & Ponc, M. (1994) Degradative behaviour of polymeric matrices in (sub)dermal and muscle tissue of the rat: a quantitative study. *Biomaterials* 15: 551-559.
- Calisanel, T., Bavbek, M., Demirhan, B., Caner, H. & Altinörs, N. (2004) The value of expanded polytetrafluoroethylene in preventing early re-ossification after craniostylosis surgery: an experimental animal study in the rat. *Acta Neurochir (Wien)* 146: 279-283.
- Den Dunnen, W.F., Robinson, P.H., van Wessel, R., Pennings, A.J., van Leeuwen, M.B. & Schakenraad, J.M. (1997) Long-term evaluation of degradation and foreign-body reaction of subcutaneously implanted poly(DL-lactide-epsilon-caprolactone). *J Biomed Mater Res* 36: 337-346.
- Gielkens, P.F.M., Schortinghuis, J., de Jong, J.R., Raghoobar, G.M., Stegenga, B. & Bos, R.R.M. (2008) Vivosorb®, Bio-Gide® and Gore-Tex® as barrier membranes in rat mandibular defects. An evaluation by microradiography and micro-CT. *Clin Oral Implants Res* 19: 516-521.
- Hollinger, J.O., Buck, D.C. & Bruder, S.P. (1999) Biology of bone healing: its impact on clinical therapy. In: Lynch, S.E., Genco, R.J. & Marx, R.E., eds. *Tissue engineering. Applications in maxillofacial surgery and periodontics*, p. 17-53. Chicago: Quintessence.
- Kaminski, E.J., Oglesby, R.J., Wood, N.K. & Sandrik, J. (1968) The behavior of biological materials at different sites of implantation. *J Biomed Mater Res* 2: 81-88.
- Kay, S.A., Wisner-Lynch, L., Marxer, M. & Lynch, S.E. (1997) Guided bone regeneration: integration of a resorbable membrane and a bone graft material. *Pract Periodontics Aesthet Dent* 9: 185-194.
- Liu, X.F., Shu, R., Li, C.L., Tian, Z. & Shen, J. (2001) Histological evaluation of the biocompatibility of PDLA membranes. *Shanghai Kou Qiang Yi Xue* 10: 122-124.
- Luttikhuisen, D.T., van Amerongen, M.J., de Feijter, P.C., Petersen, A.H., Harmsen, M.C. & van Luyn, M.J. (2006) The correlation between difference in foreign body reaction between implant locations and cytokine and MMP expression. *Biomaterials* 27: 5763-5770.
- Machtej, E.E. (2001) The effect of membrane exposure on the outcome of regenerative procedures in humans: a meta-analysis. *J Periodontol* 72: 512-516.
- Meek, M.F., Jansen, K., Steendam, R., van Oeveren, W., van Wachem, P.B. & van Luyn, M.J. (2004) In vitro degradation and biocompatibility of poly(DL-lactide-epsilon-caprolactone) nerve guides. *J Biomed Mater Res A* 68: 43-51.
- Mueller, A.A., Rahn, B.A., Gogolewski, S. & Leiggener, C.S. (2005) Early dural reaction to polylactide in cranial defects in rabbits. *Pediatr Neurosurg* 41: 285-291.
- Pêgo, A.P., van Luyn, M.J., Brouwer, L.A., van Wachem, P.B., Poot, A.A., Grijpma, D.W. & Feijen, J. (2003) In vivo behavior of poly(1,3-

trimethylene carbonate) and copolymers of 1,3-trimethylene carbonate with D,L-lactide or epsilon-caprolactone: Degradation and tissue response. *J Biomed Mater Res A* 67: 1044-1054.

Piattelli, A., Scarano, A., Piattelli, M. & Matarasso, S. (1996) Cellular colonization and bone formation into expanded polytetrafluoroethylene membranes: a light microscopical and histochemical time course study in the rabbit. *J Periodontol* 67: 720-725.

Schortinghuis, J., Ruben, J.L., Raghoobar, G.M. & Stegenga, B. (2004) Therapeutic ultrasound to stimulate osteoconduction; A placebo controlled single blind study using e-PTFE membranes in rats. *Arch Oral Biol* 49: 413-420.

Schortinghuis, J., Ruben, J.L., Raghoobar, G.M., Stegenga, B. & de Bont, L.G. (2005) Does ultrasound stimulate osteoconduction? A placebo-controlled single-blind study using collagen membranes in the rat mandible. *Int J Oral Maxillofac Implants* 20: 181-186.

Van Minnen, B., van Leeuwen, M.B., Kors, G., Zuidema, J., van Kooten, T.G. & Bos, R.R. (2007) In vivo resorption of a biodegradable polyurethane foam, based on 1,4-butanediisocyanate: A three-year subcutaneous implantation study. *J Biomed Mater Res A* (Epub ahead of print).

Von Arx, T., Cochran, D.L., Schenk, R.K. & Buser, D. (2002) Evaluation of a prototype trilayer membrane (PTLM) for lateral ridge augmentation: an experimental study in the canine mandible. *Int J Oral Maxillofac Surg* 31: 190-199.

Wang, H.L. & Carroll, M.J. (2001) Guided bone regeneration using bone grafts and collagen membranes. *Quintessence Int* 32: 504-515.

Williams, S.K., Berman, S.S. & Kleinert, L.B. (1997) Differential healing and neovascularization of ePTFE implants in subcutaneous versus adipose tissue. *J Biomed Mater Res* 35: 473-481.

Witherspoon, P., Bryson, G., Wright, D.M., Reid, R. & O'Dwyer, P.J. (2004) Carcinogenic potential of commonly used hernia repair prostheses in an experimental model. *Br J Surg* 91: 368-372.

Zucchelli, G., Cesari, C., Clauser, C. & DeSanctis, M. (1998) Early bacterial accumulation on guided tissue regeneration membrane

materials. An in vivo study. *J Periodontol* 69: 1193-1202.

A comparison of micro-CT, microradiography and histomorphometry in the evaluation of bone grafts and defects

4

This chapter is an edited version of the manuscript:
Gielkens, P.F.M., Schortinghuis, J., de Jong, J.R., Huysmans,
M.C.D.N.J.M., van Leeuwen, M.B.M., Raghoobar, G.M., Bos,
R.R.M., & Stegenga, B. (2008) A comparison of micro-CT,
microradiography and histomorphometry in bone research.
Arch Oral Biol 53: 558-566.

Abstract

Objectives:

Intraobserver reliability and agreement were determined for microradiography (MR), micro-CT (μ CT) and histomorphometry (HM). These 3 modalities were compared for quantitative measurements of bone formation and graft modeling in rat mandibular defects and grafts.

Material and Methods:

Twelve rats were randomly selected from a larger experiment, evaluating bone formation in rat mandibular defects and bone modeling in grafts. Twelve lateral microradiographs were taken of the grafts. μ CT images were obtained from all defects and grafts (24 specimens). Defects and grafts were cut perpendicularly through their center. Microradiographs, μ CT images and histological sections were obtained from the resulting 48 specimens. New bone volume and graft volume were measured using image analysis software on MR and μ CT images. Defect width and graft width were measured using images from HM, MR and μ CT. The results were compared to each other.

Results:

The intraobserver reliabilities for the measurements of new bone volume by μ CT, and the measurement of graft modeling by MR and graft volume by μ CT were high. The differences between MR, HM and μ CT were larger in defect width measurements than in graft width measurement. MR measured smaller defects than HM and μ CT. The distance between the limits of agreement was larger in defect width measurements compared to graft width measurements.

Conclusions:

The methods of MR- and μ CT-image analysis are reliable but preferably should be used in combination as to obtain valid conclusions. HM, MR and μ CT for graft widths measurements showed more agreement than for defect width measurements. MR appears to overestimate bone formation.

Introduction

New methods of inducing bone formation or influencing bone graft modeling are usually evaluated in animals. In these animal experimental mandibular critical size defects (Kaban et al. 1979; Schortinghuis et al. 2003) are frequently used to evaluate bone formation under various experimental conditions (Dahlin et al. 1988; Lundgren et al. 1997). Traditionally, histomorphometry (HM) has been used to measure bone formation inside bony defects or bone modeling of onlay bone grafts. As HM is time consuming and rather expensive, an alternate technique, micro-radiography (MR), has been applied for similar purposes. MR was successfully introduced for the quantitative evaluation of new bone formation of experimentally created defects (Schortinghuis et al. 2003). MR proved to be fast, accurate and simple. Furthermore by MR the entire defect can easily be measured, whereas HM often involves 1 section (1 dimensional) only through the center of the defects (Mueller et al. 2005) or grafts (Meijndert et al. 2005). However, a disadvantage of MR is that only a 2 dimensional image is obtained, making 3 dimensional (D) volumetric calculations impossible.

A recently evolved other technique is micro-computed tomography (μ CT), where both 3D (and 2D) reconstructions and volumetric measurements can be obtained (Lee et al. 2006). The μ CT technique seems promising for the quantification of bone formation inside bony defects as well as the evaluation of bone modeling in bone grafts. Although μ CT appears to offer more advantages than MR, it is not yet widely available to its high costs in comparison with MR.

The aim of this study was to determine better and more accurate methods than the traditional HM methods to quantitatively evaluate new bone formation and graft modeling in animal studies.

Material and Methods

Study design

The intraobserver reliability of MR and μ CT for the assessment of graft size and volume, respectively, were determined in 12 rat mandibular grafts. Similarly, the

intraobserver reliability of μ CT for new bone formation was evaluated in 12 rat mandibular defects. Furthermore, to compare HM, MR and μ CT for the evaluation of distances in mineralised tissue, it was decided to measure widths in 1 dimension in 24 defect and 24 graft samples with HM, MR and μ CT.

To obtain these numbers of samples, 12 rats, 1 from each of 12 subgroups of a larger experiment, were selected. In that experiment in each rat a mandibular defect was drilled with a trephine and the resulting bone graft was transplanted to the contralateral side of the mandible using either none (control) or 1 of 3 guided bone regeneration membranes to cover the defect or bone graft subgroups (for the procedure we refer to section, *Surgical procedure*). Bone modeling was evaluated at 2, 4 and 12 weeks in the 3 membrane groups and control, yielding 12 subgroups.

To measure new bone volume in defects by μ CT and graft modeling and volume with MR and μ CT, respectively, the 12 mandibles were cut into 2 halves, the right (defect) and left (graft) side. The 12 grafts were resized to fit in a frame and lateral microradiographs were taken. The grafts as well as the 12 defects were then embedded in polymethylmethacrylate (PMMA). μ CT images were taken from all samples.

To measure defect and graft width, radiographs were taken to identify the location of the defect and graft area. The 12 defects and 12 grafts were cut perpendicularly through their center to obtain a fixed section wherein measurements were performed with all techniques. Lateral microradiographs and μ CT images were taken from the resulting 24 defects and 24 graft specimens. A section was then made 1 mm from the previously identified center. These cross-sections were then histologically prepared to be evaluated by HM.

The study protocol was approved by the Animal Study Review committee, and in accordance with Institutional Guidelines (University Medical Center Groningen, The Netherlands).

Surgical procedure

Under nitrous-oxygen-isoflurane inhalation anaesthesia, a 1 mm diameter hole was drilled in the right mandibular angle of male Sprague-Dawley rats (mean weight 364 g \pm



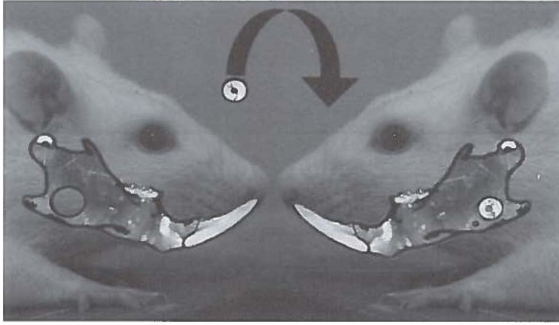


Fig. 1. Surgical procedure. In the right mandibular angle a standardised 5.0 mm bicortical defect was drilled with a trephine around a 1 mm hole that was centrally positioned. The 4.0 mm bone graft was transplanted to the left mandibular angle and fixed by a slowly resorbable suture. The defect and graft were left uncovered in the control as shown. In the other groups the defects and grafts were covered with guided bone regeneration membranes.

20 g SD, range 326-390 g). Then a standardised 5.0 mm, approximately 0.9 mm thick, bicortical defect was drilled with a trephine around the 1 mm hole that was centrally positioned (Kaban & Glowacki 1981; Schortinghuis et al. 2005). The bone graft, approximately 4.0 mm in diameter (Fig. 1), was preserved in saline. Using a 1.0 mm dental drill 2 holes of 1 mm diameter were drilled in the left mandibular angle. The graft was then fixed to the mandibular angle by a 4-0 slowly resorbable suture (Monocryl®, Ethicon, Johnson & Johnson, Amersfoort, The Netherlands), which was stitched through the burr holes. The defects and grafts were covered by a barrier membrane or were left uncovered. The 3 membranes used were (1) a polymer sheet composed of 67-69% DL (15-85)-lactide and 31-33% ϵ -caprolactone (poly(DL-lactide- ϵ -caprolactone)) (PDLLCL) (Vivosorb®, Polyganics, Groningen, The Netherlands), (2) a porcine bilayer collagen membrane (Geistlich Bio-Gide®, Geistlich Biomaterials, Wolhusen, Switzerland), and (3) an expanded polytetrafluoroethylene membrane (ePTFE, Gore-Tex®, W.L.Gore & Associates, Flagstaff, USA). The wounds were closed in layers.

A single dose of Caprofen (4.0 mg/kg) and Temgesic (0.03 mg/kg) were administered for postoperative pain relief.

The rats were housed in groups and received softened standard laboratory food for 3 days prior to surgery until 4 days postoperatively. Thereafter, the animals received

pellets. Water was administered ad libitum.

After 2, 4 and 12 weeks, a subset of rats was anaesthetised by inhalation anaesthesia and sacrificed by an intracardial injected overdose of pentobarbital. Then the mandibles were explanted and fixed in 4% phosphate buffered formaline solution.

Microradiography

An X-ray source (Philips PW 1730, Eindhoven, The Netherlands) was used with a copper anode. The explanted parts of the mandible were placed between a 35 mm film (Fuji B and W POS/71337) and the X-ray source and were exposed for 25 seconds, with a tube charge of 25 kV and 25 mA to obtain lateral microradiographs. Care was taken to place the buccal plane parallel to the film to assure a perpendicular recording of the defect and graft. The specimens, embedded in PMMA, that were cut through the center of the defect and graft were exposed for 15 seconds, with a tube charge of 40 kV and 25 mA to obtain lateral microradiographs. After processing the films with a Kodak D-19 developer for 10 minutes, fixing, rinsing, and drying, the films were placed on a light box. Digital images of the microradiographs were recorded with a stereo microscope (Wild/Leitz M7 S, Heerbrugg, Switzerland) with a 10x magnification and a CCD camera (Scion Corporation CFW 1312M, Frederick, MD, USA). The camera was linked to a personal computer equipped with a frame grabber. The magnified microradiographs were stored as images with a size of 1360 x 1024 pixels and with a resolution of 256 grey values. In addition, a digitised image of a micro-ruler was recorded for calibration.

Micro-CT

μ CT images were obtained using the Siemens MicroCAT II preclinical cone-beam CT scanner of the department of Nuclear Medicine & Molecular Imaging of the University Medical Center of Groningen. The MicroCAT II is a CCD based camera (2048 x 3072 pixels without binning) that acquires data by taking a number of planar images (projections) at regular angular intervals. The total rotational angle is adjustable as is the number of projections and the shutter speed. The field of view of the MicroCAT II is cylindrically shaped and has dimensions of length of 7 cm and of diameter 5 cm or vice versa, depending on the

orientation of the CCD sensor. The specimens, embedded in PMMA, were arranged in a 3D array not exceeding field of view dimensions in order to prevent truncation artefacts. The images were obtained using the following parameters: (1) The X-ray tube voltage was set to 80 kV. (2) The anode current was set to 250 μ A. (3) The shutter speed was set to 2500 ms. (4) The binning factor was set to 2. (5) The number of projections was set to 500. The acquisition was performed over a full 360 degrees angle and the number of calibration exposures was set to 25. The standard 0.5 mm aluminium filter was employed to define the X-ray spectrum. The reconstructions were performed using a Feldkamp cone-beam algorithm for filtered back-projection with a Shepp-Logan filter and beam hardening correction applied. The end result consisted of 3D images with an isotropic voxel size of 48 x 48 x 48 μ m.

Histomorphometry

After MR and μ CT evaluation, the specimens were decalcified and dehydrated in series of ethanol. The specimens were embedded in Glycidyl Methacrylate (GMA). The tissue blocks were cut perpendicular to the defects and grafts with a microtome. The resulting histological sections were 2 μ m thick. From all samples 2 sections were stained, 1 series with Toluidin Blue and 1 with Toluidin Blue/Basic Fuchsin. The histological sections were placed on a light box with a stereomicroscope (Wild/Leitz M7 S,

Heerbrugg, Switzerland) where digital images (2048 x 1536 pixels) were recorded by a digital colour camera (Nikon Coolpix 990, Nikon Corporation, Japan) and stored.

Measurement of new bone volume in defects by micro-CT

Blind evaluation of the explanted samples was performed by the principal investigator. The 3D μ CT data sets were evaluated with image analysis software (AMIRA 4.1, Mercury Computer Systems, Chelmsford, Massachusetts). A sagittal plane perpendicular to the central axis of the defect and thus parallel to the mandible was determined (Fig. 2). Subsequently, the lateral and medial limits of the defect parallel to this sagittal plane were established. Every third 2D micro-CT image between these boundaries was saved in a file, after manually marking the center of the defect and adding a calibrated digital line. In these images new bone formation was measured as a surface area. This calculation was computerized (Bone Growth Calculator, J. de Vries, University Medical Center Groningen, The Netherlands). The center was automatically found and calibrated. Then a 5.0 mm circle was set and new bone was automatically measured with a constant threshold of bone - no bone. The volume of new bone in the defect was calculated by multiplying the sum of all areas by 144 μ m (i.e., the thickness of 3 CT-slides). Each specimen was evaluated twice.




Fig. 2. Measurement of new bone volume in defects by micro-CT. A sagittal plane perpendicular to the central axis of the defect and thus parallel to the mandible was determined. Every third 2D micro-CT image between the lateral and medial limits of the defect was saved in a file. In these images new bone formation was measured as a surface area. For each sample, a volume of new bone was calculated by multiplying the sum of all surface areas.

Measurement of graft modeling ratio by MR and graft volume by μ CT

Blind evaluation of the explanted samples was performed by the principal investigator. In MR the amount of graft bone was expressed as the ratio of mean grey value of graft area to graft surrounding area. First, the mean grey value of the graft was obtained by measurement of 6 circular areas ($r = 0.15$ mm), which were equally spread along the graft margin. Additionally, 6 circular areas ($r = 0.15$ mm) in the graft surrounding area were marked next to the other circular areas but outside the graft area (Fig. 3). The graft area consisted of mandibular bone plus graft, whereas the surrounding area consisted of only mandibular bone. The graft area, therefore, had a whiter appearance and higher grey value on film. Theoretically, in case of full

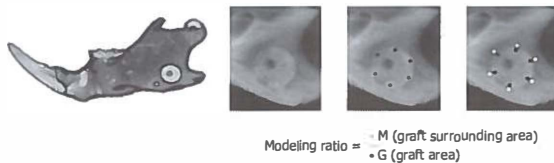


Fig. 3. Measurement of graft modeling ratio by microradiography. The mean grey value of the graft was obtained by measurement of 6 circular areas, which were equally spread along the graft margin. Additionally, 6 circular areas in the graft surrounding area were marked next to the other circular areas but outside the graft area.



Fig. 4. Measurement of bone volume in grafts by micro-CT. A transversal plane perpendicular to the mandible was chosen. Every third 2D micro-CT image between the mesial and distal limits of the bone graft was saved in a file. The outline of the graft was manually drawn in image editing software and the area of the graft was automatically calculated. For each sample, a volume of bone was calculated by multiplying the sum of all marked areas.

graft modeling no difference between graft surrounding and graft area would be observed and the ratio would be 1. Each sample was measured twice. The measurements were performed using image analysis software (Optical Bone Calculator, J. de Vries, University Medical Center Groningen, The Netherlands).

The 3D μ CT data sets were evaluated with image analysis software (AMIRA 4.1, Mercury Computer Systems, Chelmsford, Massachusetts). A transversal plane perpendicular to the mandible was chosen (Fig. 4). Subsequently, the mesial and distal limits of the bone graft were determined. Every third (an interval of $144 \mu\text{m}$) 2D μ CT image between these boundaries was saved in a file. Each image depicted a millimetre scale for calibration with the image analysis software. Then image editing software (Adobe Photo Shop 8.0) was used to manually draw the outline of the graft. The area of the graft was automatically calculated by image analysing software (Graft volume Calculations, J. de Vries, University Medical Center Groningen, The Netherlands). For each sample, a volume of bone was calculated by multiplying the sum of all marked areas by $144 \mu\text{m}$ (i.e., the thickness of 3 CT slides). Each specimen was evaluated twice.

Comparison of HM, MR and μ CT for defect and graft width measurements

To assess the relationship of HM, MR and μ CT in the measurement of distances in mineralised tissue by each of the 3 techniques the defect and graft widths were measured at the cutting edge in the center of the defects and grafts. The MR sections were evaluated from the lateral side, whereas with μ CT and HM cross-sectional samples were evaluated. For these purposes image analysis software (Scion Corporation CFW 1312M, Frederick, MD, USA) was applied. Blind evaluation of the explanted samples was performed by the principal investigator. Parallel tangents were drawn at the defect and graft rims and the distance in pixels was measured automatically between these tangents. The rims were defined as the most inner point of bone inside the defect and most outer point of the grafted bone. Each measurement was repeated 3 times and then averaged. The mean distances on the histological sections were measured in millimetres, and then compared to the corresponding microradiographs and μ CT images.

Statistical analyses

The intraobserver reliability for the measurements of new bone volume by μ CT and the measurements of the graft modeling ratio by MR and graft volume by μ CT were determined in terms of limits of agreement and intraclass correlation coefficient (ICC) (Strout & Fleiss 1979). The limits of agreement, described by Bland and Altman (1986), equal the mean change in scores of repeated measurements $\pm 1.96 * \text{the standard deviation of these changes}$.

The agreement between HM, MR and μ CT for defect and graft width measurements was determined by calculating the limits of agreement.

Results

The intraobserver reliability for the measurements of new bone volume by μ CT and the measurement of the graft modeling ratio by MR and graft volume by μ CT is represented in Table 1. The mean changes in scores between 2 consecutive measurements were small (Fig. 5a - 5c).

Outlier was PDLCL at 12 weeks (Fig. 5a and Fig. 5b). Calculating the reliability of measuring new bone volume and graft modeling ratio and volume resulted in ICCs of 0.99, 0.96 and 0.98, respectively (Table 1). Each of these results indicates high intraobserver reliability.

The graft width measurements showed more agreement than the defect widths measurements (Table 2). This was determined by the fact that the differences between MR, HM and μ CT were larger in defect width measurements than in graft width measurement. MR measured smaller defects than HM and μ CT. The distance between the limits of agreement was also larger in the defect width measurements compared to the graft width measurements, indicating more agreement for graft width measurements (Table 2, Fig. 6a - 7c). Outliers in the defect width measurements (collagen at 2 weeks, the mesial (Fig. 6a) and distal (Fig. 6b) sample, and ePTFE at 2 weeks, the mesial and distal sample (Fig. 6c)) were less extreme than the outliers in the graft width measurements (ePTFE at 12 weeks, the mesial and distal sample (Fig. 7a and 7b) and PDLCL at 2 weeks, the mesial and distal sample (Fig. 7c)).

Table 1. The intraobserver reliability for the measurements of new bone volume by micro-CT and the measurements of the graft modeling ratio and volume by microradiography and micro-CT, respectively.

	Difference between means	Limits of agreement	ICC
Bone volume μ CT	0.15	[-1.32 - 1.62]	0.99 [0.97 - 1.00]
Graft modeling ratio MR	0.0008	[-0.046 - 0.048]	0.96 [0.85 - 0.99]
Graft volume μ CT	-0.049	[-0.70 - 0.60]	0.98 [0.92 - 0.99]

Table 2. The agreement between microradiography, micro-CT and histomorphometry for defect and graft width measurements.

	Difference between means	Limits of agreement
Defect μ CT - HM	0.18	[-2.39 - 2.75]
Defect MR - HM	-0.66	[-3.46 - 2.14]
Defect μ CT - MR	0.85	[-1.82 - 3.52]
Graft μ CT - HM	-0.10	[-2.22 - 2.02]
Graft MR - HM	-0.23	[-2.73 - 1.91]
Graft μ CT - MR	0.13	[-0.42 - 0.68]

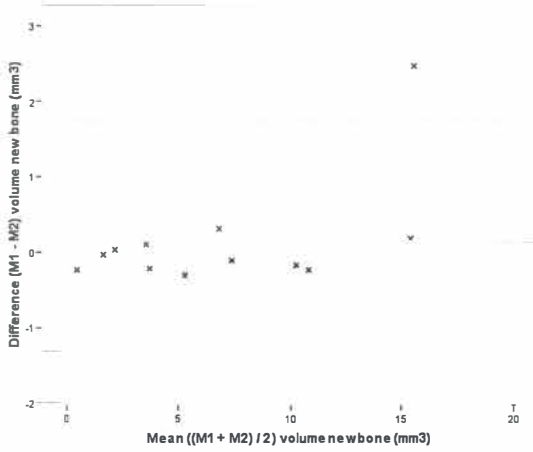


Fig. 5a. Intraobserver agreement of micro-CT evaluation of new bone volume in defects.

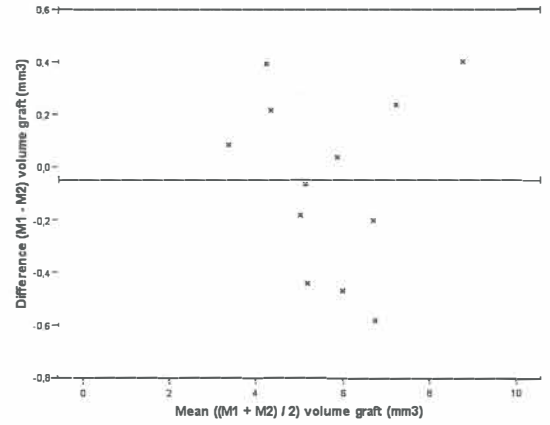


Fig. 5c. Intraobserver agreement of micro-CT evaluation of graft volume.

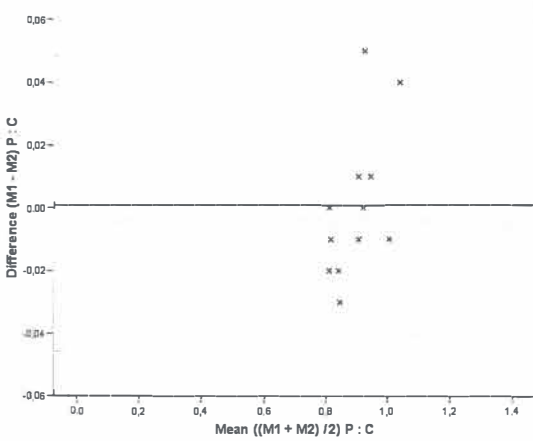


Fig. 5b. Intraobserver agreement of microradiographic evaluation of graft modeling ratio.

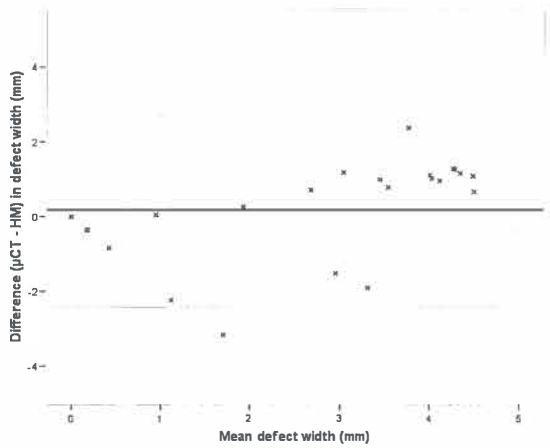


Fig. 6a. Agreement between micro-CT and histomorphometry for defect width measurements.

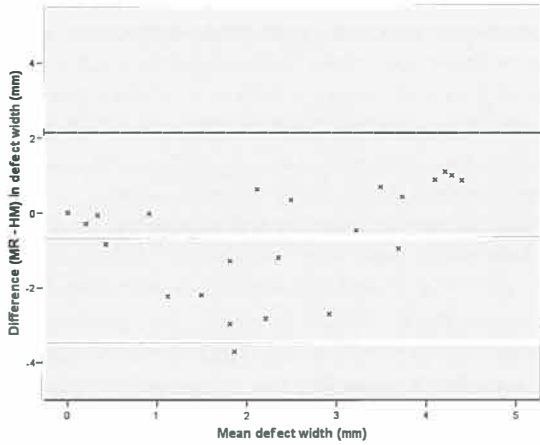


Fig. 6b. Agreement between microradiography and histomorphometry for defect width measurements.

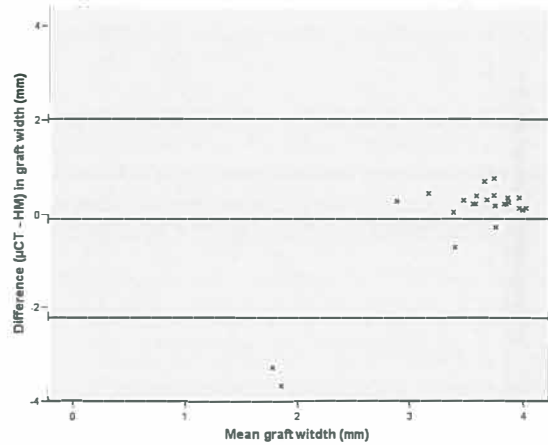


Fig. 7a. Agreement between micro-CT and histomorphometry for graft width measurements.

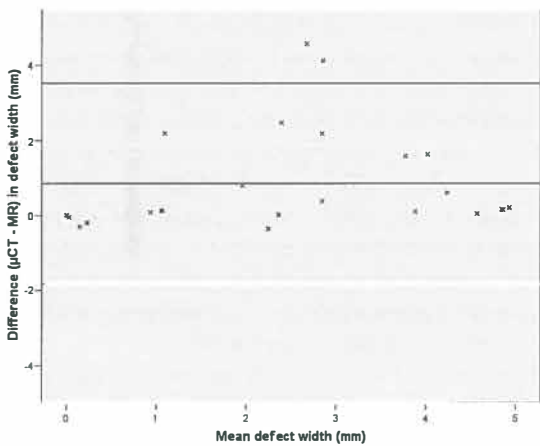


Fig. 6c. Agreement between micro-CT and microradiography for defect width measurements.

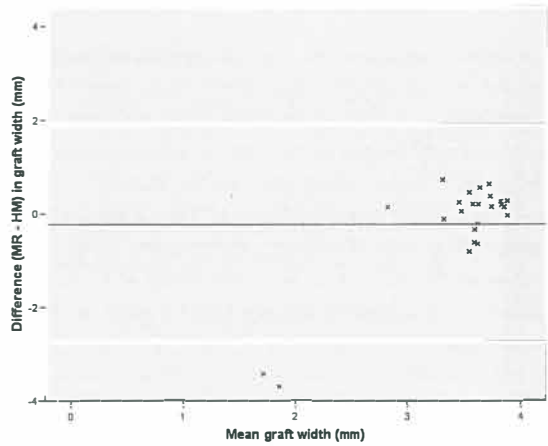


Fig. 7b. Agreement between microradiography and histomorphometry for graft width measurements.

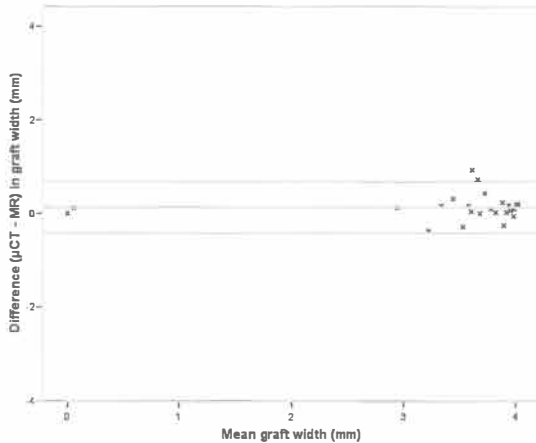


Fig. 7c. Agreement between micro-CT and microradiography for graft width measurements.

Discussion

The defect measurements of μ CT images showed to be very reliable in the present study. Other studies report a high accuracy and reproducibility (Park et al. 2007). A remarkable uncertain outline of the original 5.0 mm defect makes the defect measurements less reliable. However, this was only seen in the single outlier, i.e., the 12 weeks PDLLCL sample (Fig. 5a). Therefore, μ CT appears to be a good technique to assess new bone formation in standardised defects. In a longitudinal study design it must be possible to monitor more irregular defects with a minimal number of animals. Moreover, new analysing software, such as the software used in a recently published animal study (Oest et al. 2007), make the μ CT procedure less time consuming than in the present study.

An MR technique for measuring bone graft modeling was chosen that could focus on the ratio of grey values of the graft area in relation to the graft surrounding area rather than on graft size (Schortinghuis et al. 2003). This was primarily because it was not possible to take the microradiographs perpendicular to the grafts, what resulted in oval shaped graft areas on the microradiographs. Furthermore, the major change of the modeling grafts was not a diminishing area and diameter but a changing ratio of grey values

of the graft area to the graft surrounding area. A ratio of grey values was chosen since a mean grey value of the graft area alone would not suffice. Variations between and within the underlying bone as well as variations in grey values due to digitizing of the microradiographs would prevent a valid outcome in the case without ratio.

The difference between the grafted area and the area surrounding the graft which obviously diminished between 2 and 12 weeks was reflected by an increasing ratio of grey values with time. Nevertheless, all measurements are within the range 0.82 to 1.01. Future research with larger groups should reveal whether it is possible to distinguish between different treatment groups.

The results of MR suggest that the graft area lost mineral or height. However, only 3D μ CT can differentiate between a thick layer of minimally mineralised bone and a thin layer of maximally mineralised bone. The graft volume measurements of μ CT images showed a high rate of reliability, similar to MR image measurements, although the μ CT images in this study, processed by the present-day available scanner and software do not show the preferred contrast and resolution as is seen in MR. The perimeters of graft bone, new bone and original bone were harder to differentiate than expected, making the evaluation of the 12 weeks groups potentially less reliable. However, it appears to be possible to obtain reliable scores, provided 1 observer uses strict criteria. Evaluation with multiple investigators might have provided more accurate conclusions. Interobserver reliability could then be evaluated. However, it appears feasible to compare group results with this technique in future experiments.

To determine the relationship between HM, MR and μ CT for the evaluation of measuring distances in mineralised tissue, measurements were performed at the cutting edge in defect and graft samples (Schortinghuis et al. 2003). The defect measurements showed less agreement than the graft measurements, although μ CT and HM performed with a small difference in defect width measurements (Fig. 6a). Calibration of μ CT for bone remains difficult (Tuan & Hutmacher 2005). However, the high agreement between HM and μ CT indicate that the boundary of bone - no bone applied to the μ CT 3D data set was apparently well chosen in the present experiment. On the contrary, MR results differed significantly from the other 2 modalities. With MR

less defect width and thus more mineralised tissue was measured than with HM and μ CT. Outliers did not account for this difference. Possibly, artefacts originating in the preparation of the samples might be the cause. A notable finding was that a mineralised rim could be seen by MR in the samples that showed extreme differences, although no (mature) bone was present at these locations in HM. A possible lower threshold for bone applied in the bone - no bone boundary in MR compared to HM could cause this difference. Moreover, in HM mature bone was measured since young bone cells in premature bone could not be applied as a reliable borderline in HM. MR does not differentiate between mature and premature bone. Therefore, MR probably measured a mineralised rim of premature bone, while HM defined this as unorganised young bone cells. Schortinghuis et al. (2003) also mention that premature bone causes differences between HM and MR measurements, although the difference between means they found was smaller. The criterion of bone - no bone in HM of the present study differs from the criterion of the past study. The 2 outliers in the agreement between MR and μ CT defect width measurements were 2 weeks samples (Fig. 6c). Corresponding to HM μ CT could not reveal small mineralised rims due to the applied bone - no bone boundary. The problem of thin layers of mineralised tissue was not seen in the graft width measurements. Probably, new bone was not formed around the graft or the contrast with the (grey) background around the graft is too low to detect a rim of new bone. A rim of new bone in defects is more easily seen with the high contrasting (dark) background in the defects.

Therefore, in the grafts width measurements a large extent of agreement was seen. This is expressed in small differences between means as well as in levels of agreement. Outliers were found in the 12 weeks group when comparing MR and μ CT to HM (Fig. 7a and 7b). These grafts were rather difficult to differentiate from the underlying bone, presumably due to modeling and incorporation. HM showed a higher contrast and, therefore, the graft could be identified yielding large differences with MR and μ CT. In a study that compared HM, MR and μ CT for an evaluation of porosity of bone cement, a lower agreement between the techniques was found (Cox et al. 2006).

MR and μ CT have advantages compared to HM, although

evaluation at a cellular level is not possible with MR and μ CT. μ CT appears to have the most advantages although the current software and scanners do not yet obtain the contrast and resolution of MR.

In conclusion, defect and graft measurements with MR and μ CT are reliable when strict criteria are applied. The combination of the 3 techniques is preferred to obtain valid conclusions. MR appears to overestimate bone formation in defects compared to HM (and μ CT) and difficulties could occur in graft groups where modeling and graft incorporation are almost complete (such as in the 12 weeks group in this study). Future experiments where the described techniques are applied should reveal the feasibility of these techniques in both experimental and clinical research.

Acknowledgements

Gratitude is expressed to Mr. J. de Vries for designing the applied software, to Dr. J.J.R. Huddleston Slater for his assistance with the statistical analyses and to Mr. J.L. Ruben for his help in the microradiography evaluation.



References

- Bland, J.M. & Altman, D.G. (1986) Statistical methods for assessing agreement between two methods of clinical measurement. *Lancet* 1(8476): 307-310.
- Cox, B.D., Wilcox, R.K., Levesley, M.C. & Hall, R.M. (2006) Assessment of a three-dimensional measurement technique for the porosity evaluation of PMMA bone cement. *J Mater Sci Mater Med* 17: 553-557.
- Dahlin, C., Linde, A., Gottlow, J. & Nyman, S. (1988) Healing of bone defects by guided tissue regeneration. *Plast Reconstr Surg* 81: 672-676.
- Kaban, L.B., Glowacki, J. & Murray, J.E. (1979) Repair of experimental mandibular bony defects in rats. *Surg Forum* 30: 519-521.
- Kaban, L.B. & Glowacki, J. (1981) Induced osteogenesis in the repair of experimental mandibular defects in rats. *J Dent Res* 60: 1356-1364.
- Lee, J.K., Ha, B.H., Choi, J.H., Heo, S.M. & Perinpanayagam, H. (2006) Quantitative three-dimensional analysis of root canal curvature in maxillary first molars using micro-computed tomography. *J Endod* 32: 941-945.
- Lundgren, A.K., Lundgren, D., Sennerby, L., Taylor, A., Gottlow, J. & Nyman, S. (1997) Augmentation of skull bone using a bioresorbable barrier supported by autologous bone grafts. An individual study in the rabbit. *Clin Oral Implants Res* 8: 90-95.
- Meijndert, L., Raghoobar, G.M., Schüpbach, P., Meijer, H.J.A. & Vissink, A. (2005) Bone quality at the implant site after reconstruction of a local defect of the maxillary anterior ridge with chin bone or deproteinised cancellous bovine bone. *Int J Oral Maxillofac Surg* 34: 877-884.
- Mueller, A.A., Rahn, B.A., Gogolewski, S. & Leiggener, C.S. (2005) Early dural reaction to polylactide in cranial defects in rabbits. *Pediatr Neurosurg* 41: 285-291.
- Oest, M.E., Dupont, K.M., Kong, H.J., Mooney, D.J. & Goldberg, R.E. (2007) Quantitative assessment of scaffold and growth factor-mediated repair of critically sized bone defects. *J Orthop Res* 25: 941-950.
- Park, C.H., Abramson, Z.R., Taba, M., Jin, Q., Chang, J., Kreider, J.M., Goldstein, S.A. & Giannobile, W.V. (2007) Three-dimensional micro-computed tomographic imaging of alveolar bone in experimental bone loss or repair. *J Periodontol* 78: 273-281.
- Schortinghuis, J., Ruben, J.L., Meijer, H.J.A., Bronckers, A.L., Raghoobar, G.M. & Stegenga, B. (2003) Microradiography to evaluate bone growth into a rat mandibular defect. *Arch Oral Biol* 48: 155-160.
- Schortinghuis, J., Ruben, J.L., Raghoobar, G.M., Stegenga, B. & de Bont, L.G. (2005) Does ultrasound stimulate osteoconduction? A placebo-controlled single-blind study using collagen membranes in the rat mandible. *Int J Oral Maxillofac Implants* 20: 181-186.
- Strout, P.E. & Fleiss, J.L. (1979) Intraclass correlations: Uses in assessing rater reliability. *Psychol Bull* 86: 420-428.
- Tuan, H.S. & Hutmacher, D.W. (2005) Application of micro CT and computation modelling in bone tissue engineering. *Comput Aided Des* 37: 1151-1161.





Barrier membranes on bone grafts



The influence of barrier membranes on autologous bone grafts. An evaluation with microradiography and micro-CT

5.1

*This chapter is an edited version of the manuscript:
Gielkens, P.F.M., Schortinghuis, J., de Jong, J.R., Paans,
A.M.J., Ruben, J.L., Raghoobar, G.M., Stegenga, B. & Bos, R.R.M.
The influence of barrier membranes on autologous bone grafts.
An evaluation with microradiography and micro-CT. Submitted.*

Abstract

Objectives:

In implant dentistry, it is debated whether or not a barrier membrane should be applied to cover autologous onlay bone grafts when augmenting the jaw. The effect of 3 membranes with regard to modeling with resorption and incorporation of autologous onlay bone block grafts was examined.

Material and Methods:

192 male Sprague-Dawley rats were treated. A 4.0 mm diameter bone graft was harvested from the right mandibular angle and transplanted to the left. Poly(DL-lactide-ε-caprolactone), collagen and expanded polytetrafluoroethylene membranes were used to cover the grafts. The controls were left uncovered. Graft resorption at 2, 4 and 12 weeks was evaluated by post-mortem microradiography and micro-CT.

Results:

Overall, the analysed data did not show differences between the 4 groups.

Conclusion:

It was demonstrated that the indication of barrier membrane-use, to prevent bone modeling with resorption and to enhance incorporation of autologous onlay bone block grafts, is at least disputable.

Introduction

Sufficient bone is necessary for predictable osseointegration of dental implants and satisfactory aesthetics. The use of guided bone regeneration membranes has proven to promote bone regeneration in bony defects (McAllistar & Haghghat 2007). However, when a bone graft is applied to augment the jaw, there is a continuing debate on whether or not a barrier membrane should be used to cover the augmented site (Chiapasco et al. 1999; Donos et al. 2002a). The bone graft serves as a scaffold and carrier for living cells. The barrier membrane is expected to prevent bone modeling with resorption by shielding the graft from inhibiting factors and fibroblasts (Gordh et al. 1998) and by keeping the osteoinductive substances in situ (Linde et al. 1993; Zellin & Linde 1997). This would enhance incorporation of the bone graft (Alberius et al. 1992) and improve the predictability of the augmentation (Donos et al. 2002b). Furthermore, a barrier membrane serves as a space-maintainer, allowing bone regeneration in any remaining space (Antoun et al. 2001).

Good clinical results of barrier membranes have been reported and many clinicians cover bone grafts with a barrier membrane (Buser et al. 1996). However, membrane application increases costs (Chiapasco et al. 1999) and has a negative effect on guided bone regeneration around dental implants in case of membrane exposure (Machtei 2001). Moreover, the present best available evidence does not answer the question as to whether barrier membranes do prevent bone resorption in autologous onlay bone grafts (Gielkens et al. 2007).

The objective of this study was to examine the preventive effect of 3 barrier membranes with regard to modeling with resorption of autologous onlay bone block grafts in the rat mandible. In addition the effect of the membranes on graft incorporation was measured.

Material and Methods

In the right mandibular angle of male Sprague-Dawley rats a standardised 5.0 mm circular defect was drilled with a trephine (Kaban & Glowacki 1981; Schortinghuis et al. 2003) and the obtained bone graft (4.0 mm diameter) was

transplanted to the buccal side of the contralateral mandibular angle and fixed with a slowly degradable suture (Monocryl®, Ethicon, Johnson & Johnson, Amersfoort, The Netherlands) through a central 1 mm hole in the graft.

The rats were assigned to 1 of 4 groups: 3 membrane groups and 1 control group, in which no membrane was used. The membranes used were (1) a copolymer sheet composed of 67-69% DL (15-85)-lactide and 31-33% ε-caprolactone (poly(DL-lactide-ε-caprolactone)) (PDLLCL) (Vivosorb®, Polyganics, Groningen, The Netherlands), (2) a bilayer collagen membrane (Geistlich Bio-Gide®, Geistlich Biomaterials, Wolhusen, Switzerland), and (3) an expanded polytetrafluoroethylene membrane (ePTFE, Gore-Tex®, W.L.Gore & Associates, Flagstaff, USA).

One side of the PLLCL membranes was rough. These membranes were applied with their rough side faced to the bone to optimize integration and positioning.

The wound was closed in layers using resorbable sutures (Vicryl® Rapide 4-0, Ethicon, Johnson & Johnson, Amersfoort, The Netherlands). Postoperative pain relief was administered and the diet was composed of standard laboratory food.

After 2, 4 and 12 weeks, rats were anaesthetised by inhalation anaesthesia and sacrificed by an intracardial injection of pentobarbital, after which the mandibles were explanted and fixed in phosphatebuffered formaline solution.

The study protocol was approved by the Animal Studies Review Committee, and in accordance with Institutional Guidelines (University Medical Center Groningen, The Netherlands).

Microradiography and micro-CT

An X-ray source was used to take microradiographs of the explanted parts of the mandible (Schortinghuis et al. 2003). The mandibular buccal plane was placed parallel to the film to assure a rectangular recording of the graft. Digital images of the original microradiographs were recorded with a stereo microscope with a 10x magnification and a CCD camera. The magnified images were stored as images with a size of 1360 x 1024 pixels and with a resolution of 256 grey values. Then the specimens were embedded in polymethylmethacrylate (PMMA).

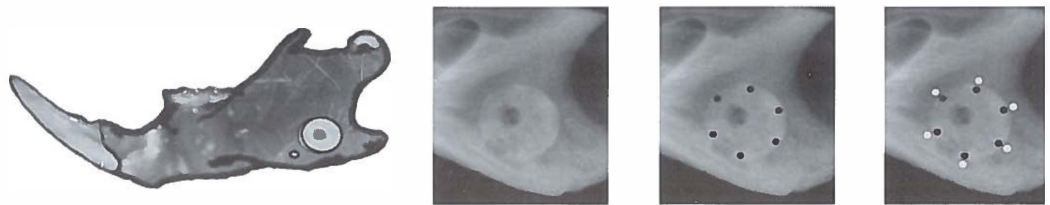
Micro-CT (μCT) images were obtained using a Siemens MicroCAT II preclinical cone-beam CT scanner. The CCD

sensor measured 7 x 5 cm. The specimens were arranged in a 3-dimensional array not exceeding field of view dimensions in order to prevent truncation artefacts. The images were obtained resulting in 3D images with an isotropic voxel size of 48 x 48 x 48 μm .

Measurement of bone modeling of the graft and graft incorporation

The principal investigator was blinded during the evaluation of the explanted samples. In the microradiographs the amount of bone modeling was expressed as the ratio of mean grey value of graft area to graft surrounding area. First, the mean grey value of the graft was obtained by

measurement of 6 circular areas ($r = 0.15 \text{ mm}$), which were equally distributed along the graft margin (Fig. 1). Additionally, 6 similar circular areas ($r = 0.15 \text{ mm}$) in the area surrounding the graft were marked. The graft area consisted of original mandibular bone plus graft, whereas the surrounding area consisted of original mandibular bone only. Thus, the graft area contained a combined layer of bone and had, consequently, a whiter appearance and higher radiodensity value on film. In the theoretical case of full graft resorption without any bone modeling, no difference between graft surrounding and graft area would be observed and the modeling ratio would be 1. The measurements were performed using image analysis software



$$\text{Modeling ratio} = \frac{\bullet \text{ M (graft surrounding area)}}{\bullet \text{ G (graft area)}}$$

Fig. 1. Measurement of graft modeling ratio by microradiography. The mean grey value of the graft was obtained by measurement of 6 circular areas, which were equally spread along the graft margin. Additionally, 6 circular areas in the graft surrounding area were marked next to the other circular areas but outside the graft area.

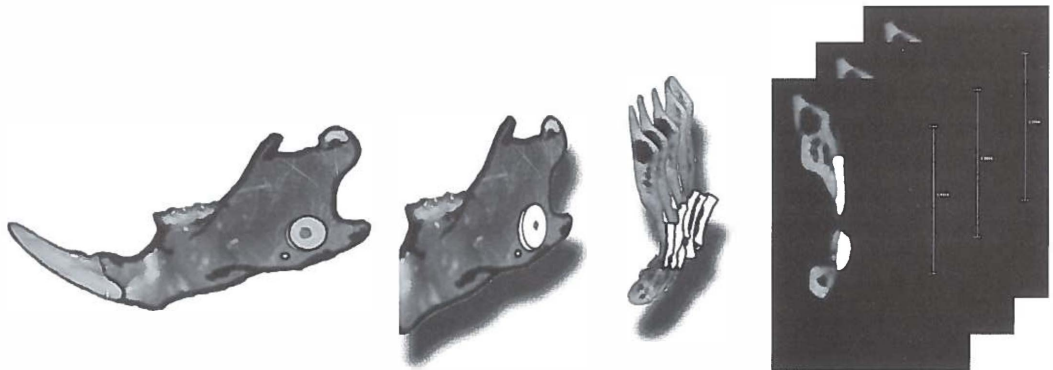


Fig. 2. Measurement of bone volume in grafts by micro-CT. A transversal plane perpendicular to the mandible was chosen. Every third 2D micro-CT image between the mesial and distal limits of the bone graft was saved in a file. The outline of the graft was manually drawn in image editing software and the area of the graft was automatically calculated. For each sample, a volume of bone was calculated by multiplying the sum of all marked areas.

(Optical Bone Calculations, J. de Vries, University Medical Center Groningen, The Netherlands).

The 3D μ CT data sets were evaluated with image analysis software (AMIRA 4.1, Mercury Computer Systems, Chelmsford, Massachusetts). A transversal plane rectangular to the mandible was chosen (Fig. 2). Every third (corresponding to an interval of 144 μ m) 2D μ CT image between the proximal and distal limits of the bone graft was saved in a file. The outline of the graft was manually drawn and then the area was calculated by image analysis software. For each sample, a mean volume of remaining graft was calculated by multiplying the sum of all marked areas by 144 μ m (i.e., the thickness of 3 CT slides). In the same way, in every third μ CT image graft incorporation was measured, which was defined as a bony connection between graft and mandible. The percentage of incorporation was defined as the length of the incorporated part of the graft divided by the total length of the graft. Observations were scored on a scale, ranging from 1 to 4: when 0-25% of the graft was incorporated a score of 1 was assigned, and a score 2, 3 and 4 were assigned in case of 26-50%, 51-75% or 76-100% of incorporation, respectively.

Statistical analyses

The sample size was determined by a power analysis based on a 90% power with a 0.05 significance level, a 40% mean difference in amount of graft volume between a membrane-treated group and non-treated control, and a mean standard deviation of 29% (Chiapasco et al. 1999; Donos et al. 2002b).

In a multiple regression analysis model the effect of the independent variables 'group' (i.e., control, PDLCL, collagen, ePTFE) and 'time' (i.e., 2, 4 and 12 weeks) and interactions between these variables on graft modeling with resorption and graft incorporation was studied.

Results

The sample size that was determined based on the power analysis did not exceed the needed sample size of a defect experiment executed on the contralateral side in the same rat. Therefore, 48 rats per group were also used in the present study, yielding a total of 192 rats (mean weight

364 g \pm 17 g SD, range 320-407 g). Peroperatively 6 rats had died. In another 6 rats the graft had fractured during drilling and in 3 samples the 1 mm drill hole, meant to be in the center, was located on the outline of the graft. These samples were excluded from statistical analysis because the validity of volume calculations in these samples could not be guaranteed. In 2 specimens (PDLCL and collagen at 12 weeks) it was not possible to identify the grafted bone with μ CT. These 2 samples were also excluded. This resulted in a median group size of 15 (range 13-16) for microradiography (MR) and a median group size of 11 (range 7-11) for μ CT. No wound infection or dehiscence did occur and all other animals gained weight.

The graft modeling with resorption as mean ratio of grey values in the graft surrounding area to graft area as measured with MR is presented in Table 1. The mean graft modeling with resorption as absolute mean volume of the graft as measured with μ CT is presented in Table 2. Table 3 presents graft incorporation. In Table 1-3 no differences were observed between membrane and control groups.

The regression analyses of the graft modeling with resorption measured as mineralization ratio and as absolute volume as well as graft incorporation are summarized in Table 4, 5 and 6, respectively. Model 1 is a regression model without the correction for possible effect modification (interaction effects). Model 2 is a regression model with correction for effect modification of time and membrane (i.e., PDLCL, collagen or ePTFE). Both models are presented to give the reader information about the relative effect of the coefficients with and without correction for effect modifications as interaction may dramatically change the value of the crude coefficients.

The regression analyses showed that graft resorption as mineralization ratio was progressive in all groups. No differences between groups were seen. The graft volume as depicted in model 2 increased in the collagen and ePTFE groups, whereas model 1 shows similar results in all membrane groups. Most graft bone was observed in non-treated controls. Based upon model 2, graft incorporation increased most in collagen. Model 1 showed least incorporation in the collagen groups. In general, although minor differences were observed, similar findings were obtained in membrane and control groups.

Table 1. Graft modeling with resorption as mean ratio of grey value in the graft surrounding area (m) to graft area (g + m) as measured by microradiography.

	2 wks (95% CI) (m / (g + m))	4 wks (95% CI) (m / (g + m))	12 wks (95% CI) (m / (g + m))
Control	0.84 (0.82 - 0.86)	0.88 (0.84 - 0.92)	0.94 (0.91 - 0.97)
PDLLCL	0.83 (0.81 - 0.85)	0.85 (0.82 - 0.88)	0.96 (0.93 - 0.99)
Collagen	0.82 (0.80 - 0.84)	0.90 (0.88 - 0.92)	0.95 (0.91 - 0.99)
ePTFE	0.86 (0.85 - 0.87)	0.88 (0.86 - 0.90)	0.99 (0.95 - 1.03)

CI = confidence interval

PDLLCL = poly(DL-lactide-ε-caprolactone)

ePTFE = expanded polytetrafluoroethylene

m = mandible; g = graft

Table 2. Graft modeling with resorption as absolute mean volume of the graft (mm³) as measured by micro-CT.

	2 wks (95% CI)	4 wks (95% CI)	12 wks (95% CI)
Control	7.55 (5.78 - 9.32)	6.76 (4.70 - 8.82)	5.35 (4.17 - 6.53)
PDLLCL	5.53 (4.76 - 6.30)	5.60 (4.83 - 6.37)	4.21 (3.37 - 5.05)
Collagen	3.91 (3.53 - 4.29)	5.92 (4.25 - 7.59)	4.80 (3.73 - 5.87)
ePTFE	4.71 (4.28 - 5.14)	6.66 (5.09 - 8.23)	4.62 (3.83 - 5.41)

CI = confidence interval

PDLLCL = poly(DL-lactide-ε-caprolactone)

ePTFE = expanded polytetrafluoroethylene

Table 3. Mean graft incorporation.

	2 wks (95% CI) (1-4)	4 wks (95% CI) (1-4)	12 wks (95% CI) (1-4)
Control	2.11 (1.52 - 2.70)	2.78 (2.25 - 3.31)	3.50 (3.17 - 3.83)
PDLLCL	1.91 (1.66 - 2.16)	2.71 (2.27 - 3.15)	3.85 (3.69 - 4.01)
Collagen	1.41 (1.20 - 1.62)	3.00 (2.59 - 3.41)	3.59 (3.24 - 3.94)
ePTFE	2.10 (1.74 - 2.46)	3.00 (2.73 - 3.27)	3.58 (3.33 - 3.83)

CI = confidence interval

PDLLCL = poly(DL-lactide-ε-caprolactone)

ePTFE = expanded polytetrafluoroethylene

1 = 0-25% graft incorporation

2 = 26-50% graft incorporation

3 = 51-75% graft incorporation

4 = 76-100% graft incorporation

Table 4. Linear regression models of graft modeling with resorption as ratio of grey value in the graft surrounding area (m) to graft area (g + m) as measured by microradiography. Model 1 is a regression model without the correction for interaction effects, model 2 with correction for interaction effects.

	Coefficients		t	Significance
	B (95% CI)	Std. Error		
Model 1				
Constant	0.767 (0.740 - 0.794)	0.014	55.879	0.000
Control (time)	0.061 (0.051 - 0.071)	0.005	11.760	0.000
PDLLCL	-0.009 (-0.033 - 0.014)	0.012	-0.787	0.433
Collagen	0.000 (-0.024 - 0.024)	0.012	-0.013	0.990
ePTFE	0.020 (-0.003 - 0.044)	0.012	1.696	0.092
Model 2				
Constant	0.787 (0.740 - 0.834)	0.024	33.089	0.000
Control (time)	0.051 (0.030 - 0.072)	0.011	4.724	0.000
PDLLCL	-0.044 (-0.108 - 0.020)	0.032	-1.360	0.176
Collagen	-0.021 (-0.086 - 0.045)	0.033	-0.620	0.536
ePTFE	-0.004 (-0.068 - 0.060)	0.032	-0.112	0.911
Interaction time*PDLLCL	0.017 (-0.012 - 0.046)	0.015	1.150	0.252
Interaction time*collagen	0.010 (-0.020 - 0.040)	0.015	0.657	0.512
Interaction time*ePTFE	0.012 (-0.018 - 0.041)	0.015	0.790	0.431

CI = confidence interval

PDLLCL = poly(DL-lactide-ε-caprolactone)

ePTFE = expanded polytetrafluoroethylene

Table 5. Linear regression models of graft modeling with resorption as absolute volume of the graft as measured by micro-CT. Model 1 is a regression model without the correction for interaction effects, model 2 with correction for interaction effects.

	Coefficients		t	Significance
	B (95% CI)	Std. Error		
Model 1				
Constant	7.057 (6.141 - 7.973)	0.463	15.255	0.000
Control (time)	-0.098 (-0.181 - -0.015)	0.042	-2.330	0.022
PDLLCL	-1.348 (-2.367 - -0.328)	0.515	-2.617	0.010
Collagen	-1.655 (-2.708 - -0.603)	0.513	-3.114	0.002
ePTFE	-1.141 (-2.153 - -0.129)	0.511	-2.234	0.027
Model 2				
Constant	8.186 (7.013 - 9.359)	0.592	13.830	0.000
Control (time)	-0.270 (-0.412 - -0.128)	0.072	-3.760	0.000
PDLLCL	-2.832 (-5.262 - -0.403)	1.227	-2.309	0.023
Collagen	-5.310 (-7.792 - -2.828)	1.253	-4.238	0.000
ePTFE	-3.852 (-6.276 - -1.429)	1.223	-3.149	0.002
Interaction time*PDLLCL	0.689 (-0.404 - 1.783)	0.552	1.249	0.214
Interaction time*collagen	1.792 (0.678 - 2.906)	0.562	3.188	0.002
Interaction time*ePTFE	1.308 (0.225 - 2.391)	0.547	2.392	0.018

CI = confidence interval

PDLLCL = poly(DL-lactide- ϵ -caprolactone)

ePTFE = expanded polytetrafluoroethylene

Table 6. Linear regression models of graft incorporation. Model 1 is a regression model without the correction for interaction effects, model 2 with correction for interaction effects.

	Coefficients		t	Significance
	B (95% CI)	Std. Error		
Model 1				
Constant	1.030 (0.683 - 1.377)	0.175	5.884	0.000
Control (time)	0.876 (0.747 - 1.004)	0.065	13.489	0.000
PDLLCL	0.037 (-0.261 - 0.335)	0.151	0.248	0.804
Collagen	-0.139 (-0.449 - 0.170)	0.156	-0.891	0.375
ePTFE	0.111 (-0.187 - 0.408)	0.150	0.736	0.463
Model 2				
Constant	1.410 (0.810 - 2.010)	0.303	4.655	0.000
Control (time)	0.695 (0.428 - 0.961)	0.135	5.163	0.000
PDLLCL	-0.522 (-1.314 - 0.271)	0.400	-1.303	0.195
Collagen	-0.953 (-1.773 - -0.132)	0.414	-2.300	0.023
ePTFE	0.000 (-0.801 - 0.801)	0.404	-0.001	0.999
Interaction time*PDLLCL	0.273 (-0.090 - 0.636)	0.183	1.489	0.139
Interaction time*collagen	0.397 (0.027 - 0.768)	0.187	2.122	0.036
Interaction time*ePTFE	0.046 (-0.316 - 0.409)	0.183	0.252	0.801

CI = confidence interval

PDLLCL = poly(DL-lactide- ϵ -caprolactone)

ePTFE = expanded polytetrafluoroethylene

Discussion

The present study indicates that the barrier membranes studied do not have a preventive effect on autologous onlay bone block graft resorption in the rat mandible and that no positive effect of these membranes on graft incorporation is to be expected. Furthermore, there were no differences between the 3 membranes. Conclusions in other studies were conflicting (Jensen et al. 1995; Chiapasco et al. 1999; Rasmusson et al. 1999; Antoun et al. 2001). A systematic review revealed that the best available evidence up to the end of 2005 does not support membrane use (Gielkens et al. 2007).

The 2D perpendicular microradiographs in the present study indicate that the radiodensity in the graft surrounding area in comparison to the combined radiodensity of the mandibular bone and graft progressively increased from 2 to 12 weeks (Table 4), suggesting nearly complete loss of volume of the graft bone at 12 weeks in all groups (Table 1).

The regression analyses of the 3D μ CT measurements (Table 5) showed effect modification between collagen and time as well as between ePTFE and time. This suggests an increase of graft volume. However, model 1 shows a decrease in all groups and the amount of graft bone at each occasion is smaller than or similar in the collagen and ePTFE groups compared to the control and PDLLCL (Table 2). Therefore the clinical relevance of these effect modifications is small.

3D μ CT measurements demonstrated that especially the 12 week groups' samples have an intact graft volume combined with a defect in the underlying mandibular host bone of approximately the size of the graft. Therefore, the decrease in the combined radiodensity as found in MR seems to be the result of volume loss of host bone and probably a decrease of the grafts bone density. The defects in host bone might be caused by higher osteoclast-activity in mandibular bone due to a better perfusion. Covered grafts, consisting of predominantly cortical bone, may be less susceptible to revascularization and might rely on previous host bone resorption both to become revascularized and to model (Salata et al. 2002).

The regression analysis demonstrates that PDLLCL and ePTFE showed as much incorporation as the control (Table

6). In the collagen group an effect modification between collagen and time was observed. This demonstrates that collagen was significantly altered within the time frame of this study. However, no more incorporation was seen in the collagen group at each occasion compared to the other groups (Table 3, Table 6: model 1). This apparent contradiction can be explained by the fact that collagen showed the least incorporation at 2 weeks. The increase of new bone per unit of time thereafter is larger compared to the other groups. If measurements would have been performed at the moment of operation (0 weeks), when probably no incorporation would have been measured in any graft, the time effect would be more valid.

The results of MR are clinically more relevant, because the combined amount of bone in the graft area is represented. Another disadvantage of μ CT was a lower than expected contrast. The outline of the graft was especially difficult to discriminate in the 12 week groups where incorporation was almost complete. In this group, 2 cases were excluded for this reason, because the graft area could not be detected.

As in other *in vivo* experiments (Chiapasco et al. 1999; Donos et al. 2002b), large confidence intervals were seen. However, the smaller confidence intervals seen overall in the membrane-treated groups compared with non-treated controls, suggest a more predictable treatment outcome by membrane application. This is in line with results in other studies (Donos et al. 2002a; Donos et al. 2002b).

The relative large confidence intervals are related to the inter-individual variation. Graft diameter was similar in each specimen (4.0 mm diameter), the height varied due to irregular anatomy and other inter-individual differences. A longitudinal study design with repetitive measurements of each sample in sedated animals is needed for future research.

The method of fixing the grafts could have been of influence on the results of the present study. It has been reported that rigid fixation of the graft is necessary for graft incorporation and maintenance of graft volume (Raghoebar et al. 2006). For this reason fixation with a micro-screw would have been preferred. However, titanium micro-screws would have interfered with the evaluation by MR and μ CT. Also, a non-degradable material combined with a degradable membrane is not rational. Degradable micro-

screws were considered to be too large to use in this study. Furthermore, favourable results for membrane treatment had been demonstrated previously when the graft was not fixed (Alberius et al. 1992; Gordh et al. 1998).

An ideal barrier membrane is not yet available (Hardwick et al. 1994). Therefore a new degradable barrier membrane (PDLLCL) (Meek et al. 2004) was compared to the standard non-synthetic degradable (collagen) and the standard synthetic non-degradable (ePTFE) reference materials. All membranes tested equal compared to each other and to the control. PDLLCL has been shown to be biocompatible and non-cytotoxic (Meek et al. 2004) and the polymer is already applied in a commercially available nerve guide (Neurolac®, Polyganics, Groningen, The Netherlands) (Bertleff et al. 2005). PDLLCL has advantages when compared to the reference materials, because it is biodegradable and synthetic (Von Arx et al. 2002; Stavropoulos et al. 2004).

In conclusion, this study shows that the indication of barrier membrane-use to prevent bone modeling with resorption and enhance incorporation of autologous onlay bone grafts is disputable. No differences between the membranes were observed. It seems that barrier membranes are unnecessary in bone grafting procedures. However, in this study only onlay block grafts were used. When articulated bone is applied, a situation that is frequently seen in clinical practice (McAllister & Haghighat 2007), the barrier membrane is necessary to secure these granules but not to prevent bone resorption.

Acknowledgements

Mr. H. Bartels, Ms. Y. Heddema and Mr. J. de Vries are acknowledged for their assistance. Gratitude is expressed to Polyganics, Geistlich Biomaterials and W.L.Gore & Associates for the provision of each of the membranes.

References

- Alberius, P., Dahlin, C. & Linde, A. (1992) Role of osteopromotion in experimental bone grafting to the skull: a study in adult rats using a membrane technique. *J Oral Maxillofac Surg* 50: 829-834.
- Antoun, H., Sitbon, J.M., Martinez, H. & Missika, P. (2001) A prospective randomized study comparing two techniques of bone augmentation: onlay graft alone or associated with a membrane. *Clin Oral Implants Res* 12: 632-639.
- Bertleff, M.J., Meek, M.F. & Nicolai, J.P. (2005) A prospective clinical evaluation of biodegradable neuroloc nerve guides for sensory nerve repair in the hand. *J Hand Surg* 30: 513-518.
- Buser, D., Dula, K., Hirt, H.P. & Schenk, R.K. (1996) Lateral ridge augmentation using autografts and barrier membranes: a clinical study with 40 partially edentulous patients. *J Oral Maxillofac Surg* 54: 420-432.
- Chiapasco, M., Abati, S., Romeo, E. & Vogel, G. (1999) Clinical outcome of autogenous bone blocks or guided bone regeneration with e-PTFE membranes for the reconstruction of narrow edentulous ridges. *Clin Oral Implants Res* 10: 278-288.
- Donos, N., Kostopoulos, L. & Karring, T. (2002a) Augmentation of the mandible with GTR and onlay cortical bone grafting. *Clin Oral Implants Res* 13: 175-184.
- Donos, N., Kostopoulos, L. & Karring, T. (2002b) Augmentation of the rat jaw with autogeneic cortico-cancellous bone grafts and guided tissue regeneration. *Clin Oral Implants Res* 13: 192-202.
- Gielkens, P.F.M., Bos, R.R.M., Raghoobar, G.M. & Stegenga, B. (2007) Is there evidence that barrier membranes prevent bone resorption in autologous bone grafts during the healing period? A systematic review. *Int J Oral Maxillofac Implants* 22: 390-398.
- Gordh, M., Alberius, P., Johnell, O., Lindberg, L. & Linde, A. (1998) Osteopromotive membranes enhance onlay integration and maintenance in the adult rat skull. *Int J Oral Maxillofac Surg* 27: 67-73.
- Hardwick, R., Scantlebury, T., Sanchez, R., Whitley, N. & Ambruster, J. (1994) Membrane design criteria for guided bone regeneration of the alveolar ridge. In: Buser, D., Dahlin, C. & Schenk, R.K., eds. *Guided bone regeneration in implant dentistry*, p. 101-136. Chicago: Quintessence.
- Jensen, O.T., Greer, R.O., Johnson, L. & Kassebaum, D. (1995) Vertical guided bone-graft augmentation in a new canine mandibular model. *Int J Oral Maxillofac Implants* 10: 335-344.
- Kaban, L.B. & Glowacki, J. (1981) Induced osteogenesis in the repair of experimental mandibular defects in rats. *J Dent Res* 60: 1356-1364.
- Linde, A., Alberius, P., Dahlin, C., Bjurstram, K. & Sundin, Y. (1993) Osteopromotion: A soft-tissue exclusion principle using a membrane for bone healing and bone neogenesis. *J Periodontol* 64: 1116-1128.
- Machtei, E.E. (2001) The effect of membrane exposure on the outcome of regenerative procedures in humans: a meta-analysis. *J Periodontol* 72: 512-516.
- McAllister, B.S. & Haghghat, K. (2007) Bone augmentation techniques. *J Periodontol* 78: 377-396.
- Meek, M.F., Jansen, K., Steendam, R., van Oeveren, W., van Wachem, P.B. & van Luyn, M.J. (2004) In vitro degradation and biocompatibility of poly(DL-lactide-epsilon-caprolactone) nerve guides. *J Biomed Mater Res A* 68: 43-51.
- Raghoobar, G.M., Liem, R.S., Bos, R.R., van der Wal, J.E. & Vissink, A. (2006) Resorbable screws for fixation of autologous bone grafts. *Clin Oral Implants Res* 17: 288-293.
- Rasmusson, L., Meredith, N., Kahnberg, K.E. & Sennerby, L. (1999) Effects of barrier membranes on bone resorption and implant stability in onlay bone grafts. An experimental study. *Clin Oral Implants Res* 10: 267-277.
- Salata, L.Z., Rasmusson, L. & Kahnberg, K.E. (2002) Effects of a mechanical barrier on the integration of cortical onlay bone grafts placed simultaneously with endosseous implant. *Clin Implant Dent Relat Res* 4: 60-68.

Schortinghuis, J., Ruben, J.L., Meijer, H.J.A., Bronckers, A.L., Raghoobar, G.M. & Stegenga, B. (2003) Microradiography to evaluate bone growth into a rat mandibular defect. *Arch Oral Biol* 48: 155-160.

Stavropoulos, F., Dahlin, C., Ruskin, J.D. & Johansson, C. (2004) A comparative study of barrier membranes as graft protectors in the treatment of localized bone defects. An experimental study in a canine model. *Clin Oral Implants Res* 15: 435-442.

Von Arx, T., Cochran, D.L., Schenk, R.K. & Buser, D. (2002) Evaluation of a prototype trilayer membrane (PTLM) for lateral ridge augmentation: an experimental study in the canine mandible. *Int J Oral Maxillofac Surg* 31: 190-199.

Zellin, G. & Linde, A. (1997) Importance of delivery systems for growth-stimulatory factors in combination with osteopromotive membranes. An experimental study using rhBMP-2 in rat mandibular defects. *J Biomed Mater Res* 35: 181-190.

The influence of three different barrier membranes on modeling and incorporation of autologous bone grafts. An evaluation by transversal microradiography

5.2

This chapter is an edited version of the manuscript:

Gielkens, P.F.M., Hoogeveen, E.J., Schortinghuis, J., Ruben, J.L., Huysmans, M.C.D.N.J.M. & Stegenga, B.
The influence of three different barrier membranes on modeling and incorporation of autologous bone grafts.
An evaluation by transversal microradiography. *Submitted.*

Abstract

Objectives:

To determine whether covering autologous onlay bone block grafts with 3 different barrier membranes prevents graft resorption, and to compare these membranes to each other.

Material and Methods:

In 192 rats a standardised 4.0 mm diameter bone graft was harvested from the right mandibular angle and transplanted to the left. Membranes used to cover the grafts were a new poly(DL-lactide-e-caprolactone) membrane, a collagen and expanded polytetrafluoroethylene membrane. The controls were left uncovered. Graft resorption and incorporation were measured with transversal microradiography (TMR) in the 4 groups at 2, 4 and 12 weeks. Data were analysed using multiple regression analyses.

Results:

Overall, there were no differences in modeling with resorption between the 4 groups. ePTFE at 12 weeks showed a lower mineralization ratio and graft height of the graft as compared to the other groups. The mean graft incorporation was progressive and nearly identical from 2 to 12 weeks in all groups.

Conclusions:

Although PDLLCL has advantages when compared to the reference materials, the indication to use a barrier membrane to prevent bone modeling with resorption and enhance incorporation of autologous onlay bone block grafts is disputable.

Introduction

Guided bone regeneration is a commonly known technique for alveolar ridge augmentation in maxillofacial surgery. The technique has been proven to promote bone regeneration in bony defects when covered by a barrier membrane (McAllistar & Haghighat 2007). When an autologous bone graft is used to augment the alveolar ridge, it can be covered with similar barrier membranes. The bone graft serves as a scaffold and carrier for living cells. The barrier membrane on top of the graft is expected to prevent bone modeling with subsequent resorption of the bone graft and the membrane may improve the predictability of the augmentation by enhancing bone graft incorporation (Donos et al. 2002b). However, due to weak evidence (Gielkens et al. 2007), it is still unclear if a barrier membrane should be used to cover the augmented site (Chiapasco et al. 1999; Donos et al. 2002a).

Although different barrier membranes have been developed over the years, the ideal barrier membrane is not yet available. Some reasons are poor space-maintaining capacities (Stavropoulos et al. 2004) and the necessity of secondary removal. An optimal membrane should be biocompatible, occlusive, synthetic, space-maintaining, clinically manageable, and degradable (Hardwick et al. 1994; Kay et al. 1997; Von Arx et al. 2002).

A new poly(DL-lactide- ϵ -caprolactone) (PDLLCL) barrier membrane (Meek et al. 2004) might have advantages when compared to the currently applied barrier membranes. This membrane has been shown to be biocompatible and non-cytotoxic (Meek et al. 2004). The polymer is already applied in a commercially available nerve guide (Neurolac[®], Polyganics, Groningen, The Netherlands) (Bertleff et al. 2005). Based on its chemical composition and size it can be expected to be occlusive, space-maintaining and flexible enough to adapt to the contour of the cortical bone and graft.

In guided bone regeneration studies, radiology (Schortinghuis et al. 2003; Mueller et al. 2005), histology (Aaboe et al. 1998; Aslan et al. 2004) and histomorphometry (Nastri & Smith 1996) are common methods to evaluate bone volume and to specify the various cell types involved. However, bone mineralization and resulting density cannot be evaluated with these methods. Transversal

microradiography (TMR) is an accurate method of measuring mineral content in a thin irradiated cross-section of a sample (Arends et al. 1997). This method has proven to be valid, precise, and useful for measuring mineral loss in caries research (Kielbassa et al. 1999; Petersson & Kambara 2004). Therefore, it can be expected that accurate comparisons of bone mineralization can also be made with TMR (Raghoobar et al. 2005). The suitability and value of TMR in assessing graft modeling with resorption and incorporation has not been described before.

The objective of this study was first to study the preventive effect of a PDLLCL, collagen and expanded polytetrafluoroethylene (ePTFE) membrane on resorption of autologous onlay bone block grafts in the rat mandible, and second the effect of the membranes on graft incorporation.

Material and Methods

Surgical procedure

In the right mandibular angle of 192 male Sprague-Dawley rats (mean weight 364 g \pm 17 g SD, range 320-407 g) a standardised 5.0 mm circular defect was drilled with a trephine (Kaban & Glowacki 1981; Schortinghuis et al. 2003) and the obtained bone graft (4.0 mm diameter) was transplanted to the buccal side of the contralateral mandibular angle and fixed with a slowly degradable suture (Monocryl[®], Ethicon, Johnson & Johnson, Amersfoort, The Netherlands) through a central 1 mm hole in the graft.

The rats were assigned to 1 of 4 groups: 3 membrane groups and 1 control group, in which no membrane was used. The membranes used were (1) a copolymer sheet composed of 67-69% DL (15-85)-lactide and 31-33% ϵ -caprolactone (poly(DL-lactide- ϵ -caprolactone)) (Vivosorb[®], Polyganics, Groningen, The Netherlands), (2) a porcine bilayer collagen membrane (Geistlich Bio-Gide[®], Geistlich Biomaterials, Wolhusen, Switzerland), and (3) an expanded polytetrafluoroethylene membrane (ePTFE, Gore-Tex[®], W.L.Gore & Associates, Flagstaff, USA).

One side of the PDLLCL membranes was rough. These membranes were applied with this side faced to the bone to optimize integration and positioning.

The wound was closed in layers using resorbable sutures (Vicryl[®] Rapide 4-0, Ethicon, Johnson & Johnson,

Amersfoort, The Netherlands). Postoperative pain relief, a single dose of Caprofen (4.0 mg/kg) and Temgesic (0.03 mg/kg), was administered and the diet was composed of standard laboratory food.

After 2, 4 and 12 weeks, rats were anaesthetised by nitrous-oxygen-isoflurane inhalation anaesthesia and sacrificed by an intracardially injected overdose of pentobarbital, after which the mandibles were explanted and fixed in 4% phosphatebuffered formaline solution.

The study protocol was approved by the Animal Studies Review Committee, and in accordance with Institutional Guidelines (University Medical Center Groningen, The Netherlands).

Preparation of samples and transversal micro-radiography (TMR)

The specimens were placed in a metal mould and embedded in polymethylmethacrylate (PMMA). Thereby, blocks with standardized dimensions were obtained to facilitate precise cutting and to prevent the samples from drying. X-rays were taken to determine the exact location of the grafts. Through the center of the graft, 3 cuts were made in the transversal plane by a circular saw blade (Buehler Diamond Wafering Blade (11-4244), diameter 10.2 cm x 0.3 mm, USA) to create 2 cross-sections with a standardized thickness of 0.50 mm (Fig. 1).

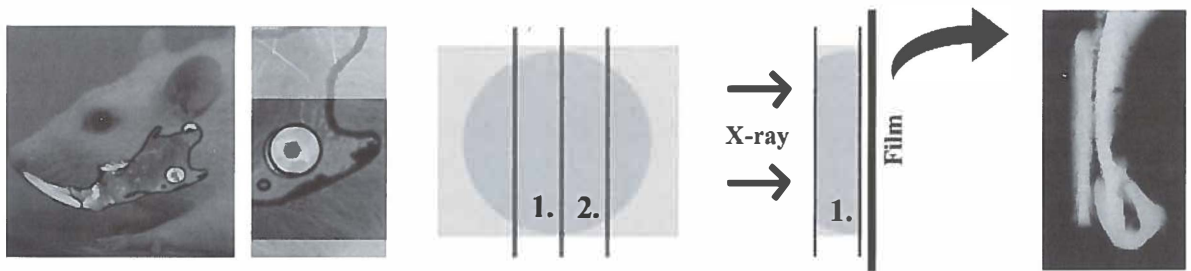
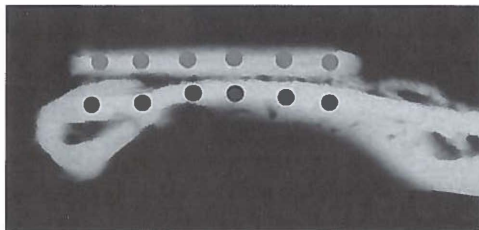


Fig. 1. Preparation of samples and transversal microradiography. Post mortem 3 cuts were made in the transversal plane through the center of the graft, located at the left mandibular angle, to create 2 cross-sections (1. and 2.) With an X-ray source transversal microradiographs were taken on film. After film development the images were magnified and digitized.



$$\text{Mineralization ratio} = \frac{\overline{\bullet} \text{ Grey value graft}}{\bullet \text{ Grey value underlying mandibular bone}}$$

Fig. 2. Graft modeling with resorption was measured as mineralization ratio, i.e., the ratio of the mean grey value of the bone graft in comparison to the mean grey value of the original underlying mandibular bone. The mean grey value in the 2 areas was obtained by selecting 12 spots on each radiograph; 6 within the bone graft and 6 within the original bone.

The sections were placed between a 35 mm film (Fuji B and W POS/71337) and an X-ray source (Philips PW 1730, Eindhoven, The Netherlands) and exposed for 18 seconds with a tube charge of 25 kV and 25 mA to obtain the transversal microradiographs (Raghoobar et al. 2005). After film development, a stereo microscope (Wild/Leitz M7 S, Heerbrugg, Switzerland; magnification 10x) and a CCD camera (Scion Corporation CFW 1312M, Frederick, MD, USA) were used to digitize the images. By means of a frame grabber the images were stored on a PC (resolution: 256 grey values / 1360 x 1024 pixels).

Measurement of graft modeling with resorption and graft incorporation

All measurements were performed twice under blind conditions and were averaged. Graft resorption was measured as mineralization ratio as well as graft height. The mineralization ratio was determined by dividing the mean grey value of the bone graft by the mean grey value of the original underlying mandibular bone. The mean grey value of the 2 areas was obtained by selecting 12 spots on each radiograph; 6 within the bone graft and 6 within the original bone (Fig. 2). The measurements were performed using image analysis software (Optical Bone Calculations, J. de Vries, University Medical Center Groningen, The Netherlands). Graft height was measured using image analysis software (Scion Corporation CFW 1312M, Frederick, MD, USA). A line was drawn between the center at the buccal side of the graft and the center of the lingual side of the graft; the length in pixels was measured automatically. Furthermore, graft incorporation, which was defined as a bony connection between graft and mandible, was measured (Schortinghuis et al. 2003). The percentage of incorporation was defined as the length of the incorporated part of the graft divided by the total length of the graft. When 0-25% of the graft was incorporated a score of 1 was assigned, and a score 2, 3 and 4 were assigned in case of 26-50%, 51-75% or 76-100% of incorporation, respectively.

Statistical analyses

The sample size was determined by a power analysis based on a 90% power with a 0.05 significance level, a 40% difference in graft size between a membrane-treated group and a non-treated control, and a mean standard deviation

of 29% (Donos et al. 2002b; Chiapasco et al. 1999). For each graft a mean score per variable was calculated by averaging the outcomes of the 2 corresponding sections. In a multiple regression analysis model the effect of the independent variables 'group' (i.e., control, PDLCL, collagen, ePTFE) and 'time' (i.e., 2, 4 and 12 weeks) and interactions between these variables on graft modeling with resorption and graft incorporation was studied.

Results

During surgery 6 rats died. In another 6 rats the graft fractured during drilling. These samples were excluded from the study. Due to problems during sectioning an additional number of samples had to be excluded. It resulted in a median group size of 14 samples (range 11-15) for mineralization, height and incorporation measurements.

The mean graft modeling with resorption as mineralization ratio, i.e., the ratio of the mean grey value of the bone graft in comparison to the mean grey value of the original underlying mandibular bone, is presented in Table 1. The mean graft modeling with resorption as graft height is presented in Table 2. Table 3 presents graft incorporation. In Table 1 and 2 is observed that ePTFE at 12 weeks shows a lower mineralization ratio and less graft height compared to the other membranes and control. Table 3 shows more incorporation in PDLCL at 2 weeks compared to the other groups.

The regression analyses of the graft modeling with resorption measured as mineralization ratio and as graft height as well as graft incorporation are summarized in Table 4, 5 and 6, respectively. Model 1 is a regression model without the correction for possible effect modification (interaction effects). Model 2 is a regression model with correction for effect modification of time and membrane (i.e., PDLCL, collagen or ePTFE), respectively. Both models are presented to give the reader information about the relative effect of the coefficients with and without correction for effect modifications, as interaction may dramatically change the value of the crude coefficients. The regression analyses showed that graft resorption as mineralization ratio was lower in the ePTFE groups compared to the other membrane groups and control. The graft height as depicted

Table 1. Graft modeling with resorption as mineralization ratio, i.e., the ratio of the mean grey value of the bone graft in comparison to the mean grey value of the original underlying mandibular bone (Fig. 2).

	2 wks (95% CI) (g / m)	4 wks (95% CI) (g / m)	12 wks (95% CI) (g / m)
Control	0.94 (0.88 - 1.00)	0.97 (0.93 - 1.01)	0.95 (0.93 - 0.97)
PDLLCL	0.94 (0.91 - 0.97)	0.95 (0.91 - 0.99)	0.90 (0.87 - 0.93)
Collagen	0.92 (0.88 - 0.96)	0.96 (0.94 - 0.98)	0.92 (0.87 - 0.97)
ePTFE	0.94 (0.92 - 0.96)	0.99 (0.97 - 1.01)	0.82 (0.77 - 0.87)

CI = confidence interval

PDLLCL = poly(DL-lactide- ϵ -caprolactone)

ePTFE = expanded polytetrafluoroethylene

g = graft bone; m = mandibular bone

Table 2. Graft modeling with resorption as graft height measured in the center of the grafts scored in mm. A line was drawn between the center at the buccal side of the graft and the center of the lingual side of the graft; the length in pixels was measured automatically.

	2 wks (95% CI) (mm)	4 wks (95% CI) (mm)	12 wks (95% CI) (mm)
Control	0.54 (0.43 - 0.65)	0.56 (0.36 - 0.76)	0.44 (0.32 - 0.56)
PDLLCL	0.44 (0.35 - 0.53)	0.40 (0.36 - 0.44)	0.41 (0.33 - 0.49)
Collagen	0.28 (0.24 - 0.32)	0.38 (0.32 - 0.44)	0.40 (0.31 - 0.49)
ePTFE	0.28 (0.24 - 0.32)	0.50 (0.39 - 0.61)	0.19 (0.15 - 0.23)

CI = confidence interval

PDLLCL = poly(DL-lactide- ϵ -caprolactone)

ePTFE = expanded polytetrafluoroethylene

Table 3. Mean graft incorporation. When 0-25% of the graft was incorporated a score of 1 was assigned, and a score 2, 3 and 4 were assigned in case of 26-50%, 51-75% or 76-100% of incorporation, respectively.

	2 wks (95% CI) (1-4)	4 wks (95% CI) (1-4)	12 wks (95% CI) (1-4)
Control	1.18 (0.83 - 1.53)	2.18 (1.55 - 2.81)	3.27 (2.70 - 3.84)
PDLLCL	2.36 (1.97 - 2.75)	2.86 (2.41 - 3.31)	3.36 (2.95 - 3.77)
Collagen	1.17 (1.03 - 1.31)	2.42 (1.98 - 2.86)	2.96 (2.37 - 3.55)
ePTFE	1.79 (1.33 - 2.25)	2.29 (1.87 - 2.71)	3.29 (2.99 - 3.59)

CI = confidence interval

PDLLCL = poly(DL-lactide- ϵ -caprolactone)

ePTFE = expanded polytetrafluoroethylene

Table 4. Linear regression models of graft modeling with resorption as mineralization ratio. Model 1 is a regression model without the correction for interaction effects, model 2 with correction for interaction effects.

	Coefficients		t	Significance
	B (95% CI)	Std. Error		
Model 1				
Constant	1.001 (0.962 - 1.040)	0.020	50.702	0.000
Control (time)	-0.022 (-0.036 - -0.007)	0.007	-2.909	0.004
PDLLCL	-0.027 (-0.060 - 0.007)	0.017	-1.583	0.115
Collagen	-0.025 (-0.059 - 0.009)	0.017	-1.431	0.155
ePTFE	-0.044 (-0.078 - -0.011)	0.017	-2.602	0.010
Model 2				
Constant	0.951 (0.885 - 1.017)	0.033	28.597	0.000
Control (time)	0.002 (-0.027 - 0.032)	0.015	0.156	0.876
PDLLCL	0.024 (-0.065 - 0.114)	0.045	0.540	0.590
Collagen	-0.012 (-0.104 - 0.080)	0.046	-0.262	0.794
ePTFE	0.082 (-0.007 - 0.171)	0.045	1.821	0.071
Interaction time*PDLLCL	-0.024 (-0.065 - 0.016)	0.020	-1.194	0.234
Interaction time*collagen	-0.006 (-0.047 - 0.036)	0.021	-0.267	0.790
Interaction time*ePTFE	-0.062 (-0.102 - -0.022)	0.020	-3.030	0.003

CI = confidence interval

PDLLCL = poly(DL-lactide-ε-caprolactone)

ePTFE = expanded polytetrafluoroethylene

Table 5. Linear regression models of graft modeling with resorption as graft height. Model 1 is a regression model without the correction for interaction effects, model 2 with correction for interaction effects.

	Coefficients		t	Significance
	B (95% CI)	Std. Error		
Model 1				
Constant	0.537 (0.437 - 0.638)	0.051	10.572	0.000
Control (time)	-0.012 (-0.050 - 0.025)	0.019	-0.653	0.515
PDLLCL	-0.096 (-0.182 - -0.009)	0.044	-2.184	0.030
Collagen	-0.155 (-0.243 - -0.067)	0.045	-3.477	0.001
ePTFE	-0.189 (-0.276 - -0.103)	0.044	-4.330	0.000
Model 2				
Constant	0.625 (0.453 - 0.797)	0.087	7.169	0.000
Control (time)	-0.054 (-0.131 - 0.023)	0.039	-1.394	0.165
PDLLCL	-0.182 (-0.416 - 0.052)	0.118	-1.539	0.126
Collagen	-0.396 (-0.637 - -0.156)	0.122	-3.253	0.001
ePTFE	-0.215 (-0.449 - 0.019)	0.118	-1.814	0.072
Interaction time*PDLLCL	0.041 (-0.065 - 0.147)	0.054	0.768	0.444
Interaction time*collagen	0.117 (0.009 - 0.225)	0.055	2.134	0.034
Interaction time*ePTFE	0.011 (-0.095 - 0.117)	0.054	0.197	0.844

CI = confidence interval

PDLLCL = poly(DL-lactide-ε-caprolactone)

ePTFE = expanded polytetrafluoroethylene

Table 6. Linear regression models of graft incorporation. Model 1 is a regression model without the correction for interaction effects, model 2 with correction for interaction effects.

	Coefficients		t	Significance
	B (95% CI)	Std. Error		
Model 1				
Constant	0.656 (0.215 - 1.097)	0.223	2.937	0.004
Control (time)	0.789 (0.623 - 0.954)	0.084	9.406	0.000
PDLLCL	0.624 (0.244 - 1.003)	0.192	3.243	0.001
Collagen	-0.043 (-0.430 - 0.343)	0.196	-0.221	0.825
ePTFE	0.219 (-0.161 - 0.599)	0.192	1.138	0.257
Model 2				
Constant	0.118 (-0.638 - 0.874)	0.383	0.309	0.758
Control (time)	1.045 (0.708 - 1.381)	0.170	6.135	0.000
PDLLCL	1.739 (0.712 - 2.766)	0.520	3.345	0.001
Collagen	0.288 (-0.769 - 1.345)	0.535	0.538	0.591
ePTFE	0.834 (-0.193 - 1.861)	0.520	1.605	0.111
Interaction time*PDLLCL	-0.545 (-1.010 - -0.079)	0.236	-2.312	0.022
Interaction time*collagen	-0.155 (-0.630 - 0.319)	0.240	-0.647	0.519
Interaction time*ePTFE	-0.295 (-0.760 - 0.171)	0.236	-1.251	0.213

CI = confidence interval

PDLLCL = poly(DL-lactide-ε-caprolactone)

ePTFE = expanded polytetrafluoroethylene

in model 2 increased only in the collagen group, whereas model 1 shows a decreasing graft height in this group. No differences were seen between the other groups. Based upon model 2, graft incorporation in the other groups increased more compared to PDLLCL, whereas model 1 showed that PDLLCL increased more compared to other membranes. Overall, equal results were obtained in membrane and control groups, although minor differences were observed.

Discussion

The results of the present study indicate that the barrier membranes studied do not have a preventive effect on autologous onlay bone block graft resorption in the rat mandible. Furthermore, the results do not support the statement that membranes would have a positive effect on graft incorporation. Conclusions in other studies were conflicting (Jensen et al. 1995; Chiapasco et al. 1999; Rasmusson et al. 1999; Antoun et al. 2001). Based on the results of a systematic review of the literature, it was concluded that the best available evidence up to the end of 2005 does not support membrane use to prevent autologous graft resorption (Gielkens et al. 2007).

In the present study graft modeling with resorption was evaluated as mineralization ratio and graft height. The mineralization was measured as a ratio between the mean grey values of the bone graft and of the original underlying mandibular bone. An absolute value of mineralization would have been more appropriate. However, calibration and validation of mineral content of different types of bone related to grey values of microradiographs is difficult. Therefore, in the present study the grey value of the original underlying original bone was chosen as 100 percent mineralization. Theoretically the original underlying original bone is more or less constant. However, especially in the 12 weeks' samples mineral was lost in the original underlying bone that possibly would explain the higher than expected mineralization ratios. It was expected that graft resorption with mineral loss, demonstrated by a decreasing ratio, would be observed from 2 to 12 weeks. However, this was only seen in the ePTFE group (Table 1 and 4). Care was taken that the mineralization of the

underlying original bone was measured in areas unaffected by modeling with resorption. The mineralization ratio and graft height of ePTFE at 12 weeks was lower compared to other groups (Table 1 and 2). It is known that ePTFE exposure to the oral environment during healing has a major negative effect on guided bone regeneration around dental implants because of infection (Machtei 2001). However, in the present study no exposure of the ePTFE membranes was observed.

Graft height increased only in the collagen groups from 2 to 12 weeks (Table 5). However, model 1 shows a decreasing graft height in the collagen group and the graft height at each occasion is smaller than or similar to the other groups (Table 5). Therefore the clinical relevance of the effect modification between time and collagen is small. A notable finding was the rather large graft height in the control groups compared to the membrane groups (Table 2). Unrestrained growth of bone in the graft surrounding region was seen in some control samples, which might explain the high means and large confidence intervals in the controls. The smaller confidence intervals seen overall in the membrane-treated groups suggest a more predictable treatment outcome by membrane application. This is in line with results in other studies (Donos et al. 2002a; Donos et al. 2002b).

The mean incorporation was progressive from 2 to 12 weeks in all groups. Most incorporation of the graft was seen in the PDLLCL groups compared to the other groups. However, since model 2 (Table 6) showed that there was effect modification between PDLLCL and time, incorporation of the graft beneath the PDLLCL membrane was significantly altered within the time frame of this study, suggesting a decreasing incorporation. This apparent contradiction can be explained by the fact that PDLLCL showed already a large amount of incorporation at 2 weeks. The increase of graft incorporation per unit of time thereafter is less compared to the other groups, although the amount of incorporation at each occasion was larger. If measurements would have been performed at the moment of operation (0 weeks), when probably no graft incorporation would have been measured in any graft, the time effect would be more valid.

The method of fixing the grafts in the present study could have been of influence on the study. Although favourable

results for membrane treatment had been demonstrated previously when the graft was not fixed (Alberius et al. 1992; Gordh et al. 1998), rigid fixation with a micro-screw would have been preferable (Raghoobar et al. 2006). However, titanium micro-screws would have interfered with the evaluation by TMR and degradable micro-screws were too large to use in this study.

In this study the new degradable barrier membrane (PDLLCL) (Meek et al. 2004) was compared to the standard non-synthetic degradable (collagen) and the standard synthetic non-degradable (ePTFE) reference materials. Although the graft of the ePTFE 12 weeks group demonstrated more resorption than the grafts in the other groups, generally all membranes tested equal compared to each other and to the control. PDLLCL has been shown to be biocompatible and non-cytotoxic (Meek et al. 2004). PDLLCL has advantages when compared to the reference materials, because it is biodegradable and synthetic (Von Arx et al. 2002; Stavropoulos et al. 2004). However, since the control group without a membrane performed equally well, the indication to use barrier membranes to prevent bone modeling with resorption and enhance incorporation of autologous onlay bone block grafts is disputable according to our measurements.

Mineralization cannot be measured as accurately in microradiography compared to TMR, because of varying thickness of the mandible (and graft). Clear high quality and resolution pictures were obtained with TMR, and differences in mineralization could be observed. However, the procedure is time consuming and only 2 sections per sample are examined.

When TMR is applied in caries research, sections with a maximum thickness of 80 to 150 μm are used (Arends et al. 1997). Because only mineralized tissues are involved, these thin sections have sufficient strength. The sections of the autologous bone grafts contained a relatively large amount of soft tissue, making them vulnerable. Therefore, larger dimensions were chosen, resulting in a section thickness of 0.50 mm. A disadvantage of this increased thickness is that neither individual bone trabeculae nor their orientation could be made visible on the radiographs.

In conclusion, membranes and controls have an equal effect on bone graft modeling and incorporation. It seems, therefore, that barrier membranes are unnecessary in

bone grafting procedures with autologous onlay bone block grafts. When particulated bone is applied, a situation that is frequently seen in clinical practice (McAllister & Haghghat 2007), the barrier membrane is necessary to secure these granules but probably does not prevent bone resorption. For clinicians an evidence-based approach is recommended when developing a treatment plan for bone augmentation cases (McAllister & Haghghat 2007).

Acknowledgements

Gratitude is expressed to Mr. J. de Vries for designing the software. Mr. H. Bartels and Ms. Y. Heddemma are acknowledged for their assistance during the surgical procedures. Furthermore, we would like to thank Polyganics for the provision of the Vivosorb® membranes, Geistlich Biomaterials for the Geistlich Bio-Gide® membranes and W.L.Gore & Associates for the Gore-Tex® Regenerative Membranes.

References

- Aaboe, M., Pinholt, E.M., Schou, S. & Hjørtting-Hansen, E. (1998) Incomplete bone regeneration of rabbit calvarial defects using different membranes. *Clin Oral Implants Res* 9: 313-320.
- Alberius, P., Dahlin, C. & Linde, A. (1992) Role of osteopromotion in experimental bone grafting to the skull: a study in adult rats using a membrane technique. *J Oral Maxillofac Surg* 50: 829-834.
- Antoun, H., Sitbon, J.M., Martinez, H. & Missika, P. (2001) A prospective randomized study comparing two techniques of bone augmentation: onlay graft alone or associated with a membrane. *Clin Oral Implants Res* 12: 632-639.
- Arends, J., Ruben, J.L. & Inaba, D. (1997) Major topics in quantitative microradiography of enamel and dentin: R parameter, mineral distribution visualization, and hyper-remineralization. *Adv Dent Res* 11: 403-414.
- Aslan, M., Simsek, G. & Dayi, E. (2004) Guided bone regeneration (GBR) on healing bone defects: a histological study in rabbits. *J Contemp Dent Pract* 5: 114-123.
- Bertleff, M.J., Meek, M.F. & Nicolai, J.P. (2005) A prospective clinical evaluation of biodegradable neurolac nerve guides for sensory nerve repair in the hand. *J Hand Surg* 30: 513-518.
- Chiapasco, M., Abati, S., Romeo, E. & Vogel, G. (1999) Clinical outcome of autogenous bone blocks or guided bone regeneration with e-PTFE membranes for the reconstruction of narrow edentulous ridges. *Clin Oral Implants Res* 10: 278-288.
- Donos, N., Kostopoulos, L. & Karring, T. (2002a) Augmentation of the mandible with GTR and onlay cortical bone grafting. *Clin Oral Implants Res* 13: 175-184.
- Donos, N., Kostopoulos, L. & Karring, T. (2002b) Augmentation of the rat jaw with autogeneic cortico-cancellous bone grafts and guided tissue regeneration. *Clin Oral Implants Res* 13: 192-202.
- Gielkens, P.F.M., Bos, R.R.M., Raghoobar, G.M. & Stegenga, B. (2007) Is there evidence that barrier membranes prevent bone resorption in autologous bone grafts during the healing period? A systematic review. *Int J Oral Maxillofac Implants* 22: 390-398.
- Gordh, M., Alberius, P., Johnell, O., Lindberg, L. & Linde, A. (1998) Osteopromotive membranes enhance onlay integration and maintenance in the adult rat skull. *Int J Oral Maxillofac Surg* 27: 67-73.
- Hardwick, R., Scantlebury, T., Sanchez, R., Whitley, N. & Ambruster, J. (1994) Membrane design criteria for guided bone regeneration of the alveolar ridge. In: Buser, D., Dahlin, C. & Schenk, R.K., eds. *Guided bone regeneration in implant dentistry*, p. 101-136. Chicago: Quintessence.
- Jensen, O.T., Greer, R.O., Johnson, L. & Kassebaum, D. (1995) Vertical guided bone-graft augmentation in a new canine mandibular model. *Int J Oral Maxillofac Implants* 10: 335-344.
- Kaban, L.B. & Glowacki, J. (1981) Induced osteogenesis in the repair of experimental mandibular defects in rats. *J Dent Res* 60: 1356-1364.
- Kay, S.A., Wisner-Lynch, L., Marxer, M. & Lynch, S.E. (1997) Guided bone regeneration: integration of a resorbable membrane and a bone graft material. *Pract Periodontics Aesthet Dent* 9: 185-194.
- Kielbassa, A.M., Wrbas, K.T., Schulte-Mönting, J. & Hellwig, E. (1999) Correlation of transversal microradiography and microhardness on in situ-induced demineralization in irradiated and nonirradiated human dental enamel. *Arch Oral Biol* 44: 243-251.
- Machtei, E.E. (2001) The effect of membrane exposure on the outcome of regenerative procedures in humans: a meta-analysis. *J Periodontol* 72: 512-516.
- McAllister, B.S. & Haghghat, K. (2007) Bone augmentation techniques. *J Periodontol* 78: 377-396.
- Meek, M.F., Jansen, K., Steendam, R., van Oeveren, W., van Wachem, P.B. & van Luyn, M.J. (2004) In vitro degradation and biocompatibility of poly(DL-lactide-epsilon-caprolactone) nerve guides. *J Biomed Mater Res A* 68: 43-51.
- Mueller, A.A., Rahn, B.A., Gogolewski, S. & Leiggener, C.S. (2005) Early dural reaction to polylactide in cranial defects in rabbits.

Pediatr Neurosurg 41: 285-291.

Nastri, A.L. & Smith, A.C. (1996) Guided osteogenesis using synthetic membranes: an experimental pilot study. *J Craniomaxillofac Surg* 24: 163-167.

Petersson, L.G. & Kambara, M. (2004) Remineralisation study of artificial root caries lesions after fluoride treatment. An in vitro study using electric caries monitor and transversal micro-radiography. *Gerodontology* 21: 85-92.

Raghoobar, G.M., Schortinghuis, J., Liem, R.S., Ruben, J.L., van der Wal, J.E. & Vissink, A. (2005) Does platelet-rich plasma promote remodeling of autologous bone grafts used for augmentation of the maxillary sinus floor? *Clin Oral Implants Res* 16: 349-356.

Raghoobar, G.M., Liem, R.S., Bos, R.R., van der Wal, J.E. & Vissink, A. (2006) Resorbable screws for fixation of autologous bone grafts. *Clin Oral Implants Res* 17: 288-293.

Rasmusson, L., Meredith, N., Kahnberg, K.E. & Sennerby, L. (1999) Effects of barrier membranes on bone resorption and implant stability in onlay bone grafts. An experimental study. *Clin Oral Implants Res* 10: 267-277.

Schortinghuis, J., Ruben, J.L., Meijer, H.J.A., Bronckers, A.L., Raghoobar, G.M. & Stegenga, B. (2003) Microradiography to evaluate bone growth into a rat mandibular defect. *Arch Oral Biol* 48: 155-160.

Stavropoulos, F., Dahlin, C., Ruskin, J.D. & Johansson, C. (2004) A comparative study of barrier membranes as graft protectors in the treatment of localized bone defects. An experimental study in a canine model. *Clin Oral Implants Res* 15: 435-442.

Von Arx, T., Cochran, D.L., Schenk, R.K. & Buser, D. (2002) Evaluation of a prototype trilayer membrane (PTLM) for lateral ridge augmentation: an experimental study in the canine mandible. *Int J Oral Maxillofac Surg* 31: 190-199.

Barrier membranes over bone defects

Vivosorb[®], Geistlich Bio-Gide[®] and Gore-Tex[®] as barrier membranes in rat mandibular defects. An evaluation by microradiography and micro-CT

This chapter is an edited version of the manuscript:

Gielkens, P.F.M., Schortinghuis, J., de Jong, J.R., Raghoobar, G.M., Stegenga, B. & Bos, R.R.M. (2008)
Vivosorb[®], Bio-Gide[®] and Gore-Tex[®] as barrier membranes in rat mandibular defects.
An evaluation by microradiography and micro-CT. *Clin Oral Implants Res* 19: 516-521.

Abstract

Objectives:

The objectives of this study were to determine whether a new degradable synthetic barrier membrane (Vivosorb®) composed of poly(DL-lactide- ϵ -caprolactone) (PDLLCL) can be useful in implant dentistry and to compare it with collagen and expanded polytetrafluoroethylene (ePTFE) membranes.

Material and Methods:

In 192 male Sprague-Dawley rats, a standardised 5.0 mm circular defect was created through the right angle of the mandible. New bone formation was evaluated by post-mortem microradiography and micro-CT (μ CT) imaging. Four groups (control, PDLLCL, collagen, ePTFE) were evaluated at 3 time intervals (2, 4 and 12 weeks). In the membrane groups the defects were covered; in the control group the defects were left uncovered. Data were analysed using a multiple regression model.

Results:

New bone formation could be detected by post-mortem microradiography in 163 samples and by μ CT imaging in 110 samples. Bone formation was progressive in 12 weeks, when the mandibular defect was covered with a membrane. Overall, more bone formation was observed underneath the collagen and ePTFE membranes than the PDLLCL membranes.

Conclusions:

In contrast to uncovered mandibular defects, substantial bone healing was observed in defects covered with a PDLLCL membrane. However, bone formation in PDLLCL covered defects tended to be less than in the defects covered with collagen or ePTFE. The high variation in the PDLLCL samples at 12 weeks may be caused by the moderate adherence of this membrane to bone compared with collagen. These results indicate that further study is needed to optimize the properties of PDLLCL membranes.

Introduction

For predictable osseointegration of dental implants and good aesthetics, the presence of sufficient bone is necessary. Bone deficiency is therefore considered a major problem, and an extensive number of treatment modalities for alveolar ridge augmentation have been used in an attempt to solve this problem. Applied treatment modalities are guided bone regeneration (Nyman 1991), transplantation of autologous bone grafts (Antoun et al. 2001; Von Arx et al. 2002; Donos et al. 2002), bone substitutes (Zitzmann et al. 2001), or a combination of these (Hallman et al. 2005). As early as in the 1950s, it was stated that the presence of a blood clot is necessary for new bone formation (Murray et al. 1957). In guided bone regeneration, a barrier membrane prevents in-growth of fibroblasts and provides a space for osteogenesis within the clot (Hollinger et al. 1999). Furthermore, the barrier membrane would exclude inhibiting factors and preserve growth factors (Ogiso et al. 1991; Zellin & Linde 1997). Although different barrier membranes have been developed, the ideal barrier membrane is not yet available. Non-degradable membranes have better space-maintaining properties than degradable membranes, but non-degradable membranes need to be removed in a second operation (Stavropoulos et al. 2004). Also, when exposed to the oral cavity, early removal of these membranes is frequently necessary because of infection (Machtei 2001; Wang & Carroll 2001). Degradable membranes are often animal derived, and may lead to disease transmission from animal to people (von Arx et al. 2002). An optimal membrane should be biocompatible, occlusive, synthetic, space-maintaining, clinically manageable, and degradable (Hardwick et al. 1994; Kay et al. 1997; von Arx et al. 2002).

In order to optimize membrane function, a new degradable membrane has been developed (Vivosorb[®]) (Meek et al. 2004). This membrane might have advantages compared with the currently existing barrier membranes. It is composed of poly(DL-lactide- ϵ -caprolactone) (PDLLCL), which is biocompatible and non-cytotoxic (Meek et al. 2004). The polymer is already applied in a commercially available nerve guide (Neurolac[®], Polyganics, Groningen, The Netherlands) (Bertleff et al. 2005). Based on its chemical composition and size, it can be expected to be occlusive,

space-maintaining, and flexible enough to adapt to the contour of the cortical bone.

The aim of this study was to evaluate PDLLCL as a guided bone regeneration membrane for bone formation in rat mandibular defects, and to compare it with a collagen and expanded polytetrafluoroethylene membrane.

Material and Methods

Under nitrous-oxygen-isoflurane inhalation anaesthesia, a standardized 5.0 mm circular defect was drilled with a trephine in the right mandibular angle of male Sprague-Dawley rats (Kaban & Glowacki 1981; Schortinghuis et al. 2003). Four groups were studied: 3 membrane groups and 1 control group. The membranes used were (1) a polymer sheet composed of 67-69% DL (15-85)-lactide and 31-33% ϵ -caprolactone PDLLCL (Vivosorb[®], Polyganics, Groningen, The Netherlands), (2) a type 1 and 3 porcine bilayer collagen (Geistlich Bio-Gide[®], Geistlich Biomaterials, Wolhusen, Switzerland), and (3) an expanded polytetrafluoroethylene membrane (ePTFE, Gore-Tex[®], W.L.Gore & Associates, Flagstaff, USA). One side of the PDLLCL membranes was rough. The membranes were applied with this rough side faced to the bone to optimize integration and positioning. In the membrane-treated groups, the defect was covered with a barrier membrane on the buccal and lingual side (Fig. 1). In the control group no membrane was used. The wound was closed in layers using 4-0 resorbable sutures (Vicryl[®] Rapid 4-0, Ethicon, Johnson & Johnson, Amersfoort, The Netherlands) (Schortinghuis et al. 2003). A single dose of Caprofen (4 mg/kg) and Temgesic (0.03 mg/kg) was administered for post-operative pain relief. The diet was composed of standard laboratory food.

After 2, 4 and 12 weeks, a subset of rats in each group was anaesthetized by nitrous-oxygen-isoflurane inhalation anaesthesia and sacrificed by an intracardial injected overdose of pentobarbital. Then the mandibles were explanted and fixated in 4% phosphate-buffered formaline solution. The study protocol was approved by the Animal Studies Review Committee, and in accordance with Institutional Guidelines (University Medical Center Groningen, The Netherlands).

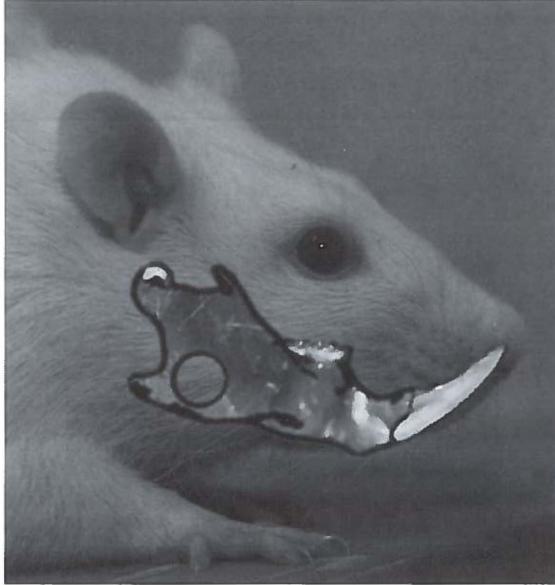


Fig. 1. A 5.0 mm diameter defect was drilled in the right mandibular angle. The defect was left uncovered in the control as shown. In the other groups the defects were covered on the buccal and lingual side with barrier membranes.

Microradiography and micro-CT

An X-ray source (Philips PW 1730, Eindhoven, The Netherlands) was used to take microradiographs of the explanted parts of the mandible on a 35 mm film (Fuji B and W POS/71337). Care was taken to place the mandibular buccal plane parallel to the film to assure a rectangular recording of the defects. After development of the film, digital images of the original microradiographs of the mandibular defects were recorded with a stereo microscope (Wild/Leitz M7S, Heerbrugg, Switzerland) with a magnification 10x and a CCD camera (Scion Corporation CFW 1312M, Frederick, MD, USA). The camera was linked to a personal computer equipped with a frame grabber. The magnified images were stored as images with a size of 1360 x 1024 pixels and with a resolution of 256 grey values. Then the specimens were embedded in polymethylmethacrylate. Micro-CT (μ CT) images were obtained using the Siemens MicroCAT II pre-clinical cone-beam CT scanner. The CCD

sensor measured 7 x 5 cm. The specimens were arranged in a 3-dimensional (3D) array not exceeding field of view dimensions in order to prevent truncation artefacts. The images were obtained resulting in 3D images with an isotropic voxel size of 48 x 48 x 48 μ m.

Measurement of new bone formation

The principal investigator was blinded during the evaluation of the explanted samples. In the microradiographs the amount of new bone formation was expressed as a percentage of defect closure using image analysis software (Scion, Scion Corporation, Frederick, MD, USA) (Schortinghuis et al. 2004). First, based on the difference in grey values, the individual threshold of bone/no-bone boundary was determined for each digitized microradiograph. Subsequently, this threshold was applied to the 5.0 mm defect as a whole and the remaining defect area was computed automatically. Finally, the remaining defect area was expressed as a percentage of the original defect size (diameter 5.0 mm) (Fig. 2).

The 3D μ CT data sets were evaluated with image analysis software (AMIRA 4.1, Mercury Computer Systems, Chelmsford, MA, USA). First, a sagittal plane perpendicular to the central axis of the defect was determined. Then the lateral and medial limits of the defect parallel to this plane were established. Every third (corresponding to an interval of 144 μ m) 2D μ CT image between these limits was saved in a file. A mean bone/no-bone threshold was determined and applied to all data. For each sample, a mean volume of new bone in the 5.0 mm defect area was calculated by multiplying the sum of all areas of new bone by 144 μ m (i.e., the thickness of 3 CT slides) (Fig. 3). Samples in which the defect was in continuum with the apex, which contains odontogenic cells, of the rats continuously erupting incisor (Levy 1971) were excluded from analysis, as were those with fractures in the mandibles.

Statistical analyses

The sample size was determined by a power analysis based on 90% power with a 0.05 significance level, a 20% difference in new bone formation between a membrane-treated group and non-treated control, and a standard deviation of 18% (Schortinghuis et al. 2004, 2005).

In a multiple regression analysis model, defect closure

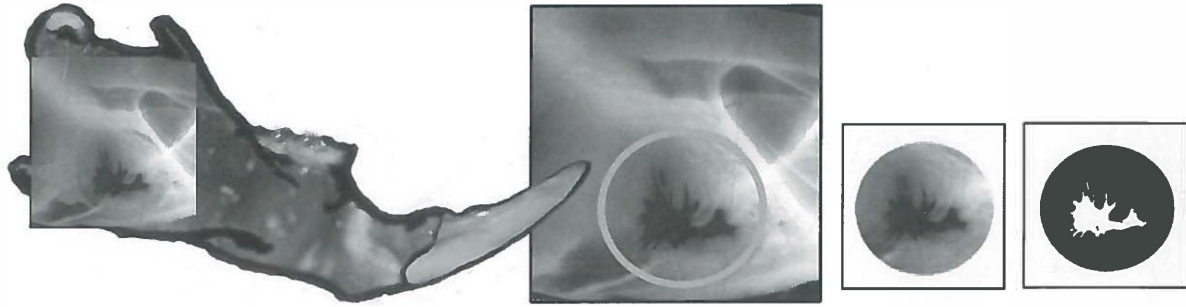


Fig. 2. Microradiographic evaluation of the defects. A 5.0 mm diameter circle was selected corresponding to the original defect. Based on the difference in grey values, the threshold of bone/no-bone boundary was determined for the selected area and applied. The remaining defect area was computed automatically and expressed as a percentage of the original defect size.

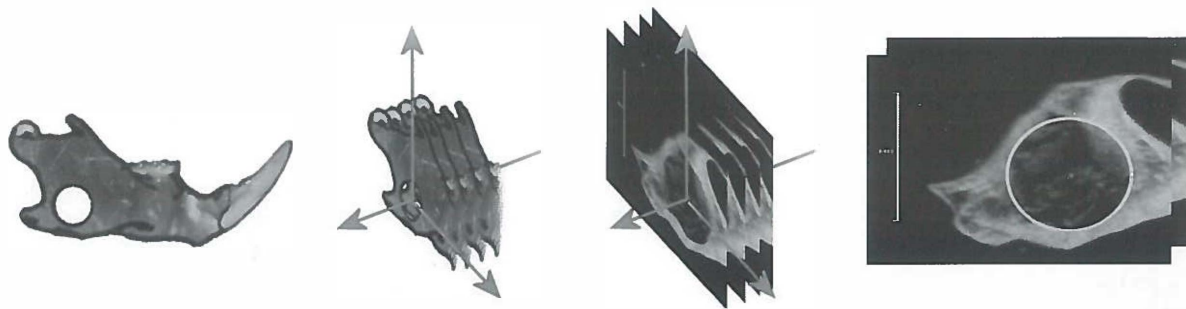


Fig. 3. Measurement of new bone volume in defects by micro-CT. A sagittal plane perpendicular to the central axis of the defect and thus parallel to the mandible was determined. Every third 2D micro-CT image between the lateral and medial limits of the defect was saved in a file. In these images, new bone formation was measured as a surface area corresponding to the microradiographic evaluation.

was predicted as a function of the independent variable 'group' (i.e., control, PDLCL, collagen and ePTFE) and 'time' (i.e., 2, 4, and 12 weeks) and interactions of these variables.

Results

One hundred and ninety-two rats (mean weight $364 \text{ g} \pm 17 \text{ g}$ SD, range 320-407 g) were assigned to 1 of 4 groups of 48 rats: 3 membrane groups and 1 control group. During surgery 6 rats had died. In 5 rats, a continuum of the defect and apex of the incisor was observed. In 12 rats

the mandibular border fractured during drilling, and in 7 rats a fracture was found during evaluation of the images. These specimens were excluded from statistical analysis and resulted in a median group size of 14 (range 10-16) for microradiographic (MR) evaluation and a median group size of 10 (range 6-11) for μCT . No wound infection or dehiscence occurred and all other animals gained weight. The mean percentages of defect closure in all groups as found with MR are presented in Table 1, and the mean volumes of new bone in the defects as evaluated by μCT are summarized in Table 2. The regression analyses of the mean percentages and volumes in MR and μCT are summarized in Tables 3 and 4, respectively.

Table 1. Percentage of defect closure as measured by microradiography.

	2 wks (95% CI)	4 wks (95% CI)	12 wks (95% CI)
PDLLCL	35.1 (27.8 - 42.4)	52.0 (42.7 - 61.3)	68.9 (55.4 - 82.4)
Control	22.8 (16.9 - 28.7)	26.9 (18.0 - 35.8)	32.8 (24.4 - 41.2)
Collagen	60.2 (44.1 - 76.3)	88.7 (81.0 - 96.4)	90.0 (84.3 - 95.8)
ePTFE	40.6 (32.5 - 48.7)	60.9 (51.6 - 70.2)	89.8 (85.1 - 94.7)

CI = confidence interval

PDLLCL = poly(DL-lactide- ϵ -caprolactone)

ePTFE = expanded polytetrafluoroethylene

Table 2. Absolute volume of new bone (mm³) in the original defect as measured by micro-CT.

	2 wks (95% CI)	4 wks (95% CI)	12 wks (95% CI)
PDLLCL	1.58 (0.92 - 2.24)	4.28 (2.91 - 5.65)	12.79 (7.11 - 18.47)
Control	3.39 (2.55 - 4.23)	3.58 (2.10 - 5.06)	4.59 (2.41 - 6.77)
Collagen	1.49 (0.85 - 2.13)	9.54 (7.67 - 11.41)	14.13 (11.04 - 17.22)
ePTFE	1.97 (0.91 - 3.03)	5.93 (4.41 - 7.45)	15.15 (12.09 - 18.21)

Note: estimated mean volume in case of complete defect closure is 16.81 mm³

CI = confidence interval

PDLLCL = poly(DL-lactide- ϵ -caprolactone)

ePTFE = expanded polytetrafluoroethylene

Table 3. Linear regression model of defect closure as measured by microradiography. Model 1 is a regression model without the correction for interaction effects, model 2 with correction for interaction effects.

	Coefficients		t	Significance
	B (95% CI)	Std. Error		
Model 1				
Constant	-0.052 (-0.145 - 0.041)	0.047	-1.100	0.273
Control (time)	0.157 (0.123 - 0.191)	0.017	9.152	0.000
PDLLCL	0.257 (0.176 - 0.338)	0.041	6.289	0.000
Collagen	0.539 (0.459 - 0.619)	0.041	13.269	0.000
ePTFE	0.374 (0.295 - 0.453)	0.040	9.326	0.000
Model 2				
Constant	0.175 (-0.018 - 0.331)	0.079	2.208	0.029
Control (time)	0.050 (-0.019 - 0.119)	0.035	1.433	0.154
PDLLCL	0.007 (-0.204 - 0.217)	0.107	0.063	0.949
Collagen	0.356 (0.138 - 0.575)	0.110	3.224	0.002
ePTFE	-0.027 (-0.230 - 0.176)	0.103	-0.264	0.792
Interaction time*PDLLCL	0.119 (0.024 - 0.213)	0.048	2.487	0.014
Interaction time*collagen	0.087 (-0.009 - 0.183)	0.049	1.785	0.076
Interaction time*ePTFE	0.195 (0.104 - 0.287)	0.046	4.213	0.000

CI = confidence interval

PDLLCL = poly(DL-lactide-ε-caprolactone)

ePTFE = expanded polytetrafluoroethylene

Table 4. Linear regression model of defect closure as measured by micro-CT. Model 1 is a regression model without the correction for interaction effects, model 2 with correction for interaction effects.

	Coefficients		t	Significance
	B (95% CI)	Std. Error		
Model 1				
Constant	-2.196 (-4.393 - 0.002)	1.108	-1.981	0.050
Control (time)	0.912 (0.725 - 1.100)	0.094	9.661	0.000
PDLLCL	2.861 (0.445 - 5.277)	1.218	2.348	0.021
Collagen	5.463 (3.057 - 7.869)	1.213	4.502	0.000
ePTFE	4.324 (1.997 - 6.687)	1.183	3.671	0.000
Model 2				
Constant	3.118 (0.146 - 6.091)	1.499	2.081	0.040
Control (time)	0.122 (-0.246 - 0.491)	0.186	0.659	0.512
PDLLCL	-3.534 (-7.377 - 0.308)	1.937	-1.825	0.071
Collagen	-0.381 (-4.359 - 3.598)	2.006	-0.190	0.850
ePTFE	-3.063 (-6.824 - 0.699)	1.896	-1.615	0.109
Interaction time*PDLLCL	0.984 (0.476 - 1.492)	0.256	3.839	0.000
Interaction time*collagen	0.870 (0.373 - 1.366)	0.250	3.476	0.001
Interaction time*ePTFE	1.150 (0.662 - 1.638)	0.246	4.673	0.000

CI = confidence interval

PDLLCL = poly(DL-lactide-ε-caprolactone)

ePTFE = expanded polytetrafluoroethylene

Discussion

The results of the present investigation indicate that bone formation in a defect does occur underneath the new PDLCL membranes. The regression analyses show that all membranes allow more bone formation than the control. In the collagen group more bone was formed than in the ePTFE and PDLCL groups. However, because model 2 (Table 3) showed no significant B for the interaction term collagen*time, bone formation beneath the collagen membrane was not significantly modified within the time frame of this study. This apparent contradiction can be explained by the fact that collagen already showed a large amount of new bone at 2 weeks. The increase of new bone per unit of time thereafter is less compared with the other membranes, although the amount of bone at each occasion is larger. If measurements would have been performed at the moment of operation (0 weeks), when probably no bone would have been measured in any defect, the time effect would be more valid.

Overall, more bone formation was observed in rats treated with collagen or ePTFE membranes compared with PDLCL. Results in the collagen and ePTFE-treated defects are in accordance with results from previous studies (Dahlin et al. 1988; Schortinghuis et al. 2004, 2005; McAllister & Haghghat 2007). Therefore, in clinical practice PDLCL in its current composition cannot be expected to give as much bone in-growth in defects as the control membranes. Other synthetic degradable membranes also showed less bone in-growth compared with collagen and ePTFE (Aaboe et al. 1998; Wiltfang et al. 1998). A recently developed polylactide membrane (Mueller et al. 2005) and a calcium alginate film (He et al. 2007) showed promising results in rabbits. However, the former study did not include a suitable control group and the latter described defect closure qualitatively. Therefore, a relevant comparison with the new PDLCL membrane is not possible.

PDLCL-treated rats at 12 weeks showed a poor defect closure in comparison with the other membrane groups and the confidence interval is about twice as large as in the other groups. This may be caused by degradation products. It is known from degradation studies that PDLCL disintegrates from 10 weeks post-operatively and causes a mild foreign body reaction (Meek et al. 2004). However,

these studies were performed *in vitro* and subcutaneously, whereas the present study was performed at a subperiosteal site. It is known that degradation characteristics differ between *in vitro* and *in vivo* studies (Bergsma et al. 1995) and that implant locations with differences in the local inflammatory microenvironment result in varying degradation (Luttikhuis et al. 2006). Another, more plausible cause could be the poor tissue-adherence to the underlying bone. Possibly, membrane movement caused by masticatory actions may have allowed soft tissue in-growth beneath the PDLCL membrane, which may explain the considerable variation in the amount of bone formation. The samples where membrane movement might have appeared, performed worse compared with the control membranes. The PDLCL samples with a successful amount of new bone in-growth at 12 weeks performed similar to the successful ones of the control membranes, demonstrating the potency of PDLCL as a barrier membrane.

During the first surgical procedures it became clear that PDLCL adhered less to the underlying bone as compared with collagen. Nevertheless, it was decided not to fix the newly designed membrane. If a new barrier membrane would show satisfactory outcomes only with fixation, then this would be a major disadvantage for clinical practice and such a membrane would not be capable of competing with the already available degradable collagen membranes.

Overall, the confidence intervals of the groups were rather large, as in most *in vivo* guided bone regeneration experiments (Vesala et al. 2002; Schmidmaier et al. 2006). For this reason, a relatively large sample size was required. Thus, the required sample sizes are much larger than have generally been used (Gunsolley et al. 1998). To reduce the total amount of animals, longitudinal studies could be executed. μ CT could be valuable in these studies in which repetitive measurements in sedated animals could be taken. This technique was not yet available when the present study was approved. Furthermore, provided that standard models and outcome measures are applied, data from different studies could be pooled in a meta-analysis. In this study, 2 methods of measuring new bone are applied to come to a more valid conclusion. MR and μ CT both showed an increase in bone in-growth from 2 to 12 weeks for the membrane groups. It appears that more bone in-growth in the control group evaluated by μ CT was measured at 2

weeks; however, this difference is statistically and clinically irrelevant. In μ CT bone in-growth relative to complete defect closure appears to happen slower compared with the results in MR. However, defect closure may start with a thin layer of new bone, which then grows thicker (Schmidmaier et al. 2006). This effect could have reduced the μ CT results for new bone formation. Furthermore, when tested it appeared that MR overestimates bone formation in defects compared with histomorphometrics and μ CT. However, generally, the results in both methods appear similar, making these findings valuable.

The critical size defect-model as described in this rat experiment is a frequently applied method to test barrier membranes (Kaban et al. 1979; Schortinghuis et al. 2003). MR and μ CT were shown to be useful techniques to reliably measure new bone formation (Schortinghuis et al. 2003; Marechal et al. 2005). This is especially the case in this defect model where the original outline can easily be retrieved.

In this study, MR and μ CT were applied to measure new bone formation in defects, although histomorphometry is considered the 'gold standard'. Histomorphometry often involves 1 section (1D) through the center of the defects (e.g., Mueller et al. 2005). On MR images the entire defect can easily be measured. MR has been proven to be fast, accurate, and simple (Schortinghuis et al. 2003). However, 3D volumetric calculations are impossible. By μ CT, 3D reconstructions and volumetric measurements can be obtained (Lee et al. 2006). Because bone growth is a 3D phenomenon, μ CT appears to be the most suitable method. However, μ CT is not yet widely available and is rather expensive in comparison with MR.

In the mandibular defect model, exposure to the oral environment is impossible due to the anatomic location of the defect. The major disadvantage of ePTFE is that it has to be removed when exposed to the oral environment because of infection (Clarizio 1999). The response of PDLLCL to exposure to the oral environment is impossible to study in this model and, therefore, unknown, but this might be a decisive factor in clinical application.

A blank control is essential in a good research design when testing a new material. Frequently, researchers (e.g., Stavropoulos et al. 2004) only test a new material in comparison with a standard reference material. In this study,

the reference materials were collagen and ePTFE because these materials are the standard non-synthetic degradable and synthetic non-degradable reference materials, respectively. These membranes have been tested extensively in animal and clinical studies (McAllister & Haghghat 2007). The results of the present study have shown that, in its current composition, PDLLCL is not ready for application in clinical practice. Although the membrane allows significantly more bone in-growth than in the control group, the problem with adherence needs to be solved.

In conclusion, substantial bone healing was observed in defects covered with a PDLLCL membrane, in contrast to uncovered mandibular defects. However, bone formation in PDLLCL-treated defects was less than in the defects covered with a collagen or ePTFE membrane. This indicates that the qualities of PDLLCL membranes need to be optimized to make it a clinically applicable and attractive barrier membrane.

Acknowledgements

Gratitude is expressed to Mr. J.L. Ruben, for his help and advice during the microradiographic procedures. Mr. H. Bartels and Ms. Y. Heddema are acknowledged for their assistance during the surgical procedures and Mr. J. de Vries for the writing of Image Analysis Software. Furthermore, we would like to thank Polyganics for the provision of the Vivosorb® membranes, Geistlich Biomaterials for the Geistlich Bio-Gide® membranes and W.L.Gore & Associates for the Gore-Tex® Regenerative Membranes.

References

- Aaboe, M., Pinholt, E.M., Schou, S. & Hjorting-Hansen, E. (1998) Incomplete bone regeneration of rabbit calvarial defects using different membranes. *Clin Oral Implants Res* 9: 313-320.
- Antoun, H., Sitbon, J.M., Martinez, H. & Missika, P. (2001) A prospective randomized study comparing two techniques of bone augmentation: onlay graft alone or associated with a membrane. *Clin Oral Implants Res* 12: 632-639.
- Bergsma, J.E., de Bruijn, W.C., Rozema, F.R., Bos, R.R. & Boering, G. (1995) Late degradation tissue response to poly(L-lactide) bone plates and screws. *Biomaterials* 16: 25-31.
- Bertleff, M.J., Meek, M.F. & Nicolai, J.P. (2005) A prospective clinical evaluation of biodegradable neuroloc nerve guides for sensory nerve repair in the hand. *J Hand Surg* 30: 513-518.
- Clarizio, L.F. (1999) Successful implant restoration without the use of membrane barriers. *J Oral Maxillofac Surg* 57: 1117-1121.
- Dahlin, C., Linde, A., Gottlow, J. & Nyman, S. (1988) Healing of bone defects by guided tissue regeneration. *Plast Reconstr Surg* 81: 672-676.
- Donos, N., Kostopoulos, L. & Karring, T. (2002) Augmentation of the rat jaw with autogeneic cortico-cancellous bone grafts and guided tissue regeneration. *Clin Oral Implants Res* 13: 192-202.
- Gunsolley, J.C., Elswick, R.K. & Davenport, J.M. (1998) Equivalence and superiority testing in regeneration clinical trials. *J Periodontol* 69: 521-527.
- Hallman, M., Sennerby, L., Zetterqvist, L. & Lundgren, S. (2005) A 3-year prospective follow-up study of implant-supported fixed prostheses in patients subjected to maxillary sinus floor augmentation with a 80:20 mixture of deproteinized bovine bone and autogenous bone. Clinical, radiographic and resonance frequency analysis. *Int J Oral Maxillofac Surg* 34: 273-280.
- Hardwick, R., Scantlebury, T., Sanchez, R., Whitley, N. & Ambruster, J. (1994) Membrane design criteria for guided bone regeneration of the alveolar ridge. In: Buser, D., Dahlin, C. & Schenk, R.K., eds. Guided bone regeneration in implant dentistry. 1st edition, p. 101-136. Chicago, IL: Quintessence.
- He, H., Huang, J., Chen, G., Dong, Y. (2007) Application of a new bioresorbable film to guided bone regeneration in tibia defect model of the rabbits. *J Biomed Mater Res A* 82: 256-262.
- Hollinger, J.O., Buck, D.C. & Bruder, S.P. (1999) Biology of bone healing: its impact on clinical therapy. In: Lynch, S.E., Genco, R.J. & Marx, R.E., eds. Tissue engineering. Applications in maxillofacial surgery and periodontics, 1st edition, p. 17-53. Chicago: Quintessence.
- Kaban, L.B. Glowacki, J. & Murray, J.E. (1979) Repair of experimental mandibular bony defects in rats. *Surg Forum* 30: 519-521.
- Kaban, L.B. & Glowacki, J. (1981) Induced osteogenesis in the repair of experimental mandibular defects in rats. *J Dent Res* 60: 1356-1364.
- Kay, S.A., Wisner-Lynch, L., Marxer, M. & Lynch, S.E. (1997) Guided bone regeneration: integration of a resorbable membrane and a bone graft material. *Pract Periodontics Aesthet Dent* 9: 185-194.
- Lee, J.K., Ha, B.H., Choi, J.H., Heo, S.M. & Perinpanayagam, H. (2006) Quantitative three-dimensional analysis of root canal curvature in maxillary first molars using micro-computed tomography. *J Endod* 32: 941-945.
- Levy, B.A. (1971) Traumatic disruption of the developing incisor in rats. *J Dent Res* 50: 565-568.
- Luttikhuisen, D.T., van Amerongen, M.J., de Feijter, P.C., Petersen, A.H., Harmsen, M.C. & van Luyn, M.J. (2006) The correlation between difference in foreign body reaction between implant locations and cytokine and MMP expression. *Biomaterials* 27: 5763-5770.
- Machtei, E.E. (2001) The effect of membrane exposure on the outcome of regenerative procedures in humans: a meta-analysis. *J Periodontol* 72: 512-516.
- Marechal, M., Luyten, F., Nijs, J., Postnov, A., Schepers, E. & van Steenberghe, D. (2005) Histomorphometry and micro-computed

- tomography of bone augmentation under a titanium membrane. *Clin Oral Implants Res* 16: 708-714.
- McAllister, B.S. & Haghghat, K. (2007) Bone augmentation techniques. *J Periodontol* 78: 377-396.
- Meek, M.F., Jansen, K., Steendam, R., van Oeveren, W., van Wachem, P.B. & van Luyn, M.J. (2004) In vitro degradation and biocompatibility of poly(DL-lactide-epsilon-caprolactone) nerve guides. *J Biomed Mater Res A* 68: 43-51.
- Mueller, A.A., Rahn, B.A., Gogolewski, S. & Leiggenger, C.S. (2005) Early dural reaction to polylactide in cranial defects in rabbits. *Pediatr Neurosurg* 41: 285-291.
- Murray, G., Holden, R. & Roschlau, W. (1957) Experimental and clinical study of new growth of bone in a cavity. *Am J Surg* 93: 385-387.
- Nyman, S. (1991) Bone regeneration using the principle of guided tissue regeneration. *J Clin Periodontol* 18: 494-498.
- Ogiso, B., Hughes, F.J., Melcher, A.H. & McCulloch, C.A.. (1991) Fibroblasts inhibit mineralised bone nodule formation by rat bone marrow stromal cells in vitro. *J Cell Physiol* 146: 442-450.
- Schmidmaier, G., Baehr, K., Mohr, S., Kretschmar, M., Beck, S. & Wildemann, B. (2006) Biodegradable polylactide membranes for bone defect coverage: biocompatibility testing, radiological and histological evaluation in a sheep model. *Clin Oral Implants Res* 17: 439-444.
- Schortinghuis, J., Ruben, J.L., Meijer, H.J.A., Bronckers, A.L.J.J., Raghoobar, G.M. & Stegenga, B. (2003) Microradiography to evaluate bone growth into a rat mandibular defect. *Arch Oral Biol* 48: 155-160.
- Schortinghuis, J., Ruben, J.L., Raghoobar, G.M. & Stegenga, B. (2004) Therapeutic ultrasound to stimulate osteoconduction. A placebo controlled single blind study using e-PTFE membranes in rats. *Arch Oral Biol* 49: 413-420.
- Schortinghuis, J., Ruben, J.L., Raghoobar, G.M., Stegenga, B. & de Bont, L.G. (2005) Does ultrasound stimulate osteoconduction? A placebo-controlled single-blind study using collagen membranes in the rat mandible. *Int J Oral Maxillofac Implants* 20:181-186.
- Stavropoulos, F., Dahlin, C., Ruskin, J.D. & Johansson, C. (2004) A comparative study of barrier membranes as graft protectors in the treatment of localized bone defects. An experimental study in a canine model. *Clin Oral Implants Res* 15: 435-442.
- Vesala, A.L., Kallioinen, M., Tormala, P., Kellomaki, M., Waris, T. & Ashammakhi, N. (2002) Bone tissue engineering: treatment of cranial bone defects in rabbits using self-reinforced poly-L,D-lactide 96/4 sheets. *J Craniofac Surg* 13: 607-613.
- Von Arx, T., Cochran, D.L., Schenk, R.K. & Buser, D. (2002) Evaluation of a prototype trilayer membrane (PTLM) for lateral ridge augmentation: an experimental study in the canine mandible. *Int J Oral Maxillofac Surg* 31: 190-199.
- Wang, H.L. & Carroll, M.J. (2001) Guided bone regeneration using bone grafts and collagen membranes. *Quintessence Int* 32: 504-515.
- Wiltfang, J., Merten, H.A. & Peters J.H. (1998) Comparative study of guided bone regeneration using absorbable and permanent barrier membranes: a histologic report. *Int J Oral Maxillofac Implants* 13: 416-421.
- Zellin, G. & Linde, A. (1997) Importance of delivery systems for growth-stimulatory factors in combination with osteopromotive membranes. An experimental study using rhBMP-2 in rat mandibular defects. *J Biomed Mater Res* 35: 181-190.
- Zitzmann, N.U., Schäfer, P. & Marinello, C.P. (2001) Long-term results of implants treated with guided bone regeneration: A 5-year prospective study. *Int J Oral Maxillofac Implants* 16: 355-366.

Barrier membranes over
bone defects with TMR

Vivosorb® as a barrier membrane in rat mandibular defects. An evaluation with transversal microradiography

6.2

This chapter is an edited version of the manuscript:
Hoogveen, E.J., Gielkens, P.F.M., Schortinghuis, J.,
Ruben, J.L., Huysmans, M.C.D.N.J.M. & Stegenga, B.
Vivosorb® as a barrier membrane in rat mandibular defects.
An evaluation with transversal microradiography. *Submitted.*

Abstract

Objectives:

Guided bone regeneration (GBR) is a successful technique in treating bone deficiency. Application of degradable membranes eliminates the need of a second surgical procedure and is, therefore, preferable to application of non-degradable membranes. However, the currently available degradable membranes lack sufficient space-maintaining properties, 1 of the prerequisites for successful bone augmentation. Vivosorb® is a new degradable membrane composed of poly(DL-lactide-ε-caprolactone) (PDLLCL). The aim of this study was to appraise its performance in GBR-procedures.

Material and Methods:

In 192 rats a 5.0 mm defect was drilled in the mandibular angle. The defects were either covered with a membrane (PDLLCL, collagen, or expanded polytetrafluoroethylene (ePTFE)) or left uncovered (control). Defect closure, mineralization and thickness of the new bone were assessed by means of transversal microradiography at 3 different time intervals (2, 4 and 12 weeks). The data were analysed using multiple regression analyses.

Results:

The membrane groups showed significantly better results than the control groups. The ePTFE and collagen membranes performed equally well and better than the PDLLCL membrane during this experiment.

Conclusion:

The results indicate that the PDLLCL membrane is not yet suitable for clinical application in its current form.

Introduction

In maxillofacial surgery different techniques for bone augmentation, including guided bone regeneration (GBR), are successfully used nowadays (Hämmerle & Jung 2003). In GBR the bony defect is covered with a barrier membrane to prevent fast growing connective tissue from migrating into the defect (Aslan et al. 2004; He et al. 2007). The barrier membrane preserves growth factors and excludes inhibiting factors (Ogiso et al. 1991, Zellin & Linde 1997). The presence of a blood clot and an adequate amount of available space are prerequisites for new bone formation (Antoun et al. 2001; McAllister & Haghghat 2007).

Good *in vitro* and clinical results have been reported with synthetic non-degradable expanded polytetrafluorethylene (ePTFE) membranes (Hämmerle & Jung 2003; McAllister & Haghghat 2007). However, infection caused by dehiscent membranes (Wang & Carroll 2001; Donos et al. 2002) and the need of a second surgical procedure are recognized disadvantages (Schliephake et al. 2004). The application of a biodegradable membrane eliminates the need of a second intervention. Furthermore, the degradable membranes show accelerated resorption rates when exposed to the oral cavity, minimizing the duration of the inflammatory reaction and protecting the regenerated bone (McAllister & Haghghat 2007).

Biodegradable membranes can be either natural (collagen) or synthetic. A synthetic material can be produced in any required amount and its macrostructure, mechanical properties and degradation profile can be modified in an attempt to optimize performance (Pêgo et al. 2003a,b). A collagen membrane tends to lose its space-maintaining ability during function in humid conditions (Hutmacher et al. 2001) and implantation of animal derived collagen includes a potential risk of disease transmission from animal to human (Von Arx et al. 2002). Overall, synthetic biodegradable barrier membranes appear preferable in GBR procedures. Although numerous membranes have been developed (Zellin et al. 1995; Strietzel et al. 2006), the ideal barrier membrane has not yet been found (Kay et al. 1997; Von Arx et al. 2002).

Vivosorb® is a synthetic biodegradable material composed of poly(DL-lactide-ε-caprolactone) (PDLLCL). The membrane is expected to be occlusive and should be stiff

enough to bridge a defect and at the same time flexible enough to adapt to the cortical bone contour. In addition, extensive *in vivo* research has proven the membrane to be highly biocompatible and non-cytotoxic (Meek et al. 2004; Jansen et al. 2004). Vivosorb® is commercially available as a nerve guide (Neurolac®, Polyganics, Groningen, The Netherlands) (Bertleff et al. 2005). Vivosorb® may be as suitable and as valuable as a GBR membrane.

So far, radiology (Schortinghuis et al. 2003; Mueller et al. 2005), histology (Aaboe et al. 1998; Aslan et al. 2004) and histomorphometry (Nastri & Smith 1996) are commonly applied methods in GBR studies, with which bone volume as well as the various cell types involved can be assessed. However, the extent of bone mineralization and resulting density cannot be measured with these methods. Transversal microradiography (TMR) is an accurate method of measuring mineral content in a thin cross-section (Arends et al. 1997). This method has proven to be valid, precise and useful for measuring mineral loss in caries research (Kielbassa et al. 1999; Petersson & Kambara 2004). Therefore, it can be expected that accurate comparisons of bone mineralization can be made with TMR in the present study (Raghoebar et al. 2005). Furthermore, since cross-sections are made through the defects, not only the amount, also the direction of bone regeneration can be evaluated. The suitability and value of TMR in assessing new bone formation should be explored.

The aim of this study was to appraise PDLLCL as a GBR membrane. Therefore, its performance was compared to a blank control group and to the reference standard non-degradable (ePTFE) and biodegradable (collagen) membranes in an *in vivo* experiment in the mandible of the rat.

Material and Methods

Surgical procedure

In 192 male Sprague-Dawley rats (mean weight 364 g (SD 17 g), ranging from 320 to 407 g) a standardised circular 5.0 mm bicortical defect was drilled with a trephine in the right mandibular angle (Kaban & Glowacki 1981; Schortinghuis et al. 2003). The defects were either covered with 1 of 3 different barrier membranes or left uncovered in random

allocation, resulting in 4 evenly distributed experimental groups (n = 48). In the first group no membrane was used to cover the defects. In the second group the defects were covered with the biodegradable PDLCL membrane (Vivosorb®, Polyganics, Groningen, The Netherlands). In the third and fourth group bilayer collagenous membranes (Geistlich Bio-Gide®, Geistlich Biomaterials, Wolhusen, Switzerland) and ePTFE membranes (Gore-Tex®, W.L. Gore & Associates, Flagstaff, USA), respectively, were applied. The wound was closed in layers using resorbable sutures (Vicryl® Rapide 4-0, Ethicon, Johnson & Johnson, Amersfoort, The Netherlands). Postoperative pain relief, a single dose of Caprofen (4.0 mg/kg) and Temgesic (0.03 mg/kg), was administered and the diet was composed of standard laboratory food.

At 3 different time intervals (2, 4 and 12 weeks), the rats were anaesthetised by nitrous-oxygen-isoflurane inhalation anaesthesia and sacrificed by an intracardially injected overdose of pentobarbital, resulting in 12 subgroups (n = 16). The mandibles were explanted and fixed in 4% phosphatebuffered formaline solution.

The study protocol was approved by the Animal studies review committee, and in accordance with Institutional Guidelines (University Medical Center Groningen, The Netherlands).

Preparation of samples and transversal micro-radiography (TMR)

The specimens were placed in a metal mould and embedded in polymethylmethacrylate (PMMA). Thereby, blocks with standardized dimensions were obtained to facilitate precise cutting and to prevent the samples from drying. X-rays were taken to determine the exact location of the defects. Through the center of the defect, 3 cuts were made in the transversal plane with a circular saw blade (Buehler Diamond Wafering Blade, diameter 10.2 cm x 0.3 mm, USA) to create 2 cross-sections with a standardized thickness of 0.50 mm (Fig. 1). With an X-ray source (Philips PW 1730, Eindhoven, The Netherlands) transversal microradiographs were taken on a 35 mm film (Fuji B and W POS/71337) and exposed for 18 seconds with a tube charge of 25 kV and 25 mA to obtain the transversal microradiographs (Raghoobar et al. 2005). After film development, a stereo microscope (Wild/Leitz M7 S, Heerbrugg,

Switzerland; magnification 10x) and a CCD camera (Scion Corporation CFW 1312M, Frederick, MD, USA) were used to digitize the images. By means of a frame grabber the images were stored on a personal computer (resolution: 256 grey values / 1360 x 1024 pixels).

Measuring new bone formation

All measurements were performed twice under (single-) blind conditions and were averaged. The overall quality of the newly formed bone was assessed with 3 different methods. The amount of mineralization of the newly formed bone was determined by dividing the mean grey value of the newly formed bone by the mean grey value of the original mandibular bone, outside the defect. The mean grey values of the 2 areas were obtained by selecting 12 spots on each radiograph; 6 within the new bone and 6 within the original mandibular bone (Fig. 2). The measurements were performed using image analysis software (Optical Bone Calculator, J. de Vries, Biomedical Engineering Groningen, The Netherlands). The second method aimed at comparing the defect closure between groups. The percentage of defect closure was defined as the length of the newly formed bone (Schortinghuis et al. 2003) in the defect divided by the total length (i.e., width) of the original defect. When 0-25% of the width of the defect was filled with newly formed bone a score of 1 was assigned. A score 2, 3 and 4 were assigned in case of 26-50%, 51-75% or 76-100% of newly formed bone compared to the original defect width, respectively. The third method assessed the thickness of new bone. The mean thickness of the newly formed bone (Schortinghuis et al. 2003) was divided by the mean thickness of the bone across the borders of the defects. These ratings were scored 1 to 4, similarly to defect closure.

Statistical analysis

The required sample size was determined by a power analysis based on 90% power with a 0.05 significance level, a 20% difference in new bone formation between a membrane-treated group and non-treated control, and a standard deviation of 18% (Schortinghuis et al. 2004,2005). In a multiple regression analysis model the outcome variables mineralization of new bone, defect closure and thickness of new bone were separately predicted as a

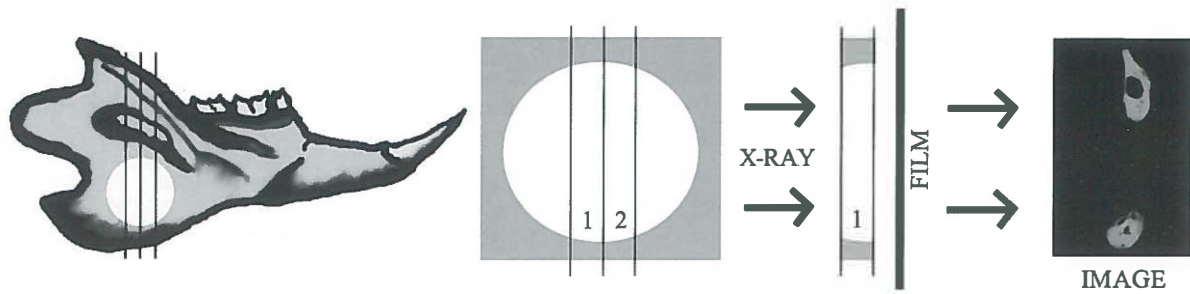


Fig. 1. Schematic view of a rat mandible and the defect's location; cross-sections were made through the center of the defects as shown, creating 2 sections per mandible suitable for transversal microradiography. The sections were radiographed 1 by 1.

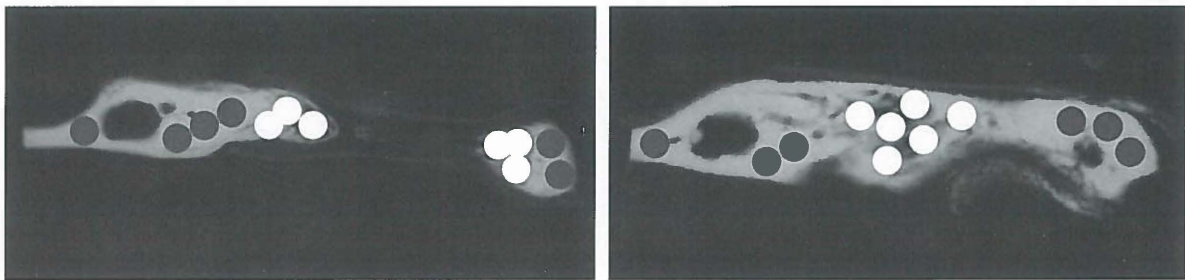


Fig. 2. The amount of mineralization of the newly formed bone was determined by dividing the mean grey value of the newly formed bone by the mean grey value of the original mandibular bone (outside the original defect). The mean grey values of the 2 areas were obtained by selecting 12 spots on each radiograph; 6 (white) within the new bone and 6 (grey) within the original mandibular bone. An open (left) and a closed (right) defect are shown.

function of the independent variables 'group' (i.e., control, PDLCL, collagen and ePTFE), 'time' (i.e., 2, 4 and 12 weeks) and interactions between these variables.

Results

Six rats did not survive the surgery. In 12 rats the mandibular border fractured during or after the surgery. In 3 cases the apex of the large lower incisor was damaged by the drilling process. An additional number of samples was damaged during preparation of the cross-sections. These groups of specimens were excluded from analysis. It resulted in a median group size of 13 samples (range 7 to 14) for mineralization ratio, defect closure and thickness. All animals gained weight postoperatively, and neither

dehiscence of the membranes nor wound infection was seen in the course of recovery.

The mean mineralization ratios, i.e., the ratio of the mean grey value of the newly formed bone divided by the mean grey value of the original mandibular bone (outside the original defect), is presented in Table 1. Defect closure scored as the relative length of the newly formed bone in the defect to the total length (i.e., width) of the original defect is presented in Table 2. Table 3 presents the thickness of newly formed bone in all groups as found with TMR scored as the thickness of the newly formed bone divided by the mean thickness of the bone across the borders of the original defects. Tables 1-3 show that collagen and ePTFE membranes performed equally well and better than the PDLCL membrane during this experiment.

The regression analyses of the mineralization ratio, defect closure and thickness of newly formed bone are summarized in Tables 4, 5 and 6, respectively. Model 1 is a regression model without the correction for possible effect modification (interaction effects). Model 2 is a regression model with correction for effect modification by time and membrane (i.e., PDLLCL, collagen or ePTFE). Both models are presented to give the reader information about the relative effect of the coefficients with and without effect

modifications, as correction for interaction dramatically changes the value of the crude coefficients. The regression analyses showed that the mineralization of the newly formed bone is higher in the collagen and ePTFE group compared to the control and PDLLCL. Most defect closure was in the collagen and ePTFE group. The bone thickness in the ePTFE groups is larger than the other membrane groups and control.

Table 1. Mean values and confidence intervals for mineralization rate, i.e., the ratio of the mean grey value of the newly formed bone divided by the mean grey value of the original mandibular bone (outside the original defect) (Fig. 2).

	2 wks (95% CI) (%)	4 wks (95% CI) (%)	12 wks (95% CI) (%)
Control	0.62 (0.59 - 0.65)	0.70 (0.64 - 0.76)	0.59 (0.54 - 0.64)
PDLLCL	0.61 (0.57 - 0.65)	0.74 (0.70 - 0.78)	0.64 (0.57 - 0.71)
Collagen	0.56 (0.53 - 0.59)	0.68 (0.66 - 0.70)	0.81 (0.75 - 0.87)
ePTFE	0.60 (0.57 - 0.63)	0.75 (0.71 - 0.79)	0.84 (0.78 - 0.90)

CI = confidence interval

PDLLCL = poly(DL-lactide- ϵ -caprolactone)

ePTFE = expanded polytetrafluoroethylene

Table 2. Mean values and confidence intervals for defect closure. When the length of the newly formed bone in the defect was 0-25% of the total length (i.e., width) of the original defect a score of 1 was assigned, and a score 2, 3 and 4 were assigned in case of 26-50%, 51-75% or 76-100%, respectively.

	2 wks (95% CI) (1 - 4)	4 wks (95% CI) (1 - 4)	12 wks (95% CI) (1 - 4)
Control	1.29 (1.00 - 1.58)	1.33 (1.05 - 1.61)	1.00 (1.00 - 1.00)
PDLLCL	1.44 (1.06 - 1.82)	1.93 (1.51 - 2.35)	2.27 (1.63 - 2.91)
Collagen	1.58 (1.14 - 2.02)	3.35 (2.82 - 3.88)	3.68 (3.38 - 3.98)
ePTFE	1.39 (1.15 - 1.63)	2.15 (1.81 - 2.49)	3.32 (2.98 - 3.66)

CI = confidence interval

PDLLCL = poly(DL-lactide- ϵ -caprolactone)

ePTFE = expanded polytetrafluoroethylene

Table 3. Mean values and confidence intervals of thickness of newly formed bone. When the mean thickness of the newly formed bone was 0-25% of the mean thickness of the bone across the borders of the defects a score of 1 was assigned, and a score 2, 3 and 4 were assigned in case of 26-50%, 51-75% or 76-100%, respectively.

	2 wks (95% CI) (1 - 4)	4 wks (95% CI) (1 - 4)	12 wks (95% CI) (1 - 4)
Control	1.86 (1.58 - 2.14)	2.42 (1.91 - 2.93)	1.58 (1.31 - 1.85)
PDLLCL	2.09 (1.63 - 2.55)	2.39 (2.02 - 2.76)	2.75 (2.36 - 3.14)
Collagen	1.85 (1.57 - 2.13)	2.62 (2.17 - 3.07)	2.79 (2.33 - 3.25)
ePTFE	1.75 (1.46 - 2.04)	2.58 (2.34 - 2.82)	3.50 (3.19 - 3.81)

CI = confidence interval

PDLLCL = poly(DL-lactide-ε-caprolactone)

ePTFE = expanded polytetrafluoroethylene

Table 4. Linear regression models of mineralization of newly formed bone. Model 1 is a regression model without the correction for interaction effects, model 2 with correction for interaction effects.

	Coefficients		t	Significance
	B (95% CI)	Std. Error		
Model 1				
Constant	0.492 (0.432 - 0.553)	0.031	16.090	0.000
Control (time)	0.066 (0.045 - 0.088)	0.011	6.070	0.000
PDLLCL	0.037 (-0.014 - 0.088)	0.026	1.425	0.156
Collagen	0.060 (0.009 - 0.111)	0.026	2.310	0.022
ePTFE	0.105 (0.054 - 0.156)	0.026	4.080	0.000
Model 2				
Constant	0.694 (0.592 - 0.796)	0.052	13.475	0.000
Control (time)	-0.026 (-0.070 - 0.018)	0.022	-1.174	0.242
PDLLCL	-0.060 (-0.191 - 0.071)	0.066	-0.902	0.368
Collagen	-0.257 (-0.386 - -0.127)	0.066	-3.916	0.000
ePTFE	-0.206 (-0.334 - -0.078)	0.065	-3.178	0.002
Interaction time*PDLLCL	0.041 (-0.017 - 0.099)	0.029	1.402	0.163
Interaction time*collagen	0.149 (0.092 - 0.206)	0.029	5.142	0.000
Interaction time*ePTFE	0.147 (0.090 - 0.204)	0.029	5.113	0.000

CI = confidence interval

PDLLCL = poly(DL-lactide-ε-caprolactone)

ePTFE = expanded polytetrafluoroethylene

Table 5. Linear regression models of defect closure. Model 1 is a regression model without the correction for interaction effects, model 2 with correction for interaction effects.

	Coefficients		t	Significance
	B (95% CI)	Std. Error		
Model 1				
Constant	-0.206 (-0.659 - 0.247)	0.229	-0.879	0.371
Control (time)	0.637 (0.474 - 0.800)	0.082	7.742	0.000
PDLLCL	0.792 (0.406 - 1.178)	0.195	4.053	0.000
Collagen	1.803 (1.426 - 2.181)	0.191	9.440	0.000
ePTFE	1.225 (0.849 - 1.600)	0.190	6.440	0.000
Model 2				
Constant	1.550 (0.794 - 2.305)	0.382	4.057	0.000
Control (time)	-0.166 (-0.491 - 0.160)	0.165	-1.005	0.317
PDLLCL	-0.479 (-1.499 - 0.541)	0.516	-0.928	0.355
Collagen	-0.773 (-1.734 - -0.189)	0.486	-1.588	0.115
ePTFE	-1.186 (-2.137 - -0.234)	0.481	-2.463	0.015
Interaction time*PDLLCL	0.573 (0.127 - 1.019)	0.226	2.538	0.012
Interaction time*collagen	1.208 (0.783 - 1.632)	0.215	5.622	0.000
Interaction time*ePTFE	1.130 (0.708 - 1.551)	0.213	5.300	0.000

CI = confidence interval

PDLLCL = poly(DL-lactide-ε-caprolactone)

ePTFE = expanded polytetrafluoroethylene

Table 6. Linear regression models of thickness of newly formed bone. Model 1 is a regression model without the correction for interaction effects, model 2 with correction for interaction effects.

	Coefficients		t	Significance
	B (95% CI)	Std. Error		
Model 1				
Constant	1.043 (0.624 - 1.461)	0.212	4.921	0.000
Control (time)	0.416 (0.267 - 0.566)	0.076	5.510	0.000
PDLLCL	0.529 (0.175 - 0.883)	0.179	2.952	0.004
Collagen	0.540 (0.187 - 0.892)	0.178	3.025	0.003
ePTFE	0.735 (0.384 - 1.085)	0.178	4.139	0.000
Model 2				
Constant	2.442 (1.713 - 3.171)	0.369	6.618	0.000
Control (time)	-0.224 (-0.538 - 0.091)	0.159	-1.404	0.162
PDLLCL	-0.693 (-1.644 - 0.258)	0.481	-1.440	0.152
Collagen	-0.961 (-1.890 - -0.032)	0.470	-2.045	0.043
ePTFE	-1.582 (-2.501 - -0.663)	0.465	-3.404	0.001
Interaction time*PDLLCL	0.554 (0.137 - 0.972)	0.211	2.623	0.010
Interaction time*collagen	0.690 (0.280 - 1.100)	0.207	3.324	0.001
Interaction time*ePTFE	1.099 (0.691 - 1.506)	0.206	5.334	0.000

CI = confidence interval

PDLLCL = poly(DL-lactide-ε-caprolactone)

ePTFE = expanded polytetrafluoroethylene

Discussion

In the present study, application of a barrier membrane clearly showed a beneficial effect on bone regeneration in a defect compared to the control group. This is in accordance with findings in other publications (Aaboe et al. 1998; Aslan et al. 2004; He et al. 2007). However, in an experimental study in the minipig, it was found that a satisfying degree of bone regeneration can also be acquired when the defect is only covered by periosteum (Wiltfang et al. 1998). Hämmerle and Jung (2003) concluded that the relative amount of bone formation was usually more favourable when an ePTFE membrane was used. It was stated that collagen membranes lacked physical strength to maintain adequate space in larger defects. By contrast, in the present study no large differences in performance were noted between the collagen and ePTFE membranes and most defect closure was in the collagen group. McAllister and Haghghat (2007) concluded that generally, collagen membranes performed in a similar manner to ePTFE with respect to defect fill, but showed less soft tissue exposure problems. In the present study no membrane dehiscence was observed. Overall, a larger amount of more mineralised and thicker newly formed bone was observed in rats treated with collagen or ePTFE membranes compared to PDLLCL.

In our experiment, application of a PDLLCL membrane showed a beneficial effect on defect closure and bone thickness compared to the blank control group. After 12 weeks, 25% of the defects had fully closed by new bone apposition. However, in some of the specimens barely gap bridging had taken place. Therefore, the confidence interval for defect closure in the PDLLCL group at 12 weeks was larger than in the other 2 membrane groups. Three possible explanations can be given for these findings. First, during surgery, the PDLLCL membrane appeared to be somewhat sticky, resulting in folding of the membrane. Because of the small bucco-lingual dimensions of the defects, it is possible that the buccal membranes eventually made contact with the lingual membranes and stuck together in the center of the defect, thereby occluding the available space for bone apposition. Secondly, the membrane's stiffness was higher than expected, and the membrane did not adhere to the bone. Considering the site of application,

where movements of the masseter muscle are evident, it is plausible that some membranes may have moved during their functional period. This has probably resulted in marginal gaps, allowing fibrous tissue cells to migrate and proliferate into the defect. The problem of membrane movement could possibly be solved by fixing it, but this would make the procedure more laborious and, therefore, less attractive to clinical use. A third explanation for the observations may be the formation of degradation products and a subsequent inflammatory reaction. Mild foreign body responses have been observed in subcutaneous degradation studies (Meek et al. 2004). This immune response and acidic degradation products might resorb some of the new bone (Strietzel et al. 2006), resulting in less volume and density. This might explain the decrease in mineralization from 4 to 12 weeks seen in the PDLLCL group. Inflammatory reactions adjacent to biodegradable materials have been documented, ranging from mild to severe (Fennis et al. 2005; McAllister & Haghghat 2007). Other authors stated however, that these processes do not interfere with bone healing (Aslan et al. 2004, Mueller et al. 2005). Resorption rates show great variability and are influenced by factors as local pH and material composition (McAllister & Haghghat 2007). From degradation studies it is known that PDLLCL starts disintegrating 10 to 12 weeks after subcutaneous implantation (Meek et al. 2004). In the present experiment it was implanted at a subperiosteal site, which may alter the disintegration process.

TMR results showed that the initially formed bone was less radiopaque than mature bone. Bone volume and density increased more or less simultaneously over time. Different patterns of bone apposition in the defects could be seen (Fig. 3). In some specimens, the defects closed quickly by means of a thin rim of bone adjacent to the membrane, followed by an increase in bone thickness. Other pictures showed a more gradual inward migration of bone from the borders towards the center, almost directly maintaining the original bone thickness. Some pictures showed multiple small bone islets across the defect, which then coalesced. The 2 first mentioned mechanisms were seen most frequently. Mueller et al. (2005) studied defect closure in rabbit calvariae and reported that first new bone apposition took place at the borders of the defect. They observed complete gap bridging in most of their

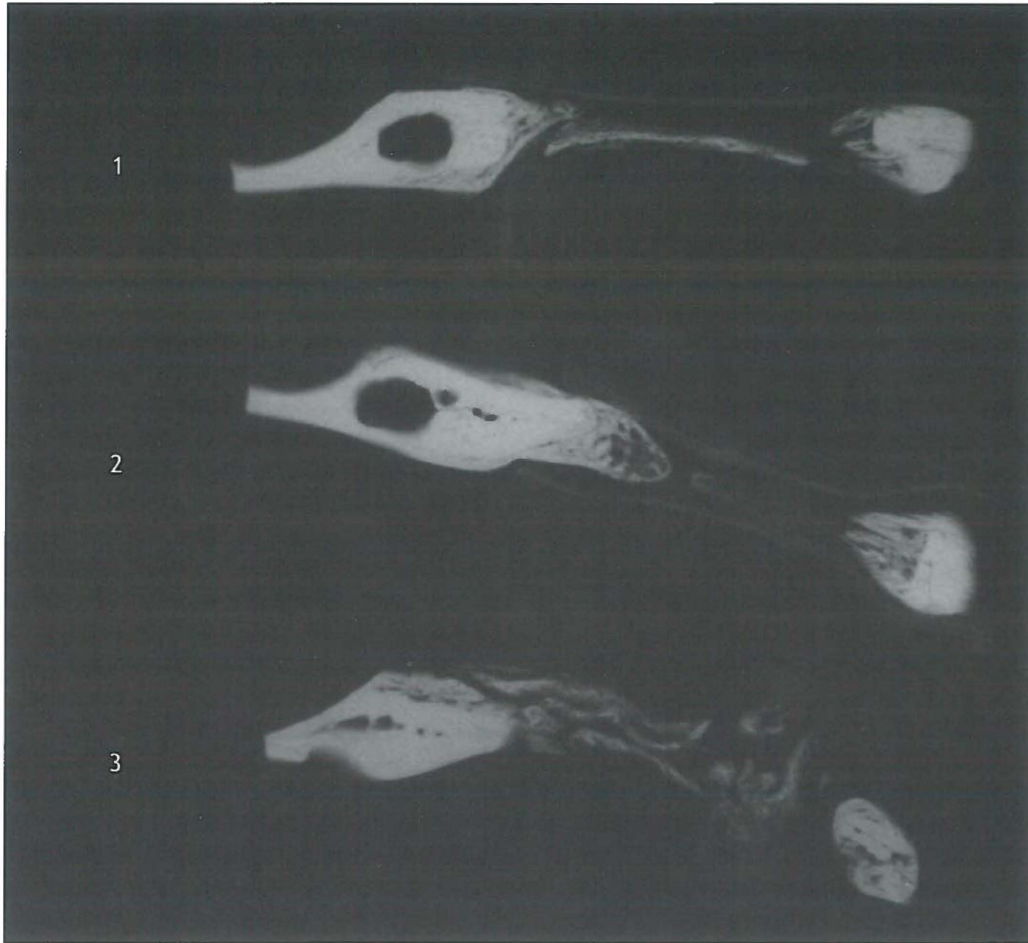


Fig. 3. Three different patterns of defect closure: (1) A quick formation of a thin rim of bone along the membrane was observed in a number of specimens (image: ePTFE, 4 weeks); (2) Gradual inward migration of new bone from the borders towards the center of the defect. Original bone thickness is almost fully maintained (image: ePTFE, 4 weeks); (3) In some of the samples multiple bone islets were observed in the earlier stages of regeneration (image: collagen membrane, 4 weeks).

samples after 6 to 8 weeks.

TMR proved to be useful to assess defect closure, bone thickness, and, moreover, mineralization. Clear high quality and resolution pictures were obtained, and differences in mineralization could be observed. However, the procedure is time consuming and only 2 sections per samples can be examined.

In caries research using TMR, sections with a maximum thickness of 80-150 μm are used (Arends et al. 1997). These thin sections have sufficient strength. By contrast, our sections contained a relatively large amount of soft tissue, making them vulnerable. Therefore, larger dimensions were chosen, resulting in a section thickness of 0.50 mm. A disadvantage of this increased thickness is that neither individual bone trabeculae nor their orientation are visible on the radiographs. Therefore, no statements could be made about bone remodeling. Furthermore, sawing thicker sections could not fully prevent damage to the specimens, and some data loss occurred for this reason. Most excluded samples were coming from the 2 weeks control and 2 weeks PDLCL groups, presumably because the amount of regenerated bone was low and the percentage of soft tissue was most prominent in these groups, resulting in fractures postoperatively or during the sawing procedure.

Based on this *in vivo* experiment, it was concluded that the PDLCL in its current composition is not ready for application in clinical practice. Although the membrane allows more bone in-growth than in the control group, its performance was inferior to the commonly used collagen and ePTFE membranes due to insufficient space-maintaining properties.

Acknowledgements

The membranes were provided by Gore-Tex®, W.L.Gore & Associates, Flagstaff, USA; Geistlich Bio-Gide®, Geistlich Biomaterials, Wolhusen, Switzerland; and Vivosorb®, Polyganics, Groningen, The Netherlands, who are gratefully acknowledged. We would like to thank J. de Vries of the Institute for Biomedical Engineering, University of Groningen, Groningen, for engineering and modifying the Optical Bone Calculator programme.

References

- Aaboe, M., Pinholt, E.M., Schou, S. & Hjorting-Hansen, E. (1998) Incomplete bone regeneration of rabbit calvarial defects using different membranes. *Clin Oral Implants Res* 9: 313-320.
- Antoun, H., Sitbon, J.M., Martinez, H. & Missika, P. (2001) A prospective randomized study comparing two techniques of bone augmentation: onlay graft alone or associated with a membrane. *Clin Oral Implants Res* 12: 632-639.
- Arends, J., Ruben, J.L. & Inaba, D. (1997) Major topics in quantitative microradiography of enamel and dentin: R parameter, mineral distribution visualization, and hyper-remineralization. *Adv Dent Res* 11: 403-414.
- Aslan, M., Simsek, G. & Dayi, E. (2004) Guided bone regeneration (GBR) on healing bone defects: a histological study in rabbits. *J Contemp Dent Pract* 5: 114-123.
- Bertleff, M.J., Meek, M.F. & Nicolai, J.P. (2005) A prospective clinical evaluation of biodegradable neuroloc nerve guides for sensory nerve repair in the hand. *J Hand Surg* 30: 513-518.
- Donos, N., Kostopoulos, L. & Karring, T. (2002) Augmentation of the rat jaw with autogenic cortico-cancellous bone grafts and guided tissue regeneration. *Clin Oral Implants Res* 13: 192-202.
- Fennis, J.P.M., Stoelinga, P.J.W., Merckx, M.A.W. & Jansen, J.A. (2005) Reconstruction of the mandible with a poly(D,L-lactide) scaffold, autogenous corticocancellous bone graft, and autogenous platelet-rich plasma: an animal experiment. *Tissue Eng* 11: 1045-1053.
- Hämmerle, C.H.F. & Jung, R.E. (2003) Bone augmentation by means of barrier membranes. *Periodontol* 2000 33: 36-53.
- He, H., Huang, J., Chen, G. & Dong, Y. (2007) Application of a new bioresorbable film to guided bone regeneration in tibia defect model of the rabbits. *J Biomed Mater Res A* 82: 256-262.
- Hutmacher, D.W., Kirsch, A., Ackermann, K.L., Hürzeler, M.B. (2001) A tissue engineered cell-occlusive device for hard tissue regeneration - a preliminary report. *Int J Periodontics Restorative Dent* 21: 49-59.
- Jansen, K., Meek, M.F., van der Werff, J.F., van Wachem, P.B. & van Luyn, M.J. (2004) Long-term regeneration of the rat sciatic nerve through a biodegradable poly(DL-lactide-epsilon-caprolactone) nerve guide: tissue reactions with focus on collagen III/IV reformation. *J Biomed Mater Res A* 69: 334-341.
- Kaban, L.B. & Glowacki, J. (1981) Induced osteogenesis in the repair of experimental mandibular defects in rats. *J Dent Res* 60: 1356-1364.
- Kay, S.A., Wisner-Lynch, L., Marxer, M. & Lynch, S.E. (1997) Guided bone regeneration: integration of a resorbable membrane and a bone graft material. *Pract Periodontics Aesthet Dent* 9: 185-194.
- Kielbassa, A.M., Wrbas, K.T., Schulte-Mönting, J. & Hellwig, E. (1999) Correlation of transversal microradiography and microhardness on in situ-induced demineralization in irradiated and nonirradiated human dental enamel. *Arch Oral Biol* 44: 243-251.
- McAllister, B.S. & Haghghat, K. (2007) Bone augmentation techniques. *J Periodontol* 78: 377-396.
- Meek, M.F., Jansen, K., Steendam, R., van Oeveren, W., van Wachem, P.B. & van Luyn, M.J. (2004) In vitro degradation and biocompatibility of poly(DL-lactide-epsilon-caprolactone) nerve guides. *J Biomed Mater Res A* 68: 43-51.
- Mueller, A.A., Rahn, B.A., Gogolewski, S. & Leiggener, C.S. (2005) Early dural reaction to polylactide in cranial defects in rabbits. *Pediatr Neurosurg* 41: 285-291.
- Nastri, A.L. & Smith, A.C. (1996) Guided osteogenesis using synthetic membranes: an experimental pilot study. *J Craniomaxillofac Surg* 24: 163-167.
- Ogiso, B., Hughes, F.J., Melcher, A.H. & McCulloch, C.A. (1991) Fibroblasts inhibit mineralised bone nodule formation by rat bone marrow stromal cells in vitro. *J Cell Physiol* 146: 442-450.
- Pêgo, A.P., Poot, A.A., Grijpma, D.W. & Feijen, J. (2003a) Biodegradable elastomeric scaffolds for soft tissue engineering. *J Control Release* 87: 69-79.

- Pêgo, A.P., Poot, A.A., Grijpma, D.W. & Feijen, J. (2003b) Physical properties of high molecular weight 1,3-trimethylene carbonate and D,L-lactide copolymers. *J Mater Sci Mater Med* 14: 767-773.
- Petersson, L.G. & Kambara, M. (2004) Remineralisation study of artificial root caries lesions after fluoride treatment. An in vitro study using electric caries monitor and transversal micro-radiography. *Gerodontology* 21: 85-92.
- Raghoobar, G.M., Schortinghuis, J., Liem, R.S., Ruben, J.L., van der Wal, J.E. & Vissink A. (2005) Does platelet-rich plasma promote remodeling of autologous bone grafts used for augmentation of the maxillary sinus floor? *Clin Oral Implants Res* 16: 349-356.
- Schliephake, H., Tavassol, F., Gelinsky, M., Dard, M., Sewing, A. & Pompe, W. (2004) Use of a mineralized collagen membrane to enhance repair of calvarial defects in rats. *Clin Oral Implants Res* 15: 112-118.
- Schortinghuis, J., Ruben, J.L., Meijer, H.J.A., Bronckers, A.L., Raghoobar, G.M. & Stegenga, B. (2003) Microradiography to evaluate bone growth into a rat mandibular defect. *Arch Oral Biol* 48: 155-160.
- Schortinghuis, J., Ruben, J.L., Raghoobar, G.M. & Stegenga, B. (2004) Therapeutic ultrasound to stimulate osteoconduction; A placebo controlled single blind study using e-PTFE membranes in rats. *Arch Oral Biol* 49: 413-420.
- Schortinghuis, J., Ruben, J.L., Raghoobar, G.M., Stegenga, B. & de Bont, L.G. (2005) Does ultrasound stimulate osteoconduction? A placebo-controlled single-blind study using collagen membranes in the rat mandible. *Int J Oral Maxillofac Implants* 20: 181-186.
- Strietzel, F.P., Khongkhunthian, P., Khattiya, R., Patchanee, P. & Reichart, P.A. (2006) Healing pattern of bone defects covered by different membrane types--a histologic study in the porcine mandible. *J Biomed Mater Res B* 78: 35-46.
- Von Arx, T., Cochran, D.L., Schenk, R.K. & Buser, D. (2002) Evaluation of a prototype trilayer membrane (PTLM) for lateral ridge augmentation: an experimental study in the canine mandible. *Int J Oral Maxillofac Surg* 31: 190-199.
- Wang, H.L. & Carroll, M.J. (2001) Guided bone regeneration using bone grafts and collagen membranes. *Quintessence Int* 32: 504-515.
- Wiltfang, J., Merten, H.A. & Peters, J.H. (1998) Comparative study of guided bone regeneration using absorbable and permanent barrier membranes: a histologic report. *Int J Oral Maxillofac Implants* 13: 416-421.
- Zellin, G., Gritli-Linde, A. & Linde, A. (1995) Healing of mandibular defects with different biodegradable and non-biodegradable membranes: an experimental study in rats. *Biomaterials* 16: 601-609.
- Zellin, G. & Linde, A. (1997) Importance of delivery systems for growth-stimulatory factors in combination with osteopromotive membranes. An experimental study using rhBMP-2 in rat mandibular defects. *J Biomed Mater Res* 35: 181-190.

General discussion

Discussion

In the 1990s clinicians started to cover bone grafts with barrier membranes in bone augmentation procedures (Buser et al. 1996). The barrier membranes would prevent the resorption of these grafts (Gordh et al. 1998; Von Arx & Buser 2006). However, the debate whether onlay bone grafts should be covered with barrier membranes or not still continues (Chiapasco et al. 1999; Donos et al. 2002a). The primary aim of this thesis was to study whether barrier membranes prevent resorption of autologous onlay bone grafts. From the results of our investigations, we conclude that barrier membranes do *not* prevent resorption of autologous onlay bone block grafts.

Research has been performed, showing good results achieved with barrier membranes in combination with autologous bone grafts (Antoun et al. 2001; Jardini et al. 2005). However, because of the lack of adequate control groups, many of these publications do actually not provide a sufficient evidence based answer (Carpio et al. 2000; Von Arx & Buser 2006). Moreover, it was 1 of the reasons that we could include only a minimal number of articles in our review. The major problem arising from the reviewed studies to come to a clinically relevant conclusion was the small number of human studies, the marginal number of test-sites, ambiguity and lack of significance. In none of these studies sample size requirements were reported. Most studies included in the review showed conclusions reasoned from the assumption of a positive effect size. Due to major differences in outcome variables, measures and study designs (i.e., clinical heterogeneity) and lack of data-assessment description, it was not possible to perform a meta-analysis. The clustered effect size remained, therefore, unknown. Nonetheless, based on the reviewed literature there might be a positive effect of applying barrier membranes. However, in our (controlled) experiments we found that barrier membranes do not prevent autologous bone block graft resorption.

In this thesis, the techniques applied to measure graft modeling with resorption were micro-CT (μ CT), microradiography (MR) and transversal microradiography (TMR). The advantage of μ CT in comparison to other modalities is that the whole region of interest (e.g., graft or defect) can be evaluated in 3 dimensions, enabling volume

measurements. In the experiment evaluated by μ CT, the graft volumes appeared to benefit from the collagen and ePTFE membranes, as analysed in a regression model with correction for effect modification by time and membranes. However, more bone volume is present in the control group at all times and the model without correction for effect modification shows a decrease of graft volume in all groups. Baseline values at 2 weeks appeared to differ although we have assumed that the group means of the graft volume were equal when transplanted (i.e., at 0 weeks). The disadvantage of the regression analysis is that it does not take into account the values at the moment of transplantation. A pilot experiment in which the graft (and defect) size are evaluated directly following the operation would, in retrospect, have precluded this ambiguity. A longitudinal design might have offered the most accurate conclusions.

The MR results are based on a 2 dimensional evaluation. On examination of the microradiographs of the grafted areas it became evident that it was not possible to use MR for graft area measurements as proposed by Schortinghuis et al. (2003). For these reasons, a MR technique for measuring bone graft modeling was chosen that could focus on the ratio of grey values rather than on graft size. The decreasing ratios of the grafted area compared to the graft surrounding area in all groups suggest nearly complete loss of volume of the grafted bone at 12 weeks. However, the bone within the graft area is depicted as a combined radiodensity of graft and overprojected original underlying mandibular bone on the 2D microradiographs. Due to μ CT and TMR it is now known that loss of graft volume and mineral did not occur as MR suggested since the 3D μ CT and 2D TMR measurements did not show a tendency of volume, height or mineral loss of the bone grafts. It must be noted that, especially in the 12 week groups, samples showed an intact graft volume combined with a defect in the underlying mandibular host bone of approximately the size of the graft. Similarly, especially in the 12 weeks samples, it appeared that mineral was lost in the original underlying bone, possibly causing the higher than expected mineralization ratios. Theoretically the mineralization of the original underlying bone is more or less constant.

The decrease in radiodensity of the grafted area as found

in MR seems to be the result of volume loss of the underlying host bone and probably a decrease of bone density. The defects in host bone might be caused by higher osteoclast-activity in mandibular bone due to a better perfusion. Covered grafts, consisting of predominantly cortical bone, may be less susceptible to revascularization and might rely on previous host bone resorption both to become revascularized and to model (Salata et al. 2002).

A notable finding with TMR was the low mineralization ratio and low height of ePTFE covered grafts at 12 weeks, compared to all other groups. A significant cause of these findings could not be found. No infections were observed in our study (Machtei 2001).

Advantages of barrier membrane application other than the prevention of graft resorption would be enhanced incorporation and predictability of the treatment outcome (Gordh et al. 1998; Donos et al. 2002b). The incorporation was evaluated in μ CT-slides and transversal microradiographs. Overall incorporation increases from 2 until 12 weeks in both membrane covered and control sites. No differences between groups were seen and therefore it is concluded that no additional effect from membrane application on graft incorporation is to be expected. However, increased predictability of the outcome of the bone augmentation was indicated by smaller confidence intervals in barrier membrane-treated groups compared to the controls.

The original reason to use TMR in this thesis was to describe the resorption process at a more detailed 'microscopic' level. Ordinary microradiography cannot measure mineralization as accurately as TMR, because of varying thickness of the mandible (and graft). The sections of the grafts contained a relatively large amount of soft tissue, making them vulnerable. Therefore, larger dimensions were chosen, resulting in a section thickness of 0.50 mm compared to 80 to 150 μ m in caries research (Arends et al. 1997). A disadvantage of this increased thickness is that detailed information as individual bone trabeculae and their orientation are not visible on the radiographs. Therefore, no statements can be made about bone remodeling at a 'microscopic' level.

In this thesis ratios of grey values of the area of interest (i.e., graft bone or new bone in defects) compared to the original mandibular bone, were evaluated to study bone modeling. A mean grey value of the area of interest alone

would not suffice, since variations between and within the underlying bone as well as variations in grey values due to digitizing of the microradiographs would prevent a valid outcome. An absolute value of mineralization of the area of interest would have been most appropriate. However, calibration and validation of mineral content of different types of bone related to grey values of microradiographs is difficult. Another problem when measuring with techniques using X-ray is the validation of the 'bone-no bone' threshold (Tuan & Hutmacher 2005). In this thesis, it was sufficient to compare groups to answer the research questions. Therefore, the reliability was more important than the validity (since possible systematic errors occurred in all groups). However, to study the relationship between μ CT, MR and the 'gold standard' histomorphometry in graft and defect width measurements (Schortinghuis et al. 2003), a series of samples was evaluated by all methods. Intraclass correlation coefficients for intraobserver reliability showed that the methods used in this thesis were very reliable. An unclear perimeter of the original defect as well as unclear perimeters of grafts made the evaluation of the 12 weeks groups more difficult. However, it appeared to be possible to obtain reliable scores, provided 1 observer uses strict criteria.

The relationships between the modalities were also studied. The defect measurements showed less agreement than the graft measurements. MR appeared to overestimate bone formation in defects compared to HM and μ CT. The high agreement between HM and μ CT indicate that the boundary of 'bone-no bone' applied to the μ CT 3D data set was apparently well chosen in the experiments. Conclusions based on μ CT are not only reliable but also rather valid. Considering the fact that the whole graft or defect is measured in μ CT in contrast with HM which measures usually 1 or 2 sections only, the validity of μ CT would be superior to HM. Overall, it is thus in any case feasible to compare group results with this technique.

In conclusion, this thesis shows that only minor differences between the barrier membranes were observed on autologous bone block graft modeling and incorporation. However, it is hazardous to extrapolate the results to the human situation. Ideally, a human model is chosen but the problem of obtaining sufficient statistical power is considerable. Meijndert et al. (in press) studied the effect

of barrier membrane application in 93 partially edentulous patients. It was concluded that barrier membranes do not prevent autologous onlay bone graft resorption. It seems therefore that barrier membranes are unnecessary in bone grafting procedures. However, in this study only onlay block grafts were used. When particulated bone is applied, a situation that is frequently seen in clinical practice (McAllister & Haghghat 2007), the barrier membrane is necessary to secure these granules but probably not to prevent bone resorption (Meijndert et al. 2005).

The secondary aim of this thesis was to evaluate a new degradable synthetic barrier membrane, manufactured out of poly(DL-lactide- ϵ -caprolactone) (Vivosorb[®], Polyganics, Groningen, The Netherlands). The *in vivo* application as a barrier membrane (defect and graft coverage) was studied. Furthermore biocompatibility was evaluated.

Since the copolymer had only been tested in a short-term *in vivo* implantation study (Meek et al. 2004) it was decided to perform a long-term implantation study. The implantation site of the polymer influences the polymer behaviour *in vivo* (Kaminski et al. 1968). As a result the final device designs in maxillofacial surgery are usually evaluated in their eventual anatomic (i.e., subperiosteal) environment (Von Arx et al. 2002). Nevertheless the polymers are often implanted and evaluated subcutaneously (Williams et al. 1997). It was explored whether it is valid to test biomaterials only subcutaneously, when the final device will be applied in a subperiosteal environment. In conclusion, the PDLLCL samples tested to be biocompatible. Although minor differences were seen, the tissue reaction and degradation of PDLLCL were in the same range subcutaneously when compared to subperiosteal implants. We may assume that minor differences between both implant sites do not influence the clinical results of the final device. Factors as a less radical operation and a more simple histological procedure as well as a larger number of test sites appear decisive. Therefore, it seems appropriate to evaluate a biomaterial for biocompatibility and degradation subcutaneously, even when the final application is subperiosteally.

Remarkable findings were the spatial configuration of PDLLCL and the tissue reaction to ePTFE, a standard reference material. PDLLCL tended to fold in the majority of cases, leading to a loss of surface contact of the

barrier membrane to bone. The contact loss was also seen in ePTFE samples, but folding was almost never seen. Folding of PDLLCL when applied as a barrier membrane can be a disadvantage with respect to defect and graft coverage. PDLLCL is an amorphous polymer and therefore it is not likely that during degradation tension forces develop causing the folding. Probably, the glass transition temperature below room temperature as well as the low molecular degradation products make the copolymer sticky. Muscle movement may fold the polymer which then sticks together.

A notable finding was that, particularly at subcutaneous sites, monocytes and lymphocytes were present in ePTFE samples, although the material is considered to be inert and non-degrading (Calisanelle et al. 2004), with only a fibrous capsule formation as foreign body response. Liu et al. (2001) found a similar non-specific reaction with macrophages and lymphocytes with ePTFE and biodegradable poly(DL-lactide) membranes tested subcutaneously in rats. In the present study it seemed that the material itself provoked some chronic inflammatory reaction in the subcutaneous samples. During the total implantation time this reaction decreased, possibly due to an increase of tissue tolerance to ePTFE.

The folding of PDLLCL might be a factor that influenced the results in the defect studies. Moreover, during the first surgical procedures it became clear that PDLLCL adhered less to the underlying bone as compared to collagen. Nevertheless, it was decided not to fix the newly designed barrier membrane. If a new barrier membrane would show satisfactory outcomes only with fixation, then this would be a major disadvantage for clinical practice and such a barrier membrane would not be capable to compete to the already available degradable collagen membranes. ePTFE does also not adhere to bone, in contrast to collagen. However, as performed by Schortinghuis et al. (2004) the ePTFE membranes were fixed with 1 suture.

Bone in-growth in defects with and without barrier membrane coverage was evaluated with μ CT, MR and TMR. The regression analyses show that all membranes allow more bone formation than the control. In the collagen group more bone was formed than in the ePTFE and PDLLCL groups. The collagen group evaluated with MR showed already a large amount of new bone at 2 weeks, which

precluded a significant effect modification of collagen over time. If measurements were performed at the moment of operation (0 weeks), when probably no bone would have been measured in any defect, the interaction terms could have been of significance.

More bone formation was observed in rats treated with collagen or ePTFE membranes as compared to PDLLCL. Overall minor differences between μ CT, MR and TMR were noted. One of the aims of the application of TMR was to obtain results for a detailed description of bone in-growth in defects at a 'microscopic' level. This was not possible, due to relative thick sections. However, it was feasible to differentiate 3 different patterns of bone growth in defects: (1) a quick formation of a thin rim of bone along the barrier membrane; (2) gradual inward migration of new bone from the borders towards the center of the defect whereby original bone thickness is maintained almost completely; (3) formation of multiple bone islets. Others found that bone growth in defects originated from the borders of the defect (Mueller et al. 2005; Strietzel et al. 2006).

Overall, results in the collagen and ePTFE treated defects are in accordance with results from previous studies (Dahlin et al. 1988; Schortinghuis et al. 2004; Schortinghuis et al. 2005; McAllister & Haghight 2007). Therefore, in clinical practice PDLLCL in its current composition cannot be expected to give as much bone in-growth in defects as the control membranes. Other synthetic degradable membranes showed also less bone in-growth compared to collagen and ePTFE (Aaboe et al. 1998; Wiltfang et al. 1998; Mueller et al. 2005). The defect closure at 12 weeks in PDLLCL in comparison to the other barrier membrane groups demonstrated a lower group's mean and a confidence interval about twice as large as in the other groups. The PDLLCL samples with a successful amount of new bone in-growth at 12 weeks performed similar to the successful ones of the control membranes, showing the potency of PDLLCL as a barrier membrane.

However, the results of the present study have shown that, in its current composition, PDLLCL is not ready for application in clinical practice. Although the barrier membrane allows significantly more bone in-growth than the control group, the problem with adherence and folding needs to be solved.

Conclusions

The conclusions from the work presented in this thesis are:

- » Barrier membranes do not prevent resorption of autologous onlay bone block grafts nor enhance graft incorporation. The augmentation procedure might be more predictable due to membrane coverage as indicated by smaller confidence intervals in membrane-treated groups.
- » PDLLCL is biocompatible and degradable in the long term.
- » PDLLCL in its current composition is not ready for application in clinical practice, although the barrier membrane allows significantly more bone in-growth than the control group.
- » Subcutaneous biocompatibility testing is adequate when the final device will be implanted subperiosteally.
- » μ CT and MR are reliable methods to determine bone modeling, μ CT appears valid compared to HM.

Future perspectives

In this thesis we concluded that barrier membranes do not prevent autologous onlay bone block graft resorption nor do they enhance incorporation, whereas in most other studies the contrary is concluded (Gordh et al. 1998; Antoun et al. 2001; Jardini et al. 2005). However, most research on barrier membranes and bone grafts do not include a blank control (Von Arx et al. 2002; Von Arx & Buser 2006). Therefore future membrane research should always apply a blank control group. If sufficient evidence, whether or not graft coverage makes sense, will be available, then a blank control can be omitted.

Bony defect treatment with barrier membranes (without bone grafts) is elegant and as long as minor defects can be treated with a barrier membrane this treatment modality appears preferable. Collagen membranes have been tested extensively and are considered the standard degradable reference material (McAllister & Haghight 2007). Apparently, not any degradable synthetic barrier membrane has shown to be equivalent to collagen membranes so far. Probably degradation products and other

features inherent to the polymers have effect on the bone modeling (Strietzel et al. 2006). This should be studied. Overall, the search for a synthetic degradable membrane is still fertile.

Autologous bone still is considered the 'gold standard' as bone grafting material (Merkx et al. 1999; Antoun et al. 2001). However, harvesting of bone is painful (Kalk et al. 1996; Joshi & Kostakis 2004). Therefore a treatment modality that precludes graft harvesting is preferred. A lot of research on bone substitutes has been and is being performed (Veis et al. 2006; Simion et al. 2007; Yamada et al. 2007). The search for the ideal bone substitute has not been finished yet.

In this thesis different techniques based on X-ray are used to evaluate bone modeling. Although μ CT is nowadays not widespread, the advantages of this technique are obvious. Development of better software and scanners will make it possible to obtain high resolution images of living animals. Uncomplicated calibration techniques for bone should be developed. Then, in longitudinal study designs it must be possible to monitor bone modeling in irregular defects and bone grafts. If this can be established, longitudinal designs with a minimal number of animals are feasible.

References

- Aaboe, M., Pinholt, E.M., Schou, S. & Hjorting-Hansen, E. (1998) Incomplete bone regeneration of rabbit calvarial defects using different membranes. *Clin Oral Implants Res* 9: 313-320.
- Antoun, H., Sitbon, J.M., Martinez, H. & Missika, P. (2001) A prospective randomized study comparing two techniques of bone augmentation: onlay graft alone or associated with a membrane. *Clin Oral Implants Res* 12: 632-639.
- Arends, J., Ruben, J.L. & Inaba, D. (1997) Major topics in quantitative microradiography of enamel and dentin: R parameter, mineral distribution visualization, and hyper-remineralization. *Adv Dent Res* 11: 403-414.
- Buser, D., Dula, K., Hirt, H.P. & Schenk, R.K. (1996) Lateral ridge augmentation using autografts and barrier membranes: a clinical study with 40 partially edentulous patients. *J Oral Maxillofac Surg* 54: 420-432.
- Calisaneller, T., Bavbek, M., Demirhan, B., Caner, H. & Altinörs, N. (2004) The value of expanded polytetrafluoroethylene in preventing early re-ossification after cranosynostosis surgery: an experimental animal study in the rat. *Acta Neurochir (Wien)* 146: 279-283.
- Carpio, L., Loza, J., Lynch, S. & Genco, R. (2000) Guided bone regeneration around endosseous implants with anorganic bovine bone mineral. A randomized controlled trial comparing bioabsorbable versus non-resorbable barriers. *J Periodontol* 71: 1743-1749.
- Chiapasco, M., Abati, S., Romeo, E. & Vogel, G. (1999) Clinical outcome of autogenous bone blocks or guided bone regeneration with e-PTFE membranes for the reconstruction of narrow edentulous ridges. *Clin Oral Implants Res* 10: 278-288.
- Dahlin, C., Linde, A., Gottlow, J. & Nyman, S. (1988) Healing of bone defects by guided tissue regeneration. *Plast and Reconstr Surg* 81: 672-676.
- Donos, N., Kostopoulos, L. & Karring, T. (2002a) Augmentation of the mandible with GTR and onlay cortical bone grafting. *Clin Oral Implants Res* 13: 175-184.
- Donos, N., Kostopoulos, L. & Karring, T. (2002b) Augmentation of the rat jaw with autogeneic cortico-cancellous bone grafts and guided tissue regeneration. *Clin Oral Implants Res* 13: 192-202.
- Gordh, M., Alberius, P., Johnell, O., Lindberg, L. & Linde, A. (1998) Osteopromotive membranes enhance onlay integration and maintenance in the adult rat skull. *Int J Oral Maxillofac Surg* 27: 67-73.
- Jardini, M.A., De Marco, A.C. & Lima, L.A. (2005) Early healing pattern of autogenous bone grafts with and without e-PTFE membranes: a histomorphometric study in rats. *Oral Surg Oral Med Oral Pathol Oral Radiol Endod* 100: 666-673.
- Joshi, A. & Kostakis, G.C. (2004) An investigation of post-operative morbidity following iliac crest graft harvesting. *Br Dent J* 196: 167-171.
- Kalk, W.W., Raghoobar, G.M., Jansma, J. & Boering, G. (1996) Morbidity from iliac crest bone harvesting. *J Oral Maxillofac Surg* 54: 1424-1429.
- Kaminski, E.J., Oglesby, R.J., Wood, N.K. & Sandrik, J. (1968) The behavior of biological materials at different sites of implantation. *J Biomed Mater Res* 2: 81-88.
- Liu, X.F., Shu, R., Li, C.L., Tian, Z. & Shen, J. (2001) Histological evaluation of the biocompatibility of PDLA membranes. *Shanghai Kou Qiang Yi Xue* 10: 122-124, 134.
- Machtei, E.E. (2001) The effect of membrane exposure on the outcome of regenerative procedures in humans: a meta-analysis. *J Periodontol* 72: 512-516.
- McAllister, B.S. & Haghghat, K. (2007) Bone augmentation techniques. *J Periodontol* 78: 377-396.
- Meek, M.F., Jansen, K., Steendam, R., van Oeveren, W., van Wachem, P.B. & van Luyn, M.J. (2004) In vitro degradation and biocompatibility of poly(DL-lactide-epsilon-caprolactone) nerve guides. *J Biomed Mater Res A* 68: 43-51.
- Meijndert, L., Raghoobar, G.M., Schüpbach, P., Meijer, H.J. & Vissink, A. (2005) Bone quality at the implant site after

- reconstruction of a local defect of the maxillary anterior ridge with chin bone or deproteinised cancellous bovine bone. *Int J Oral Maxillofac Surg* 34: 877-884.
- Meijndert, L., Raghoobar, G.M., Meijer, H.J.A. & Vissink, A. Clinical and radiographic characteristics of single tooth replacements preceded by local ridge augmentation. *Clin Oral Impl Res*, in press.
- Merx, M.A., Maltha, J.C., Freihofer, H.P. & Kuijpers-Jagtman, A.M. (1999) Incorporation of particulated bone implants in the facial skeleton. *Biomaterials* 20: 2029-2035.
- Mueller, A.A., Rahn, B.A., Gogolewski, S. & Leiggenger, C.S. (2005) Early dural reaction to polylactide in cranial defects in rabbits. *Pediatr Neurosurg* 41: 285-291.
- Salata, L.Z., Rasmusson, L. & Kahnberg, K.E. (2002). Effects of a mechanical barrier on the integration of cortical onlay bone grafts placed simultaneously with endosseous implant. *Clin Implant Dent Relat Res* 4: 60-68.
- Schortinghuis, J., Ruben, J.L., Meijer, H.J., Bronckers, A.L., Raghoobar, G.M. & Stegenga, B. (2003) Microradiography to evaluate bone growth into a rat mandibular defect. *Arch Oral Biol* 48: 155-160.
- Schortinghuis, J., Ruben, J.L., Raghoobar, G.M. & Stegenga, B. (2004) Therapeutic ultrasound to stimulate osteoconduction; A placebo controlled single blind study using e-PTFE membranes in rats. *Arch Oral Biol* 49: 413-420.
- Schortinghuis, J., Ruben, J.L., Raghoobar, G.M., Stegenga, B. & de Bont, L.G. (2005) Does ultrasound stimulate osteoconduction? A placebo-controlled single-blind study using collagen membranes in the rat mandible. *Int J Oral Maxillofac Implants* 20: 181-186.
- Simion, M., Fontana, F., Rasperini, G. & Maiorana, C. (2007) Vertical ridge augmentation by expanded-polytetrafluoroethylene membrane and a combination of intraoral autogenous bone graft and deproteinized anorganic bovine bone (Bio Oss). *Clin Oral Implants Res* 18: 620-629.
- Strietzel, F.P., Khongkhunthian, P., Khattiya, R., Patchanee, P. & Reichart, P.A. (2006) Healing pattern of bone defects covered by different membrane types--a histologic study in the porcine mandible. *J Biomed Mater Res B* 78: 35-46.
- Tuan, H.S. & Huttmacher, D.W. (2005) Application of micro CT and computation modelling in bone tissue engineering. *Comput Aided Des* 37: 1151-1161.
- Veis, A.A., Dabarakis, N.N., Parisi, N.A., Tsirlis, A.T., Karanikola, T.G. & Printza, D.V. (2006) Bone regeneration around implants using spherical and granular forms of bioactive glass particles. *Implant Dent* 15: 386-394.
- Von Arx, T., Cochran, D.L., Schenk, R.K. & Buser, D. (2002) Evaluation of a prototype trilayer membrane (PTLM) for lateral ridge augmentation: an experimental study in the canine mandible. *Int J Oral Maxillofac Surg* 31: 190-199.
- Von Arx, T. & Buser, D. (2006) Horizontal ridge augmentation using autogenous block grafts and the guided bone regeneration technique with collagen membranes: a clinical study with 42 patients. *Clin Oral Implants Res* 17: 359-366.
- Williams, S.K., Berman, S.S. & Kleinert, L.B. (1997) Differential healing and neovascularization of ePTFE implants in subcutaneous versus adipose tissue. *J Biomed Mater Res* 35: 473-481.
- Wiltfang, J., Merten, H.A. & Peters J.H. (1998) Comparative study of guided bone regeneration using absorbable and permanent barrier membranes: a histologic report. *Int J Oral Maxillofac Implants* 13: 416-421.
- Yamada, M., Shiota, M., Yamashita, Y. & Kasugai, S. (2007) Histological and histomorphometrical comparative study of the degradation and osteoconductive characteristics of alpha- and beta-tricalcium phosphate in block grafts. *J Biomed Mater Res B* 82: 139-148.

Summary / Samenvatting



Summary

Summary

Guided bone regeneration (GBR) can be described as the use of a barrier membrane to provide a space available for new bone formation in a bony defect. The barrier membrane protects the defect from in-growth of soft tissue cells and allows bone progenitor cells to develop bone within a blood clot that is formed beneath the barrier membrane. Furthermore, the membrane excludes inhibiting factors from outside the defect and preserves bone growth factors inside. GBR was developed in the 1950s and 1960s and has been applied in trauma and reconstructive surgery. In the 1980s, clinicians started to use barrier membranes in implant dentistry. The membranes were applied to reconstruct small bony defects prior to implantation or to cover dehiscences or fenestrations around dental implants.

In large defects a bone graft is frequently necessary. The bone graft serves as a scaffold and carrier for living cells. However, bone grafting is not always successful because of graft resorption or insufficient graft incorporation. To enhance the predictability of bone augmentation procedures, in the mid-1990s grafts were covered with barrier membranes in an attempt to prevent bone graft resorption. A barrier membrane would prevent graft resorption and possibly would enhance graft incorporation by keeping the osteoinductive substances in place and secluding the grafted area from inhibiting factors and connective tissue cells. The overlying barrier membrane would maintain space in remaining crevices for bone regeneration.

Although most studies have been uncontrolled, the application of barrier membranes to cover bone grafts is now widespread among clinicians because the reported results were promising. However, in maxillofacial surgery and implant dentistry a continuing debate exists as to whether a barrier membrane should be applied to cover autologous onlay bone block grafts when augmenting the jaw. It is desirable that this question is answered because the use of barrier membrane may have adverse effects and is rather expensive.

Numerous membranes have been developed throughout the years. Although the standard reference materials, i.e., a porcine bilayer collagen membrane for biodegradable membranes and a synthetic expanded polytetrafluoroethylene (ePTFE) membrane for non-degradable membranes,

have been established as being successful in covering defects, there are some disadvantages to their application. Collagen has poor space making properties in wet conditions and its composition of animal derived collagen may possibly lead to disease transmission from animal to people, at least theoretically. The ePTFE is non-degradable and therefore must be removed in an additional surgical procedure. Furthermore, the membrane has to be removed when exposed to the oral cavity to resolve an inflammatory reaction that occurs. The 'ideal' barrier membrane for alveolar ridge augmentation is thus not yet applied in clinical practice. The 'ideal' membrane should be both biodegradable and synthetic. A recently developed Vivosorb® membrane composed of poly(DL-lactide-ε-caprolactone) (PDLLCL) is biodegradable and synthetic and might have the required properties of an 'ideal' barrier membrane.

The first aim of this thesis was to study the preventive effect of barrier membranes on bone resorption of autologous onlay bone grafts. The second aim was to evaluate the newly developed PDLLCL barrier membrane by comparing it to collagen and ePTFE barrier membranes. For these purposes micro-computed tomography (micro-CT), microradiography, and transversal microradiography were used in the GBR experiments.

In Chapter 2 the available literature is critically appraised in a systematic literature review to identify the evidence for barrier membranes to prevent autologous onlay bone graft resorption. The primary outcome measure was bone resorption. The search yielded 182 articles, 32 of which were relevant to the study. Two observers independently appraised these 32 studies methodologically, yielding 14 controlled studies.

The articles included human and animal experiments with heterogeneous objectives and outcome variables. Although most authors concluded that they had found evidence for the protective effect of barrier membranes on bone resorption in autologous onlay bone grafts, this systematic review revealed that the available evidence is too weak to support this.

It was concluded that further evidence was needed to determine whether barrier membranes prevent bone resorption in autologous onlay bone grafts.

In Chapter 3 the tissue-biomaterial response of the PDLLCL barrier membrane was compared to that of ePTFE *in vivo* in rats. Short-term subcutaneous *in vivo* and *in vitro* research had already shown that this copolymer is both degradable and biocompatible. However, long-term biocompatibility and degradation of PDLLCL *in vivo* cannot be assumed without proper testing, as is illustrated by the problems with crystalline PLLA particles in the long term of seemingly biodegradable materials in the 1980s.

The implantation site of polymers influences the polymer behaviour *in vivo*. As a result the final device designs in maxillofacial surgery are usually evaluated in their eventual anatomic (i.e., subperiosteal) environment. Nevertheless, the polymers are often implanted and evaluated subcutaneously. To our knowledge it has not been established that biocompatibility and degradation are similar at subcutaneous and at subperiosteal implant sites. Therefore it was explored whether it is valid to test biomaterials only subcutaneously, when the final device will be applied subperiosteally. In each of 36 rats a total of 4 discs, 2 PDLLCL and 2 ePTFE, were implanted subcutaneously in the back and subperiosteally on the mandible. Groups of 6 rats were sacrificed at 6, 12, 26, 48, 65 and 81 weeks after implantation. The samples were evaluated by light microscopy.

No abnormalities in tissue healing were seen except that ePTFE evoked a response of phagocytes and lymphocytes. Folding was predominantly seen in PDLLCL and might be a problem when applied as a barrier membrane. Minor differences in the tissue reaction and degradation of PDLLCL were seen subcutaneously when compared to subperiosteally.

It was concluded that PDLLCL tested to be degradable and biocompatible. It would be worthwhile to compare PDLLCL to the reference standards collagen and ePTFE barrier membranes on grafts and in defects. The minor differences between both implant sites probably will not influence the clinical results of the final device. Less radical surgery, a simpler histological procedure, and a larger number of test sites appear decisive to choose a subcutaneous implantation site for polymer testing. It seems appropriate to evaluate a biomaterial for biocompatibility and degradation subcutaneously, when the final application is subperiosteally.

Traditionally, histomorphometry (HM) has been used to measure bone formation in bony defects or bone modeling of onlay bone grafts. An alternative technique, microradiography (MR), was successfully introduced for the quantitative evaluation of new bone formation of experimentally created mandibular defects in rats. The entire defect can easily be measured in 2 dimensions (D), whereas HM often involves 1 section (1 dimension) through the center of the defects or grafts. However, 3D volumetric calculations are impossible with MR. A recently evolved other technique is micro-computed tomography (μ CT), where both 3D (and 2D) reconstructions and volumetric measurements can be obtained.

In Chapter 4 MR, μ CT and HM, were compared for quantitative measurements of bone formation and graft modeling with resorption in rat mandibular defects and grafts. The intraobserver reliability and agreement were determined for the 3 modalities.

Microradiographs, μ CT images and histological sections were obtained from 48 specimens. New bone volume and graft modeling with resorption were measured using image analysis software on MR and μ CT images. Defect width and graft width were measured using images from MR, μ CT and HM.

The intraobserver reliabilities for the measurements of new bone volume by μ CT and the measurement of graft modeling ratio by MR and graft volume by μ CT were high. The differences between MR, μ CT and HM were larger in defect width measurements than in graft width measurement. MR measured smaller defects than μ CT and HM; MR appears thus to overestimate bone formation. The distance between the limits of agreement was larger in defect width measurements compared to graft width measurements.

We concluded that the methods of MR and μ CT image analysis are reliable but preferably should be used in combination as to obtain valid conclusions.

The tested modalities were used in the rest of the experiments. In Chapter 5 the effect of PDLLCL, collagen and ePTFE membranes on graft modeling with resorption and incorporation of autologous onlay bone block grafts in rats were described using MR, μ CT (Chapter 5.1) and transversal microradiography (TMR) (Chapter 5.2).

In the experiment a total of 192 male Sprague-Dawley rats were treated. A 4.0 mm diameter bone graft was harvested from the right mandibular angle and transplanted to the left. The 3 barrier membranes were used to cover the grafts. The controls were left uncovered. Graft resorption at 2, 4 and 12 weeks was evaluated by post-mortem MR, μ CT and TMR. Resorption was measured as a decrease in mineralization ratio of the graft, graft volume and graft height. Data were analysed using multiple regression analyses. ePTFE at 12 weeks showed a lower mineralization ratio and graft height as compared to the other groups in TMR. Smaller confidence intervals were seen in the membrane-treated groups compared with non-treated controls. Overall, there were no differences in modeling with resorption between the 4 groups.

Graft incorporation was measured as the length of the incorporated part of the graft divided by the total length of the graft. The mean graft incorporation was progressive and nearly identical from 2 to 12 weeks in all groups, including the control group. This demonstrates that the indication of barrier membrane use, to prevent bone modeling with resorption and to enhance incorporation of autologous onlay bone block grafts, is at least disputable.

In Chapter 6 the qualitative and quantitative effects of the 3 different types of membranes on bone formation in mandibular critical size defects in rats were evaluated. In the same group of 192 rats 5.0 mm defects created during bone graft harvesting (Chapter 5) were treated with the 3 membranes. MR, μ CT (Chapter 6.1) and TMR (Chapter 6.2) were used for measurements.

Four groups (control, PDLLCL, collagen, ePTFE) were evaluated at 3 time intervals (2, 4 and 12 weeks). In the membrane groups the defects were covered; in the control group the defects were left uncovered. Data were analysed using a multiple regression model.

New bone was measured as area, volume and percentage of defect bridging. Bone formation was progressive in 12 weeks, when the mandibular defect was covered with a membrane. Although substantial bone healing was observed in defects covered with a PDLLCL membrane, overall, more bone formation was observed underneath the collagen and ePTFE membranes than the PDLLCL membranes. The high variation in the PDLLCL samples at

12 weeks may be caused by the moderate adherence of this membrane to bone compared with collagen. PDLLCL in its current composition is not ready for application in clinical practice, although the barrier membrane allows significantly more bone in-growth than the control group.

In Chapter 7 the results and conclusions of the former chapters are compared and discussed. From the review it could be concluded that it is at least disputable that barrier membrane application prevents autologous onlay bone graft resorption, although most authors of the reviewed articles claimed a preventive effect. Most of these reviewed articles showed conclusions reasoned from the assumption of a positive effect size.

In the experiments in this thesis, possible evidence for increased predictability of bone augmentation by membrane coverage was suggested by the smaller confidence intervals seen overall in the membrane-treated groups compared with non-treated controls. However, autologous onlay block graft resorption and incorporation were not influenced by membranes. When particulated bone is applied, a situation that is frequently seen in clinical practice, the barrier membrane is necessary to secure these granules.

μ CT and MR are reliable methods to determine bone modeling with resorption in grafts and bone formation in defects, therefore groups could be compared. μ CT appeared to be valid (with HM serving as a reference). TMR measurements provided less information than expected, because the slices were too thick to study the intended details of bone modeling. To overcome some of the encountered problems it is suggested to determine baseline values and to apply a longitudinal design in future research.

In the defect studies more bone in-growth was seen in the PDLLCL groups compared to the control groups. However, its performance was inferior to the commonly used collagen and ePTFE membranes, possibly due to folding and little bone adherence as demonstrated in the degradation study. In this degradation study PDLLCL was tested to be biocompatible and degradable. ePTFE, considered to be highly inert and used as control, showed infiltration of phagocytes and lymphocytes. No cause could be found to explain this observation. Another conclusion was that subcutaneous biocompatibility testing is adequate when the

final device will be implanted subperiosteally.
In conclusion, in this thesis autologous onlay bone block graft resorption and incorporation were not influenced by barrier membrane coverage. Furthermore, it was concluded that the PDLLCL membrane is not suitable for clinical application in its current form and further study is needed to optimize the properties of PDLLCL membranes.

Samenvatting

Samenvatting

Geleide bot regeneratie (GBR) kan omschreven worden als het toepassen van een membraan over een botdefect als barrière tegen bindweefselgroei, zodat zich ongestoord nieuw bot in het defect kan vormen. Het membraan werkt daarbij als een soort tent waardoor de voorlopercellen van bot de gelegenheid krijgen om nieuw bot te maken in de bloedprop die in het defect onder het membraan wordt gevormd. Tevens weert het membraan botgroeiremmende factoren en houdt het groeifactoren voor bot onder het membraan ter plaatse. Het gebruik van membranen om botvorming in botdefecten te stimuleren is in de 50- en 60-er jaren van de vorige eeuw ontwikkeld en werd toen toegepast in de traumatologie en reconstructieve chirurgie. In de 80-er jaren startten klinici met het gebruik van membranen in de tandheelkundige implantologie om botdefecten te reconstrueren voordat tandheelkundige implantaten, ook wel 'kunstwortels' genoemd, werden geplaatst. Als het implantaat na plaatsing niet volledig door bot bedekt bleek te zijn, werden de blootliggende delen daarvan bedekt met membranen.

In grote botdefecten is de toepassing van een bottransplantaat regelmatig nodig. Een botblokje wordt dan aangebracht om de kaak te verbreden of te verhogen (botaugmentatie), alvorens implantaten geplaatst kunnen worden. Het bottransplantaat dient als dragermateriaal van levende cellen en als matrix voor nieuwe botvorming. Door transplantaatresorptie en onvoldoende vastgroeien van het transplantaat (incorporatie) is deze toepassing echter niet altijd succesvol. In een poging de mate van voorspelbaarheid van botopbouw te verhogen bedekten onderzoekers in de 90-er jaren de transplantaten met membranen. Het gebruik van een membraan zou het oplossen (resorptie) van het bottransplantaat voorkómen en mogelijk de incorporatie van het transplantaat bevorderen door botgroeistimulerende stoffen ter plaatse te houden en het opgebouwde gebied vrij te houden van remmende factoren en bindweefselcellen. Er zou tevens nieuw bot gevormd kunnen worden in de ruimten die door het overliggende membraan worden gecreëerd.

Hoewel de meeste studies met betrekking tot dit onderwerp zonder controle groep zijn uitgevoerd, is de toepassing van barrière membranen om bottransplantaten te

bedekken nu wijdverbreid omdat de gepubliceerde resultaten veelbelovend leken. De vraag of bottransplantaten van lichaamseigen bot (autoloog) wel of niet bedekt dienen te worden met een membraan bij botopbouw is echter nog niet beantwoord. De voordelen van membranen moeten wel opwegen tegen de nadelen; zo zijn ze een substantiële kostenpost bij het opbouwen van de kaak.

Er zijn in de loop der jaren vele membranen ontwikkeld voor toepassing in de kaakchirurgie. De standaard vergelijkingsmaterialen zijn een varkenscollageen membraan, Geistlich Bio-Gide®, voor de biologisch oplosbare (biodegradeerbare) en een synthetisch geëxpandeerd polytetrafluoroethylene (ePTFE), ook wel Gore-Tex® genaamd, voor de niet-degradeerbare membranen. Hoewel deze membranen bewezen succesvol zijn bij het bedekken van botdefecten, kennen zij ook enkele nadelen. Collageen wordt slap in een natte omgeving en is daardoor minder geschikt voor het openhouden van ruimten voor botingroei. Ook bestaat er een, in ieder geval theoretisch, risico van ziekteoverdracht van dier op mens, doordat het collageen van dierlijke oorsprong is. De ePTFE membraan is niet-degradeerbaar, wat het noodzakelijk maakt om deze in een tweede operatieve ingreep te verwijderen. Tevens moet het membraan verwijderd worden in het geval het door het bedekkende slijmvlies heen bloot komt te liggen in de mondholte en hierdoor zou leiden tot een ontstekingsreactie. Het 'ideale' membraan voor opbouw van de kaak, dat zowel biodegradeerbaar als synthetisch zou moeten zijn, wordt nog niet toegepast in de kliniek. Een recent ontwikkeld membraan, gemaakt van een poly(DL-lactide-ε-caprolacton) (PDLLCL) copolymeer (Vivosorb®), is zowel biodegradeerbaar als synthetisch en daarom mogelijk het 'ideale' barrière membraan.

Het doel van dit proefschrift was in de eerste plaats een antwoord krijgen op de vraag of barrière membranen daadwerkelijk de botresorptie van autologe botblok transplantaten op de kaak (oftewel onlay transplantaten) voorkómen. Het tweede doel was het evalueren van een nieuw ontwikkelde PDLLCL membraan door deze te vergelijken met collageen en ePTFE barrière membranen. Voor deze doelen werden in de transplantaat- en defectstudies micro-computed tomography (micro-CT), microradiografie en transversale microradiografie toegepast.

In Hoofdstuk 2 werd de beschikbare literatuur op systematische wijze bestudeerd om bewijs te vinden voor de veronderstelling dat barrière membranen botresorptie van autologe bottransplantaten voorkómen. De primaire uitkomstvariabele was botresorptie. De zoekstrategie leverde 182 artikelen op, waarvan er 32 relevant bleken voor deze studie. Twee onderzoekers beoordeelden deze artikelen onafhankelijk van elkaar op basis van methodologische criteria. Dit resulteerde in 14 geschikte gecontroleerde studies.

De artikelen bestonden uit humane en dierlijke experimenten met heterogene doelen en uitkomstvariabelen. Ondanks dat de meeste auteurs concludeerden dat ze bewijs hadden gevonden voor het beschermende effect van barrière membranen ten aanzien van resorptie van bottransplantaten, toonde de systematische review aan dat het beschikbare bewijs te zwak is om deze conclusie te ondersteunen.

Er werd daarom geconcludeerd dat meer bewijs nodig is om vast te stellen of door barrière membranen botresorptie van autologe bottransplantaten, die op de kaak aangebracht worden, wordt voorkómen.

In Hoofdstuk 3 werd de reactie van het weefsel op het PDLLCL barrière membraan *in vivo* in ratten vergeleken met die op ePTFE. In onderhuids (subcutaan) *in vivo* en *in vitro* onderzoek was al aangetoond dat PDLLCL zowel biodegradeerbaar als biocompatibel ('weefselvriendelijk') is voor de korte termijn. Echter, de biocompatibiliteit en degradatie van PDLLCL *in vivo* zouden ook moeten worden getest in een lang lopende studie, gezien de problemen op de lange termijn met kristallijne restpartikels van ongeschijnlijk biodegradeerbare materialen in de jaren 80 van de vorige eeuw.

De plaats van implantatie van polymeren beïnvloedt het materiaalgedrag *in vivo*. Om deze reden wordt het prototype van de uiteindelijke toepassing in de kaakchirurgie, bijvoorbeeld een schroef, normaliter getest op de uiteindelijk beoogde anatomische plaats van toepassing. Binnen de kaakchirurgie is dat meestal onder het botvlies (subperiostaal). Toch worden de polymeren waaruit het prototype gemaakt gaat worden vaak onderhuids geïmplantéerd en geëvalueerd. Voor zover bekend is echter niet bewezen dat biocompatibiliteit en degradatie identiek zijn op

lokaties onder de huid en onder het botvlies. Daarom werd onderzocht of kan worden volstaan met het onderhuids testen van biomaterialen, ook wanneer de uiteindelijke toepassing onder het botvlies is. In ieder van 36 ratten werden 4 schijfjes, 2 PDLLCL en 2 ePTFE, onderhuids in de rug respectievelijk onder het botvlies op de onderkaak geïmplantéerd. Explantatie vond plaats per groep van 6 ratten op 6, 12, 26, 48, 65 en 81 weken na implantatie. De weefselstukjes werden histologisch onderzocht met behulp van lichtmicroscopie.

Er werden geen afwijkingen gezien in de weefselgenezing, behalve dat ePTFE een weefsel reactie van fagocyten en lymfocyten veroorzaakte. Opvouwen van het materiaal was voornamelijk te zien in PDLLCL; dit zou tot problemen kunnen leiden wanneer het toegepast wordt als barrière membraan. Tussen de lokatie onder de huid en onder het botvlies waren kleine verschillen in weefselreactie en degradatie van PDLLCL te zien.

Er werd geconcludeerd dat PDLLCL degradeerbaar en biocompatibel is. Het zou daarom waardevol zijn om PDLLCL als barrière membraan te vergelijken met collageen en ePTFE. De kleine verschillen tussen beide implantatieplaatsen zullen waarschijnlijk de klinische resultaten van de uiteindelijke toepassing niet beïnvloeden. Een minder ingrijpende operatie, een eenvoudigere histologische procedure en tevens een groter aantal implantatieplaatsen lijken doorslaggevende argumenten te zijn voor het onderhuids uitvoeren van biocompatibiliteits- en degradatietesten. Het lijkt daarom terecht dat biomaterialen onder de huid worden getest voor biocompatibiliteit en degradatie, ook wanneer de uiteindelijke toepassing onder het botvlies ligt.

Van oudsher wordt histomorfometrie (HM) gebruikt om botvorming in botdefecten of botbouw in bottransplantaten te meten. Bij HM worden in histologische coupes oppervlakten en afstanden gemeten van en in de diverse weefsels. Een alternatieve techniek is microradiografie (MR), waarbij kleine, hoogresolutie röntgenfoto's worden vervaardigd. Deze techniek werd succesvol geïntroduceerd voor de kwantitatieve evaluatie van vorming van nieuw bot in defecten in de onderkaak van ratten. Het hele defect kan gemakkelijk worden gemeten in 2 dimensies (D), terwijl het bij HM vaak gaat om 1 coupe (1 dimensionaal) door

het centrum van het defect of implantaat. Drie dimensionale volumetrische metingen zijn echter niet mogelijk met MR. Met een andere recent ontwikkelde techniek, micro-CT (μ CT), kunnen zowel 3D (en 2D) reconstructies als volumetrische metingen verricht worden bij zeer kleine proefmonsters.

In Hoofdstuk 4 werden MR, μ CT en HM vergeleken voor wat betreft kwantitatieve metingen van botvorming en implantaatombouw met resorptie in respectievelijk onderkaaksdefecten en bottransplantaten in ratten. Voor de 3 meetinstrumenten werden de intra-waarnemer betrouwbaarheid en overeenstemming bepaald. De intra-waarnemer betrouwbaarheid geeft aan in hoeverre de uitkomst van opeenvolgende metingen door 1 persoon van hetzelfde proefstukje overeenkomen; de overeenstemming geeft weer in hoeverre de resultaten van metingen van hetzelfde proefstukje met verschillende technieken overeenkomen.

Van 48 monsters werden microradiografische opnamen, μ CT beelden en histologische coupes gemaakt. Nieuw bot en implantaatombouw werden gemeten met behulp van beeldanalyse-software op de MR en μ CT beelden. De diameter van de defecten en implantaatbreedte werden gemeten met opnamen van MR, μ CT en HM.

De intra-waarnemer betrouwbaarheden voor de metingen van nieuw botvolume met μ CT, de metingen van implantaatombouw als mineralisatieverhouding van implantaat en onderliggend bot met MR en het implantaatvolume met μ CT waren hoog. De verschillen tussen MR, μ CT en HM waren groter in defectdiameter-metingen dan in implantaatbreedte-metingen. MR, μ CT en HM in implantaatbreedte-metingen toonden dus meer overeenstemming dan bij defectdiameter-metingen. Met behulp van MR werden kleinere defecten gemeten dan met μ CT en HM; MR lijkt botvorming dus te overschatten.

Geconcludeerd werd dat de methoden van MR en μ CT beeldanalyse betrouwbaar zijn maar bij voorkeur in combinatie gebruikt zouden moeten worden om valide conclusies te trekken.

De geteste meetmethoden werden in alle overige experimenten toegepast. In Hoofdstuk 5 werd met MR, μ CT (Hoofdstuk 5.1) en transversale microradiografie (TMR) (Hoofdstuk 5.2) het effect van PDLLCL, collageen en

ePTFE membranen gemeten op implantaatombouw met resorptie en incorporatie van autologe bottransplantaten in ratten. TMR is een variatie op MR waarbij opnamen vervaardigd worden van een doorsnede van een proefmonster.

In de experimenten werden in totaal 192 Sprague-Dawley ratten geoperieerd. Een bottransplantaat met een diameter van 4.0 mm werd geogst uit de rechter kaakhoek en getransplanteerd naar de linker. De 3 barrière membranen werden gebruikt om de transplantaten te bedekken. De controle-transplantaten werden onbedekt gelaten. Resorptie van de transplantaten werd 2, 4 en 12 weken postoperatief geëvalueerd met post-mortem MR, μ CT en TMR door een mineralisatieverhouding van implantaat en onderliggend bot, implantaatvolume en implantaathoogte te meten. De mate van incorporatie werd gemeten als de lengte van het geïncorporeerde deel van het implantaat gedeeld door de totale lengte van het implantaat. De data werden geanalyseerd met behulp van multi-pele regressie analyses. Er werd minder spreiding in de uitkomsten van groepen gezien die met membranen waren behandeld in vergelijking tot de onbehandelde controles. Over het algemeen kan men stellen dat er geen verschillen waren in botombouw met resorptie tussen de 4 groepen. ePTFE op 12 weken toonde een lagere mineralisatie en implantaathoogte in vergelijking met de andere groepen in TMR. De gemiddelde implantaatincorporatie was progressief en bijna identiek in alle groepen van 2 tot 12 weken. Het laat zien dat de indicatie voor het gebruik van barrière membranen om resorptie van autologe botblok transplantaten op de kaak te voorkomen en incorporatie te vergroten op zijn minst twijfelachtig is.

In Hoofdstuk 6 werden de kwalitatieve en kwantitatieve effecten van de 3 verschillende typen membranen (PDLLCL, collageen en ePTFE) op botvorming in defecten in de onderkaak van ratten geëvalueerd.

In dezelfde groep van 192 ratten werden de 5.0 mm diameter defecten, die achterbleven na het oogsten van de bottransplantaten (Hoofdstuk 5) bedekt met de 3 membranen. MR, μ CT (Hoofdstuk 6.1) en TMR (Hoofdstuk 6.2) werden gebruikt om botvorming in de defecten te meten na 2, 4 en 12 weken. Tevens werd de botvorming gemeten in een controlegroep waar geen membraan werd gebruikt.

De data werden geanalyseerd met behulp van multi-pele regressie.

Nieuw bot werd gemeten als oppervlakte, volume en lengte. Vorming van nieuw bot werd gezien gedurende de 12 weken, mits het defect bedekt was met een membraan. Hoewel substantiële botvorming werd gemeten in defecten bedekt met PDLCL, werd over het algemeen meer bot gemeten onder het collageen en ePTFE membraan in vergelijking met PDLCL. De gevonden grote variatie in hoeveelheid nieuw bot op 12 weken in de PDLCL groep zou veroorzaakt kunnen zijn door het matige aanliggen van dit membraan aan het bot in vergelijking tot collageen. PDLCL in de huidige samenstelling is niet klaar voor klinische toepassing, hoewel het barrière membraan significant meer botvorming toonde vergeleken met de onbehandelde controle groep.

In Hoofdstuk 7 worden de resultaten en conclusies van de vorige hoofdstukken vergeleken en bediscussieerd. In de literatuurstudie werd geconcludeerd dat het op zijn minst twijfelachtig is dat membraangebruik transplantatresorptie zou voorkómen, hoewel de meeste auteurs van de bestudeerde artikelen een preventief effect veronderstellen. De meeste van deze bestudeerde artikelen toonden conclusies geredeneerd vanuit een aanname dat er een positief effect zou moeten zijn.

In de experimenten die in dit proefschrift zijn beschreven werd een mogelijk bewijs voor een hogere mate van voorspelbaarheid van botopbouw door membraangebruik gevonden. Dat wordt gesuggereerd door de kleinere spreiding in uitkomsten in de groepen die met membraan behandeld zijn. Transplantaatresorptie en -incorporatie werden echter niet beïnvloed door de membranen. In de kliniek wordt vaak gebruik gemaakt van botpartikels voor botopbouw. Membranen zijn in dat geval nodig om deze botkorrels op hun plaats te houden.

Omdat μ CT en MR betrouwbare methoden zijn om botvorming en resorptie te meten, konden groepen met elkaar worden vergeleken. μ CT lijkt valide te zijn bij gebruik van HM als referentiestandaard. TMR metingen gaven minder informatie dan verwacht. De coupes waren te dik om de beoogde details van botopbouw te bestuderen. Om enkele van de tegengekomen problemen in toekomstig onderzoek te vermijden is het aan te bevelen ook uitgangswaarden

te bepalen om een longitudinale gegevensanalyse toe te kunnen passen.

In de defectstudie werd meer botingroei gezien in de PDLCL groepen vergeleken met de controlegroep. De veelgebruikte collageen en ePTFE membranen bleken echter superieur, mogelijk doordat PDLCL vouwt of krult en dat het niet makkelijk aansluit aan het bot zoals dat werd aangetoond in de degradatiestudie. In deze degradatiestudie bleek PDLCL biocompatibel en degradeerbaar te zijn. ePTFE, dat algemeen beschouwd wordt als zeer inert en daarom vaak wordt gebruikt als controlemateriaal, toonde een weefselreactie met infiltratie van fagocyten en lymfocyten. Hiervoor kon geen oorzaak worden gevonden. Een andere conclusie was dat het onderhuids testen van de biocompatibiliteit adequaat is, ook wanneer de uiteindelijke toepassing van het materiaal onder het botvlies is. Welbeschouwd blijkt uit dit proefschrift dat resorptie en incorporatie van autologe botblok transplantaten op de kaak niet worden beïnvloed door het bedekken met een barrière membraan. Daarnaast kan worden geconcludeerd dat de huidige PDLCL membranen niet bruikbaar zijn voor klinische toepassing. Verdere ontwikkeling en onderzoek is nodig om de eigenschappen van het PDLCL membraan te optimaliseren.

Dankwoord



Dankwoord

Mijn onderzoek was niet geworden wat het nu is als ik het karwei alleen had moeten klaren. De kennis en kunde van velen zijn onmisbaar geweest. Ik wil daarom een aantal mensen in het bijzonder bedanken.

Prof.dr. R.R.M. Bos, geachte professor, beste Ruud. Met ongelimiteerd enthousiasme wist je mij te boeien voor het specialisme Kaakchirurgie. Na een afstudeerscriptie over hechtdraden en een keuze-coschap op de afdeling startte ik met mijn promotieonderzoek bij jou. Jouw netwerk en creatieve geest bleken meer dan eens zeer handig te zijn. Ik heb de vrijheid die je mij gaf zeer gewaardeerd. Prijzenswaardig is je persoonlijke benadering. Bedankt voor de leuke tijd die we hebben gehad bij de verschillende congresbezoeken.

Prof.dr. B. Stegenga, geachte professor, beste Boudewijn. Nog voor mijn promotieonderzoek bleek jouw hulp hard nodig. Toen maakte je mij op een bijzondere manier duidelijk hoe lastig het meten van pijn is. Hoewel ik in het begin nog wat moest wennen aan je indringende blik, raakte ik snel gewend aan je handelsmerk. Jij hebt mij geweldig geholpen. Het manuscript was niet van deze kwaliteit geweest zonder jou. Ik ben je daarom zeer erkentelijk. Bedankt voor al je tijd, inzet en leerzame bijeenkomsten.

Prof.dr. G.M. Raghoobar, geachte professor, beste Gerry. Toen na mijn eerste jaar onderzoek werd besloten om een ander pad te kiezen heb jij mij geweldig op weg geholpen. Jouw inhoudelijke expertise hoedde mij voor het verkondigen van klinisch irrelevante informatie. Je onuitputtelijk positivisme stemde mij meer dan eens gerust, wanneer ik alleen maar 'beren' op de weg zag. Dank hiervoor.

Dr. J. Schortinghuis, beste Jurjen. Jouw proefschrift was mijn 'Wikipedia'. Ik heb een enorm voordeel gehad door jouw kennis en ervaring. Regelmatig kon ik na een gesprek met jou wel een knoop doorhakken. Ik bewonder je heldere manier van redeneren en wil je bedanken voor al het correctiewerk, ook in het meest prille stadium.

De leden van de beoordelingscommissie: Geachte Prof.dr. C.M. ten Bruggenkate, Prof.dr. D.W. Grijjma en Prof.dr. M.A.W. Merkk. Ik ben u allen zeer erkentelijk dat u de tijd heeft genomen mijn proefschrift te beoordelen.

Prof.dr. L.G.M. de Bont, geachte professor. Bedankt voor de faciliteiten en de mogelijkheid die ik kreeg om het onderzoek uit te voeren op de afdeling Kaakchirurgie. Een goede werkplek en een prettige sfeer staan mijns inziens aan de basis van plezier in het werk. De afgelopen jaren heb ik dan ook met veel voldoening onderzoek gedaan.

Mw. Ing. M.B.M. van Leeuwen, beste Babs. Uren heb ik doorgebracht bij jou op het lab. We hebben heel wat verhitte discussies gevoerd; dikwijls bleek achteraf dat je dan toch weer gelijk had. Het proefschrift is er gekomen, mede ook doordat je me er op wees niet te veel van de 'snelweg' af te gaan. Je hebt me op een leuke manier wegwijs gemaakt in de histologie. Ik wil je bedanken voor al je hulp bij het gehele project.

Dhr. J.L. Ruben, beste Jan. Op een gegeven moment was ik het goed zat met het zagen van alle monsters. Ik ben daarom blij dat dit bij jou op het lab plaats vond. Jouw geestdrift, gezelligheid, humor en interesse maakten het werk meer dan dragelijk: het was een hele leuke periode. Bedankt voor je kennis, tips en hulp bij het vervaardigen en analyseren van de microradiografische en micro-CT beelden. Dankzij jou is het ons gelukt geweldig mooie afbeeldingen te 'photoshopen' voor de verschillende artikelen.

Dr. J.R. de Jong, beste Johan. Hartelijk dank voor alle tijd en energie die je gestoken hebt in je hulp bij het maken en interpreteren van micro-CT scans. Het was niet altijd even plezierig vertoeven in de kelder van het ziekenhuis, maar je gezelschap en je bevlogen verhalen over Linux en programmeren maken het een mooie tijd om op terug te kijken.

Drs. E.J. Hoogeveen, beste Eelke. In 2003 werden wij jaargenoten. We hebben allebei een voorliefde voor 'boardsports' dus de klik was er al snel. Ik ben erg blij dat jij mij hebt geholpen met het onderzoek. Je bent een

goede schrijver, zoals ook mag blijken uit een hoofdstuk in dit boekwerk. Daarnaast heb ik met heel veel plezier met je op het lab gewerkt. Je hebt me veel werk uit handen genomen, daarvoor ben ik je zeer erkentelijk.

Dr. T.G. van Kooten, beste Theo. Hartelijk dank voor je inbreng op het gebied van de histologie en je bijdrage aan in het bijzonder de startfase van mijn promotietraject.

Prof.dr. M.C.D.N.J.M. Huysmans, geachte professor, beste Marie-Charlotte. Ik wil je bedanken voor je kritische blik waarmee je een aantal van mijn artikelen hebt beoordeeld.

Prof.dr. A.M.J. Paans, geachte professor. Bedankt voor de medewerking van u en uw afdeling aan het project. Zonder het gebruik van de micro-CT was het onderzoek een stuk minder spannend geweest.

Dhr. J. de Vries, beste Joop. Zonder de door jouw ontwikkelde computerprogramma's had mijn onderzoek nog wel een jaartje langer geduurd. Hartelijk dank voor het automatiseren van de metingen en de gezelligheid tijdens de lunches.

Dr. J.J.R. Huddleston-Slater, beste James. Bedankt voor je hulp met de statistiek. Je bent wat mij betreft een enorme aanwinst voor de afdeling.

Beste Linda. In mijn geval kan je stellen: Zonder biomateriaal geen onderzoek. Jullie medewerking was daarom van onschatbare waarde. Ik wil jou, maar ook de rest van Polyganics, met in het bijzonder Johan Zuidema, bedanken voor jullie kennis, interesse en het altijd op tijd leveren van voldoende materiaal.

Beste Yvonne en Hans. Bedankt voor alle uren assistentie, humor en gezelligheid tijdens de operaties op het dierenlab. Arie en Flip, dank voor jullie medewerking en tips. Annet, Hester, Marcia en overige medewerkers van het CDL, ook jullie bedankt voor de samenwerking en goede sfeer.

Dames van de röntgen, beste Anja, Emmy, Niki, Tiny en

Yvonne. Met jullie hulp was het mogelijk om het centrum van de defecten en transplantaten te bepalen, onmisbaar bij de experimenten. Hartelijk dank voor jullie hulp.

Beste heren van de Instrumentmakerij. Zeer bedankt voor de mooie attributen die jullie voor de verschillende onderzoeken gemaakt hebben. Ik wil jullie in het bijzonder danken voor het vervaardigen van een spatplint voor mijn keuken. Ik heb er elke dag plezier van!

Beste Nienke, Lisa, Karin en Harrie, ik wil jullie heel erg bedanken voor de gezelligheid, jullie hulp en ondersteuning 'boven'.

Beste Geerten-Has en Jappe, mijn 'roomies'. Ik heb een (te)gezellige tijd gehad met jullie op de kamer. Frustratie, vreugde, roddels en grappen, het was er allemaal bij. Ik vind het jammer dat deze periode nu afgesloten is. Bedankt voor jullie steun. Ik wil jullie heel veel succes wensen met het afronden van jullie eigen onderzoek, de vervolgopleiding, carrière en eigen praktijk.

Beste Jiska, bedankt voor je hulp bij de proefdierexperimenten. Fijn dat je altijd paraat stond om in te vallen.

Beste onderzoekers, stafleden en collega's van 'beneden', bedankt voor alle goede en gezellige momenten, zeker ook op de vrijdagmiddag.

Beste jaar- en teamgenootjes van de opleiding Tandheelkunde, ik wil jullie bedanken voor de interesse voor het onderzoek, de tips and tricks, oude tentamens en borrels op de donderdagen.

Teamdocenten, drs. H. van Olm en drs. E. Hekman, beste Hans en Eddy, zeer bedankt voor de geweldige begeleiding op de kliniek. Jullie hebben me enorm geholpen de klinische fase zo efficiënt mogelijk te doorlopen zodat er voldoende tijd voor mijn promotieonderzoek overbleef.

Lieve Jolien en beste Harold. Het boekwerk ziet er echt prachtig uit. Enorm bedankt voor al het werk dat jullie me uit handen hebben genomen en de originaliteit waarmee jullie de layout en omslag hebben vormgegeven.

Beste Michiel. Wij kennen elkaar vanaf de beginperiode van de studie Geneeskunde. We hebben heel veel plezier gehad aan de Hereweg 61 en op vakanties, met elkaar, de rest van de huisgenootjes en gezamenlijke studievrienden. Ook in minder leuke tijden was jij er altijd voor een schouder of opbeurend gesprek. Ik heb grote bewondering voor je scherpe, analytische geest. Ik wil je heel hartelijk bedanken voor je vriendschap en ik ben blij dat jij vandaag één van mijn paranimfen wilt zijn.

Beste Christiaan. Jij werd mijn studiematje bij Tandheelkunde. Jut en Jul, beiden in het traject voor de opleiding tot kaakchirurg, beiden in hetzelfde schuitje. Veel geklaagd, maar tenminste evenveel gelachen. Ik ben enorm blij dat ik dit traject met jou heb kunnen doorlopen en dat we goed bevriend zijn geraakt. Bedankt voor je openheid en betrokkenheid. Ik vind het erg fijn dat jij mijn paranimf wilt zijn.

Lieve Hub, Annelies en Lieke. Verspreid over het land en toch heel dichtbij. Ik ben blij dat we zo'n goede band met elkaar hebben. Hub en Annelies, ik wil jullie bedanken voor alle kansen en vrijheden die jullie Lieke en mij gaven. Jullie hebben altijd enorm veel interesse getoond in onze werkzaamheden, hobbies en vrienden. Vooral mijn verrichtingen als student Tandheelkunde hebben jullie van dichtbij mogen beleven. Hub, je bent de trotse bezitter van de enige brug die ik ooit gemaakt zal hebben, wees er zuinig op! Annelies, je bent de beste moeder die ik me kan wensen en Lieke, ik hoop dat ik nu wat meer rust vind in de weekenden en dat we elkaar wat vaker zien.

Liefste Astrid. Het kan raar lopen tussen jaargenootjes. Ik ben blij dat wij elkaar na de studie niet uit het oog zijn verloren. Bedankt voor al je hulp, steun en geduld. Ik heb een geweldige tijd achter de rug met jou en ik hoop dat we nog een lange toekomst met elkaar in het verschiep hebben. Mijn boekje is af, jij heel veel succes met het afschrijven van dat van jou.

Pepijn Gielkens, juni 2008

Curriculum Vitae

Curriculum Vitae

The author was born on October 21st, 1977 in Kerkrade, The Netherlands. In 1996 he graduated at the 'Geert Groote College' (Gymnasium, pre-university education) in Deventer. The same year he started his medical education at the University of Groningen. In the winter months of 1999-2000 he worked as tour-guide in Val Thorens, a ski-resort in France. After receiving his medical degree in 2003 he started his research at the Department of Oral and Maxillofacial Surgery of the University Medical Center Groningen. This work was combined with his dental training (2003-2007) and with his work as a lecturer at the Department of Oral Hygiene of the 'Hanzehogeschool' in Groningen (2004-2007). In December 2007 he started his oral and maxillofacial residency at the Department of Oral and Maxillofacial Surgery, University Medical Center Groningen (head: Prof. dr. L.G.M. de Bont).

Address for Correspondence:

Pepijn Gielkens
Slachthuisstraat 27
9713 MA Groningen

Tel: +31 (0) 50 3613840

E-mail: p.f.m.gielkens@kchir.umcg.nl



