

University of Groningen

## Bile duct injury in liver transplantation

Dries, Sanna op den

**IMPORTANT NOTE: You are advised to consult the publisher's version (publisher's PDF) if you wish to cite from it. Please check the document version below.**

*Document Version*

Publisher's PDF, also known as Version of record

*Publication date:*

2013

[Link to publication in University of Groningen/UMCG research database](#)

*Citation for published version (APA):*

Dries, S. O. D. (2013). *Bile duct injury in liver transplantation: studies on etiology and the protective role of machine perfusion*. s.n.

### Copyright

Other than for strictly personal use, it is not permitted to download or to forward/distribute the text or part of it without the consent of the author(s) and/or copyright holder(s), unless the work is under an open content license (like Creative Commons).

The publication may also be distributed here under the terms of Article 25fa of the Dutch Copyright Act, indicated by the "Taverne" license. More information can be found on the University of Groningen website: <https://www.rug.nl/library/open-access/self-archiving-pure/taverne-amendment>.

### Take-down policy

If you believe that this document breaches copyright please contact us providing details, and we will remove access to the work immediately and investigate your claim.

Downloaded from the University of Groningen/UMCG research database (Pure): <http://www.rug.nl/research/portal>. For technical reasons the number of authors shown on this cover page is limited to 10 maximum.

# **Bile Duct Injury in Liver Transplantation**

**Studies on Etiology and the Protective Role of Machine Perfusion**

Sanna op den Dries

Different parts of this thesis were funded by the Groningen University Institute for Drug Exploration (GUIDE), Junior Scientific Masterclass (JSM), Ubbo Emmius Foundation / JSM Talent Grant, grants from the Jan Kornelis de Cock Foundation, the Tekke Huizinga Foundation, Innovatief Actieprogramma Groningen (IAG-3) and the Astellas Transplantatie Research Prijs 2013.

For the printing of this thesis, financial support of the following institutions and companies is gratefully acknowledged:

Op den Dries, S.

Bile duct injury in liver transplantation: Studies on etiology and the protective role of machine perfusion

Dissertation University of Groningen, The Netherlands

ISBN: 978-90-367-6446-9 (printed version)

ISBN: 978-90-367-6445-2 (electronic version)

© Copyright 2013 S. op den Dries, The Netherlands

All rights reserved. No part of this book may be reproduced, stored in a retrieval system or transmitted in any form or by any means, without the written permission of the author.

Cover design and photo: Brett McManus and Sanna op den Dries

Cover photo: Scanning Electron Microscopy (SEM) image of human bile duct epithelium.

Lay-out and Printed by: Gildeprint drukkerijen, Enschede, The Netherlands



rijksuniversiteit  
 groningen

## **Bile Duct Injury in Liver Transplantation**

### **Studies on Etiology and the Protective Role of Machine Perfusion**

Proefschrift

ter verkrijging van het doctoraat in de  
 Medische Wetenschappen  
 aan de Rijksuniversiteit Groningen  
 op gezag van de  
 Rector Magnificus, dr. E. Sterken,  
 in het openbaar te verdedigen op  
 woensdag 13 november 2013  
 om 16:15 uur

door

**Sanna op den Dries**

geboren op 29 april 1986  
 te Dongeradeel



Promotores: Prof. dr. R.J. Porte  
Prof. dr. J.A. Lisman

Beoordelingscommissie: Prof. dr. U. Beuers  
Prof. dr. E. Heineman  
Prof. dr. H.J. Verkade

Paranimfen:

Drs. Negin Karimian

Drs. Wieke G. Dalenberg

# INHOUDSOPGAVE

## Part A: The Scope of Bile Duct Injury in Liver Transplantation

- Chapter 1** General Introduction and Aims of This Thesis 9
- Chapter 2** Biliary Complications Following Liver Transplantation 17  
*In: Clavien PA, Trotter JF, editors. Medical Care of the Liver Transplant Patient. Wiley-Blackwell; 2012. p. 319-331.*
- Chapter 3** Protection of Bile Ducts in Liver Transplantation: Looking Beyond Ischemia 39  
*Transplantation 2011; 92: 373-379.*

## Part B: Immune- and Ischemia-mediated Etiologies of Bile Duct Injury

- Chapter 4** Combination of Primary Sclerosing Cholangitis and CCR5-Δ32 in Recipients is Strongly Associated with the Development of Non-anastomotic Biliary Strictures after Liver Transplantation 55  
*Liver Int 2011; 31: 1102-1109.*
- Chapter 5** The Origin of Biliary Strictures after Liver Transplantation: Is it the Amount of Epithelial Injury or Insufficient Regeneration that Counts? 71  
*Adapted from: J Hepatol 2013; 58: 1065-1067.*
- Chapter 6** Regeneration of Human Extrahepatic Biliary Epithelium: The Peribiliary Glands as Progenitor Cell Compartment 77  
*Liver Int 2012; 32: 554-559.*
- Chapter 7** Injury of Peribiliary Glands and Vascular Plexus before Liver Transplantation Predicts Formation of Non-anastomotic Biliary Strictures 89  
*Submitted for publication.*

## Part C: Machine Perfusion: A Potential Strategy to Prevent Bile Duct Injury

- Chapter 8** Hypothermic Oxygenated Machine Perfusion Prevents Arteriolonecrosis of the Peribiliary Plexus in Pig Livers Donated after Cardiac Death 109  
*Submitted for publication.*
- Chapter 9** Normothermic Machine Perfusion Reduces Bile Duct Injury and Improves Biliary Epithelial Function in Rat Donor Livers 127  
*Submitted for publication.*
- Chapter 10** Ex-vivo Normothermic Machine Perfusion and Viability Testing of Discarded Human Donor Livers 147  
*Am J Transplant. 2013; 13: 1327-1335.*
- Chapter 11** Criteria for Viability Assessment of Discarded Human Donor Livers during Ex-Vivo Normothermic Machine Perfusion 163  
*Submitted for publication.*

## Part D: Addendum

- Chapter 12** Shared Decision Making in Transplantation: How Patients See Their Role in the Decision Process of Accepting a Donor Liver 181  
*Submitted for publication.*
- Chapter 13** An Ex-Vivo Oxygenated Normothermic Machine Perfusion System for Rat Livers 197
- Chapter 14** Summary, Discussion and Future Perspectives 211
- Nederlandse samenvatting 225
- List of publications 239
- List of contributing authors 241
- Acknowledgements 247
- Biography 253
- List of abbreviations cover

# PART A

The Scope of Bile Duct Injury in Liver Transplantation



# CHAPTER 1

**General Introduction and Aims of This Thesis**

Liver transplantation has proven to be a successful treatment for patients with end stage chronic or acute liver failure. Due to improved surgical techniques, enhanced intensive care, and effective immunosuppressant medications, excellent one- and five-year patient (around 90% and 80%, respectively) and graft survival rates (around 85% and 75%, respectively) are currently achieved (1,2).

Nevertheless, liver transplant waiting lists are increasing more rapidly than the supply of donor organs, leaving many patients stranded without access to what is often a life-saving therapy. Efforts to increase the donor pool are being made by accepting more donors at the expense of diminished quality of their organs (i.e. extended criteria donors). An extended criteria donor (ECD) implies a higher donor-related risk in comparison with a standard criteria donor (SCD). This risk may manifest as increased incidence of postoperative complications, such as delayed graft function, graft failure, biliary complications or transmission of a donor-derived disease (3).

Despite the good overall survival data, biliary complications are a major problem after liver transplantation. The incidence of biliary complications varies between 10% and 40% in different studies and these types of complications are associated with frequent hospital admissions, and high morbidity and mortality rates (4-6). Among the various biliary complications that can occur after OLT, bile duct strictures are of the greatest concern. Bile duct strictures can be classified as anastomotic strictures (AS) or non-anastomotic strictures (NAS). Solitary strictures at the biliary anastomosis have been reported in 9%-12% of the patients (7-9), and NAS have been reported in 1%-13% of patients receiving a liver from donation after brain death (DBD) and in 21%-33% of patients receiving a liver from donation after cardiac death (DCD) (10-13). NAS may occur in the extrahepatic donor bile duct as well as the intrahepatic bile ducts, but they are usually limited to the larger bile ducts.

For many years researchers have been trying to understand the underlying mechanisms of AS and NAS. Current evidence suggests that AS are mainly related to the surgical technique and local ischemia of the distal bile duct stump, leading to fibrotic scarring of the anastomosis (4,9). The etiology of NAS is thought to be multifactorial and three relevant types of biliary injury have been identified as a potential cause of NAS: ischemia/reperfusion related injury; immune-mediated injury; and cytotoxic injury caused by hydrophobic bile salts (4,14). The etiologies of NAS are still poorly understood and therapeutic options are limited and often unsuccessful (15,16).

Despite the high numbers of patients on the waiting list for transplantation, many donor livers are still declined for transplantation for various reasons. According to the United Network for Organ Sharing (UNOS) database, 58.2% of the DCD livers (and 14.4% of livers donated after brain death [DBD]) with consent for donation are currently not accepted due to the perceived high risk of complications after transplantation (4). In order to expand the donor pool through utilization of these livers, research should focus on better defining the mechanism underlying NAS and on the development of effective preventive measures. Machine perfusion as an alternative to static cold storage (SCS) is increasingly discussed as a promising tool to optimize DCD and other ECD

livers before transplantation. However, there are no convincing data as to whether preservation related injury of the bile ducts prior to transplantation is a risk factor for the development of biliary complications after transplantation. Moreover, there are no studies on machine perfusion that have specifically addressed the question whether this preservation method provides better protection of the bile ducts, compared to SCS.

Therefore, the aim of this thesis was to gain a better understanding of the etiologies underlying NAS and to study the potential protective role of machine perfusion in the prevention of bile duct injury before transplantation. In addition, we provide an overview of the literature to understand the scope of the problem and the thesis concludes with a study on how to inform and involve patients in the decision to accept a liver with increased risk of bile duct complications.

### **Part A: The Scope of Bile Duct Injury in Liver Transplantation**

The aim of this section is to provide an overview of the literature in order to understand the scope of bile duct injury in liver transplantation. The different types of biliary complications that can occur after liver transplantation are discussed in **chapter 2**. Surgical aspects of bile duct reconstruction that are relevant for the development of biliary complications are covered, followed by a discussion of diagnostic and imaging methods and a description of the pathogenesis, clinical presentation, and management of the various types of biliary complications after liver transplantation.

**Chapter 3** focuses on the most prevalent and troublesome of all bile duct complications: non-anastomotic bile duct strictures (NAS). Current and emerging insight into the pathogenesis of NAS, including the lacunae in our current knowledge and potential targets to reduce biliary injury and preserve bile ducts are discussed in this chapter.

### **Part B: Immune and Ischemia-mediated Etiologies of Bile Duct Injury**

The aim of this section is to gain better understanding of the etiologies underlying NAS. Despite extensive research, the exact etiological mechanisms of NAS remain unclear and improved understanding of the pathophysiology of NAS may lead to the development of preventive or curative treatments. The aim of the clinical study described in **chapter 4** was to determine the role of the immune system in the development of NAS. NAS has been associated with various immunological processes, such as ABO-incompatible liver transplantation (17), pre-existing diseases with a presumed autoimmune component (18-20), cytomegalovirus infection (18,21) and chronic rejection (17). The exact role of the immune system in the pathogenesis of NAS, however, remains unclear. A loss-of-function mutation in the chemokine receptor CCR5 (CCR5- $\Delta$ 32) leads to changes in the immune system, including impaired chemotaxis of regulatory T-cells (22-24). To determine whether the immune system is involved in the pathogenesis of NAS we assessed the impact of the CCR5- $\Delta$ 32 mutation in liver donors and recipients on outcome, and the development of NAS after OLT.



The aim of **chapter 5** is to draw attention to the changing perspective on the pathogenesis of biliary strictures after liver transplantation. For decades it was assumed that only few biliary epithelial cells are damaged and lost during cold preservation and that most of the biliary injury occurs after transplantation during reperfusion injury. Two recently published studies provided new perspective from which to view biliary injuries and the development of strictures after transplantation (25,26). Subsequently, the new perspective on the pathogenesis of biliary strictures is now based on the insufficient regeneration of the biliary epithelium, resulting in the development of NAS.

It is conceivable that biliary epithelium of the extrahepatic bile duct has an endogenous regenerative capacity, which may be impaired when NAS develops after liver transplantation. The aim of **chapter 6** is to identify possible site(s) where epithelial regeneration may be initiated in the human extrahepatic bile duct and to study the possible role of proliferation of mature biliary epithelial cells as well as that of local progenitor cells in this process. We examined tissue specimens from normal and diseased human EHBD varying from mild cellular injury (as in cholangitis/cholecystitis) to severe epithelial injury with cholangiocyte loss, as can be seen in NAS after orthotopic liver transplantation.

In **chapter 6** the peribiliary glands of large bile ducts were identified as a local niche of biliary progenitor cells that contribute to regeneration of the biliary epithelial lining after major injury. However, it is unknown whether injury or loss of the peribiliary glands is a risk factor for the development of NAS after transplantation. In **chapter 7** we examined biopsies taken during 128 liver transplant procedures, taken from the distal end of the extrahepatic bile duct. Slides were examined by light microscopy, using a systematic injury grading system. Special attention was paid to the peribiliary glands and peribiliary vasculature. The aim of this study was to determine the impact of injury to the peribiliary glands and the vasculature in the development of NAS.

### **Part C: Machine Perfusion: A Potential Strategy to Prevent Bile Duct Injury**

The aim of this section is to study the potentially protective effect of machine perfusion on the development of bile duct injury, and to demonstrate feasibility of machine perfusion in human livers. Machine perfusion is increasingly discussed as a promising tool to optimize DCD and other ECD livers before transplantation. During machine preservation livers are perfused with an oxygenated or non-oxygenated perfusion fluid at either low temperature or normal body temperature (27-31).

Thus far, most investigations have focused on hypothermic machine perfusion (HMP; 0-4°C) and studies have suggested that HMP results in better preservation of the liver parenchyma, compared to the classical method of organ preservation, static cold storage (SCS) (29-31). However, it is unknown whether hypothermic oxygenated machine perfusion results in better preservation of

biliary epithelium and the peribiliary vasculature. Therefore, the aim of **chapter 8** is to study bile duct injury and morphology in a porcine DCD model, comparing oxygenated HMP with SCS.

Although hypothermic perfusion has achieved adequate results in near-clinical and clinical setting (27,32), its use seems to offer too little protection in suboptimal grafts (33,34). Moreover, HMP in porcine livers did not provide protection of the bile duct epithelium, when compared to SCS in a porcine DCD model (chapter 8). Normothermic machine perfusion (NMP) of donor livers offers potential to meet the higher requirements for DCD graft preservation. An important advantage of NMP over conventional static cold storage (SCS) is the delivery of oxygen and nutrients at 37°C, providing full metabolic support. The aim of **chapter 9** is to determine the impact of NMP on bile duct preservation in both DCD and non-DCD rat livers.

Although normothermic machine perfusion may provide better viability testing and resuscitation, it requires challenging, near-physiological conditions (35). To date, successful normothermic perfusion of livers has been reported only in animal models (36-40). Although these results are promising, feasibility of normothermic machine perfusion in human livers remains to be demonstrated. In **chapter 10** we studied the feasibility of normothermic, oxygenated machine preservation and *ex vivo* viability testing of discarded human ECD livers, using a newly developed liver perfusion machine. In order to move forward to clinical use of machine perfusion, it is necessary to identify markers during machine perfusion that can predict liver function after transplantation. In **chapter 11** we aimed to identify markers as early as possible during the course of machine perfusion that would allow us to predict liver function after 6 hours of NMP, as a first step towards using machine perfusion in a clinical setting.

#### **Part D: Addendum**

DCD and other ECD donor grafts are increasingly used for transplantation, resulting in an increased risk of bile duct complications after transplantation. At the time of organ offer for transplantation, donor-related risks such as disease transmission and graft failure are weighed against the patient's risk of remaining on the waiting list. The patient's role in decision-making, as well as the timing and extent of donor-specific risk information, has been discussed in the medical literature. However, there is very little data on how patients themselves see their role in making these complicated decisions. In **chapter 12** we describe the first study revealing the opinion of liver patients on these issues. Forty patients listed for liver transplantation and 179 transplanted liver patients participated in an anonymous questionnaire-based survey. The aim of this chapter is to investigate how to inform and involve patients in the decision on whether or not to accept a liver with an increased risk of complications.

The aim of **chapter 13** is to describe the details of a new pressure and temperature controlled dual perfusion system that we have developed to perfuse rat livers for the study described in chapter 9. In **chapter 14** the results of this thesis are summarized, followed by a general discussion and future perspectives.

## REFERENCES

- (1) OPTN/SRTR. UNOS Annual Data Report. 2011.
- (2) Eurotransplant Annual Report. 2011.
- (3) Durand F, Renz JF, Alkofer B, Burra P, Clavien PA, Porte RJ, et al. Report of the Paris consensus meeting on expanded criteria donors in liver transplantation. *Liver Transpl* 2008;14:1694-1707.
- (4) Op den Dries S, Sutton ME, Lisman T, Porte RJ. Protection of bile ducts in liver transplantation: looking beyond ischemia. *Transplantation* 2011;92:373-379.
- (5) Buck DG, Zajko AB. Biliary complications after orthotopic liver transplantation. *Tech Vasc Interv Radiol* 2008;11:51-59.
- (6) Verdonk RC, Buis CI, Porte RJ, Haagsma EB. Biliary complications after liver transplantation: a review. *Scand J Gastroenterol Suppl* 2006;89-101.
- (7) Gastaca M. Biliary complications after orthotopic liver transplantation: a review of incidence and risk factors. *Transplant Proc* 2012;44:1545-1549.
- (8) Verdonk RC, Buis CI, Porte RJ, van der Jagt EJ, Limburg AJ, van den Berg AP, et al. Anastomotic biliary strictures after liver transplantation: causes and consequences. *Liver Transpl* 2006;12:726-735.
- (9) Jagannath S, Kalloo AN. Biliary Complications After Liver Transplantation. *Curr Treat Options Gastroenterol* 2002;5:101-112.
- (10) Meurisse N, Vanden Bussche S, Jochmans I, Francois J, Desschans B, Laleman W, et al. Outcomes of liver transplantations using donations after circulatory death: a single-center experience. *Transplant Proc* 2012;44:2868-2873.
- (11) Pine JK, Aldouri A, Young AL, Davies MH, Attia M, Toogood GJ, et al. Liver transplantation following donation after cardiac death: an analysis using matched pairs. *Liver Transpl* 2009;15:1072-1082.
- (12) Suarez F, Otero A, Solla M, Arnal F, Lorenzo MJ, Marini M, et al. Biliary complications after liver transplantation from maastricht category-2 non-heart-beating donors. *Transplantation* 2008;85:9-14.
- (13) Dubbeld J, Hoekstra H, Farid W, Ringers J, Porte RJ, Metselaar HJ, et al. Similar liver transplantation survival with selected cardiac death donors and brain death donors. *Br J Surg* 2010;97:744-753.
- (14) Buis CI, Hoekstra H, Verdonk RC, Porte RJ. Causes and consequences of ischemic-type biliary lesions after liver transplantation. *J Hepatobiliary Pancreat Surg* 2006;13:517-524.
- (15) Sharma S, Gurakar A, Jabbour N. Biliary strictures following liver transplantation: past, present and preventive strategies. *Liver Transpl* 2008;14:759-769.
- (16) Verdonk RC, Buis CI, van der Jagt EJ, Gouw AS, Limburg AJ, Slooff MJ, et al. Nonanastomotic biliary strictures after liver transplantation, part 2: Management, outcome, and risk factors for disease progression. *Liver Transpl* 2007;13:725-732.
- (17) Rull R, Garcia Valdecasas JC, Grande L, Fuster J, Lacy AM, Gonzalez FX, et al. Intrahepatic biliary lesions after orthotopic liver transplantation. *Transpl Int* 2001;14:129-134.

- (18) Hoekstra H, Buis CI, Verdonk RC, van der Hilst CS, van der Jagt EJ, Haagsma EB, et al. Is Roux-en-Y choledochojejunostomy an independent risk factor for nonanastomotic biliary strictures after liver transplantation? *Liver Transpl* 2009;15:924-930.
- (19) Feller RB, Waugh RC, Selby WS, Dolan PM, Sheil AG, McCaughan GW. Biliary strictures after liver transplantation: clinical picture, correlates and outcomes. *J Gastroenterol Hepatol* 1996;11:21-25.
- (20) Guichelaar MM, Benson JT, Malinchoc M, Krom RA, Wiesner RH, Charlton MR. Risk factors for and clinical course of non-anastomotic biliary strictures after liver transplantation. *Am J Transplant* 2003;3:885-890.
- (21) Halme L, Hockerstedt K, Lautenschlager I. Cytomegalovirus infection and development of biliary complications after liver transplantation. *Transplantation* 2003;75:1853-1858.
- (22) Wysocki CA, Jiang Q, Panoskaltis-Mortari A, Taylor PA, McKinnon KP, Su L, et al. Critical role for CCR5 in the function of donor CD4+CD25+ regulatory T cells during acute graft-versus-host disease. *Blood* 2005;106:3300-3307.
- (23) Nozaki T, Rosenblum JM, Schenk AD, Ishii D, Fairchild RL. CCR5 is required for regulation of alloreactive T-cell responses to single class II MHC-mismatched murine cardiac grafts. *Am J Transplant* 2009;9:2251-2261.
- (24) Dobaczewski M, Xia Y, Bujak M, Gonzalez-Quesada C, Frangogiannis NG. CCR5 signaling suppresses inflammation and reduces adverse remodeling of the infarcted heart, mediating recruitment of regulatory T cells. *Am J Pathol* 2010;176:2177-2187.
- (25) Brunner SM, Junger H, Ruemmele P, Schnitzbauer AA, Doenecke A, Kirchner GI, et al. Bile duct damage after cold storage of deceased donor livers predicts biliary complications after liver transplantation. *J Hepatol* 2013;58:1133-1139.
- (26) Hansen T, Hollemann D, Pitton MB, Heise M, Hoppe-Lotichius M, Schuchmann M, et al. Histological examination and evaluation of donor bile ducts received during orthotopic liver transplantation--a morphological clue to ischemic-type biliary lesion? *Virchows Arch* 2012;461:41-48.
- (27) Guarrera JV, Henry SD, Samstein B, Odeh-Ramadan R, Kinkhabwala M, Goldstein MJ, et al. Hypothermic machine preservation in human liver transplantation: the first clinical series. *Am J Transplant* 2010;10(2):372-381.
- (28) Op den Dries S, Karimian N, Sutton ME, Westerkamp AC, Nijsten MW, Gouw AS, et al. Ex vivo normothermic machine perfusion and viability testing of discarded human donor livers. *Am J Transplant* 2013;13:1327-1335.
- (29) Bae C, Henry SD, Guarrera JV. Is extracorporeal hypothermic machine perfusion of the liver better than the 'good old icebox'? *Curr Opin Organ Transplant* 2012;17:137-142.
- (30) Dutkowski P, de Rougemont O, Clavien PA. Machine perfusion for 'marginal' liver grafts. *Am J Transplant* 2008;8:917-924.
- (31) Schlegel A, Rougemont O, Graf R, Clavien PA, Dutkowski P. Protective mechanisms of end-ischemic cold machine perfusion in DCD liver grafts. *J Hepatol* 2013;58:278-286.

- (32) Monbaliu D, Liu Q, Libbrecht L, De Vos R, Vekemans K, Debbaut C, et al. Preserving the morphology and evaluating the quality of liver grafts by hypothermic machine perfusion: a proof-of-concept study using discarded human livers. *Liver Transpl* 2012;18:1495-1507.
- (33) Fondevila C, Hessheimer AJ, Maathuis MH, Munoz J, Taura P, Calatayud D, et al. Hypothermic oxygenated machine perfusion in porcine donation after circulatory determination of death liver transplant. *Transplantation* 2012;94:22-29.
- (34) Hessheimer AJ, Fondevila C, Garcia-Valdecasas JC. Extracorporeal machine liver perfusion: are we warming up? *Curr Opin Organ Transplant* 2012;17:143-147.
- (35) Monbaliu D, Brassil J. Machine perfusion of the liver: past, present and future. *Curr Opin Organ Transplant* 2010;15:160-166.
- (36) Vogel T, Brockmann JG, Friend PJ. Ex-vivo normothermic liver perfusion: an update. *Curr Opin Organ Transplant* 2010;15:167-172.
- (37) Brockmann J, Reddy S, Coussios C, Pigott D, Guirriero D, Hughes D, et al. Normothermic perfusion: a new paradigm for organ preservation. *Ann Surg*. 2009;250(1):1-6.
- (38) St Peter SD, Imber CJ, Lopez I, Hughes D, Friend PJ. Extended preservation of non-heart-beating donor livers with normothermic machine perfusion. *Br J Surg* 2002;89:609-616.
- (39) Xu H, Berendsen T, Kim K, Soto-Gutierrez A, Bertheium F, Yarmush ML, et al. Excorporeal normothermic machine perfusion resuscitates pig DCD livers with extended warm ischemia. *J Surg Res* 2012;173:e83-8.
- (40) Schon MR, Kollmar O, Wolf S, Schrem H, Matthes M, Akkoc N, et al. Liver transplantation after organ preservation with normothermic extracorporeal perfusion. *Ann Surg* 2001;233:114-123.



# CHAPTER 2

## **Biliary Complications Following Liver Transplantation**

Op den Dries S, Verdonk RC, Porte RJ.

*In: Clavien PA, Trotter JF, editors. Medical Care of the Liver Transplant Patient. Wiley-Blackwell; 2012. p. 319-331.*

## **ABSTRACT**

Biliary complications are a major cause of morbidity and graft failure after liver transplantation. Advances in surgical techniques and preservation methods during the last decades have led to better results, but biliary complications still occur in 10-40% of the recipients and are associated with mortality rates of 8-15%. The use of livers from extended criteria donors is inevitable in the attempt to scale down the worldwide shortage of organs for transplantation, but these organs carry an increased risk of developing complications of the biliary system. The same is true for liver grafts from living donors. Of all biliary complications, bile duct strictures and bile leakage are most common after liver transplantation. This chapter discusses the pathogenesis, epidemiology and management of these and other less frequently occurring biliary complications.



## INTRODUCTION

Biliary complications are a major cause of morbidity and graft failure after liver transplantation. Although advances in the surgical technique of liver transplantation have led to a better overall outcome and fewer surgical complications, biliary complications still occur in 10-40% of the recipients and are associated with mortality rates of 8-15% (1,2). The continuing high biliary complication rate in liver transplantation can at least partially be explained by the increasing diversity of liver grafts used for transplantation in recent years. Besides livers derived from donation after brain death (DBD) donors, livers from DCD donors (donation after cardiac death) are increasingly used for transplantation, and these grafts are associated with a higher risk of biliary complications (3). The use of these and other extended-criteria donor livers, however, is inevitable in an attempt to scale down the worldwide shortage of organs. In order to expand the pool of potential donors, split-liver transplantation and living donors have also evolved as surgical alternatives and numbers have increased in recent years, providing particularly young children opportunity to receive a graft in time. In western countries, both split- and living- donor transplantation currently account for about 10% of all liver transplantations, although there are large variations among countries. Some countries in Asia might even reach a living donor liver transplantation rate of almost 100%. Yet, both surgical variants of liver transplantation carry an increased risk of biliary complications. Diversity in the quality and type of transplanted organs, variations in recipient risk factors, and variations in the applied surgical technique lead to a diversity in biliary complications that may occur after liver transplantation.

Of all biliary complications, bile leaks and bile duct strictures (anastomotic or non-anastomotic) are the most common types. These and other less frequent biliary complications are summarized in **Table 1** and will be discussed in this chapter. First, surgical aspects of bile duct reconstruction that are relevant for the development of biliary complications will be covered, followed by a discussion of diagnostic and imaging methods and a description of the pathogenesis, clinical presentation, and management of the various types of biliary complications after liver transplantation.



**Table 1.** Biliary complications after liver transplantation

Ischemic biliary complications due to hepatic artery thrombosis or stenosis
– Stricture
– Leak
– Bile collection (biloma)
– Biliary abscess
Technical biliary complications
– Anastomotic stricture
– Anastomotic leak
– T-tube related
– Parenchymal cut surface leak <sup>1</sup>
– Kinking of redundant bile duct
– External compression (cystic duct mucocele or hepatic lymphoma)
Ischemic-type biliary lesions / non-anastomotic strictures
– Ischemia-reperfusion injury
– Immune-mediated injury
– Bile salt cytotoxic injury
Infectious biliary complications / cholangitis
Uncommon biliary complications
– Sphincter of Oddi dysfunction
– Biliary stones, sludge, and casts

<sup>1</sup> *Living donor or split liver grafts*

## SURGICAL TECHNIQUE IN RELATION TO BILIARY COMPLICATIONS

### Biliary Reconstruction

The two main types of biliary reconstruction used in liver transplantation nowadays are 1) choledochocholedochostomy, also called the duct-to-duct anastomosis (using either an end-to-end anastomosis or a side-to-side anastomosis), and 2) a hepatico-jejunostomy using a Roux-Y jejunal loop. The use of one type of reconstruction instead of the other largely depends on the anatomical situation of the recipient's extrahepatic bile ducts and sometimes the surgical preference.

In case of a duct-to-duct choledochocholedochostomy, an anastomosis is created between donor and recipient choledochal ducts (common bile duct). An end-to-end anastomosis is generally easier to perform than a side-to-side anastomosis, and the former is therefore used more frequently. In a prospective, randomized trial comparing end-to-end anastomosis with side-to-side anastomosis, no major differences in outcome between the two techniques were found (4). An end-to-end reconstruction restores the physiologic anatomical situation and does not carry the risk of bile sludge or cast formation as can occur in the dead ends of a side-to-side anastomosis.

In case of a Roux-Y hepatico-jejunostomy, an end-to-side anastomosis is constructed between the donor hepatic duct and a Roux-Y jejunal loop created in the recipient. Roux-Y hepatico-jejunostomy is mainly used in patients whose native extrahepatic bile duct is not suitable for

anastomosis with the bile duct of the donor liver. The main indications for using a Roux-Y loop for biliary reconstruction are primary sclerosing cholangitis with involvement of the extrahepatic bile duct, biliary atresia, significant size discrepancy between the donor and recipient choledochal duct, and retransplantation (1,2). Although a hepatico-jejunostomy may be a safe alternative when duct-to-duct anastomosis is not feasible, the disadvantage is that it creates an open connection between the intrahepatic bile ducts of the graft and the bowel lumen. This may result in reflux of small bowel content into the bile ducts and subsequently ascending bacterial migration and (recurrent) cholangitis. Additional advantage of using a choledochocholedochostomy is easier access for diagnostics and therapy compared with a Roux-Y hepatico-jejunostomy. It is, therefore, generally agreed that the preferred method of biliary reconstruction in liver transplantation should be a choledochocholedochostomy whenever possible.

Few centers have advocated and reported on the use of a direct connection between the donor bile duct and the recipient duodenum (so called choledochoduodenostomy) as a safe alternative to a hepatico-jejunostomy (5).

### **The Use of a Biliary Drain**

When reconstructing the biliary system in a liver transplant recipient, this can be done either with or without the insertion of a biliary drain. A biliary drain can be either a T-tube or a straight (open tip) catheter. A T-tube is a flexible tube that is inserted in the choledochal duct in the proximity of the end-to-end anastomosis in case of a choledochocholedochostomy. This tube allows the bile to drain in two directions; towards the duodenum and outward of the body. Alternatively, a straight catheter can be used, with the advantage of a lower risk of bile leakage upon removal of the drain as it results in smaller hole in the bile duct after extraction.

Choledochocholedochostomy reconstructions over T-tubes have been the subject of controversy for many years, but it has nevertheless remained common practice in some transplant centers. Yet, with increasing surgical experience, many centers have begun to abandon the routine use of biliary drains in their liver transplant recipients (6,7).

Benefits of using a biliary drain include direct visual evaluation of the quality of bile produced by the recently implanted graft and easy access to the biliary tree for radiological imaging. Especially in liver grafts that contain a higher risk of developing biliary complications (e.g. livers from DCD donors) this could be an advantage. Some studies have suggested that placement of a T-tube may reduce the incidence of anastomotic strictures (8). In addition, a T-tube may result in adequate decompression of the biliary tree and a reduction of the intraductal pressure, which may subsequently contribute to a lower rate of intrahepatic biliary strictures and leakage.

The main drawback of using T-tubes is their association with an increased rate of biliary complications, especially bile leakage at the site of the drain insertion after its removal occurring in 5-15% of patients (1). In addition, the use of a T-tube increases the risk of ascending cholangitis and peritonitis, due to an open connection of the choledochal duct with the exterior. In a recent

systematic review and meta-analysis of studies focusing on the use of biliary drains in liver transplantation it was concluded that biliary drains such as T-tubes should be abandoned (6). Although this meta-analysis showed lower rates of anastomotic and non-anastomotic strictures in patients with a T-tube, the incidence of interventions was not diminished in comparison to patients without a T-tube. Patients without a T-tube had fewer episodes of cholangitis and fewer episodes of peritonitis. Yet, patients with or without a T-tube had equivalent outcomes with respect to anastomotic bile leaks or fistulas, the need for biliary interventions, incidence of hepatic artery thrombosis, retransplantation rate, and mortality due to biliary complications. The use of alternative devices, like internal stents, have been reported by some centers, but these stents have been associated with increased rates of serious complications, including obstruction, migration, and erosion with hemobilia (9).

The use of biliary drains such as a T-tube in liver transplant recipients, therefore, remains controversial. Probably the only remaining argument to use a T-tube is to allow accurate monitoring and easy access to the biliary tree in liver grafts that carry an increased risk of biliary complications, such as livers from DCD donors.

### **Relevance of the Donor / Back Table Procedure**

Efforts to minimize the risk of biliary complications after liver transplantation should start with proper surgical and preservation techniques during the donor procedure. Aspects of liver procurement and preservation which have been demonstrated to reduce the risk of biliary complications include: 1) efforts to minimize ischemic injury of the bile ducts, 2) preservation of the vasculature of the extrahepatic bile duct by avoiding dissection too close to the bile duct, 3) thorough rinsing of the bile duct lumen to remove toxic bile, and 4) adequate arterial perfusion of the liver with preservation fluid to preserve the peribiliary capillary plexus. These aspects are relevant as biliary epithelial cells (cholangiocytes) are very sensitive to ischemia/reperfusion injury (10). In addition to primary preservation-related ischemic injury, ischemic damage of the peribiliary plexus will result in secondary ischemic injury of the biliary epithelium. The strong relationship between ischemia and bile duct injury is illustrated by studies demonstrating an association between both cold and warm ischemia time and the development of non-anastomotic strictures (NAS). As long as the cold ischemia time is kept below 10 h, the incidence of NAS is not increased, however more prolonged cold ischemia is clearly associated with a higher risk of such strictures (11-13). Warm ischemia time, on the other hand, has been identified as a risk factor in several studies. The relevance of warm ischemia is also illustrated by the high incidence of NAS after transplantation of livers from DCD donors, which suffer an inevitable period of warm ischemia prior to organ procurement (13,14).

During organ procurement, surgeons should avoid "stripping" of the extrahepatic bile duct, which will damage its microvascularization. The extrahepatic bile duct should always remain surrounded by adequate amount of tissue to ensure sufficient blood supply.

Preservation injury results in increased arterial resistance and may cause circulatory disturbances in small capillaries, such as the biliary plexus. Since the blood supply to the biliary tract is solely dependant on arterial inflow, disturbances in the blood flow through the peribiliary plexus may result in insufficient oxygenation and subsequent damage of the biliary epithelium.

Gentle retrograde flushing of the bile ducts with preservation fluid is considered an important method to remove bile from the bile duct lumen. Bile contains bile salts, which are cytotoxic due to their detergent properties. Several studies have shown that bile salts may contribute to toxic damage of the biliary epithelium both during liver preservation and after liver transplantation (15,16).

University of Wisconsin (UW) solution has been recognized as the gold standard preservation solution (17). Although some studies have suggested that highly viscous preservation solutions such as the UW solution may result in an incomplete flush out of the small donor peribiliary arterial plexus, resulting in a higher incidence of NAS (11,18), this could not always be confirmed in other studies (17). Therefore, it remains debatable whether low viscosity preservation fluids are associated with a lower incidence of biliary complications. Adequately powered randomized, controlled trials with long-term follow up are needed to determine whether the type of preservation fluid has an impact on biliary complications after liver transplantation.

One method to overcome inadequate flush-out and preservation of the peribiliary plexus is the application of high pressure arterial infusion of preservation fluid either *in vivo* during procurement or immediately afterwards on the back table. Several studies have shown that additional flushing of the peribiliary plexus by controlled arterial back-table pressure perfusion may result in a considerable reduction in the incidence of NAS (19).

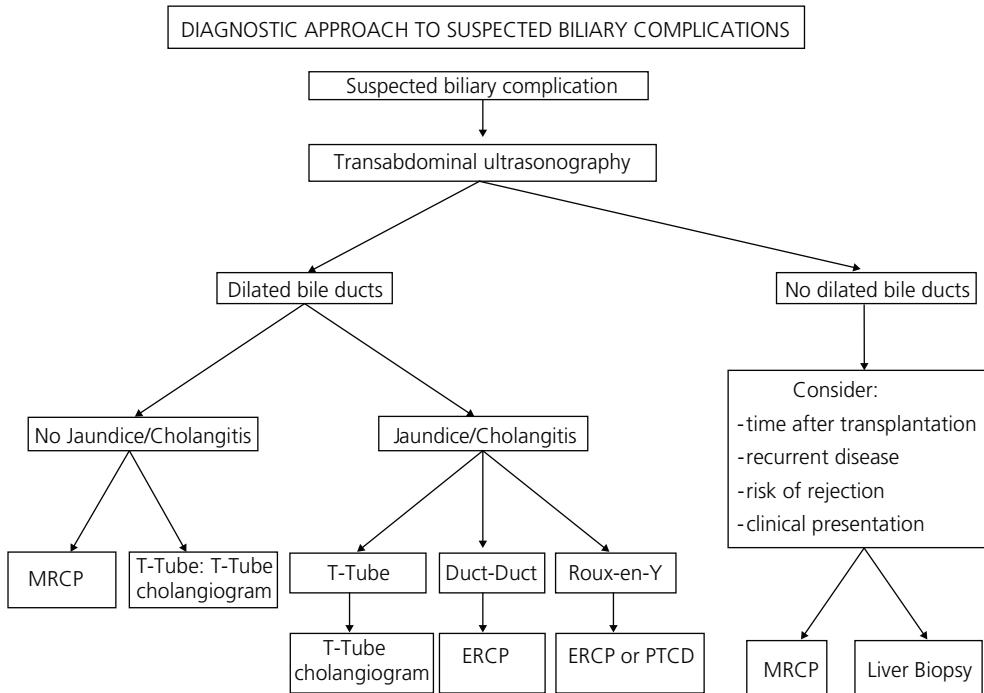
Better flush out and preservation of the peribiliary capillary plexus may also be achieved by machine preservation. Although machine preservation of organs for transplantation is receiving increasing attention and is subject of intensive research, it remains to be established whether this technique will result in a reduction of biliary complications after liver transplantation.

## DIAGNOSTIC MODALITIES

In most cases, the suspicion of a biliary complication will arise after an increase in liver enzymes is noted. There is no specific pattern to reliably distinguish a biliary complication from other causes of graft dysfunction, although an increase in serum bilirubin, alkaline phosphatase and/or gamma-glutamyl transferase has been suggested to be most specific. Alternatively, patients can present with upper abdominal pain or bacterial cholangitis. In many instances of liver enzyme disturbances, a liver biopsy will be performed after gross biliary congestion and bile duct dilatation have been excluded by ultrasonography. The presence of specific pathological features such as centrilobular cholestasis and portal changes including edema, predominantly neutrophil polymorph infiltration, ductular proliferation and cholangiolitis may be indicative of the presence

of a biliary complication (20). These findings, however, are not very specific and can be absent. In addition, biopsy findings are not informative with regard to the type and severity of biliary abnormalities.

The diagnostic work-up of an increase in liver enzymes will always depend on clinical context such as primary disease, time after transplantation, local experience and information on the biliary anatomy. A general algorithm is provided in **Figure 1**.



**Figure 1.** Schematic presentation of the clinical decisions and diagnostic steps in the work-up of a liver transplant recipient with a suspected biliary complication.

### Transabdominal Ultrasonography

Transabdominal ultrasonography is a useful primary diagnostic tool when a biliary complication is suspected. Allograft vascularization can be assessed (especially patency of the hepatic artery), fluid collections can be identified, the liver parenchyma can be studied, and dilatation of bile ducts can be identified. It should be noted that the transplanted liver behaves differently from a normal liver, in that the biliary system does not dilate as easily in the presence of a biliary obstruction as in normal livers (21). This leads to a limited sensitivity of approximately 60% of transabdominal ultrasonography to detect biliary strictures (21,22). The predictive value of transabdominal ultrasonography to detect non-anastomotic biliary strictures is rather low.

Therefore, normal ultrasonography of the liver graft in a patient with clinical or biochemical evidence of biliary pathology warrants further investigation.

### **Magnetic Resonance Cholangiography and Computed Tomography**

Magnetic resonance cholangiography (MRC) is a rapidly emerging diagnostic tool for the detection of biliary abnormalities. It has the strong advantage of providing excellent anatomical information without being invasive. In the present era, every transplant centre should be able to offer MRC and have an expert radiologist in the transplant team. MRC is useful in the detection of both leakages and strictures. Also, the use of an additional magnetic resonance imaging or magnetic resonance angiography scanning protocol can provide information about the liver parenchyma and vasculature. The reported sensitivity and specificity of MRC for the detection of biliary complications is well over 90% (23). After ultrasonography, MRC is the diagnostic tool of choice when a biliary complication is suspected. Recently, also computed tomography (CT) scanning has been suggested to be of value for the detection of post-transplant biliary complications – it has a higher spatial resolution compared to MRC. However, the experience with CT cholangiography after liver transplantation is very limited: 1) it can only be performed using a contrast medium, 2) it is associated with significant radiation, and 3) it is less reliable in the presence of biliary obstruction or high serum bilirubin levels. The use of CT cholangiography to detect a biliary complication should still be considered experimental.

### **Direct Cholangiography**

Direct cholangiography, either percutaneously or through endoscopic retrograde cholangio-pancreaticography (ERCP), is the gold standard for the detection of biliary abnormalities. It has the inherent advantage of biliary access to facilitate therapeutic measures. Since the use of a biliary drain (e.g. T-tube) is no longer routine practice in most transplant centers, ERCP will be the most frequently used method to detect biliary complications. There are no data to suggest that ERCP after liver transplantation is associated with more complications than the use of ERCP in the general population. Considering the safety, diagnostic yield, and therapeutic potential of ERCP, this should be considered the invasive method of choice. In the presence of altered biliary anatomy, such as a Roux-Y hepatico-jejunostomy, ERCP is more difficult to perform. In these cases, percutaneous transhepatic cholangiography (PTC) or PTC drainage is a good alternative method to obtain adequate imaging of the bile ducts. However, in several series successful ERCP in the presence of a Roux-Y reconstruction has been reported using either a normal duodenoscope or double-balloon endoscopes (24,25). PTC is most easily obtained in the presence of dilated bile ducts. In experienced hands, however, this can be a safe procedure also with undilated bile ducts (26). It not only allows adequate imaging of the bile ducts, but also provides access for therapeutic interventions such as balloon dilatation (see below).

### **Hepatobiliary Scintigraphy**

Hepatobiliary scintigraphy can be used as a diagnostic tool to detect post-transplant biliary obstruction and leakage. It has a sensitivity of approximately 60% for these indications (27). The main advantage is its noninvasive nature; its main disadvantage is low resolution and lack of direct visualization of the biliary anatomy. The sensitivity of hepatobiliary scintigraphy to detect NAS is not known. With the increasing use and availability of MRC, scintigraphy is nowadays rarely used to detect biliary strictures. It could be of value in those patients in whom an obstruction at the level of the Roux-Y jejunal loop is suspected or when MRC is not possible (i.e. presence of a pacemaker).

### **Other Diagnostic Tools**

Endoscopic ultrasonography is an emerging tool for the detection of hepatobiliary diseases. It has excellent diagnostic properties for the distal bile duct. Endoscopic intraductal ultrasonography can be used for the characterization of intraductal abnormalities. Use of these techniques in liver transplant recipients is still anecdotal. A potentially more valuable tool is direct cholangioscopy. With this technique, a small endoscope (cholangioscope) can be advanced through a normal duodenoscope to directly visualize the bile ducts. This can provide information about the biliary epithelium and the presence of stones, sludge and strictures. It can also be a therapeutic tool to advance guide wires or to remove bile duct stones. The number of indications for these highly specialized techniques, however, is still limited.

## **PATHOGENESIS, CLINICAL PRESENTATION AND MANAGEMENT**

The most common types of biliary complication after liver transplantation are bile duct strictures and bile leaks. Strictures at the site of the bile duct anastomosis are often referred to as “anastomotic strictures” (AS). Strictures occurring at any other location in the biliary tree of the liver are called “non-anastomotic strictures” (NAS).

### **Anastomotic Strictures: Pathogenesis and Clinical Presentation**

Isolated strictures at the site of the bile duct anastomosis, so called anastomotic strictures, are reported in 4-9% of the patients after liver transplantation (28). In general, anastomotic strictures do not remain subclinical and are detected after the occurrence of cholestatic laboratory liver function tests, jaundice or cholangitis (28). Anastomotic strictures are thought to result mainly from surgical technique and/or local ischemia, leading to fibrotic scarring of the anastomosis. Surgical factors include inadequate mucosa-to-mucosa adaptation at the anastomosis and damage of microvascularization due to dissection too close to the bile duct (29). To minimize the risk of local ischemia at the distal end of the donor choledochal duct, the bile duct should therefore remain surrounded by an adequate amount of tissue. Generalized hepatic ischemia due

to hepatic artery thrombosis can also result in anastomotic stricturing. Other risk factors for the development of anastomotic structures are anastomotic bile leakage after transplantation and a sex mismatch between donor and recipient (28,30).

Liver transplantation using a split graft or a liver derived from a living donor is associated with a higher risk of developing an anastomotic bile duct stricture, because of the frequent discrepancy between the diameter of the hepatic duct of the graft and choledochal duct in the recipient. In addition, vascularization of the hepatic duct can be compromised when a partial graft is derived from a living donor or split liver.

### **Anastomotic Strictures: Management**

The most frequently used therapeutic approach to an anastomotic stricture is endoscopic balloon dilatation and stenting of the stenosis. This treatment has been widely studied and is both safe and effective. Technical success is obtained in 90-100%, and long-term resolution of the stricture in 70-100% of cases (31). Although disputed by some, most centers have best results with a protocol of progressive stenting every 8-12 weeks with increasing numbers and diameters of stents until resolution of the stenosis is obtained (32). In some cases, the stenosis recurs despite effective initial therapy. Some centers have used a covered expandable metal stent to treat a refractory biliary stenosis after transplantation. This, however, is not routine practice. Presentation of an anastomotic stricture more than 6 months after transplantation and previous bile leakage at the site of the anastomosis are risk factors for difficult to manage strictures (28). When an anastomotic stenosis does not respond to repeated dilatation and stenting, surgical revision or conversion to a Roux-en-Y hepatico-jejunostomy anastomosis is a good alternative with excellent long-term success (28). Incidentally, narrowing at the anastomosis can be detected while it remains unclear whether this is a clinically relevant stricture. In such cases, a short trial of stenting can be of value (33).

In the presence of a hepatico-jejunostomy, where the anastomosis is not accessible by endoscopy, percutaneous transhepatic treatment by balloon dilatation and temporary stenting is usually successful. This approach can also be used after split liver or living donor liver transplantation, although results are not as good, possibly because compromised microvascularization and local ischemia are more frequently the underlying cause (31,34).

### **Non-anastomotic Strictures: Pathogenesis and Clinical Presentation**

Non-anastomotic biliary strictures are strictures at any location in the biliary system other than the anastomosis. Biliary strictures may be confined to the hepatic bifurcation, but may also present as a more diffuse type including narrowing of the more peripheral bile ducts in the liver. Non-anastomotic strictures can be accompanied by intraductal sludge or cast formation. This type of bile duct strictures is regarded the most troublesome biliary complication as the strictures are often resistant to therapy and one of the most frequent indications for retransplantation (31,35).



The clinical presentation of patients with NAS is often not specific; symptoms may include fever due to cholangitis, abdominal complaints and increased cholestatic liver function tests, either with or without clinical jaundice.

The reported incidence of NAS after liver transplantation varies between different studies, ranging from 1-20% (1,2,13), which can partly be explained by variations in the definition of non-anastomotic biliary strictures used in different studies. About half of all NAS occur within one year after transplantation, and the remainder can be detected up to several years after transplantation (31,35). In livers obtained from DCD donors, the incidence of non-anastomotic strictures is about 10% higher and they may occur earlier than in livers obtained from DBD donors (31,35).

NAS were first described after liver transplantation in association with hepatic artery thrombosis. In case of hepatic artery thrombosis occurring early after transplantation, the biliary tree (which is entirely dependent on arterial blood supply from the hepatic artery) becomes ischemic and eventually necrotic; resulting in a typical cholangiographic image of biliary strictures, dilatations and intraductal cast formation. Such cholangiographic abnormalities of strictures and dilatations, however, can also be seen in patients who do not have a hepatic artery thrombosis. The name first given to this last group of strictures was “ischemic-type biliary lesions”, because the appearance was similar to cholangiographic bile duct abnormalities seen in patients with hepatic artery thrombosis. Other names used in the literature for this condition are “ischemic cholangiopathy” or the more general term NAS. In this chapter the latter will be used.

Knowledge about the pathogenesis of non-anastomotic strictures is slowly emerging from clinical and experimental studies. Several risk factors for this type of biliary complication have been identified, strongly suggesting a multifactorial origin. In general, the mechanisms underlying NAS can be grouped into three categories: 1) preservation or ischemia related, 2) cytotoxic injury induced by hydrophobic bile salts, and 3) immune-mediated injury.

In one large clinical study in which patients were grouped based on the time interval between transplantation and the occurrence of biliary strictures, it was suggested that ischemia-mediated mechanisms are mainly responsible for the development of biliary strictures within the first year after transplantation, whereas immune-mediated mechanisms play a more important role in the pathogenesis of strictures occurring beyond the first year (11).

The radiological similarities between the abnormalities of NAS and bile duct abnormalities seen in the presence of hepatic artery thrombosis strongly suggest an ischemic factor in the origin of these strictures. The relevance of adequate blood supply and the impact of ischemia on the bile ducts are discussed in more detail above (see paragraph: Relevance of Donor / Back Table Procedure).

Another relevant factor in the pathogenesis of bile duct injury after liver transplantation is toxicity caused by hydrophobic bile salts. Hydrophobic bile salts have potent detergent properties towards cellular membranes of hepatocytes and biliary epithelial cells. Normally, the toxic effects

of bile salts are prevented by complex formation with phospholipids and cholesterol (mixed micelle). However, early after liver transplantation, the balance in biliary excretion of these three components is disturbed, leading to the formation of more toxic bile (15). Evidence for a pivotal role of bile salt-mediated toxicity in the pathogenesis of bile duct injury and subsequent bile duct stricturing has gradually emerged during the last decade. Both experimental animal studies and clinical studies have demonstrated that biliary bile salt toxicity early after transplantation is associated with the development of microscopic as well as macroscopic bile duct injury (15). Bile salt toxicity acts synergistically to ischemia-mediated injury of the biliary epithelium (16). Despite the increasing evidence that bile salts play a role in the pathogenesis of bile duct injury and subsequent biliary structuring, it remains to be established whether the administration of non-toxic hydrophilic bile salts (e.g. ursodeoxycholic acid) to liver transplant recipients results in a reduction of the incidence of this type of biliary complication.

Several studies have provided evidence for an immunological component in the pathogenesis of NAS. NAS have been associated with various immunologically mediated processes, such as ABO-incompatible liver transplantation, pre-existing diseases with a presumed autoimmune component (such as primary sclerosing cholangitis and autoimmune hepatitis), cytomegalovirus infection, chronic rejection, and finally with a genetic polymorphism in one of the CC chemokine receptors (13). Recurrent primary sclerosing cholangitis may be another cause of NAS occurring late (> 6-12 months) after transplantation (11). The true clinical relevance of immune-mediated bile duct injury in the pathogenesis of NAS after liver transplantation remains to be established and this is an area that requires further research.

### **Non-anastomotic Strictures: Management**

Contrary to anastomotic strictures, non-anastomotic structures are much more heterogeneous in localization and severity. General recommendations regarding management are hard to make, and good quality prospective studies are rare. In every case, adequate vascularization of the biliary system of the allograft should be obtained. In the case of diffuse and severe biliary strictures with progressive jaundice and bacterial cholangitis or biliary cirrhosis, usually re-transplantation is the most favorable option. In most patients, the strictures are more localized and cirrhosis has not yet developed. Many cases are amenable to endoscopic therapy. In endoscopic therapy, repeated endoscopies with balloon dilatation and multiple stents are used. With this approach, success rates are 50-75% (31). As in anastomotic strictures, PTC can be used when endoscopic access is not feasible. In case of NAS that are confined to the extrahepatic bile ducts, surgical resection of the diseased part and construction of a hepatico-jejunostomy should be considered. In case of recurrent cholangitis, maintenance antibiotics may result in long-term relief of symptoms. Although widely used, there is no clinical evidence that supports the use of ursodeoxycholic acid.

Similar approaches can be used with NAS after split- and living-donor liver transplantation, but (as with anastomotic structures) with success rates that are significantly lower than after full size liver transplantation.

While most types of biliary complications can usually be managed successfully (either surgically or by endoscopic techniques) or run a self-limiting course, NAS remain the most challenging type of biliary complication as they are frequently therapy resistant and frequently associated with long-term sequelae. Up to 50% of patients with non-anastomotic strictures either die or require retransplantation. Mortality rates differ markedly among studies (2).

### **Bile Leakage: Pathogenesis and Clinical Presentation**

Bile leakage after liver transplantation is reported in 1-25% of the recipients. The incidence of bile leakage is the highest after transplantation of a split liver or a graft from a living donor due to presence of the hepatic resection surface (1,2). Bile leakage can either be symptomatic or asymptomatic, and may be discovered coincidentally on a postoperative cholangiogram. Symptomatic patients may present with abdominal pain, localized or generalized peritonitis, fever, and sometimes elevated serum liver enzymes and/or bilirubin.

Biliary leakage can occur at various sites and intervals after transplantation. The majority of postoperative leaks occur at the site of anastomosis or the T-tube insertion site, but also the resection surface of the graft in case of living donor or split donor transplantation is a common site for leakage. Bile leakage early after liver transplantation most likely originates from the anastomosis or the T-tube insertion site. Anastomotic leaks are mainly related to errors in surgical technique and/or ischemic necrosis at the end of the bile duct. Insufficient blood supply or traction of the stitches causes ischemia, which can result in bile leakage. A hepatic artery thrombosis can lead to massive biliary necrosis resulting in dehiscence of the biliary anastomosis. Bile leakage at the T-tube insertion site can occur immediately after transplantation or after removal of the T-tube due to an insufficiently formed fistula around the tract of the bile drain. Occasionally, bile leakage occurs after percutaneous liver biopsy or iatrogenic duct damage.

### **Bile Leakage: Management**

The management of bile leaks depends on the type of biliary anastomosis, clinical presentation, the severity and the localization of the bile leak. If a leak presents shortly after surgery, the abdominal drains should be left in place and opened. Ultrasonography should be made to confirm arterial perfusion of the graft. The majority of bile leaks is due to leakage at the site of the biliary anastomosis.

A small anastomotic bile leak can usually be managed conservatively, especially when the patient is asymptomatic. Symptomatic or infected bile collections should be treated with a radiologically placed percutaneous drain. An anastomotic bile leak without disruption of the anastomosis can be successfully managed primarily nonsurgically. Stenting of the bile duct, nasobiliary drainage,

sphincterotomy and a combination of these have all been used with a success rate of 85-100%. Since sphincterotomy may lead to specific complications (bleeding and perforation), it should not be routinely performed. The optimal timing of stent removal after resolution of symptoms is still unclear, but 8 weeks has been proven successfully (36). In the presence of a hepatico-jejunostomy, ERCP can be attempted, but is frequently not successful. Alternatively, a PTC drain can be placed, even in the presence of non-dilated bile ducts (26).

In the rare case of a complete disruption of the anastomosis, prompt surgery with conversion to a hepatico-jejunostomy is most appropriate. In selected cases a redo of the choledochocholedochostomy can be considered. In the case of diffuse bilious peritonitis with hemodynamic instability or sepsis, direct laparotomy should always be considered.

Leakage after removal of a bile drain can be managed successfully in one-third of cases by conservative measure, including intravenous fluids, antibiotics, analgesics and observation (37). In the absence of improvement, ERCP with stent placement should be performed. A laparotomy is indicated when clinical signs of biliary peritonitis persist despite adequate drainages of the biliary system.

### **Other Biliary Complications: Pathogenesis, Clinical Presentation and Management**

#### *Sphincter of Oddi dysfunction*

The sphincter of Oddi is a small smooth muscle sphincter located at the junction of the bile duct, pancreatic duct, and duodenum. The sphincter controls flow of bile and pancreatic juices into the duodenum and prevents reflux of duodenal content into the ducts. Disorder in its motility is called sphincter of Oddi dysfunction. Clinically sphincter of Oddi dysfunction presents with cholestasis, dilatation of the distal extrahepatic bile duct, and cholangiographic absence of any anatomic cause for biliary obstruction.

Studies focusing on sphincter of Oddi dysfunction are scarce and often report only very few patients. Reported incidence of sphincter of Oddi dysfunction varies from 0-7% (1,2). Development of sphincter of Oddi dysfunction after liver transplantation may be imputed to operative denervation of the sphincter of Oddi during recipient hepatectomy, leading to impairment of ampullary relaxation and increased intraductal biliary pressure (1).

Sphincter of Oddi dysfunction after liver transplantation is an obscure diagnosis. Formal proof of this diagnosis will require pressure measurement in the bile duct lumen, which is difficult to perform in the absence of a biliary drain. In case of clinical suspicion and exclusion of any other possible cause of cholestasis, an endoscopic sphincterotomy or temporary stent placement can be performed.

*Biliary casts, sludge and stones*

Casts, sludge and stones in the bile ducts are also known as bile duct filling defects. Sludge is a viscous collection of mucus, calcium bilirubinate and cholesterol. When left untreated, biliary casts can develop. Casts consist of retained lithogenic material morphologically confined to bile duct dimensions. Biliary sludge and casts tend to occur within the first year after transplantation, and when given enough time they may progress to biliary stones. Bile duct filling defects are a relatively rare complication compared with biliary strictures and leaks. A 5.7% incidence of bile duct filling defects after transplantation was reported in the largest study so far, including 1650 transplanted livers (38). Most patients with biliary stones and sludge present with cholangitis and only a small percentage present with abdominal pain. Despite the relative infrequency, studies have shown an increased morbidity and mortality as a result of biliary sludge and casts caused by recurrent cholangitis, repeated need for surgery, graft loss, and death (39).

The exact pathogenesis is yet to be discovered, but multiple factors contribute to bile duct filling defect formation, including ischemia, infection, and preservation injury (13). Theoretically, anything that increases viscosity of bile or reduces bile flow can predispose to bile duct filling defects. It is likely that ischemia contributes to the formation of filling defects both through stasis of bile (as a result of strictures) and through its direct injury to the biliary epithelium, resulting in the release of cell debris into the bile duct lumen as well as increasing the epithelial susceptibility to precipitation of lithogenic materials. Other pathogenic factors thought to be associated with filling defects are biliary cholesterol content, bacterial infection in relation to stents, presence of a hepatico-jejunostomy, fungal infections and the use of cyclosporine (2).

Stones and sludge of the biliary tree can almost universally be managed successfully by endoscopic removal. However, the long-term success of this will depend on the underlying cause. If the formation of sludge or casts is caused by a local obstruction such as a biliary drain or an anastomotic stricture that can be treated successfully, removal of the obstruction may be curative. However, when biliary sludge and casts are a symptom of ischemic bile duct injury, the severity of the latter will determine the long-term success of cast removal and will determine the fate of the graft.

*External compression of the biliary tract*

External compression of the biliary tract is a very rare type of biliary complication, characterized by extrahepatic cholestasis and jaundice. The main causes of external compression of the bile ducts are mucoceles of the cystic duct remnant and periductal lymphoma's.

Although clinically relevant mucoceles of the cystic duct have been reported in several case reports, the exact incidence of this type of complication remains unclear. In one study, non-obstructive mucoceles of the cystic duct were reported in 4.5% of the liver transplant recipients (40). A mucocele of the cystic duct can develop when both ends of donor cystic duct are ligated, e.g. due to incorporation into the suture line of the biliary anastomosis. Continued endothelial

secretion causes enlargement of the cystic duct and may subsequently cause extrinsic compression of the extrahepatic bile duct. External compression of the bile duct by a mucocele can usually be treated successfully by surgical excision of the cystic duct remnant.

A lymphoma in the hepatic (neo-)hilum can be caused by post-transplantation lymphoproliferative disorder and may result in compression of the extrahepatic bile ducts. While therapy should primarily focus on the medical treatment of the underlying lymphomas (2), temporary endoscopic stenting of the bile duct may be indicated to restore bile drainage.

#### *Kinking of redundant bile duct*

Excessive length of the donor or recipient bile duct can cause kinking of the bile duct, leading to bile flow obstruction. This is a rare technical complication that is mainly found after a choledochocholedochostomy. Patients may present with cholestatic liver function tests, fever due to cholangitis, or bile duct dilatation due to obstruction of the bile flow. The kinked bile duct can be repaired in two manners: 1) surgical resection of the redundant part and re-anastomosing of the bile ducts, or 2) by an endoscopic approach. The latter involves placement of an endoscopic stent to stretch the bile duct at the site of the choledochocholedochostomy. After the repair, scar tissue will have formed around the bile duct, which prevents recurrence of kinking. The stent can usually be removed safely after 6 weeks. In selected cases, surgical or endoscopic correction of the choledochocholedochostomy is not possible and in these cases surgical conversion to a Roux-Y hepatico-jejunostomy is indicated.

#### *Bacterial cholangitis*

Bacterial cholangitis after liver transplantation usually presents with cholestatic liver function test abnormalities in combination with high fever, either with or without chills. The risk of cholangitis is increased in patients in whom a T-tube is used, who underwent a hepatico-jejunostomy, and in patients complicated by anastomotic or non-anastomotic bile duct strictures. All of these conditions may facilitate ascending migration of bacteria into the biliary tree. When a biliary drain is present, positive bacterial cultures from the bile may support the diagnosis, although it should be noted that colonization of the bile is not infrequent in these patients. In other patients the diagnosis cholangitis is rarely supported by positive bile cultures and usually made after exclusion of other causes of fever. Management of acute cholangitis after transplantation is similar to that recommended to nontransplant patients and should include appropriate antibiotic therapy.

## SUMMARY

Biliary complications are a frequent cause of morbidity after liver transplantation. Advances in surgical techniques and preservation methods during the last decades have led to better results, but biliary complications still occur in 10-40% of the recipients and are associated with mortality rates of 8-15%. Partial liver grafts (e.g. split livers and livers from living donors) as well as livers from extended criteria donors (e.g. DCD donors), are associated with a relatively high risk of biliary complications. Of all biliary complications, bile duct strictures and bile leakage are most common after liver transplantation. While bile leakage and anastomotic bile duct strictures can usually be managed successfully without long-term sequelae, non-anastomotic biliary strictures are the most troublesome type of biliary complication. NAS are often multifocal and can be difficult to treat by endoscopic techniques. When associated with recurrent cholangitis, jaundice or even secondary biliary fibrosis, retransplantation may be the only treatment option left over. Future studies should focus on better defining the mechanism underlying NAS and on the development of effective preventive measures. In this respect it will be interesting to see if the development of machine preservation for liver grafts will result in better preservation of the bile ducts and a subsequent decrease in the incidence of this type of biliary complications.

## REFERENCES

- (1) Wojcicki M, Milkiewicz P, Silva M. Biliary tract complications after liver transplantation: a review. *Dig Surg* 2008;25:245-57.
- (2) Verdonk RC, Buis CI, Porte RJ, Haagsma EB. Biliary complications after liver transplantation: a review. *Scand J Gastroenterol Suppl* 2006;89-101.
- (3) Pine JK, Aldouri A, Young AL, Davies MH, Attia M, Toogood GJ, et al. Liver transplantation following donation after cardiac death: an analysis using matched pairs. *Liver Transpl* 2009;15:1072-82.
- (4) Davidson BR, Rai R, Kurzawinski TR, Selves L, Farouk M, Dooley JS, et al. Prospective randomized trial of end-to-end versus side-to-side biliary reconstruction after orthotopic liver transplantation. *Br J Surg* 1999;86:447-52.
- (5) Bennet W, Zimmerman MA, Campsen J, Mandell MS, Bak T, Wachs M, et al. Choledochoduodenostomy is a safe alternative to Roux-en-Y choledochojejunostomy for biliary reconstruction in liver transplantation. *World J Surg* 2009;33:1022-5.
- (6) Sotiropoulos GC, Sgourakis G, Radtke A, Molmenti EP, Goumas K, Mylona S, et al. Orthotopic liver transplantation: T-tube or not T-tube? Systematic review and meta-analysis of results. *Transplantation* 2009;87:1672-80.
- (7) Weiss S, Schmidt SC, Ulrich F, Pascher A, Schumacher G, Stockmann M, et al. Biliary reconstruction using a side-to-side choledochocholedochostomy with or without T-tube in deceased donor liver transplantation: a prospective randomized trial. *Ann Surg* 2009;250:766-71.
- (8) Shaked A. Use of T tube in liver transplantation. *Liver Transpl Surg* 1997;3(5 Suppl 1):S22-S23.
- (9) Porayko MK, Kondo M, Steers JL. Liver transplantation: late complications of the biliary tract and their management. *Semin Liver Dis* 1995;15:139-55.
- (10) Noack K, Bronk SF, Kato A, Gores GJ. The greater vulnerability of bile duct cells to reoxygenation injury than to anoxia. Implications for the pathogenesis of biliary strictures after liver transplantation. *Transplantation* 1993;56:495-500.
- (11) Buis CI, Verdonk RC, van der Jagt EJ, van der Hilst CS, Slooff MJ, Haagsma EB, et al. Nonanastomotic biliary strictures after liver transplantation, part 1: Radiological features and risk factors for early vs. late presentation. *Liver Transpl* 2007;13:708-18.
- (12) Sanchez-Urdazpal L, Gores GJ, Ward EM, Maus TP, Wahlstrom HE, Moore SB, et al. Ischemic-type biliary complications after orthotopic liver transplantation. *Hepatology* 1992;16:49-53.
- (13) Buis CI, Hoekstra H, Verdonk RC, Porte RJ. Causes and consequences of ischemic-type biliary lesions after liver transplantation. *J Hepatobiliary Pancreat Surg* 2006;13:517-24.
- (14) Dubbeld J, Hoekstra H, Farid WRR, Ringers J, Porte RJ, Metselaar HJ, et al. Similar liver transplantation survival with selected cardiac death and brain death donors. *British Journal of Surgery*. *Br J Surg* 2010;97:744-753



- (15) Buis CI, Geuken E, Visser DS, Kuipers F, Haagsma EB, Verkade HJ, et al. Altered bile composition after liver transplantation is associated with the development of nonanastomotic biliary strictures. *J Hepatol* 2009;50:69-79.
- (16) Hoekstra H, Porte RJ, Tian Y, Jochum W, Stieger B, Moritz W, et al. Bile salt toxicity aggravates cold ischemic injury of bile ducts after liver transplantation in Mdr2+/- mice. *Hepatology* 2006;43:1022-31.
- (17) Feng L, Zhao N, Yao X, Sun X, Du L, Diao X, et al. Histidine-tryptophan-ketoglutarate solution vs. University of Wisconsin solution for liver transplantation: a systematic review. *Liver Transpl* 2007;13:1125-36.
- (18) Canelo R, Hakim NS, Ringe B. Experience with histidine tryptophan ketoglutarate versus University Wisconsin preservation solutions in transplantation. *Int Surg* 2003;88:145-51.
- (19) Moench C, Moench K, Lohse AW, Thies J, Otto G. Prevention of ischemic-type biliary lesions by arterial back-table pressure perfusion. *Liver Transpl* 2003;9:285-9.
- (20) Sebagh M, Yilmaz F, Karam V, Falissard B, Roche B, Azoulay D, et al. The histologic pattern of "biliary tract pathology" is accurate for the diagnosis of biliary complications. *Am J Surg Pathol* 2005;29:318-23.
- (21) St Peter S, Rodriguez-Davalos MI, Rodriguez-Luna HM, Harrison EM, Moss AA, Mulligan DC. Significance of proximal biliary dilatation in patients with anastomotic strictures after liver transplantation. *Dig Dis Sci* 2004;49:1207-11.
- (22) Kok T, Van der Sluis A, Klein JP, Van der Jagt EJ, Peeters PM, Slooff MJ, et al. Ultrasound and cholangiography for the diagnosis of biliary complications after orthotopic liver transplantation: a comparative study. *J Clin Ultrasound* 1996;24:103-15.
- (23) Boraschi P, Donati F, Gigoni R, Volpi A, Salemi S, Filipponi F, et al. MR cholangiography in orthotopic liver transplantation: sensitivity and specificity in detecting biliary complications. *Clin Transplant* 2010;24:E82-87.
- (24) Chahal P, Baron TH, Poterucha JJ, Rosen CB. Endoscopic retrograde cholangiography in post-orthotopic liver transplant population with Roux-en-Y biliary reconstruction. *Liver Transpl* 2007;13:1168-73.
- (25) Kawano Y, Mizuta K, Hishikawa S, Egami S, Fujiwara T, Hyodo M, et al. Rendezvous penetration method using double-balloon endoscopy for complete anastomosis obstruction of hepaticojejunostomy after pediatric living donor liver transplantation. *Liver Transpl* 2008;14:385-7.
- (26) Righi D, Franchello A, Ricchiuti A, Breatta AD, Versace K, Calvo A, et al. Safety and efficacy of the percutaneous treatment of bile leaks in hepaticojejunostomy or split-liver transplantation without dilatation of the biliary tree. *Liver Transpl* 2008;14:611-5.
- (27) Kurzawinski TR, Selves L, Farouk M, Dooley J, Hilson A, Buscombe JR, et al. Prospective study of hepatobiliary scintigraphy and endoscopic cholangiography for the detection of early biliary complications after orthotopic liver transplantation. *Br J Surg* 1997;84:620-3.
- (28) Verdonk RC, Buis CI, Porte RJ, van der Jagt EJ, Limburg AJ, Van den Berg AP, et al. Anastomotic biliary strictures after liver transplantation: causes and consequences. *Liver Transpl* 2006;12:726-35.

- (29) Jagannath S, Kalloo AN. Biliary Complications After Liver Transplantation. *Curr Treat Options Gastroenterol* 2002;5:101-12.
- (30) Bourgeois N, Deviere J, Yeaton P, Bourgeois F, Adler M, Van De Stadt J, et al. Diagnostic and therapeutic endoscopic retrograde cholangiography after liver transplantation. *Gastrointest Endosc* 1995;42:527-34.
- (31) Sharma S, Gurakar A, Jabbour N. Biliary strictures following liver transplantation: past, present and preventive strategies. *Liver Transpl* 2008;14:759-69.
- (32) Zoepf T, Maldonado-Lopez EJ, Hilgard P, Malago M, Broelsch CE, Treichel U, et al. Balloon dilatation vs. balloon dilatation plus bile duct endoprosthesis for treatment of anastomotic biliary strictures after liver transplantation. *Liver Transpl* 2006;12:88-94.
- (33) Cantu P, Tenca A, Donato MF, Rossi G, Forzenigo L, Piodi L, et al. ERCP and short-term stent-trial in patients with anastomotic biliary stricture following liver transplantation. *Dig Liver Dis* 2009;41:516-22.
- (34) Gomez CM, Dumonceau JM, Marcolongo M, de Santibanes E, Ciardullo M, Pekolj J, et al. Endoscopic management of biliary complications after adult living-donor versus deceased-donor liver transplantation. *Transplantation* 2009;88:1280-5.
- (35) Verdonk RC, Buis CI, van der Jagt EJ, Gouw AS, Limburg AJ, Slooff MJ, et al. Nonanastomotic biliary strictures after liver transplantation, part 2: Management, outcome, and risk factors for disease progression. *Liver Transpl* 2007;13:725-32.
- (36) Morelli J, Mulcahy HE, Willner IR, Baliga P, Chavin KD, Patel R, et al. Endoscopic treatment of post-liver transplantation biliary leaks with stent placement across the leak site. *Gastrointest Endosc* 2001;54:471-5.
- (37) Shuhart MC, Kowdley KV, McVicar JP, Rohrmann CA, McDonald MF, Wadland DW, et al. Predictors of bile leaks after T-tube removal in orthotopic liver transplant recipients. *Liver Transpl Surg* 1998;4:62-70.
- (38) Sheng R, Ramirez CB, Zajko AB, Campbell WL. Biliary stones and sludge in liver transplant patients: a 13-year experience. *Radiology* 1996;198:243-7.
- (39) Shah JN, Haigh WG, Lee SP, Lucey MR, Brensinger CM, Kochman ML, et al. Biliary casts after orthotopic liver transplantation: clinical factors, treatment, biochemical analysis. *Am J Gastroenterol* 2003;98:1861-7.
- (40) Caputo M, Piolanti M, Riccioli LA, Paziienza L, Fabbro E, Gruppioni F, et al. [Nonobstructive residual mucocele of the cystic duct. Reassessment of complications in our 13 years' experience with liver transplantation]. *Radiol Med* 2000;100:354-6.





# CHAPTER 3

## **Protection of Bile Ducts in Liver Transplantation: Looking Beyond Ischemia**

Op den Dries S, Sutton ME, Lisman T, Porte RJ.

*Transplantation* 2011; 92: 373-379.

## **ABSTRACT**

Biliary complications, especially nonanastomotic biliary strictures (NAS), are a major cause of morbidity after orthotopic liver transplantation (OLT). Of all donor and recipient characteristics known to increase the risk of developing NAS, the role of prolonged ischemia times is most extensively described in the literature. However, there is increasing evidence that several other, non-ischemia related factors play a critical role in the pathogenesis of NAS as well. The clinical presentation of NAS may vary considerably among liver transplant recipients, including large variations in time of occurrence, as well as in location and severity of the strictures. Additional underlying causes such as bile salt toxicity and immune-mediated injury are thought to explain the wide spectrum of biliary strictures after OLT. Current and emerging insight in the pathogenesis of NAS and potential targets to reduce biliary injury and preserve bile ducts are discussed in this overview.

## BILIARY COMPLICATIONS AFTER LIVER TRANSPLANTATION

Orthotopic liver transplantation (OLT) has proven to be a successful treatment for patients with end stage chronic or acute liver failure. Despite excellent 1-year patient and graft survival rates (85-90% and 75-85%, respectively), liver transplantation brings along the risk of complications such as infection, rejection of the graft, primary non-function or initial poor function of the graft, vascular complications and biliary complications. Of all liver transplant recipients, 10-40% develop biliary complications which are associated with mortality rates of 8-15% (1-3). There is a variety of biliary complications that can occur after OLT, the most common being bile leakage and bile duct strictures.

Bile leakage can occur at various sites and intervals after transplantation. The majority of postoperative leaks occur at the site of anastomosis or at the T-tube insertion site. Another common site for leakage is the resection surface of the graft in case of living donor or split liver transplantation. Depending on the size of the leak, bile leakage can be managed successfully conservatively, non-surgically or surgically (4-7).

Bile duct strictures are grouped into anastomotic biliary strictures and nonanastomotic biliary strictures (NAS). Anastomotic biliary strictures are isolated strictures at the site of the bile duct anastomosis. They result mainly from surgical technique and local ischemia, leading to fibrotic scarring of the anastomosis (8). Most anastomotic biliary strictures are treated with dilatation and stenting. Sometimes surgical revision or conversion to a Roux-en-Y hepatico-jejunostomy is required, all associated with excellent long term results (9-11).

Compared with anastomotic biliary strictures, NAS present much more heterogeneously and are regarded the most troublesome biliary complication after OLT. NAS are strictures at any location in the biliary system of the transplanted liver (either intrahepatic or extrahepatic). NAS were first described after OLT as a cholangiographic image of biliary strictures and dilatations caused by ischemia following hepatic artery thrombosis (HAT). However, such cholangiographic abnormalities of strictures and dilatations can also be seen in patients who do not have biliary ischemia caused by HAT, and the name first given to this last subgroup of strictures was "ischemic-type biliary lesions" (**Figure 1**). Alternative names used in the literature are "ischemic cholangiopathy" or the more general term "nonanastomotic biliary strictures", which is used in this overview.

The reported incidence of NAS after OLT varies between 1% and 20% (2,3,12,13), which can partly be explained by variations in the definition of NAS used. Although most types of biliary complications can usually be treated successfully (either surgically or by endoscopic techniques), or run a self-limiting course, NAS remain the most challenging type of biliary complication as they are frequently therapy resistant and often associated with long-term consequences. Therapeutic options are endoscopic dilatation or stenting, percutaneous transhepatic cholangiography (PTC) drainage or dilatation, or surgical resection followed by construction of a hepatico-jejunostomy.

Because of limited therapeutic options and therapy resistance, up to 50% of patients with NAS die or require retransplantation (2). High mortality rates and the impact on the already undersized pool of donor organs make NAS a complication in desperate need for better preventive strategies and treatment options. Therefore, it is important to understand the pathogenesis of NAS and discover ways in which development of NAS after OLT can be prevented.

Knowledge about the pathogenesis of NAS is slowly emerging from clinical and experimental studies performed during the last decade. Several risk factors have been identified, strongly suggesting a multifactorial origin (12). Although a true causative relationship may not have been proven for many putative risk factors, most current evidence is circumstantial and based on observational studies. In general, proposed mechanisms underlying the pathogenesis of NAS can be divided into three categories: a) ischemia-related injury, b) immune-mediated injury, and c) cytotoxic injury induced by hydrophobic bile salts. These mechanisms are summarized in **Table 1** and are discussed in more detail below.

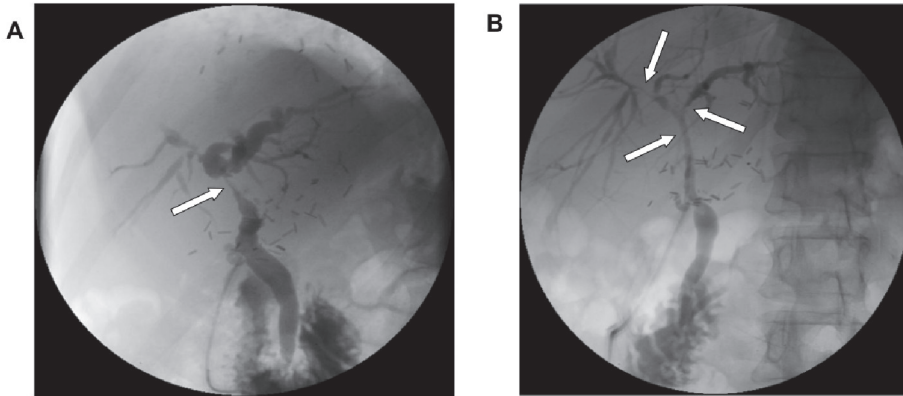
**Table 1.** Mechanisms of Biliary Epithelial Injury after Liver Transplantation

- A. Ischemia-related injury caused by:
  - Warm and cold ischemia associated with organ preservation
  - Warm ischemia in donation after cardiac death donors
  - Inadequate preservation of the peribiliary capillary plexus
- B. Immune-mediated injury due to:
  - ABO-incompatible transplantation
  - CMV-infection
  - Female organs in male recipients
  - Chemokine receptor CCR5-Δ32 polymorphism
- C. Cytotoxic effect of hydrophobic bile salts caused by:
  - Inadequate flush out of bile from the bile ducts at organ retrieval
  - High biliary bile salt / phospholipid ratio after transplantation
  - Impaired cholehepatic shunt with intracellular accumulation of bile salts in cholangiocytes
  - Impairment of the protective HCO<sub>3</sub><sup>-</sup> umbrella at the canalicular membrane of cholangiocytes

## NOT ALL PRESENTATIONS OF NAS ARE EQUAL

NAS is a heterogeneous group of bile duct strictures and not all presentations of NAS are equal. A large variation is observed in the time interval between liver transplantation and the first presentation of NAS, ranging from 0.3-155 months (14,15). Location and severity also differ between patients. NAS may be confined to the hepatic bifurcation (large bile ducts), but may also present as a more diffuse type, affecting the small peripheral bile ducts of the liver (**Figure 1**).





**Figure 1.** Contrast cholangiography of the bile ducts in patients after liver transplantation. **Panel A:** radiological example of a patient with predominantly abnormalities in the central bile ducts (arrow). **Panel B:** radiological example of a patient with a diffuse type of nonanastomotic biliary strictures (arrows).

One large clinical study reported differences in anatomical localization and underlying causes of NAS presenting early (<1 year) versus late (>1 year) after OLT (15). In the group with early presentation of NAS, the vast majority of lesions were found around the bile duct bifurcation and the extrahepatic bile duct. On the contrary, biliary abnormalities in the group with late presentation of NAS were more frequently located in the periphery of the liver. Moreover, NAS presenting within 1 year after OLT were associated with ischemia-related variables, such as a longer cold and warm ischemia time, compared to NAS occurring more than 1 year after OLT. The latter group was more frequently associated with variables that may explain an immunological cause. It has, therefore, been suggested that ischemia-mediated mechanisms are frequently responsible for the development of biliary strictures early (<1 year) after transplantation, whereas immune-mediated mechanisms play an important role in the pathogenesis of strictures occurring beyond the first year (15).

## ISCHEMIA AS A CAUSE OF NAS

### Ischemia-Reperfusion Injury

Bile ducts entirely depend on arterial blood supply for oxygenation. Hepatocytes, on the other hand, are supplied by both the hepatic artery and the portal vein. For this reason, HAT is specifically detrimental for bile duct epithelial cells (cholangiocytes) and may result in massive bile duct necrosis (16). Additionally, cholangiocytes are highly susceptible to reoxygenation after anoxia (reperfusion injury) (17). Reoxygenation of anoxic liver cells improves survival of hepatocytes, but causes increased cell death of cholangiocytes. The increased susceptibility to



reoxygenation injury by cholangiocytes is associated with increased production of toxic reactive oxygen species by cholangiocytes during reoxygenation with concomitant low basal levels of the antioxidant glutathione in these epithelial cells (17).

Ischemic preconditioning (IPC) has been proposed as an attractive surgical strategy to decrease liver ischemia-reperfusion injury. Thus far, there is still significant controversy regarding the use of IPC in the liver transplant setting (18). There is currently no evidence to support or refute the use of IPC in donor liver procurement (19). However, the effect of IPC on survival of cholangiocytes during liver transplantation has not been studied, as outcome parameters used to determine liver injury in previous studies were mainly hepatocyte-specific.

### **Cold Ischemia**

The duration of cold ischemic storage of a graft is strongly associated with the development of biliary strictures. Prolonged cold ischemia time (>13 hrs) greatly increases the occurrence of NAS after transplantation (13). However, with the shorter periods of cold ischemia in OLT these days (on average 8-10 hours), the association between cold ischemia time and the development of NAS has become less evident (15).

### **Warm Ischemia**

One of the best-known risk factors for NAS is donation after cardiac death (DCD). Warm ischemic time in the donor in addition to subsequent cold ischemia-reperfusion injury is thought to result in increased damage to biliary epithelial cells. Grafts from DCD donors are used to increase the number of organs available for liver transplantation, and about 20% of the livers available for transplantation in the US and many European countries is currently derived from a DCD donor (20,21). The use of DCD grafts and restrictive criteria can result in patient and graft survival rates similar to those of donation after brain death (DBD) liver transplantation; however, this is associated with a higher risk of biliary strictures. The incidence of NAS following DCD is 10-30% compared with a 1-10% incidence of NAS following donation after brain death (20,22-26).

### **Preservation**

Insufficient flush out of the microvasculature of the liver (peribiliary capillary plexus) is thought to play a role in the development of NAS. A sufficient flush out is needed for adequate exposure of cholangiocytes and endothelium to preservation fluids. The preservation fluid prevents injury of these cells and subsequent formation of microthrombi in the small arteries as a result of cell necrosis and local coagulation. With that, it prevents prolonged hypoxia of the bile ducts. The use of high-viscosity preservation solution is thought to result in an insufficient flush out of the peribiliary capillary plexus, leading to a higher incidence of NAS, compared with low-viscosity preservation solutions (27). Lower viscosity could provide a faster initial flush during organ retrieval, resulting in faster cooling and improved washout of blood cells. Equally, arterial back-

table pressure perfusion used to achieve sufficient perfusion of the peribiliary plexus significantly decreased the occurrence of NAS after transplantation, compared with standard perfusion methods (28). In contrast with the potentially favorable effect of low-viscosity solutions such as histidine-tryptophan-ketoglutarate solution on the biliary system, this type of solution has recently been associated with reduced graft survival in deceased donor livers, especially those from DCD donors (29). The cardiac standstill in DCD donors is not only thought to result in warm ischemic injury, but also in the formation of thrombi in the microvasculature of the donor organ. Animal studies have shown that the use of a fibrinolytic agent in a preflush before preservation of a DCD liver markedly improves flush out of such microthrombi and improves microperfusion with University of Wisconsin solution (30).

### **Potential Targets**

An obvious target to reduce ischemia-induced bile duct injury in OLT is keeping ischemic times as short as possible. Moreover, low-viscosity organ preservation solution and arterial back-table pressure perfusion either with or without thrombolysis seem to be beneficial. Adequately powered randomized controlled trials (RCTs) with long follow-up periods are required to evaluate the long-term effect of histidine-tryptophan-ketoglutarate (HTK) and University of Wisconsin (UW) solutions. The safety and side-effects of thrombolysis in DCD donation should be studied more extensively and future studies should also focus more on bile duct related outcome parameters. (31). In the future, normothermic or hypothermic machine perfusion could potentially greatly decrease ischemic injury to the liver graft. Some positive results have been shown in this field, however, more research and experience are required (32). In addition, more research on the role of IPC in the protection of cholangiocytes against ischemia is warranted.

## **IMMUNOLOGICAL FACTORS AS A CAUSE OF NAS**

NAS has been associated with various immunological processes. Although the exact role of the immune system in the pathogenesis of NAS remains unclear, there are several studies suggesting a role for the immune system in the pathogenesis of NAS.

For example, ABO-incompatible liver transplantation has been associated with the development of NAS. This may be explained by either a persisting ABH antigen expression in the intrahepatic biliary system of the hepatic allograft, resulting in a biliary system more susceptible to immunologic injury, or by occlusion and consequent ischemic injury caused by endothelial injury, or both. Increased bile duct damage after transplantation across the ABO barrier will eventually result in a higher rate of NAS (33-35). Moreover, pre-existing diseases with a presumed autoimmune component, such as primary sclerosing cholangitis and autoimmune hepatitis, have been associated with a higher incidence of NAS (36-38).

In one retrospective study, a female to male donor/recipient match was significantly associated with late occurrence of NAS (15). It was suggested that the higher incidence of NAS in male recipients of a female graft is related to immunological processes.

Biliary complications develop significantly more often in the presence of preceding or concomitant cytomegalovirus (CMV) viremia, especially in conjunction with primary CMV infection (38,39). CMV inclusions have been detected in a histopathologic specimen of bile duct strictures from a liver transplant patient, in whom biliary strictures developed during CMV infection (39). However, the exact mechanisms explaining the relationship between CMV infection and NAS are still to be elucidated. Thus far it is unclear whether CMV injures the biliary epithelium in a direct manner by infecting biliary epithelial cells, or in an indirect manner by immune attack evoked against infected biliary epithelial cells. Alternatively, it is potentially possible that CMV infection causes ischemic injury of the biliary epithelium via injury of endothelial cells of the peribiliary capillary plexus and subsequent formation of microthrombi and inadequate oxygenation of the biliary epithelium.

Another line of evidence for an immune-mediated mechanism of bile duct injury and NAS formation was provided by a recently described association between a loss-of-function mutation in the chemokine receptor CCR5 (CCR5- $\Delta$ 32) and the development of NAS after OLT. Retrospective studies have shown that liver transplant recipients carrying CCR5- $\Delta$ 32 are at much greater risk of developing NAS after transplantation, compared with CCR5 wild-type recipients (40,41). This risk is even higher in recipients with CCR5- $\Delta$ 32 transplanted for primary sclerosing cholangitis (PSC). Moreover, late development of NAS is significantly more present in recipients carrying CCR5- $\Delta$ 32 (41). A possible explanation for this may be functional changes in the immune system resulting from the CCR5- $\Delta$ 32 mutation, including impaired attraction of regulatory T cells to the site of injury (42-44).

### **Potential Targets**

Because the exact role of the immune system in the pathogenesis of NAS remains unclear, this aspect requires further research and is not yet ready for targeted therapy. At this stage, only anti-CMV prophylaxis to prevent NAS in liver recipients who are seronegative for CMV is supported by scientific data, as de novo CMV infections are clearly associated with a higher incidence of NAS.

## **THE ROLE OF BILE SALTS IN THE DEVELOPMENT OF NAS**

Another potential factor in the pathogenesis of bile duct injury after liver transplantation is bile salt toxicity. Hydrophobic bile acids can induce damage to hepatocytes and cholangiocytes based on either their detergent effects towards lipid cellular membranes or by intracellular cytotoxic effects and induction of apoptosis.

### **Inadequate Flush Out of Bile During Cold Ischemia**

Experimental studies in pigs have indicated that hydrophobic bile salts are able to induce damage to the biliary epithelium of the liver graft during cold ischemia when hydrophobic bile salts are added to the preservation solution. This type of injury is characterized by loss of microvilli, cell-surface erosions, and cell death (45-47). Based on these observations the importance of adequate flush out of the biliary tract, to remove bile during the backtable procedure, has been emphasized.

### **Altered Composition of Bile After Liver Transplantation**

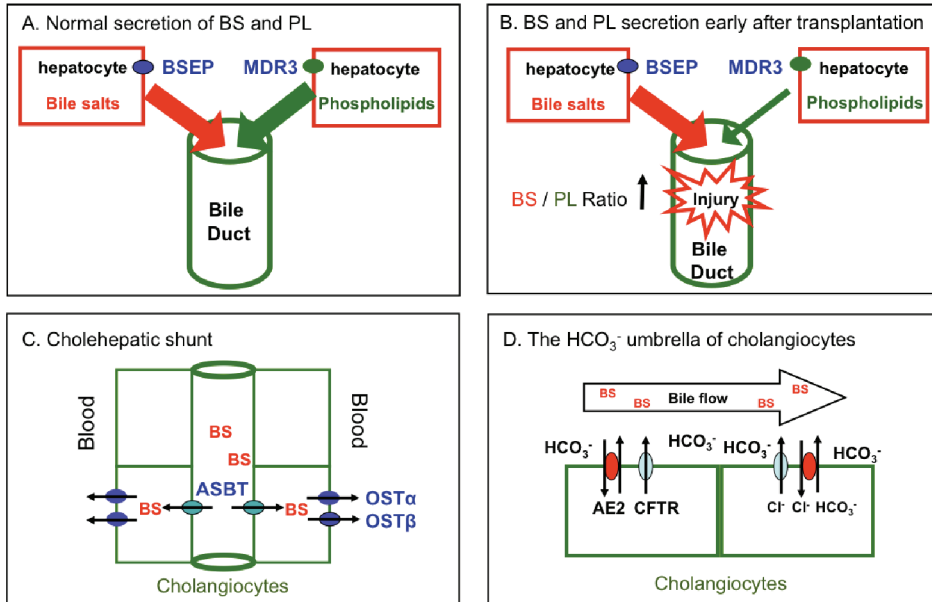
Hepatic secretion of bile salts, phospholipids and cholesterol is an active process mediated by specific hepatobiliary transporter proteins located in the canalicular cell membrane of hepatocytes. While the bile salt export pump (BSEP; gene ABCB11) is largely responsible for the secretion of bile salts, the multidrug resistance protein 3 (MDR3; gene ABCB4) is responsible for the secretion of phospholipids (48).

Experimental and clinical studies have provided increasing evidence that the expression and function of these transporters may be impaired after OLT, resulting in an abnormal bile composition that has been associated with bile duct injury and NAS after OLT. A well functioning graft immediately starts to secrete bile salts upon graft reperfusion, but the overall biliary secretion of bile salts remains low within the first week after OLT. Restoration of biliary secretion of phospholipids, however, may recover even slower. These differences may be explained by differences in the expression and function of the transporters bile salt export pump (BSEP) and multidrug resistance protein 3 (MDR3), resulting in a higher bile salt/phospholipid (BS/PL) ratio in the bile during the first days after OLT (**Figure 2A,B**). The formation of protective mixed micelles is therefore impaired and free hydrophobic bile salts may cause injury of the cellular lipid membranes of cholangiocytes via their detergent activities. Compelling evidence that this high BS/PL ratio is correlated with the development of biliary injury and NAS has been provided in experimental animal studies (46,49,50) and two prospective clinical studies (51,52).

### **Intracellular Accumulation of Hydrophobic Bile Salts in Cholangiocytes**

At physiological concentrations, a simple detergent-like effect involving disruption of cell membranes is likely not the only explanation for bile salt-induced biliary injury after transplantation. An alternative mechanism of bile salt-mediated bile duct injury after OLT is the intracellular accumulation of hydrophobic bile salts in cholangiocytes. Intracellular accumulation of bile salts may occur when the transporters responsible for canalicular uptake and basolateral excretion of bile salts by cholangiocytes are no longer in balance (**Figure 2C**). These cholangiocyte transporters are, under physiological circumstances, believed to be responsible for the so called cholehepatic shunt (53). Bile salt accumulation leading to cellular damage in hepatocytes has been described in cholestatic diseases (54), and it is likely that a similar process may occur in

cholangiocytes. A recent experimental study in rats has indicated that in addition to the high biliary BS/PL ratio, an ischemia related discrepancy may occur in the recovery of the cholangiocyte bile acid reuptake transporter apical sodium-dependent bile acid transporter (ASBT) and the cholangiocyte basolateral export transporters (organic solute and steroid transporters  $OST\alpha$  and  $OST\beta$ ), resulting in the accumulation of toxic bile acids and subsequent injury of cholangiocytes, especially in the larger bile ducts (55).



**Figure 2.** Schematic presentation of the hepatobiliary transporter proteins responsible for the uptake and secretion of bile components by hepatocytes and cholangiocytes. **Panel A:** Normal situation. **Panel B:** Reduced expression or functional impairment of hepatocellular transporters for bile salts and phospholipids (BSEP and MDR3) may result in abnormal bile composition with a relatively high bile salt/phospholipid ratio. This has been associated with increased bile duct injury and development of nonanastomotic strictures. **Panel C:** Unbalanced alteration in ASBT,  $OST\alpha$  and  $OST\beta$ , the main transporters involved for the cholehepatic shunt, may result in accumulation of toxic bile salts inside cholangiocytes. **Panel D:** Finally, a functional impairment of the secretion of  $HCO_3^-$  by cholangiocytes may diminish the protective effect of an alkaline environment at the canalicular membrane of cholangiocytes, making them more susceptible to uncontrolled membrane permeation of hydrophobic bile salts (full description of this hypothesis is provided in ref 56).

**Abbreviations used:** BS, bile salt; PL, phospholipid; BSEP, bile salt export pump; MDR3, multidrug resistance protein 3 (phospholipid flippase); ASBT, apical sodium-dependent bile acid transporter;  $OST\alpha$ , organic solute and steroid transporter  $\alpha$ ;  $OST\beta$ , organic solute and steroid transporter  $\beta$ ; AE2, anion exchanger 2; CFTR, cystic fibrosis transmembrane conductance regulator.

### Impaired Biliary $\text{HCO}_3^-$ Secretion as A Cause of Biliary Injury

Biliary  $\text{HCO}_3^-$  secretion has been proposed as a mechanism to prevent the uncontrolled membrane permeation of hydrophobic bile salts by maintaining an alkaline pH near the apical surface of hepatocytes and cholangiocytes (56). An alkaline environment results in deprotonation of hydrophobic bile acids, making them less capable of attacking cell membranes (**Figure 2D**). Biliary secretion of  $\text{HCO}_3^-$  is largely controlled by the cholangiocyte  $\text{Cl}^-/\text{HCO}_3^-$  exchanger  $\text{AE}_2$  and the transporter cystic fibrosis transmembrane conductance regulator (CFTR), which are adenosine triphosphate (ATP) dependent. Ischemia, as inevitably occurs in transplantation, will not only result in a reduction of ATP levels, but may also result in altered expression of  $\text{AE}_2$  and CFTR, which will subsequently lead to a diminished function of the “ $\text{HCO}_3^-$  umbrella” protecting cholangiocytes (57). Although this mechanism has been hypothesized to contribute to the development and progression of NAS after OLT, formal evidence for this is still lacking and further research in this area is needed (56).

### Potential Targets

The accumulating evidence that hydrophobic bile acids contribute to biliary epithelial injury after OLT provides new avenues for possible preventive strategies. Adequate retrograde flushing of the bile ducts during organ procurement alone may not be enough to avoid bile salt-mediated biliary injury. Additional therapies, such as substitution of hydrophobic bile salts by more hydrophilic bile salts, which are thought to exert cytoprotective instead of detrimental effects on cholangiocytes (i.e. ursodeoxycholic acid or nor-ursodeoxycholic acid), are an attractive and relatively simple option. However, formal evidence that substitution of (nor-)ursodeoxycholic acid in liver transplant recipients results in a reduction of the incidence of NAS is still lacking. Randomized clinical trials on the efficacy of (nor-)ursodeoxycholic acid in the prevention of NAS are needed. In addition, future research should focus on the potentially protective effects of stimulating  $\text{HCO}_3^-$  secretion by cholangiocytes after OLT.

## CONCLUSIONS

NAS continues to be a serious cause of morbidity and graft loss after OLT. Not all cases of NAS are equal. Timing, localization and severity of strictures vary between patients. Differences in the pathogenesis of NAS are thought to, at least partly, explain these variations in presentation. Although NAS occurring early after OLT are largely associated with an ischemia-related pathogenesis, NAS occurring late after OLT are believed to have a more immune-mediated origin. Endogenous bile salts may play an additional role in the pathogenesis of bile duct injury after OLT. Hydrophobic bile salts have a direct cytotoxic effect on the cholangiocytes and this may contribute to the post-ischemic injury of the biliary epithelium. Donor surgeons can help prevent NAS by reducing warm and cold ischemia time as much as possible, providing adequate

flush out of the liver, the peribiliary plexus, and the bile ducts. Recipient (transplant) surgeons can help reducing the incidence of NAS by keeping the cold ischemia time as short as possible and by performing arterial back-table pressure perfusion of the liver graft to ensure adequate perfusion of the peribiliary capillary plexus. More studies will be needed to provide better insight in the immune-mediated mechanisms of NAS that occur late after OLT.

Recent advancements in normothermic and hypothermic machine perfusion could potentially have an important impact on incidence of NAS through a reduction of preservation injury of the bile ducts and the peribiliary capillary plexus of liver grafts.

## REFERENCES

- (1) Buck DG, Zajko AB. Biliary complications after orthotopic liver transplantation. *Tech Vasc Interv Radiol* 2008;11:51-59.
- (2) Verdonk RC, Buis CI, Porte RJ, Haagsma EB. Biliary complications after liver transplantation: a review. *Scand J Gastroenterol Suppl* 2006;89-101.
- (3) Wojcicki M, Milkiewicz P, Silva M. Biliary tract complications after liver transplantation: a review. *Dig Surg* 2008;25:245-257.
- (4) Morelli J, Mulcahy HE, Willner IR et al. Endoscopic treatment of post-liver transplantation biliary leaks with stent placement across the leak site. *Gastrointest Endosc* 2001;54:471-475.
- (5) Osorio RW, Freise CE, Stock PG et al. Nonoperative management of biliary leaks after orthotopic liver transplantation. *Transplantation* 1993;55:1074-1077.
- (6) Righi D, Franchello A, Ricchiuti A et al. Safety and efficacy of the percutaneous treatment of bile leaks in hepaticojejunostomy or split-liver transplantation without dilatation of the biliary tree. *Liver Transpl* 2008;14:611-615.
- (7) Shuhart MC, Kowdley KV, McVicar JP et al. Predictors of bile leaks after T-tube removal in orthotopic liver transplant recipients. *Liver Transpl Surg* 1998;4:62-70.
- (8) Jagannath S, Kalloo AN. Biliary Complications After Liver Transplantation. *Curr Treat Options Gastroenterol* 2002;5:101-112.
- (9) Sharma S, Gurakar A, Jabbour N. Biliary strictures following liver transplantation: past, present and preventive strategies. *Liver Transpl* 2008;14:759-769.
- (10) Verdonk RC, Buis CI, Porte RJ et al. Anastomotic biliary strictures after liver transplantation: causes and consequences. *Liver Transpl* 2006;12:726-735.
- (11) Zoepf T, Maldonado-Lopez EJ, Hilgard P et al. Balloon dilatation vs. balloon dilatation plus bile duct endoprosthesis for treatment of anastomotic biliary strictures after liver transplantation. *Liver Transpl* 2006;12:88-94.
- (12) Buis CI, Hoekstra H, Verdonk RC, Porte RJ. Causes and consequences of ischemic-type biliary lesions after liver transplantation. *J Hepatobiliary Pancreat Surg* 2006;13:517-524.

- (13) Sanchez-Urdazpal L, Gores GJ, Ward EM et al. Ischemic-type biliary complications after orthotopic liver transplantation. *Hepatology* 1992;16:49-53.
- (14) Graziadei IW, Schwaighofer H, Koch R et al. Long-term outcome of endoscopic treatment of biliary strictures after liver transplantation. *Liver Transpl* 2006;12:718-725.
- (15) Buis CI, Verdonk RC, van der Jagt EJ et al. Nonanastomotic biliary strictures after liver transplantation, part 1: Radiological features and risk factors for early vs. late presentation. *Liver Transpl* 2007;13:708-718.
- (16) Stange BJ, Glanemann M, Nuessler NC, Settmacher U, Steinmuller T, Neuhaus P. Hepatic artery thrombosis after adult liver transplantation. *Liver Transpl* 2003;9:612-620.
- (17) Noack K, Bronk SF, Kato A, Gores GJ. The greater vulnerability of bile duct cells to reoxygenation injury than to anoxia. Implications for the pathogenesis of biliary strictures after liver transplantation. *Transplantation* 1993;56:495-500.
- (18) Montalvo-Jave EE, Pina E, Montalvo-Arenas C et al. Role of ischemic preconditioning in liver surgery and hepatic transplantation. *J Gastrointest Surg* 2009;13:2074-2083.
- (19) Gurusamy KS, Kumar Y, Sharma D, Davidson BR. Ischaemic preconditioning for liver transplantation. *Cochrane Database Syst Rev* 2008; CD006315.
- (20) Dubbeld J, Hoekstra H, Farid W et al. Similar liver transplantation survival with selected cardiac death donors and brain death donors. *Br J Surg* 2010;97:744-753.
- (21) Saidi RF, Bradley J, Greer D et al. Changing pattern of organ donation at a single center: are potential brain dead donors being lost to donation after cardiac death? *Am J Transplant* 2010;10:2536-2540.
- (22) Abt P, Crawford M, Desai N, Markmann J, Olthoff K, Shaked A. Liver transplantation from controlled non-heart-beating donors: an increased incidence of biliary complications. *Transplantation* 2003;75:1659-1663.
- (23) Garcia-Valdecasas JC, Tabet J, Valero R et al. Evaluation of ischemic injury during liver procurement from non-heart-beating donors. *Eur Surg Res* 1999;31:447-456.
- (24) Chan EY, Olson LC, Kisthard JA et al. Ischemic cholangiopathy following liver transplantation from donation after cardiac death donors. *Liver Transpl* 2008;14:604-610.
- (25) Grewal HP, Willingham DL, Nguyen J et al. Liver transplantation using controlled donation after cardiac death donors: an analysis of a large single-center experience. *Liver Transpl* 2009;15:1028-1035.
- (26) Pine JK, Aldouri A, Young AL et al. Liver transplantation following donation after cardiac death: an analysis using matched pairs. *Liver Transpl* 2009;15:1072-1082.
- (27) Pirenne J, Van GF, Coosemans W et al. Type of donor aortic preservation solution and not cold ischemia time is a major determinant of biliary strictures after liver transplantation. *Liver Transpl* 2001;7:540-545.
- (28) Moench C, Moench K, Lohse AW, Thies J, Otto G. Prevention of ischemic-type biliary lesions by arterial back-table pressure perfusion. *Liver Transpl* 2003;9:285-289.



- (29) Stewart ZA, Cameron AM, Singer AL, Montgomery RA, Segev DL. Histidine-Tryptophan-Ketoglutarate (HTK) is associated with reduced graft survival in deceased donor livers, especially those donated after cardiac death. *Am J Transplant* 2009;9:286-293.
- (30) Yamauchi JI, Richter S, Vollmar B, Menger MD, Minor T. Warm preflush with streptokinase improves microvascular procurement and tissue integrity in liver graft retrieval from non-heart-beating donors. *Transplantation* 2000;69:1780-1784.
- (31) Porte RJ, Clavien PA. Preflush with plasminogen activator in non-heart-beating donors: is it worth it? *Transplantation* 2000;69:1769-1771.
- (32) de RO, Lehmann K, Clavien PA. Preconditioning, organ preservation, and postconditioning to prevent ischemia-reperfusion injury to the liver. *Liver Transpl* 2009;15:1172-1182.
- (33) Rapaport FT, Dausset J. Activity of the ABO antigen system as a determinant of histocompatibility in human transplantation. *Transplant Proc* 1987;19:4487-4491.
- (34) Rull R, Garcia Valdecasas JC, Grande L et al. Intrahepatic biliary lesions after orthotopic liver transplantation. *Transpl Int* 2001;14:129-134.
- (35) Sanchez-Urdazpal L, Gores GJ, Ward EM et al. Clinical outcome of ischemic-type biliary complications after liver transplantation. *Transplant Proc* 1993;25:1107-1109.
- (36) Feller RB, Waugh RC, Selby WS, Dolan PM, Sheil AG, McCaughan GW. Biliary strictures after liver transplantation: clinical picture, correlates and outcomes. *J Gastroenterol Hepatol* 1996;11:21-25.
- (37) Guichelaar MM, Benson JT, Malinchoc M, Krom RA, Wiesner RH, Charlton MR. Risk factors for and clinical course of non-anastomotic biliary strictures after liver transplantation. *Am J Transplant* 2003;3:885-890.
- (38) Hoekstra H, Buis CI, Verdonk RC et al. Is Roux-en-Y choledochojejunostomy an independent risk factor for nonanastomotic biliary strictures after liver transplantation? *Liver Transpl* 2009;15:924-930.
- (39) Halme L, Hockerstedt K, Lautenschlager I. Cytomegalovirus infection and development of biliary complications after liver transplantation. *Transplantation* 2003;75:1853-1858.
- (40) Moench C, Uhrig A, Lohse AW, Otto G. CC chemokine receptor 5delta32 polymorphism-a risk factor for ischemic-type biliary lesions following orthotopic liver transplantation. *Liver Transpl* 2004;10:434-439.
- (41) Op den Dries S, Buis CI, Adelman J et al. The combination of primary sclerosing cholangitis and CCR5-Delta32 in recipients is strongly associated with the development of nonanastomotic biliary strictures after liver transplantation. *Liver Int* 2011;31:1102-1109.
- (42) Dobaczewski M, Xia Y, Bujak M, Gonzalez-Quesada C, Frangogiannis NG. CCR5 signaling suppresses inflammation and reduces adverse remodeling of the infarcted heart, mediating recruitment of regulatory T cells. *Am J Pathol* 2010;176:2177-2187.
- (43) Nozaki T, Rosenblum JM, Schenk AD, Ishii D, Fairchild RL. CCR5 is required for regulation of alloreactive T-cell responses to single class II MHC-mismatched murine cardiac grafts. *Am J Transplant* 2009;9:2251-2261.

- (44) Wysocki CA, Jiang Q, Panoskaltis-Mortari A et al. Critical role for CCR5 in the function of donor CD4+CD25+ regulatory T cells during acute graft-versus-host disease. *Blood* 2005;106: 3300-3307.
- (45) Hertl M, Harvey PR, Swanson PE et al. Evidence of preservation injury to bile ducts by bile salts in the pig and its prevention by infusions of hydrophilic bile salts. *Hepatology* 1995;21: 1130-1137.
- (46) Hoekstra H, Porte RJ, Tian Y et al. Bile salt toxicity aggravates cold ischemic injury of bile ducts after liver transplantation in *Mdr2*<sup>+/-</sup> mice. *Hepatology* 2006;43:1022-1031.
- (47) Knoop M, Schnoy N, Keck H, Neuhaus P. Morphological changes of human common bile ducts after extended cold preservation. *Transplantation* 1993;56:1572-1573.
- (48) Hofmann AF. The continuing importance of bile acids in liver and intestinal disease. *Arch Intern Med* 1999;159:2647-2658.
- (49) Yska MJ, Buis CI, Monbaliu D et al. The role of bile salt toxicity in the pathogenesis of bile duct injury after non-heart-beating porcine liver transplantation. *Transplantation* 2008;85:1625-1631.
- (50) Chen G, Wang SG, Bie P, Li XW, Dong J. Endogenous Bile Salts Are Associated With Bile Duct Injury in the Rat Liver Transplantation Model. *Transplantation* 2009;87:330-339.
- (51) Buis CI, Geuken E, Visser DS et al. Altered bile composition after liver transplantation is associated with the development of nonanastomotic biliary strictures. *J Hepatol* 2009;50:69-79.
- (52) Geuken E, Visser D, Kuipers F et al. Rapid increase of bile salt secretion is associated with bile duct injury after human liver transplantation. *Journal of Hepatology* 2004;41: 1017-1025.
- (53) Xia XF, Francis H, Glaser S, Alpini G, LeSage G. Bile acid interactions with cholangiocytes. *World Journal of Gastroenterology* 2006;12:3553-3563.
- (54) Palmeira CM, Rolo AP. Mitochondrially-mediated toxicity of bile acids. *Toxicology* 2004;203:1-15.
- (55) Cheng L, Zhao L, Li D et al. Role of cholangiocyte bile Acid transporters in large bile duct injury after rat liver transplantation. *Transplantation* 2010;90:127-134.
- (56) Beuers U, Hohenester S, de Buy Wenniger LJ, Kremer AE, Jansen PL, Elferink RP. The biliary HCO<sub>3</sub><sup>-</sup> umbrella: a unifying hypothesis on pathogenetic and therapeutic aspects of fibrosing cholangiopathies. *Hepatology* 2010;52:1489-1496.
- (57) Guimbellot JS, Fortenberry JA, Siegal GP et al. Role of oxygen availability in CFTR expression and function. *Am J Respir Cell Mol Biol* 2008;39:514-521.

# PART **B**

Immune- and Ischemia-mediated Etiologies of Bile Duct Injury



# CHAPTER 4

**Combination of Primary Sclerosing Cholangitis  
and CCR5- $\Delta$ 32 in Recipients is Strongly Associated  
with the Development of Non-anastomotic  
Biliary Strictures after Liver Transplantation**

Op den Dries S, Buis CI, Adelmeijer J, Van der Jagt EJ, Haagsma EB, Lisman T, Porte RJ.

*Liver Int* 2011; 31: 1102-1109.

## ABSTRACT

**Background:** The role of the immune system in the pathogenesis of non-anastomotic strictures (NAS) after orthotopic liver transplantation (OLT) is unclear. A loss-of-function mutation in the chemokine receptor CCR5 (CCR5- $\Delta$ 32) leads to changes in the immune system, including impaired chemotaxis of regulatory T-cells.

**Aim:** To investigate the impact of the CCR5- $\Delta$ 32 mutation on the development of NAS.

**Methods:** In 384 OLTs we assessed CCR5 genotype in donors and recipients and correlated this with the occurrence of NAS.

**Results:** The CCR5- $\Delta$ 32 allele was found in 65 (16.9%) patients. Cumulative incidence of NAS at 5 years was 6.5% in wild-type (Wt) recipients versus 17.2% for carriers of the CCR5- $\Delta$ 32 allele ( $p < 0.01$ ). In recipients with CCR5- $\Delta$ 32, 50% of all NAS occurred  $>2$  years after OLT, compared to 10% in the Wt group. In multivariate regression analysis, the adjusted risk of developing NAS was 4-fold higher in recipients with CCR5- $\Delta$ 32 ( $p < 0.01$ ). The highest risk of NAS was seen in patients transplanted for primary sclerosing cholangitis (PSC), who also carried CCR5- $\Delta$ 32 (RR 5.4, 95% CI 2.2-12.9;  $p < 0.01$ ). Donor CCR5 genotype had no impact on the occurrence of NAS.

**Conclusions:** Patients with the CCR5- $\Delta$ 32 mutation have a 4-fold higher risk of developing NAS, compared with Wt recipients. This risk is even higher in patients with CCR5- $\Delta$ 32 transplanted for PSC. Late development of NAS is significantly more present in patients with CCR5- $\Delta$ 32. These data suggest that the immune system plays a critical role in development of NAS after OLT.

## INTRODUCTION

Biliary complications are a major cause of morbidity and graft failure following orthotopic liver transplantation (OLT) (1,2). Non-anastomotic bile duct strictures (NAS) are regarded the most troublesome biliary complication as they are frequently resistant to therapy and one of the most frequent indications for retransplantation (2-4). The reported incidence of NAS after OLT varies between different studies, ranging from 1-26% (5-10), which can partly be explained by variations in the definition of NAS used in different studies. Despite extensive research, the exact etiological mechanism of NAS remains unclear. However, several risk factors have been identified, strongly suggesting a multifactorial origin.

In general, risk factors for NAS can be divided into three categories: ischemia-related injury to the biliary epithelium, cytotoxic injury, and immune-mediated injury (11). NAS has been associated with various immunological processes, such as ABO-incompatible liver transplantation (12), pre-existing diseases with a presumed autoimmune component (such as primary sclerosing cholangitis [PSC] (1,13,14) and autoimmune hepatitis (1)), cytomegalovirus infection (14,15) and chronic rejection (12). The role of the immune system in the pathogenesis of NAS, however, remains unclear. A loss-of-function mutation in the chemokine receptor CCR5 (CCR5-Δ32) has been associated with functional changes in the immune system, including impaired attraction of regulatory T cells (16-18).

CC chemokine receptor 5 came into worldwide attention about a decade ago when it was identified as one of the major co-receptors for human immunodeficiency virus (HIV) infectivity (19). CCR5 is expressed on the cell surface of natural killer T (NKT) cells, CD4<sup>+</sup> T cells, CD8<sup>+</sup> T cells, macrophages, and regulatory T cells. A 32-bp deletion in this gene (CCR5-Δ32 polymorphism) introduces a premature stop codon into the CCR5 chemokine-receptor locus and thus obliterates the receptor (20). About 10-15% of the European population is a heterozygous carrier of CCR5-Δ32, and about 1% is homozygous for CCR5-Δ32 (20,21). Homozygous carriers do not express CCR5 and heterozygous carriers exhibit a diminished expression of CCR5 on the cell surface, in both cases leading to functionally impaired immune cells (20). In the liver, ligands of CCR5 (CCL3, CCL4 or CCL5) are expressed by biliary epithelial cells (22).

To determine whether the immune system is involved in the pathogenesis of NAS we assessed the impact of the CCR5-Δ32 mutation in liver donors and recipients on outcome and the development of NAS after OLT.

## PATIENTS AND METHODS

### Patients

Between May 1992 and June 2006, a total of 681 liver transplantations were performed at the University Medical Center Groningen. Peripheral blood from 568 patients was available for

genotyping. After the exclusion of children (age <18) and patients with NAS caused by hepatic artery thrombosis, 384 transplant procedures remained for inclusion in this study. In 354 cases, splenocytes from the corresponding donors were available for genotyping. The follow-up period ended on the 1<sup>st</sup> of August 2009, which yielded a minimum post-transplant follow-up of 4.3 years. Clinical information was obtained from a prospectively collected database. Where necessary, missing information was obtained from the original, electronic patient files. Patient survival was defined as the time period (in years) between transplantation and death of the recipient. Graft survival was defined as the time period (in years) between transplantation and retransplantation, or death of the recipient. This study was conducted in accordance with Dutch legislation and the local ethical committee guidelines.

### **Definition of NAS**

NAS were defined as strictures, dilatations, or irregularities of the intra- or extrahepatic bile ducts of the liver graft. Isolated strictures at the bile duct anastomosis were excluded. The diagnosis of NAS was based on at least one adequate imaging study of the biliary tree, after exclusion of hepatic artery thrombosis by either Doppler ultrasound or conventional angiography. Imaging studies of the arterial vasculature were repeated over time if no other explanation for the NAS was found and to confirm patency of the hepatic artery. Minor isolated biliary irregularities, previously scored by our group as mild NAS, were not defined as NAS in this study (23). The time of first presentation of NAS was recorded for all patients.

### **Genotype Analysis**

The CCR5 gene location is on the short (p) arm at position 21 on chromosome 3. Genotypes were determined by polymerase chain reaction (PCR) allelic discrimination. Each assay required two unlabeled primers (Life Technologies, Foster City, CA, USA) and two allele-specific probes (PE Biosystems, Foster City, CA, USA), and the PCR was accomplished using Taqman universal master mix (PE Biosystems). A detailed description has been published previously (24). Patients were divided in two groups according to their CCR5 genotype: those homozygous for the major allele (non-carriers or wild-type) and those with 1 or 2 deletion alleles (carriers). Patients carrying one or two deletion alleles were grouped together, as the number of homozygous CCR5-Δ32 carriers was too small to be analyzed as a separate group. The same methodology was used to group patients based on donor CCR5 genotyping.

### **Statistical Analysis**

Continuous variables were presented as median and interquartile range, whereas categorical variables were presented as number and percentage. Patient and graft survival curves and the cumulative incidence of NAS were calculated using the Kaplan-Meier method and compared using the log rank test. Categorical variables were compared with the Pearson chi-square test or



Fisher's exact test where appropriate. Comparison of continuous variables was performed by the Mann-Whitney *U*-test. The level of significance was set at 0.05. A multivariate logistic regression analysis was performed to determine independent risk factors and relative risks. Statistical analyses were performed using SPSS software version 16.0 for Windows (SPSS, Inc., Chicago, IL).

## RESULTS

### Recipient Characteristics

Donor and recipient characteristics, surgical variables, and postoperative outcomes are presented in **Table 1**. Of 384 recipients tested, 2 (0.5%) recipients were homozygous for the CCR5-Δ32 allele, 63 (16.4%) were heterozygous, and 319 (83.1%) were homozygous for the Wt allele. Of the 354 donors tested, 1 (0.3%) donor was homozygous for the CCR5-Δ32 allele, 73 (20.6%) were heterozygous, and 280 (79.1%) were homozygous for the Wt allele. The median postoperative follow-up was 10.7 years (interquartile range, 7.7-13.8 years).

### Cumulative Incidence of NAS and Impact of Donor and Recipient CCR5 Genotype

Non-anastomotic strictures were observed in 28 of 384 (7.3%) transplanted livers at a median time interval of 4.1 months (interquartile range, 1.2 - 24.4 months) after transplantation.

Donor CCR5 genotype was not associated with development of NAS (**Figure 1A**). However, CCR5 genotype in recipients was strongly associated with development of NAS (**Figure 1B**). The cumulative incidence of NAS at 5 years after OLT was 6.5% in recipients with CCR5 Wt versus 17.2% for carriers of the CCR5-Δ32 allele. Interestingly, the time interval between OLT and the occurrence of NAS was different in recipients with CCR5-Δ32, compared to recipients with CCR5 Wt. In recipients with CCR5 Wt, only 10% of all cases of NAS occurred > 2 years after OLT. In the recipients with CCR5-Δ32, 50% of the cases of NAS occurred > 2 years after OLT.

### Recipient CCR5-Δ32 Is an Independent Risk Factor for NAS

In a univariate analysis, CCR5-Δ32 was significantly associated with the development of NAS (15.4% vs. 5.6% in the CCR5 Wt group;  $p = 0.006$ ). The following variables, which were previously reported in other studies as important risk factors for the development of NAS, were subsequently included in a multivariate logistic regression model together with CCR5-Δ32: PSC as the indication for transplantation; postoperative CMV infection; type of donor (donation after brain death [DBD] versus donation after cardiac death [DCD] and living donor liver grafts); type of preservation solution (high-viscosity University of Wisconsin solution versus low-viscosity histidine-tryptophan-ketoglutarate solution); and warm and cold ischemia times (1,14,23,25). In this multivariate regression analysis, only two variables were identified as independent risk factors for NAS: CCR5-Δ32 and postoperative cytomegalovirus infection (**Table 2**).



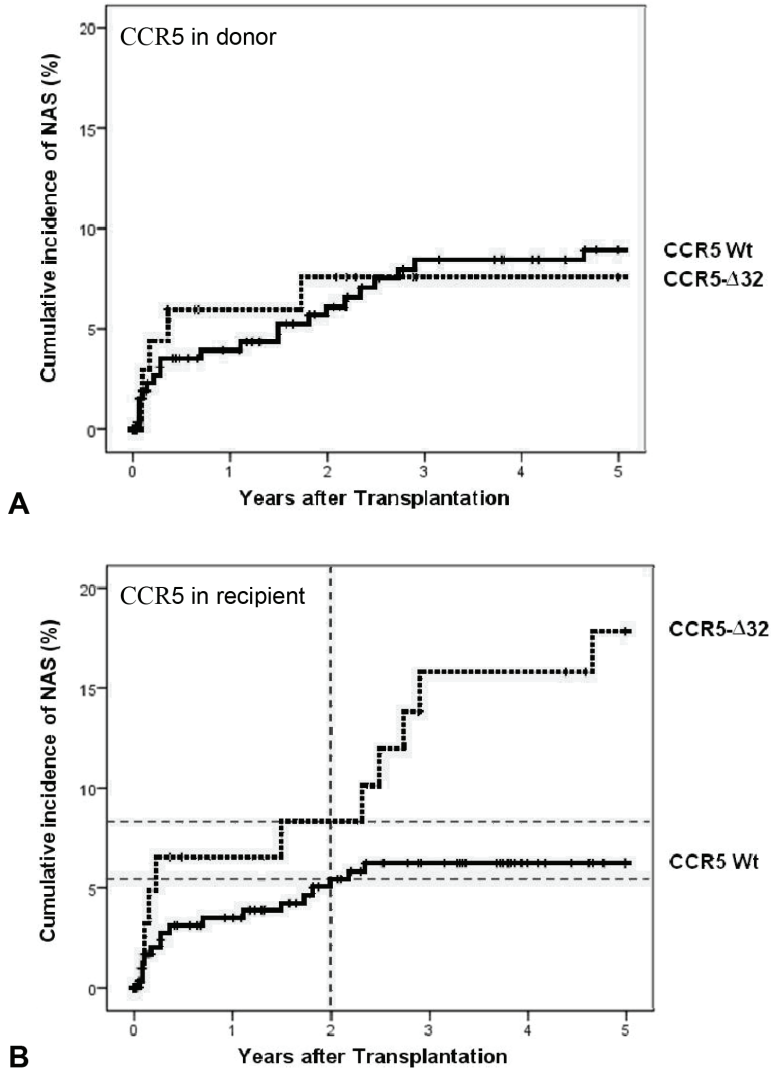
**Table 1.** Comparison of Donor, Recipient, Surgical, and Postoperative Variables in OLT Recipients With or Without the CCR5-Δ32 Polymorphism

Characteristics*	CCR5 wild-type (n=319)	CCR5-Δ32 (n=65)**	P-value
<i>Donor variables:</i>			
Age (years)	43 (32-52)	42 (26-50)	0.315
Gender (male/female)	148/162 (46.4/5.8%)	29/29 (44.6/44.6%)	0.752
Gender match (donor/recipient):			0.924
Male/male	91 (28.5%)	16 (24.6%)	
Female/female	81 (25.4%)	14 (21.5%)	
Male/female	58 (18.2%)	13 (20.0%)	
Female/male	80 (25.1%)	15 (23.1%)	
Type of donor:			0.756
Deceased brain death	309 (96.9%)	64 (98.5%)	
Donation after cardiac death	9 (2.8%)	1 (1.5%)	
Living donor	1 (0.3%)	0 (0%)	
<i>Recipient variables:</i>			
Age (years)	47 (37-55)	48 (38-53)	0.447
Gender (male/female)	175/144 (54.9/45.1%)	36/29 (55.4/44.6%)	0.938
Disease:			
PSC	61 (19.1%)	16 (24.6%)	0.313
PBC + SBC	34 (10.7%)	10 (15.4%)	0.276
Postviral cirrhosis	53 (16.6%)	8 (12.3 %)	0.387
Autoimmune hepatitis	27 (8.5%)	7 (10.8%)	0.551
Alcoholic cirrhosis	36 (11.3%)	2 (3.1%)	0.043
Cryptogenic cirrhosis	38 (11.9%)	3 (4.6%)	0.083
Other	70 (21,9 %)	19 (29.2%)	0.204
Child-Pugh Classification			0.786
Child A/B/C)	53 (16.6%)	10 (15.4%)	
Child B	149 (46.7%)	33 (50.8%)	
Child C	116 (36.4%)	21 (32.3%)	
Retransplantation	25 (7.8%)	2 (3.1%)	0.171
<i>Surgical variables:</i>			
Type of graft:			0.737
Whole	311 (97.5%)	63 (96.9%)	
Reduced	2 (0.6%)	1 (1.5%)	
Reduced split	6 (1.9%)	1 (1.5%)	
Type of preservation solution:			0.786
Low-viscosity (HTK)	17 (5.3%)	4 (6.2%)	
High-viscosity (UW)	298 (93.4%)	60 (92.3%)	
Ischemia time (minutes):			
Cold ischemia	564 (439-724)	515 (446-707)	0.618
Warm ischemia	54 (45-64)	51 (43-60)	0.131
Type of bile duct reconstruction:			0.263
Roux-en-Y	42 (13.2%)	14 (21.5%)	
Duct-to-duct	270 (84.6%)	50 (76.9%)	
Duct-duodenostomy	3 (0.9%)	1 (1.5%)	
Not performed	4 (1.4%)	0 (0%)	
<i>Postoperative variables:</i>			
Serum AST on POD 2 (U/L)	366 (171-847)	317 (168-784)	0.699
CMV infection	152 (47.6%)	25 (38.5%)	0.218
Acute cellular rejection	124 (38.9%)	26 (40%)	0.865

\*) Continuous variables are presented as median and interquartile range, whereas categorical variables are presented as number and percentage. Statistical analyses were performed using Mann-Whitney U test for continuous variables, Pearson chi-square was used for categorical variables.

\*\*) 63 heterogous for CCR5-Δ32, 2 patients were homozygous for CCR5-Δ32)

**Abbreviations table 1:** CCR5, CC chemokine receptor 5; AST, aspartate aminotransferase; CMV, cytomegalovirus; HTK, histidine-tryptophan-ketoglutarate; ICU, intensive care unit; PBC, primary biliary cirrhosis; POD, postoperative day; PSC, primary sclerosing cholangitis; SBC, secondary biliary cirrhosis; UW, University of Wisconsin.



**Figure 1.** Cumulative incidence of NAS. **(A)** CCR5Δ32 in the donor is not associated with development of NAS (log-rank,  $p = 0.82$ ). **(B)** CCR5Δ32 in recipients is associated with development of NAS (log-rank,  $p < 0.01$ ). In patients with CCR5 Wt, only 10% of all cases of NAS occurred late (> 2 years) after transplantation. In contrast with this, in patients with CCR5Δ32, 50% of all cases of NAS were detected > 2 years after transplantation.

**Table 2.** Multivariate Logistic Regression Analysis of Risk Factors for Non-anastomotic Bile Duct Strictures

Risk factors	RR	95% CI	P-value
CCR5-Δ32	4.047	1.698 - 9.643	<b>0.002</b>
CMV infection	3.905	1.572 - 9.698	<b>0.003</b>
PSC	1.775	0.719 - 4.379	0.213
Cold ischemia time	0.999	0.997 - 1.002	0.484
Warm ischemia time	1.010	0.979 - 1.041	0.543
Preservation solution (UW vs HTK)	0.593	0.062 - 5.660	0.650
Donor type (DCD vs DBD/LD)	5.515	0.906 - 33.572	0.064

**Abbreviations:** CCR5, CC chemokine receptor 5; NAS, non-anastomotic strictures; RR, relative risk; CI, confidence interval; PSC, primary sclerosing cholangitis; CMV, cytomegalovirus; UW, University of Wisconsin. HTK, histidine-tryptophan-ketoglutarate; DBD, deceased brain death; DCD, donation after cardiac death; LD, living donor.

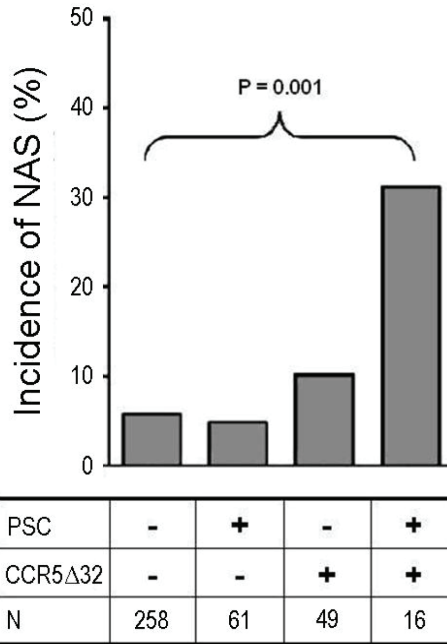
### Combination of CCR5-Δ32 and PSC Is Highly Predictive for NAS

In previous studies, PSC as the indication for transplantation was identified as an independent risk factor for NAS (1,14). As described above, PSC was not identified as an independent risk factor when CCR5-Δ32 was included in the analysis. However, when CCR5-Δ32 was excluded from the multivariate logistic regression, PSC was present as independent risk factor (data not shown). We therefore examined the relationship between PSC and CCR5-Δ32. Although there were no differences in the distribution of CCR5-Δ32 in patients with or without PSC (**Table 1**), the combination of CCR5-Δ32 and PSC was associated with a significantly higher incidence of NAS (**Figure 2**). In patients without CCR5-Δ32 and not transplanted for PSC, 5.8% developed NAS. In patients without CCR5-Δ32, but transplanted for PSC, a similar percentage developed NAS (4.9%). Patients carrying CCR5-Δ32, but not transplanted for PSC, had a higher incidence of NAS (10.2%), but most interestingly, recipients with CCR5-Δ32 and transplanted for PSC developed NAS in 31.2% of the cases.

### CCR5-Δ32 Is Associated with Higher Retransplantation Rate

Retransplantation rate within the first year after OLT was significantly higher in recipients carrying CCR5-Δ32 compared with recipients with CCR5 Wt (10.8% versus 2.5%;  $p < 0.01$ ). The most frequent indications for retransplantation in recipients carrying CCR5-Δ32 were HAT (4.6% vs 0.0% in recipients with CCR5 Wt;  $p < 0.01$ ) and NAS (4.6% vs 0.6% in recipients with CCR5 Wt;  $p = 0.01$ ) (**Table 3**).

Despite disadvantageous associations between CCR5-Δ32 and the development of NAS and a higher retransplantation rate in recipients with CCR5-Δ32, the 5-year patient survival rate in recipients carrying CCR5-Δ32 was significantly higher than the 5-year patient survival rate in CCR5 Wt recipients (90.8% versus 76.5%;  $p = 0.01$ ) (**Figure 3**). Analysis of the causes of death revealed no major differences between the two groups, apart from a lower incidence of infection-related mortality in recipients carrying CCR5-Δ32 (3.1% vs. 9.7%;  $p = 0.08$ ) (**Table 4**).

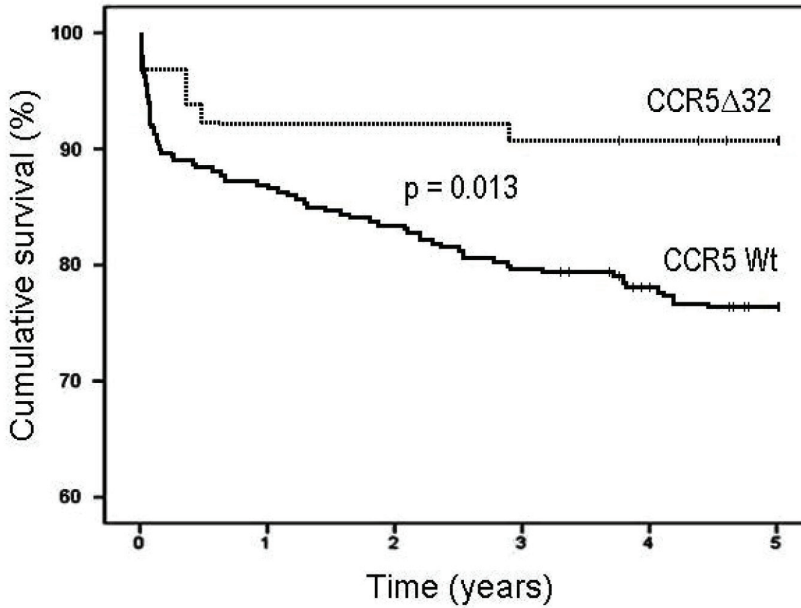


**Figure 2.** Development of non-anastomotic biliary strictures in recipients with/without PSC and with/without CCR5-Δ32. The combination of both CCR5-Δ32 and PSC was associated with a significantly higher incidence of NAS after OLT (overall Pearson chi-square,  $p = 0.001$ ).

**Table 3.** Causes of Graft Loss Leading to Replantation Within One-Year After Liver Transplantation in Recipients Carrying CCR5-Δ32 vs CCR5 Wild-type

Reason re-OLT	CCR5 Wt (n=319)	CCR5-Δ32 (n=65)	P-value
Re-OLT	8 (2.5%)	7 (10.8%)	<b>0.002</b>
HAT	0 (0.0%)	3 (4.6%)	<b>&lt; 0.001</b>
PNF	0 (0.0%)	1 (1.5%)	<b>0.027</b>
NAS	2 (0.6%)	3 (4.6%)	<b>0.010</b>
Rejection	6 (1.9%)	0 (0.0%)	0.265

**Abbreviations:** CCR5, CC chemokine receptor 5; Wt, wild type; HAT, hepatic artery thrombosis; PNF, primary non function; NAS, non-anastomotic strictures.



**Figure 3.** Patient survival after liver transplantation in recipients carrying CCR5-Δ32 versus Wild-type CCR5. The 5-year patient survival rate was significantly higher in patients carrying CCR5-Δ32, compared with CCR5 Wild-type patients (90.8% versus 76.5%; log-rank test  $p = 0.013$ ).

**Table 4.** Causes of Death Within Five-Years After Liver Transplantation in Recipients Carrying CCR5-Δ32 vs CCR5 Wild-type

Causes of death	CCR5 wild-type (n=319)	CCR5-Δ32 (n=65)	P-value
Alive	244 (76.5%)	59 (90.8%)	<b>0.01</b>
Graft-related	14 (4.4%)	1 (1.5%)	0.280
Cardiac	5 (1.6%)	1 (1.5%)	0.986
Infections	31 (9.7%)	2 (3.1%)	<b>0.082</b>
Malignancies	3 (0.9%)	0 (0.0%)	0.433
Cerebral-vascular	7 (2.2%)	1 (1.5%)	0.736
GI haemorrhage	4 (1.3%)	0 (0.0%)	0.364
Miscellaneous	11 (3.4%)	1 (1.5%)	0.420

**Abbreviations:** CCR5, CC chemokine receptor 5; GI, gastro-intestinal.

## DISCUSSION

The role of the immune system in the pathogenesis of NAS is unclear. In T-cell-mediated liver diseases such as autoimmune and viral liver diseases, CCR5 and its respective ligands have been implicated in the recruitment of effector T cell subtypes into the liver, as well as their modulation of the inflammatory response (22). Recent studies have indicated that CCR5 plays a critical role in chemotaxis of regulatory T cells to the site of injury (16-18). In the current study, a functional mutation of the CCR5 gene (CCR5-Δ32) was assessed with the aim to find proof for involvement of the immune system in the pathogenesis of NAS after OLT.

Patients with the CCR5-Δ32 mutation had a 4-fold higher risk of developing NAS, compared with Wt recipients. This risk was even higher in patients with CCR5-Δ32 transplanted for PSC. Moreover, late development of NAS was significantly more present in patients with CCR5-Δ32 compared with Wt patients. Donor CCR5 genotype was not associated with development of NAS. These data suggest that the immune system of the recipient plays a critical role in development of NAS especially late (> 2 years) after OLT.

The significantly higher incidence of NAS in recipients with CCR5-Δ32 may be explained by an immunological imbalance caused by the lack of a functional CCR5 in these patients. CCR5 deficiency in humans, as well as in experimental animal models of inflammation and infection, is associated with significant increases of tissue levels of CCR5 ligand CCL5, which promotes enhanced influx of T cells into tissues by binding to one of its alternative receptors, CCR1 (19,26-28). Moreover, the CCR5-Δ32 mutation has been associated with impaired attraction of regulatory T cells to the site of tissue injury (16-18). Regulatory T cells reduce inflammation and suppress activation of potentially harmful, self-reactive lymphocytes. The strong association between CCR5-Δ32 and NAS observed in the current study could therefore possibly be explained by an increased inflammatory response of the host towards the biliary epithelium of the liver graft. We speculate that this increased response may subsequently lead to bile duct injury and the development of biliary strictures.

Moench *et al.* first described an association between CCR5-Δ32 in recipients and the occurrence of NAS after liver transplantation (6), but these findings were not confirmed by a study of Heidenhain *et al.* Both studies, however, included a relatively small number of transplant procedures (146 and 169, respectively), whereas 384 cases were included in the current study. Moreover, the minimum post-transplant follow-up in the study of Heidenhain *et al.* was only 2 years and 11 patients with established diagnosis of NAS were selectively included into the study due to a low incidence of NAS. The minimum post-transplant follow-up in the current study was 4.3 years.

In addition to a higher incidence of NAS in recipients with CCR5-Δ32, the time of development differed from CCR5 Wt recipients. In recipients with CCR5 Wt only 10% of the cases of NAS were detected >2 years after transplantation. In contrast, in recipients with CCR5-Δ32 50% of

the cases occurred >2 years after OLT. This finding is in accordance with a previously suggested hypothesis that the underlying cause of early NAS might be different from the etiology of late NAS (23). While NAS occurring early after OLT has been suggested to have a predominant (post-) ischemia-mediated pathogenesis, NAS occurring late after OLT may be more frequently immune-mediated in origin (23). The latter is in accordance with the observed higher incidence of late NAS in recipients with CCR5- $\Delta$ 32 in the current study.

Interestingly, the strong association between CCR5- $\Delta$ 32 and NAS was most pronounced in patients transplanted for PSC. In previous studies, PSC has been identified as an important, and in some studies even as an independent, risk factor for NAS (1,13,14,29). In the current study, we were not able to identify PSC as an independent risk factor for the development of NAS when CCR5- $\Delta$ 32 was included as a co-variable in the multivariate logistic regression model. However, in a more detailed analysis of the interaction between PSC and CCR5- $\Delta$ 32, we found that CCR5- $\Delta$ 32 has a greater impact in patients transplanted for PSC than in patients transplanted for other diseases. While PSC alone was not a risk factor for NAS, the combination of PSC and CCR5- $\Delta$ 32 resulted in a dramatically increased incidence of NAS. This finding may very well explain the observed correlation between PSC and NAS in previous studies.

Recipients carrying CCR5- $\Delta$ 32 showed a higher retransplantation rate within the first year after OLT, compared with recipients carrying CCR5 Wt. The overall graft survival, however, was similar in the two groups. HAT and NAS as a reason for graft loss were significantly more present in the CCR5- $\Delta$ 32 group, but patients survived because they were retransplanted.

The observed positive association between CCR5- $\Delta$ 32 and excellent long-term patient survival after OLT may be explained by a protection against infection-related mortality. Infections as cause of death were less prevalent in recipients carrying CCR5- $\Delta$ 32, compared with CCR5 Wt recipients, although this difference did not reach statistical significance. A protective role for CCR5- $\Delta$ 32 in infectious (especially viral) and inflammatory diseases outside the setting of liver transplantation is well described in several studies (30-32). The exact mechanisms underlying this apparently protective effect of CCR5- $\Delta$ 32 in infectious diseases remain unclear.

The higher incidence of NAS in recipients carrying CCR5- $\Delta$ 32 and especially the pronounced risk present in recipients with both CCR5- $\Delta$ 32 and PSC (30% NAS) are of significant clinical relevance. The clinical consequences of our findings might involve donor organ selection for these recipients. One might want to avoid the use of donor organs with increased risk of NAS such as livers derived from DCD donors in recipients with both CCR5- $\Delta$ 32 and PSC. More research in this direction, especially in patients who received a liver from a DCD donor is warranted.

This study is limited by its retrospective design. Imaging of the biliary tree was not performed routinely at regular time intervals after OLT and imaging was always guided by clinical symptoms or laboratory abnormalities. Therefore, asymptomatic biliary lesions might have been missed. The overall incidence of NAS in the current study was 7.3%, which is lower than previously reported by our group, but similar to percentages are reported in other studies (5,9,10). This difference

can be explained by differences in the definition of NAS. In the current study, minor biliary irregularities were not included in the definition of NAS.

In summary, this study provides evidence that the immune system plays a critical role in the development of NAS after OLT. A loss-of-function mutation in the chemokine receptor CCR5 (CCR5-Δ32) leads to changes in the immune system, including impaired chemotaxis of regulatory T-cells. Patients with CCR5-Δ32 had a 4-fold higher risk of developing NAS, compared with CCR5 Wt recipients. This risk was even higher in CCR5-Δ32 carrying patients transplanted for PSC. In addition, retransplantation for NAS was seen more frequently in patients with CCR5-Δ32 and more late development of NAS occurred in patients with CCR5-Δ32. These data suggest a critical role for the immune system in development of NAS after OLT and warrant further clinical and experimental studies to define the role of CCR5 in the development of bile duct injury.

## REFERENCES

- (1) Guichelaar MM, Benson JT, Malinchoc M, Krom RA, Wiesner RH, Charlton MR. Risk factors for and clinical course of non-anastomotic biliary strictures after liver transplantation. *Am J Transplant* 2003;3:885-90.
- (2) Verdonk RC, Buis CI, van der Jagt EJ, Gouw AS, Limburg AJ, Slooff MJ et al. Nonanastomotic biliary strictures after liver transplantation, part 2: Management, outcome, and risk factors for disease progression. *Liver Transpl* 2007;13:725-32.
- (3) Colonna JO, Shaked A, Gomes AS, Colquhoun SD, Jurim O, McDiarmid SV et al. Biliary strictures complicating liver transplantation. Incidence, pathogenesis, management, and outcome. *Ann Surg* 1992;216:344-50.
- (4) Sharma S, Gurakar A, Jabbour N. Biliary strictures following liver transplantation: past, present and preventive strategies. *Liver Transpl* 2008;14:759-69.
- (5) Heidenhain C, Pratschke J, Puhl G, Neumann U, Pascher A, Veltzke-Schlieker W, Neuhaus P. Incidence of and risk factors for ischemic-type biliary lesions following orthotopic liver transplantation. *Transpl Int* 2010; 23:14-22.
- (6) Moench C, Uhrig A, Lohse AW, Otto G. CC chemokine receptor 5delta32 polymorphism-a risk factor for ischemic-type biliary lesions following orthotopic liver transplantation. *Liver Transpl* 2004; 10:434-9.
- (7) Heidenhain C, Puhl G, Moench C, Lautem A, Neuhaus P. Chemokine receptor 532 mutation reduces the risk of acute rejection in liver transplantation. *Ann Transplant* 2009; 14:36-44.
- (8) Sanchez-Urdazpal L, Gores GJ, Ward EM, Maus TP, Buckel EG, Steers JL et al. Diagnostic features and clinical outcome of ischemic-type biliary complications after liver transplantation. *Hepatology* 1993; 17:605-9.



- (9) Nemeč P, Ondrasek J, Studenik P, Hokl J, Cerny J. Biliary complications in liver transplantation. *Ann Transplant* 2001;6:24-8.
- (10) Thethy S, Thomson BN, Pleass H, Wigmore SJ, Madhavan K, Akyol M et al. Management of biliary tract complications after orthotopic liver transplantation. *Clin Transplant* 2004;18:647-53.
- (11) Buis CI, Hoekstra H, Verdonk RC, Porte RJ. Causes and consequences of ischemic-type biliary lesions after liver transplantation. *J Hepatobiliary Pancreat Surg* 2006;13:517-24.
- (12) Rull R, Garcia Valdecasas JC, Grande L, Fuster J, Lacy AM, Gonzalez FX et al. Intrahepatic biliary lesions after orthotopic liver transplantation. *Transpl Int* 2001; 14:129-34.
- (13) Feller RB, Waugh RC, Selby WS, Dolan PM, Sheil AG, McCaughan GW. Biliary strictures after liver transplantation: clinical picture, correlates and outcomes. *J Gastroenterol Hepatol* 1996;11:21-5.
- (14) Hoekstra H, Buis CI, Verdonk RC, van der Hilst CS, van der Jagt EJ, Haagsma EB, Porte RJ. Is Roux-en-Y choledochojejunostomy an independent risk factor for nonanastomotic biliary strictures after liver transplantation? *Liver Transpl* 2009;15:924-30.
- (15) Halme L, Hockerstedt K, Lautenschlager I. Cytomegalovirus infection and development of biliary complications after liver transplantation. *Transplantation* 2003;75:1853-8.
- (16) Dobaczewski M, Xia Y, Bujak M, Gonzalez-Quesada C, Frangogiannis NG. CCR5 signaling suppresses inflammation and reduces adverse remodeling of the infarcted heart, mediating recruitment of regulatory T cells. *Am J Pathol* 2010;176:2177-87.
- (17) Nozaki T, Rosenblum JM, Schenk AD, Ishii D, Fairchild RL. CCR5 is required for regulation of alloreactive T-cell responses to single class II MHC-mismatched murine cardiac grafts. *Am J Transplant* 2009; 9:2251-61.
- (18) Wysocki CA, Jiang Q, Panoskaltis-Mortari A, Taylor PA, McKinnon KP, Su L et al. Critical role for CCR5 in the function of donor CD4+CD25+ regulatory T cells during acute graft-versus-host disease. *Blood* 2005;106:3300-7.
- (19) Locati M, Murphy PM. Chemokines and chemokine receptors: biology and clinical relevance in inflammation and AIDS. *Annu Rev Med* 1999;50:425-40.
- (20) Galvani AP, Novembre J. The evolutionary history of the CCR5-Delta32 HIV-resistance mutation. *Microbes Infect* 2005;7:302-9.
- (21) Galvani AP, Slatkin M. Evaluating plague and smallpox as historical selective pressures for the CCR5-Delta 32 HIV-resistance allele. *Proc Natl Acad Sci U S A* 2003;100:15276-9.
- (22) Ajuebor MN, Carey JA, Swain MG. CCR5 in T cell-mediated liver diseases: what's going on? *J Immunol* 2006;177:2039-45.
- (23) Buis CI, Verdonk RC, van der Jagt EJ, van der Hilst CS, Slooff MJ, Haagsma EB, Porte RJ. Nonanastomotic biliary strictures after liver transplantation, part 1: Radiological features and risk factors for early vs. late presentation. *Liver Transpl* 2007;13:708-18.
- (24) Clark VJ, Metheny N, Dean M, Peterson RJ. Statistical estimation and pedigree analysis of CCR2-CCR5 haplotypes. *Hum Genet* 2001;108:484-93.

- (25) Maheshwari A, Maley W, Li Z, Thuluvath PJ. Biliary complications and outcomes of liver transplantation from donors after cardiac death. *Liver Transpl* 2007;13:1645-53.
- (26) Ajuebor MN, Wondimu Z, Hogaboam CM, Le T, Proudfoot AE, Swain MG. CCR5 deficiency drives enhanced natural killer cell trafficking to and activation within the liver in murine T cell-mediated hepatitis. *Am J Pathol* 2007; 70:1975-88.
- (27) Dawson TC, Beck MA, Kuziel WA, Henderson F, Maeda N. Contrasting effects of CCR5 and CCR2 deficiency in the pulmonary inflammatory response to influenza A virus. *Am J Pathol* 2000;156:1951-9.
- (28) Carr DJ, Ash J, Lane TE, Kuziel WA. Abnormal immune response of CCR5-deficient mice to ocular infection with herpes simplex virus type 1. *J Gen Virol* 2006;87:489-99.
- (29) Sheng R, Zajko AB, Campbell WL, Abu-Elmagd K. Biliary strictures in hepatic transplants: prevalence and types in patients with primary sclerosing cholangitis vs those with other liver diseases. *AJR Am J Roentgenol* 1993;161:297-300.
- (30) Muntinghe FL, Verduijn M, Zuurman MW, Grootendorst DC, Carrero JJ, Qureshi AR et al. CCR5 deletion protects against inflammation-associated mortality in dialysis patients. *J Am Soc Nephrol* 2009;20:1641-9.
- (31) Goulding C, McManus R, Murphy A, MacDonald G, Barrett S, Crowe J et al. The CCR5-delta32 mutation: impact on disease outcome in individuals with hepatitis C infection from a single source. *Gut* 2005;54:1157-61.
- (32) Thio CL, Astemborski J, Bashirova A, Mosbrugger T, Greer S, Witt MD et al. Genetic protection against hepatitis B virus conferred by CCR5Delta32: Evidence that CCR5 contributes to viral persistence. *J Virol* 2007;81:441-5.





# CHAPTER 5

## **The Origin of Biliary Strictures after Liver Transplantation: Is it the Amount of Epithelial Injury or Insufficient Regeneration that Counts?**

Karimian N, op den Dries S, Porte RJ.

*Adapted from: J Hepatol 2013; 58: 1065-1067.*

Biliary complications continue to be a major problem after orthotopic liver transplantation (OLT). The incidence of biliary complications varies between 10% and 40% in different series and this type of complications is associated with frequent hospital admissions and high morbidity and mortality rates (1-3). Among the variety of biliary complications that can occur after OLT, bile duct strictures are of the most concern. Bile duct strictures can be classified as anastomotic strictures (AS) or non-anastomotic strictures (NAS). Solitary strictures at the biliary anastomosis have been reported in 9%-12% of the patients (4-6), and NAS have been reported in 1%-20% of patients receiving a liver from donation after brain death and in up to 30% of patients receiving a liver from donation after cardiac death (DCD) (4,7,8). NAS may occur in the extrahepatic donor bile duct as well as the intrahepatic bile ducts, but they are usually limited to the larger bile ducts. NAS may be accompanied by intraductal biliary sludge and cast formation.

For many years researchers have been trying to understand the underlying mechanisms of AS and NAS. Current evidence suggests that AS are mainly related to the surgical technique and local ischemia of the distal bile duct stump, leading to fibrotic scarring of the anastomosis (1,6). The etiology of NAS is thought to be multifactorial and three relevant types of biliary injury have been identified as a potential cause of NAS: ischemia/reperfusion related injury; immune-mediated injury; and cytotoxic injury caused by hydrophobic bile salts (1, 9). Current understanding of the occurrence of these types of biliary injury is that they originate mainly after transplantation of the liver. Depending on the severity of bile duct injury, the healing process may lead to scar formation and subsequent stricturing of the affected bile duct segments. Thus far, it remains unclear as to which extend bile ducts of donor livers are injured already before transplantation.

In a recent issue of the *Journal of Hepatology*, Brunner *et al.* describe a clinical cohort study including 79 liver transplant procedures in which biopsies were taken from the distal end of the extrahepatic bile duct of the donor liver at the time of organ retrieval and during transplantation (10). Biopsies were evaluated by light microscopy and immunofluorescence to determine the amount of biliary epithelial injury, using a self-developed semi-quantitative bile duct damage scoring system. The investigators subsequently correlated the grade of biliary injury with the occurrence of biliary complications after OLT. The most striking finding in this study was the high percentage of donor livers with severe injury and loss of biliary epithelium in the distal bile duct before implantation. Of all biopsies taken at the end of cold preservation, 86% had signs of bile duct epithelial cell loss. The degree of bile duct injury increased only slightly after reperfusion of the graft. Few clinicians working in the field of clinical liver transplantation are aware of the fact that the vast majority of donor livers have severe bile duct epithelial injury already prior to implantation. Interestingly, Brunner and colleagues also found that their histological bile duct damage score can be helpful to predict development of bile duct complications after transplantation.

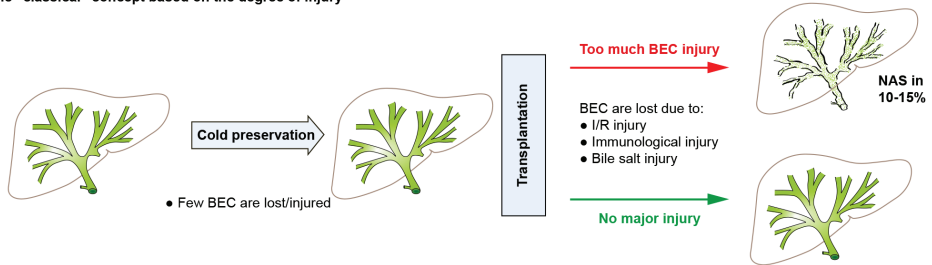
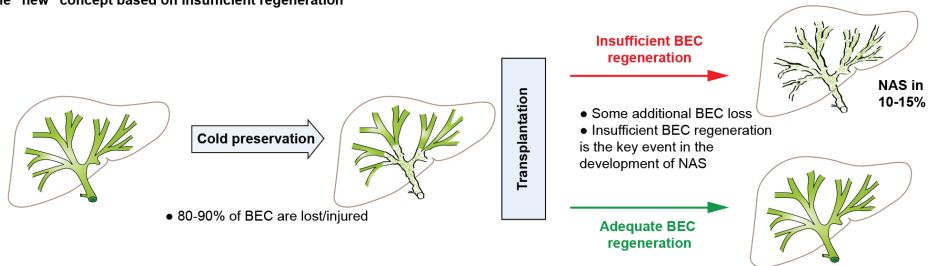
This study is in accordance with another recent clinical study on donor bile duct histology published by Hansen *et al.* (11). In a cohort of 93 liver transplant procedures these investigators also performed histological evaluation of donor bile duct biopsies. In this study biopsies were

taken after graft reperfusion, before constructing the biliary anastomosis. This research group described another histological injury grading system that, in addition to biliary epithelium loss, includes the degree of injury of the peribiliary vascular plexus (arteriolonecrosis and thrombosis) and necrosis of the bile duct wall stroma. Major bile duct epithelial loss was observed in 88% (77/93) of the cases, a percentage that is strikingly similar to the 86% of biliary epithelium loss observed by Brunner *et al.* The results from the study by Hansen and colleagues suggested that the presence of arteriolonecrosis in the bile duct wall is strongly associated with the development of biliary strictures after transplantation (11).

These two studies not only provide evidence that histological assessment of the donor bile duct may help predict the occurrence of biliary strictures after transplantation, they also offer additional perspective from which to view the pathogenesis of these strictures. The high percentage of donor livers with severe biliary epithelial injury before transplantation is striking. In fact, many extrahepatic donor bile ducts appeared to be nothing more than a scaffold of connective tissue without any epithelial lining of the lumen. With this knowledge it is a surprise that not every donor liver develops biliary strictures after OLT. If the vast majority of donor livers already have severe bile duct injury prior to transplantation, yet “only” 10-20% develop NAS or AS, it could very well be that the critical factor that determines whether a graft will develop NAS or not is insufficient biliary regeneration rather than the initial biliary injury. This new perspective from which to view the pathogenesis of biliary strictures is summarized in **Figure 1**.

The study by Brunner *et al.* (10), as well as the recent paper by Hansen *et al.* (11) open interesting new avenues for further research. Firstly, the studies show that current methods of organ preservation are far from sufficient to protect the biliary epithelium and bile duct wall in the time period between organ procurement and transplantation. It is possible that current organ preservation fluids used to flush the bile ducts during procurement are suboptimal to preserve the biliary epithelium. Alternatively, it might be that the current preservation method based on cooling is not the best way to protect the biliary epithelium. The only way to eliminate the need for cooling down an organ during preservation would be normothermic, oxygenated organ perfusion. Our group has recently demonstrated that normothermic, oxygenated perfusion of human donor livers is technically feasible; however, more research in this area is needed to determine whether this will also result in better preservation of the biliary epithelium (12).

Secondly, the papers by Brunner *et al.* and Hansen *et al.* should be seen as a stimulus to study in more detail the processes underlying regeneration of the biliary epithelium. Apparently many livers have adequate and timely restoration of their biliary epithelium, as these livers do not develop biliary strictures despite massive epithelial loss prior to transplantation. Unfortunately, the mechanisms of biliary epithelium regeneration in the larger and extrahepatic bile ducts are not very well known. Most previous research has focused on the smaller, intrahepatic bile ducts and ductules. Studies have suggested a role for the proliferation of remnant biliary epithelial cells, but bipotent stem cells in the canals of Herring (oval cells), bone marrow derived stem

**A** The “classical” concept based on the degree of injury**B** The “new” concept based on insufficient regeneration

**Figure 1. Schematic presentation of the changing perspective on the pathogenesis of biliary strictures after liver transplantation. Panel A.** The “classical” concept based on the degree of biliary epithelial injury. Few biliary epithelial cells (BEC) are damaged and lost during cold preservation and most part of biliary damage occurs after transplantation due to reperfusion injury, immunological causes and hydrophobic bile salt toxicity. **Panel B.** The “new” concept based on insufficient regeneration of the biliary epithelium. Biliary injury and cell loss is almost universally present in all donor livers. Yet only a minority of livers develop biliary strictures, suggesting that regeneration of the biliary epithelium is rapid and successful in most donors livers. The key question that arises from this novel perspective is “what determines successful regeneration of the biliary epithelium and how can we stimulate adequate regeneration in all livers?”

cells, and peribiliary glands could be involved as well (13,14). If the mechanisms of successful reepithelialization of the large and extrahepatic bile ducts are better understood, therapeutic strategies to stimulate regeneration in all livers could potentially be developed. For example, preconditioning of livers to stimulate regeneration of biliary epithelium before transplantation by flushing the bile duct with growth factors or mesenchymal stem cells is an interesting option that needs further exploration.

Thirdly, there is a need to develop non-invasive methods that enable assessment of the biliary epithelium during organ preservation and before implantation. Histological examinations can only be performed by taking biopsies from the distal end of the donor bile duct. It is impossible to obtain biopsies from the more proximal or intrahepatic bile ducts without risk for the graft and recipients. An attractive alternative could be the development of molecular imaging techniques using near-infrared fluorescence that allow a non-invasive assessment of the biliary epithelium. If such molecular imaging techniques are combined with visible light cholangioscopy this



could provide an intraoperative tool for surgeons to judge viability of the biliary tree prior to transplantation (15).

This also touches on a limitation of the study by Brunner *et al*: specimens were only taken from the distal free margin of the extrahepatic bile ducts. It remains unknown whether injury detected in these specimens is representative for the epithelial lining higher up in the biliary tree. In addition, the series reported by these investigators did not include DCD livers and it would be very interesting to know the type and degree of bile duct injury in that type of donor livers prior to transplantation.

In conclusion, the study presented by Brunner *et al* (10), together with the recent data published by Hansen *et al* (11), gives important new information on preservation injury of the bile ducts in human liver transplantation. These studies provide new perspective from which to view biliary injuries and the development of strictures after transplantation. If loss of the biliary epithelium and injury of the bile duct wall is so universally present in human donor livers, yet (fortunately) only a minority develops biliary strictures after transplantation, an important new question that arises is: 'Why does regeneration of biliary epithelium fail in certain livers and how can we stimulate the regenerative capacity of the biliary epithelium after OLT?'

## REFERENCES

- (1) Op den Dries S, Sutton ME, Lisman T, Porte RJ. Protection of bile ducts in liver transplantation: looking beyond ischemia. *Transplantation* 2011;92:373-379.
- (2) Buck D G, Zajko AB. Biliary complications after orthotopic liver transplantation. *Tech Vasc Interv Radiol* 2008;11:51-59.
- (3) Verdonk R C, Buis CI, Porte RJ, Haagsma EB. Biliary complications after liver transplantation: a review. *Scand J Gastroenterol Suppl* 2006;243:89-101.
- (4) Gastaca M. Biliary complications after orthotopic liver transplantation: a review of incidence and risk factors. *Transplant Proc* 2012;44:1545-1549.
- (5) Verdonk R C, Buis CI, Porte RJ, van der Jagt EJ, Limburg AJ, van den Berg AP et al. Anastomotic biliary strictures after liver transplantation: causes and consequences. *Liver Transpl* 2006;12:726-735.
- (6) Jagannath S, Kalloo AN. Biliary Complications After Liver Transplantation. *Curr Treat Options Gastroenterol* 2002;5:101-112.
- (7) Sanchez-Urdazpal L, Gores GJ, Ward EM, Maus TP, Wahlstrom HE, Moore SB et al. Ischemic-type biliary complications after orthotopic liver transplantation. *Hepatology* 1992;16:49-53.
- (8) Dubbeld J, Hoekstra H, Farid W, Ringers J, Porte RJ, Metselaar HJ et al. Similar liver transplantation survival with selected cardiac death donors and brain death donors. *Br J Surg* 2010;97:744-753.
- (9) Buis C I, Hoekstra H, Verdonk RC, Porte RJ. Causes and consequences of ischemic-type biliary lesions after liver transplantation. *J Hepatobiliary Pancreat Surg* 2006; 13:517-524.



- (10) Brunner S M, Junger H, Ruemmele P, Schnitzbauer AA, Doenecke A, Kirchner GI et al. Bile duct damage after cold storage of deceased donor livers predicts biliary complications after liver transplantation. *J Hepatol* 2013;58:1133-9.
- (11) Hansen T, Hollemann D, Pitton MB, Heise M, Hoppe-Lotichius M, Schuchmann M et al. Histological examination and evaluation of donor bile ducts received during orthotopic liver transplantation--a morphological clue to ischemic-type biliary lesion? *Virchows Arch* 2012;461:41-48.
- (12) Op den Dries S, Karimian N, Sutton ME, Westerkamp AC, Nijsten MWN, Gouw ASH et al. Ex-vivo normothermic machine perfusion and viability testing of discarded human livers. *Am J Transplant* 2013;13:1327-1335.
- (13) Demetris AJ, Lunn JG, Specht S, Nozaki I. Biliary wound healing, ductular reactions, and IL-6/gp130 signaling in the development of liver disease. *World J Gastroenterol* 2006;12:3512-3522.
- (14) Sutton ME, op den Dries S, Koster MH, Lisman T, Gouw ASH, Porte RJ. Regeneration of human extrahepatic biliary epithelium: the peribiliary glands as progenitor cell compartment. *Liver Int* 2012;32:554-559.
- (15) Moon JH, Terheggen G, Choi HJ, Neuhaus H. Peroral cholangioscopy: diagnostic and therapeutic applications. *Gastroenterology* 2013;144:276-282.



# CHAPTER 6

## **Regeneration of Human Extrahepatic Biliary Epithelium: The Peribiliary Glands as Progenitor Cell Compartment**

Sutton ME, op den Dries S, Koster MH, Lisman T, Gouw ASH, Porte RJ.

*Liver Int 2012; 32: 554-559.*

**ABSTRACT**

**Background & Aims:** Although regeneration of intrahepatic bile ducts has been extensively studied and intrahepatic progenitor cells have been identified, few studies have focussed on the extrahepatic bile duct (EHBD). We hypothesized that local progenitor cells are present within the EHBD of humans. Human EHBD specimens (n=17) were included in this study.

**Methods:** Specimens of normal EHBD tissue were obtained from healthy donor livers (n=6), mildly injured EHBD from patients with cholangitis (n=6) and severely injured EHBD from patients with ischemic type biliary lesions (n=5). Double immunostaining for K19 and the proliferation marker Ki-67 was performed to identify and localize proliferating cells. In addition, immunofluorescent doublestaining using antibodies against K19 and c-Kit was performed to identify and localize cholangiocytes co-expressing putative progenitor cell markers.

**Results:** In normal EHBD, few Ki-67<sup>+</sup> cells were detected, whereas large numbers of Ki-67<sup>+</sup> were found in the diseased EHBD. In EHBD affected by cholangitis, Ki-67<sup>+</sup> cells were mainly located in the basal layer of the lumen. EHBD specimens from patients with ischemic type biliary lesions displayed histological signs of epithelial cell loss and large numbers of Ki-67<sup>+</sup> cells were observed in the peribiliary glands. C-Kit expression was localized throughout the EHBD wall and immunofluorescent doublestaining identified a few K19<sup>+</sup>/c-Kit<sup>+</sup> cells in the luminal epithelium of the EHBD as well as in the peribiliary glands.

**Conclusions:** These findings support the hypothesis that progenitor cells exist in the EHBD and that the peribiliary glands can be considered a local progenitor cell niche in the human EHBD.

## INTRODUCTION

The liver and its various cell types, including hepatocytes and biliary epithelial cells (or cholangiocytes), have a well-described regenerative capacity in response to different types of injury and cellular loss. While mild to moderate hepatocellular injury or depletion is considered a stimulus for the replication of mature hepatic cells, more severe acute and chronic types of injury have been associated with a regenerative response that includes the recruitment of hepatic progenitor cells (1,2). Accumulating evidence suggests that there are four possible intrahepatic stem/progenitor cell niches: the canals of Hering, intralobular bile ducts, periductal mononuclear cells, and peribiliary hepatocytes (3,4). Hepatic progenitor cells have been shown to have bi-potent capacities, allowing them to differentiate into either hepatocytes or cholangiocytes (5). Most studies on hepatic regeneration alluding to these progenitor cells dealt with replenishment of hepatocytes and intrahepatic bile ducts. Data of regeneration of the cholangiocytes lining the extrahepatic bile ducts (EHBD) are sparse. The biliary epithelial lining of the EHBD consists of simple columnar epithelial cells, which are continuously exposed to bile flow and the cytotoxic properties of bile salts. In addition, toxins and pathogens may cause cellular injury in pathological situations, such as in ascending bacterial cholangitis. Therefore, it is conceivable that biliary epithelium of the EHBD has an endogenous regenerative capacity, which may include a local niche of progenitor cells (6). Because the above mentioned intrahepatic progenitor cell niches are thought to be closely related to hepatocytes and due to the lack of hepatocytes in the EHBD it is conceivable that a different source of progenitor cells exists in the proximity of the EHBD.

The intrahepatic bi-potent progenitor cells have been characterized by the expression of hematopoietic markers such as c-Kit (7-10). The expression of these progenitor cell markers in combination with the biliary markers keratin 7 (K7) and keratin 19 (K19) has been used to identify sub-lineages of the bi-potent progenitor cells differentiating into cholangiocytes. Experiments in mice have suggested that the EHBD contains local progenitor cells that are c-Kit positive (11). In addition, Cohen *et al.* and Nakanuma *et al.* hypothesized that the peribiliary glands of the EHBD might be the compartment that harbors regenerative cells, but formal evidence for this is still lacking (6,12).

The aim of the current study was to identify possible site(s) where epithelial regeneration may be initiated in the human EHBD and to study the possible role of local progenitor cells in this process. We have examined tissue specimens from normal and diseased human EHBD varying from mild cellular injury (as in cholangitis/cholecystitis) to severe epithelial injury with cholangiocyte loss, as can be seen in post-ischemic cholangiopathy, i.e. ischemic type biliary lesions (ITBL), after orthotopic liver transplantation.

## EXPERIMENTAL PROCEDURES

### Source of Human EHBD Specimens

All procedures and use of (anonymized) tissue specimens were performed according to recent national guidelines. A total of 17 human EHBD specimens were included in this study. Specimens of normal EHBD tissue were obtained from six healthy donor livers that had been retrieved from DCD (donation after cardiac death) organ donors. These samples were obtained during the backtable procedure prior to transplantation of these organs. Specimens of mildly injured EHBD were obtained from six patients with cholangitis/cholecystitis who underwent cholecystectomy. Specimens of severely injured EHBD were obtained from five patients undergoing a retransplantation of the liver due to ITBL, in whom hepatic artery thrombosis was excluded by either Doppler ultrasound or CT angiography. All specimens were fixed in 10% buffered formalin, embedded in paraffin and 4- $\mu\text{m}$  thick sections were used for immunohistochemical analysis.

### Immunohistochemistry

To determine the number and location of proliferating cholangiocytes within the EHBD, double immunostaining using monoclonal antibodies against keratin 19 (rabbit anti-keratin 19, Abcam, Cambridge, United Kingdom, dilution of 1/100) and Ki-67 (mouse anti-Ki-67, DAKO, Glostrup, Denmark, dilution of 1/100) were performed. In short, after deparaffinization through a graded alcohol series, antigen retrieval was performed with 0.1M Tris/HCL buffer (pH=9) for 15 min at 98 °C in a microwave oven. Endogenous peroxidase was blocked with  $\text{H}_2\text{O}_2$  for 30 min. Thereafter, sections were incubated with Ki-67 for 1 h at room temperature, followed by incubation with peroxidase-labeled rabbit anti-mouse antibody (dilution 1/100) and goat anti-rabbit antibody (dilution 1/100). The staining reaction was developed using diaminobenzidin (DAB). Sections were then washed in a glycine/HCL solution (pH=2) for 45 min, followed by incubation with K19 for 1 h at room temperature. This was followed by peroxidase-labeled goat anti-rabbit antibody (dilution 1/100) and rat anti-goat antibody (1/100) and the staining reaction was developed with 3-amino-9-ethyl-carbazole (AEC). Sections were counterstained with hematoxylin. Histological evaluation was performed by a single pathologist (A.S.H.G).

### Immunofluorescent Double Stainings

Immunofluorescent double staining using monoclonal antibodies against K19 (mouse anti-K19, Abcam, Cambridge, United Kingdom, dilution of 1/100) and polyclonal antibodies against c-Kit (rabbit anti-c-Kit, DAKO, C7244, Glostrup, Denmark) was performed on 4  $\mu\text{m}$  paraffin sections. In short, after deparaffinization antigen retrieval was performed with 1 mmol/L ethylene diamine tetra acetate (EDTA) buffer (pH=8) for 15 min at 98 °C in a microwave oven. Thereafter, sections were incubated with antibodies against c-Kit for 1 h at room temperature, followed by incubation

with antibodies against K19 for 1 h at room temperature. Thereafter, slides were incubated in the dark with a mixture of secondary fluorescent antibodies Alexa Fluor 568-conjugated goat anti-rabbit IgG antibody (dilution 1/50) and Alexa Fluor 488-conjugated goat anti-mouse IgG antibody (dilution 1/50) for 1 h at room temperature. Sections were counterstained with 4',6-diaminido-2-phenylindole (DAPI) dilution 1/1000 for 5 minutes at room temperature in the dark and then mounted with Vectashield H 1000 (Vector Laboratories, Burlingame, CA, USA). Microscopy images were captured using a Leica DMLB microscope (Leica Microsystems, Rijswijk, the Netherlands) equipped with a Leica DC300F camera and Leica QWin 2.8 software.

## RESULTS

### Cholangiocyte Damage in Normal and Diseased EHBD

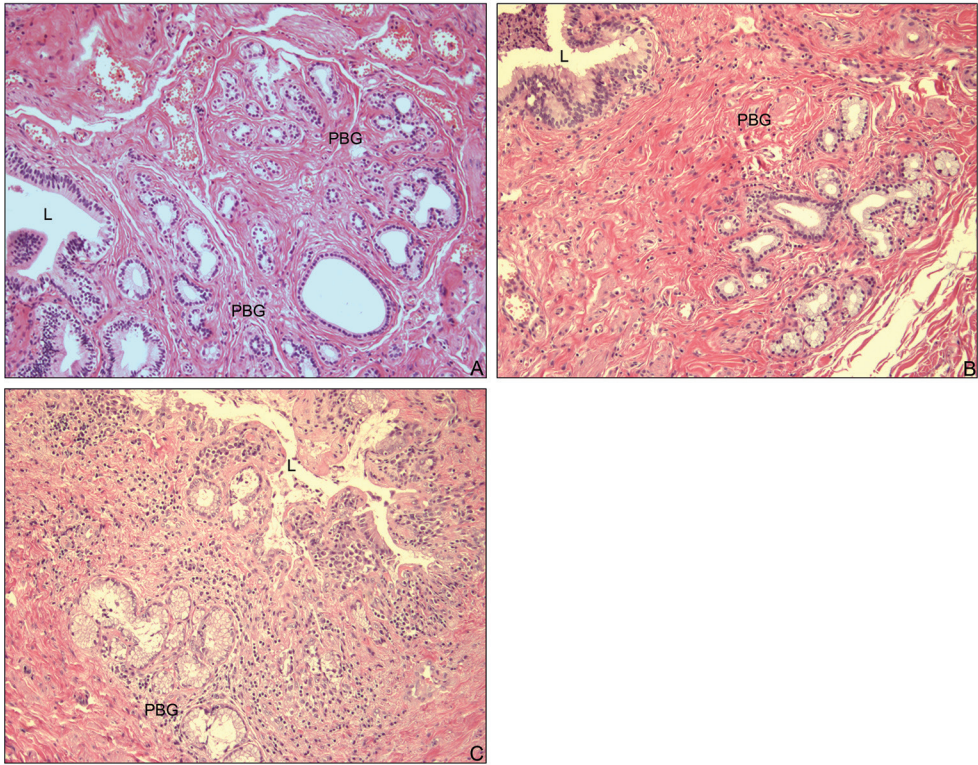
Examples of the microscopic appearance of healthy and diseased EHBD specimens are presented in **Figure 1**. Samples of EHBD obtained from donor livers had a fully preserved epithelial lining, without any other histological abnormalities in the bile duct wall. In contrast, specimens from patients with cholangitis showed variable grades of inflammation but a preserved epithelial lining. EHBD specimens from patients with ITBL showed complete or partial denudation of the biliary epithelial lining.

### Cholangiocyte Turnover in Normal and Diseased EHBD

Healthy and diseased EHBD sections were double stained for the proliferation marker Ki-67 and the biliary epithelial marker K19. K19 positive cholangiocytes were detected lining the bile ducts and the peribiliary glands. In the healthy EHBD, a few isolated cells expressing both Ki-67 and K19 (K19<sup>+</sup>/Ki-67<sup>+</sup> cells) were identified at the basal layer of the lumen and no expression of Ki-67 was detected in the peribiliary glands (**Figure 2**).

In EHBD from patients with cholangitis, with mild to moderate biliary epithelial injury, the intact cholangiocytes were K19 positive and a substantial number of K19<sup>+</sup>/Ki-67<sup>+</sup> cells were detected in the basal layer of the lumen of the EHBD, whereas K19<sup>+</sup>/Ki-67<sup>+</sup> cells were detected only sporadically in the peribiliary glands (**Figure 2**). In contrast, EHBD of patients with ITBL and severe biliary epithelial injury, characterized by a marked loss of lining cholangiocytes on the luminal side, exhibited a high number of K19<sup>+</sup>/Ki-67<sup>+</sup> cells in the peribiliary glands, whereas only a few double positive cells were observed at the lumen of the bile duct (**Figure 2**).



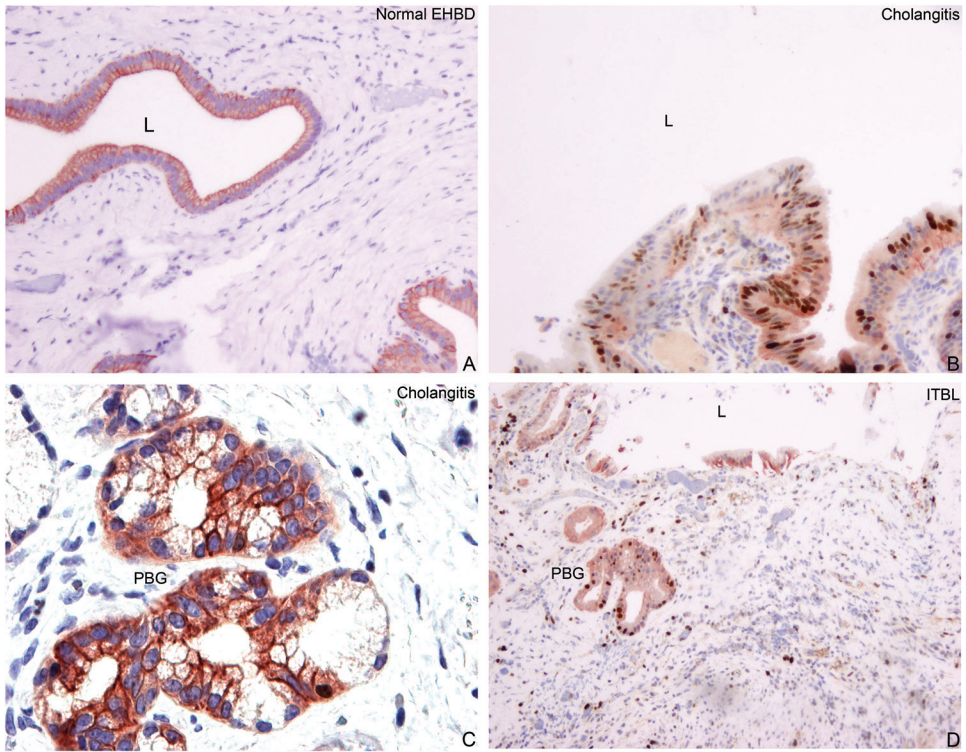


**Figure 1. Overview of the different pathological features of the extrahepatic bile ducts (EHBD) examined.** Representative hematoxylin-eosin staining of surgical specimens of a normal EHBD without pathological signs of injury (**A**), an EHBD from a patient with cholangitis, expressing signs of inflammation without disruption of the epithelial layer (**B**) and an EHBD suffering from ischemic type biliary lesions (ITBL) with severe cholangiocyte injury indicated by loss of the continuity of the cholangiocyte layer (**C**). **Abbreviations:** L; lumen, PBG; peribiliary glands.

### Cellular Localization of c-Kit

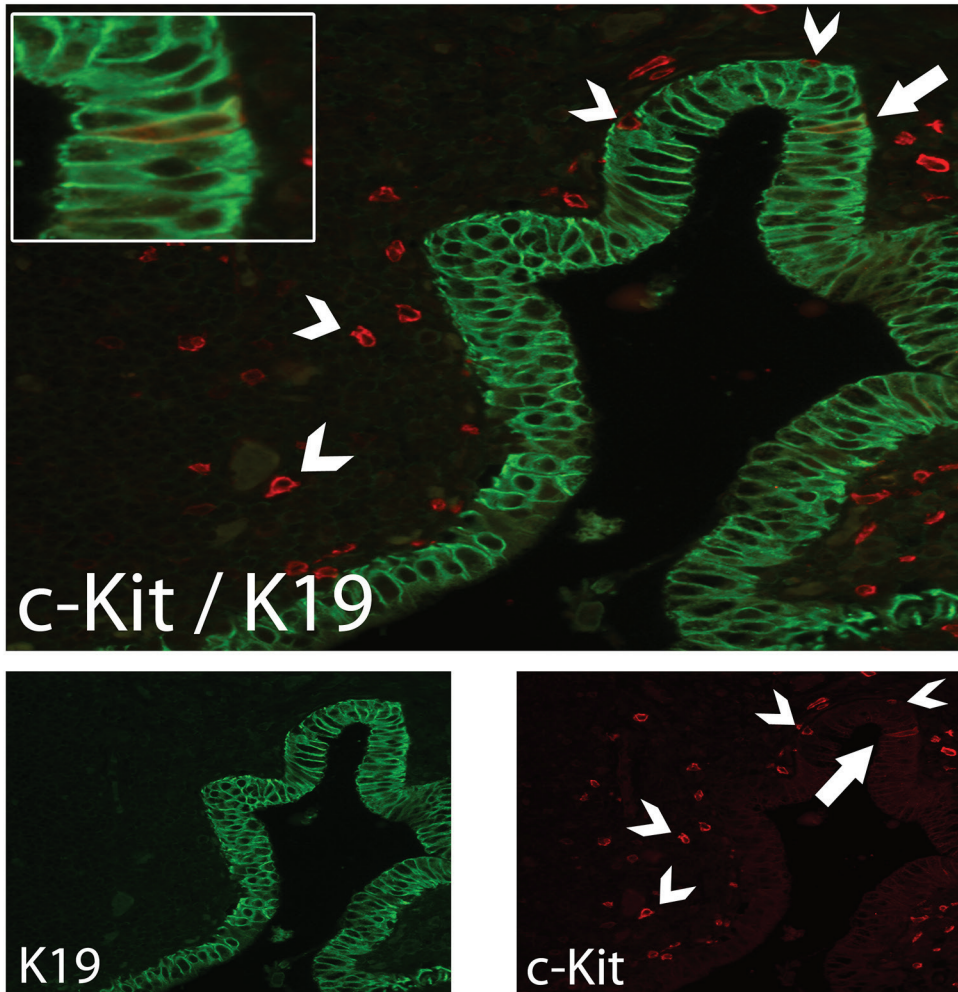
We next examined whether cells expressing c-Kit could be detected in the EHBD specimens. Expression of c-Kit was detected in individual cells throughout the bile duct wall. Cells positive for c-Kit were located at the basal epithelial layer of the lumen, in the connective tissue of the bile duct, and a few positive cells were detected in the peribiliary glands. No differences in number and localization between normal, mildly and severely injured EHBDs were present.

To determine if a subpopulation of c-Kit positive cells also express K19, double immunofluorescence staining was performed. A few K19<sup>+</sup>/c-Kit<sup>+</sup> cells were observed at the epithelial lining of the lumen (**Figure 3**) of the EHBD as well as in the peribiliary glands (**Figure 4**). The number and localization of these cells did not differ between normal and diseased EHBD.

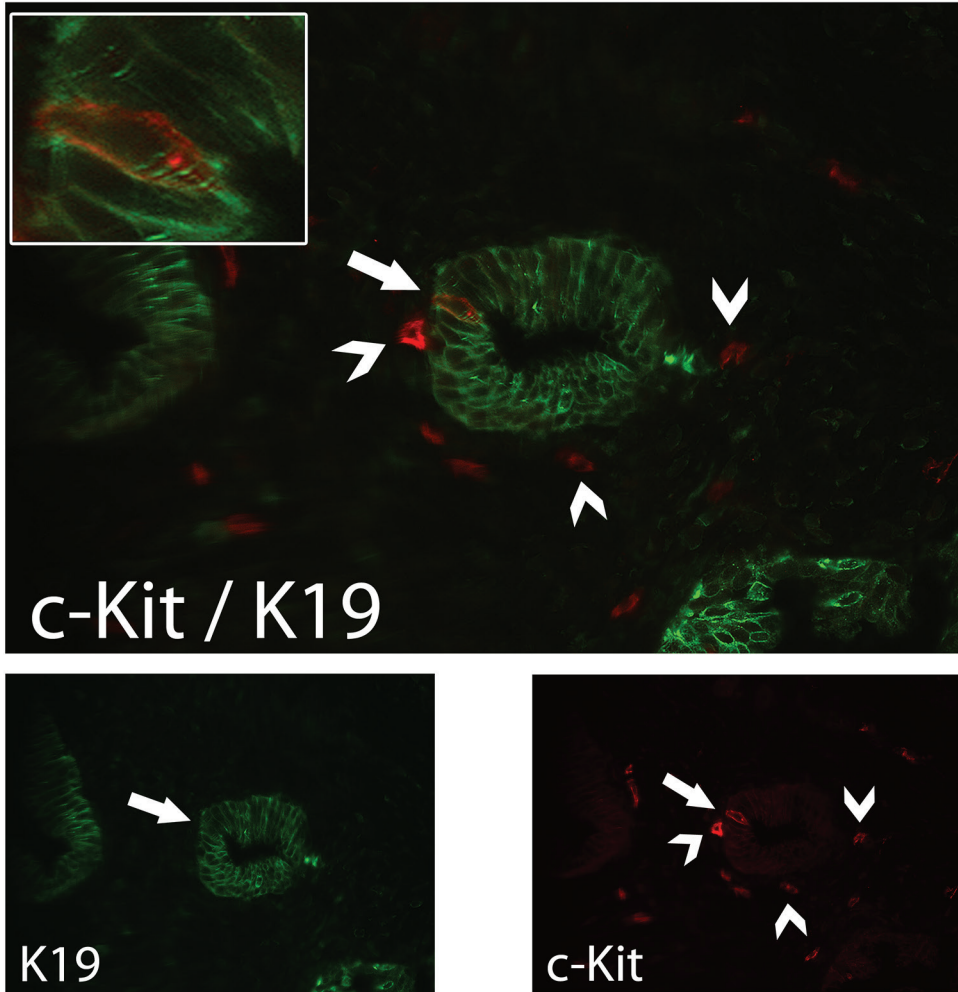


**Figure 2. The pattern of cholangiocyte proliferation after different types of biliary injury.** Immunohistochemical stainings showed that the number of proliferating cholangiocytes is very low in normal extrahepatic bile ducts (EHBD) (A). Cholangiocyte proliferation predominantly occurred in the luminal lining of the EHBD in the case of cholangitis (B) with low proliferation in the peribiliary glands (C). However, in EHBD suffering from ischemic type biliary lesions (severe injury with partial denudation of the cholangiocytes lining the lumen), proliferation was mainly located in the peribiliary glands with only low numbers of proliferating cholangiocytes within the luminal cholangiocyte lining (D). Cholangiocytes are stained in red (keratin 19), proliferating cells are stained in brown (Ki-67). **Abbreviations:** L; lumen, PBG; peribiliary glands.





**Figure 3. Evaluation of c-Kit expression by cholangiocyte-like cells at the luminal compartment.** Immunofluorescent double staining with c-Kit (red) and keratin 19 (K19) (green) showed that, although in small numbers, K19<sup>+</sup>/c-Kit<sup>+</sup> cells are present in the epithelial lining of the extrahepatic bile ducts (EHBD) lumen (indicated by an arrow). These K19<sup>+</sup>/c-Kit<sup>+</sup> were found in normal and diseased states (cholangitis or ischemic type biliary lesions) of the EHBD. This population of double positive cells is in contrast with other type of cells that are positive for c-Kit but do not express K19 (indicated by arrowheads).



6

**Figure 4. Evaluation of c-Kit expression by cholangiocyte-like cells in the peribiliary glands.** Immunofluorescent double staining with c-Kit (red) and keratin 19 (K19) (green) showed that, small numbers of K19<sup>+</sup>/c-Kit<sup>+</sup> cells are present in the peribiliary glands of the extrahepatic bile duct (EHBD) wall (indicated by an arrow). These K19<sup>+</sup>/c-Kit<sup>+</sup> were found in normal and diseased states (cholangitis or ischemic type biliary lesions) of the EHBD. This population of double positive cells is in contrast with other type of cells that are positive for c-Kit but do not express K19 (indicated by arrowheads).

## DISCUSSION

In the present study we provide evidence that there are two distinct sites in the human EHBD where regeneration of cholangiocytes can be identified. In addition, our data suggest that biliary progenitor cells reside within these sites.

In specimens with mild to moderate injury of the EHBD, proliferating cells with cholangiocyte characteristics were primarily present in the epithelial lining of the EHBD lumen, whereas proliferating cholangiocyte-like cells were primarily present in the peribiliary glands in specimens with more severe damage showing loss of cholangiocytes at the luminal side of the EHBD. In line with this, we have also demonstrated K19 positive putative progenitor cells within both the lining of the bile duct lumen and the peribiliary glands.

Several studies on intrahepatic regeneration of hepatocytes and cholangiocytes have suggested c-Kit as a useful marker of biliary progenitor cells (8,13). However, it is also expressed by other cell types inside the liver leading to a less unambiguous interpretation of c-Kit stainings. In the current study, we found c-Kit expression in small cholangiocytes at the epithelial lining of the lumen as well as in the epithelial lining of the peribiliary glands. This finding strongly suggests that both the luminal epithelial lining and the peribiliary glands contain cholangiocyte progenitors that are involved in repair of the biliary epithelial lining following injury.

We observed only low proliferative activity in the biliary epithelium of normal EHBD. Despite the fact that biliary epithelium is continuously exposed to bile flow and the cytotoxic effects of bile salts, cellular renewal activity is apparently low under physiological circumstances. In contrast with this, substantial proliferative activity was observed in specimens obtained from patients with cholangitis and ITBL. We found a striking difference in the pattern of proliferative activity between these two disease entities. In cholangitis, the biliary epithelial lining remains largely intact and the degree of injury can be graded as mild to moderate. In this situation, proliferating cells were observed at the luminal side of the EHBD. In contrast, in patients with ITBL and severe EHBD injury, resulting in partial or complete denudation of the epithelial lining, proliferating cells were mainly observed in the peribiliary glands and proliferation at the luminal side of the EHBD was low. These findings suggest that after relatively mild injury of the epithelium, the necessary renewal of cholangiocytes is achieved by replication of neighboring cholangiocytes. This repair mechanism may not suffice in the situation of severe epithelial injury when there is partial or complete loss of cholangiocytes at the lumen of the bile duct. In this situation, no actual loss of cholangiocytes was observed in the inner lining of the peribiliary glands, and recruitment seems to occur from these peribiliary glands. Altogether, these findings suggest that replication of mature cholangiocytes at the EHBD lumen is a first-line regenerative mechanism of EHBD repair. When this first-line mechanism fails, a second-line mechanism is initiated resulting in the recruitment of cells from more distant sites such as the peribiliary glands.

A similar concept is found in hepatocyte regeneration. In massive hepatic necrosis in which there is severe loss of parenchymal cells, the progenitor cell compartment is activated whereas after partial hepatectomy these progenitor cells remain quiescent and regeneration is mainly contributed by adult hepatocytes (4, 5).

Our findings are in agreement with studies performed by Nakanuma *et al.*, who previously suggested that the peribiliary glands may be an important reservoir of epithelial regeneration in the EHBD. Nakanuma was also the first to describe that there is a micro-structural connection between the peribiliary glands and the lumen of the bile duct making it possible for replenishing cells to migrate from the peribiliary glands to the site of luminal epithelial injury (6).

To investigate the hypothesis that local progenitor cells are (in part) responsible for cholangiocyte repair during mild and more severe injury, we examined the localization of c-Kit positive cells within the EHBD. C-Kit is a putative progenitor cell maker, but is also expressed on mature cell types such as mast cells and Cajal cells. Indeed, individual c-Kit positive (but K19 negative) cells were detected in the wall of the EHBD with morphological characteristics resembling mast cells and Cajal cells. However, we found a third population of c-Kit positive/K19 positive cells located within the epithelial layer of the lumen and the peribiliary glands. These cells were found in low numbers in all sections investigated but no different pattern between normal and diseased EHBD was demonstrated. C-Kit expression by biliary epithelial cells of the human intrahepatic bile duct has been described previously by Ahmadi *et al.* but these investigators thought this was due to non-specific immunofluorescence staining (14). In contrast, in our study we clearly show these c-Kit positive cells are present within the epithelial layer, albeit in very low numbers. Our findings that a limited number of K19 positive cells co-expressed c-Kit, is in accordance with findings of Crosby *et al.* who showed similar expression of c-Kit positive/K19 positive cells lining the lumen of the intrahepatic bile duct (8,13).

We have demonstrated that a population of cholangiocytes co-expressing c-Kit resides in the luminal lining of the human EHBD and the adjacent peribiliary glands. The lack of differences between the distribution of c-Kit positive cholangiocytes in different disease states and healthy controls is supportive for the hypothesis that these are progenitor cells permanently residing in the EHBD. Progenitor cells are responsible for self-renewal instead of being the proliferating cells themselves. They give rise to a progeny of proliferating cells as indicated by our Ki-67 stainings. In summary, in this study we have demonstrated that different patterns of cholangiocyte proliferation occur in the human EHBD. Following a mild to moderate type of injury (i.e. cholangitis) restoration of the epithelial lining seems predominantly provided by proliferation of (mature) cholangiocytes at the luminal lining of the EHBD. In case of severe injury and cholangiocyte loss recruitment of cells from the peribiliary glands will add to this. In addition to this, the peribiliary glands of the EHBD could be considered as a local niche of biliary progenitor cells. More studies will be needed to further identify these progenitor cells and to examine the specific stimuli that are involved in the activation of the peribiliary glands.

## ACKNOWLEDGEMENT

The authors thank Lydia Visser for her technical assistance of the immunohistochemical analysis.

## REFERENCES

- (1) Santoni-Rugiu E, Jelines P, Thorgeirsson SS, Bisgaard HC. Progenitor cells in liver regeneration: molecular responses controlling their activation and expansion. *Apmis* 2005;113:876-902.
- (2) Sell S. The role of progenitor cells in repair of liver injury and in liver transplantation. *Wound Repair and Regeneration* 2001;9:467-482.
- (3) Kuwahara R, Kofman AV, Landis CS, Swenson ES, Barendsward E, Theise ND. The hepatic stem cell niche: Identification by label-retaining cell assay. *Hepatology* 2008;47:1994-2002.
- (4) Theise ND, Saxena R, Portmann BC, Thung SN, Yee H, Chiriboga L, et al. The canals of Hering and hepatic stem cells in humans. *Hepatology* 1999;30:1425-1433.
- (5) Duncan AW, Dorrell C, Grompe M. Stem Cells and Liver Regeneration. *Gastroenterology* 2009;137:466-481.
- (6) Nakanuma Y, Hosono M, Sanzen T, Sasaki M. Microstructure and development of the normal and pathologic biliary tract in humans, including blood supply. *Microsc Res Tech* 1997;38:552-570.
- (7) Gordon GJ, Coleman WB, Hixson DC, Grisham JW. Liver regeneration in rats with retrorsine-induced hepatocellular injury proceeds through a novel cellular response. *American Journal of Pathology* 2000;156:607-619.
- (8) Baumann U, Crosby HA, Ramani P, Kelly DA, Strain AJ. Expression of the stem cell factor receptor c-kit in normal and diseased pediatric liver: Identification of a human hepatic progenitor cell? *Hepatology* 1999;30:112-117.
- (9) Petersen BE, Goff JP, Greenberger JS, Michalopoulos GK. Hepatic oval cells express the hematopoietic stem cell marker Thy-1 in the rat. *Hepatology* 1998;27:433-445.
- (10) Masson NM, Currie IS, Terrace JD, Garden OJ, Parks RW, Ross JA. Hepatic progenitor cells in human fetal liver express the oval cell marker Thy-1. *American Journal of Physiology-Gastrointestinal and Liver Physiology* 2006;291:G45-G54.
- (11) Irie T, Asahina K, Shimizu-Saito K, Teramoto K, Arii S, Teraoka H. Hepatic progenitor cells in the mouse extrahepatic bile duct after a bile duct ligation. *Stem Cells Dev* 2007;16:979-987.
- (12) Cohen PJ. Renewal Areas of Common Bile Duct Epithelium in Rat. *Anatomical Record* 1964;150:237-241.
- (13) Crosby HA, Kelly DA, Strain AJ. Human hepatic stem-like cells isolated using c-kit or CD34 can differentiate into biliary epithelium. *Gastroenterology* 2001;120:534-544.
- (14) Ahmadi O, Nicholson MD, Gould ML, Mitchell A, Stringer MD. Interstitial cells of Cajal are present in human extrahepatic bile ducts. *J Gastroenterol Hepatol* 2010;25:277-285.





# CHAPTER 7

## **Injury of Peribiliary Glands and Vascular Plexus before Liver Transplantation Predicts Formation of Non-anastomotic Biliary Strictures**

Op den Dries S, Westerkamp A, Karimian N, Gouw ASH, Markmann JF,  
Lisman T, Yeh H, Uygun K, Martins P, Porte RJ.

*Submitted for publication.*

**ABSTRACT**

Peribiliary glands of large bile ducts have been identified as a niche of progenitor cells that contribute to regeneration of biliary epithelium after injury. It is unknown whether injury of the peribiliary glands is a risk factor for the development of non-anastomotic biliary strictures (NAS) after liver transplantation. Moreover, it is unknown whether pretransplant biliary injury is different in livers donated after brain death (DBD) or cardiac death (DCD). In 128 liver transplant procedures, biopsies were taken from the extrahepatic bile duct and injury was assessed using a systematic histological grading system. Histological injury was correlated with the occurrence of posttransplant biliary strictures and a comparison was made between DBD (n=97) and DCD livers (n=29). Biliary epithelial loss >50% was observed in 91.8% of the grafts before transplantation, yet NAS occurred in 16.4%. Periluminal peribiliary glands were more severely injured than the deep peribiliary glands located near the fibromuscular layer (>50% loss in 56.9% versus 17.5%, respectively;  $p<0.001$ ). Injury of deep peribiliary glands was more prevalent and more severe in livers that later developed NAS, compared to uncomplicated grafts (>50% loss in 50.0% versus 9.8%, respectively;  $p=0.004$ ). In parallel, injury of the peribiliary vascular plexus was more severe in livers that developed NAS, compared to uncomplicated grafts (>50% vascular changes in 57.1% versus 20.3%;  $p=0.006$ ). Comparison of DBD and DCD livers revealed significantly more vascular injury in the latter ( $p=0.005$ ). Conclusion: Injury of peribiliary glands and vascular plexus before transplantation is strongly associated with the occurrence of biliary strictures after transplantation. This suggests that insufficient regeneration due to loss of peribiliary glands and blood supply may explain the development of biliary strictures.

## INTRODUCTION

Biliary complications are a major cause of morbidity and graft failure after orthotopic liver transplantation (1-3). Anastomotic and non-anastomotic bile duct strictures (NAS) are the most frequent type of biliary complication, with a reported incidence of anastomotic strictures varying between 1-15% and of NAS between 5-30% (3-5). The highest incidence of NAS has been reported after transplantation of livers donated after cardiac death (DCD) (6-8). In contrast to livers obtained from brain death donors (DBD), livers from DCD donors suffer additional warm ischemia in the donor during the time interval between cardiac arrest and *in situ* cold perfusion. Duration of warm and cold ischemia during organ retrieval; storage; and transportation have been identified as important risk factors for the development of NAS after transplantation (9,10). In addition, bile salt induced cellular injury and immune-mediated injury have been shown to play a role in the pathogenesis of biliary injury and the subsequent formation of biliary strictures (11-13). Biliary epithelial cells (or cholangiocytes) are known to be very sensitive to ischemia and relatively short periods of ischemia result in a rapid and prolonged depletion of the intracellular concentrations of adenosine triphosphate (ATP) (14-16). As a consequence of ATP depletion, biliary epithelial cells lose their intercellular connections and detach from the basement membrane, resulting in sloughing of the epithelial lining and denudation of the bile duct luminal surface. Two independent clinical studies have recently demonstrated that major epithelial cell loss in the extrahepatic bile ducts can be observed in more than 80% of DBD donor livers at the time of transplantation (17,18). In both studies, histological severity of bile duct injury, including loss of epithelial lining and mural necrosis, correlated significantly with the postoperative occurrence of biliary strictures. The observation that biliary injury is almost universally (>80%) present at the time of transplantation, yet biliary strictures are (fortunately) seen in only a minority of transplant recipients, has led to the hypothesis that proliferation and regeneration of the bile duct wall and epithelium, rather than the initial injury alone, are important determinants in the pathogenesis of biliary strictures (19).

Timely and adequate biliary regeneration requires at least two important preconditions: adequate supply of oxygen and nutrients and a vital source from which biliary epithelial cells can proliferate and regenerate. Regarding regeneration of the biliary epithelial lining of the larger bile ducts, the peribiliary glands have been identified as an important niche of biliary progenitor cells (20-24). Peribiliary glands are connected to the luminal surface via small canals through which newly formed biliary epithelial cells can migrate and contribute to the restoration of the epithelial lining of the bile duct lumen (23,24). Progenitor-like cells are mainly found in peribiliary glands that are located in the deeper layers of the bile duct wall, near the fibromuscular layer (22,23). Despite the presumed critical role of peribiliary glands in the regenerative capacity of large bile ducts, there are no studies in which preservation injury of the peribiliary glands has been examined in relation to the development of biliary strictures after transplantation. We, therefore, performed a



systematic histological analysis of the bile ducts of donor livers at the time of liver transplantation. The aim of this study was two-fold: 1) to determine the impact of injury of the peribiliary glands in the development of posttransplant biliary strictures, and 2) to determine whether there is a difference in severity of pretransplant bile duct injury, including the peribiliary glands and vascular plexus, between DBD and DCD livers.

## **MATERIALS AND METHODS**

### **Donors and Recipients**

This study was conducted as a prospective, collaborative research project of the liver transplant programs at Massachusetts General Hospital (MGH) in Boston, MA and the University Medical Center Groningen (UMCG) in the Netherlands. Between May 1, 2010 and January 1, 2013, biopsies from the extrahepatic donor bile duct were collected at the time of transplantation in 128 liver transplant procedures. Date of last follow-up was June 1, 2013, resulting in a median follow-up interval of 17 months (range 5-36 months). Fifty-four transplant procedures were included at MGH and 74 at UMCG.

Biopsies were taken from segments of donor extrahepatic bile duct that were excised to adjust its length and facilitate adequate positioning of the bile duct and the biliary anastomosis. Specimens were cut with either fine Metzenbaum scissors or a surgical scalpel, taking care not to touch the inside of the bile ducts. Bile duct biopsies were taken at the end of cold storage, during back table preparation of the graft, in 73 cases, after graft reperfusion in 99 cases, and at both time points in 44 cases. In both centers, bile duct anastomoses were routinely constructed using absorbable monofilament sutures.

Donor and recipient characteristics were collected from the local transplant databases and missing data were retrieved from individual electronical patient files. Histological characteristics of biliary injury were correlated with biliary outcome parameters after transplantation, as defined below.

For the part of the study performed at MGH, local institutional review board approval was obtained and for the part performed at the UMCG, collection of data and biopsies was compliant with national legislation and the code for usage of human remnant material (*Code Goed Gebruik*, Federation of Medical Scientific Societies in the Netherlands).

### **Histological Assessment of Bile Ducts**

Bile duct biopsies were immediately preserved in 10% formaldehyde for inclusion in paraffin. Paraffin-embedded slides were prepared for hematoxylin and eosin (H&E) staining. In 47 cases, bile duct biopsies were embedded in Tissue-Tek® (Sakura Finetek, Alphen aan den Rijn, Netherlands) and frozen in isopentane on dry ice (-78 °C) for subsequent preparation as cryostat sections and H&E staining. Injury of the biliary epithelium, stromal layer, and peribiliary vascular plexus was

graded according to a systematic histological scoring system as described by Hansen *et al.* (17) and summarized in **Table 1**. In addition, injury of the peribiliary glands was assessed according to a self developed scoring system in which the subluminal glands were graded separately from the deeper glands located at the junction of bile duct wall stroma and the muscular layer (**Table 1**). Injury of the subluminal and deeper located peribiliary glands was defined as detachment of the cells from the basement membrane and/or disappearance of epithelial cells from the glands. The degree of injury was graded using the following criteria: grade 0, no signs of injury; grade 1, ≤50% injury; grade 2, >50% injury. Injury was defined as detachment or loss of epithelial cells (**Figure 1**). All bile duct sections were examined in a blinded fashion under supervision of an experienced liver pathologist (ASHG) using a Nikon Eclipse 50i light microscope (Nikon Instruments Inc, Melville, NY)

**Table 1.** Overview of the histological characteristics and scoring system used in the assessment of the degree of injury of the extrahepatic bile ducts\*

Bile duct wall component	Injury Score			
	Grade 0	Grade 1	Grade 2	Grade 3
Biliary epithelium	No loss	≤50% loss	>50% loss	N/A
Mural stroma	No injury	≤25% necrotic	25-50% necrotic	>50% necrotic
Peribiliary vascular plexus	No injury	≤50% of vessels with changes	>50% of vessels with changes	Grade 2 + arteriolonecrosis
Thrombosis	Absent	Present	N/A	N/A
Intramural bleeding	None	≤50% of duct wall	>50% of duct wall	N/A
Periluminal PBG	No injury	≤50% loss of cells	>50% loss of cells	N/A
Deep PBG	No injury	≤50% loss of cells	>50% loss of cells	N/A
Inflammation	None	At least 10 leukocytes / HPF	At least 50 leukocytes / HPF	N/A

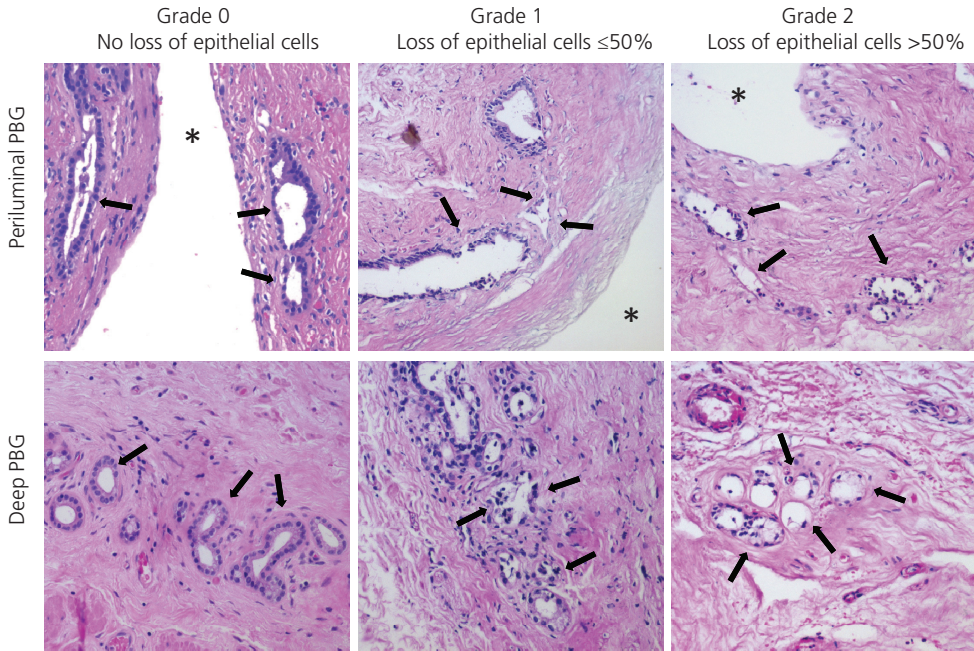
\*) Modified from Hansen et al (17)

**Abbreviations used:** PBG, peribiliary gland; HPF, high power field; NA, not applicable

### Outcome Parameters

The primary postoperative outcome parameter of this study was the occurrence of anastomotic biliary strictures and NAS. NAS were defined as any irregularities or narrowing of the intra- or extrahepatic donor biliary tree in the absence of hepatic artery thrombosis (4). Anastomotic strictures were defined as any narrowing of the anastomosis between donor and recipient bile duct, requiring an intervention. In all cases of an anastomotic stricture or NAS, the diagnosis was based on radiological imaging of the biliary system, including endoscopic retrograde cholangiography, magnetic resonance cholangiography, or percutaneous transhepatic cholangiography. In most patients, imaging of the bile ducts was indicated based on symptoms (i.e. jaundice, cholangitis) or laboratory abnormalities suggesting biliary pathology. Time intervals between transplantation and the first diagnosis of an anastomotic stricture or NAS were recorded.

In addition to biliary complications, graft survival rates were examined as a general outcome parameter.



**Figure 1.** Histological grading system to assess injury of the peribiliary glands of the extrahepatic donor bile duct, based on H&E staining. The periluminal glands below the bile duct epithelial lining and the deep peribiliary glands located near the fibromuscular layer were scored separately. The following criteria were used for determining the degree of injury: grade 0, no signs of injury; grade 1,  $\leq 50\%$  of the glands displayed loss or detachment of epithelial cells; grade 2,  $>50\%$  of the glands displayed loss or detachment of epithelial cells. Bile duct lumen is marked by an asterisk, and arrows point at peribiliary glands.

### Statistical Analysis

Continuous variables are presented as median and interquartile range (IQR). Categorical variables are presented as number and percentage. Continuous variables were compared between groups using the Mann-Whitney U and categorical variables were compared with the Pearson Chi-Square test. Survival analysis was performed according to the Kaplan Meier method and groups were compared using the log-rank test. The level of significance was set at p-value of 0.05. All statistical analyses were performed using SPSS software version 16.0 for Windows (SPSS, Inc., Chicago, IL).

## RESULTS

### Donors and Recipients

Demographics of donors and patients, as well as relevant surgical variables are summarized in **Table 2**. In 97 patients (75.7%) the donor liver was derived from a DBD donor, in 29 (22.7%) from a DCD donor, and in one case (0.8%) from a living donor (in one patient this information was missing). University of Wisconsin (UW) preservation fluid was used in 92 cases (71.9%) and histidine-tryptophan-ketoglutarate (HTK) solution in 34 (26.6%). The median duration of cold ischemia was 407 min (IQR 341-484 min). Biliary reconstruction was achieved by performing a duct-to-duct anastomosis in 108 (84.4%) patients, whereas a hepatico-jejunostomy using a Roux-en-Y jejunal loop was constructed in 16 (12.5%) patients (data missing in 4 cases).

**Table 2.** Demographics of 128 Donors and Patients and Surgical Variables

Variable	Number (%) or Median (IQR)
<i>Donor characteristics</i>	
Age (years)	49 (35-56)
Gender (male)	70 (54.7%)
Body Mass Index	25 (23-28)
Cause of death	
Cerebrovascular accident	68 (53.1%)
Post-anoxia	35 (27.3%)
Trauma	22 (17.2%)
Other	3 (2.4%)
Type of donor	
DBD	97 (75.7%)
DCD	29 (22.7%)
Living	1 (0.8%)
Unknown	1 (0.8%)
Type of graft	
Full size graft	118 (92.2%)
Reduced size	9 (7.0%)
Split graft	1 (0.8%)
Type of preservation fluid	
UW solution	92 (71.9%)
HTK solution	34 (26.6%)
Unknown	2 (1.5%)
Donor warm ischemia time in DCD (minutes)	22 (12-33)

Variable	Number (%) or Median (IQR)
<i>Recipient characteristics</i>	
Age (years)	55 (38-61)
Gender (male)	92 (71.9%)
Indication for transplantation	
Post-alcoholic cirrhosis	19 (14.8%)
Hepatocellular carcinoma	18 (14.1%)
Biliary cirrhosis (PSC, PBC or atresia)	17 (13.3%)
Post-viral cirrhosis (hepatitis B or C)	16 (12.5%)
Acute liver failure	10 (7.8%)
Non-alcoholic steatohepatitis	7 (5.5%)
Cryptogenic cirrhosis	5 (3.9%)
Metabolic disease	4 (3.1%)
Auto-immune hepatitis	2 (1.6%)
Retransplantation	20 (15.6%)
Miscellaneous	10 (7.8%)
MELD score	19 (11-31)
<i>Surgical variables</i>	
Cold ischemia time (minutes)	407 (341-484)
Warm ischemia time in recipient (minutes)	42 (38-50)
Type of biliary anastomosis	
Duct-to-duct	108 (84.4%)
Roux-en-Y hepatico-jejunostomy	16 (12.5%)
Unknown	4 (3.1%)

**Abbreviations used:** DBD, donation after brain death; DCD; donation after cardiac death; HTK; histidine-tryptophan-ketoglutarate; IQR, interquartile range; MELD, model for end-stage liver disease; UW, University of Wisconsin; WIT, warm ischemia time.

### Histological Grading of Bile Duct Injury

Results of the histological grading of bile duct injury at the end of cold storage and after graft reperfusion are presented in **Table 3**. Major loss of biliary epithelium at the luminal surface (grade 2 or >50%) was observed in 91.8% of all bile ducts at the end of cold storage, and this did not increase further after reperfusion. Signs of >50% bile duct wall stroma necrosis (grade 2 or more) were noted in 12.4% of all samples at the end of cold storage, which increased to 42.4% after reperfusion. In general, the degree of injury was most severe in the central layers of the bile duct wall, including the luminal epithelial lining and subluminal stroma, whereas the outer stromal layers were relatively well preserved (**Figure 2**).

Damage to the peribiliary vascular plexus was found in the majority of all bile ducts. Grade 2 or more vascular lesions (>50% vascular changes) were observed in 27.4% at the end of cold

**Table 3.** Comparison of Histological Grading of Bile Duct Injury Before and After Reperfusion

Bile duct wall component	Injury Score (%)		p-value
	End of Cold Storage	After Reperfusion	
Biliary epithelial injury			0.974
Grade 0	0	0	
Grade 1	8.2	8.1	
Grade 2	91.8	91.9	
Mural stroma necrosis			<b>&lt;0.001</b>
Grade 0	46.6	12.1	
Grade 1	41.1	45.5	
Grade 2	11.0	22.2	
Grade 3	1.4	20.2	
Vascular injury			<b>&lt;0.001</b>
Grade 0	12.3	1.0	
Grade 1	60.3	47.5	
Grade 2	15.1	19.2	
Grade 3	12.3	32.3	
Thrombosis			<b>&lt;0.001</b>
Grade 0	97.3	68.7	
Grade 1	2.7	31.3	
Intramural bleeding			<b>&lt;0.001</b>
Grade 0	97.3	46.5	
Grade 1	1.4	21.2	
Grade 2	1.4	32.3	
Periluminal PBG injury			0.113
Grade 0	4.2	0	
Grade 1	38.9	41.1	
Grade 2	56.9	58.9	
Deep PBG injury			0.493
Grade 0	23.8	16.7	
Grade 1	58.7	61.1	
Grade 2	17.5	22.2	
Inflammation			<b>0.007</b>
Grade 0	54.8	37.4	
Grade 1	34.2	32.3	
Grade 2	11.0	30.3	

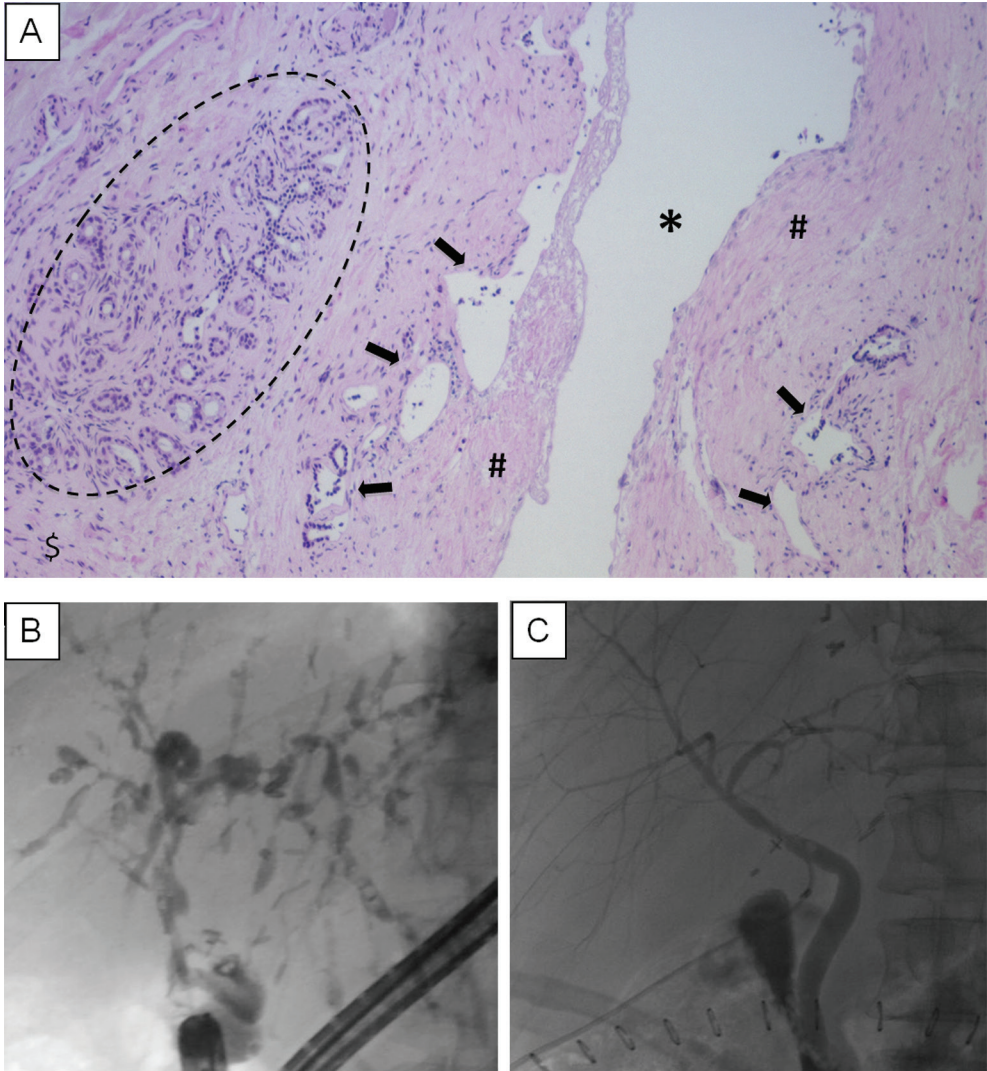
**Abbreviations used:** PBG, peribiliary glands

storage and in 51.5% after reperfusion (**Table 3**). Vascular thrombosis and bleeding were rarely seen at the end of cold storage, but these abnormalities were noted more frequently after reperfusion (**Table 3**).

Injury of the epithelial cells of the peribiliary glands was much less severe and less frequently observed than injury of the biliary epithelial cells at the surface of the bile duct lumen (**Table 3**). In parallel with the gradient of increasing stroma necrosis toward the more superficial layers, the deep peribiliary glands were less severely injured than the superficial, periluminal peribiliary glands (**Figure 2A**). Overall, grade 2 injury (>50% loss of cells) of the periluminal glands was observed in 56.9% of the end of cold storage biopsies, compared to 17.5% of the deep peribiliary glands



( $p < 0.001$ ). Injury of periluminal or deep peribiliary glands did not worsen after graft reperfusion (**Table 3**). A separate analysis of all paraffin embedded slides, after exclusion of frozen sections, did not change the results (data not shown).



**Figure 2. Panel A:** Histology (H&E staining) of an extrahepatic donor bile duct, demonstrating a gradient of increasing injury from the outer layers toward the more central layers near the bile duct lumen. In 91.8% of all patients, there was >50% loss of biliary epithelium at the surface of the bile duct lumen (marked by an asterisk). Necrosis of mural stroma was most severe near the lumen (marked by #) and cells of the periluminal peribiliary glands (arrows) were generally more detached or lost than the deeper glands located near the fibromuscular layer (marked by dashed circle). **Panel B and C:** Cholangiographic images of a patient after liver transplantation with severe non-anastomotic biliary strictures (NAS) (panel B) and a patient without NAS (panel C).

### Relation between Histology and Postoperative Biliary Complications

We next examined whether the severity of the various components of bile duct injury correlated with the occurrence of biliary strictures. The overall incidence of anastomotic strictures was 20.3% and NAS were seen in 16.4% of the transplant recipients. Median (IQR) time interval between transplantation and the diagnosis of an anastomotic stricture or NAS was 40 (9-142) days and 104 (47-201) days, respectively. Radiological examples of patients with and without NAS are presented in **Figure 2B** and **C**.

A comparison of bile duct injury at the end of cold storage in livers that developed NAS and those that did not develop NAS is presented in **Table 4**. There was no significant difference in the amount of biliary epithelial injury at the luminal surface in livers that developed NAS or those that did not develop NAS. However, the degree of mural stroma necrosis, the severity of injury to the peribiliary vascular plexus, as well as injury of the deep peribiliary glands was all significantly worse in livers that developed NAS (**Figure 4**). The distribution of mild-moderate versus severe injury of relevant histological bile duct wall components is summarized in **Figure 3**. Mural necrosis of  $\geq 25\%$  of the bile duct stroma ( $\geq$  grade 2) was noted in 6.8% of the livers that did not develop NAS, compared to 35.7% of the livers that did develop NAS ( $p=0.007$ ). Vascular lesions with  $>50\%$  vascular abnormalities (grade 2) was 20.7% in livers that did not develop NAS, compared to 57.1% of the livers that did develop NAS ( $p=0.006$ ). Grade 2 injury ( $>50\%$  loss of cells) of the deep peribiliary glands was observed in 9.8% of livers without NAS, compared to 50.0% in livers that were complicated by the development of NAS ( $p=0.004$ ). Injury of the superficial, periluminal peribiliary glands was not significantly different between livers with or without NAS (**Table 4**).

Graft survival rates at two years for liver grafts with either severe injury ( $>50\%$ ) of the deep peribiliary glands or severe injury ( $>50\%$ ) of the peribiliary vascular plexus versus those without these types of bile duct injury were 66.7% and 85.1%, respectively ( $p=0.205$ ).

There were no significant differences in any of the histological components of bile duct injury at the end of cold storage between grafts that developed an anastomotic stricture, compared to those without an anastomotic stricture.

### Differences in Bile Duct Injury between DBD and DCD Livers

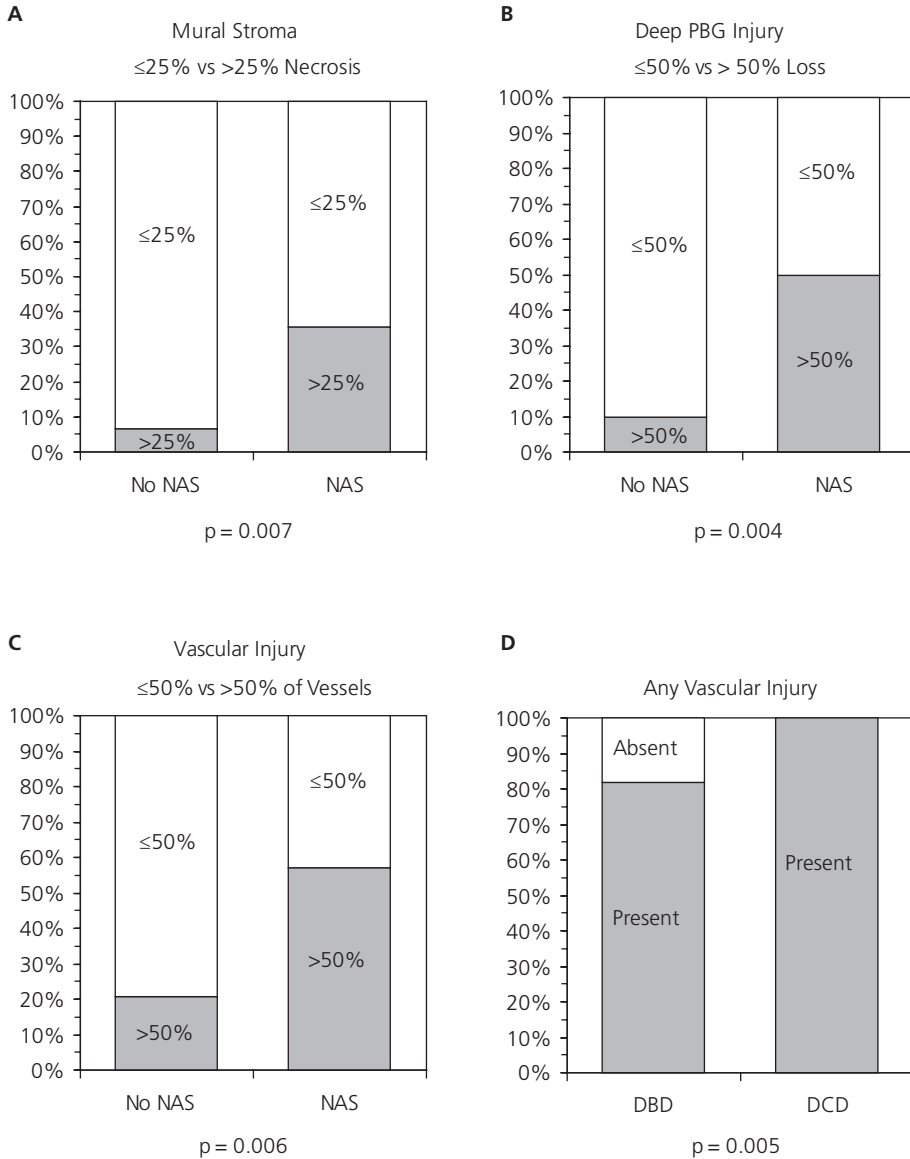
As expected, NAS occurred more frequently after transplantation of DCD livers, compared to DBD livers (35.0% and 13.4%, respectively;  $p=0.165$ ). A comparison of the degree of bile duct injury in DBD and DCD livers revealed no statistically significant differences, apart from a significantly higher percentage of grafts without any vascular injury in the DBD group versus the DCD group (18% versus 0%;  $p=0.005$ ) (**Figure 3D**).



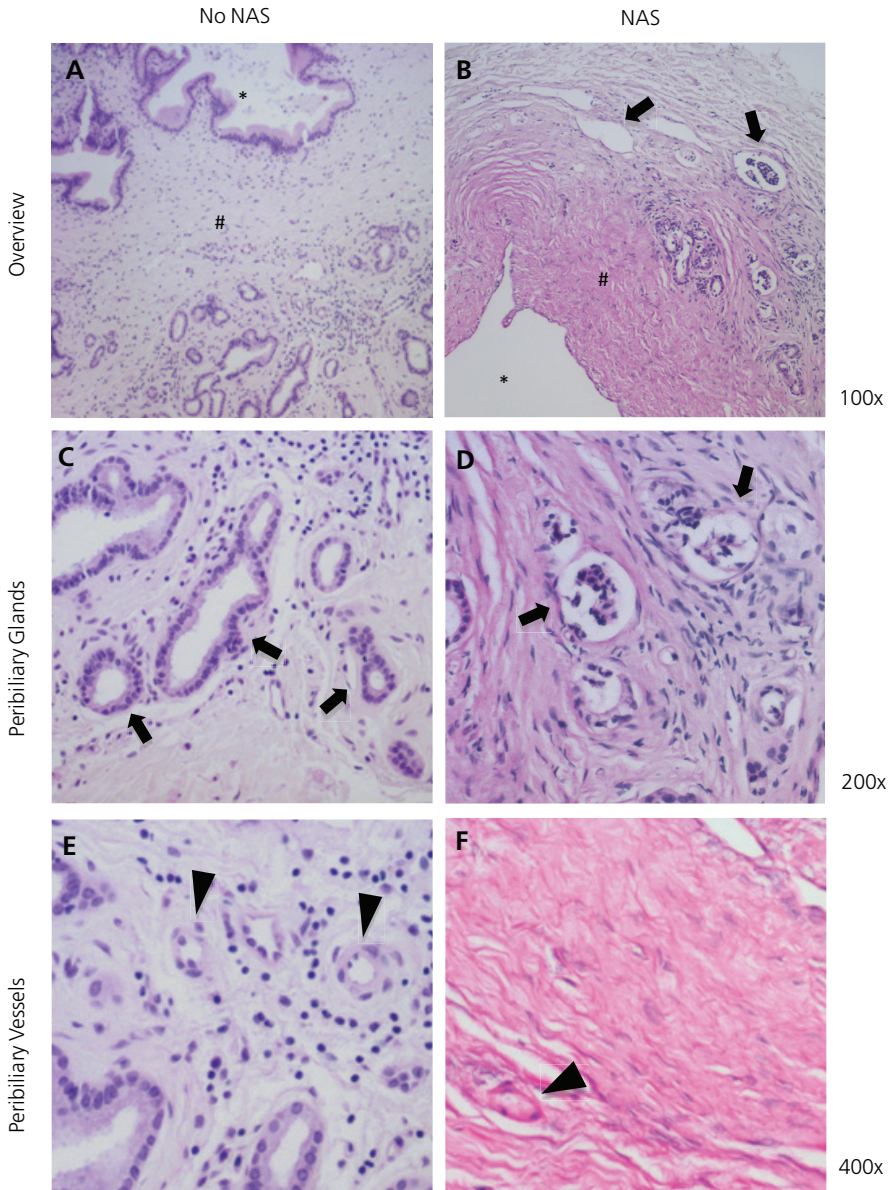
**Table 4.** Histological Grading of Bile Duct Injury Before Transplantation in Donor Livers Which Postoperatively Developed Non-anastomotic Biliary Strictures (NAS) or Not

Bile duct wall component	Injury Score (%)		p-value
	No NAS	NAS	
Biliary epithelium			0.213
Grade 0	0	0	
Grade 1	10.2	0	
Grade 2	89.8	100	
Mural stroma necrosis			<b>0.015</b>
Grade 0	50.8	28.6	
Grade 1	42.4	35.7	
Grade 2	6.8	28.6	
Grade 3	0	7.1	
Vascular injury			<b>0.033</b>
Grade 0	11.9	14.3	
Grade 1	67.8	28.6	
Grade 2	11.9	28.6	
Grade 3	8.5	28.6	
Thrombosis			0.485
Grade 0	96.6	100	
Grade 1	3.4	0	
Intramural bleeding			0.784
Grade 0	96.6	100	
Grade 1	1.7	0	
Grade 2	1.7	0	
Periluminal PBG injury			0.398
Grade 0	5.2	0	
Grade 1	41.4	28.6	
Grade 2	53.4	71.4	
Deep PBG injury			<b>0.004</b>
Grade 0	27.5	8.3	
Grade 1	62.7	41.7	
Grade 2	9.8	50.0	
Inflammation			0.275
Grade 0	54.2	57.1	
Grade 1	37.3	21.4	
Grade 2	8.5	21.4	

**Abbreviations used:** NAS, non-anastomotic biliary strictures; PBG, peribiliary gland.



**Figure 3.** Overview of the distribution of mild-moderate versus severe injury of relevant histological bile duct wall components. **Panel A:** Comparison of the percentage of bile ducts with  $<25\%$  or  $\geq 25\%$  mural stroma necrosis before transplantation in livers that developed non-anastomotic biliary strictures (NAS) after transplantation and those that remained uncomplicated (no NAS). **Panel B:** Similar comparison of bile ducts displaying  $<50\%$  or  $\geq 50\%$  loss of the deep peribiliary glands. **Panel C:** Comparison of bile ducts displaying  $<50\%$  or  $\geq 50\%$  injury of the peribiliary vasculature. **Panel D:** Comparison of the percentage of bile ducts with any vascular injury versus no injury in DBD and DCD liver grafts.



**Figure 4.** Examples of characteristic histological injury (H&E staining) of the various bile duct wall components at the time of transplantation in livers that later developed NAS or remained uncomplicated. **Panel A and B:** Overview demonstrating injury of the biliary epithelial lining of the bile duct lumen (marked by an asterisk), various degrees of necrosis of the periluminal stroma (marked by #) and the peribiliary glands (arrows). **Panel C and D:** Higher magnification of the peribiliary glands (arrows). Deep peribiliary glands located near the fibromuscular layer displayed significantly worse injury in liver that developed NAS, compared to those that did not. **Panel E and F:** Higher magnification of small arteries of the peribiliary vascular plexus (arrowheads). Bile ducts of livers that developed NAS after transplantation displayed significantly more vascular injury, including arteriolonecrosis, compared to livers that did not develop biliary strictures.

## DISCUSSION

The peribiliary glands of large intra- and extrahepatic bile ducts have been proposed as a niche of progenitor cells that contribute to regeneration of biliary epithelium after injury. Cells expressing stem/progenitor cell markers have been identified mainly in the glands located deep in the duct wall, while more mature cells can be found in glands located near the epithelium of the luminal surface (22-24). The results of the current study suggest that injury of the deep peribiliary glands during cold preservation is a major risk factor for the development of NAS after transplantation. Although the vast majority of the biopsies of bile ducts taken before transplantation revealed major loss of biliary epithelium at the bile duct lumen, this finding alone did not correlate with the development of NAS after transplantation. The only histological characteristics that were significantly associated with the postoperative occurrence of NAS were injury of the deep peribiliary glands, the peribiliary vascular plexus and mural stroma necrosis. These findings suggest that insufficient regeneration due to loss of peribiliary glands and blood supply is a critical mechanism underlying the development of biliary strictures after transplantation.

The high percentage of livers with major loss of biliary epithelium from the luminal surface is in line with the results of the recent studies by Hansen *et al* and Brunner *et al* (17,18). The overall rate of bile duct specimens with major biliary epithelial cell loss or detachment from the luminal basement membrane was 91.8% in the current study versus 88% and 86% in the previous two studies. While the previous two studies included only patients who received a liver from a DBD donor, we also included recipients of a DCD liver. Moreover, we have focussed on the role of the peribiliary glands, which were not considered in the previous studies. Interestingly, there were no major differences in the degree of any of the components of biliary injury in DBD and DCD livers, apart from a significantly higher percentage of livers with injury of the peribiliary vascular plexus in the DCD group. This finding suggests the higher incidence of biliary complications, especially NAS, after transplantation of DCD livers may be explained by more severe injury of the vessels and subsequent blood supply to the bile ducts, compared to DBD liver grafts. In fact, all of the DCD livers had at least some degree of histological injury of the peribiliary vasculature prior to transplantation. The higher rate of vascular injury in bile ducts of DCD livers was accompanied by a more than two times higher postoperative rate of NAS, compared to DBD livers (35.0% versus 13.4%). These percentages of NAS are in accordance with previous reports in the literature (4,7,8). This study provides important new insight in the pathogenesis of biliary strictures after liver transplantation. It has become obvious that almost every donor liver used for transplantation has at least some degree of bile duct injury, yet bile duct strictures are seen in only a minority of transplant recipients. This suggests that rapid and effective regeneration of the bile ducts occurs in most patients after transplantation. The process of biliary regeneration, however, requires adequate supply of oxygen and nutrients and preservation of a vital source from which biliary epithelial cells can proliferate and regenerate. This may explain why the degree of vascular injury

is associated with the development of NAS. Injury of the peribiliary glands is another, hereto unrecognized risk factor for the development of NAS after transplantation. The peribiliary glands have been identified as a local niche of biliary progenitor cells for the larger bile ducts and, therefore, may be a second critical component in the process of biliary regeneration (20-24). The observed higher rate of injury of the superficial, periluminal glands compared to glands situated deep in the duct wall in the current study is compatible with the fact that blood supply to the bile ducts enters from the periphery. This results in the highest oxygen tension in the outer layers of the bile ducts, while lower oxygen tension can be anticipated in structures situated near the lumen. A similar phenomenon is well described for the bowel and the liver parenchyma where hypotension and ischemia typically lead to cell death and necrosis in zone 3 surrounding the central vein, which is most remote from the arteries and portal branches in the portal triads. For the bile ducts, this differential susceptibility to ischemia is the likely explanation why the peripherally located (deep) peribiliary glands were better preserved after cold preservation than glands located near the bile duct lumen. Interestingly, detailed histological studies of the peribiliary glands have indicated the highest percentage of biliary progenitor-like cells in the deeper located glands (23). Descendants from these progenitors undergo maturation while they migrate from the interior to the luminal surface of the bile ducts (23,24). The current study suggests that adequate preservation of at least the peribiliary glands located deep in the bile duct wall, as well the peribiliary plexus to support the supply of oxygen and nutrients, may be critical in a timely recovery of the post-ischemic bile duct.

Previous studies have demonstrated that bile salt toxicity may contribute to biliary injury and subsequent formation of bile duct strictures after transplantation (11-13). These observations become even more interesting in the light of the current knowledge that the biliary epithelial lining of the larger bile ducts is absent in a high percentage of donor livers. The lack of epithelial lining may result in the leakage of toxic bile salts into the bile duct wall, which may further contribute to the injury of stroma, peribiliary glands and vascular plexus.

It is obvious that the current method of liver preservation for transplantation does not provide sufficient protection of the bile ducts. Some clinical studies have suggested that inadequate wash out and preservation of the peribiliary vascular plexus is risk factor for the development of biliary complications (13,25). In addition to suboptimal preservation of the vasculature, it could well be that the usage of the current preservation fluids to flush the bile duct lumen during procurement provides suboptimal preservation of, or may even be deleterious to, the biliary epithelium and stroma. The current preservation fluids were designed to protect hepatocytes and sinusoidal endothelial cells and there is surprisingly limited literature on the effects of these fluids on the bile duct epithelium. This is an area that requires more research.

Alternatively, it might be that the current preservation method based on cooling is not a good method to protect the bile ducts. The high rate a severe histological injury of the bile ducts found in the current study, as well as the high incidence of NAS reported after DCD liver transplantation,

suggest that the combination of warm and subsequent cold ischemia could be particularly detrimental. Reduction, or even elimination, of cold ischemia during organ preservation can only be provided by machine perfusion. Machine perfusion is currently receiving increased research attention as this technology allows continuous perfusion and oxygenation of a donor organ at either hypothermic or (sub)normothermic conditions (26-28). Using a porcine model of DCD livers, our group has recently demonstrated that hypothermic oxygenated machine perfusion provides better protection of the peribiliary vascular plexus of the extrahepatic bile duct, compared to static cold storage (op den Dries *et al*, unpublished data 2013). However, this technique did not result in a reduction of the amount of biliary epithelial cell loss or stroma necrosis, suggesting that a more advanced methodology such as normothermic oxygenated perfusion will be needed to protect these components of the bile duct wall. Our group has recently reported the first study on the technical feasibility of normothermic machine perfusion of human donor livers (29) and in an experimental study using pig DCD livers others have suggested that normothermic oxygenated perfusion may indeed provide better preservation of bile duct epithelium and stroma (30). More research in this area is eagerly awaited to help us define the place of machine perfusion in reducing the amount of biliary injury associated with liver transplantation. The current study indicates that preservation of the peribiliary glands should be considered as an important target in research on machine preservation of donor livers.

The strength of this study is the prospective collection of the bile duct specimens in two established liver transplant centers: one in the US and one in Europe.

A limitation of the current study is that we did not obtain paraffin embedded sections in all patients. Paraffin embedded sections were available in 81 (64%) of the patients, whereas cryostat sections were available in 47 patients (36%). Morphology of the bile duct wall was sometimes less well preserved in the cryostat sections, however, we were still able to score the various histological characteristics in these biopsies. Moreover, there were no major differences in the results when cryostat sections were excluded from the analyses. Finally, imaging of the biliary tree after transplantation was only performed when clinically indicated. Subclinical and asymptomatic biliary complications, therefore, may have been missed.

In conclusion, this study provides histological evidence for a high incidence of preservation injury of the extrahepatic bile ducts of donor livers after cold storage. We have identified injury of the deep peribiliary glands and the vascular plexus as significant risk factors for the development of biliary strictures after liver transplantation. Injury to the peribiliary vasculature was more frequently present in bile ducts of DCD livers compared with DBD livers. These findings suggest that preservation of the peribiliary glands and vascular plexus is critical in the timely regeneration of the biliary epithelial lining and bile duct wall stroma after liver transplantation. Alternative preservation methods such as machine perfusion may not only reduce the incidence of biliary complications by lowering the amount of biliary injury prior to transplantation, but also by providing better protection of the peribiliary glands and vascular plexus.

## REFERENCES

- (1) Buis C I, Hoekstra H, Verdonk RC, Porte RJ. Causes and consequences of ischemic-type biliary lesions after liver transplantation. *J Hepatobiliary Pancreat Surg* 2006;13:517-524.
- (2) Buck DG, Zajko AB. Biliary complications after orthotopic liver transplantation. *Tech Vasc Interv Radiol* 2008;11:51-59.
- (3) Sharma S, Gurakar A, Jabbour N. Biliary strictures following liver transplantation: Past, present and preventive strategies. *Liver Transpl* 2008;14:759-769.
- (4) Buis CI, Verdonk RC, van der Jagt EJ, van der Hilst CS, Slooff MJ, Haagsma EB, et al. Nonanastomotic biliary strictures after liver transplantation, part 1: Radiological features and risk factors for early vs. late presentation. *Liver Transpl* 2007;13:708-18.
- (5) Verdonk R C, Buis CI, Porte RJ, van der Jagt EJ, Limburg AJ, van den Berg AP et al. Anastomotic biliary strictures after liver transplantation: causes and consequences. *Liver Transpl* 2006;12:726-735.
- (6) Meurisse N, Vanden Bussche S, Jochmans I, Francois J, Desschans B, Laleman W, Van der Merwe S, et al. Outcomes of liver transplantations using donations after circulatory death: A single-center experience. *Transplant Proc* 2012;44:2868-2873.
- (7) Pine JK, Aldouri A, Young AL, Davies MH, Attia M, Toogood GJ, Pollard SG, et al. Liver transplantation following donation after cardiac death: An analysis using matched pairs. *Liver Transpl* 2009;15:1072-1082.
- (8) Dubbeld J, Hoekstra H, Farid W, Ringers J, Porte RJ, Metselaar HJ, Baranski AG, et al. Similar liver transplantation survival with selected cardiac death donors and brain death donors. *Br J Surg* 2010;97:744-753.
- (9) Sanchez-Urdazpal L, Gores GJ, Ward EM, Maus TP, Wahlstrom HE, Moore SB et al. Ischemic-type biliary complications after orthotopic liver transplantation. *Hepatology* 1992;16:49-53.
- (10) Demetris AJ, Lunz JG, Specht S, Nozaki I. Biliary wound healing, ductular reactions, and IL-6/gp130 signaling in the development of liver disease. *World J Gastroenterol* 2006;12:3512-3522.
- (11) Hoekstra H, Porte RJ, Tian Y, Jochum W, Stieger B, Moritz W, Slooff MJ, et al. Bile salt toxicity aggravates cold ischemic injury of bile ducts after liver transplantation in Mdr2+/- mice. *Hepatology* 2006;43:1022-1031.
- (12) Buis CI, Geuken E, Visser DS, Kuipers F, Haagsma EB, Verkade HJ, Porte RJ. Altered bile composition after liver transplantation is associated with the development of nonanastomotic biliary strictures. *J Hepatol* 2009;50:69-79.
- (13) Op den Dries S, Sutton ME, Lisman T, Porte RJ. Protection of bile ducts in liver transplantation: Looking beyond ischemia. *Transplantation* 2011;92:373-379.
- (14) Noack K, Bronk SF, Kato A, Gores GJ. The greater vulnerability of bile duct cells to reoxygenation injury than to anoxia. implications for the pathogenesis of biliary strictures after liver transplantation. *Transplantation* 1993;56:495-500.



- (15) Doctor RB, Dahl RH, Salter KD, Fitz JG. Reorganization of cholangiocyte membrane domains represents an early event in rat liver ischemia. *Hepatology* 1999;29:1364-1374.
- (16) Doctor RB, Dahl RH, Salter KD, Fouassier L, Chen J, Fitz JG. ATP depletion in rat cholangiocytes leads to marked internalization of membrane proteins. *Hepatology* 2000;31:1045-1054.
- (17) Hansen T, Hollemann D, Pitton MB, Heise M, Hoppe-Lotichius M, Schuchmann M, Kirkpatrick CJ, et al. Histological examination and evaluation of donor bile ducts received during orthotopic liver transplantation--a morphological clue to ischemic-type biliary lesion? *Virchows Arch* 2012;461:41-48.
- (18) Brunner SM, Junger H, Ruemmele P, Schnitzbauer AA, Doenecke A, Kirchner GI, Farkas SA, et al. Bile duct damage after cold storage of deceased donor livers predicts biliary complications after liver transplantation. *J Hepatol* 2013;58:1133-1139.
- (19) Karimian N, op den Dries S, Porte RJ. The origin of biliary strictures after liver transplantation: Is it the amount of epithelial injury or insufficient regeneration that counts? *J Hepatol* 2013; 58: 1065-1067.
- (20) Nakanuma Y, Hosono M, Sanzen T, Sasaki M. Microstructure and development of the normal and pathologic biliary tract in humans, including blood supply. *Microsc Res Tech* 1997;38:552-570.
- (21) Irie T, Asahina K, Shimizu-Saito K, Teramoto K, Arii S, Teraoka H. Hepatic progenitor cells in the mouse extrahepatic bile duct after a bile duct ligation. *Stem Cells Dev* 2007;16:979-987.
- (22) Sutton ME, op den Dries S, Koster MH, Lisman T, Gouw ASH, Porte RJ. Regeneration of human extrahepatic biliary epithelium: the peribiliary glands as progenitor cell compartment. *Liver Int* 2012;32:554-559.
- (23) Carpino G, Cardinale V, Onori P, Franchitto A, Berloco PB, Rossi M, et al. Biliary tree stem/progenitor cells in galnds of extrahepatic and intrahepatic bile ducts: an anatomical in situ study yielding evidence of maturational lineages. *J Anat* 2012;220:186-199.
- (24) Dipaola F, Shivakumar P, Pfister J, Walters S, Sabla G, Bezerra JA. Identification of intramural epithelial networks linked to peribiliary glands that express progenitor cell markers and proliferate after injury. *Hepatology Epub* 2013 May 22.
- (25) Moench C, Moench K, Lohse AW, Thies J, Otto G. Prevention of ischemic-type biliary lesions by arterial back-table pressure perfusion. *Liver Transpl* 2003;9:285-9.
- (26) Dutkowski P, de Rougemont O, Clavien PA. Machine perfusion for 'marginal' liver grafts. *Am J Transplant* 2008;8:917-924.
- (27) Monbaliu D, Brassil J. Machine perfusion of the liver: Past, present and future. *Curr Opin Organ Transplant* 2010;15:160-166.
- (28) Imber CJ, St Peter SD, Lopez de Cenarruzabeitia I, Pigott D, James T, Taylor R, et al. Advantages of normothermic perfusion over cold storage in liver preservation. *Transplantation* 2002;73:701-709.
- (29) Op den Dries S, Karimian N, Sutton ME, Westerkamp AC, Nijsten MW, Gouw AS, et al. Ex vivo normothermic machine perfusion and viability testing of discarded human donor livers. *Am J Transplant* 2013;13:1327-1335.
- (30) Boehnert MU, Yeung JC, Bazerbachi F, Knaak JM, Selzner N, McGilvray ID, et al. Normothermic acellular ex vivo liver perfusion reduces liver and bile duct injury of pig livers retrieved after cardiac death. *Am J Transplant* 2013;13:1441-1449.



# PART C

Machine Perfusion:

A Potential Strategy to Prevent Bile Duct Injury



# CHAPTER 8

## **Hypothermic Oxygenated Machine Perfusion Prevents Arteriolonecrosis of the Peribiliary Plexus in Pig Livers Donated after Cardiac Death**

Op den Dries S, Sutton ME, Karimian N, de Boer MT, Wiersema-Buist J, Gouw ASH, Leuvenink HGD, Lisman T, Porte RJ.

*Submitted for publication.*

## ABSTRACT

**Background:** Livers derived from donation after cardiac death (DCD) are increasingly accepted for transplantation. However, DCD livers suffer additional donor warm ischemia, leading to biliary injury and more biliary complications after transplantation. It is unknown whether oxygenated machine perfusion results in better preservation of biliary epithelium and the peribiliary vasculature. We compared oxygenated hypothermic machine perfusion (HMP) with simple cold storage (SCS) in a porcine DCD model.

**Methods:** After 30 min of cardiac arrest, livers were perfused *in situ* with histidine-tryptophan-ketoglutarate (HTK) solution (4°C) and preserved for 4h by either SCS (n=9) or oxygenated HMP (10°C; n=9), using pressure-controlled arterial and portal venous perfusion. To simulate transplantation, livers were reperfused *ex vivo* at 37°C with oxygenated autologous blood. Bile duct injury and function were determined by biochemical and molecular markers, and a systematic histological scoring system.

**Results:** After reperfusion, arterial flow was higher in the HMP group, compared to SCS. Release of hepatocellular enzymes was significantly higher in the SCS group. Markers of biliary epithelial injury (biliary LDH, gamma-GT) and function (biliary pH and bicarbonate, and biliary transporter expression) were similar in the two groups. However, histology of bile ducts revealed significantly less arteriolonecrosis of the peribiliary vascular plexus in HMP preserved livers.

**Conclusions:** Oxygenated HMP prevents arteriolonecrosis of the peribiliary vascular plexus of the bile ducts of DCD pig livers and results in higher arterial flow after reperfusion. Together this may contribute to better perfusion of the bile ducts, providing a potential advantage in the post-ischemic recovery of bile ducts.

## INTRODUCTION

Livers from donation after cardiac death (DCD) donors are increasingly used for transplantation. Although this may help to increase the number of donor livers available for transplantation, DCD livers are associated with a higher risk of non-anastomotic biliary strictures (NAS), compared to livers donated after brain death (DBD (1-4). NAS have been reported in 20-33% of patients receiving a DCD liver, compared to 0-13% in patients receiving a DBD liver graft, contributes to a higher rate of morbidity and graft failure after DCD liver transplantation (5-7). In contrast to DBD liver grafts, livers from DCD donors suffer from warm ischemia in the donor during the time period between cardiac arrest and in situ cold perfusion. This donor warm ischemia in combination with subsequent cold ischemia during organ preservation is believed to be a main cause of bile duct injury leading to NAS after transplantation (8). Biliary epithelial cells have been shown to be more susceptible to warm ischemic injury than hepatocytes, which may explain the high rate of NAS following otherwise successful DCD liver transplantation (9,10). In a recent clinical study, using a standardized histological evaluation of biopsies taken from the extrahepatic bile duct at the time of transplantation, arteriolonecrosis of the peribiliary vascular plexus was identified as the only independent histological parameter predictive for the development of NAS after transplantation (11).

Machine perfusion is increasingly discussed as a promising tool to optimize livers before transplantation. During machine preservation livers are perfused with an oxygenated or non-oxygenated perfusion fluid at either low temperature or normal body temperature (12-16). So far, most investigations have focused on hypothermic machine perfusion (HMP) and studies have suggested that HMP results in better preservation of the liver parenchyma, compared to the classical method of organ preservation, static cold storage (SCS) (14-16). Although machine perfusion may be particularly beneficial for preservation of hepatocellular energy status and viability of high risk liver grafts, it is still unclear whether it also provides better protection of the biliary epithelium and the peribiliary vascular plexus, especially in livers from DCD donors.

We hypothesized that oxygenated HMP leads to reduced injury of the biliary epithelium and the bile duct wall, compared to SCS. To test this hypothesis we compared oxygenated HMP and SCS in an established DCD model of liver donation in pigs. Outcome parameters were selected to assess biliary epithelial injury and function, as well as bile duct morphology after graft preservation followed by ex vivo reperfusion using oxygenated autologous blood.

## MATERIALS AND METHODS

### Liver Procurement and Preservation

Experiments were performed in accordance with the Dutch Law on Animal Experiments and the study protocol was approved by the Institutional Animal Care and Use Committee of the University of Groningen.

Dutch Landrace pigs (n= 18; weight 90-110 kg) were premedicated with atropine, tiletamine/zolazepam, and Finadyne. General anaesthesia was induced with a 4% sevoflurane mixture with air/oxygen and maintained after intubation by mechanical ventilation using 2% sevoflurane. After administration of 20,000 U heparin and 4 mg pancuronium iv mechanical ventilation was stopped and cardiac arrest was awaited. Animals were subsequently left untouched for 30 min, resulting in a mean time interval between cessation of ventilation and *in situ* cooling of 48 min. A midline laparotomy was performed and the distal aorta and inferior vena cava were cannulated for rapid *in situ* flush out with ice-cold histidine-tryptophan-ketoglutarate (HTK) preservation solution. The abdominal cavity was filled with slush ice for additional topical cooling. The first 2L of blood, drained from the inferior vena cava, was collected in a polyethylene bag with 20.000 IU of heparin.

On the backtable, liver grafts were perfused with additional 1L of cold HTK via the portal vein, the cystic duct was ligated. After careful flushing of the bile duct with preservation solution, an 8Fr silicon catheter was inserted and secured in the distal extrahepatic bile duct for collection of bile.

Livers were randomly assigned to one of the following two groups: SCS for 4h, followed by 2h of *ex vivo* reperfusion with autologous blood (n= 9) or oxygenated HMP for 4h (n= 9), followed by 2h of *ex vivo* reperfusion with autologous blood at 37 °C.

### Hypothermic Oxygenated Machine Perfusion

HMP was initiated immediately after procurement, using a CE marked device that enables dual perfusion via both the hepatic artery and the portal vein in a closed circuit (Liver Assist®, Organ Assist, Groningen, Netherlands). Livers were perfused for 4h with Belzer machine perfusion fluid (Bridge-to-Life, Ltd., Northbrook, IL), oxygenated with 100% O<sub>2</sub>. Two rotary pumps provided pulsatile flow to the hepatic artery and continuous flow to the portal vein. Two hollow fiber membrane oxygenators provided oxygenation of the perfusion solution and removal of CO<sub>2</sub>. The system was both pressure and temperature (10°C) controlled, allowing auto-regulation of the blood flow through the liver. Pressure was limited to a mean of 30 mmHg in the hepatic artery and 5 mmHg in the portal vein, respectively.

Livers that were preserved by SCS were packed in sterile organ bags with ice-cold HTK preservation fluid on melting ice.

### **Normothermic Reperfusion**

To simulate transplantation, liver grafts were reperfused with pig blood, using the same perfusion machine as used for HMP. Temperature was kept at 37°C and mean arterial and portal pressure were limited to 60 mmHg and 11 mmHg, respectively. Flow was monitored continuously. Sodium bicarbonate (8.4% solution) was added to the perfusion fluid to maintain a physiological pH.

### **Assessment of Hepatocellular Function and Injury**

During graft reperfusion, samples were taken from the perfusion fluid every 30 min and analyzed immediately for blood gas parameters ( $pO_2$ ,  $pCO_2$ ,  $sO_2$ ,  $HCO_3^-$  and pH) using an ABL800 FLEX analyzer (Radiometer, Brønshøj, Denmark). In addition, plasma from the perfusion fluid was collected, frozen and stored at -80°C for determination of alkaline phosphatase, gamma-glutamyl transferase (gamma-GT), aspartate aminotransferase (AST), lactate dehydrogenase (LDH), and total bilirubin, using standard biochemical methods. Total biliary bile salt concentration was measured spectrophotometrically using 3-hydroxysteroid dehydrogenase (27). Biliary phospholipid concentration was analyzed using a commercially available enzymatic method; the Phospholipids FS Kit (DiaSys Diagnostic Systems, Holzheim, Germany).

### **Assessment of Biliary Epithelial Cell Function and Injury**

After reperfusion, bile production was measured gravimetrically at 30 min intervals. Biliary epithelial cell function was assessed by measuring pH, bicarbonate and glucose concentration in bile. For this purpose, bile samples were collected under mineral oil and analyzed immediately using an ABL800 FLEX analyzer. In addition, biliary concentrations of gamma-GT, alkaline phosphatase, and LDH were measured as biomarkers of biliary epithelial injury (28). TBARS were measured in bile samples as a marker for oxidative stress in bile ducts. Twenty microliters of bile (1:10 diluted with  $H_2O$ ) was mixed with 90 $\mu$ L sodium dodecyl sulfate, 10 $\mu$ L 0.05M butylated hydroxytoluene, 400 $\mu$ L 0.1 N HCL, 50 $\mu$ L 10% phosphotungstic acid and 200 $\mu$ L 0.7% 2-thiobarbituric acid. Samples were kept at 92-97°C for exactly 30 min and the content was mixed with 800 $\mu$ L 1-butanol. After centrifugation for 10 min (3,000 rpm/960g), samples from the butanol layer were transferred to a 96-well microtitre plate and fluorescence was detected at an excitation wavelength of 530nm and emission wavelength of 590nm. TBARS concentrations were calculated from a calibration curve of malondialdehyde constructed on the same plate.

### **Gene Expression of Hepatobiliary Transporter Proteins**

Hepatic mRNA expression of relevant hepatocellular and cholangiocyte transporter proteins involved in bile secretion was determined by quantitative real-time PCR. Total RNA was isolated from frozen liver tissue using TRIzol (Gibco Life Technologies, Grand Island, NY), and M-MLV reverse transcriptase (Invitrogen, Basel, Switzerland) was used to convert RNA into cDNA. For quantitative real-time detection, sense and antisense porcine-specific primers (Invitrogen,

Paisly, Scotland) were designed for the following genes, using Primer Express software (Applied Biosystems, Foster City, CA): the hepatocellular transporters BSEP (bile salt export pump; Abcb11) and MDR3 (the phospholipid translocator multidrug resistant protein 3; Abcb4), as well as the biliary epithelial transporters involved in biliary bicarbonate secretion CFTR (cystic fibrosis transmembrane conductance regulator; Abc35) and AE2 (anion exchanger 2; Slc4a2), CK19 (cytokeratin 19; used as internal standard for biliary epithelium) and 18s rRNA (internal standard). Amplification and detection were performed with the ABI Prism 7900HT Sequence Detection System using emission from SYBR® Green (Applied Biosystems). Copy numbers of CK19 and transporter gene mRNA were normalized for 18s rRNA and additionally for CK19 mRNA if appropriate. Sense and antisense porcine-specific primers used for real-time PCR can be found in **Table 1**.

**Table 1.** Sequences of primers used for real time RT PCR analysis

Gene	Code	Primers	PCR product (bp)	
BSEP (Abcb11)	DQ530510 U20587	Forward	5'-GCC AAG AAA GGA GCC TAC TAC AAA C-3'	79
		Reverse	5'-CTG TGC ATG AAG TTC TCA AGT CAG AT-3'	
MDR3 (Abcb4)	EF067318	Forward	5'-CCA GGA AGC AAA GAA ACT CAA TG-3'	139
		Reverse	5'-CTC CTC CAG GGT CAC AAT GC-3'	
CFTR (Abc35)	NM_001104950.1	Forward	5'-AATGACTGTCAAAGACCTCACTGC-3'	55
		Reverse	5'-TAATACGGCGTCCACCAT-3'	
AE2 (Slc4a2)	XM_003360081.2	Forward	5'-GATTTTCCTGTACATGGGTGTCAC-3'	53
		Reverse	5'-GCTCGTAGAACTGGATTCCGTAA-3'	
CK19	XM_003131437.1	Forward	5'-TGCCACCATTGAGAACTCCA-3'	52
		Reverse	5'-CAGACGGGCGTTGTCGA-3'	
18s	NR_46261	Forward	5'-AGTCCCTGCCCTTGTACACAC-3'	51
		Reverse	5'-AACCATCCAATCGGTAGTAGCG-3'	

### Adenosine-5'-triphosphate (ATP) Extraction and Measurement

Hepatic concentration of ATP was used as an indicator of the energy status of grafts. Liver samples were immediately frozen in liquid nitrogen. Frozen tissue was cut into 20µm slices and a total amount of ±50mg was homogenized in 1 mL of SONOP (0.372g EDTA in 130mL H<sub>2</sub>O and NaOH (pH 10.9) + 370 mL 96% ethanol) and sonificated. Precipitate was removed by centrifugation (13,000 rcf for 10 min). Supernatant was diluted with SONOP to attain a protein concentration of 200-300 µg/mL (Pierce BCA Protein Assay Kit, Thermo Scientific, Rockford, IL) and mixed with 450µL of 100mM phosphate buffer (Merck; pH 7.6-8.0). Fifty microliters of phosphate buffered supernatant was used for ATP measurement using ATP Bioluminescence assay kit CLS II (Boehringer, Mannheim, Germany) and a luminometer (Victor<sup>3</sup>™ 1420 multilabel



counter, PerkinElmer). ATP concentrations were calculated from a calibration curve constructed on the same plate, corrected for amount of protein, and values were expressed as  $\mu\text{mol/g}$  protein.

### **Histological Evaluation of Liver Parenchyma and Bile Ducts**

Before and after SCS or HMP, biopsies were taken from liver parenchyma and distal extrahepatic bile ducts. After reperfusion, additional biopsies were taken from liver parenchyma, the extrahepatic bile duct (proximal from the tip of the biliary catheter), and from the intrahepatic bile ducts beyond the level of the first and second bifurcation. Bile ducts were gently grasped with fine forceps, taking care not to touch the mucosa and specimens were excised using fine Metzenbaum scissors or a scalpel. Biopsies were divided into two sections: one preserved in 10% formaldehyde for inclusion in paraffin and one snap-frozen in liquid nitrogen and stored at  $-80^{\circ}\text{C}$  for RNA extraction. Paraffin-embedded slides were prepared for hematoxylin and eosin (H&E) staining. Additional slides were prepared for immunohistochemical detection of activated caspase-3 (Asp175, Cell Signaling #9661; 1:100), a marker for apoptosis. Injury of bile ducts was semiquantified using a systematic scoring system described by Hansen *et al.* (11). All sections were examined in a blind fashion by two independent observers. In the case of discordant results, slides were examined by a third investigator.

### **Statistical Analysis**

Continuous variables are presented as mean  $\pm$  standard error (SE). Categorical variables are presented as number and percentage. Continuous variables were compared between groups using the Student-T test and within groups by a paired T-test. Categorical variables were compared with the Pearson chi-square or Fisher's exact test. The level of significance was set at a p-value of 0.05. All statistical analyses were performed using SPSS software version 16.0 for Windows (SPSS, Inc., Chicago, IL).

## **RESULTS**

### **Reperfusion Characteristics**

After 4h of either HMP or SCS livers were reperfused *ex vivo* for 2h at  $37^{\circ}\text{C}$  using oxygenated autologous blood. During the entire reperfusion period hepatic artery flow was higher in the HMP group, which was statistically significant at 1h after reperfusion (**Figure 1A**). Portal vein flow was similar in the two groups (**Figure 1B**).

Cellular energy status as assessed by hepatic ATP content decreased significantly during SCS, but increased during oxygenated HMP. In both groups hepatic ATP content increased after normothermic reperfusion (**Figure 1C**).

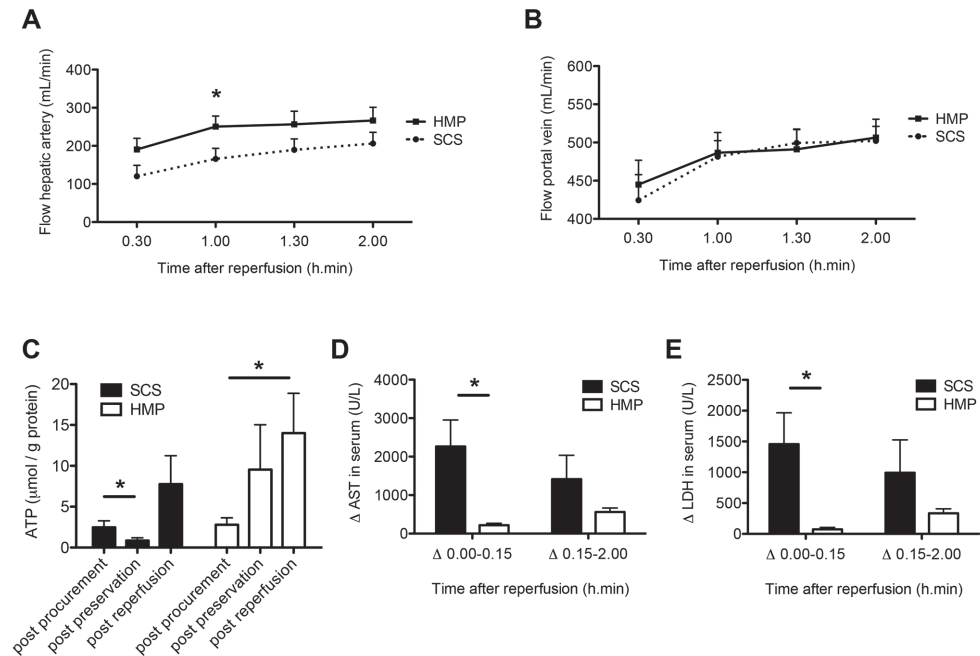


Mean weight of livers before and after HMP+ reperfusion was  $1427 \pm 208$  g and  $1381 \pm 154$  g, respectively. Liver weight before and after SCS+ reperfusion was  $1301 \pm 207$  g and  $1610 \pm 161$  g, respectively. Changes in weight were not significantly different between the two groups.

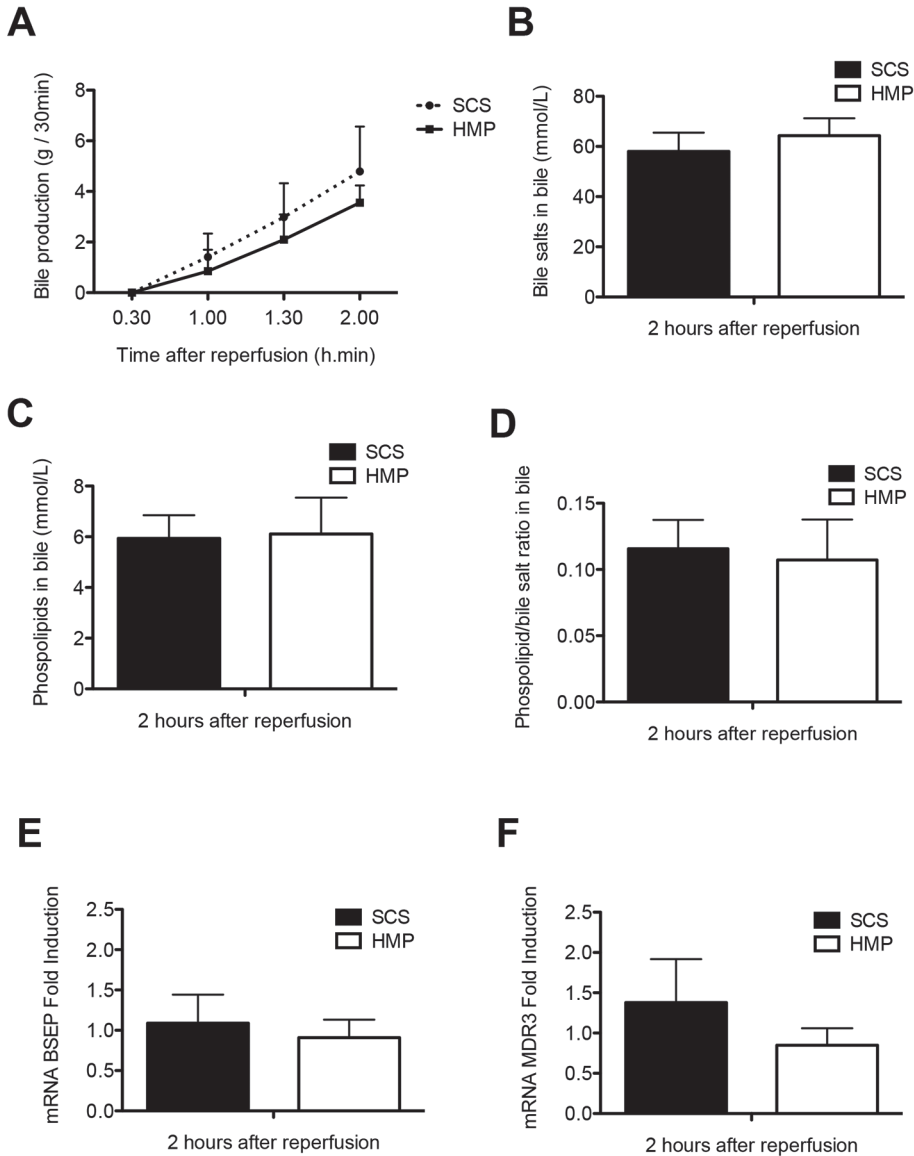
### Impact of HMP on Hepatocellular Injury and Function

Release of liver enzymes after reperfusion was used to assess the degree of hepatocellular injury. To correct for a wash-out effect of machine perfusion, the relative increase in plasma levels of AST and LDH during and after the first 15 min of reperfusion was determined. For both time intervals increase in serum enzymes was lower in the HMP group, which was significant for the first time period (**Figure 1**).

During reperfusion, increasing bile production was observed in both groups, without significant differences between the groups (**Figure 2**). There were no significant differences in biliary concentrations of bile salts and phospholipids, as well as their ratio at 2h after reperfusion or in gene expression levels of the transporter proteins BSEP (bile salt export pump; Abcb11) and MDR3 (multidrug resistance protein 3; Abcb4), responsible for the biliary secretion of bile salts and phospholipids, respectively (**Figure 2**).



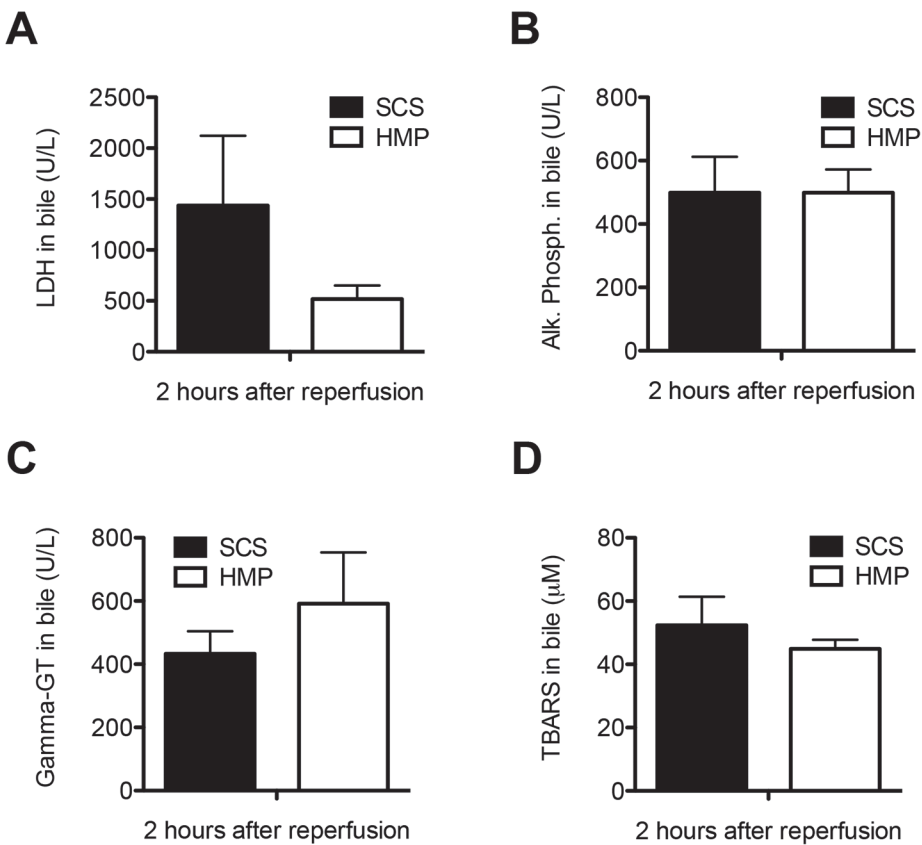
**Figure 1.** Perfusion characteristics during and changes in serum concentrations of AST and LDH after 2h of normothermic *ex vivo* sanguineous reperfusion of DCD livers that were preserved by either 4h of oxygenated HMP or SCS. **Panel A:** Blood flow through the hepatic artery. **Panel B:** Blood flow through the portal vein. **Panel C:** Changes in hepatic energy content as reflected by hepatic ATP content. **Panel D and E:** Relative increase of liver enzymes was significantly greater for SCS preserved livers, compared to livers preserved by oxygenated HMP. \* p-value < 0.05.



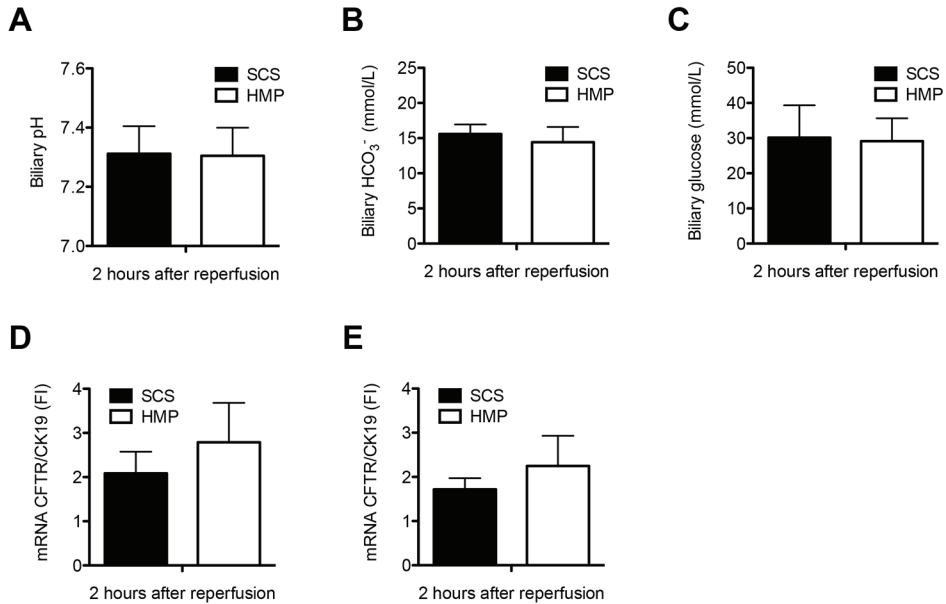
**Figure 2.** Parameters of hepatocellular secretory function of DCD livers that were preserved by either 4h of oxygenated HMP or SCS and subsequently reperfused for 2h by normothermic *ex vivo* sanguineous perfusion. **Panel A:** Evolution of bile production in the HMP and SCS group. **Panel B and C:** Biliary concentration of bile salts and phospholipids, respectively. **Panel D:** Bile salt toxicity, as represented by the ratio of biliary bile salt and phospholipid concentrations. There were no statistically significant differences between the groups. **Panel E-F:** Relative mRNA expression of the main hepatocellular bile transporters BSEP (bile salt export pump; Abcb11) and MDR3 (multidrug resistance protein 3; Abcb4) after 2h of *ex vivo* sanguineous reperfusion of DCD livers that were preserved by either 4h of oxygenated HMP or SCS. There were no significant differences between the two groups.

### Impact of HMP on Biliary Epithelial Injury and Function

Biliary concentrations of lactate dehydrogenase (LDH), alkaline phosphatase and gamma-GT at 2h after reperfusion were similar in the two groups (**Figure 3A-C**). In parallel with this, there was no difference in concentration of Thiobarbituric acid reactive substances (TBARS) in bile, a marker of oxidative stress in the bile ducts (**Figure 3D**). Moreover, there were no significant differences in biliary pH and concentrations of bicarbonate and glucose in bile at 2h after reperfusion or in gene expression of the biliary epithelial transporters involved in the secretion of bicarbonate into the bile, cystic fibrosis transmembrane conductance regulator (CFTR) and anion exchanger 2 (AE2) between the two groups (**Figure 4**).



**Figure 3.** Comparison of biochemical parameters of bile duct injury and oxidative stress in DCD livers that were preserved by either 4h of oxygenated HMP or 4h of SCS and subsequently reperfused for 2h by normothermic *ex vivo* sanguineous perfusion. **Panel A-C:** Concentration of LDH, alkaline phosphatase, and gamma-GT in bile samples at 2h after reperfusion. **Panel D:** Comparison of biliary concentration of TBARS, a marker for oxidative stress and lipid peroxidation in bile ducts, at 2h after graft reperfusion.



**Figure 4.** Comparison of functional parameters of biliary epithelial cell function in DCD livers that were preserved by either 4h of oxygenated HMP or 4h of SCS and subsequently reperfused for 2h by normothermic *ex vivo* sanguineous perfusion. There were no significant differences in biliary pH (A), biliary bicarbonate (B) and glucose concentration (C) at 2h after reperfusion between the two groups. Relative mRNA expression of the main cholangiocyte transporter proteins involved in biliary bicarbonate secretion, CFTR (cystic fibrosis transmembrane conductance regulator; ABC35) (D) and AE2 (anion exchanger 2; SLC4A2) (E) after 2h of *ex vivo* sanguineous reperfusion of DCD livers that were preserved by either 4h of oxygenated HMP or SCS. There were no significant differences between the two groups.

### Impact of HMP on Preservation of Hepatocellular and Biliary Morphology

Hematoxylin and eosin (H&E) staining and activated caspase-3 immunohistochemistry of liver parenchyma revealed less signs of ischemia-reperfusion injury in the HMP group, compared to SCS preserved livers (Figure 5). H&E staining of bile duct samples was used for semiquantitative analysis of bile duct injury, as described by Hansen *et al* (11). The results of this morphological analysis of extrahepatic bile ducts are summarized in Table 2. In this model of DCD livers, we observed extensive loss of biliary epithelial lining immediately after organ procurement. The underlying mural stroma and peribiliary vascular plexus, however, appeared relatively normal (Figure 6A). After preservation and reperfusion, bile ducts of both HMP and SCS preserved livers displayed signs of increased mural necrosis with loss of cell nuclei in the subepithelial stroma (Figure 6B). Immunohistochemistry revealed very few activated caspase-3 positive cells, suggesting that cells died from necrosis rather than apoptosis (Figure 6C). In both groups, the degree of bile duct injury was less severe in the more proximal (intrahepatic) biliary branches

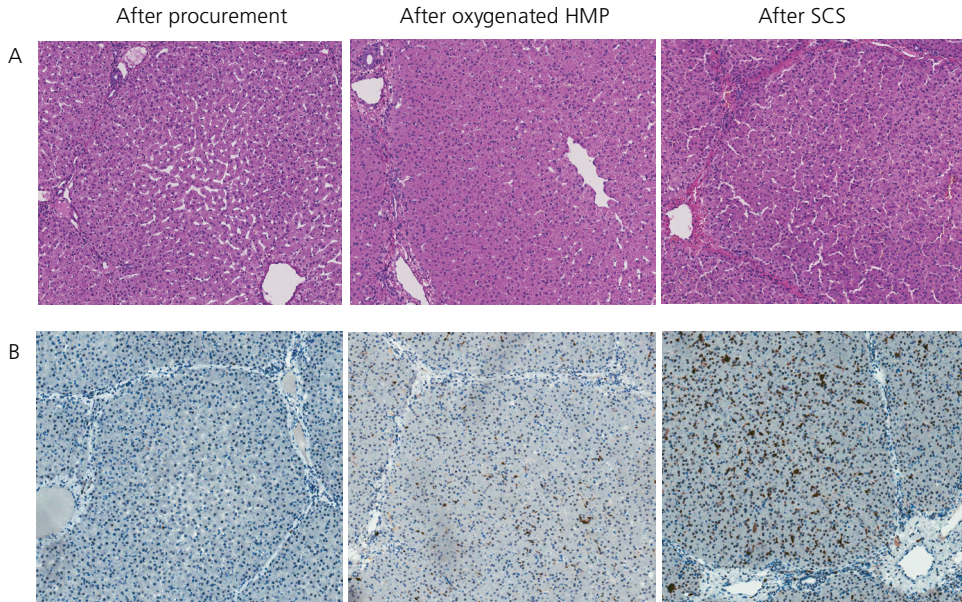
(data not shown). Interestingly, the degree of arteriolonecrosis of the peribiliary vascular plexus was significantly lower in the HMP group, compared to the SCS group (**Table 2** and **Figure 6D**).

**Table 2.** Histological analysis of bile duct injury according to Hansen et al. (11)

	Oxygenated HMP group (n=8)*	Static Cold Storage Group (n=9)	p-value
Mucosal loss			
Score 0 (no BEC loss)	0	0	NA
Score 1 ( $\leq$ 50% BEC loss)	0	0	
Score 2 ( $>$ 50% BEC loss)	8	9	
Mural necrosis			
Score 0 (no necrosis)	0	0	0.92
Score 1 ( $\leq$ 25% necrosis)	0	0	
Score 2 (25-50% necrosis)	1	1	
Score 3 (50-75% necrosis)	1	2	
Score 4 ( $>$ 75% necrosis)	6	6	
Arteriolonecrosis			
Score 0 (no arteriolonecrosis)	1	0	<b>0.02</b>
Score 1 ( $\leq$ 50% arteriolonecrosis)	6	2	
Score 2 ( $>$ 50% arteriolonecrosis)	1	7	
Bleeding			
Score 0 (no bleeding)	8	9	NA
Score 1 ( $\leq$ 50% of the bile duct)	0	0	
Score 2 ( $>$ 50% of the bile duct)	0	0	
Thrombosis			
Score 0 (no thrombi)	7	7	0.60
Score 1 (occurrence of thrombi)	1	2	

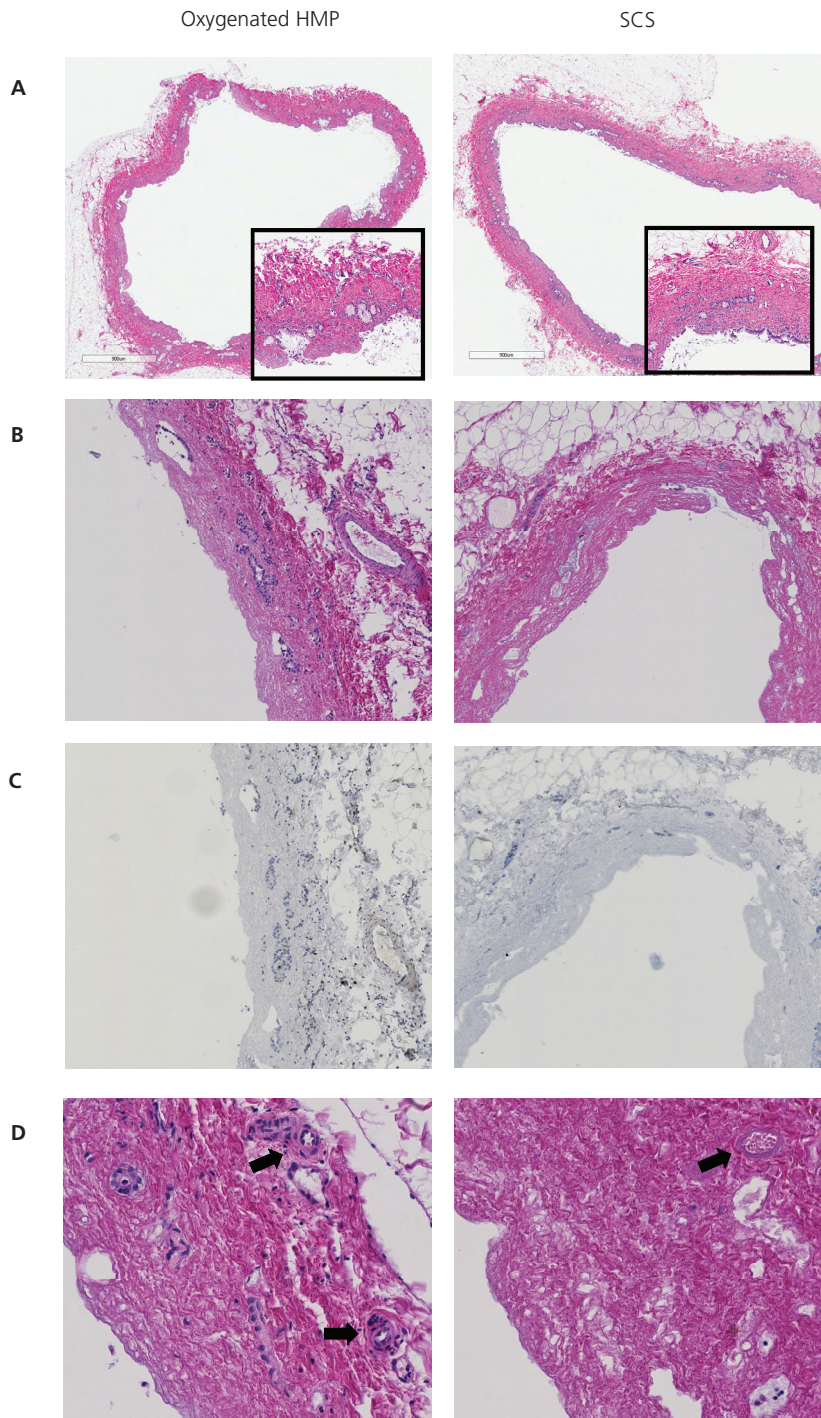
\* Bile duct histology was missing for one pig in the HMP group.

**Abbreviations used:** BEC, biliary epithelial cells; NA, not assessable



**Figure 5.** Representative examples of histology of liver parenchyma of DCD liver grafts preserved by either 4h of oxygenated HMP or 4h of SCS followed by 2h by normothermic *ex vivo* sanguineous perfusion. **Panel A:** H&E staining of a central biopsy of the liver parenchyma. **Panel B:** Caspase-3 immunohistochemistry of liver parenchyma showing less intense caspase-3 staining of hepatocytes, sinusoidal endothelial cells, and Kupffer cells in the HMP group, compared to the SCS group. Brown color indicates immunopositivity. Original magnification 200x





**Figure 6.** Representative examples of H&E histology of bile ducts of DCD liver grafts preserved by either 4h of oxygenated HMP or 4h of SCS followed by 2h by normothermic *ex vivo* sanguineous perfusion. **Panel A:** extrahepatic bile duct immediately after procurement (magnification 200x). The insert represents a higher magnification of 400x. **Panel B:** extrahepatic bile duct after preservation and reperfusion (magnification 280x). **Panel C:** Immunohistochemistry for activated caspase-3 of the same bile ducts as presented in panel B (brown color indicates immunopositivity; counterstaining with hematoxylin). Very few caspase-3 positive cells were detected in the bile duct wall stroma. Remnant biliary epithelial cells (i.e. in the peribiliary glands) were not positive for activated caspase-3. **Panel D:** higher magnification (400x) of extrahepatic bile ducts focusing on the peribiliary plexus. Arrows indicate peribiliary arterioles. Bile ducts of livers preserved by oxygenated HMP displayed significantly less signs of arteriolonecrosis, compared to livers preserved by SCS (see also **Table 1**).

## DISCUSSION

Although several authors have proposed machine perfusion as an attractive alternative method for preservation of DCD livers, it remains to be established whether this technique will reduce the amount of bile duct injury and contributes to a reduction of biliary complications. We here report the first study on the impact of oxygenated HMP on the preservation of the bile ducts in a porcine DCD model. The most striking histological difference between oxygenated HMP and SCS was a lower degree of arteriolonecrosis of the peribiliary plexus in the extrahepatic bile ducts of grafts preserved by HMP. In parallel with this we observed a higher arterial blood flow after reperfusion of HMP preserved livers, compared to SCS. Although HMP did not result in a lower amount of injury of the biliary epithelial lining or underlying stroma, the observed difference in preservation of the peribiliary vascular plexus may be clinically relevant as the presence of arteriolonecrosis in extrahepatic bile duct biopsies at the time of transplantation was recently identified as the only independent histological parameter predictive for the development of NAS after human liver transplantation (11). Machine perfusion of liver grafts may enable better preservation of the arterial vasculature of the biliary tree by providing a continuous supply of oxygen to the endothelium, better distribution of the preservation fluid, and wash-out of waste products. Adequate blood supply to the bile ducts is known to be of critical importance in maintaining viability. Insufficient arterial perfusion of liver grafts, either due to hepatic artery thrombosis or stenosis, leads to ischemic cholangiopathy, characterized by loss of biliary epithelium, necrosis of the bile duct wall and subsequent narrowing of the bile duct lumen due to sclerosing fibrosis (9,17). Therefore, better preservation of the peribiliary plexus and higher arterial flow after reperfusion as observed in the current study is an important finding.

Apart from the differences in arterial flow after reperfusion and better preservation of the peribiliary vascular plexus, we found no histological differences in amount of biliary epithelial cell loss or bile duct stroma. In parallel with this, biochemical parameters of biliary epithelial cell function (biliary pH and bicarbonate secretion) or biliary injury (concentrations LDH, AF, and gamma-GT in bile) did not differ between the two groups. Nevertheless, better of preservation and perfusion of the peribiliary vascular plexus as observed in the HMP group may result in faster and more efficient regeneration of the biliary epithelium. Two recent clinical studies have



demonstrated that biliary epithelial cell loss can be found in more than 80% of all human liver grafts before transplantation (11,18). This interesting new finding has changed the perspective from which to view the pathogenesis of biliary strictures after transplantation as it suggests that the critical factor that determines whether a graft will develop biliary strictures or not, is insufficient biliary regeneration rather than the initial biliary injury (19).

In accordance with previous studies (12,16,20,21) we have observed a reduction in biochemical and histological markers of hepatocellular injury and histological injury of the parenchyma. Release of ALT and LDH after graft reperfusion was lower in the HMP group, compared to SCS preserved livers. A difference persisted when we corrected for a possible wash-out effect in HMP preserved livers by calculating the relative change in concentration of these enzymes after the first 15 minutes of reperfusion. Although preservation of the liver parenchyma was not the primary focus of the current study, these findings confirm previous studies suggesting that HMP provides better preservation of the liver parenchyma than SCS.

Although great progress has been made in the development of machine perfusion as an alternative to SCS for preservation of donor organs, it remains to be established which method of machine perfusion is most effective. Several variations of machine perfusion have been explored, including hypothermic oxygenated or non-oxygenated, subnormothermic and normothermic perfusion (12,13,21-24). It also remains unclear whether or not machine perfusion should replace SCS completely, or whether it is sufficient to provide a short period of machine perfusion at the end of cold storage before transplantation (16). The most basic type of machine preservation is non-oxygenated hypothermic perfusion, a technique that was first applied in a clinical setting by Guarrera *et al* (12). The advantage of this technique is its relative simplicity and safety, but there is doubt whether this method is sufficient to protect high risk grafts such as those from DCD donors (20,25). Optimal preservation and protection of the biliary epithelium and bile duct wall may require a more advanced technique in which liver grafts are perfused with oxygenated perfusion fluid and at body temperature. Using a porcine model of DCD livers, Boehnert *et al* recently reported favourable effects of normothermic acellular machine perfusion of bile duct preservation in pig DCD livers (26). Our group previously demonstrated that normothermic, oxygenated perfusion of human donor livers is technically feasible. However, more research in this area is needed to determine whether this will also result in a reduction of biliary complications after transplantation (13).

In conclusion, this study suggests that oxygenated HMP of liver grafts from DCD donors provides protection against ischemic injury of the peribiliary vascular plexus, as reflected by a lower degree of arteriolonecrosis in the bile duct wall. Moreover, it is associated with higher arterial flow rates early after reperfusion, compared to SCS. Although, we observed no differences in the degree of biliary epithelial cell loss or bile duct necrosis between livers preserved by HMP or SCS, the combination of better preservation of the peribiliary plexus and higher arterial flow may contribute to a faster recovery of the post ischemic bile ducts. Whether this results in a reduction

of the rate of biliary complications after transplantation of DCD livers should be answered in clinical trials.

## ACKNOWLEDGEMENTS

We are grateful to Arjan van der Plaats and Martin Kuizenga (Organ Assist, Groningen, Netherlands) for their technical support and assistance during the perfusion experiments and to Martha op den Dries for her surgical assistance during the liver procurement procedures.

## REFERENCES

- (1) Pine JK, Aldouri A, Young AL, et al. Liver transplantation following donation after cardiac death: an analysis using matched pairs. *Liver Transpl* 2009;15:1072.
- (2) Meurisse N, Vanden Bussche S, Jochmans I, et al. Outcomes of liver transplantations using donations after circulatory death: a single-center experience. *Transplant Proc* 2012;44:2868.
- (3) Suarez F, Otero A, Solla M, Arnal F, Lorenzo MJ, Marini M, et al. Biliary complications after liver transplantation from Maastricht category-2 non-heart-beating donors. *Transplantation* 2008;85:9-14.
- (4) Dubbeld J, Hoekstra H, Farid W, et al. Similar liver transplantation survival with selected cardiac death donors and brain death donors. *Br J Surg* 2010;97:744.
- (5) Verdonk RC, Buis CI, van der Jagt EJ, et al. Nonanastomotic biliary strictures after liver transplantation, part 2: Management, outcome, and risk factors for disease progression. *Liver Transpl* 2007;13:725-732.
- (6) Sharma S, Gurakar A, Jabbour N. Biliary strictures following liver transplantation: past, present and preventive strategies. *Liver Transpl* 2008;14:759.
- (7) Heidenhain C, Pratschke J, Puhl G, et al. Incidence of and risk factors for ischemic-type biliary lesions following orthotopic liver transplantation. *Transpl Int* 2010;23:14.
- (8) Op den Dries S, Sutton ME, Lisman T, Porte RJ. Protection of bile ducts in liver transplantation: looking beyond ischemia. *Transplantation* 2011;92:373.
- (9) Stange BJ, Glanemann M, Nuessler NC, Settmacher U, Steinmuller T, Neuhaus P. Hepatic artery thrombosis after adult liver transplantation. *Liver Transpl* 2003;9:612.
- (10) Noack K, Bronk SF, Kato A, Gores GJ. The greater vulnerability of bile duct cells to reoxygenation injury than to anoxia. Implications for the pathogenesis of biliary strictures after liver transplantation. *Transplantation* 1993;56:495.
- (11) Hansen T, Hollemann D, Pitton MB, et al. Histological examination and evaluation of donor bile ducts received during orthotopic liver transplantation--a morphological clue to ischemic-type biliary lesion? *Virchows Arch* 2012;461:41.

- (12) Guarrera JV, Henry SD, Samstein B, et al. Hypothermic machine preservation in human liver transplantation: the first clinical series. *Am J Transplant* 2010;10:372.
- (13) Op den Dries S, Karimian N, Sutton ME, et al. Ex vivo normothermic machine perfusion and viability testing of discarded human donor livers. *Am J Transplant* 2013;13:1327.
- (14) Bae C, Henry SD, Guarrera JV. Is extracorporeal hypothermic machine perfusion of the liver better than the 'good old icebox'? *Curr Opin Organ Transplant* 2012;17:137.
- (15) Dutkowski P, de Rougemont O, Clavien PA. Machine perfusion for 'marginal' liver grafts. *Am J Transplant* 2008;8:917.
- (16) Schlegel A, Rougemont O, Graf R, Clavien PA, Dutkowski P. Protective mechanisms of end-ischemic cold machine perfusion in DCD liver grafts. *J Hepatol* 2013;58:278.
- (17) Nishida S, Nakamura N, Kadono J, et al. Intrahepatic biliary strictures after liver transplantation. *J Hepatobiliary Pancreat Surg* 2006;13:511.
- (18) Brunner SM, Junger H, Ruemmele P, et al. Bile duct damage after cold storage of deceased donor livers predicts biliary complications after liver transplantation. *J Hepatol* 2013;58:1133.
- (19) Karimian N, op den Dries S, Porte RJ. The origin of biliary strictures after liver transplantation: Is it the amount of epithelial injury or insufficient regeneration that counts? *J Hepatol* 2013;58:1065.
- (20) Fondevila C, Hessheimer AJ, Maathuis MH, et al. Hypothermic oxygenated machine perfusion in porcine donation after circulatory determination of death liver transplant. *Transplantation* 2012;94:22.
- (21) Vekemans K, van Pelt J, Komuta M, et al. Attempt to rescue discarded human liver grafts by end ischemic hypothermic oxygenated machine perfusion. *Transplant Proc* 2011;43:3455.
- (22) Imber CJ, St Peter SD, Lopez de Cenarruzabeitia I, et al. Advantages of normothermic perfusion over cold storage in liver preservation. *Transplantation* 2002;73:701.
- (23) Berendsen TA, Bruinsma BG, Lee J, et al. A simplified subnormothermic machine perfusion system restores ischemically damaged liver grafts in a rat model of orthotopic liver transplantation. *Transplant Res* 2012;1:6.
- (24) Gringeri E, Bonsignore P, Bassi D, et al. Subnormothermic machine perfusion for non-heart-beating donor liver grafts preservation in a Swine model: a new strategy to increase the donor pool? *Transplant Proc* 2012;44:2026.
- (25) Hessheimer AJ, Fondevila C, Garcia-Valdecasas JC. Extracorporeal machine liver perfusion: are we warming up? *Curr Opin Organ Transplant* 2012;17:143.
- (26) Boehnert MU, Yeung JC, Bazerbachi F, et al. Normothermic acellular ex vivo liver perfusion reduces liver and bile duct injury of pig livers retrieved after cardiac death. *Am J Transplant* 2013;13:1441.
- (27) Turley SD, Dietschy JM. Re-evaluation of the 3 alpha-hydroxysteroid dehydrogenase assay for total bile acids in bile. *J Lipid Res* 1978;19:924.
- (28) Vajdova K, Smrekova R, Kukan M, Lutterova M, Wsolova L. Bile analysis as a tool for assessing integrity of biliary epithelial cells after cold ischemia--reperfusion of rat livers. *Cryobiology* 2000;41:145.
- (29) Yska MJ, Buis CI, Monbaliu D, et al. The role of bile salt toxicity in the pathogenesis of bile duct injury after non-heart-beating porcine liver transplantation. *Transplantation* 2008;85:1625.



# CHAPTER 9

## **Normothermic Machine Perfusion Reduces Bile Duct Injury and Improves Biliary Epithelial Function in Rat Donor Livers**

Op den Dries S, Karimian N, Sutton ME, Kuipers M, Wiersema-Buist J,  
Ottens PJ, Kuipers J, Giepmans BN, Leuvenink HGD, Lisman T, Porte RJ.

*Submitted for publication.*

## ABSTRACT

Injury of bile ducts may occur during liver procurement and transplantation, especially in livers donated after cardiac death (DCD). Normothermic machine perfusion (NMP) has been shown to reduce hepatic injury, compared to static cold storage (SCS). However, it is unknown whether NMP provides better preservation of bile ducts. The aim of this study was to determine the impact of NMP on bile duct preservation in both DCD and non-DCD livers. DCD and non-DCD livers obtained from Lewis rats were preserved for 3h using either SCS or NMP, followed by 2h *ex-vivo* reperfusion. Biliary epithelial cell injury and function were assessed by quantification of biochemical markers and immunohistochemistry. Morphology of biliary epithelial cells was analyzed by scanning and transmission electron microscopy. Biomarkers of bile duct injury (gamma-GT and LDH in bile) were lower in NMP preserved livers, compared to SCS preserved livers. Biliary bicarbonate concentration, reflecting biliary epithelial function, was 2-fold higher in NMP preserved livers ( $p < 0.01$ ). In parallel with this, the pH of the bile was significantly higher in NMP preserved livers ( $7.63 \pm 0.02$  and  $7.74 \pm 0.05$ , for non-DCD and DCD livers, respectively), compared with SCS ( $7.46 \pm 0.02$  and  $7.49 \pm 0.04$ , for non-DCD and DCD livers, respectively). Scanning and transmission electron microscopy of donor extrahepatic bile ducts demonstrated significantly decreased injury of the biliary epithelium of NMP preserved donor livers (including loss of lateral interdigitations and mitochondrial injury). Differences between NMP and SCS were most prominent in DCD livers.

**Conclusion:** Compared to conventional SCS, NMP provides superior preservation of bile duct epithelial cell function and morphology, especially in DCD donor livers. By reducing biliary injury, NMP could have an important impact on the utilization of DCD livers and outcome after transplantation.

## INTRODUCTION

Non-anastomotic bile duct strictures are a major cause of morbidity after liver transplantation (1-3). These biliary strictures occur more frequently in livers donated after cardiac death (DCD; 20.5-33.3%), compared to livers donated after brain death (DBD; 0-12.5%) and are notoriously therapy resistant (4-7). In an effort to expand the donor pool, DCD donors are increasingly used for transplantation. In the US, the percentage of DCD donors increased from 1.1% in 1995 to 11.2% in 2010 (8). DCD grafts are procured after the donor's circulation ceases, and are subject to a period of warm ischemia in addition to the cold storage period between procurement and implantation. The combination of subsequent warm and cold ischemia is thought to lead to increased biliary injury, which can explain the increased risk of biliary strictures in DCD donor livers (9). Biliary epithelial cells have shown to be more susceptible to ischemic injury than hepatocytes, which may explain the high rate of non-anastomotic biliary strictures following otherwise successful DCD liver transplantation (10,11). As the discrepancy between available donor organs and the number of patients waiting for transplantation increases, more DCD grafts will be used, necessitating the development of better preservation methods to minimize bile duct injury and the subsequent risk for non-anastomotic strictures.

Normothermic machine perfusion (NMP) of donor livers offers potential to meet the higher requirements for DCD graft preservation. An important advantage of NMP over conventional static cold storage (SCS) is the delivery of oxygen and nutrients at 37°C, providing full metabolic support. NMP can potentially minimize or even eliminate cold ischemia during preservation. Animal studies comparing NMP with SCS have demonstrated increased bile production; lower levels of hepatocellular enzymes; and decreased parenchymal necrosis after reperfusion of NMP preserved livers (12-14). Transplantation of NMP preserved livers in animal models has been associated with improved survival (14,15). So far, studies on NMP preservation have focused on hepatocellular injury and general viability outcome parameters. It is still unknown whether NMP is protective for the bile ducts and whether it results in better preservation of biliary epithelial function than SCS.

We hypothesized that NMP provides better preservation of the bile ducts, when compared to conventional SCS. To test this hypothesis, we studied the impact of NMP on the preservation of biliary epithelium in both DCD and non-DCD rat donor livers.

## MATERIALS AND METHODS

### Animals

Male Lewis rats (LEW/Han<sup>o</sup>Hsd), weighing 303±4 g (mean±SEM) were obtained from Harlan Laboratories (Boxmeer, Netherlands). Animals received care according to the Dutch Law on



Animal Experiments, and the study protocol was approved by the Institutional Animal Care and Use Committee of the University of Groningen (IACUC-RuG).

### Experimental Design

Thirty-eight rat livers were divided into 4 experimental groups and a control group (**Table 1**). Livers were procured from DCD and non-DCD donors and in each group livers were either preserved by NMP or SCS (n=7-9 for each group). In the control group, rats (n=6) were used for *in vivo* collection of bile during 30 minutes of anesthesia as described below for liver donation. Control rats were supported with mechanical ventilation to maintain a stable arterial blood gas (pH 7.35-7.45). After bile collection, the liver and extrahepatic bile duct was excised and tissue samples were processed immediately for further analyses.

**Table 1.** Experimental design

Experimental group:	Procurement:	Storage:	Reperfusion:
Non-DCD+NMP	Non-DCD	3h normothermic machine perfusion	2h reperfusion
Non-DCD+SCS	Non-DCD	3h static cold storage	2h reperfusion
DCD+NMP	DCD	3h normothermic machine perfusion	2h reperfusion
DCD+SCS	DCD	3h static cold storage	2h reperfusion

### Procurement of DCD and Non-DCD Donor Livers

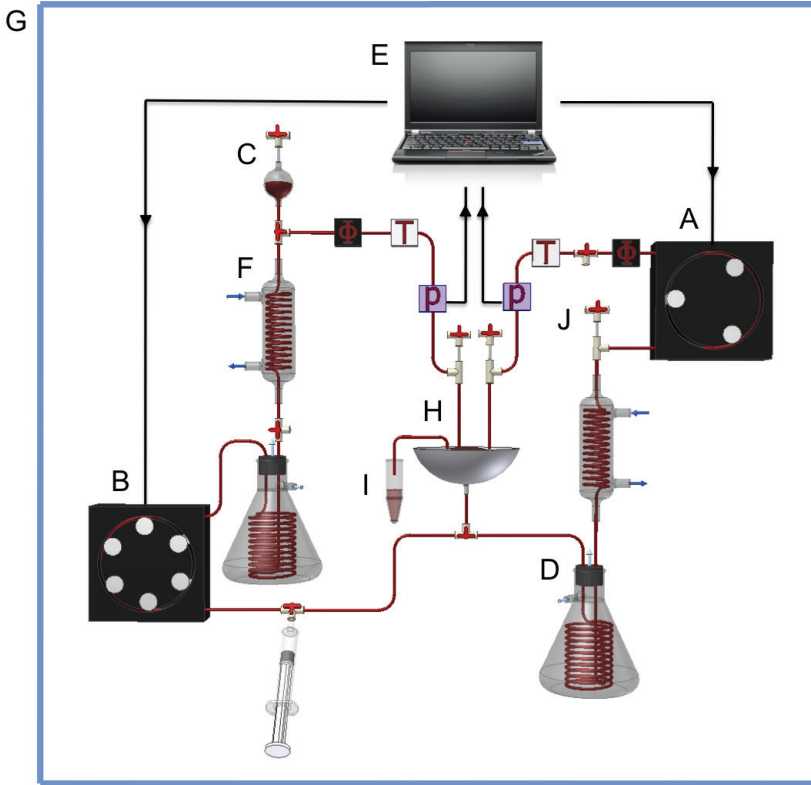
Inhalation anesthesia with isoflurane and oxygen was used before (5% isoflurane) and during the procurement (2-3% isoflurane). The extrahepatic bile duct was cannulated and 1 ml 0.9% NaCl with 500 IU of heparin was administered via the dorsal penile vein. In case of a DCD donation, manual pressure was applied to the heart for 2 minutes until cardiac contractions ceased. The aorta and pulmonary artery were clamped close to the heart and the rat was kept at 37°C for 30 minutes. In case of non-DCD donation, livers were procured immediately after laparotomy. In all groups, cannulation of the celiac trunk was followed by clamping the infra-hepatic inferior vena cava and the portal vein. The splenic vein, mesenteric artery and mesenteric vein were ligated and the portal vein was cannulated. After immediate *in situ* perfusion of the liver with 5mL 0.9% NaCl (37°C) via the portal vein cannula, the supra-hepatic inferior vena cava was transected, followed by a cold flush out with 5 mL 0.9% NaCl (4°C) via the portal vein cannula. The liver was removed and flushed with an additional 20mL of cold (4°C) 0.9% NaCl via the portal vein and 5mL of cold (4°C) 0.9% NaCl via the hepatic artery (celiac trunk cannula) before preservation by either SCS or NMP.

### Static Cold Storage and Normothermic Machine Perfusion

In the SCS groups, livers were stored in 0.9% NaCl at 4°C for 3h. In the NMP groups, livers were preserved by *ex vivo* perfusion for 3h, with a perfusion fluid consisting of 20mL human red blood cell concentrate (final hematocrit 15-20%), 59mL William's Medium E solution, 20mL



human albumin (200g/L Albuman®, Sanquin, Amsterdam, Netherlands), 1mL insulin (100 IE/mL Actrapid®, Novo Nordisk, Alphen aan den Rijn, Netherlands) and 0,1mL unfractionated heparin (5000 IE/mL), adding up to a total volume of 100mL. The same fluid was used for two hours of reperfusion.



**Figure 1.** *Ex vivo* rat liver machine perfusion system. Two roller pumps provided a pulsatile flow to the hepatic artery (A) and a continuous flow to the portal vein (B), after eliminating pulses with an air chamber (C). Two tubular membrane oxygenators provided oxygenation of the perfusion solution, as well as removal of CO<sub>2</sub> (D). The system was both pressure and temperature controlled. Flow ( $\phi$ ), pressure (P) and temperature (T) were detected by inline sensors and data were analyzed by and displayed in real-time on a connected laptop (E). Heat exchangers (F) and a plexiglass box encapsulating the perfusion system (G), ensured temperature control at 37°C. The rat liver was placed into an organ chamber (H), protected with a transparent cover to maintain a moist and warm environment. Bile was collected in Eppendorf tubes (I). Several three-way connectors were used as bubble traps (J).

For both NMP and *ex vivo* reperfusion of rat donor livers we developed a liver machine perfusion system that enabled dual perfusion via both the hepatic artery and the portal vein in a closed circuit (Figure 1). Two roller pumps (Ismatec ISM404 + ISM719 and MS-2/6-160; IDEX Health & Science, Wertheim-Mondfeld, Germany) provided pulsatile flow to the hepatic artery and

continuous flow to the portal vein. Two tubular membrane oxygenators provided oxygenation of the perfusion solution and removal of CO<sub>2</sub>. The system was pressure- and temperature-controlled, allowing auto regulation of blood flow through the liver, with constant pressure at variable flow rates. Inline sensors detected flow, pressure and temperature, and data were analyzed by and displayed in real-time on a connected laptop (software kindly provided by Organ Assist, Groningen, Netherlands). Pressure was limited to a mean of 110 mmHg in the hepatic artery and 11 mmHg in the portal vein and temperature was set to 37°C. After each liver perfusion experiment, the system was thoroughly cleaned with biological soap based on active enzyme complexes (Biotex Groen, Unilever, Rotterdam, Netherlands), water, ethanol (70%) and subsequently dried with compressed air.

### **Biochemical Markers of Function and Injury**

During *ex vivo* reperfusion, flow and temperature were registered every 15 minutes. Before reperfusion and 1h after reperfusion, samples were taken from the perfusion fluid. Samples were centrifuged (2700 rpm for 5 min at 4°C) and plasma was collected, frozen and stored at -80°C for determination of aspartate aminotransferase (AST), alanine aminotransferase (ALT), lactate dehydrogenase (LDH) and albumin, using standard biochemical methods.

Bile production was measured at 30-minute intervals by weighing Eppendorf tubes in which bile was collected from the biliary drain. Biliary epithelial cell function was assessed by measuring pH and bicarbonate concentration in bile. For this purpose, bile samples were collected under mineral oil and analyzed immediately using an ABL800 FLEX analyzer (Radiometer, Brønshøj, Denmark). Biliary concentration of gamma-glutamyl transferase (gamma-GT) and LDH were measured as biomarkers of biliary epithelial cell injury (17), and biliary bilirubin concentration was measured as biomarker of hepatocellular secretory function, using standard biochemical methods.

### **Immunohistochemistry for Activated Caspase-3 of the Extrahepatic Bile Ducts**

Immunohistochemistry for activated caspase-3 was performed to detect apoptotic cell death in extrahepatic bile ducts. After 2h of reperfusion, a segment of the extrahepatic bile duct proximal from the tip of the biliary catheter (and therefore not mechanically injured) was dissected free and stored in 10% formaldehyde for inclusion in paraffin. Slides were prepared for immunohistochemical detection of activated caspase-3 (Asp175, Cell Signaling #9661; 1:100 dilution). Antigen retrieval was performed with 1mM EDTA (pH 8.0) and microwave (15 min, 400W). GaRpo (1:50 dilution; DAKO p0448) and RaGpo (1:50 dilution; DAKO P0449) were used as secondary and tertiary antibodies. Slides were counterstained with hematoxylin.

### **Electron Microscopy of the Extrahepatic Bile Duct Epithelium**

Scanning and transmission electron microscopy (EM) were used for ultrastructural assessment of morphology of biliary epithelial lining of extrahepatic bile ducts. For this purpose, a segment of

the extrahepatic bile duct proximal from the tip of the biliary catheter was excised after 2 hours of reperfusion and samples were fixed in 2.5% glutaraldehyde in 0,1M sodiumcacodylate, postfixed with osmiumtetroxide, dehydrated through ethanol and critical point dried for scanning EM or embedded in EPON before sectioning for transmission EM. Scanning EM (Jeol6301F; 2kV) was used for qualitative assessment of the apical surface of the biliary epithelial layer. Transmission EM (FEI Cm100; 80kV) was used to assess ultrastructural changes, focusing on cellular attachments (including lateral interdigitations, tight-junctions, and cell-basement membrane contact), microvilli, and mitochondria. Characteristic ultrastructural mitochondrial changes were assessed, using a semi-quantitative scoring system modified from Crouser *et al.* (18). Ultrastructural morphology of mitochondria was graded as normal (grade 0), minimal-moderate swelling (grade 1) and severe swelling and/or flocculent condensation (grade 2). Two investigators (SodD and NK) examined all mitochondria in a blinded fashion in at least ten epithelial cells per bile duct, resulting in 20-40 biliary epithelial cells per group. Mean total number of mitochondria per cell and relative distribution of the injury grades were calculated per group.

### Statistical Analyses

Continuous data are presented as mean  $\pm$  SEM. Student T-test was used to compare two groups of continuous variables. Kruskal-Wallis Test was used for statistical comparison of >2 groups. Categorical data are expressed as numbers and percentage and groups were compared using Pearson chi-square test or Fischer's exact test as appropriate. The level of significance was set at p-value of 0.05. Analyses were performed using SPSS software version 16.0 for Windows (SPSS Inc., Chicago, IL, USA).

## RESULTS

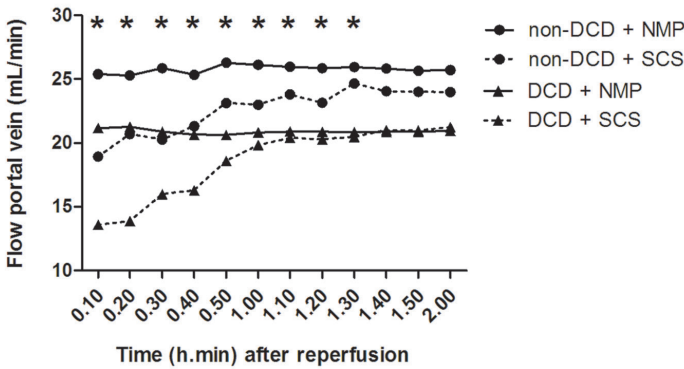
### Does NMP Provide Better Protection of Hepatic Parenchyma?

In a pressure-controlled perfusion system, blood flow through the liver can be used as an indicator of intrahepatic vascular resistance. The average arterial flow at 1h after perfusion was  $5.3 \pm 0.4$  mL/min and the portal flow was  $22.6 \pm 0.8$  mL/min. Changes in portal flow during reperfusion are presented in **Figure 2A**. The lowest initial portal flow was noted in livers preserved by SCS (both DCD and non-DCD) and the highest flow in non-DCD livers preserved by NMP. This resulted in a significant difference in portal flow between the four groups during the first 1.5h of reperfusion ( $p=0.001$  to  $0.045$  for the various time points). No significant differences in arterial flow were observed between the groups (data not shown).

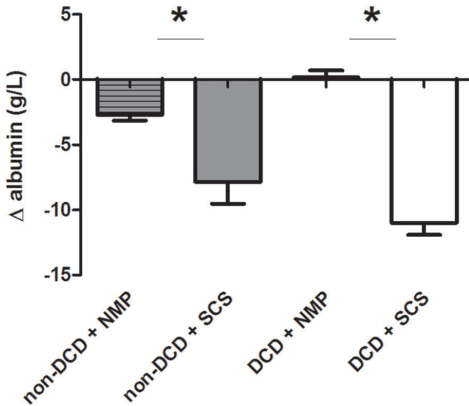
During reperfusion, plasma albumin levels in perfusion fluid decreased in SCS preserved livers, whereas no or a minimal decrease was noted in NMP preserved livers, suggesting a greater capillary leak in the SCS preserved livers (**Figure 2B**).

The relative increase of cellular enzymes AST, ALT and LDH in the perfusion fluid after reperfusion was used as a biochemical marker of hepatocellular injury. In both non-DCD and DCD donor livers the release of hepatocellular enzymes was significantly higher after SCS preservation, compared to NMP preservation (**Figure 3A-C**). The highest increase in plasma levels of AST, ALT and LDH was noted in the DCD+SCS group and lowest increase in the non-DCD+NMP group.

### A



### B



**Figure 2.** Markers of vascular resistance and integrity during reperfusion. DCD and non-DCD rat livers were preserved by normothermic machine perfusion (NMP) or static cold storage (SCS) for 3h and subsequently reperused *ex vivo*. **Panel A:** Portal vein flow during reperfusion in the four groups. A significant difference in portal flow between the four groups was observed during the first 1.5h of reperfusion. **Panel B:** Change in plasma albumin concentration in the perfusion fluid during the first hour of reperfusion. Data are expressed as mean±SEM; \* p < 0.05.

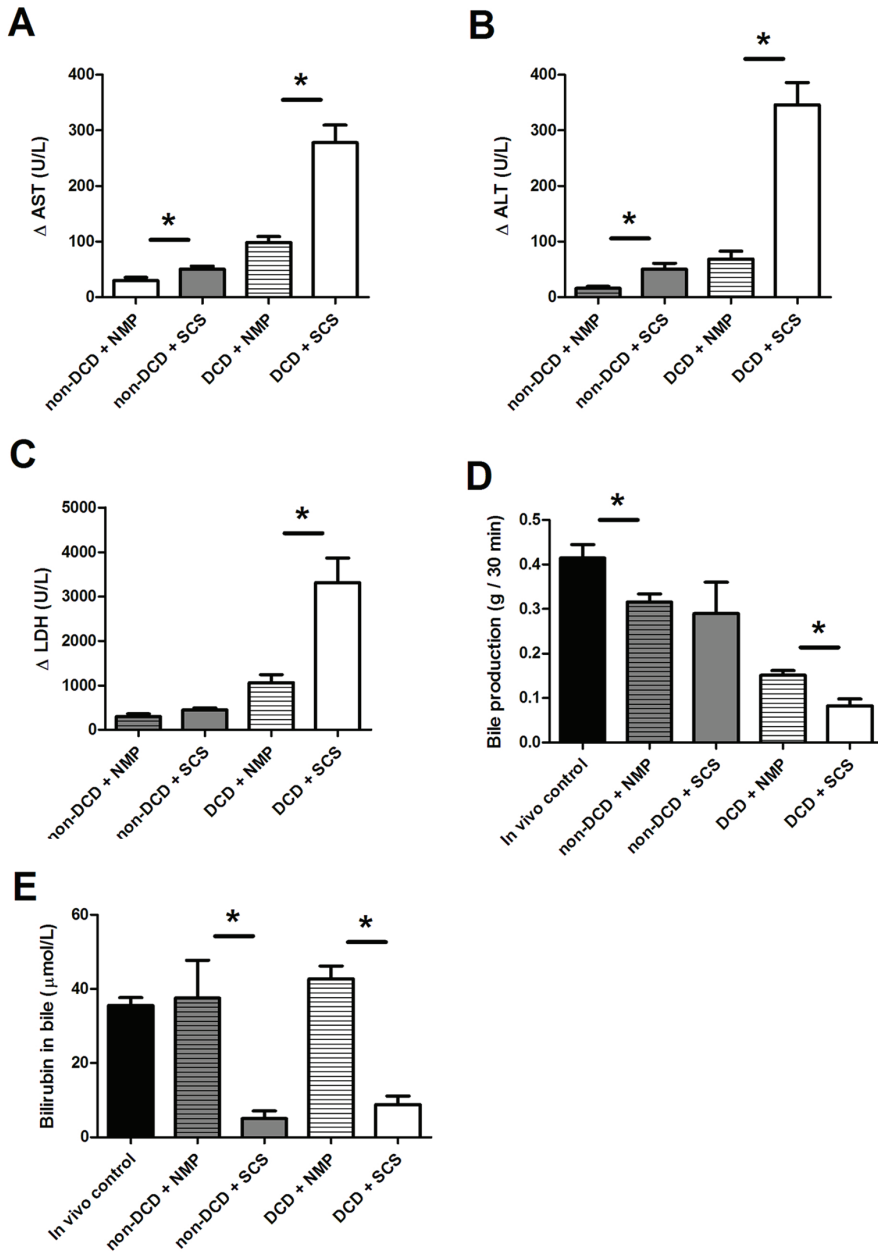
Bile production (an important parameter of hepatocyte function) was significantly higher after reperfusion of NMP preserved DCD livers, compared to SCS preserved DCD livers (**Figure 3D**). This beneficial effect of NMP was less pronounced in non-DCD donor livers. In all four groups, bile flow after *ex vivo* reperfusion remained lower than *in vivo* bile flow in control rats. In NMP preserved livers from both DCD and non-DCD donors, biliary bilirubin concentration was not significantly different from that in bile collected *in vivo* from normal controls. However, bilirubin concentration in bile produced by SCS preserved livers (both DCD and non-DCD) were about 4-times lower, compared with NMP preserved livers ( $p < 0.05$ ) (**Figure 3E**).

### **Does NMP Provide Better Protection Against Bile Duct Epithelial Cell Injury?**

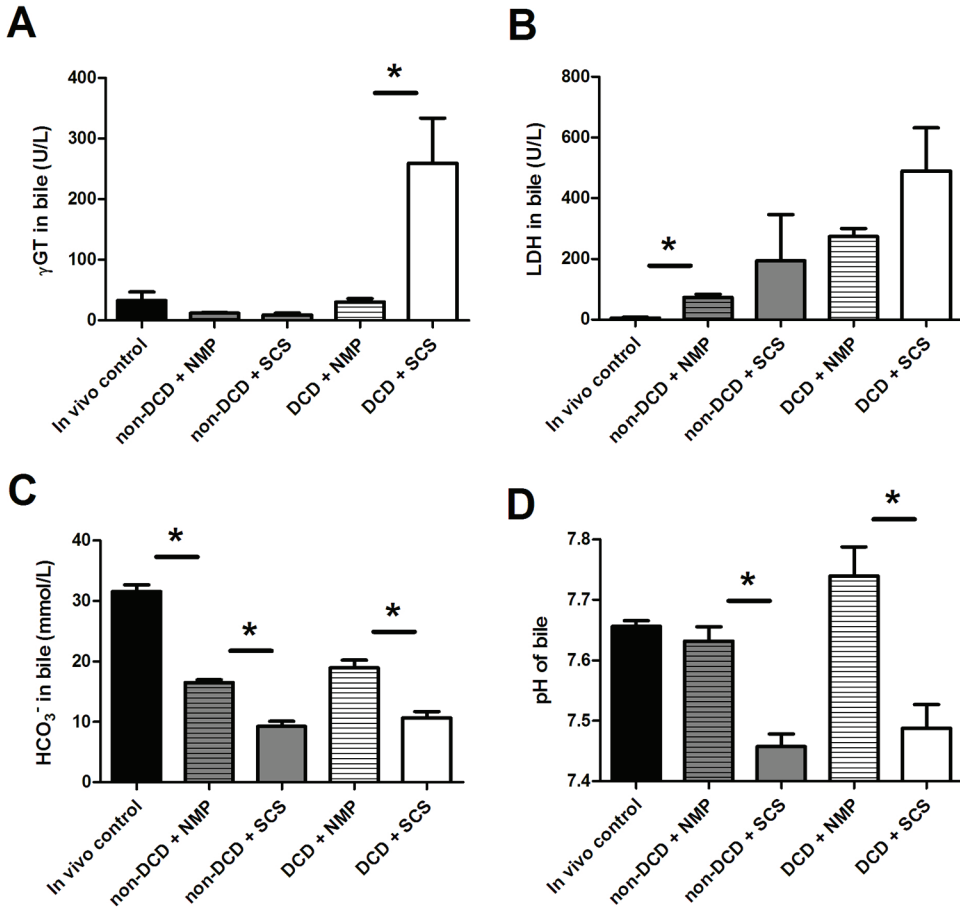
Concentrations of gamma-GT and LDH in bile were used as biomarkers of biliary epithelial injury (20). The highest biliary concentrations of enzymes at 1h after reperfusion were found in DCD livers preserved by SCS (**Figure 4A and B**). In DCD livers preserved by NMP, the mean concentration of gamma-GT in bile was significantly lower compared to SCS. In fact, mean biliary gamma-GT concentration in the DCD+NMP group was not different from values in the non-DCD groups or *in vivo* normal controls (**Figure 4A**). A similar pattern was seen for biliary LDH concentration. Although the highest biliary concentration of LDH was again found in the DCD+SCS group, the differences between the experimental groups did not reach statistical significance (**Figure 4B**).

### **Does NMP Provide Better Preservation of Bile Duct Epithelial Cell Function?**

Biliary epithelial cells contribute to bile flow and composition by active secretion of bicarbonate ( $\text{HCO}_3^-$ ) into bile, resulting in an alkalotic pH. Biliary pH and bicarbonate concentration were used as markers of epithelial function. Bile collected at 1h of reperfusion of NMP preserved livers contained 2-times higher concentration of bicarbonate compared to SCS preserved livers, in both DCD and non-DCD groups ( $p < 0.01$ ). The concentration of biliary bicarbonate, however, was significantly lower in all experimental groups than in bile collected from *in vivo* controls (**Figure 4C**). In both DCD and non-DCD livers, pH of bile was significantly higher in NMP preserved livers (pH  $7.63 \pm 0.02$  and  $7.74 \pm 0.02$ , respectively), compared with SCS (pH  $7.46 \pm 0.02$  and  $7.49 \pm 0.04$ , respectively). In fact, the biliary pH of NMP-preserved livers was normal and not significantly different from values obtained in *in vivo* controls (**Figure 4D**).



**Figure 3.** Biochemical markers of hepatocyte injury and function, measured in the perfusion fluid. DCD and non-DCD rat livers were preserved by normothermic machine perfusion (NMP) or static cold storage (SCS) for 3h and subsequently reperfused *ex vivo*. **Panel A-C:** Relative change in plasma concentration of AST, ALT and LDH into the perfusion fluid during the first hour of reperfusion. **Panel D and E:** Bile production and bilirubin concentration in bile at 1 hour after reperfusion. Data are expressed as mean $\pm$ SEM; \*  $p < 0.05$ .

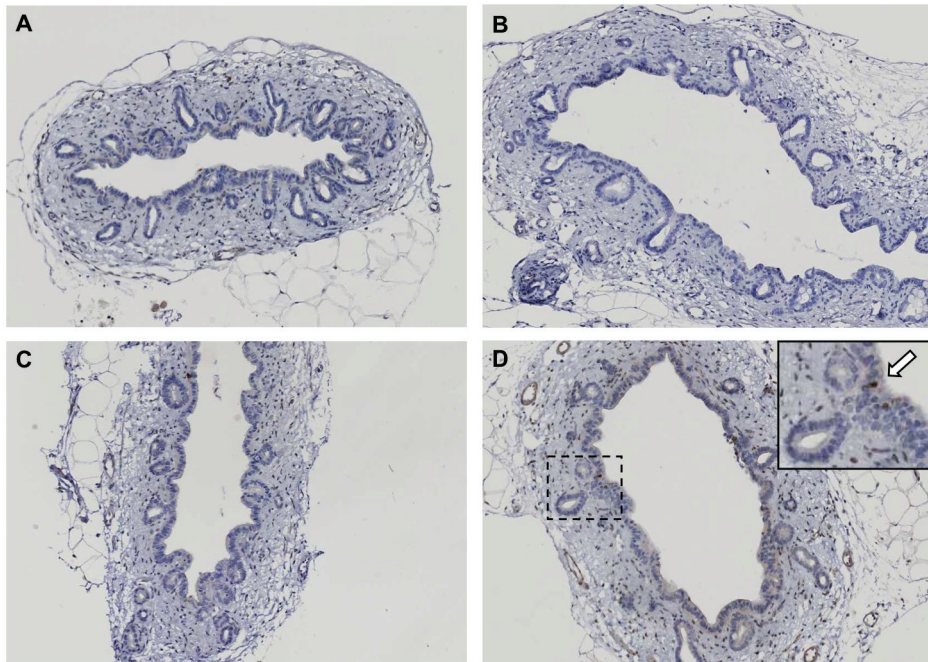


**Figure 4.** Biochemical markers of biliary epithelia cell injury and function, detected in bile. **Panel A and B:** Markers of biliary epithelial cell injury: LDH and  $\gamma$ GT in bile at 1h after reperfusion. **Panel C and D:** Markers of cholangiocyte function:  $\text{HCO}_3^-$  concentration in bile and pH of bile at 1h after reperfusion. Data are expressed as mean $\pm$ SEM; \*  $p < 0.05$ .

### Does NMP Provide Better Preservation of Bile Duct Epithelial Cell Morphology?

Light microscopy (H&E) did not show obvious injury to the bile duct epithelium. To determine whether biliary epithelial cell were apoptotic, immunohistochemistry for activated caspase-3 was compared among the groups. In general, there were hardly any caspase-3 positive cells detected (**Figure 5**). Only in the group of DCD livers preserved by SCS, caspase-3 positive biliary epithelial cells were sporadically noted (**Figure 5D**).

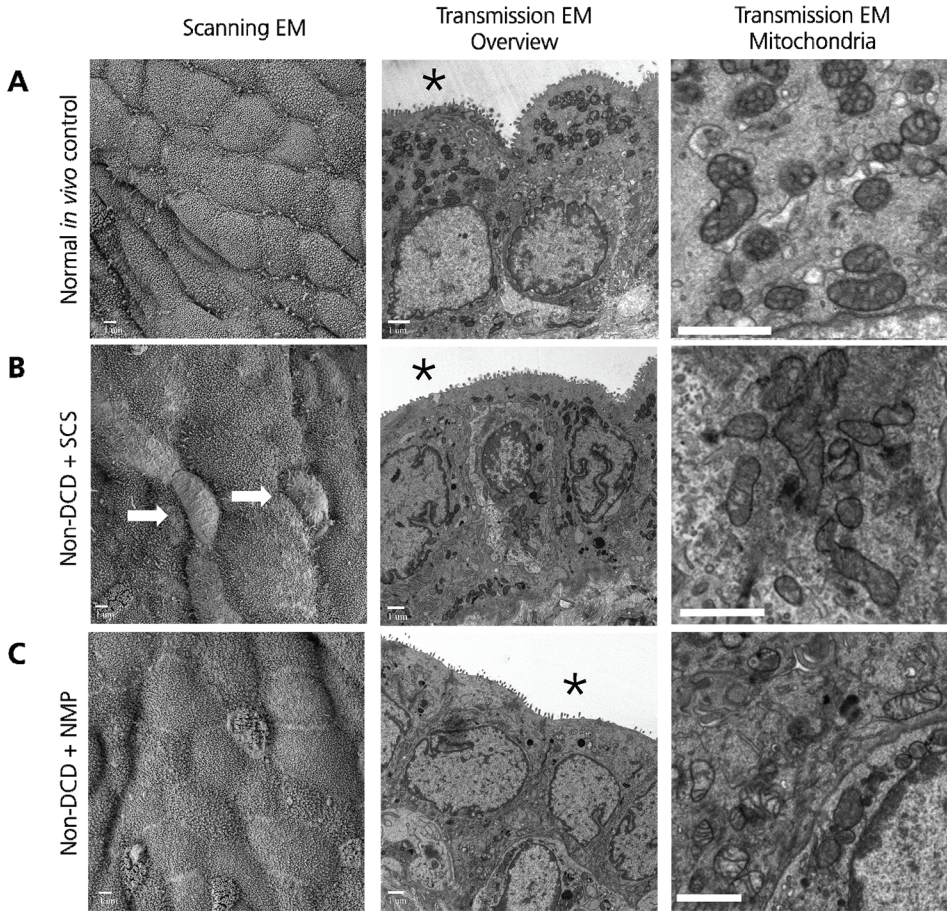




**Figure 5.** Immunohistochemistry of activated caspase-3 as marker of apoptosis. Biopsies were taken 2h after reperfusion of DCD and non-DCD rat livers preserved by either normothermic machine perfusion (NMP) or static cold storage (SCS). Immunoreactivity for caspase-3 (brown color) was only noted sporadically in DCD livers preserved by SCS. **Panel A:** non-DCD liver preserved by NMP. **Panel B:** non-DCD liver preserved by SCS. **Panel C:** DCD liver preserved by NMP. **Panel D:** DCD liver preserved by SCS. The insert presents a higher magnification with a caspase-3 positive biliary epithelial cell (arrow). Original magnification 200x. Counter staining was with hematoxylin (blue color).

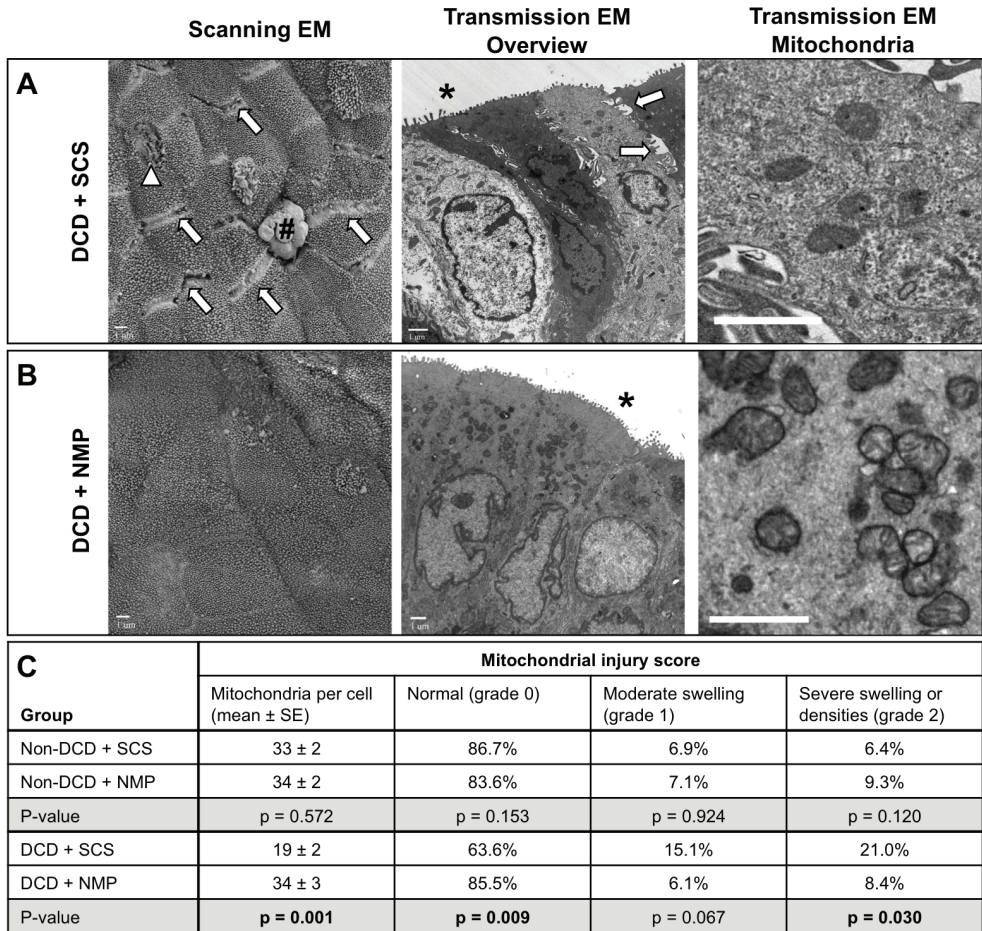
Ultrastructural changes in the morphology of extrahepatic bile ducts were assessed by scanning and transmission EM. Although the degree of morphological changes varied along the length of extrahepatic bile ducts, there were clear differences between the four groups (**Figures 6 and 7**). Scanning EM revealed no or only minor changes in bile ducts of non-DCD livers preserved by either SCS or NMP (**Figure 6**). The biliary epithelial layer was intact and most cells had normal appearing microvilli and cilia on their luminal membrane, except for the non-DCD+SCS group where some cells displayed reduced density of microvilli. Scanning EM of bile ducts of DCD livers preserved by NMP displayed well-preserved apical surface of the epithelial layer (**Figure 7B**). In contrast with this, bile ducts of DCD livers preserved by SCS exhibited signs of severe loss of lateral cell-cell contact, loss of microvilli, and sporadic epithelial cell apoptosis (**Figure 7A**). Loosening of cell-cell contact between biliary epithelial cells of DCD livers preserved by SCS was confirmed by transmission EM. Lateral cell contacts at the level of tight junction appeared less firm and a loss of intercellular interdigitations was noted along the basolateral membrane of biliary epithelial cells in the DCD+SCS group (**Figure 7A and B**). Differences between SCS and NMP were much less pronounced for non-DCD livers (**Figure 6B and C**). In addition, transmission

EM revealed a significantly reduced number of mitochondria per cell in SCS preserved DCD livers, when compared to the other three experimental groups as well as normal controls. The degree of mitochondrial injury, as assessed by a semi-quantitative scoring system, was significantly higher in SCS preserved DCD livers, compared to the other groups (**Figure 7C**).



**Figure 6.** Non-DCD rat livers: Images of scanning and transmission electron microscopy of biliary epithelium of extrahepatic bile ducts. Biopsies were taken 2h after reperfusion of non-DCD rat livers preserved by either normothermic machine perfusion (NMP) or static cold storage (SCS). **Panel A:** Images of normal bile duct epithelium. **Panel B:** Bile duct epithelium of SCS preserved non-DCD livers. **Panel C:** Bile duct epithelium of NMP preserved non-DCD livers. The lumen of the bile duct is marked with an asterisk. Biliary epithelial cells with loss of microvilli are marked with white arrows. Scale bars are 1  $\mu\text{m}$ .





**Figure 7.** DCD rat livers: Images of scanning and transmission electron microscopy of biliary epithelium of extrahepatic bile ducts. Biopsies were taken 2h after reperfusion of DCD rat livers preserved by either normothermic machine perfusion (NMP) or static cold storage (SCS). **Panel A:** Bile duct epithelium of SCS preserved DCD livers. **Panel B:** Bile duct epithelium of NMP preserved DCD livers. The lumen of the bile duct is marked with an asterisk, the arrows point at widening of tight-junctions (SEM) and loss of lateral interdigitations (TEM). White triangles indicate loss of microvilli at the apical membrane. An apoptotic bile duct epithelium cell is marked with a pound symbol (#). **Panel C:** Summary of mitochondrial injury in biliary epithelial cells in all four groups, based on a modified semi-quantitative grading system, as described by Crouser *et al.* (19). Scale bars are 1  $\mu$ m.

## DISCUSSION

Machine perfusion is receiving increasing attention as an attractive alternative for static cold storage of liver grafts before transplantation. Previous animal studies on NMP have shown decreased hepatocellular injury and better early posttransplant survival in NMP preserved livers, compared to SCS preserved livers (12-15). However, it remains unknown whether NMP also provides better protection against biliary injury. In the current study we have performed a detailed analysis of bile duct epithelial injury and function in both DCD and non-DCD rat livers preserved by either NMP or SCS.

The principal novel finding of our study is that liver graft preservation by NMP provided significantly better protection against biliary epithelial cell injury and dysfunction than conventional SCS. In addition, NMP resulted in better preservation of the cellular ultrastructural morphology of biliary epithelium, compared to SCS. Importantly, the beneficial effects of NMP were most prominent in DCD livers.

In both DCD and non-DCD livers, the post-reperfusion release of AST, ALT and LDH was significantly lower in NMP preserved livers, compared to SCS preserved livers. These findings confirm data from previous studies in rat and porcine livers, which have shown a protective effect of NMP against preservation injury of liver parenchyma. (12-15). Based on a porcine model of normothermic perfusion, bile output has been suggested as the most relevant parameter of liver viability (12,13). In our study we observed both increased bile production and higher levels of bilirubin in bile in NMP preserved livers, confirming improved preservation of the donor liver parenchyma by NMP.

The highest concentrations of gamma-GT and LDH (established biomarkers of biliary epithelial injury [17]) were found in bile samples obtained after reperfusion of DCD livers preserved by SCS. On the contrary, biliary gamma-GT concentrations in NMP preserved DCD livers were similar to those in bile from normal controls. This indicates that NMP provides important protection of biliary epithelium against ischemia-reperfusion injury in DCD livers.

In parallel with this, we observed a significantly better preservation of biliary epithelial cell function in NMP preserved livers, as was reflected by increased biliary secretion of bicarbonate and higher biliary pH. This functional beneficial effect of NMP was seen in both DCD and non-DCD livers. Bicarbonate secretion by biliary epithelial cells contributes to bile flow and plays an important role in protection of these cells against bile salt toxicity (19). The concept of a 'biliary HCO<sub>3</sub><sup>-</sup> umbrella' was recently introduced as a key protective mechanism of biliary epithelium against the toxic effects of hydrophobic bile salt monomers in human bile (20). *In vitro* studies have shown that biliary bicarbonate secretion by biliary epithelial cells is critical for their protection against bile salt induced injury and apoptosis (19). Secretion of bicarbonate results in elevation of the biliary pH, especially near the apical cell membrane. In an alkaline environment, bile salts

are deprotonated, which is clinically relevant as protonated bile salts can passively enter cells by uncontrolled membrane permeation, causing apoptosis (19,20).

Several experimental and clinical studies have shown that bile salt toxicity contributes to bile duct injury and is associated with the occurrence of non-anastomotic biliary strictures after transplantation (16,21,22). The observed increased bicarbonate concentrations in bile samples of NMP preserved livers in the current study could, therefore, be an important ancillary factor protecting these cells against bile salt-induced injury after transplantation.

Although bicarbonate concentration in post-reperfusion bile samples was twice as high in NMP preserved livers compared to SCS preserved livers, absolute values were still lower than in bile samples from normal *in vivo* controls. This suggests that there is still room for improvement by further stimulation of biliary bicarbonate secretion during NMP. On the other hand, it should be noted that the pH of bile samples obtained from NMP preserved livers was already comparable to values in normal *in vivo* controls. Apparently, bicarbonate-independent mechanisms also play a role in the alkalization of bile.

Although previous studies have suggested that apoptosis is a possible mechanism of biliary cell death due to ischemia (23), this is not confirmed by the current study. Morphological changes compatible with apoptosis were found only sporadically in the DCD+SCS group. Paucity of apoptotic cells was confirmed by scanning EM of the biliary epithelium. The most prominent ultrastructural change after reperfusion of SCS preserved DCD livers was loss of cell-cell contact and intracellular digitations between biliary epithelial cells. In addition, the number of mitochondria per cell was significantly reduced and mitochondria displayed prominent changes compatible with ischemia-induced injury (18). These ultrastructural changes were most severe in DCD livers preserved by SCS and absent in NMP preserved DCD livers. Intracellular depletion of adenosine triphosphate (ATP) in SCS preserved livers is a likely explanation for the observed morphological changes. In an *in vitro* model of cultured normal rat biliary epithelial cells, depletion of ATP has been shown to result in substantial morphological changes as detected by EM, including extensive loss of basolateral interdigitations and apical microvilli (24,25). Interestingly, several hours after restoration of ATP, viable cells still failed to display organized secondary membrane structures such as lateral interdigitations, which coincided with a protracted recovery of cellular functions. Necrotic or apoptotic cells were noted only occasionally (24,25). The morphological changes described in these *in vitro* cell culture studies are remarkably similar to those observed in SCS preserved livers in the current study.

Apart from the remarkably protective effect of NMP on the bile duct epithelium, NMP could provide additional clinical opportunities, such as *ex vivo* selection of donor livers prior to implantation (26,27). According to the United Network for Organ Sharing (UNOS) database, 58.2% of the DCD livers (and 14.4% of the non-DCD livers) with consent for donation, are currently not accepted due to the perceived high risk of complications after transplantation (8). NMP could not only provide better preservation of these DCD livers, but also allows pharmacological

preconditioning and *ex vivo* testing of hepatic viability and function prior to transplantation. Our group has recently demonstrated that normothermic, oxygenated perfusion of human donor livers is technically feasible, which could contribute to a considerable expansion of the number of organs available for transplantation (28).

We deliberately did not transplant livers and we performed *ex vivo* reperfusion to mimic transplantation. The limitation of a transplant model would have been the impossibility to take biopsies from the extrahepatic bile ducts after graft reperfusion. In addition, transplantation would have introduced potentially confounding factors such as immune-mediated bile duct injury due to acute rejection. On the other hand, the current model of *ex vivo* reperfusion did not allow us to determine the process of biliary epithelial cell injury more long-term after reperfusion. From the current experiments we could not determine whether the observed injury to epithelial cells is progressive with time or reversible.

Two recent clinical studies have demonstrated that biliary epithelial cell loss can be found in more than 80% of all human liver grafts before transplantation (29,30). In accordance with this, our group has recently observed extensive loss of biliary epithelial cells immediately after liver procurement in a DCD model of pig livers (op den Dries, unpublished data). Collectively, these findings suggest that detachment and loss of the biliary epithelium is a key event in ischemia-induced injury of donor livers. In the current study we observed epithelial cell injury and detachment, but no complete loss of the epithelial layer. Apparently, biliary epithelial cells of rat bile ducts are less susceptible to ischemia or the process of detachment is slower compared to human and porcine bile ducts. Alternatively, it could be that the differences between rats, pigs and humans are explained by the more hydrophobic, and therefore, more toxic bile salt composition in the latter two (31).

In conclusion, this study suggests that NMP provides superior preservation of the bile ducts of both DCD and non-DCD liver grafts, compared to conventional SCS. This beneficial effect of NMP is most pronounced in DCD livers. By reducing biliary injury, NMP could have an important impact on the utilization of DCD livers and may improve outcome after transplantation. These findings provide a strong stimulus for a clinical trial of NMP in human DCD liver transplantation.

## ACKNOWLEDGEMENT

We are grateful to Pieter Hamming (Organ Assist, Groningen, Netherlands) for his IT support and Gert op den Dries for technically illustrating the rat liver perfusion system (**Figure 1**).

## REFERENCES

- (1) Verdonk RC, Buis CI, van der Jagt EJ, Gouw AS, Limburg AJ, Slooff MJ, Kleibeuker JH, et al. Nonanastomotic biliary strictures after liver transplantation, part 2: Management, outcome, and risk factors for disease progression. *Liver Transpl* 2007;13:725-732.
- (2) Sharma S, Gurakar A, Jabbour N. Biliary strictures following liver transplantation: Past, present and preventive strategies. *Liver Transpl* 2008;14:759-769.
- (3) Heidenhain C, Pratschke J, Puhl G, Neumann U, Pascher A, Veltzke-Schlieker W, Neuhaus P. Incidence of and risk factors for ischemic-type biliary lesions following orthotopic liver transplantation. *Transpl Int* 2010;23:14-22.
- (4) Meurisse N, Vanden Bussche S, Jochmans I, Francois J, Desschans B, Laleman W, Van der Merwe S, et al. Outcomes of liver transplantations using donations after circulatory death: A single-center experience. *Transplant Proc* 2012;44:2868-2873.
- (5) Pine JK, Aldouri A, Young AL, Davies MH, Attia M, Toogood GJ, Pollard SG, et al. Liver transplantation following donation after cardiac death: An analysis using matched pairs. *Liver Transpl* 2009;15:1072-1082.
- (6) Suarez F, Otero A, Solla M, Arnal F, Lorenzo MJ, Marini M, Vazquez-Iglesias JL, et al. Biliary complications after liver transplantation from maastricht category-2 non-heart-beating donors. *Transplantation* 2008;85:9-14.
- (7) Dubbeld J, Hoekstra H, Farid W, Ringers J, Porte RJ, Metselaar HJ, Baranski AG, et al. Similar liver transplantation survival with selected cardiac death donors and brain death donors. *Br J Surg* 2010;97:744-753.
- (8) Orman ES, Barritt AS, 4th, Wheeler SB, Hayashi PH. Declining liver utilization for transplantation in the united states and the impact of donation after cardiac death. *Liver Transpl* 2013;19:59-68.
- (9) Op den Dries S, Sutton ME, Lisman T, Porte RJ. Protection of bile ducts in liver transplantation: Looking beyond ischemia. *Transplantation* 2011;92:373-379.
- (10) Stange BJ, Glanemann M, Nuessler NC, Settmacher U, Steinmuller T, Neuhaus P. Hepatic artery thrombosis after adult liver transplantation. *Liver Transpl* 2003;9:612-620.
- (11) Noack K, Bronk SF, Kato A, Gores GJ. The greater vulnerability of bile duct cells to reoxygenation injury than to anoxia. implications for the pathogenesis of biliary strictures after liver transplantation. *Transplantation* 1993;56:495-500.
- (12) Imber CJ, St Peter SD, Lopez de Cenarruzabeitia I, Pigott D, James T, Taylor R, McGuire J, et al. Advantages of normothermic perfusion over cold storage in liver preservation. *Transplantation* 2002;73:701-709.
- (13) St Peter SD, Imber CJ, Lopez I, Hughes D, Friend PJ. Extended preservation of non-heart-beating donor livers with normothermic machine perfusion. *Br J Surg* 2002;89:609-616.



- (14) Tolboom H, Pouw RE, Izamis ML, Milwid JM, Sharma N, Soto-Gutierrez A, Nahmias Y, et al. Recovery of warm ischemic rat liver grafts by normothermic extracorporeal perfusion. *Transplantation* 2009;87:170-177.
- (15) Fondevila C, Hessheimer AJ, Maathuis MH, Munoz J, Taura P, Calatayud D, Leuvenink H, et al. Superior preservation of DCD livers with continuous normothermic perfusion. *Ann Surg* 2011;254:1000-1007.
- (16) Hoekstra H, Porte RJ, Tian Y, Jochum W, Stieger B, Moritz W, Slooff MJ, et al. Bile salt toxicity aggravates cold ischemic injury of bile ducts after liver transplantation in Mdr2+/- mice. *Hepatology* 2006;43:1022-1031.
- (17) Vajdova K, Smrekova R, Kukan M, Lutterova M, Wsolova L. Bile analysis as a tool for assessing integrity of biliary epithelial cells after cold ischemia--reperfusion of rat livers. *Cryobiology* 2000;41:145-152.
- (18) Crouser ED, Julian MW, Blaho DV, Pfeiffer DR. Endotoxin-induced mitochondrial damage correlates with impaired respiratory activity. *Crit Care Med* 2002;30:276-284.
- (19) Hohenester S, Wenniger LM, Paulusma CC, van Vliet SJ, Jefferson DM, Elferink RP, Beuers U. A biliary HCO<sub>3</sub><sup>-</sup> umbrella constitutes a protective mechanism against bile acid-induced injury in human cholangiocytes. *Hepatology* 2012;55:173-183.
- (20) Beuers U, Hohenester S, de Buy Wenniger LJ, Kremer AE, Jansen PL, Elferink RP. The biliary HCO<sub>3</sub><sup>-</sup> umbrella: A unifying hypothesis on pathogenetic and therapeutic aspects of fibrosing cholangiopathies. *Hepatology* 2010;52:1489-1496.
- (21) Yska MJ, Buis CI, Monbaliu D, Schuurs TA, Gouw AS, Kahmann ON, Visser DS, et al. The role of bile salt toxicity in the pathogenesis of bile duct injury after non-heart-beating porcine liver transplantation. *Transplantation* 2008;85:1625-1631.
- (22) Buis CI, Geuken E, Visser DS, Kuipers F, Haagsma EB, Verkade HJ, Porte RJ. Altered bile composition after liver transplantation is associated with the development of nonanastomotic biliary strictures. *J Hepatol* 2009;50:69-79.
- (23) Yang F, Gaudio E, Onori P, Wise C, Alpini G, Glaser SS. Mechanisms of biliary damage. *J Cell Death* 2010;2010:13-21.
- (24) Doctor RB, Dahl RH, Salter KD, Fitz JG. Reorganization of cholangiocyte membrane domains represents an early event in rat liver ischemia. *Hepatology* 1999;29:1364-1374.
- (25) Doctor RB, Dahl RH, Salter KD, Fouassier L, Chen J, Fitz JG. ATP depletion in rat cholangiocytes leads to marked internalization of membrane proteins. *Hepatology* 2000;31:1045-1054.
- (26) Dutkowski P, de Rougemont O, Clavien PA. Machine perfusion for 'marginal' liver grafts. *Am J Transplant* 2008;8:917-924.
- (27) Monbaliu D, Brassil J. Machine perfusion of the liver: Past, present and future. *Curr Opin Organ Transplant* 2010;15:160-166.
- (28) Op den Dries S, Karimian N, Sutton ME, Westerkamp AC, Nijsten MW, Gouw AS, Wiersema-Buist J, et al. Ex vivo normothermic machine perfusion and viability testing of discarded human donor livers. *Am J Transplant* 2013;13:1327-1335.

- (29) Hansen T, Hollemann D, Pitton MB, Heise M, Hoppe-Lotichius M, Schuchmann M, Kirkpatrick CJ, et al. Histological examination and evaluation of donor bile ducts received during orthotopic liver transplantation--a morphological clue to ischemic-type biliary lesion? *Virchows Arch* 2012;461:41-48.
- (30) Brunner SM, Junger H, Ruemmele P, Schnitzbauer AA, Doenecke A, Kirchner GI, Farkas SA, et al. Bile duct damage after cold storage of deceased donor livers predicts biliary complications after liver transplantation. *J Hepatol* 2013;58:1133-1139.
- (31) Heuman DM. Quantitative estimation of the hydrophilic-hydrophobic balance of mixed bile salt solutions. *J Lipid Res* 1989;30:719-730.



# CHAPTER 10

## **Ex-vivo Normothermic Machine Perfusion and Viability Testing of Discarded Human Donor Livers**

Op den Dries S, Karimian N, Sutton ME, Westerkamp AC, Nijsten MWN, Gouw ASH, Wiersema-Buist J, Lisman T, Leuvenink HGD, Porte RJ.

*Am J Transplant. 2013; 13: 1327-1335.*

## ABSTRACT

In contrast to traditional static cold preservation of donor livers, normothermic machine perfusion may reduce preservation injury, improve graft viability, and potentially allows *ex-vivo* assessment of graft viability prior to transplantation. We have studied the feasibility of normothermic machine perfusion in four discarded human donor livers.

Normothermic machine perfusion consisted of pressure and temperature controlled pulsatile perfusion of the hepatic artery and continuous portal perfusion for 6 hours. Two hollow fiber membrane oxygenators provided oxygenation of the perfusion fluid. Biochemical markers in the perfusion fluid reflected minimal hepatic injury and improving function. Lactate levels decreased to normal values, reflecting active metabolism by the liver (mean lactate  $10.0 \pm 2.3$  mmol/L at 30 min to  $2.3 \pm 1.2$  mmol/L at 6 h). Bile production was observed throughout the 6 h perfusion period (mean rate  $8.16 \pm 0.65$  g/h after the first hour). Histological examination before and after 6 h of perfusion showed well-preserved liver morphology without signs of additional hepatocellular ischemia, biliary injury, or sinusoidal damage.

In conclusion, this study shows that normothermic machine perfusion of human donor livers is technically feasible. It allows assessment of graft viability before transplantation, which opens new avenues for organ selection, therapeutic interventions and preconditioning.

## INTRODUCTION

Although the traditional organ preservation method of static cold storage is sufficient for preserving most livers for transplantation, it fails to maintain viability in part of the grafts of suboptimal quality, or so called extended criteria donor (ECD) grafts. Higher rates of delayed graft function, primary nonfunction, and cholangiopathies are seen in recipients of donation after cardiac death (DCD), older and steatotic grafts (1,2). As the discrepancy between available donor organs and the number of patients waiting for transplantation increases, more ECD grafts will be used, necessitating the development of new and better preservation and selection methods. Machine perfusion of donor livers offers potential to meet the requirements to preserve ECD grafts. A relatively simple option is hypothermic machine perfusion (0-4°C), offering oxygen supply to the liver and the removal of waste products. However, although hypothermic perfusion has achieved adequate results in near-clinical and clinical setting (3,4), its use seems to offer too little protection in suboptimal grafts (5,6). An important advantage of normothermic perfusion (37°C) over static cold preservation and hypothermic perfusion is the full metabolic support and the possibility to assess graft viability prior to transplantation. In addition, liver grafts could potentially be optimized by pharmacological conditioning during normothermic perfusion. However, although normothermic machine perfusion may provide better viability testing and resuscitation, it requires challenging, near-physiological conditions (7). To date, successful normothermic perfusion of livers has been reported only in animal models (8-12). Although these results are promising, feasibility of normothermic machine perfusion in human livers remains to be demonstrated. We studied the feasibility of normothermic, oxygenated machine preservation and *ex vivo* viability testing of discarded human ECD livers, using a newly developed liver perfusion machine.

## MATERIALS AND METHODS

### Donor Livers

Between May 2012 and August 2012, four human livers derived from DCD donors that were declined for transplantation by all three transplant centers in the Netherlands were included in this study. Characteristics of these four livers are presented in **Table 1**. In all cases permission to use the liver for this study was obtained from the relatives. The study was approved by the medical ethical committee of the University Medical Center Groningen and the Nederlandse Transplantatie Stichting, the competent authority for organ donation in the Netherlands.

### Normothermic Machine Perfusion

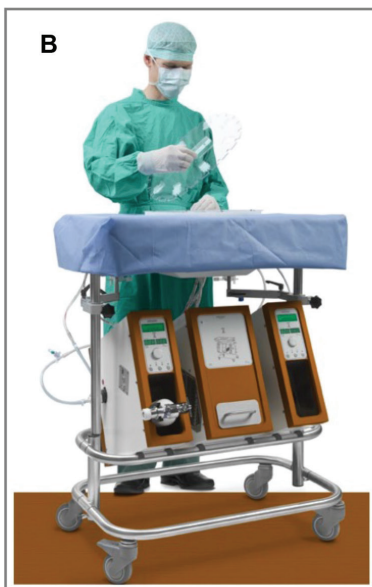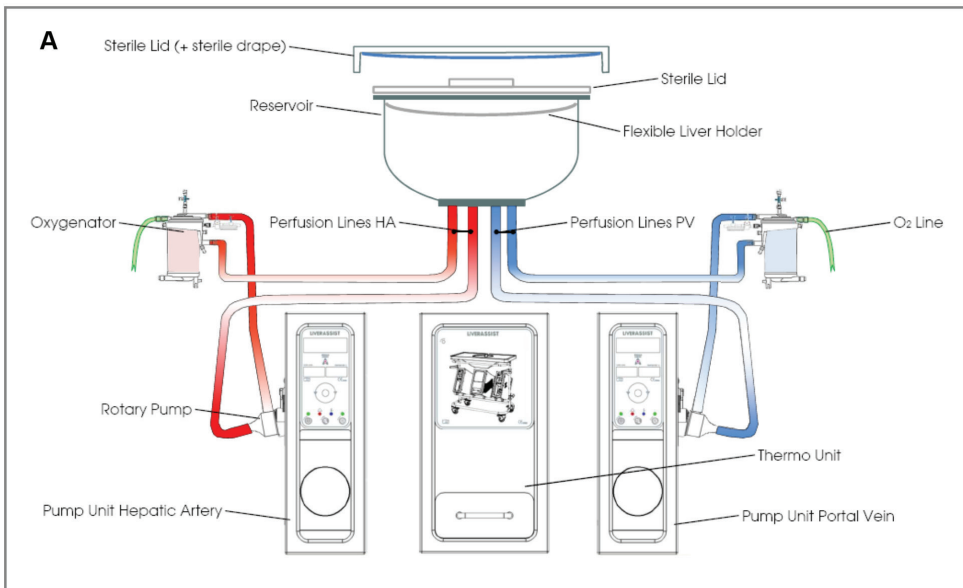
For normothermic perfusion of the donor livers we used a CE marked (European Union certification of safety, health and environmental requirements) device that enables dual perfusion via both

the hepatic artery and the portal vein in a closed circuit (Liver Assist®, Organ Assist, Groningen, The Netherlands; **Figure 1**). Two rotary pumps provided a pulsatile flow to the hepatic artery and a continuous flow to the portal vein. Two hollow fiber membrane oxygenators provided oxygenation of the perfusion solution, as well as removal of CO<sub>2</sub>. The system was both pressure and temperature controlled, which allowed auto regulation of the blood flow through the liver, with constant pressure at variable flow rates. Flow, pressure and temperature were displayed on the device in real-time. Pressure was limited to a mean of 50 mmHg in the hepatic artery and 11 mmHg in the portal vein. The temperature was set to 37°C and a new sterile disposable set of tubing, reservoir and oxygenators was used for each liver.

**Table 1.** Characteristics of the discarded human donor livers used for normothermic machine perfusion.

Donor characteristics	Liver no.			
	1	2	3	4
DCD / DBD	DCD	DCD	DCD	DCD
Age (years)	66	44	38	64
Sex	male	female	female	male
Height (m)	1.85	1.65	1.70	1.80
Weight (kg)	105	92	65	75
Cause of brain injury	Subdural hematoma	Subarachnoid hemorrhage	Drowning	Traumatic brain injury
Weight of the liver (kg)	2.06	2.37	2.06	1.75
Reason for rejection for transplantation	DCD, age 60+ and steatosis	35 minutes of O <sub>2</sub> -saturation <30% prior to death	Tumor detected, malignancy could not be excluded	DCD, age 60+ and alcohol abuse in medical history.
Time between withdrawal of life support and cardiac death	17 min	40 min	11 min	24 min
Time between cardiac death and cold perfusion	17 min	16 min	12 min	17 min
Cold ischemic preservation	4 h 46 min	6 h 29 min	9 h 28 min	6 h 56 min
Preservation solution during initial cold preservation	HTK	HTK	HTK	UW
Normothermic perfusion time	6 h	6 h	6 h	6 h
Histological grade of steatosis*	Grade 1	Grade 0	Grade 0	Grade 0

\* The grade of steatosis was based on the grading system established by a leading group of expert liver pathologists (Kleiner DE, Brunt EM, Van Natta M, et al. *Design and validation of a histological scoring system for non-alcoholic fatty liver disease. Hepatology. 2005; 41: 1313-1321*). Grade I translates to 5-33% of macrovesicular steatosis. Abbreviations used: DCD, donation after cardiac death; DBD, donation after brain death; HTK, histidine-tryptophan-ketoglutarate; UW, university of Wisconsin.



**Figure 1.** A schematic drawing **(A)** and a photo **(B)** of the perfusion machine used for normothermic perfusion of human donor livers (Liver Assist®, Organ Assist, Groningen, The Netherlands).

### Composition of Perfusion Fluid

We aimed for a perfusion fluid containing all nutrients, oxygen and protective substances required by a metabolically active liver. Detailed information on the various components and



the biochemical characteristics of the perfusion fluid are provided in **Table 2** and **3**. The base of our perfusion fluid was human packed red blood cells and fresh frozen plasma; blood group and Rhesus factor identical to the donor liver. These blood products were obtained from the local blood bank and derived from third party blood donors. Because of the relatively low hematocrit of the perfusion solution ( $0.23 \pm 0.01$  at the start of perfusion) the pO<sub>2</sub> was targeted at supernormal values (60 kPa) in order to provide sufficient oxygen to the liver. Heparin was added for anticoagulation, and vitamins, glucose, amino acids and trace elements were added to provide sufficient nutrients for the liver. Broad-spectrum antibiotics cefazolin and metronidazole were added to prevent bacterial growth and graft infection under normothermic conditions. To prevent the development of interstitial edema or intracellular contraction, the oncotic and osmotic pressure of the perfusion fluid was adjusted by adding sterile H<sub>2</sub>O, saline and human albumin. The targeted osmolality of the perfusion fluid was 302 mosmol/L. Sodium bicarbonate was added for buffering capacity.

**Table 2.** Composition of the perfusion fluid used for normothermic machine preservation of human donor livers

Component	Quantity
Red blood cell concentrate (hematocrit 60%)	750 mL
Fresh frozen plasma	900 mL
Human albumin 200g/L (Albuman®, Sanquin)	100 mL
Modified parenteral nutrition (Clinimix® N17G35E, Baxter international Inc.)	7.35 mL
Multivitamins for infusion (Cernevite®, Baxter international Inc.)	7 µL
Concentrated trace elements for infusion (Nutritrace®, B. Braun Melsungen AG)	7.35 mL
Metronidazol for i.v. administration (5 mg/ml) (Flagyl®, Sanofi-Aventis)	40 mL
Cefazolin 1000 mg flask 5 mL powder for i.v. administration (Servazolin®, Sandoz )	2 mL
Fast-acting insulin (100 IU/ml) (Actrapid®, Novo Nordisk)	20 mL
Calcium glubionate, intravenous solution 10%, 137.5 mg/mL (Sandoz®)	40 mL
Sterile H <sub>2</sub> O	51.3 mL
NaCl 0.9% solution	160 mL
Sodium bicarbonate 8.4% solution	31 mL
Heparin 5000 IE/mL for i.v. administration	4 mL
<b>Total volume</b>	<b>2120 mL</b>

**Table 3.** Biochemical characteristics of the perfusion fluid before connecting the liver, after 30 min and 6 hours of normothermic perfusion.

Chemical variable*	Before start perfusion	At 30 min	At 6 h	Reference values in blood
pH	7.59 ± 0.11	7.53 ± 0.09	7.36 ± 0.01	7.35 - 7.45
pCO <sub>2</sub> (kPa)	3.5 ± 0.4	1.9 ± 0.8	5.0 ± 1.0	4.6 - 6.0
pO <sub>2</sub> (kPa)	74.8 ± 2.4	69.7 ± 3.6	53.1 ± 8.0	9.5 - 13.5
sO <sub>2</sub> (%)	100 ± 0.1	100 ± 0.2	100 ± 0.2	96 - 99
HCO <sub>3</sub> <sup>-</sup> (mmol/L)	28 ± 10	11 ± 3	21 ± 3	21 - 25
Base excess (mmol/L)	4.9 ± 10.5	-12.6 ± 4.4	-5.1 ± 2.8	-3.0 - 3.0
Na <sup>+</sup> (mmol/L)	150 ± 7	139 ± 5	144 ± 4	135 - 145
K <sup>+</sup> (mmol/L)	5.3 ± 0.6	4.8 ± 0.9	6.5 ± 1.0	3.5 - 5.0
free Ca <sup>2+</sup> (mmol/L)	0.62 ± 0.03	1.47 ± 0.15	1.32 ± 0.14	1.15 - 1.29
Glucose (mmol/L)	13.7 ± 0.6	27.8 ± 6.0	11.3 ± 5.5	4 - 9
Lactate (mmol/L)	6.3 ± 0.5	10.0 ± 2.3	2.3 ± 1.2	0.5 - 2.2
Hemoglobin (mmol/L)	4.7 ± 0.1	3.8 ± 0.1	3.9 ± 0.2	8.7 - 10.6
Hematocrit	0.23 ± 0.01	0.19 ± 0.01	0.20 ± 0.01	0.42 - 0.52

\* To convert values for glucose to mg/dL, multiply by 18.02. To convert values for lactate to mg/dL, multiply by 9.01. To convert values for hemoglobin to g/dL, multiply by 1.650. Data are expressed as mean ± SEM.

### Procurement and Preparation of Donor Livers

All liver procurement procedures were performed by one of the regional multi-organ retrieval teams, in the Netherlands, using a standard technique of *in situ* cooling and flush-out with ice cold preservation fluid (University of Wisconsin (UW) or histidine-tryptophan-ketoglutarate (HTK) solution). Care was taken to leave a segment of the suprarenal aorta attached. Livers were packed and stored in standard sterile donor organ bags and a box with crushed ice, and subsequently transported to our center. Immediately upon arrival of the donor liver in the operating room, the back table procedure was performed by an experienced transplant surgeon. Arteries and the portal vein were dissected free and the arterial cannula was inserted and secured in the proximal end of the suprarenal aorta segment. The distal end of the aorta was closed below the origin of the celiac trunc, using a prolene 4-0 suture. A second cannula was inserted and secured in the distal end of the portal vein. The cannulas for the hepatic artery and the portal vein are part of the sterile disposables provided by Organ Assist. The cystic duct was ligated to prevent bile flow from the gallbladder into the common bile duct. The gallbladder was not removed to avoid continuous bleeding from the gallbladder fossa in a fully heparinized system. A Meredith silicon catheter no. 8 was inserted and secured in the distal common bile duct. After preparation on the back table, the liver was weighed. Immediately before connecting

the liver to the perfusion machine, the liver was rapidly flushed with 1L cold NaCl 0.9% solution (only when UW solution was used for preservation), followed by 1L warm NaCl 0.9% solution.

### **Liver Function Assessment**

During machine perfusion, samples were taken from the perfusion fluid every 30 min and analyzed immediately for blood gas parameters ( $pO_2$ ,  $pCO_2$ ,  $sO_2$ ,  $HCO_3^-$  and pH) and for biochemical parameters (glucose, calcium, lactate, potassium, sodium) by an ABL800 FLEX analyzer (Radiometer, Brønshøj, Denmark). In addition, plasma from the perfusion fluid was collected (after 5 min centrifugation 2700 RPM at 4°C), frozen and stored at -80°C for determination of alkaline phosphatase, gamma-glutamyl transferase (gamma-GT), alanine aminotransferase (ALT), urea and total bilirubin, using standard biochemical methods. Bile production was measured at 30 min intervals by weighing the Eppendorf tubes in which bile was collected from the biliary drain. Biliary epithelial cell function was assessed by measuring biliary bicarbonate concentration. For this purpose, bile samples were collected under mineral oil and analyzed immediately using an ABL800 FLEX analyzer (Radiometer). Biliary concentration of gamma-GT and lactate dehydrogenase (LDH) were measured as biomarkers of biliary epithelial cell injury (13), and biliary bilirubin concentration was measured as biomarker of hepatocellular secretory function, using standard biochemical methods.

### **Histological Evaluation**

Biopsies were obtained from the liver parenchyma as well as the extrahepatic bile ducts before and after machine perfusion and stored in formalin for histological evaluation. Paraffin-embedded slides of liver biopsies were prepared for hematoxylin and eosin (H&E) staining and complementary liver staining with periodic acid-Schiff after diastase digestion, Masson's trichrome, iron and reticulin. Additional slides were prepared for immunohistochemical detection of activated caspase-3 (Asp175, Cell Signaling #9661; 1:100 dilution), a marker for apoptosis. Paraffin-embedded slides of extrahepatic bile ducts were prepared for H&E staining and complementary staining with periodic acid-Schiff after diastase digestion. Slides of the extrahepatic bile ducts were graded according to a systematic scoring system of bile duct injury as first described by Hansen *et al* (14). All liver and bile duct slides were examined by an experienced liver pathologist (ASH Gouw) using light microscopy.

## **RESULTS**

### **Perfusion Characteristics**

Immediately after arrival in our center, donor livers were prepared on the back table and connected to the normothermic perfusion system, resulting in a mean cold storage period of  $415 \pm 58$  min. Both the arterial and portal flow increased during the first 30 min of normothermic perfusion and remained stable thereafter, with a mean arterial flow of  $283 \pm 29$  mL/min and a mean

portal flow of  $686 \pm 25$  mL/min at 6 h (**Figure 2A**). The perfusion machine provided adequate oxygenation of the perfusion fluid and extraction of carbon dioxide (**Figure 2B**). Macroscopically all livers appeared well perfused (**Figure 3**).

### Assessment of Hepatic Injury and Function

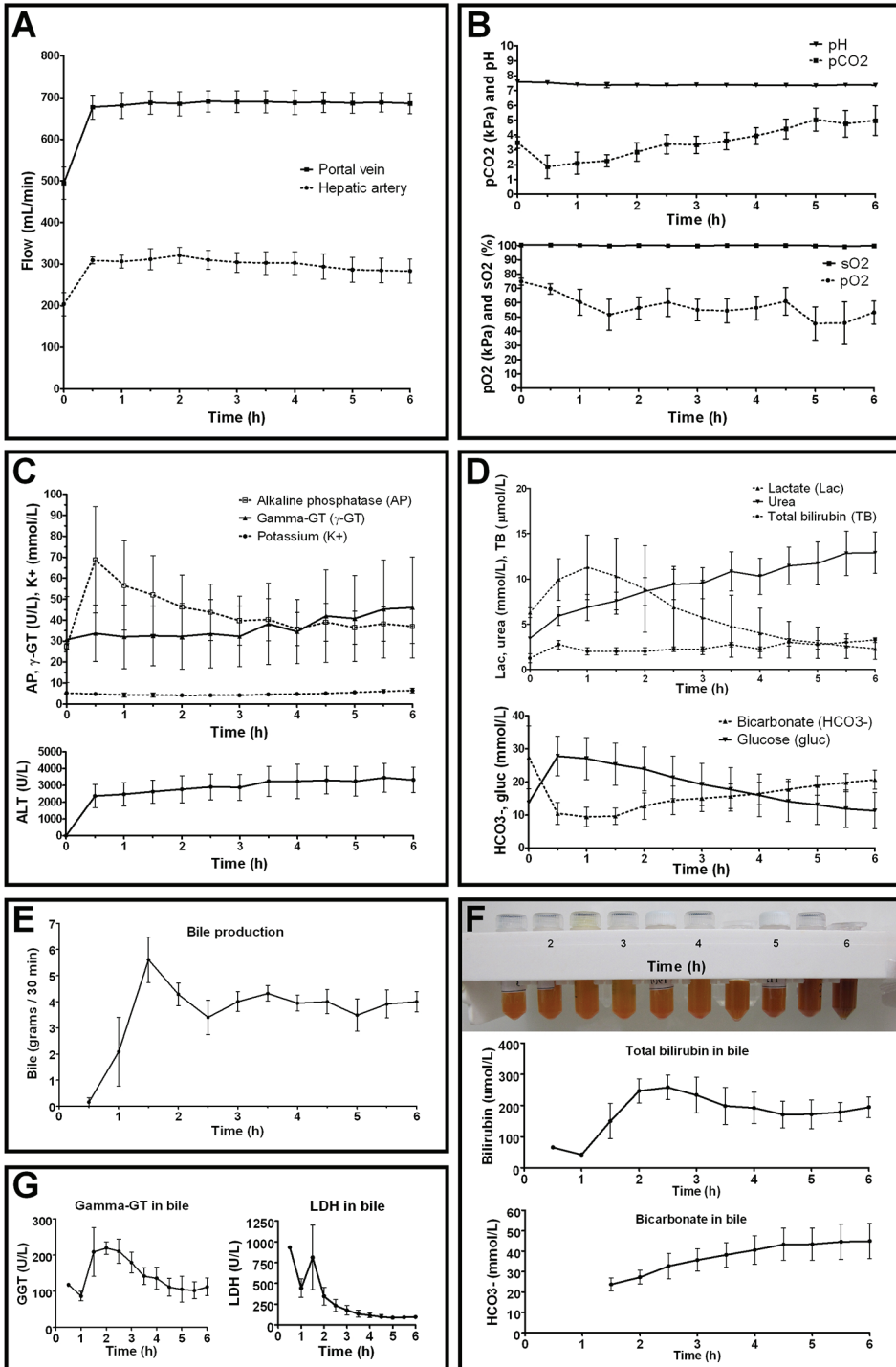
Changes in the concentration of biochemical markers in the perfusion fluid reflected minimal hepatic injury and improving function (**Figure 2C and D**). After a temporary rise in ALT directly after the start of perfusion, ALT concentrations remained stable. Other markers of cell injury also remained stable (gamma-GT and potassium) or decreased (alkaline phosphatase; **Figure 2C**). Lactate concentrations initially increased but subsequently decreased to normal values, reflecting active metabolism by the liver (mean lactate  $10.0 \pm 2.3$  mmol/L at 30 min to  $2.3 \pm 1.2$  mmol/L at 6 h; **Figure 2D**). Similarly, glucose levels decreased to near-normal values (mean  $11 \pm 5$  mmol/L at 6 h). Bicarbonate levels increased during perfusion to physiological levels (mean  $20.7 \pm 2.8$  mmol/L at 6 h). Overall, the pH at the start of perfusion was slightly alkalotic, but in all procedures it returned to normal values within the first hour (mean pH  $7.40 \pm 0.06$  at 1 h) (**Figure 2B**). Urea, produced by the liver, increased from  $5.9 \pm 1.0$  mmol/L at 30 min to  $12.9 \pm 2.3$  mmol/L at 6 h (**Figure 2D**).

Bile production was observed throughout the entire perfusion period (**Figure 2E**). The mean rate of bile production after the first hour was  $8.16 \pm 0.65$  g/h. The quality of bile improved during perfusion as indicated by a gradual change in color to a darker shade and increasing concentrations of biliary bilirubin and bicarbonate (**Figure 2F**). Biliary gamma-GT and LDH concentrations decreased after an initial peak at 90 min of perfusion (**Figure 2G**).

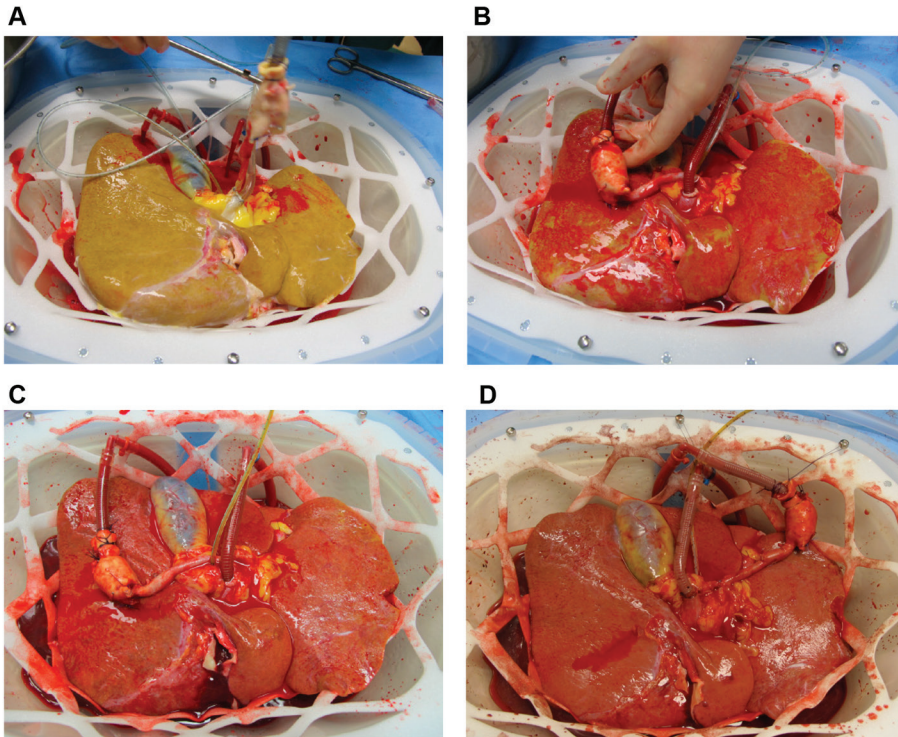
### Liver and Extrahepatic Bile Duct Histology

Histological examination of H&E stained liver biopsies showed no major differences between biopsies taken before and after 6 hours of perfusion (**Figure 4**). In general, hepatocytes appeared viable without additional ischemic changes and no signs of biliary injury or sinusoidal damage were present in the liver biopsies after machine perfusion. Additional liver staining with Masson's trichrome, reticulin, iron, periodic acid-Schiff after diastase digestion and immunohistochemistry for caspase-3 confirmed normal liver morphology and provided no evidence of additional apoptotic cell death after machine perfusion (data not shown).

Histological examination of biopsies from the distal end of the extrahepatic bile duct taken before machine preservation revealed partial loss of the biliary epithelial cell layer similar to what has been described by Hansen *et al.* (14) in human liver transplantation (**Figure 5**). Further histological assessment of bile duct wall injury revealed no evidence of major intramural bleeding and no microthrombi in the vasculature. The amount of arteriolonecrosis remained stable in graft #3 and #4, but increased with one degree in grafts #1 and #2. After perfusion, normal morphology of the bile duct wall stroma with presence of cell nuclei was seen in graft #3, but a decrease in the number of cell nuclei in the stroma was noted in the other grafts.

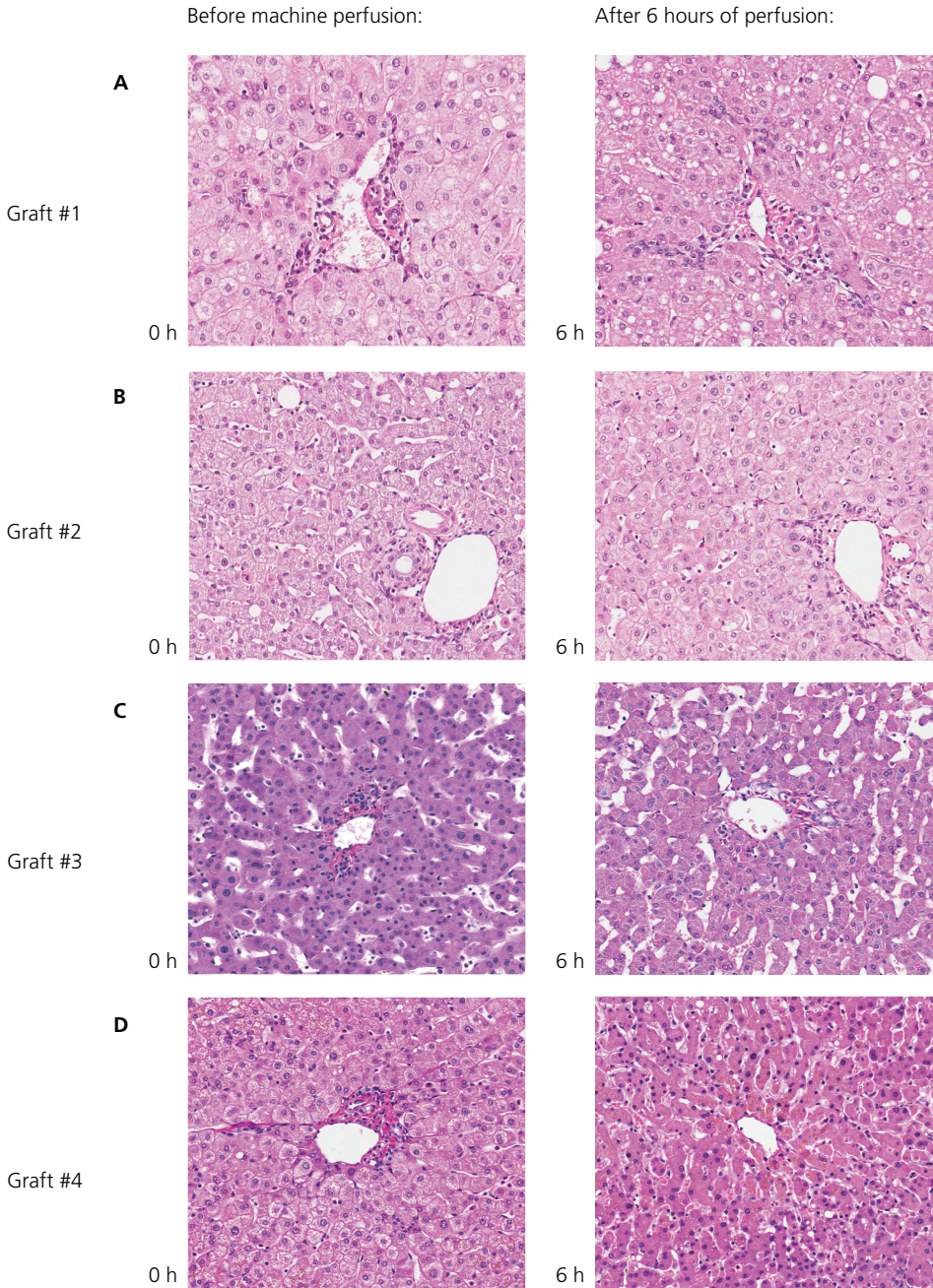


**Figure 2.** Functional parameters of the perfusion machine and markers of liver viability and injury during 6 hours of normothermic machine perfusion (n=4). **Panel A and B:** Perfusion characteristics and gas exchange parameters. **Panel C and D:** Concentrations of hepatobiliary injury and function markers in the perfusion fluid. **Panel E:** Bile production during perfusion (n=3). **Panel F:** Eppendorf tubes containing bile from graft #1; demonstrating a gradual change to a darker shade over time, in parallel with increasing biliary concentration of bilirubin and bicarbonate. **Panel G:** Evolution of biliary concentrations of gamma-GT and LDH as markers of biliary injury. Data are expressed as mean  $\pm$  SEM.



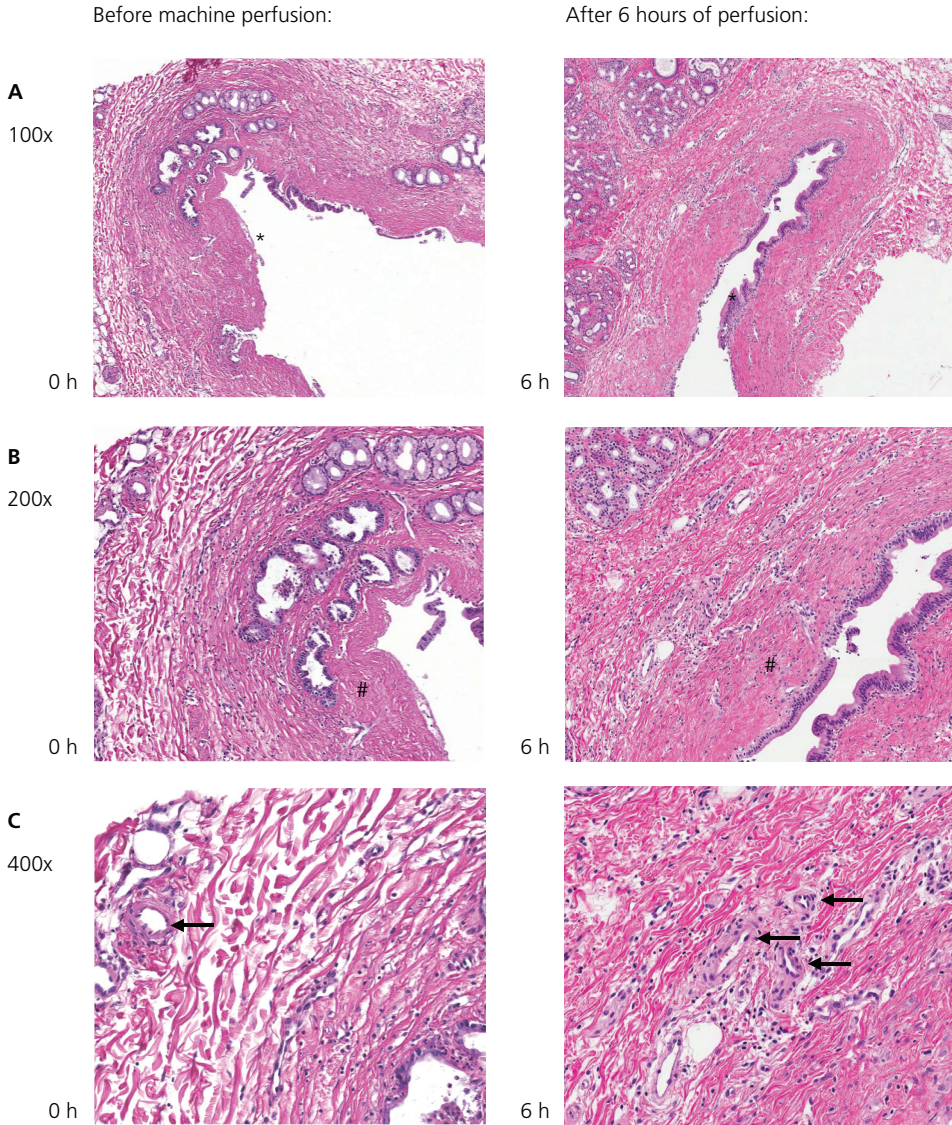
**Figure 3.** Photos of liver #1 before and during normothermic machine perfusion. **Panel A:** Just before connecting the liver to the perfusion machine. **Panel B:** One minute after connecting the liver. **Panel C:** 20 minutes after connecting the liver. **Panel D:** After 6 hours of normothermic machine perfusion. During operation the organ chamber is covered by a transparent cover to maintain a moist environment for the liver (not shown in these pictures).





**Figure 4.** Hematoxylin and eosin staining of liver biopsies before (A-D 0 h) and after (A-D 6 h) 6 hours of normothermic machine perfusion, showing well preserved microscopic architecture in all four perfused livers.





**Figure 5.** Hematoxylin and eosin stainings of biopsies from the distal end of the extrahepatic bile duct (graft #3), taken before and after 6 hours of normothermic machine perfusion. **Panel A** shows an overview at 100x magnification, the lumen of the bile duct is marked by the asterisk. Similar to what has been described in over 80% of human livers prior to clinical transplantation (14), biopsies taken before machine preservation revealed partial loss of the biliary epithelial cell layer. The amount of biliary epithelial cell loss did not increase during 6 hours of machine perfusion. Further histological assessment at higher magnification (**panel B and C**) revealed no evidence of major intramural bleeding and no microthrombi in the vasculature. Well-preserved bile duct wall stroma is marked by # in panel B. Arrows in panel C indicate arteries/arterioles of the peribiliary plexus with normal morphology.

## DISCUSSION

In this study we demonstrated feasibility of normothermic machine perfusion of four discarded human donor livers. There were no technical failures of the perfusion machine and all livers were well perfused and oxygenated. The livers, although discarded for varying reasons, functioned well *ex vivo*. Macroscopically well-perfused livers, continuous bile production (possibly the most important outcome parameter for a well-functioning liver (9)) and normalization of various biochemical parameters in the perfusion fluid were noted over time in all procedures. Histological examinations confirmed adequate preservation of liver morphology.

This is the first description of successful normothermic machine perfusion of human livers, ever since the first unsuccessful attempts of hypothermic perfusion of human livers by Starzl *et al.* in 1967, after which the clinical use and development of human liver perfusion devices stagnated (15). Only recently, renewed clinical application of machine preservation has been reported by Guarrera *et al.* (4). The device used by these investigators, however, was based on hypothermic perfusion (at 4°C) without oxygenation of the perfusion fluid. In contrast to oxygenated, normothermic machine perfusion, hypothermic perfusion does not allow an adequate functional assessment of liver viability prior to transplantation. Especially in an era of donor organ shortage, normothermic machine preservation has great potential as a tool to increase the number of donor livers by enabling pretransplant assessment of ECD livers that would otherwise not have been accepted for transplantation because of the presumed too high risk of primary non-function.

Based on a porcine model of normothermic perfusion, bile output has been suggested as the most significant parameter of liver viability (9). We observed increasing bile output in all four livers tested during 6 h of normothermic machine preservation. Assessment of bile composition showed a gradual increase in biliary bilirubin and bicarbonate concentration, reflecting recovery of secretory function of hepatocytes and biliary epithelial cells, respectively. In parallel with this, biomarkers of biliary epithelial cell injury such as biliary concentrations of gamma-GGT and LDH decreased, indicating that there was no ongoing biliary epithelial cell injury during the 6 hours of perfusion.

In a recent clinical study in 93 liver transplants, Hansen *et al.* (14) have observed a >50% loss of biliary epithelium in 82.8% of extrahepatic bile duct biopsies taken before transplantation. Therefore, it is not surprising that we observed similar changes in our biopsies before machine perfusion. Although some signs of bile duct wall injury as described by Hansen *et al.*, such as intramural bleeding and microthrombi in the vasculature, could not be detected, other signs such as arteriolonecrosis and loss of cell nuclei in the bile duct wall stroma were observed after perfusion. Collectively, these histological findings indicate that normothermic machine perfusion alone is not sufficient to completely avoid ischemia/reperfusion injury of the extrahepatic bile ducts. It needs to be awaited whether modifications of the perfusion fluid, for example by adding cytoprotective hydrophilic bile salts, will result in a reduction of the degree of biliary ischemia/

reperfusion injury and a subsequent lower rate of biliary complications after transplantation. Clearly this is an area that still requires intensive further research.

Whether *ex vivo* bile output and assessment of other viability parameters can be used as reliable parameters to discriminate viable from nonviable human donor livers will also require confirmation in a larger cohort. This work is in progress in our center and the ultimate goal will be to perform a clinical trial. One option would be to apply normothermic machine perfusion in ECD livers that have been rejected for transplantation and will otherwise be discarded. This is a strategy followed by Guarrera *et al.* in a clinical trial on hypothermic liver machine perfusion (4). Alternatively, one could think of a randomized clinical trial of ECD livers, such as livers obtained from DCD donors, using biliary strictures as the primary end-point.

Transplantation of ECD livers, such as steatotic or old livers, results in an increased risk of primary non-function or delayed graft function (1). In the case of DCD livers, the most important complication is the development of cholangiopathies (2). Although we have been able to assess overall viability of the perfused livers by measurement of bile production, serial analysis of biochemical markers in the perfusion fluid and bile, as well as histological examination, accurate functional assessment of biliary epithelium viability is more difficult. We have used biliary secretion of bicarbonate as a biomarker of biliary epithelial function. Biliary epithelial cells contribute significantly to bile volume and flow by active secretion of bicarbonate and we have observed a recovery of biliary bicarbonate secretion during machine perfusion. The amount of bicarbonate secretion in the bile, however, is the result of all biliary epithelial cells present in the intra- and extrahepatic bile ducts and it does not necessarily reflect function of the epithelium of the larger bile ducts, which are most prone for the development of stricture after transplantation. More research in this area is clearly needed (16).

In conclusion, this study shows that normothermic machine perfusion of human donor livers is technically feasible. Normothermic perfusion of ECD livers allows assessment of graft viability prior to transplantation and opens new avenues for donor organ selection, therapeutic interventions and preconditioning. This may not only improve organ quality and function, but will also lead to a considerable expansion of the number of organs available for transplantation.

## ACKNOWLEDGEMENTS

We are grateful to Arjan van der Plaats and Martin Kuizenga (Organ Assist, Groningen, Netherlands) for their technical support and assistance during the perfusion experiments. Furthermore, we are appreciative to all the Dutch transplantation coordinators, Ernst Buijter and Cees Brugman in particular, for identifying the potential discarded livers and obtaining informed consent.

**REFERENCES**

- (1) Merion RM, Goodrich NP, Feng S. How can we define expanded criteria for liver donors? *J Hepatol* 2006;45:484-488.
- (2) Op den Dries S, Sutton ME, Lisman T, Porte RJ. Protection of bile ducts in liver transplantation: looking beyond ischemia. *Transplantation* 2011;92:373-379.
- (3) Monbaliu D, Liu Q, Libbrecht L, de Vos R, Vekemans K, Debbaut C, et al. Preserving morphology and evaluating quality of liver grafts by hypothermic machine perfusion, a proof of concept study using discarded human livers. *Liver Transpl* 2012;18:1495-1507.
- (4) Guarrera JV, Henry SD, Samstein B, Odeh-Ramadan R, Kinkhabwala M, Goldstein MJ, et al. Hypothermic machine preservation in human liver transplantation: the first clinical series. *Am J Transplant* 2010;10:372-381.
- (5) Fondevila C, Hessheimer AJ, Maathuis MH, Muñoz J, Taurá P, Calatayud D, et al. Hypothermic oxygenated machine perfusion in porcine donation after circulatory determination of death liver transplant. *Transplantation* 2012;94:22-29.
- (6) Hessheimer AJ, Fondevila C, García-Valdecasas JC. Extracorporeal machine liver perfusion: are we warming up? *Curr Opin Organ Transplant* 2012;17:143-147.
- (7) Monbaliu D, Brassil J. Machine perfusion of the liver: past, present and future. *Curr Opin Organ Transplant* 2010;15:160-166.
- (8) Vogel T, Brockmann JG, Friend PJ. Ex-vivo normothermic liver perfusion: an update. *Curr Opin Organ Transplant* 2010;15:167-172.
- (9) Brockmann J, Reddy S, Coussios C, Pigott D, Guirriero D, Hughes D, et al. Normothermic perfusion: a new paradigm for organ preservation. *Ann Surg* 2009;250:1-6.
- (10) St Peter SD, Imber CJ, Lopez I, Hughes D, Friend PJ. Extended preservation of non-heart-beating donor livers with normothermic machine perfusion. *Br J Surg* 2002;89:609-616.
- (11) Xu H, Berendsen T, Kim K, Soto-Gutiérrez A, Bertheim F, Yarmush ML, Hertl M. Excorporeal normothermic machine perfusion resuscitates pig DCD livers with extended warm ischemia. *J Surg Res* 2012;173:83-88.
- (12) Schön MR, Kollmar O, Wolf S, Schrem H, Matthes M, Akkoc N, et al. Liver transplantation after organ preservation with normothermic extracorporeal perfusion. *Ann Surg* 2001;223:114-123.
- (13) Vajdová K, Smreková R, Kukan M, Lutterová M, Wsóllová L. Bile analysis as a tool for assessing integrity of biliary epithelial cells after cold ischemia-reperfusion of rat livers. *Cryobiology* 2000;41:145-152.
- (14) Hansen T, Holleman D, Pitton MB, Heise M, Hoppe-Lotichius M, Schuchmann M, Kirkpatrick CJ, Otto G. Histological examination and evaluation of donor bile ducts received during orthotopic liver transplantation – a morphological clue to ischemic-type biliary lesion? *Virchows Arch* 2012;461:41-48.
- (15) Starzl TE, Marchioro TL, Porter KA, Brettschneider L. Homotransplantation of the liver. *Transplantation* 1967;5:790-803.
- (16) Dutkowski P, de Rougemont O, Clavien PA. Machine perfusion for ‘marginal’ liver grafts. *Am J Transplant* 2008;8:917-924.





# CHAPTER 11

## **Criteria for Viability Assessment of Discarded Human Donor Livers during *Ex-Vivo* Normothermic Machine Perfusion**

Op den Dries S, Sutton ME, Karimian N, de Boer MT,  
Wiersema-Buist J, Gouw ASH, Leuvenink HGD, Lisman T, Porte RJ.

*Submitted for publication.*

**ABSTRACT**

Although normothermic machine perfusion of donor livers may allow assessment of graft viability prior to transplantation, there is currently no data on what would be a good parameter of graft viability. To determine whether bile production is a suitable biomarker that can be used to discriminate viable from non-viable livers we have studied functional performance as well as biochemical and histological evidence of hepatobiliary injury during *ex vivo* normothermic machine perfusion of human donor livers. After a median duration of cold storage of 6.5 hours, twelve extended criteria human livers that were declined for transplantation were *ex vivo* perfused for 6 h at 37°C with an oxygenated solution based on red blood cells and plasma, using pressure controlled pulsatile perfusion of the hepatic artery and continuous portal perfusion. During perfusion, two patterns of bile flow could be identified: 1) steadily increasing bile production, resulting in a cumulative output of  $\geq 30$  g after 6 h (high bile output group), and 2) a cumulative bile production  $< 20$  g in 6h (low bile output group). Concentrations of transaminases and potassium in the perfusion fluid were significantly higher in the low bile output group, compared to the high bile output group. Biliary concentrations of bilirubin and bicarbonate were 4-times and 2-times higher in the high bile output group. Livers in the low bile output group displayed more signs of hepatic necrosis and venous congestion, compared to the high bile output group.

**In conclusion**, bile production is an easy assessable biomarker of hepatic viability during *ex vivo* machine perfusion of human donor livers. It could potentially be used to identify extended criteria livers that are suitable for transplantation.

## INTRODUCTION

Donor liver shortage remains a limiting factor in liver transplant programs in most parts of the world. In an attempt to reduce the discrepancy between donor liver availability and demand, criteria for organ acceptance have gradually widened with increasing acceptance of livers that carry a higher risk of early graft failure or transmission of an infectious or malignant disease (so called extended criteria donor (ECD) livers). The types of ECD livers most frequently considered for transplantation, despite a higher risk of early dysfunction, are livers with mild-moderate steatosis, livers from older donors or donor with a high body mass index, and livers from donation after cardiac death (DCD) (1-3). Although livers from ECD donors are increasingly considered for transplantation, many of them are still declined. A recent study in the US has shown that the proportion of donor livers not used for transplantation is increasing since 2004 (4). The proportion of nonuse attributable to DCD increased from 9% in 2004 to 28% in 2010, probably because in many cases the risk of early graft failure after transplantation is considered to be too high (4).

The decision to either accept or decline a potential donor liver for transplantation is currently based on the interpretation of the physician before or during procurement and is primarily based on parameters such as donor past medical history, last known laboratory values, findings during liver procurement, and other procurement variables such as expected ischemia times. Once a donor liver is retrieved and stored in an organ box for transportation functional assessment is no longer possible until after transplantation. The uncertainty about how much additional damage a liver will sustain during the hours of cold storage poses an important hurdle for accepting many ECD livers.

During the past decade, machine perfusion of donor livers has received increasing research attention as a tool to improve organ preservation and improve outcome after transplantation (5-9). Several experimental studies have shown superiority of machine perfusion compared to static cold storage with respect to reduction of ischemia/reperfusion (IR) injury (10-12). Apart from providing better graft protection against IR injury, machine perfusion provides the possibility of functional assessment of a liver graft short before implantation in a recipient. Although machine perfusion can be performed at various temperatures, only normothermic oxygenated machine perfusion (NMP) may allow a full functional assessment of an organ prior to transplantation. During NMP the liver is offered physiological amounts of oxygen and nutrients supporting a full functional metabolic activity (13). The possibility of functional assessment of an ECD liver after static cold storage and transportation would be of great importance in the judgment of livers that would otherwise be declined for transplantation based on the current criteria.

Despite the growing amount of literature on the role of machine perfusion as an alternative and better preservation method compared to static cold storage, there is no data on what would be



reliable parameters for functional assessment of human donor livers during NMP. Based on a porcine model of normothermic liver perfusion, Imber *et al* have suggested that bile production is directly attributed to liver viability and could therefore be used as a predictive marker of liver function (11). In addition, bile production has long been recognized as an important clinical parameter to predict early graft dysfunction (including primary non-function and delayed graft function) after liver transplantation (14). We, therefore, hypothesized that bile production during NMP of human donor livers is a suitable and easy to assess biomarker of hepatic viability that can be used to discriminate a potentially transplantable from a non-transplantable graft. To test this hypothesis we have studied functional performance as well as biochemical and histological signs of hepatobiliary injury during *ex vivo* NMP of human donor livers that were declined for transplantation. Secondary aim of this study was to determine the minimal duration of NMP needed to discriminate viable and potentially transplantable livers from non-viable livers.

## MATERIALS AND METHODS

### Liver Donors

Between May 2012 and May 2013 twelve human livers that were declined for transplantation by all three liver transplant centers in The Netherlands were included in this study. Of these, ten were obtained from a DCD donor and two were obtained from donors after brain death (DBD). Livers were retrieved using a standard surgical technique of *in situ* cooling and flush-out with ice cold preservation fluid (University of Wisconsin [UW] or histidine–tryptophan–ketoglutarate [HTK] solution). Livers were subsequently packed and stored on ice and transported to our center. In all cases, permission to use a donor liver for this study was obtained from the relatives. The study protocol was approved by the medical ethical committee of the University Medical Center Groningen and the *Nederlandse Transplantatie Stichting*, the competent authority for organ donation in the Netherlands.

### Normothermic Oxygenated Machine Perfusion

Upon arrival at center, cold preserved livers were prepared on the back table for normothermic oxygenated machine perfusion as described previously (13). NMP was initiated using a CE marked (European Union certification of safety, health and environmental requirements) device that enables dual perfusion via both the hepatic artery and the portal vein in a closed circuit (Liver Assist® Organ Assist, Groningen, Netherlands). Livers were perfused for 6h with a perfusion solution based on heparinized human plasma and red blood cells fortified with nutrients, trace elements and antibiotics as described previously (13). Two rotary pumps provided pulsatile flow to the hepatic artery and a continuous flow to the portal vein. Two hollow fiber membrane oxygenators provided oxygenation of the perfusion solution, as well as removal of CO<sub>2</sub>. The system was temperature and pressure controlled, allowing auto-regulation of the blood flow

through the liver. Pressure was limited to a mean of 60 mmHg in the hepatic artery and 11 mmHg in the portal vein. The temperature was set to 37°C and a new sterile disposable set of tubing, reservoir and oxygenators was used for each liver. Before connecting the liver to the device, the perfusion fluid was primed with the addition of sodium bicarbonate 8.4% solution to obtain a stable physiological pH. A summary of the composition of perfusion fluid prior to initiation of NMP is provided in **Table 1**.

### **Assessment of Hepatobiliary Function and Injury**

Bile samples were collected from a catheter in the donor common bile duct and bile production was measured gravimetrically at 30 min intervals. Bile production was expressed as g/30 min. Concentration of bilirubin in bile was determined as a marker of hepatic secretory function, using a standard biochemical method. Biliary concentration of bicarbonate and glucose were determined as markers of biliary epithelial cell (cholangiocyte) function. For this purpose, bile samples were collected under mineral oil and analyzed immediately using an ABL800 FLEX analyzer (Radiometer, Brønshøj, Denmark).

During NMP, samples were taken from the perfusion fluid at 30 min intervals and analyzed immediately for blood gas parameters ( $pO_2$ ,  $pCO_2$ ,  $sO_2$ ,  $HCO_3^-$  and pH) and for biochemical parameters (glucose, calcium, lactate, potassium, sodium, and hemoglobin) by an ABL800 FLEX analyzer (Radiometer, Brønshøj, Denmark).

In addition, plasma from the perfusion fluid was collected (after 5 min centrifugation at 2700 rpm at 4°C), frozen and stored at -80°C for determination of alkaline phosphatase (ALP), gamma-glutamyl transferase (gamma-GT), alanine aminotransferase (ALT), urea, lactate dehydrogenase (LDH), total bilirubin, and albumin, using standard biochemical methods.

### **Histological Evaluation**

Biopsies were obtained from the liver grafts before and after 6h of machine perfusion and stored in formalin for histological evaluation. Paraffin-embedded slides of liver biopsies were prepared for hematoxylin and eosine (H&E) staining, and assessed for the degree of steatosis, parenchymal necrosis, hepatic congestion, and biliary injury. All liver and slides were examined in a blinded fashion by an experienced liver pathologist (ASH Gouw) using light microscopy.

### **Statistical Analysis**

Continuous variables are presented as medians and interquartile range (IQR). Categorical variables are presented as number and percentage. Continuous variables were compared between groups using the Mann-Whitney U test. Categorical variables were compared with the Pearson chi-square. A p-value <0.05 was considered to indicate statistical significance. All statistical analyses were performed using SPSS software version 16.0 for Windows (SPSS, Inc., Chicago, IL).

**Table 1.** Biochemical composition of perfusion fluid used from normothermic machine perfusion of donor livers

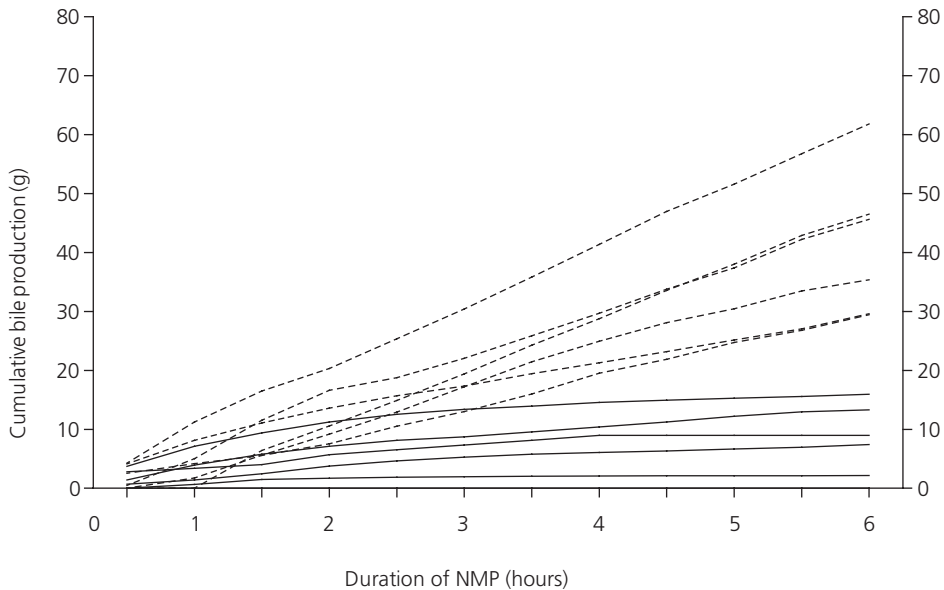
Variable	Median	IQR	Reference values in blood
pH	7.40	7.34 – 7.45	7.35 – 7.45
pCO <sub>2</sub> (kPa)	4.1	3.5 – 4.6	4.6 – 6.0
pO <sub>2</sub> (kPa)	71	65 – 75	9.5 – 13.5
sO <sub>2</sub> (%)	100	99 – 100	96 – 99
HCO <sub>3</sub> <sup>-</sup> (mmol/L)	19	17 – 21	21 – 25
Base Excess (mmol/L)	-4.6	-6.7 – -3.5	-3 to 3.0
Na <sup>+</sup> (mmol/L)	150	145 – 154	135 – 145
K <sup>+</sup> (mmol/L)	4.4	3.8 – 5.6	3.5 – 5.0
Free Ca <sup>2+</sup> (mmol/L)	0.67	0.61 – 0.72	1.15 – 1.29
Glucose (mmol/L)*	14	13 – 15	4 – 9
Lactate (mmol/L)*	6	6 – 7	0.5 – 2.2
Hemoglobin (mmol/L)	*4.7	4.6 – 4.9	8.7 – 10.6
Albumin (mmol/L)	31	29 – 33	35 – 50
Chloride (mmol/L)	97	91 – 98	97 – 107
Urea (mmol/L)	3.5	2.9 – 3.6	2.5 – 7.5
Phosphate (mmol/L)	1.8	1.5 – 2.2	0.7 – 1.5
Magnesium (mmol/L)	0.55	0.51 – 0.63	0.70 – 1.00
Alanine-aminotransferase (U/L)	9	8 – 11	0 – 45
Aspartate-aminotransferase (U/L)	13	13 – 17	0 – 40
Alkaline phosphatase (U/L)	24	23 – 28	0 – 120
Gamma-glutamyltransferase (U/L)	9	7 – 16	0 – 40
Lactate dehydrogenase (U/L)	101	93 – 114	0 – 250
Total bilirubin (umol/L)	2	2 – 3	0 – 17

\* ) To convert values for glucose to mg/dL, multiply by 18.02. To convert values for lactate to mg/dL, multiply by 9.01. To convert values for hemoglobin to g/dL, multiply by 1.650.

## RESULTS

### Bile Production as Discriminating Variable during Machine Perfusion

First aim of this study was to determine whether bile production is a suitable marker of hepatic viability that can be used to during NMP to discriminate a potentially transplantable from a non-transplantable graft. Therefore, we determined the evolution of bile production during 6h of NMP for all twelve livers. Two distinct patterns of bile flow could be identified: 1) a steadily increasing bile production, resulting in a cumulative bile output of  $\geq 30$  g during the 6 h of perfusion, and 2) an initially increasing bile production during the first 2-3 hours, followed by a diminishing production, resulting in a cumulative bile production in 6h  $< 20$  g (**Figure 1**). Based on these observations, a cutoff value of 20 g cumulative bile production during 6 h of NMP was chosen to separate high from low bile output. There were six livers in each group and these two groups were used for further analyses.



**Figure 1.** Cumulative bile production during *ex vivo* normothermic machine perfusion of human donor livers. Presented are individual values for 12 livers that were declined for transplantation. *Ex vivo* machine perfusion and viability testing was started after a median cold storage of 6.5 hours. Two distinct patterns of bile flow could be identified: 1) a steadily increasing bile production, resulting in a cumulative bile output of  $\geq 30$  g during the 6 h of perfusion (dotted lines), and 2) an initially increasing bile production during the first 2-3 hours, followed by a diminishing production, resulting in a cumulative bile production in 6h  $< 20$  g (continuous lines).

A comparison of donor characteristics between livers with a high bile output versus livers with a low bile output during *ex vivo* machine perfusion is provided in **Table 2**. There were no statistically significant differences for any of these variables. Most livers were declined for transplantation because of a combination of DCD and age ( $>60$  years) or DCD and high BMI. Two livers were declined because of macrovesicular steatosis  $>30\%$  and both livers were in the low bile output group. It was obvious from this comparison that one would not have been able to identify livers with a high versus low bile output before organ procurement based on these conventional donor characteristics alone.

**Table 2.** Donor Characteristics

	<b>Total Group (n = 12)</b>	<b>Low Bile Output (n=6)</b>	<b>High Bile Output (n=6)</b>	<b>P-value</b>
Type of donor				0.12
DCD	10 (83 %)	4 (67%)	6 (100%)	
DBD	2 (17%)	2 (33%)	0 -	
Age (years)	61 (50-64)	55 (48-65)	63 (51-65)	0.47
Gender				0.22
Male	8 (67%)	3 (50%)	1 (17%)	
Female	4 (33%)	3 (50%)	5 (83%)	
Height (m)	1.77 (1.67-1.80)	1.77 (1.64-1.81)	1.78 (1.71-1.81)	0.69
Weight (kg)	88 (76-98)	90 (85-100)	78 (75-95)	0.20
Reason for rejection				0.25
DCD + age >60 years	5 (41%)	1 (17%)	4 (67%)	
DCD + high BMI	3 (25%)	2 (33%)	1 (17%)	
DCD + other reason**	2 (17%)	1 (17%)	1 (17%)	
Severe steatosis	2 (17%)	2 (33%)	0 -	
Preservation Solution				1.00
UW solution	6 (50%)	3 (50%)	3 (50%)	
HTK solution	6 (50%)	3 (50%)	3 (50%)	
Time between switch-off and cardiac death (min)	23 (8-51)	18 (0-23)	24 (17-53)	0.36
Donor warm ischemia time (min)	14 (17-20)	8 (0-52)	17 (15-18)	0.75
Cold ischemia time (min)	389 (458-585)	530 (431-750)	409 (363-473)	0.11
Liver weight (kg)	2.09 (1.6-2.24)	2.17 (1.60-2.31)	2.03 (1.71-2.18)	0.63

\*) continuous variables are presented as median and interquartile range, categorical variables are presented as numbers and percentage.

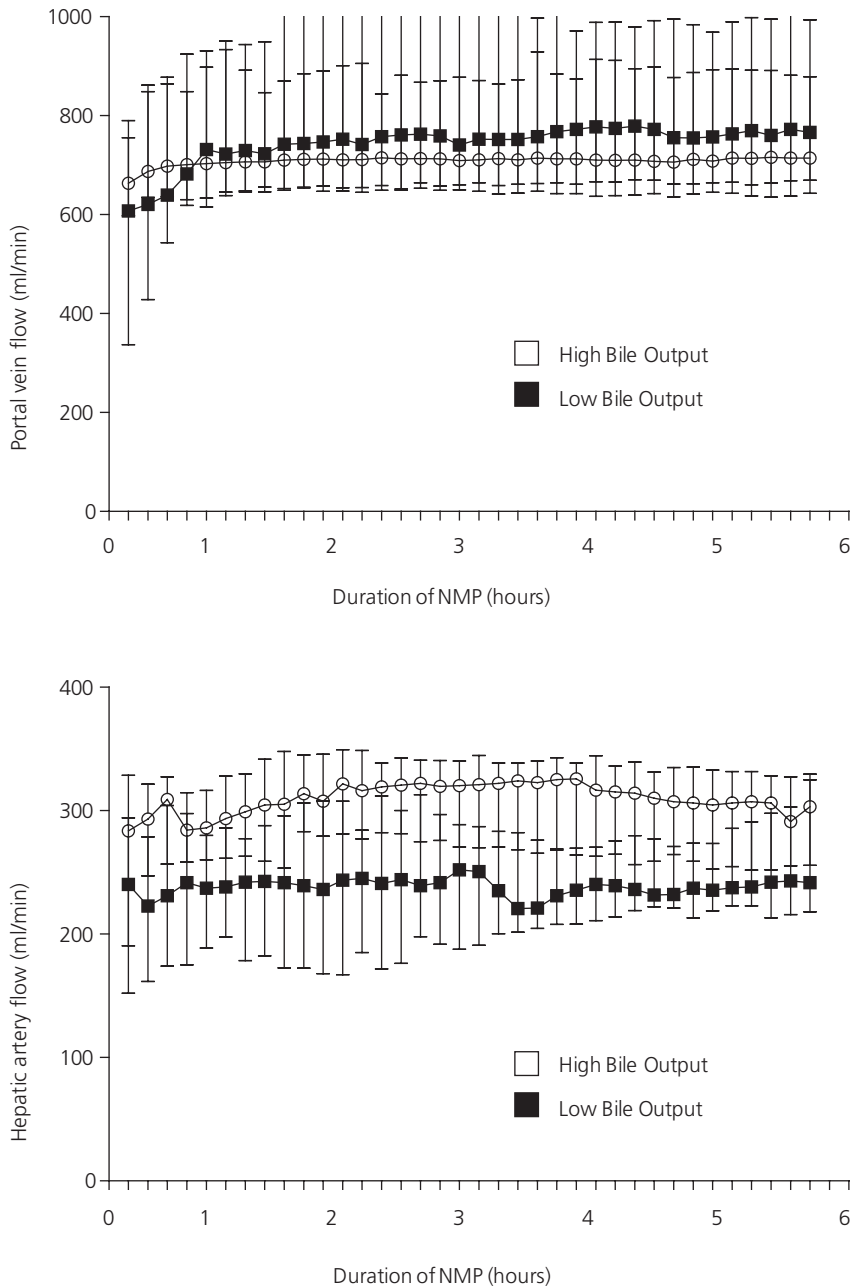
\*\*) One DCD donor with history of iv drug abuse (low bile output group) and one donor with prolonged  $sO_2 < 30\%$  after withdrawal of life support (high bile output group).

**Abbreviations used:** DCD, donation after cardiac death; DBD, donation after brain death; UW, university of Wisconsin; HTK, Histidine tryptophan-ketoglutarate

### Comparison of Hepatic Function and Injury

We next examined whether the differences in bile production correlated with other markers of hepatobiliary function and injury during NMP. First, we compared perfusion characteristics between the two groups. During NMP the flow in the portal vein and hepatic artery increased rapidly during the first 30 min and flows remained stable thereafter for the entire 6h perfusion period (**Figure 2**). There were no significant differences in portal flow and although median arterial flow was constantly lower in livers with a low bile output, compared to the high bile output group, this did not reach statistical significance.

Biochemical markers of hepatobiliary function and injury after 6 h of *ex vivo* perfusion are presented in **Table 3**. Most striking differences were significantly higher concentrations of



**Figure 2.** Changes in portal flow (**panel A**) and arterial flow (**panel B**) during ex vivo normothermic machine perfusion of human donor livers, using a pressure controlled device. Flow in the portal vein and hepatic artery increased rapidly during the first 30 min and flows remained stable thereafter for the entire 6h perfusion period. There were no significant differences in portal flow and although median arterial flow was constantly lower in livers with a low bile output, compared to the high bile output group, this did not reach statistical significance.

transaminases and a higher potassium level in the perfusion fluid of the low bile output group, compared to the high bile output group. These findings are compatible with a higher degree of IR injury and hepatocellular lysis in the former group. Bicarbonate concentration in perfusion fluid of livers with high bile output was 26 mmol/L (22-28 mmol/L), compared to 18 mmol/L (13-29 mmol/L) in the group of low bile output livers. Although this difference was not statistically different, it should be noted that about 4-times more sodium bicarbonate solution (8.4%) had been added during perfusion in the low bile output group to maintain a physiologic pH. After initiation of machine perfusion, glucose and lactate concentrations in the perfusion fluid initially increased in all cases. In the group of livers with high bile output glucose and lactate levels subsequently decreased rapidly and levels were normal at 6 h of NMP. In contrast with this, glucose and lactate levels in the low bile output group did not normalize during machine perfusion (**Table 3**).

Biochemical analysis of bile samples during 6 h of NMP revealed a 4-times higher concentration of bilirubin and a 2-times higher biliary concentration of bicarbonate in the high bile output group, compared to the low bile output group (**Table 3**). These findings indicate that a better secretory function of hepatocytes (bilirubin) coincides with that of cholangiocytes (bicarbonate).

### **Histological Comparison**

Finally, we compared histology of liver grafts after 6 h of NMP between the two groups. In accordance with the observed differences in biochemical markers of hepatic injury, livers in the low bile output group displayed more signs of hepatic necrosis and venous congestion, compared to the high bile output group (**Figure 3 A-D**). Despite these differences in hepatic parenchymal damage between the two groups, there were no major differences in the degree of biliary damage (**Figure 3 E-F**).

### **Minimal Duration of NMP Needed for Viability Assessment**

Secondary aim of this study was to determine the minimal duration of NMP needed to discriminate viable and potentially transplantable livers from non-viable livers. For this, we used the individual data on cumulative bile production as depicted in **Figure 1**. It can be deduced from this figure that livers in the low and high bile output groups can be discriminated from each other as early as 150 min after *ex vivo* machine perfusion. The combination of a cumulative bile production of  $\geq 10$  grams at 150 min and a bile production of  $\geq 4$  grams in the preceding hour identified 100% of the livers that would be considered as a high bile output liver after 6 h (**Table 4**). This finding indicates that after cold storage of a donor liver, a short period of 2.5 hours of *ex vivo* assessment during NMP is sufficient to identify a liver that may be preserved well enough to be transplanted successfully.



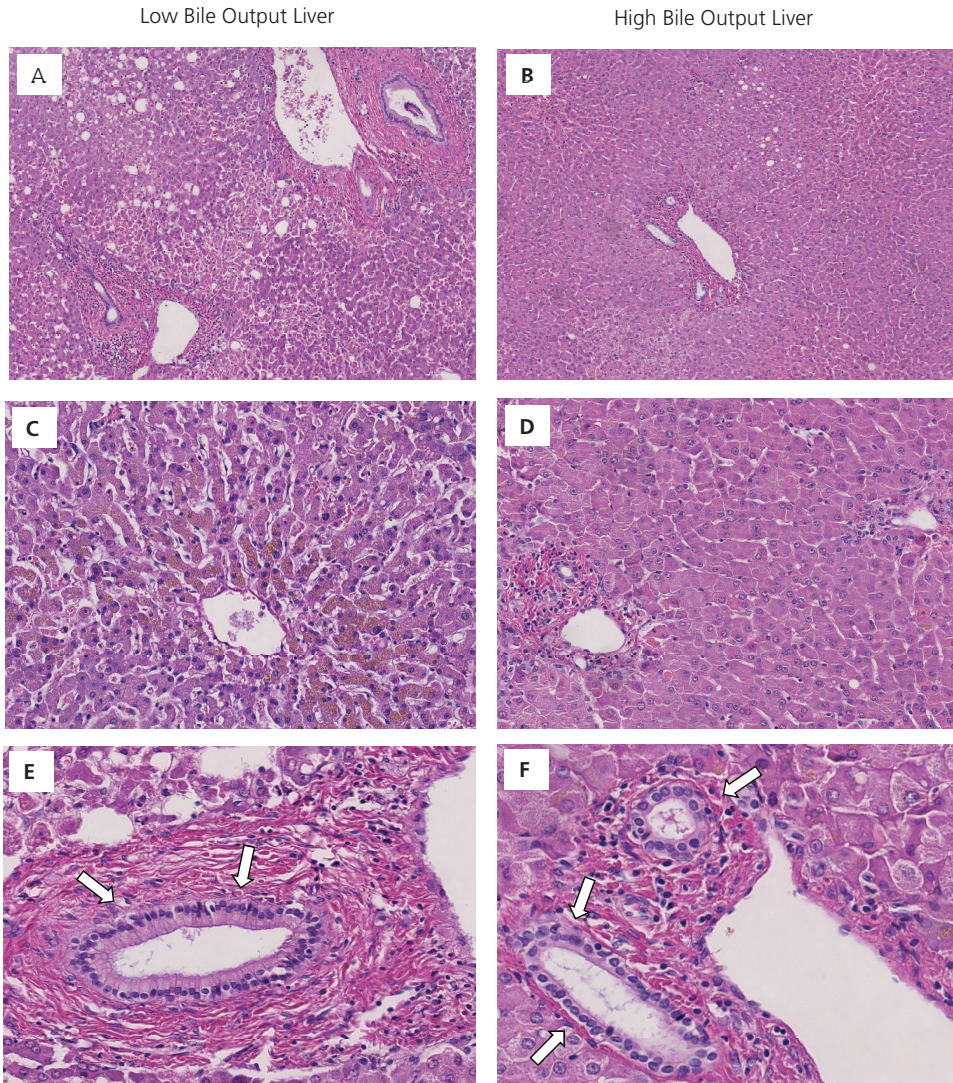
**Table 3.** Biochemical Composition of Perfusion Fluid and Bile after 6 hour of *Ex Vivo* Normothermic Machine Perfusion

	High Bile Output (n=6)	Low Bile Output (n=6)	p- value
<i>Blood gas variables</i>			
pH	<b>7.36</b> (7.25 – 7.40)	<b>7.34</b> (7.29 – 7.40)	1.00
pCO <sub>2</sub> (kPa)	<b>6.7</b> (5.9 – 7.8)	<b>5.0</b> (3.4 – 6.3)	0.08
pO <sub>2</sub> (kPa)	<b>64</b> (54 – 65)	<b>35</b> (10 – 67)	0.42
sO <sub>2</sub> (%)	<b>100</b> (99 – 100)	<b>98</b> (94 – 99)	<b>0.04</b>
HCO <sub>3</sub> <sup>-</sup> (mmol/L)	<b>26</b> (22 – 28)	<b>18</b> (13 – 29)	0.20
Added HCO <sub>3</sub> <sup>-</sup> 8.4 % (mL)	<b>8</b> (0 – 20)	<b>25</b> (4 – 86)	0.24
Base excess (mmol/L)	<b>+0.1</b> (-3.6 – +3.6)	<b>-6.8</b> (-12.0 – -4.0)	0.34
Hemoglobin (mmol/L)*	<b>4.2</b> (3.7 – 4.3)	<b>4.3</b> (4.1 – 4.6)	0.26
<i>Electrolytes and Metabolites</i>			
Na <sup>+</sup> (mmol/L)	<b>154</b> (143 – 155)	<b>142</b> (139 – 151)	0.26
K <sup>+</sup> (mmol/L)	<b>4</b> (2 – 8)	<b>13</b> (8 – 18)	<b>0.01</b>
Urea (mmol/L)	<b>14</b> (11 – 16)	<b>15</b> (12 – 22)	0.63
Glucose (mmol/L)*	<b>10</b> (8 – 19)	<b>23</b> (16-32)	0.07
Lactate (mmol/L)*	<b>2</b> (1 – 4)	<b>6</b> (3-11)	<b>0.03</b>
<i>Injury markers</i>			
ALT (U/L)	<b>2795</b> (1761 – 3972)	<b>11074</b> (6144 – 16050)	<b>0.04</b>
ALP (U/L)	<b>36</b> (25 – 44)	<b>154</b> (82 – 258)	<b>0.01</b>
GGT (U/L)	<b>35</b> (20 – 55)	<b>124</b> (107 – 187)	0.06
LDH (U/L)	<b>6227</b> (5151 – 6703)	<b>22119</b> (9584 – 34558)	0.06
Total bilirubin (μmol/L)	<b>3</b> (3 – 3)	<b>5</b> (3 – 7)	0.20
<i>Variables measured in bile*</i>			
Biliary pH	<b>7.58</b> (7.56 – 7.70)	<b>7.37</b> (7.05 – 7.71)	0.10
Biliary HCO <sub>3</sub> <sup>-</sup> (mmol/L)	<b>44</b> (35 – 50)	<b>20</b> (7 – 41)	0.09
Bilirubin in bile (μmol/L)	<b>1100</b> (968 – 1398)	<b>270</b> (215 – 525)	<b>0.02</b>

\*) To convert values for glucose to mg/dL, multiply by 18.02. To convert values for lactate to mg/dL, multiply by 9.01. To convert values for hemoglobin to g/dL, multiply by 1.650. To convert the value for bilirubin to mg/dL, divide by 17.1.

\*\*) Peak values during 6 h of machine perfusion.

**Abbreviations used:** ALT, alanine aminotransferase; ALP, alkaline phosphatase; GGT, gamma-glutamyl transferase; LDH, lactate dehydrogenase.



**Figure 3.** Histology of livers after 6 hours of normothermic machine perfusion. In comparison to livers with high bile output, livers in the low bile output group displayed more signs of hepatic necrosis (**panels A and B**) and venous congestion (**panels C en D**). Despite these differences in hepatic parenchymal damage between the two groups, there were no major differences in the degree of biliary damage (**panels E and F**).

**Table 4.** Criteria to Assess Bile Production after 2.5 hours of Normothermic Machine Perfusion

	<b>Liver (Number)</b>	<b>Cumulative Bile Output After 2.5 h (g)</b>	<b>Bile Output Between 1.5 h and 2.5 h (g)</b>	<b>Meets Both Criteria*</b>
Low-bile output				
	1	6.54	2.52	No
	2	12.53	3.14	No
	3	1.86	0.37	No
	4	4.66	2.19	No
	5	0.00	0.00	No
	6	8.14	2.36	No
High-bile output				
	7	18.77	7.22	Yes
	8	12.93	7.33	Yes
	9	14.92	8.50	Yes
	10	10.55	5.00	Yes
	11	15.72	4.66	Yes
	12	25.35	8.85	Yes

\*) Criteria are: 1) Cumulative bile production of  $\geq 10$  grams after 2.5 h and 2) a bile production of  $\geq 4$  grams in the preceding hour (1.5 - 2.5 h of perfusion)

## DISCUSSION

Machine perfusion of donor livers is receiving increased attention as experimental studies have suggested that this method can provide better protection during storage and transportation, compared to static cold storage (10-12). Especially ECD livers have been shown to be more susceptible to IR injury, requiring the introduction of novel and more complex preservation techniques (7,15). Besides the potential benefits of machine perfusion in providing better protection against preservation injury, this technique also provides the possibility of viability testing of a donor organ prior to transplantation. Pretransplant viability testing may become an important new tool to compensate for the increasing proportion of ECD livers (i.e. livers from donors with advanced age, elevated body mass index, diabetes, or livers from DCD donors), which has resulted in an increasing proportion of non-use of donor livers during the last decade (4). The main finding in this study is that bile production can be used as an easy assessable marker of liver graft viability during *ex vivo* NMP. Cumulative bile production of  $\geq 30$  g during 6 h of NMP was associated with significantly lower release of transaminases and potassium into the perfusion fluid and better hepatobiliary function as reflected by a normalization of glucose and lactate levels and higher biliary secretion of bilirubin. In addition, histology of grafts with a high bile output showed less signs of venous congestion and hepatocellular necrosis, compared to livers with a low cumulative bile output. The second novel finding of this study is that the minimal duration of NMP needed to discriminate viable and potentially transplantable livers from

non-viable livers is 2.5 hours. This relatively short time period facilitates a timely selection and preparation of a potential recipient, making this new selection method clinically applicable.

The results of this study open interesting new avenues for the clinical application of *ex vivo* viability testing of ECD livers that, based on conventional criteria, are declined for transplantation. This method has the potential to have a significant impact on the number of donor liver available for transplantation. Of the twelve discarded livers included in this study, 6 (50%) displayed improving function and normalization of hepatobiliary metabolism. Although all livers were declined for transplantation because they were considered ECD livers with a too high risk of primary non-function after transplantation, 50% of these may have functioned well after transplantation. All livers were retrieved from a donor outside our hospital and the median duration of cold storage prior to initiation of *ex vivo* viability testing was 6.5 hours. This time sequence can also be expected when this technique is introduced in clinical practice.

In an experimental study using pig livers, Imber *et al* have previously suggested that bile production is probably the most important parameter of liver function (11). The amount of bile production correlated strongly with the degree of hepatic IR injury. Our experience with discarded human donor livers is in line with this experimental study.

The significant higher release of potassium and ALT in low-bile output livers reflects a higher degree of hepatocellular injury. The absolute concentrations of ALT measured in the perfusion fluid may seem relatively high; however, these results cannot be compared directly with values usually obtained after clinical liver transplantation. First of all, livers were perfused *ex vivo* in a closed circuit and values represent the cumulative release of ALT without any clearance from the system. Secondly, the perfusion circuit contained only 2 liters compared to an average of 5 liters of blood *in vivo*.

In addition to bile production alone, good liver function was reflected by a normalization of glucose and lactate levels in the perfusion fluid, as well as an increasing production of bicarbonate in the livers with high bile output. The latter was reflected by an increasing median concentration of bicarbonate in perfusion fluid from 19 mmol/L at baseline to 26 mmol/L after 6 h of NMP in the high bile output group. In the low bile output group median bicarbonate concentration in the perfusion fluid at 6 h was only 18 mmol/L, despite the addition of a 4-times higher amount of sodium bicarbonate 8.4% during perfusion to maintain a physiologic pH. These findings are in accordance with a previous animal study that has indicated that autoregulation of the acid-base balance is a reflection of a well-functioning liver (16).

In the current study, we did not add bile salts to the perfusion fluid. Hepatocellular secretion of bile salts into bile canaliculi is an important driving force of bile flow (17,18). *In vivo*, bile salts are reabsorbed from the gut and transported back to the liver through the enterohepatic circulation. Bile salts are subsequently secreted again into the bile, causing a choleric increase in total bile flow. Obviously, this enterohepatic circulation is interrupted during *ex vivo* NMP and this could theoretically lead to bile salt depletion and a subsequent decline in bile production. However,

experimental studies using pig livers have shown that bile salt depletion does not occur until after 10 hours of NMP (18). In the current study, livers were perfused for 6 hours and we did not observe a decline in bile output. Therefore, we do not believe that the addition of bile salts is necessary when livers are perfused for less than 10 hours. In fact, hydrophobic bile salts have been demonstrated to play a role in bile duct epithelial injury after liver transplantation and this could be considered an additional argument not to add bile salts to the perfusion fluid (19-21). On the other hand, due to the strong choleric effect of bile salts, bile production during *ex vivo* NMP will be higher when bile salts are added to the perfusion fluid. This should be kept in mind when comparing bile output values obtained in different studies.

Bile production is an energy consuming, multi-step process that requires an intact network of sinusoidal cells, hepatocytes and cholangiocytes. Therefore, it is intuitive that bile production is a strong and reliable indicator of overall liver quality and viability. In clinical liver transplantation, poor initial bile production has been associated with poor outcomes. In one study, graft survival at one year was only 45% for livers that failed to produce bile in the operating room (14). In addition to bile volume, we have shown a higher biliary secretion of bilirubin in grafts with high bile output, reflecting better bile quality produced by these livers.

Although some studies on kidney and liver machine perfusion have suggested that a decline in arterial flow in a pressure controlled system of machine perfusion can be used as a marker of decreasing graft viability (22-24), we found stable flows in both high and low bile output livers. Apparently, change in perfusion flow is not a reliable parameter of graft viability in human liver machine perfusion. However, in livers with a low bile production we did observe a lower arterial flow during the entire 6 h of NMP, compared to the low bile output group, but this did not reach statistical significance. In general, we do not advise to use flow values as an indicator of liver damage and viability during human liver machine perfusion.

In conclusion, this study provides evidence that the assessment of bile production is a discriminative indicator of hepatic function and injury during *ex vivo* NMP of human donor livers. It could potentially be used to identify ECD livers that are declined for transplantation based on donor risk factors, but that may still be suitable for transplantation. The next step is to use *ex vivo* bile production as a new critical selection criterion to accept ECD livers that would otherwise have been declined for transplantation based on an anticipated poor postoperative function. We are currently preparing a clinical trial to implement this novel selection tool based on *ex vivo* assessment of ECD donor livers after cold storage.

## ACKNOWLEDGEMENTS

We are grateful to Arjan van der Plaats and Martin Kuizenga (Organ Assist, Groningen, Netherlands) for their technical support and assistance during the perfusion experiments. Furthermore, we are appreciative to all the Dutch transplantation coordinators, Ernst Buiter and Cees Brugman in particular, for identifying the potential discarded livers and obtaining informed consent.

## REFERENCES

- (1) Merion RM, Goodrich NP, Feng S. How can we define expanded criteria for liver donors? *J Hepatol* 2006;45:484-488.
- (2) McCormack L, Dutkowski P, El-Badry AM, Clavien PA. Liver transplantation using fatty livers: always feasible? *J Hepatol* 2011;54:1055-1062.
- (3) Op den Dries S, Sutton ME, Lisman T, Porte RJ. Protection of bile ducts in liver transplantation: looking beyond ischemia. *Transplantation* 2011;92:373-379.
- (4) Orman ES, Barritt AS, 4th, Wheeler SB, Hayashi PH. Declining liver utilization for transplantation in the United States and the impact of donation after cardiac death. *Liver Transpl* 2013;19:59-68.
- (5) Bae C, Henry SD, Guarrera JV. Is extracorporeal hypothermic machine perfusion of the liver better than the 'good old icebox'? *Curr Opin Organ Transplant* 2012;17:137-142.
- (6) Brockmann J, Reddy S, Coussios C, Pigott D, Guirriero D, Hughes D, et al. Normothermic perfusion: a new paradigm for organ preservation. *Ann Surg* 2009;250:1-6.
- (7) Dutkowski P, de Rougemont O, Clavien PA. Machine perfusion for 'marginal' liver grafts. *Am J Transplant* 2008;8:917-924.
- (8) Hessheimer AJ, Fondevila C, Garcia-Valdecasas JC. Extracorporeal machine liver perfusion: are we warming up? *Curr Opin Organ Transplant* 2012;17:143-147.
- (9) Monbaliu D, Brassil J. Machine perfusion of the liver: past, present and future. *Curr Opin Organ Transplant* 2010;15:160-166.
- (10) Fondevila C, Hessheimer AJ, Maathuis MH, Munoz J, Taura P, Calatayud D, et al. Hypothermic oxygenated machine perfusion in porcine donation after circulatory determination of death liver transplant. *Transplantation* 2012;94:22-29.
- (11) Imber CJ, St Peter SD, Lopez de Cenarruzabeitia I, Pigott D, James T, Taylor R, et al. Advantages of normothermic perfusion over cold storage in liver preservation. *Transplantation* 2002;73:701-709.
- (12) Schlegel A, Rougemont O, Graf R, Clavien PA, Dutkowski P. Protective mechanisms of end-ischemic cold machine perfusion in DCD liver grafts. *J Hepatol* 2013;58:278-286.
- (13) Op den Dries S, Karimian N, Sutton ME, Westerkamp AC, Nijsten MW, Gouw AS, et al. Ex vivo normothermic machine perfusion and viability testing of discarded human donor livers. *Am J Transplant* 2013;13:1327-1335.



- (14) Markmann JF, Markmann JW, Desai NM, Baquerizo A, Singer J, Yersiz H, et al. Operative parameters that predict the outcomes of hepatic transplantation. *J Am Coll Surg* 2003;196:566-572.
- (15) Pomfret EA, Sung RS, Allan J, Kinkhabwala M, Melancon JK, Roberts JP. Solving the organ shortage crisis: the 7th annual American Society of Transplant Surgeons' State-of-the-Art Winter Symposium. *Am J Transplant* 2008;8:745-752.
- (16) Reddy SP, Bhattacharjya S, Maniakina N, Greenwood J, Guerreiro D, Hughes D, et al. Preservation of porcine non-heart-beating donor livers by sequential cold storage and warm perfusion. *Transplantation* 2004;77:1328-1332.
- (17) Portincasa P, Calamita G. Water channel proteins in bile formation and flow in health and disease: when immiscible becomes miscible. *Mol Aspects Med* 2012;33:651-664.
- (18) Imber CJ, St Peter SD, de Cenarruzabeitia IL, Lemonde H, Rees M, Butler A, et al. Optimisation of bile production during normothermic preservation of porcine livers. *Am J Transplant* 2002;2:593-599.
- (19) Buis CI, Geuken E, Visser DS, Kuipers F, Haagsma EB, Verkade HJ, et al. Altered bile composition after liver transplantation is associated with the development of nonanastomotic biliary strictures. *J Hepatol* 2009;50:69-79.
- (20) Yska MJ, Buis CI, Monbaliu D, Schuur TA, Gouw AS, Kahmann ON, et al. The role of bile salt toxicity in the pathogenesis of bile duct injury after non-heart-beating porcine liver transplantation. *Transplantation* 2008;85:1625-1631.
- (21) Hoekstra H, Porte RJ, Tian Y, Jochum W, Stieger B, Moritz W, et al. Bile salt toxicity aggravates cold ischemic injury of bile ducts after liver transplantation in Mdr2+/- mice. *Hepatology* 2006;43:1022-1031.
- (22) Obara H, Matsuno N, Enosawa S, Shigeta T, Huai-Che H, Hirano T, et al. Pretransplant screening and evaluation of liver graft viability using machine perfusion preservation in porcine transplantation. *Transplant Proc* 2012;44:959-961.
- (23) Nyberg SL, Baskin-Bey ES, Kremers W, Prieto M, Henry ML, Stegall MD. Improving the prediction of donor kidney quality: deceased donor score and resistive indices. *Transplantation* 2005;80:925-929.
- (24) Impedovo SV, Martino P, Palazzo S, Ditunno P, Tedeschi M, Giangrande F, et al. Value of the resistive index in patient and graft survival after kidney transplant. *Arch Ital Urol Androl* 2012;84:279-282.



# PART D

Addendum



# CHAPTER 12

## **Shared Decision Making in Transplantation: How Patients See Their Role in the Decision Process of Accepting a Donor Liver**

Op den Dries S, Annema C, van den Berg AP, Ranchor AV, Porte RJ.

*Submitted for publication.*

## **ABSTRACT**

At the time of organ offer for transplantation, donor-related risks such as disease transmission and graft failure are weighed against the patient's risk of remaining on the waiting list. The patient's role in decision-making and the timing and extent of donor-specific risk information has been discussed in the medical literature. This is the first study revealing the opinion of liver patients on these issues. Forty patients listed for liver transplantation and 179 transplanted liver patients participated in an anonymous questionnaire-based survey. The majority of patients wanted to be informed about donor-related risks (59.8-74.8%). The preferred timing of donor-related risk information was for 53.3% of the patients at the time of organ allocation. Of these patients, 79.8% wished to be involved in decision-making, 10.6% wished to make the final decision alone and only 9.6% did not want to be involved in the decision-making process. Implementing this knowledge by standardizing the content, the manner of transfer, and the amount of information that we provide to our patients will improve opportunities for shared decision-making at different time points along the transplant allocation process. This will enable us to provide the same opportunities and care to every patient on the waiting list.

## INTRODUCTION

Liver transplant waiting lists increase more rapidly than the supply of donor organs, leaving many patients stranded, without access to what is often a life-saving therapy. Efforts to increase the donor pool are being made by accepting more donors at the expense of diminished quality of their organs (i.e. extended criteria donors). An extended criteria donor (ECD) implies a higher donor-related risk in comparison with a standard criteria donor (SCD). This risk may manifest as increased incidence of poor allograft function, allograft failure, or transmission of a donor-derived disease (1).

To which extent donor-related risks are discussed with the liver transplant candidate and whether or not the transplant candidate is involved in the decision-making process at the time of donor offer, varies between countries and hospitals (2-4). In the US, since the 2007 implementation of the guidelines from the Department of Health and Human Services, Centers for Medicare and Medicaid Services (CMS), consent forms are required for various stages of the transplant process, starting with the initial evaluation and ending with the surgery. However, consent for ECD liver transplantation is not a requirement of the CMS; it is offered at the discretion of the provider (3). A recent study by Bruzzone *et al.* has provided insight in the European implementation of informed consent for ECD liver donation; the majority of transplant centers inform transplant candidates about the ECD status of the donor, but great variation was observed in the timing of informing (before listing and/or at the time of organ allocation), the topics discussed, and whether a special consent form was signed (2).

Standardization for the timing and content of the informed consent and the transplant patient's role in the decision-making process is currently lacking, although both topics receive increasing attention in medical literature (5-9). Health researchers and policy-makers increasingly urge both patient and clinician engagement in shared decision making (SDM) to facilitate greater involvement of patients in their personal healthcare management (10). Paternalistic health care has fallen out of favour, replaced by the 'patient-centered model', which emphasizes patient autonomy, informed consent and empowerment (11). Although SDM has been examined and implemented in numerous clinical settings (12,13), it has received little attention in solid organ transplantation, especially in the field of (deceased) liver transplantation (8,10). In a transplant setting, decisions often have to be made quickly and the risks and benefits are difficult to explain fully at the time of an organ offer, complicating patient involvement in SDM. Moreover, medical decision making for liver transplantation raises additional challenges for SDM given that liver transplant patients have no effective alternative medical options to transplantation, such as dialysis in renal patients (10).

Various ideas about the patient's role in decision-making and the time and extent of informed consent have been proposed in medical literature (6,8,14). However, there is a more fundamental question to be answered first – what do patients really want? There is very limited information

on the donor-related risk information that patients want to receive, the preferred timing of ECD informed consent, whether potential transplant candidates want to be involved in decision-making at the time of organ allocation, and how much risk they are willing to accept. We therefore performed an anonymous questionnaire-based survey among patients listed for transplantation and transplanted liver patients, addressing these questions.

## PATIENTS AND METHODS

### Participants and Study Design

All adult liver transplant recipients at the University Medical Center in Groningen (UMCG) between 2000 and 2010, who were still receiving post-transplant care at our center, were invited to participate. In addition, adult patients that were actively listed for transplantation on the 1<sup>st</sup> of February 2013, were invited for participation. All eligible post- and pre-transplant liver patients received an information letter and a questionnaire. Questionnaires were coded and confidentiality was guaranteed. After 4 weeks, a reminder was sent to non-responders and another 4 weeks were allowed for completion. The study met the criteria for an exemption from approval (approval letter METc2012.306). The questionnaire was composed for the purpose of the study under guidance of an experienced health psychology researcher (AVR). Internal validation questions were added to assess the patients' understanding of the questionnaire and demonstrated conformity of 90-96%. The original information letter and questionnaire are available upon request.

### Assessment

All liver patients were approached by mail and asked to complete a 20-30 min questionnaire. Patients were first reminded of the distinction between standard criteria donor livers (SCD) and donor livers with an increased risk of complications after transplantation; the so-called extended criteria (ECD) donor livers. The difference between the general risk of a transplant procedure and (specific) donor-related risks was explained. Age >60 yr, steatosis and donation after cardiac death (DCD) were described as risk factors for liver failure and bile duct complications, respectively. Also, the potential risk of transferring a malignancy or an infectious disease from the donor to the recipient was explained. Following this introduction, patients were asked personal questions with respect to time on the waiting list, experience with previous liver transplantation and experience with complications after liver transplantation (self or an acquaintance).

**Patients' Acceptable Risk of Disease Transmission.** Next, patients were informed that the risk of transferring a malignancy or infectious disease from the donor in SCD donor livers is generally kept below 1%, leading to discard of livers that are otherwise suitable for transplantation. Patients then were asked to indicate on a visual proportion scale (1-50%) the risk of disease-transmission that they considered a high risk, followed by indicating the risk of disease-transmission that they

were willing to accept. The latter two questions were repeated (on the following page) after informing the patients about the 15% mortality rate on the waiting list.

**Informing Patients About Donor-Related Risks.** In the subsequent question, patients were asked whether they wished to be informed when a donor liver was offered with: 1) *an increased risk of transferring an infectious disease such as hepatitis or HIV*, 2) *an increased risk of transferring a malignant disease (tumor)*, 3) *an increased risk of bile duct strictures*, 4) *an increased risk of early graft failure*. Early graft failure was explained as requiring re-transplantation within 2 weeks after transplantation.

**Timing of donor-specific informed consent.** Next, it was explained that patients are informed (in general terms) about donor-related risks before waiting list registration. It is currently not common practice to inform patients about specific donor-related risks at the time of donor offer. First, patients were asked to agree or disagree (*strongly disagree, disagree, uncertain, agree or strongly agree*) with four statements in which motives for wanting or not wanting information about donor-related risks were explored: 1) *It would cause distress (I would worry) if I would receive information about donor-related risks at the time of donor offer*, 2) *I would like to receive information about donor-related risks at the time of donor offer, because it will allow me to be mentally prepared*, 3) *I prefer not to receive information about donor-related risks at the time of donor offer, because I would be already overwhelmed*, 4) *I would like to receive information about donor-related risks at the time of donor offer, since it will allow me to decide whether I do or do not want to receive that donor liver*. Subsequently, patients were asked whether they wished to be informed about donor-related risks of the liver offered to them for transplantation, with the following options for answers: 1) *No, I do not want to be informed about the donor-related risks*, 2) *I want to be informed at the time of donor offer, even when this is at 3 a.m.*, 3) *I want to be informed afterwards, when I have recovered from the transplant surgery*.

**The Patient's Role in the Decision Process.** The patients that wished to be informed at the time of donor offer, were asked what they plan to do with the acquired information: a) *Just for the sake of knowing, the decision on whether or not to accept the liver should be made by my physicians*; b) *I would like to make the decision together with my physician, we should decide together on whether or not to accept the liver*; c) *I would like to make the final decision alone (by myself)*.

Next, patients were explained that in some countries, listed patients are allowed to exclude certain groups of (increased risk) donor livers from being offered to them for transplantation, such as DCD livers, livers from older donors, or donors with an increased risk of infectious disease transmission. They were told that this would decrease the risk of complications after transplantation, but it also would increase the waiting time for a donor liver and thereby increase the mortality risk while on the waiting list. Patients were asked if they want to be able to exclude certain groups of donor livers, before being listed for transplantation.

**Presented Cases.** Finally, two cases were presented to the patients, one concerning an 18-year old donor acquainted with intra-venous drug use, the second case concerning an 81-year old, healthy, donor (**Table 3**). First, patients were asked to assess the expected risk of infectious disease transmission or early graft failure (respectively) in those two cases. Next, the patients were asked whether they would accept these livers for transplantation if 1) their personal medical situation was stable and if 2) their liver disease was progressively severe and the situation therefore unstable.

Information was obtained about patient age, gender, country of origin, civil status, education and employment status. Data regarding primary liver disease etiology and time on the waiting list were extracted from medical databases.

### **Statistical Analysis**

Data were expressed as means and standard deviations, medians or percentage of participants with specific responses. Categorical variables were compared with the Pearson Chi-square test or Fisher's Exact test where appropriate. Continuous variables were compared with the Student-T test. Repeated measurements of ordinal variables within one group were compared using the Wilcoxon Signed Ranks Test. The level of significance was set at a p-value of 0.05. Statistical analyses were performed using SPSS software version 16.0 for Windows (SPSS, Inc., Chicago, IL).

## **RESULTS**

### **Respondent Characteristics**

Patients on the waiting list with status 'non-active' (n=18) and age <18 years (n=15) were excluded. In total, 243 transplanted patients and 66 patients on the waiting list were invited to participate. Overall response was 70.9% (n=219), including 60.6% (n=40) of the approached waiting list patients and 73.7% (n=179) of the transplanted patients.

The study population was predominantly middle aged, male, Dutch, married and educated at intermediate level (**Table 1**). The most common indications for transplantation were non-cholestatic cirrhosis (34.7%), cholestatic cirrhosis (33.3%) and metabolic disease (10.5%). Time since (the last) liver transplantation was  $6.4 \pm 3.1$  years (mean $\pm$ SD) for transplanted patients and  $9.4 \pm 4.2$  years for patients on the waiting list who had been transplanted before (n=8; 20% of all participating listed patients). Of all transplanted patients, 54.4% (n=99) had developed one or more complications after transplantation, with biliary complications being the most common (n=55; 30.2%). Average time on the waiting list was 34.9 months (median: 26, interquartile range 6-49 months) for the waiting list patients. Non-responders did not differ significantly from responders with regard to gender, liver disease before transplantation and time since last transplantation. However, non-responders were significantly younger (mean and SD  $46.7 \pm 16.6$  vs



54.5±13.1;  $p < 0.001$ ). During the study period, two non-responders died and one was admitted to the hospital.

**Table 1.** Patient characteristics

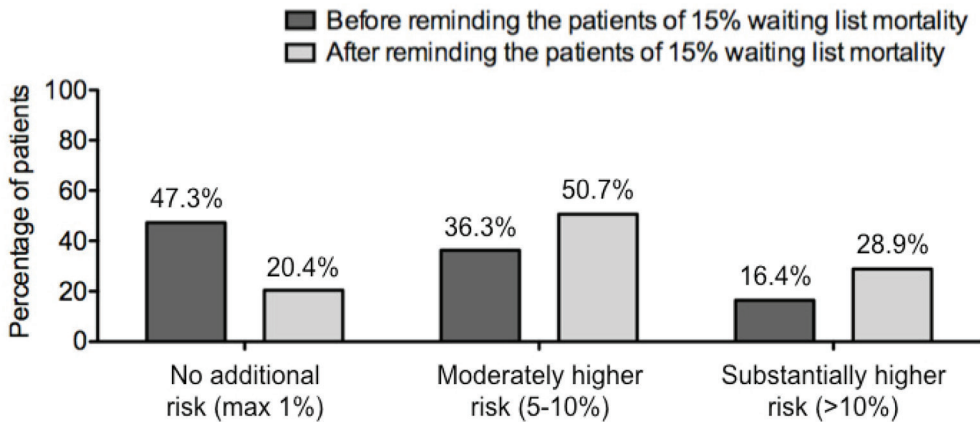
	Overall (n=219)	Post-tx (n=179)	Waiting list (n=40)
Age, years	54.5 ± 13.1	55.8 ± 12.8	48.6 ± 13.1
Sex, female	94 (42.9%)	76 (42.5%)	18 (45.0%)
Country of origin			
Netherlands	203 (93.1%)	164 (92.1%)	39 (97.5%)
Other	15 (6.9%)	14 (7.9%)	1 (2.5%)
Civil status			
Married	145 (66.8%)	120 (67.8%)	25 (62.5%)
De facto union	17 (7.8%)	12 (6.8%)	5 (12.5%)
Partner, not living together	8 (3.7%)	6 (3.4%)	2 (5.0%)
No partner	33 (15.2%)	26 (14.7%)	7 (17.5%)
Divorced	7 (3.2%)	6 (3.4%)	1 (2.5%)
Widow	7 (3.2%)	7 (4.0%)	0 (0.0%)
Highest education achieved			
Lower vocational education or primary school	53 (24.5%)	47 (26.6%)	6 (15.4%)
Intermediate vocational education	99 (45.8%)	80 (45.2%)	19 (48.7%)
Higher vocational education or university	64 (29.6%)	50 (28.2%)	14 (35.9%)
Occupation			
Full-time/part-time job	56 (26.9%)	42 (24.9%)	14 (35.9%)
Retired	55 (26.4%)	49 (29.0%)	6 (15.4%)
Partial or complete incapacity to work	58 (27.9%)	44 (26.0%)	14 (35.9%)
Other (student, voluntary, looking for job, etc)	39 (18.8%)	34 (20.1%)	5 (12.8%)
Liver disease (before transplantation)			
Acute hepatic failure	13 (5.9%)	13 (7.3%)	0 (0.0%)
Non-cholestatic cirrhosis	76 (34.7%)	59 (33.0%)	17 (42.5%)
Cholestatic cirrhosis	73 (33.3%)	55 (30.7%)	18 (45.0%)
Metabolic disease	23 (10.5%)	22 (12.3%)	1 (2.5%)
Hepatocellular carcinoma	18 (8.2%)	17 (9.5%)	1 (2.5%)
Congenital pediatric liver disease	4 (1.8%)	3 (1.7%)	1 (2.5%)
Miscellaneous	12 (5.5%)	10 (5.6%)	2 (5.0%)
Liver transplantation in the past	187 (85.4%)	179 (100%)	8 (20.0%)
Time since (last) liver transplantation, years	6.5 ± 3.1	6.4 ± 3.1	9.4 ± 4.2 (n=8)
Time on waiting list, months	NA	NA	34.9 ± 43.2

Values are presented as mean ± SD or N (%)

### Patients' View on Acceptable Risk of Disease Transmission

In general, the risk of disease transmission during organ transplantation is kept below 1%. Patients reported significantly higher willingness to accept an increased risk of disease transmission after having received information about the current 15% waiting list mortality (**Figure 1**). The risk of disease transmission that patients were willing to accept was 7±1% (mean±SE), which increased to 12±1% after having received information about the current waiting list mortality ( $p < 0.001$ ). After providing information about the 15% waiting list mortality, 79.6% of the patients accepted a risk of ≥ 5%. No significant differences were found between subgroups based on patient status

(transplanted/waiting list), age, gender, level of education (low/intermediate/high), country of origin (Netherlands/other) or civil status (living alone/with partner).



**Figure 1.** Acceptable risk of disease transmission. Acceptable risk of disease transmission, according to all patients, before (dark grey) and after (light grey) receiving information about the 15% waiting list mortality.

### Informing About Different Types of Donor-Related Risks

The vast majority wished to be informed when donor-related risks are increased. In case of increased risk of transmission of an infectious disease or a malignant tumor, 73.5% and 74.8% of respondents, respectively, wished to be informed (**Table 2**). In case of increased risk of bile duct strictures, 59.8% of respondents wished to be informed. When increased risk of early graft failure is present, 70.1% of the patients wished to be informed. Experience with bile duct complications or early graft failure after liver transplantation (self or acquaintance) was not associated with an increased wish to be informed about an increased risk of bile duct strictures or early graft failure, respectively. No significant differences were found between subgroups based on age, gender, level of education (low/intermediate/high), country of origin (Netherlands/other) or civil status (living alone/with partner). However, compared to transplanted patients, significantly more waiting list patients wished to be informed about donor-related risks (**Table 2**).

**Table 2.** Number of patients that wish to be informed about donor-related risks

Information about:	Overall	Post-tx	Waiting list	P-value
Increased risk of infectious disease transmission	150 (73.5%)	115 (69.3%)	35 (92.1%)	<b>0.014</b>
Increased risk of malignant tumor transmission	154 (74.8%)	120 (71.4%)	34 (89.5%)	0.061
Increased risk of developing bile duct strictures	122 (59.8%)	95 (57.2%)	27 (71.1%)	0.269
Increased risk of early graft failure*	143 (70.1%)	109 (65.7%)	34 (89.5%)	<b>0.015</b>

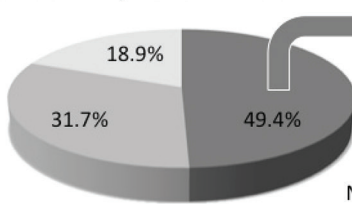
\* Re-transplantation required within 2 weeks after transplantation

**Preferred Time for Providing Donor-Related Risk Information**

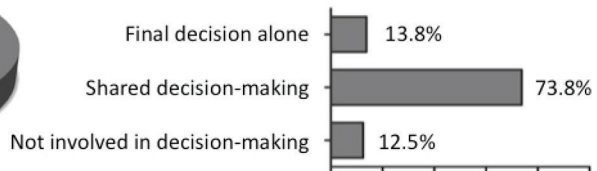The preferred timing of donor-related risk information was for 53.3% of the patients at the time of organ allocation, for 18.8% of the patients after the transplant procedure and 27.7% of the patients did not wish to be informed. Significantly more waiting list patients wished to be informed at the time of organ allocation (71.1%), compared to transplanted patients (49.4%);  $p=0.021$  (Figure 2). Younger patients ( $\leq 40$  years) wished to be informed at the time of organ allocation more often (70.3%), compared with older patients (55.6% of age 41-60 and 44.0% of age 60+). More patients with a lower level of education preferred not to be informed at all (43.8%), when compared with intermediate educated (25.5%) or higher educated patients (16.9%);  $p=0.026$ . No significant differences were found between subgroups based on gender, country of origin (Netherlands/other) or civil status (living alone/with partner). When compared with waiting list patients, transplanted patients indicated more frequently that they would feel worried if donor-related risk information was provided at the time of organ allocation (59.5% vs 39.5%) and that they would feel overwhelmed (39.2% vs 18.4%);  $p=0.048$  and  $p=0.047$ , respectively.

**Transplanted patients:**

When would you like to be informed:

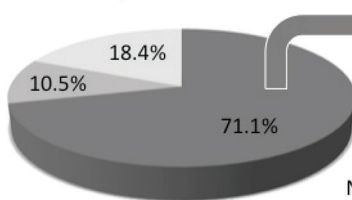


What would you do with this information?

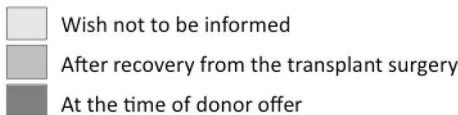
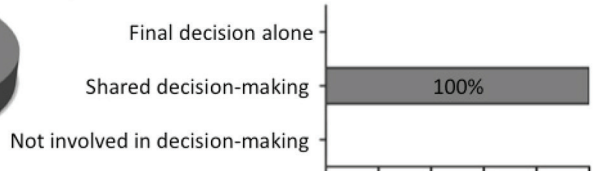


**Patients on the waiting list:**

When would you like to be informed:



What would you do with this information?



**Figure 2.** Timing and consequence of providing donor-related risk information. The majority of patients want to be informed about donor-related risks at the time of organ allocation (pie chart; dark grey) and wishes to be involved in the decision-making process (the grey bars on the right).

### **The Patient's Role in the Decision Process**

All respondents that wished to be informed about donor-related risk at the time of organ allocation, were asked if they wished to be actively involved in the decision-making process for accepting or declining the liver for transplantation. Overall, 79.8% of respondents preferred shared decision-making, 10.6% wished to make the final decision alone and only 9.6% did not want to be involved in the decision-making process. No significant differences were found between subgroups based on age, gender, level of education (low/intermediate/high), country of origin (Netherlands/other) or civil status (living alone/with partner). As presented in **Figure 2**, significantly more waiting list patients wished to be involved in share-decision making (100%), when compared to transplanted patients (73.8%);  $p=0.019$ ).

Patients were asked if they want to be able to exclude certain groups of donor livers, before being listed for transplantation. Only 21.6% of transplanted patients and 31.6% of the waiting list patients wished to be able to exclude certain groups of donor livers, before being listed for transplantation. No differences were found between the above-mentioned subgroups.

### **Presented Cases**

Finally, two potential donor cases were presented; a healthy 18-year-old previous heroin user tested negative for HIV and a healthy 81-year-old donor. Of all patients, only 19.4% judged the risk of disease transmission associated with accepting the liver from the 18-year-old donor as high. Similarly, only 16.5% of the patients judged potential non-function in the 81-year-old liver as a high risk. No less than 74.3% of respondents would accept a liver from the 18-year-old previous heroin user and 73.1% would accept a liver from the healthy 81-year-old donor if the respondent's own condition was deteriorating. If the own condition was moderately stable, still 40.7% of the respondents would accept the 18-year-old liver and 39.2% would accept the 81-year-old liver (**Table 3**).

In case of the healthy 18-year-old previous heroin user, no significant differences were found between subgroups based on patient status (waiting list/transplanted), age, level of education (low/intermediate/high), country of origin (Netherlands/other) or civil status (living alone/with partner). Male respondents, however, were significantly more often willing to accept this 18-year-old liver, when compared with female respondents; 50.4% vs 27.5% ( $p<0.001$ ) when the respondent's condition is moderately stable and 80.5% vs 65.9% ( $p=0.052$ ) when the respondent's condition is deteriorating. In case of the healthy 81-year-old donor, no significant differences were found between the above-mentioned subgroups.

**Table 3.** Two cases and situations: Would you accept this liver?

	Acceptable?		
	Yes	No	Uncertain
<p><b>A)</b> An 18-year-old young man died of an acute stroke (brain death). He was in good health and his blood liver tests were normal. There is no evidence of a (endured) virus infection like Hepatitis B or C virus or HIV. However, the donor was acquainted with intravenous heroin use.</p> <p><i>Situation 1:</i> You have been listed for transplantation for 8 months and your condition is deteriorating, you are admitted to hospital with significant jaundice, ascites and fatigue. <b>There are concerns as to whether there will be a liver available for transplantation in time.</b></p>	74%	3%	23%
<p><b>B)</b> Same donor profile as case A</p> <p><i>Situation 2:</i> You have been listed for transplantation for 8 months and your condition is fairly stable. You work part-time (half days) because of your liver disease and you suffer mild jaundice. <b>Arguably, you have some time to wait for a suitable organ offer.</b></p>	41%	17%	43%
<p><b>C)</b> An 81-year-old woman died of an acute stroke. She lived more or less independently, relying only on her neighbours for help with groceries. She has been healthy her whole life. Blood liver tests were normal.</p> <p><i>Situation 1:</i> You have been listed for transplantation for 8 months and your condition is deteriorating, you are admitted to hospital with significant jaundice, ascites and fatigue. <b>There are concerns as to whether there will be a liver available for transplantation in time.</b></p>	73%	3%	24%
<p><b>D)</b> Same donor profile as case C</p> <p><i>Situation 2:</i> You have been listed for transplantation for 8 months and your condition is fairly stable. You work part-time (half days) because of your liver disease and you suffer mild jaundice. <b>Arguably, you have some time to wait for a suitable organ offer.</b></p>	39%	15%	46%

## DISCUSSION

Various ideas about the patient's role in decision-making and the timing and extent of informed consent in transplantation have been proposed and discussed in literature by medical professionals (5-9,14). This is the first study revealing the opinion of liver patients on these issues. The four main findings are: (1) most liver patients want to be informed about donor-related risks, (2) half of the liver patients want to be informed at the time of organ allocation, (3) of those patients, the majority wishes to participate in the decision making process to accept or decline a potential donor liver, and (4) liver patients are willing to accept a relatively high risk of disease transmission and graft failure.

The vast majority of patients (60-75%) want to be informed when the donor-related risk of infectious disease, a malignant tumor, bile duct strictures or early graft failure is increased. The need for a full, clear and frank explanation about general and donor-specific risks of transplantation is supported in the literature (7,9). Moreover, better-informed patients may establish more realistic expectations, which in turn have shown to improve postsurgical health outcomes and decrease legal claims (15,16). This finding also supports the call for standardization

of informed consent prior to placement on the waiting list, which would promote the autonomy of recipients by helping to ensure that they are informed of all relevant donor risk factors (6). Interestingly, for more than 50% of the patients the preferred timing of donor-related risk information is at the time of organ allocation. Additionally, more than 90% of those patients want to be involved in the decision-making process on whether to accept or decline a potential donor liver. This confronts medical teams with a dilemma; on one hand, the principles of patient autonomy and dignity require nothing less than complete disclosure, especially when potentially risky therapies are offered (14), and on the other hand, disclosure of donor-specific risk requires extra time precisely when time is at a premium (during organ allocation), which could therefore prevent the optimal use of the organ supply (6).

A suggested alternative to shared decision-making at the time of organ allocation, is to give patients the opportunity to accept or decline ECD organs as a group before transplantation (6). However, a classification of organs into two groups might be inaccurate, since some of the standard organs would not be acceptable for certain recipients and not all ECD organs are of equal quality and risk (8). It has therefore been suggested to classify ECD organs in several groups, but it is still questionable whether the patient can understand the impact of these risks and make a good decision, especially since the patients' own medical condition is a dynamic process which will change their willingness to accept ECD livers, as shown in this study. Only a quarter of the patients in this study wished to be able to exclude certain groups of donor livers, before being listed for transplantation.

There is recognition that shared decision-making may not suit all types of patients. Studies of shared decision-making have found that patients with more serious or life-threatening illnesses, or those for whom there are no alternative treatments, do not wish to participate in the decision making process (17). In contrast to renal patients, patients with end-stage liver disease have no effective alternative medical options to transplantation, such as dialysis. Interestingly, this study showed that the majority of the liver transplant patients do actually want to be involved in shared decision making at the time of organ allocation.

This study also showed that patients are willing to accept a relatively high risk of disease transmission and potential graft failure, especially when the patient's clinical situation is deteriorating. Previous studies have shown a similar high willingness of patients to accept donor-related risks, such as ECD donor livers or donor kidneys at risk for viral infections (18,19). Interestingly, we noticed that informing the patients of the 15% waiting list mortality rate significantly increased the willingness to accept more donor-related risk. This suggests that providing information affects the decision-making process. Providing standardized information on the risks and benefits of the different types of ECD donor transplantation at the time of waiting list registration, potentially in combination with comprehension assessment tools and e-health educational tools, might enable liver patients to participate in shared decision-making at the time of organ allocation. Decision

aids have demonstrated to affect long-term behavior and appear to promote informed decision-making (20).

A potential bias could reside in the fact that we do not know whether the non-responders to this questionnaire would have given the same answers to the questions, when compared to the responders. We did, however, compare responder and non-responder characteristics and we found no significant differences with regard to gender, liver disease and time since transplantation. On the other hand, non-responders were about 8 years younger. During the study period, two non-responders died and one was admitted to the hospital. Therefore, we think that a part of the non-responders might have been too sick to respond to the questionnaire. One might expect that these patients have less interest to participate in shared decision-making at the time of organ allocation.

This study is clinically relevant to anyone who is involved in transplantation. Decisions concerning the patient's role in decision-making and the timing and extent of informed consent in transplantation need to be made by every transplant centre. Both the physician's opinion and the patient's opinion on these issues should be taken into consideration. Standardization of the information about the different donor types provided before listing the patients and shared decision-making at the time of organ allocation is important to provide the same opportunities and care to every patient. We are aware that the results of the current study only represent the opinion of liver patients in The Netherlands. The opinion of patients elsewhere in the world could be different. We hope that this study stimulates other transplant centers to perform a similar survey to reveal the local need for information and involvement of patients in the decision-making process surrounding liver transplantation.

In case of deceased liver transplantation, decisions often have to be made quickly and the risks and benefits are difficult to explain fully at the time of an organ offer. The involvement in shared decision-making should be consistent with patient preferences; the process of involvement may be as important as who eventually makes the decision (21,22). Based on the results of this study we suggest that information on risks related to SCD and ECD transplantation is provided in detail to all patients listed for transplantation. Moreover, patients who want to be informed and involved in SDM at the time of organ allocation should be identified at the time of listing for transplantation. Accordingly, these patients should receive additional information and potentially decision aids to allow shared decision making at the time of organ allocation.

In conclusion, the questionnaire presented in this paper provides unique information on the opinion of liver patients on donor-related risks. The majority of respondents wished to be informed about donor-related risks and wanted to be involved with shared decision-making at the time of organ allocation. Implementing this knowledge and standardizing the content, the manner of transfer and the amount of information we provide to our patients at the different time points along the transplant allocation process will be important to provide the same opportunities and care to every patient on the waiting list.



## REFERENCES

- (1) Durand F, Renz JF, Alkofer B, Burra P, Clavien PA, Porte RJ, et al. Report of the Paris consensus meeting on expanded criteria donors in liver transplantation. *Liver Transpl* 2008;14:1694-1707.
- (2) Bruzzone P, Giannarelli D, Nunziale A, Manna E, Coiro S, De Lucia F, et al. Extended criteria liver donation and transplant recipient consent: the European experience. *Transplant Proc* 2011;43:971-973.
- (3) Rosenthal L. Design and implementation of an informed consent process before liver transplantation. *Prog Transplant* 2008;18:273-283.
- (4) McLaren A, Morris-Stiff G, Casey J. Issues of consent in renal transplantation. *Ann R Coll Surg Engl* 2001;83:343-346.
- (5) Freeman RB, Cohen JT. Transplantation risks and the real world: what does 'high risk' really mean? *Am J Transplant* 2009;9:23-30.
- (6) Halpern SD, Shaked A, Hasz RD, Caplan AL. Informing candidates for solid-organ transplantation about donor risk factors. *N Engl J Med* 2008;358:2832-2837.
- (7) Panico M, Solomon M, Burrows L. Issues of informed consent and access to extended donor pool kidneys. *Transplant Proc* 1997;29:3667-3668.
- (8) Ross LF, Zenios S, Thistlethwaite JR, Jr. Shared decision making in deceased-donor transplantation. *Lancet* 2006;368:333-337.
- (9) Sells RA. Informed consent from recipients of marginal donor organs. *Transplant Proc* 1999;31:1324-1325.
- (10) Gordon EJ, Butt Z, Jensen SE, Lok-Ming Lehr A, Franklin J, Becker Y, et al. Opportunities for shared decision making in kidney transplantation. *Am J Transplant* 2013;13:1149-1158.
- (11) Edwards A, Elwyn G. Shared decision-making in health care: achieving evidence-based patient choice. Second edition ed. Oxford, UK: Oxford University Press;2009.
- (12) van Til JA, Drossaert CH, Punter RA, Ijzerman MJ. The potential for shared decision-making and decision aids in rehabilitation medicine. *J Rehabil Med* 2010;42:598-604.
- (13) Whelan T, Levine M, Willan A, Gafni A, Sanders K, Mirsky D, et al. Effect of a decision aid on knowledge and treatment decision making for breast cancer surgery: a randomized trial. *JAMA* 2004;292:435-441.
- (14) Pomfret EA, Sung RS, Allan J, Kinkhabwala M, Melancon JK, Roberts JP. Solving the organ shortage crisis: the 7th annual American Society of Transplant Surgeons' State-of-the-Art Winter Symposium. *Am J Transplant* 2008;8:745-752.
- (15) Gordon EJ, Daud A, Caicedo JC, Cameron KA, Jay C, Fryer J, et al. Informed consent and decision-making about adult-to-adult living donor liver transplantation: a systematic review of empirical research. *Transplantation* 2011;92:1285-1296.

- (16) Leclercq WK, Keulers BJ, Scheltinga MR, Spauwen PH, van der Wilt GJ. A review of surgical informed consent: past, present, and future. A quest to help patients make better decisions. *World J Surg* 2010;34:1406-1415.
- (17) Pentz RD, Pelletier W, Alderfer MA, Stegenga K, Fairclough DL, Hinds PS. Shared decision-making in pediatric allogeneic blood and marrow transplantation: what if there is no decision to make? *Oncologist* 2012;17:881-885.
- (18) Reese PP, Tehrani T, Lim MA, Asch DA, Blumberg EA, Simon MK, et al. Determinants of the decision to accept a kidney from a donor at increased risk for blood-borne viral infection. *Clin J Am Soc Nephrol* 2010;5:917-923.
- (19) Rodrigue JR, Hanto DW, Curry MP. Patients' willingness to accept expanded criteria donor liver transplantation. *Am J Transplant* 2011;11:1705-1711.
- (20) Volk RJ, Spann SJ, Cass AR, Hawley ST. Patient education for informed decision making about prostate cancer screening: a randomized controlled trial with 1-year follow-up. *Ann Fam Med* 2003;1:22-28.
- (21) Edwards A, Elwyn G. Inside the black box of shared decision making: distinguishing between the process of involvement and who makes the decision. *Health Expect* 2006;9:307-320.
- (22) Dy SM, Purnell TS. Key concepts relevant to quality of complex and shared decision-making in health care: a literature review. *Soc Sci Med* 2012;74:582-587.





# CHAPTER 13

## **An Ex-Vivo Oxygenated Normothermic Machine Perfusion System for Rat Livers**

Op den Dries S, Kuipers M, Karimian N, op den Dries GH, Lisman T, Leuvenink HGD, Porte RJ.

## **ABSTRACT**

An attractive alternative to cold preservation of donor livers before transplantation is ex-vivo normothermic machine perfusion (NMP) providing oxygen and nutrients at 37°C. To allow different NMP protocols to be studied, a normothermic machine perfusion device for rat livers, comparable to devices available for human livers, is needed. In this chapter we describe the protocol of the ex-vivo oxygenated normothermic machine perfusion system for rat livers that we built for the experiment in chapter 9 and for future studies on the different aspects of normothermic machine perfusion.

## INTRODUCTION

Ex-vivo machine perfusion of donor organs is receiving increasing attention as an attractive alternative to static cold storage (SCS) for preservation of liver grafts before transplantation. Contrary to SCS preservation at 4°C, intended to decrease metabolism, normothermic machine perfusion at 37°C offers full metabolic support and the possibility to assess graft viability prior to transplantation. Moreover, the quality of liver grafts could potentially be improved by pharmacological conditioning during ex-vivo normothermic perfusion. Successful normothermic machine perfusion requires a device that allows portal and arterial perfusion of the liver, an oxygenated perfusion fluid containing nutrients and an oxygen carrier in a temperature- and a pressure controlled system in order to protect sinusoids from perfusion pressure-related injury (1-3). Such devices for normothermic machine perfusion are available for perfusion of human and large animal liver grafts (1,4). However, existing ex-vivo normothermic machine perfusion devices for rat livers do not meet the above criteria. In order to study the impact of different aspects of normothermic machine perfusion (perfusion fluid, temperature protocol, pharmacological agents) on liver function and injury, a normothermic machine perfusion device for rat livers is needed. Therefore, we aimed to build a pressure-controlled, ex-vivo oxygenated normothermic machine perfusion system for rat livers providing both arterial and portal perfusion.

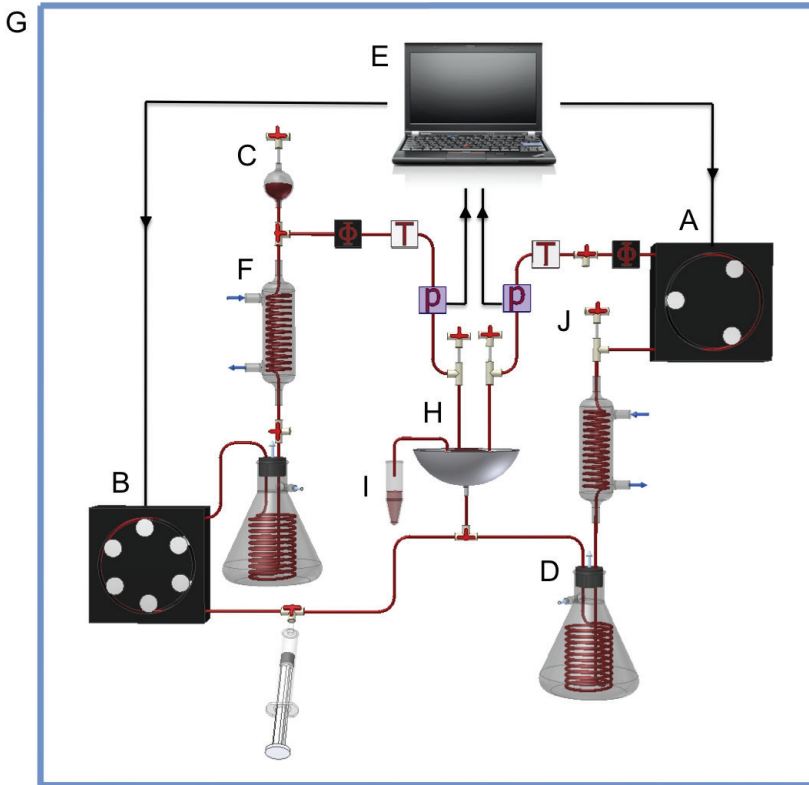
### Previous applications of the protocol

This protocol was used for the study described in chapter 9, in which we determined the impact of normothermic machine perfusion on bile duct preservation in rat livers.

### Overview of the rat liver perfusion system


We developed a normothermic machine perfusion system that enables dual perfusion via both the hepatic artery and the portal vein in a closed circuit (**Figure 1 and 2**). Two roller pumps provide a pulsating flow to the hepatic artery and a continuous flow to the portal vein. The air chamber and the oxygenator minimize pulses caused by the roller pump on the portal side, resulting in a continuous portal flow. A physiological arterial flow of 6 mL/min results in a physiological arterial pulse of 250/min delivered to the hepatic artery. To minimize loss of pulse we used inelastic tubing between the arterial roller pump and the liver. Two tubular membrane oxygenators provide oxygenation of the perfusion solution and removal of CO<sub>2</sub>. The system is pressure-controlled, allowing auto regulation of blood flow through the liver, with constant pressure at variable flow rates. The Ohm's formula was used to correct for additional resistance caused by the cannulas:  $P_{total} = P_{liver} (1 + (R_{cannula} / (R_{total} - R_{cannula})))$ . Inline sensors detect flow, pressure and temperature, and data are analyzed by and displayed in real-time on a connected laptop. Pressure is limited to a mean of 110 mmHg in the hepatic artery and 11 mmHg in the portal vein. Two glassware coil type heat exchangers connected to two water baths are used to heat

the perfusate to 37°C and the entire perfusion system is placed inside a Perspex climate box containing a fan-driven heater regulated by a thermostat to maintain a constant temperature. The stainless steel organ chamber allows perfusion fluid to easily return to the circuit. The liver is placed in the organ chamber on a metal grid covered with plastic paraffin film to prevent physical injury to the bottom of the liver. A transparent plastic cover on the organ chamber maintains a moist environment for the perfused rat liver (**Figure 3**).




**Figure 1.** Schematic overview of rat liver perfusion system. Two roller pumps provided a pulsatile flow to the hepatic artery (**A**) and a continuous flow to the portal vein (**B**), after eliminating pulses with an air chamber (**C**). Two tubular membrane oxygenators provided oxygenation of the perfusion solution, as well as removal of  $\text{CO}_2$  (**D**). The system was both pressure and temperature controlled. Flow ( $\phi$ ), pressure ( $P$ ) and temperature ( $T$ ) were detected by inline sensors and data were analyzed by and displayed in real-time on a connected laptop (**E**). Heat exchangers (**F**) and a plexiglass climate box encapsulating the perfusion system (**G**), ensured temperature control at 37°C. The rat liver was placed into an organ chamber (**H**), protected with a transparent cover to maintain a moist and warm environment. Bile was collected in Eppendorf tubes (**I**). Several three-way connectors were used as bubble traps (**J**).





**Figure 2. Photographic overview of the rat liver perfusion system.** The transparent climate box containing the perfusion system is flanked by the two water baths. The laptop on the left regulates the portal and arterial flows, in a pressure-controlled manner.



**Figure 3. Photos during normothermic machine perfusion.** The bright red colour of oxygenated blood exiting one of the two arterificial lungs (A). The organ chamber with a perfused rat liver (B) and bile produced by the liver, collected in an Eppendorf tube (C).

## MATERIALS

### Reagents

- NaCl 0.9%
- D-glucose 0.9 g/L
- Human full blood
- William's Medium E solution with phenol red (Sigma Chemical)
- Human albumin (200g/L Albuman®, Sanquin, Amsterdam, Netherlands)
- Insulin (100 IE/mL Actrapid®, Novo Nordisk, Alphen aan den Rijn, Netherlands)
- Unfractionated heparin (5000 IE/mL)
- Ethanol 70%
- Demineralized water
- Sodium Bicarbonate (8.4% for IV use)
- Biological soap based on active enzyme complexes (Biotex Groen, Unilever, Rotterdam, Netherlands)

### Equipment

#### *General Supplies*

- Syringes 5 mL/10mL/20mL
- Syringe 5 mL with NaCl (0.9%) at 37°C
- Syringe 5 mL with NaCl (0.9%) at 4°C
- Gauzes and cotton buds
- Microsurgery set + vascular clamps
- Surgical microscope
- Silk sutures (6-0 and 4-0)
- Crushed ice + ice container
- Petri dish
- Eppendorf tubes

#### *Ex-vivo Machine Perfusion System*

- Roller pump + pump head with 3 rollers for the hepatic artery  
(Ismatec ISM404 + ISM719; IDEX Health and Science)
- Roller pump with 6 rollers for the portal vein  
(Ismatec MS-2/6-160; IDEX Health and Science)
- Tubing for roller pumps  
(Ismatec Pharmed BPT NSF-51; IDEX Health and Science)

- Porous silicon tubing for the oxygenator (Rubber BV)
- Glass Büchner flask with rubber bung (Schott Duran; 500 mL)
- Two inline pressure sensors (Truwave Transducer PX600FPR; Edwards Lifesciences Corporation)
- Two inline flow sensors (Transonic Systems Inc. Type 1PXN)
- Flow measuring device (Transonic Systems Inc. Model T402; 2 channels)
- Two inline temperature sensors (MEDOS NTC)
- Two glassware coil type heat exchangers (Radnoti Heating coil; 5.5 mL)
- Three-way connectors (Cole-Parmer Y-form Fitting; 35mm by 21 mm)
- Air chamber with membrane
- Digital thermostat (Lucky Reptile. Thermo Control Pro 2)
- Fan-driven heater (Euromac bv. Personal Heater 200; 200 Watt)
- Two water baths (Julabo Labortechnik GMBH MP-5; 2.1 Kilowatt)
- Custom-made stainless steel organ chamber on a tripod + metal grid
- Extended Clamps (to position portal and arterial cannulas)
- Plastic paraffin film (Parafilm® Pechiney Plastic Packaging Company, Chicago, US)
- Laptop with software (Kindly provided by Organ Assist, Groningen, Netherlands)
- Custom-made Perspex climate box (Research Instrument Manufacturing Department UMCG)
- Portal, arterial and common bile duct cannulas (**Figure 4**) (Insyte, Becton Dickinson BV. Portal 18 Gauge IV Catheter; Arterial 20 Gauge)



**Figure 4. Cannulas.** Cannulas for the portal vein **(A)**, celiac trunk (hepatic artery) **(B)** and common bile duct **(C)**. Cannulas are composed of pieces of tubing slid over one another, with a small ring of tubing at the tip to prevent them from being pulled out of the blood vessel or bile duct.

### Reagent Setup

#### *Red blood cell concentrate*

1) Dissolve 0.18 g D-glucose (0.9g/L) in 200 mL NaCl (0.9%). 2) Centrifuge human blood at 1400 G for 10 min at room temperature, without brake. 3) Pipet plasma + buffy coat from the red blood cell concentrate (RBC). 4) Mix the RBC with the glucose/NaCl solution 1:1. Repeat step 2-3 three times.


#### *Perfusion Fluid*

Mix 20 mL human red blood cell concentrate (final hematocrit 15-20%), 59mL William's Medium E solution, 20mL human albumin (200g/L Albuman®, Sanquin, Amsterdam, Netherlands), 1mL insulin (100 IE/mL Actrapid®, Novo Nordisk, Alphen aan den Rijn, Netherlands) and 0,1mL unfractionated heparin (5000 IE/mL), adding up to a total volume of 100mL.

**Equipment Setup** to a source of carbogen flow (95% O<sub>2</sub> + 5% CO<sub>2</sub>) with flexible tubing. Insert three needles through the rubber bung in the neck of the Büchner flask; two for in- and outflow of perfusion fluid and one for the outflow of carbogen. Drape porous tubing over a hook inserted into the bottom of the rubber bung in order to increase surface area contact with carbogen and connect the tubing to two of the inserted needles (**Figure 5K**).

#### *Ex-vivo machine perfusion system*

Connect the different parts of the perfusion system as shown in **figure 1** and **figure 2**.



**Figure 5.** Photographic details of the rat liver perfusion system. A thermostat was used to maintain a constant temperature at 37°C (A), regulated via a fan-driven heater (I) and a heat exchanger (D). An outlet (B) for the carbogen used in the two tubular membrane oxygenators (K) on top of the cabinet. An inline pressure sensor (C), temperature sensor (E) and flow sensor (F). Cannulas for the hepatic artery and portal vein (G). A three-way connector with a small tube inserted, used as a bubble-trap (H) and an air chamber to minimize pulses in the portal flow, also functioning as an additional bubble-trap (J).

## Procedure

### *Preparing the ex-vivo machine perfusion system*

1. Set the thermostat to 37°C and switch on the connected fan driven heater inside the cabinet. Turn on the water baths and set to 37°C.
2. Turn on the laptop, roller pumps and the flow-measuring device. Open the software that regulating the pressure-controlled flow in the system.
3. Flush the system with 70% ethanol, unhook the tubing from the roller pumps and dry the system using pressurized air.
4. Flush the system with demineralized water and subsequently circulate NaCl 0.9% for 15 minutes.
5. Fill the system with the prepared perfusion fluid (about 100 mL) and turn on the carbogen flow. Use a low flow, as a high flow may cause bubbles to form inside the tubes containing perfusion fluid. Check the system for bubbles and use bubble-traps to remove bubbles if needed.

6. Weigh Eppendorf tubes for bile collection and take a perfusate sample for blood gas measurement. Correct the pH of the perfusion fluid to 7.35-7.45 by using Sodium Bicarbonate and repeat blood gas measurement.

#### *Preparing the hepatectomy*

1. Place a 5 mL syringe with NaCl 0.9% in a 37°C stove
2. Place two 5 mL syringes, one 1 mL syringe and one 20 mL syringe with NaCl 0.9% on crushed ice in a foam ice container.
3. Fill a Petri dish with crushed ice, cover it with a gauze, the metal grid and a layer of plastic paraffin film, to protect the liver from the grid. Place the Petri dish on ice.
4. Prepare a 1 mL syringe with 0.1 mL heparin and 0.9 mL NaCl 0.9%
5. Keep two 20 mL syringes with NaCl 0.9% at room temperature to keep the bowels moist during the hepatectomy.
6. Lay out the ligatures and sutures required during the surgery (8x ligature 6/0 and 1x suture 4/0)

#### *Hepatectomy*

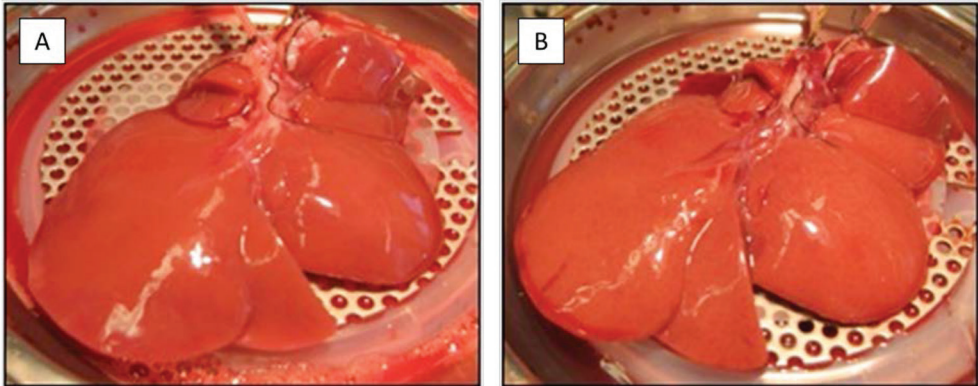
1. Initiate anesthesia of the rat with a gas mixture of 5% isoflurane and 100% oxygen, maintain anesthesia with 2-3% isoflurane + 100% oxygen.
2. Weigh the rat and place the rat in supine position with the nose pointed into the anesthesia nose mask.
3. Shave the incision area and determine the effectiveness of the anesthesia by testing eye reflexes and response to pain stimuli.
4. Disinfect the incision area with 70% ethanol and open the abdomen with a transverse abdominal incision just below the rib cage. Retract the xiphoid using a suture.
5. Move bowels with a gauze drenched in NaCl 0.9% to the left side of the rat.
6. Cut the falciform ligament and shift the liver towards the diaphragm.
7. Expose the bile duct and place a loose ligature around the bile duct.
8. Incise the bile duct distally from the ligature and cannulate the bile duct. Collect the bile in an Eppendorf tube.
9. Expose the portal vein, the splenic vein, the mesenteric vein, the hepatic artery and localize the two side branches of the celiac trunk. If possible, place a loose ligature around the 3 side branches of the portal vein and the 2 side branches of the celiac trunk. Do not tighten the ligatures yet, in order to prevent congestion.
10. Place a loose ligature around the proximal side of the portal vein. Be sure not to accidentally ligate the hepatic artery.
11. Expose the distal portal vein (where the portal clamp will be placed for cannulation).

12. Ligate the branches of the celiac trunk and place 2 loose ligature proximal and distal from the celiac trunk.
13. Inject 1 mL of heparin (500 U/mL) via the dorsal vein of the penis.
14. Expose the distal vena cava.
15. Try to dissect the ligaments attaching the liver to the surrounding structures.
16. Ligate the distal celiac trunk, cannulate the trunc and fixate the cannula with the proximal ligature. Pay attention to face the opening of the canula downwards, with the sharp tip facing up.
17. Clamp the distal vena cava and place a clamp on the distal portal vein. From this moment onwards the liver has no circulation.
18. Ligate the lienal vein, the mesenteric artery and the mesenteric vein.
19. Insert the cannula into the portal vein, immediately flush 5 mL NaCl 0.9% at 37°C via the portal vein. Pay attention to face the opening of the canula downwards, with the sharp tip facing up. Dissect the proximal vena cava to prevent backflow of blood, immediately followed by 5 mL NaCl 0.9% flush at 4°C via the portal vein. Fixate the portal vein cannula using the proximal ligature.
20. Dissect the diaphragm of the rat for easy removal of the liver.
21. Carefully hold the cannulas with tweezers and dissect the liver free. Flush 20 mL NaCl 0.9% at 4°C via the portal vein cannula and 3 mL NaCl 0.9% at 4°C via the celiac trunk/hepatic artery cannula.

#### *Ex-vivo machine perfusion*

1. Before connecting the liver to the system, be sure to recalibrate the system to pressure = zero with the spare set of hepatic artery and portal vein cannulas in place and the roller pumps on hold.
2. Place the liver in the organ chamber on the convex side (**Figure 6**). Connect the portal vein cannula and the celiac trunk (hepatic artery) cannula to the tubes of the perfusion system. Make sure there are no bubbles in the cannula or elsewhere in the perfusion system.
3. Set the portal pressure at 11 mmHg and the arterial pressure at 110 mmHg.
4. Direct the bile cannula into an Eppendorf tube that has been weighed before the start of the experiment. Attach the Eppendorf tube to the holder on one of the legs of the organ chamber.





**Figure 6.** Normothermic machine perfusion of rat livers. A rat liver just after connecting to the perfusion system (**A**) and the same rat liver after 5 hours of normothermic machine perfusion (**B**).

*Cleaning the ex-vivo machine perfusion system*

1. Remove the liver by disconnecting the portal vein cannula and hepatic artery cannula from the perfusion system.
2. Flush the system with demineralized water (single-pass) until the water exiting the system is clear.
3. Make a Biotex soap solution by passing 500 mL of demineralized water with biotex through a filter, heat it in a water bath and flush the system with this warm soap solution.
4. Flush the system with at least 1 L of warm demineralized water (single-pass).
5. Flush the system with 70% alcohol and dry the system with pressured air. Be aware to disconnect the tubing from the roller pumps, before drying the system. The tubing should remain unhooked from the pumps to prevent stretching and tearing.

## ACKNOWLEDGEMENT

We are grateful to Pieter Hamming (Organ Assist, Groningen, Netherlands) for his IT support.

## REFERENCES

- (1) Op den Dries S, Karimian N, Sutton ME, Westerkamp AC, Nijsten MW, Gouw AS, et al. Ex vivo normothermic machine perfusion and viability testing of discarded human donor livers. *Am J Transplant* 2013;13:1327-1335.
- (2) 't Hart NA, der van Plaats A, Leuvenink HG, van Goor H, Wiersema-Buist J, Verkerke GJ, et al. Determination of an adequate perfusion pressure for continuous dual vessel hypothermic machine perfusion of the rat liver. *Transpl Int* 2007;20:343-352.
- (3) Luer B, Koetting M, Efferz P, Minor T. Role of oxygen during hypothermic machine perfusion of the liver. *Transpl Int* 2010;23:944-950.
- (4) Imber CJ, St Peter SD, Lopez de Cenarruzabeitia I, Pigott D, James T, Taylor R, et al. Advantages of normothermic perfusion over cold storage in liver preservation. *Transplantation* 2002;73:701-709.





# CHAPTER 14

**Summary, Discussion and Future Perspectives**

## SUMMARY AND GENERAL DISCUSSION

Non-anastomotic biliary strictures (NAS) are a major complication after liver transplantation. The development of strictures of the bile ducts inside or more frequently outside the liver (extrahepatic) is characteristic of this complication. The aim of this thesis was to gain a better understanding of the etiologies underlying NAS and to study the potentially protective role of machine perfusion in the prevention of bile duct injury before transplantation. In addition, we aimed to investigate how patients want to be informed and involved in the decision to accept a liver with increased risk of bile duct complications. In this chapter, the results of this thesis are summarized and discussed, followed by a section on future perspectives.

### **Part A: The Scope of Bile Duct Injury in Liver Transplantation**

**Chapter 1** provides a general introduction to this thesis, including the aims of each chapter. The pathogenesis, clinical presentation, and management of the various types of biliary complications that can occur after liver transplantation are discussed in **chapter 2**. In summary, biliary complications are a frequent cause of morbidity after liver transplantation that occur in 10-40% of the recipients, resulting in mortality rates of 8-15%. Partial liver grafts (e.g. split livers and livers from living donors) as well as livers from extended criteria donors (e.g. DCD donors) are associated with a relatively high risk of biliary complications. Of all biliary complications, bile duct strictures and bile leakage are the most common after liver transplantation. While bile leakage and anastomotic bile duct strictures can usually be managed successfully without long-term sequelae, non-anastomotic biliary strictures are the most troublesome type of biliary complication. NAS are often multifocal and can be difficult to treat. When associated with recurrent cholangitis, jaundice or even secondary biliary fibrosis, retransplantation may be the only treatment option left.

The subsequent **chapter 3** focuses on the pathogenesis of NAS, including the lacunae in our current knowledge and potential targets to reduce NAS. Not all cases of NAS are equal; the timing, localization and severity of strictures varies between patients. Differences in the pathogenesis of NAS are thought to, at least partly, explain these variations in presentation. Although NAS occurring early after OLT are largely associated with an ischemia-related pathogenesis, NAS occurring late after OLT are believed to have a more immune-mediated origin. Endogenous bile salts may play an additional role in the pathogenesis of bile duct injury after OLT. Hydrophobic bile salts have a direct cytotoxic effect on the cholangiocytes, and this may contribute to the post-ischemic injury of the biliary epithelium. Donor surgeons can help prevent NAS by reducing warm and cold ischemia time as much as possible, providing adequate flush out of the liver, the peribiliary plexus, and the bile ducts. Recipient (transplant) surgeons can help reducing the incidence of NAS by keeping the cold ischemia time as short as possible and by performing arterial back-table pressure perfusion of the liver graft to ensure adequate perfusion of the

peribiliary capillary plexus. More studies are needed to provide better insight in the immune-mediated mechanisms of NAS that occur late after OLT. Recent advancements in normothermic and hypothermic machine perfusion could potentially have an important impact on the incidence of NAS through a reduction of preservation injury of the bile ducts and the peribiliary capillary plexus of liver grafts.

### **Part B: Immune and Ischemia-mediated Etiologies of Bile Duct Injury**

In **chapter 4** we provide evidence that the immune system plays a critical role in the development of NAS after OLT. A loss-of-function mutation in the chemokine receptor CCR5 (CCR5- $\Delta$ 32) leads to changes in the immune system, including impaired chemotaxis of regulatory T-cells. Patients with CCR5- $\Delta$ 32 had a 4-fold higher risk of developing NAS, compared with CCR5 Wt recipients. This risk was even higher in CCR5- $\Delta$ 32 carrying patients transplanted for PSC. In addition, retransplantation for NAS was seen more frequently in patients with CCR5- $\Delta$ 32 and more late development of NAS occurred in patients with CCR5- $\Delta$ 32. These data suggest that the immune system of the recipient plays a critical role in development of NAS, especially late (> 2 years) after liver transplantation, and warrant further experimental studies to unravel the mechanism through which CCR5 is involved in the development of bile duct injury.

In **chapter 5** we discuss the changing perspective on the pathogenesis of NAS after liver transplantation. For decades it was assumed that only few biliary epithelial cells are damaged or lost during cold preservation, and that most of the biliary injury occurs after transplantation due to reperfusion injury, immunological causes and hydrophobic bile salt toxicity. Two recently published studies provided new perspective from which to view biliary injury and the development of strictures after transplantation. In both studies major bile duct epithelial loss was observed in more than 85% of the common bile duct biopsies collected at the end of static cold storage (SCS). If loss of the biliary epithelium and injury of the bile duct wall is so universally present in human donor livers, yet only a minority develops biliary strictures after transplantation, this gives rise to the important new question as to 'Why does regeneration of biliary epithelium fail in certain livers and how can we stimulate the regenerative capacity of the biliary epithelium after OLT?' It is conceivable that biliary epithelium of the extrahepatic bile duct has an endogenous regenerative capacity, which may be impaired when NAS develops after liver transplantation.

The aim of **chapter 6** was to identify possible site(s) where epithelial regeneration may be initiated in the human extrahepatic bile duct and to study the possible role of local progenitor cells in this process. We examined tissue specimens from normal and diseased human extrahepatic bile duct varying from mild cellular injury (as in cholangitis/cholecystitis) to severe epithelial injury with cholangiocyte loss, as can be seen in NAS after orthotopic liver transplantation. Mild injury of the biliary epithelial layer was accompanied with increased cellular proliferation at the luminal surface, whereas severe injury was associated with increased cell replication in the peribiliary glands. Moreover, the peribiliary glands of large bile ducts were identified as a local niche

of biliary progenitor cells that contribute to regeneration of the biliary epithelial lining after major injury. Collectively, these data suggest that minor biliary epithelial injury and loss can be compensated for by proliferation of mature biliary epithelial cells, and major injury requires the mobilization and proliferation of biliary progenitor cells in the peribiliary glands.

In **chapter 7** we examined biopsies taken during 140 liver transplant procedures, from the distal end of the extrahepatic bile duct. Slides were examined by light microscopy, using a systematic injury grading system. This study demonstrates a high incidence of preservation injury of the extrahepatic bile ducts of donor livers after cold storage. We identified injury of the peribiliary glands and the vascular plexus as significant risk factors for the development of biliary strictures after liver transplantation. These findings support our hypothesis that preservation of the peribiliary glands and vascular plexus is critical in the timely regeneration of the biliary epithelial lining and bile duct wall stroma after liver transplantation. Apparently, the current preservation method used in organ transplantation, which is based on flush-out, cooling and static cold storage, is insufficient to maintain bile duct viability. It has become clear that we need better and probably more sophisticated preservation techniques to protect this delicate part of the liver graft. An attractive alternative preservation method is machine perfusion. Machine perfusion may not only reduce the incidence of biliary complications by lowering the amount of biliary injury prior to transplantation, but also by providing better protection of the peribiliary glands and vascular plexus. This, therefore, has been the focus of the third part of this thesis.

### **Part C: Machine Perfusion: A Potential Strategy to Prevent Bile Duct Injury**

During machine preservation livers are perfused with an oxygenated or non-oxygenated perfusion fluid at either low temperature or normal body temperature (1-5). Thus far, most investigations have focused on hypothermic machine perfusion (HMP; 0-4°C) and studies have suggested that HMP results in better preservation of the liver parenchyma, compared to the classical method of organ preservation, SCS (3-5). However, it is unknown whether hypothermic oxygenated machine perfusion results in better preservation of biliary epithelium and the peribiliary vasculature. In **chapter 8** we compared oxygenated HMP and SCS in an established DCD model of liver donation in pigs. After preservation with either HMP or SCS, liver grafts were *ex vivo* reperfused with autologous whole blood, as a model to simulate transplantation. After reperfusion, arterial flow was higher in the HMP group, and histological examination of bile ducts revealed significantly less arteriolonecrosis of the peribiliary vascular plexus compared to SCS preserved livers. Although we did not observe differences in the degree of biliary epithelial cell loss or bile duct stroma necrosis between livers preserved by HMP or SCS, the combination of better preservation of the peribiliary plexus and higher arterial flow may contribute to a faster recovery of the post ischemic bile ducts. Whether this results in a reduction of the rate of biliary complications after transplantation of DCD livers should be answered in clinical trials.



Alternatively, livers can be perfused at a higher temperature; such as normothermic (37°C) or subnormothermic (below 37°C; usually 21°C). An important advantage of normothermic machine perfusion (NMP) over conventional SCS is the delivery of oxygen and nutrients at 37°C, providing full metabolic support. NMP offers the potential to protect the bile ducts from injury caused by the cold ischemia during SCS, and might allow pharmacological preconditioning as well as *ex vivo* testing of hepatic viability and function prior to transplantation. In **chapter 9** we studied the impact of NMP on bile duct preservation in both DCD and non-DCD rat livers. Livers were preserved for 3h using either SCS or NMP, followed by 2h *ex-vivo* reperfusion. Compared with conventional SCS, NMP provided superior preservation of bile duct epithelial cell function and morphology. This beneficial effect of NMP was most pronounced in DCD livers. By reducing biliary injury, NMP could have an important impact on the utilization of DCD livers and may improve outcome after transplantation. These findings provide a strong stimulus for a clinical trial of NMP in human DCD liver transplantation.

Successful normothermic perfusion of livers has been reported only in animal models (6-10). In **chapter 10** we demonstrate that normothermic machine perfusion of human donor livers is technically feasible. Four discarded human livers were perfused successfully *ex vivo* at 37°C for 6 hours. Oxygenated, normothermic machine perfusion consisted of pressure and temperature controlled pulsatile perfusion of the hepatic artery and continuous portal perfusion. Biochemical markers in the perfusion fluid reflected minimal hepatic injury and improving function during perfusion. Lactate levels decreased to normal values, reflecting active metabolism by the liver. Bile production was observed throughout the 6 h perfusion period (mean rate  $8.16 \pm 0.65$  g/h after the first hour). Histological examination before and after 6 h of perfusion showed well-preserved liver morphology without signs of additional hepatocellular ischemia, biliary injury, or sinusoidal damage. This study is the first study to show that NMP is of human livers technically feasible.

One of the advantages of NMP is the *ex vivo* testing of suboptimal liver grafts that, based on conventional clinical criteria, are considered not suitable for transplantation because of a too high early failure rate. In order to move forward to clinical use of machine perfusion for selecting transplantable organs, it is necessary to identify markers during machine perfusion that can predict adequate liver function after transplantation. In case of end-ischemic NMP, we should ideally be able to assess and predict liver quality within 1-3 hours of perfusion to allow time for selection and preparation of a patient from the waiting list for liver transplantation. In **chapter 11** we evaluated 12 discarded human livers for graft function at 6h of NMP. Six livers demonstrated excellent graft function at 6 h of NMP and 6 livers demonstrated clear signs of injury and nonfunction. Bile production at 2.5 h of NMP was identified as the only 100% discriminating predictor of graft function at 6 hours of NMP. From this study we concluded that normothermic perfusion of ECD livers allows assessment of graft viability prior to transplantation, which opens new avenues for donor organ selection, therapeutic interventions and preconditioning. This may

not only improve organ quality and function, but will also lead to a considerable expansion of the number of organs available for transplantation.

### **Part D: Addendum**

DCD and other ECD donor grafts are increasingly used for transplantation, resulting in an increased risk of bile duct complications. At the time of organ offer for transplantation, donor-related risks such as disease transmission and graft failure are weighed against the patient's risk of remaining on the waiting list. The patient's role in decision-making and the timing and extent of donor-specific risk information has been discussed in the medical literature; however it has not been documented what patients themselves think of this. In **chapter 12** we describe the first study revealing the opinion of liver patients on these issues. Forty patients listed for liver transplantation and 179 transplanted liver patients participated in an anonymous questionnaire-based survey. The majority of respondents wished to be informed about donor-related risks and wanted to be involved with shared decision-making at the time of organ allocation. Implementing this knowledge and standardizing the content, the manner of transfer, and the amount of information we provide to our patients at the different time points along the transplant allocation process will be important to provide the same opportunities and care to every patient on the waiting list.

The rat liver perfusion system, used for our study in chapter 9, is described in detail in **chapter 13**. The system allows NMP in a pressure- and temperature controlled manner. Two artificial lungs provide oxygenation, the arterial flow is pulsatile and the portal flow continuous.

In **chapter 14**, the current chapter, the results of this thesis are summarized and discussed, followed by a section on future perspectives.

## **CONCLUSIONS AND FUTURE PERSPECTIVES**

The studies described in this thesis have resulted in a better understanding of the etiologies underlying bile duct injury and the subsequent formation of NAS after liver transplantation. Moreover, they have provided first evidence that machine preservation provides superior protection of the bile ducts of liver grafts, compared to conventional SCS.

### **The most important findings and conclusions of this thesis are:**

- 1) Injury of the biliary epithelial lining of the large bile ducts, characterized by detachment and loss of epithelial cells as well as reduced epithelial cell function, is almost universally present in donor livers prior to transplantation. However, this type of injury does not correlate with the development of NAS after transplantation. Nevertheless, this unexpected new finding has totally changed our view on the pathogenesis of NAS. If biliary injury is universally present, yet only a minority of livers grafts develop biliary strictures, this suggests that lack of

regeneration of bile duct epithelium, rather than the amount of injury determines whether a transplant will be complicated by biliary strictures or not.

- 2) Peribiliary glands are a niche of biliary progenitor cells and these glands play a critical role in regeneration of the bile duct epithelium after severe injury.
- 3) In addition to damage of the epithelial lining of bile duct lumen, injury of the peribiliary glands and peribiliary vasculature plexus can be found in some of the livers prior to transplantation. Injury to these components of the bile duct wall is strongly related to the development of NAS early after transplantation, supporting the novel concept of insufficient biliary regeneration as the main determinant of NAS.
- 4) Machine perfusion provides better preservation of the bile ducts of donor livers, compared to SCS. Injury to the peribiliary vasculature can be reduced by HMP (in a porcine model of DCD donation). Bile duct epithelial cell loss and dysfunction can be prevented by NMP (in a rat model of DCD donation).
- 5) NMP of human livers is technically feasible and this new technique may allow us to provide better protection of the bile ducts prior to transplantation. In addition, NMP provides a novel tool to improve the selection of donor livers for transplantation. Bile production during NMP is likely to be a good predictive parameter for *ex vivo* viability testing of ECD donor livers prior to transplantation.
- 6) In addition to biliary injury that occurs during cold preservation, immune mediated biliary injury may occur after transplantation and this plays a significant role in the development of NAS that occur late (>2 years) after transplantation.
- 7) Finally, we should reconsider the way we allow patients to be involved in the decision-making process when an ECD donor liver is offered for transplantation. Patients have a strong wish to participate in this complex process and we should develop protocols to inform them better.

Although the studies described in this thesis have provided important answers to the clinical questions that were raised at the start of this PhD research project, new challenges and questions have subsequently arisen. In this last paragraph of this thesis, I would like to spend a few words on the issues that have emerged and are still unanswered and to describe some of the new directions and opportunities for future research.

Concerning the etiology of NAS, we have demonstrated a significantly higher incidence of late NAS in recipients with CCR5- $\Delta$ 32 (chapter 4). This observation may be explained by an immunological imbalance caused by the lack of a functional CCR5 in these patients. CCR5 deficiency in humans, as well as in experimental animal models of inflammation and infection, is associated with significant increases of tissue levels of CCR5 ligand CCL5, which promotes enhanced influx of T-cells into tissues by binding to one of its alternative receptors, CCR1 (11-14). Moreover, the CCR5- $\Delta$ 32 mutation has been associated with impaired attraction of regulatory T cells to the site of tissue injury (15-17). Regulatory T-cells reduce inflammation and suppress

activation of potentially harmful, self-reactive lymphocytes. The strong association between CCR5-Δ32 and late NAS observed in the study described in chapter 4 could therefore possibly be explained by an increased inflammatory response of the host towards the biliary epithelium of the liver graft and a lack of regulatory T cells at the place of injury. However, this clinical, observational study did not allow us to define the underlying mechanisms as to why CCR5-Δ32 leads to the development of biliary strictures. Better understanding of the mechanisms underlying this clinical observation could be derived from an experimental animal study. One option would be to study bile duct injury and proliferation after bile duct ligation in CCR5 knockout mice. Influx of immune cells into the liver in response to bile duct injury caused by bile duct ligation could be quantified by flowcytometry and immunohistochemistry. Recognizing the difference in immune response between CCR5 wildtype and knockout mice would create a greater understanding of the pathophysiology of (late) NAS and therefore bring us closer to potential therapeutic strategies for this subtype of NAS.

Concerning the prevention of NAS, it has become evident that the current clinical practice of a single flush out and cooling of donor livers, followed by static cold storage is not sufficient to protect and preserve the bile ducts prior to transplantation. Machine perfusion of donor livers is an attractive alternative to SCS, as it provides a promising new strategy to prevent bile duct injury. The technical advances made in this field, in combination with the increasing shortage of donor livers, provide an exciting new avenue of research opportunities and clinical challenges. After a time period of more than 40 years in which static cold preservation and storage of donor organs has been the gold standard in clinical transplantation, we may see a great change in clinical practice with the introduction of machine perfusion. Although the animal models and the studies using human donor livers described in this thesis have demonstrated the technical feasibility of machine perfusion systems, as well as their protective effects on bile ducts, several questions remain unanswered.

To answer these new questions, future studies should focus on the following aspects and questions:

- 1) **What is the optimal temperature** for bile duct preservation during machine perfusion? It is unclear whether 37°C is the optimal temperature or whether perfusion at lower temperatures (e.g. between 4-10 °C or at room temperature) is equally effective, yet cheaper and possibly safer.
- 2) As long as the surgical technique of a multi-organ donation procedure is not changed, organs will be flushed out initially with cold preservation fluid. If organs are subsequently preserved by machine perfusion, **what is the best strategy to increase the temperature?** Should this be done gradually and if so, at what speed?
- 3) **When and how long should machine perfusion best be used?** Should static cold preservation completely be replaced by machine perfusion, or is it sufficient to combine SCS

with a period of machine perfusion? If so, should machine perfusion be performed before SCS (immediately after organ retrieval in the donor hospital) or at the end of SCS upon arrival at the transplant center?

- 4) **Can we improve the quality** of donor livers and their bile ducts by using machine perfusion prior to transplantation? Preconditioning could focus on the stimulation of natural defense mechanisms or the enhancement of endogenous repair processes. Alternatively, machine perfusion could enable us to improve the quality of a donor liver by reducing a preexisting pathological condition, such as steatosis.
- 5) Another important question that needs to be addressed is: **What is the best type of perfusion fluid?**
- 6) Finally, future research should aim to identify specific biomarkers or to develop molecular imaging tools that allow adequate **assessment of bile duct viability** prior to transplantation.

### **Ad 1 – The optimal temperature**

During machine preservation livers can be perfused with an oxygenated or non-oxygenated perfusion fluid at either low temperature or normal body temperature (2-4,18,19). A relatively simple and safe option is hypothermic machine perfusion (0-4°C), which allows the removal of waste products while perfusing with a preservation solution and at a temperature similar to the conventional SCS. The first clinical study on machine perfusion of human livers was performed by Guarrera *et al.*, using HMP without oxygenation (1). Although a reduction in delayed graft function was demonstrated in this study, long-term benefits have not been described. Recent studies in animal models have demonstrated the beneficial effects of oxygenation during cold machine perfusion, resulting in improved protection of mitochondrial function, lower markers of hepatocellular injury and stress, and enhanced functional recovery after reperfusion (19,20). Moreover, in chapter 8 of this thesis we have demonstrated improved preservation of the peribiliary vascular plexus in oxygenated HMP preserved porcine livers. However, it remains unknown to which extent the peribiliary glands are preserved during oxygenated HMP, and whether this in combination with better preservation of the peribiliary vasculature also results in a reduction of biliary strictures after transplantation of human livers. The answer to this question should come from a clinical study and the time has come to initiate a randomized clinical trial comparing SCS with oxygenated HMP in liver transplantation. Based on the high incidence of NAS after DCD liver transplantation, such a trial should best be performed in DCD livers grafts.

### **Ad 2 – The best strategy to increase temperature**

An alternative to choosing one temperature for perfusion is to combine different temperatures in a protocol that covers transport, assessment and preconditioning of the liver. In a recent study by Minor *et al.* 90 minutes of controlled oxygenated rewarming by machine perfusion up to 20°C significantly reduced cellular enzyme loss and more bile production, when compared to

90 minutes of SCS or subnormothermic machine perfusion (21). More research in this area will be needed to define the best clinical protocol.

### **Ad 3 – Timing and duration of machine perfusion**

Machine perfusion can be used to replace cold storage entirely or in combination with a period of cold storage. A strategy to replace cold storage entirely is followed by the group of Friend in Oxford, UK, using NMP. This method may be most successful, but also requires exceptional organizational planning and carries a higher risk of failure. Accidental disconnection of a liver from the perfusion device at 37°C poses great risk to the graft as it immediately results in deleterious warm ischemia. Safer and possibly still effective may be a short period of oxygenated hypothermic perfusion either before or after conventional cold storage during transportation. While the latter option is actively investigated by the group of Dutkowski in Zurich, Switzerland (19,22), a Japanese group recently presented very promising preliminary results of a short period of oxygenated normothermic perfusion before SCS in an animal model of DCD liver transplantation (23). Which option is most effective and the safest in clinical practice will be investigated in clinical trials in the coming years.

### **Ad 4 – Improving donor organ quality**

In contrast to HMP, NMP enables restoration of normal physiology and metabolic function. This creates a unique opportunity to improve organ quality and biliary integrity by activation of endogenous or exogenous repair mechanisms. Potentially interesting topics that deserve further exploration are, for example, the addition of mesenchymal stem cells (24) or growth factors (25) to the perfusion fluid. Especially humoral factors that have been identified to stimulate proliferation of biliary epithelial cells, such as vascular endothelial growth factor, glucagon-like peptide-1, insulin-like growth factor-1 are interesting targets during NMP (25). Alternatively, it is worthwhile to explore the potentially protective effects of *ex vivo* stimulation of bicarbonate secretion by biliary epithelial cells, as this has been described as a critical endogenous protection mechanism of biliary epithelial cells against bile salt mediated toxicity and cell death (26). Finally, NMP could be used to improve bile duct preservation and function by the addition of cytoprotective, anti-inflammatory and antifibrotic hydrophilic bile salts or their derivatives, such as tauroursodeoxycholic acid, nor-ursodesoxycholic acid, or 6alpha-ethyl-chenodeoxycholic acid (27-29)

### **Ad 5 – The best perfusion fluid**

In our NMP experiments (chapter 9-11) we used a perfusion fluid that would mimic physiology, with exception of the potentially harmful leukocytes and thrombocytes, based on human blood products such as red blood cells (RBC), fresh frozen plasma (FFP) and albumin. Since blood products are sparse and rely on donation, it is worthwhile to evaluate artificial oxygen carriers

and plasma replacements as alternative components of a perfusion fluid. Moreover, protocols involving machine perfusion at different temperatures will require an alternative to RBCs, since they lose their flexibility and oxygen-binding capacity at lower temperatures.

#### **Ad 6 – Bile duct viability assessment *ex vivo***

Although we have shown the ability to assess viability of the hepatic parenchyma during *ex vivo* machine perfusion (chapter 10 and 11), we have not yet been able to assess bile duct viability other than by taking biopsies from the distal end of the common bile duct (chapter 7). In the experiments focusing on NMP of human donor livers, we have used biliary secretion of bicarbonate as a biomarker of biliary epithelial function. Biliary epithelial cells contribute significantly to bile volume and flow by active secretion of bicarbonate and we have observed a recovery of biliary bicarbonate secretion during machine perfusion. The amount of bicarbonate secretion in the bile, however, is the result of all biliary epithelial cells present in the intra- and extrahepatic bile ducts and it does not necessarily reflect function of the epithelium of the larger bile ducts, which are most prone for the development of strictures after transplantation. Therefore, we need to identify better biomarkers of biliary epithelial cell injury and function. The group of van der Laan in Rotterdam has recently identified miRNA's as an attractive new biomarker for hepatobiliary injury (30). It needs to be demonstrated whether measurement of biliary epithelial cell specific miRNA's in bile can be used as a marker to predict bile duct viability during NMP. Alternatively, an attractive option could be the development of molecular imaging techniques using near-infrared fluorescence that allow a non-invasive assessment of the biliary epithelium. If such molecular imaging techniques are combined with visible light cholangioscopy this could provide an intraoperative tool for surgeons to judge viability of the biliary tree prior to transplantation (31).

In summary, the studies described in this thesis have contributed significantly to a better understanding of the etiologies underlying biliary injury during and after liver transplantation. Moreover, they have provided the first evidence that machine preservation is a feasible and very attractive alternative to static cold storage of donor livers prior to transplantation. Machine perfusion was shown to provide better protection of the bile ducts of liver grafts, compared to conventional SCS. It is expected that this novel technique will change the surgical practice of liver transplantation. It is my hope and expectation that machine perfusion of donor livers may not only reduce the amount of biliary complications after transplantation, but will also increase the number of organs that are suitable for transplantation, providing a greater chance for patients suffering from end-stage acute or chronic liver disease to receive this life-saving therapy.



**REFERENCES**

- (1) Guarrera JV, Henry SD, Samstein B, Odeh-Ramadan R, Kinkhabwala M, Goldstein MJ, et al. Hypothermic machine preservation in human liver transplantation: the first clinical series. *Am J Transplant* 2010;10:372-381.
- (2) Op den Dries S, Karimian N, Sutton ME, Westerkamp AC, Nijsten MW, Gouw AS, et al. Ex vivo normothermic machine perfusion and viability testing of discarded human donor livers. *Am J Transplant* 2013;13:1327-1335.
- (3) Bae C, Henry SD, Guarrera JV. Is extracorporeal hypothermic machine perfusion of the liver better than the 'good old icebox'? *Curr Opin Organ Transplant* 2012;17:137-142.
- (4) Dutkowski P, de Rougemont O, Clavien PA. Machine perfusion for 'marginal' liver grafts. *Am J Transplant* 2008;8:917-924.
- (5) Schlegel A, Rougemont O, Graf R, Clavien PA, Dutkowski P. Protective mechanisms of end-ischemic cold machine perfusion in DCD liver grafts. *J Hepatol* 2013;58:278-286.
- (6) Vogel T, Brockmann JG, Friend PJ. Ex-vivo normothermic liver perfusion: an update. *Curr Opin Organ Transplant* 2010;15:167-172.
- (7) Brockmann J, Reddy S, Coussios C, Pigott D, Guirriero D, Hughes D, et al. Normothermic perfusion: a new paradigm for organ preservation. *Ann Surg* 2009;250:1-6.
- (8) St Peter SD, Imber CJ, Lopez I, Hughes D, Friend PJ. Extended preservation of non-heart-beating donor livers with normothermic machine perfusion. *Br J Surg* 2002;89:609-616.
- (9) Xu H, Berendsen T, Kim K, Soto-Gutierrez A, Bertheium F, Yarmush ML, et al. Excorporeal normothermic machine perfusion resuscitates pig DCD livers with extended warm ischemia. *J Surg Res* 2012;173:e83-88.
- (10) Schon MR, Kollmar O, Wolf S, Schrem H, Matthes M, Akkoc N, et al. Liver transplantation after organ preservation with normothermic extracorporeal perfusion. *Ann Surg* 2001;233:114-123.
- (11) Sharma S, Gurakar A, Jabbour N. Biliary strictures following liver transplantation: past, present and preventive strategies. *Liver Transpl* 2008;14:759-769.
- (12) Ajuebor MN, Wondimu Z, Hogaboam CM, Le T, Proudfoot AE, Swain MG. CCR5 deficiency drives enhanced natural killer cell trafficking to and activation within the liver in murine T cell-mediated hepatitis. *Am J Pathol* 2007;170:1975-1988.
- (13) Dawson TC, Beck MA, Kuziel WA, Henderson F, Maeda N. Contrasting effects of CCR5 and CCR2 deficiency in the pulmonary inflammatory response to influenza A virus. *Am J Pathol* 2000;156:1951-1959.
- (14) Carr DJ, Ash J, Lane TE, Kuziel WA. Abnormal immune response of CCR5-deficient mice to ocular infection with herpes simplex virus type 1. *J Gen Virol* 2006;87:489-499.
- (15) Dobaczewski M, Xia Y, Bujak M, Gonzalez-Quesada C, Frangogiannis NG. CCR5 signaling suppresses inflammation and reduces adverse remodeling of the infarcted heart, mediating recruitment of regulatory T cells. *Am J Pathol* 2010;176:2177-2187.

- (16) Nozaki T, Rosenblum JM, Schenk AD, Ishii D, Fairchild RL. CCR5 is required for regulation of alloreactive T-cell responses to single class II MHC-mismatched murine cardiac grafts. *Am J Transplant* 2009;9:2251-2261.
- (17) Wysocki CA, Jiang Q, Panoskaltzis-Mortari A, Taylor PA, McKinnon KP, Su L, et al. Critical role for CCR5 in the function of donor CD4+CD25+ regulatory T cells during acute graft-versus-host disease. *Blood* 2005;106:3300-3307.
- (18) Guarrera JV, Henry SD, Samstein B, Odeh-Ramadan R, Kinkhabwala M, Goldstein MJ, et al. Hypothermic machine preservation in human liver transplantation: the first clinical series. *Am J Transplant* 2010;10:372-381.
- (19) Schlegel A, Rougemont O, Graf R, Clavien PA, Dutkowski P. Protective mechanisms of end-ischemic cold machine perfusion in DCD liver grafts. *J Hepatol* 2013;58:278-286.
- (20) Luer B, Koetting M, Efferz P, Minor T. Role of oxygen during hypothermic machine perfusion preservation of the liver. *Transpl Int* 2010;23:944-950.
- (21) Minor T, Efferz P, Fox M, Wohlschlaeger J, Luer B. Controlled oxygenated rewarming of cold stored liver grafts by thermally graduated machine perfusion prior to reperfusion. *Am J Transplant* 2013;13:1450-1460.
- (22) Schlegel A, Graf R, Clavien PA, Dutkowski P. Hypothermic oxygenated perfusion (HOPE) protects from biliary injury in a rodent model of DCD liver transplantation. *J Hepatol*. 2013.
- (23) Hara Y, Akamatsu Y, Maida K, Kashiwadate T, Kobayashi Y, Ohuchi N, et al. A new liver graft preparation method for uncontrolled non-heart-beating donors, combining short oxygenated warm perfusion and prostaglandin E1. *J Surg Res* 2013.
- (24) Van Raemdonck D, Neyrinck A, Rega F, Devos T, Pirenne J. Machine perfusion in organ transplantation: a tool for ex-vivo graft conditioning with mesenchymal stem cells? *Curr Opin Organ Transplant* 2013;18:24-33.
- (25) Glaser SS, Onori P, Wise C, Yang F, Marzioni M, Alvaro D, et al. Recent advances in the regulation of cholangiocyte proliferation and function during extrahepatic cholestasis. *Dig Liver Dis* 2010;42:245-252.
- (26) Beuers U, Hohenester S, de Buy Wenniger LJ, Kremer AE, Jansen PL, Elferink RP. The biliary HCO<sub>3</sub>(-)-umbrella: a unifying hypothesis on pathogenetic and therapeutic aspects of fibrosing cholangiopathies. *Hepatology* 2010;52:1489-1496.
- (27) Falasca L, Tisone G, Palmieri G, Anselmo A, Di Paolo D, Baiocchi L, et al. Protective role of tauroursodeoxycholate during harvesting and cold storage of human liver: a pilot study in transplant recipients. *Transplantation* 2001;71:1268-1276.
- (28) Demetris AJ, Lunz JG, 3rd, Specht S, Nozaki I. Biliary wound healing, ductular reactions, and IL-6/gp130 signaling in the development of liver disease. *World J Gastroenterol* 2006;12:3512-3522.
- (29) Marzioni M, Saccomanno S, Candelaresi C, Rychlicki C, Agostinelli L, Trozzi L, et al. Clinical implications of novel aspects of biliary pathophysiology. *Dig Liver Dis* 2010;42:238-244.

- (30) Farid WR, Pan Q, van der Meer AJ, de Ruiter PE, Ramakrishnaiah V, de Jonge J, et al. Hepatocyte-derived microRNAs as serum biomarkers of hepatic injury and rejection after liver transplantation. *Liver Transpl* 2012;18:290-297.
- (31) Moon JH, Terheggen G, Choi HJ, Neuhaus H. Peroral cholangioscopy: diagnostic and therapeutic applications. *Gastroenterology* 2013;144:276-282.

## Nederlandse samenvatting

Het ontstaan van non-anastomotische galwegstricturen (NAS) is een veel voorkomend en moeilijk behandelbaar probleem na levertransplantatie. Kenmerkend voor deze complicatie is het ontstaan van vernauwingen (stricturen) van de galwegen in of vaker net buiten de lever (extrahepatisch). De doelstelling van dit proefschrift is om de onderliggende etiologie (oorzaken) van NAS beter te begrijpen en aan de hand hiervan de potentieel beschermende rol van machineperfusie in het voorkomen van galwegschaade te onderzoeken. Daarnaast wordt beschreven hoe leverpatiënten geïnformeerd willen worden en betrokken willen zijn bij het besluit om een donorlever te accepteren, indien deze lever een verhoogd risico heeft op galwegcomplicaties. In dit hoofdstuk worden de resultaten van dit proefschrift samengevat en besproken, gevolgd door een paragraaf met toekomstperspectieven.

### **Deel A: Omvang en oorzaken van galwegschaade tijdens levertransplantatie**

**Hoofdstuk 1** is een algemene inleiding tot dit proefschrift, inclusief de doelstellingen van ieder hoofdstuk. De pathogenese, het klinische beeld en de behandelmogelijkheden van verschillende types galwegcomplicaties die na levertransplantatie kunnen optreden, worden besproken in **hoofdstuk 2**. Samengevat zijn galwegcomplicaties een frequente oorzaak van ziekte na levertransplantatie. Het komt voor in 10-40% van de ontvangers, resulterend in een sterftepercentage van 8-15%. Zowel partiële levertransplantaten (zoals splitlivers en donorlivers afkomstig van levende donoren) als levers van zogenaamde 'extended criteria donoren' (ECD), in het bijzonder de 'donation after cardiac death' (DCD) donoren, zijn geassocieerd met een relatief groot risico op galwegcomplicaties. Van alle galwegcomplicaties zijn galwegstricturen en gallekkage de meest voorkomende complicaties na levertransplantatie. Hoewel gallekkage en een strictuur van de anastomose gewoonlijk succesvol behandeld kunnen worden, is dit bij non-anastomotische galwegstricturen helaas niet het geval. NAS zit vaak op meerdere plekken tegelijk, is erg therapie-resistent en meestal is re-transplantatie de enige effectieve behandeling. In **hoofdstuk 3** wordt de pathogenese van NAS beschreven, inclusief de lacunes in onze huidige kennis en de potentiële aangrijpingspunten om NAS te kunnen voorkomen of verminderen. Niet iedere manifestatie van NAS is identiek; de timing, de lokalisatie en de ernst van de galwegstricturen verschillen tussen patiënten. Gedacht wordt dat deze variaties in manifestatie (in elk geval deels) te verklaren zijn door verschillen in etiologie. Hoewel NAS vroeg na levertransplantatie grotendeels geassocieerd wordt met een ischemie-gerelateerde pathogenese, wordt NAS laat na levertransplantatie toegeschreven aan een immuun-gemedieerde oorzaak. Endogene galzouten spelen waarschijnlijk een additionele rol in de pathogenese van galwegschaade na levertransplantatie. Hydrofobe galzouten hebben een direct cytotoxisch effect op de cholangiocyten (galwegepitheelcellen) en dit kan bijdragen aan de post-ischemische

schade van het galwegepithel. Donorchirurgen kunnen NAS proberen te voorkomen door de warme en koude ischmietijden zo kort mogelijk te maken en daarbij de lever, de peribiliaire vasculaire plexus (de kleine bloedvaten die de galwegen van zuurstof voorzien) en de galwegen adequaat te doorspoelen met koude preservatievloeistof. Transplantatiechirurgen kunnen de incidentie van NAS proberen te verlagen door de koude ischmietijd zo kort mogelijk te houden en een arteriele back-table druk-perfusie van het transplantaat uit te voeren, zodat de peribiliaire vasculaire plexus adequaat wordt geperfuseerd. Meer studies zijn nodig om beter inzicht te leveren in de immuun-gemedieerde mechanismen van NAS die pas laat na OLT optreden. De recente ontwikkelingen in normotherme en hypotherme machineperfusie kunnen potentieel een belangrijke impact hebben op de incidentie van NAS door een reductie van preservatieschade van de galwegen en de peribiliaire vasculaire plexus van de donorlevers.

### **Deel B: Immun- en ischemiegerelateerde etiologieën van galwegscha**

In **hoofdstuk 4** tonen we aan dat het immuunsysteem een belangrijke rol speelt in de ontwikkeling van NAS na levertransplantatie. Een verlies-van-functie mutatie in de chemokine receptor CCR5 (CCR5- $\Delta$ 32) leidt tot veranderingen in het immuunsysteem, inclusief een gestoorde chemotaxis van regulatoire T-cellen. Leverpatiënten met CCR5- $\Delta$ 32 hebben, vergeleken CCR5 wildtype leverpatiënten, een viervoudig verhoogd risico op het ontwikkelen van NAS. Dit risico is nog hoger in CCR5- $\Delta$ 32 dragers die getransplanteerd werden voor de ziekte primaire scleroserende cholangitis (PSC). Daarnaast is er bij patiënten met CCR5- $\Delta$ 32 vaker sprake van re-transplantatie ten gevolge van NAS en treedt de ontwikkeling van NAS vaak laat op (>2 jaar na transplantatie). Deze resultaten suggereren dat het immuunsysteem van de ontvanger een belangrijke rol speelt in het ontwikkelen van NAS, in het bijzonder van de NAS die pas laat (>2 jaar) na transplantatie ontstaat. Experimentele studies zijn nodig om te ontrafelen op welke manier CCR5 exact betrokken is bij de ontwikkeling van galwegscha.

In **hoofdstuk 5** wordt een nieuwe visie op de pathogenese van NAS besproken. Jarenlang werd er verondersteld dat slechts enkele galwegepithelcellen beschadigd raken of verloren gaan tijdens de koude preservatietijd, en dat de meeste galwegscha ontstaat na levertransplantatie als gevolg van reperfusiescha, immunologische oorzaken en hydrofobe galzouttoxiciteit. Twee recent gepubliceerde studies wierpen nieuw licht op het ontstaan van galwegscha en het ontwikkelen van galwegstricturen na transplantatie. In beide studies werd uitgebreide galwegepithelscha gezien in meer dan 85% van de extrahepatische galwegbiopten die verzameld waren aan het einde van de koude preservatietijd. Blijkbaar is verlies van galwegepithel zeer frequent aanwezig in humane donorlevers, maar slechts een minderheid ontwikkelt galwegstricturen na levertransplantatie. Deze bevinding leidt tot de belangrijke vraag 'Waarom faalt de regeneratie van het galwegepithel in sommige levers, en hoe kunnen we de regeneratieve capaciteit van het galwegepithel na lever transplantatie stimuleren?' Het is

denkbaar dat het galwegepitheel van de extrahepatische galweg een endogene regeneratieve capaciteit heeft, welke afwijkend is in de levers die NAS ontwikkelen na levertransplantatie.

Het doel van **hoofdstuk 6** is tweeledig. Het eerste doel is het identificeren van mogelijke locaties rondom de humane extrahepatische galweg waar regeneratie van het galwegepitheel wordt geïnitieerd. Het tweede doel is het bestuderen van de mogelijke rol van lokale voorlopercellen (progenitorcellen) in dit regeneratieproces. Weefsel van gezonde en zieke humane extrahepatische galwegen werd bestudeerd, variërend van milde schade (zoals bij cholangitis/cholecystitis) tot ernstige schade met verlies van galwegepitheel, zoals wordt gezien bij NAS na levertransplantatie. Milde schade van het galwegepitheel ging gepaard met een verhoogde cellulaire proliferatie aan de luminale zijde van de galweg, terwijl ernstige schade geassocieerd was met een verhoogde celdeling in de peribiliaire klieren. Daarnaast werden de peribiliaire klieren van de grote galwegen geïdentificeerd als een lokale nis voor biliaire progenitorcellen. Deze data suggereert dat milde schade aan het galwegepitheel hersteld kan worden door proliferatie van volgroeide galwegepitheelcellen in het lumen. Ernstige galwegschaade daarentegen, vereist proliferatie en mobilisatie van biliaire progenitorcellen vanuit de biliaire klieren.

In **hoofdstuk 7** onderzochten we galwegbiopten van het distale uiteinde van de extrahepatische galweg, afkomstig van 140 transplantatieprocedures. De biopten werden lichtmicroscopisch bestudeerd aan de hand van een systematisch scoringsstelsel. Deze studie demonstreert een hoge incidentie van galwegschaade van de extrahepatische galwegen van donorlevers na koude preservatie. We identificeerden schade aan de peribiliaire klieren en de peribiliaire vasculaire plexus als significante risicofactoren voor het ontwikkelen van NAS na levertransplantatie. Deze bevindingen ondersteunen onze hypothese dat preservatie van de peribiliaire klieren en vasculaire plexus van de extrahepatische galwegen cruciaal is voor tijdige regeneratie van het galwegepitheel en de galwegwand na levertransplantatie. Blijkbaar geeft de huidige preservatiemethode van donororganen, welke gebaseerd is op doorspoelen, koelen en koud conserveren, onvoldoende bescherming om de levensvatbaarheid van het galwegepitheel te behouden. Het is duidelijk geworden dat we betere en waarschijnlijk meer geavanceerde preservatiemethoden nodig hebben om dit kwetsbare onderdeel van de donorlever te kunnen beschermen. Een aantrekkelijke alternatieve preservatiemethode is machineperfusie. Deze techniek biedt de mogelijkheid om niet alleen de hoeveelheid galwegschaade vóór levertransplantatie te verminderen, maar ook een betere bescherming te bieden van de peribiliaire klieren en peribiliaire vasculaire plexus. Om deze reden staat machineperfusie centraal in het derde deel van dit proefschrift.

### **Deel C: Machineperfusie: Een potentiële strategie om galwegschaade te voorkomen**

Tijdens machineperfusie worden donorlevers doorspoeld (geperfuseerd) met een geoxygeneerde of niet-geoxygeneerde perfusievloeistof bij lichaamstemperatuur of kouder (1-5). Tot nu toe hebben de meeste studies zich geconcentreerd op hypotherme machineperfusie (HMP; 0-4°C) en onderzoek heeft uitgewezen dat HMP resulteert in een betere preservatie van het

leverparenchym, vergeleken met de klassieke methode van orgaanpreservatie 'static cold storage' (SCS) (3-5). Echter, het is onbekend of hypotherme geoxygeneerde machineperfusie resulteert in een betere preservatie van het galwegepithel en de peribiliaire vasculaire plexus. In **hoofdstuk 8** vergeleken we geoxygeneerde HMP met SCS in varkenslevers afkomstig van een 'donation after cardiac death' (DCD) donatieprocedure. Om een transplantatie na te bootsen werden de levers, na preservatie met HMP of SCS, *ex vivo* met autoloog volbloed gereperfuseerd. Na reperfusie was de arteriële doorstroming beter in de HMP groep en histologisch onderzoek van de galwegen onthulde significant minder arteriolonecrose (afsterven van bloedvaten) in de peribiliaire vasculaire plexus vergeleken met SCS gepreserveerde levers. Hoewel er geen verschil werd gezien in de mate van galwegepithelverlies of galwegwandnecrose tussen de HMP en SCS gepreserveerde levers, draagt de combinatie van een gespaarde peribiliaire vasculaire plexus en een betere arteriële doorstroming daarentegen waarschijnlijk wel bij aan een sneller herstel van de post-ischemische galwegen. Of dit resulteert in een verminderde incidentie van galwegcomplicaties na transplantatie van NHB levers zal moeten blijken uit klinische studies.

Machineperfusie kan ook op een hogere temperatuur worden uitgevoerd; zoals normotherme (37°C) of subnormotherme (<37°C; meestal 21°C) machineperfusie. Een groot voordeel van normotherme machineperfusie (NMP) boven de klassieke SCS is de afgifte van zuurstof en voedingsstoffen op lichaamstemperatuur, waarbij de lever wordt voorzien van complete metabole ondersteuning. NMP heeft de potentie om galwegen te beschermen tegen schade veroorzaakt door koude ischemie tijdens SCS, daarnaast biedt het de potentiële mogelijkheid tot farmacologische preconditionering en het *ex vivo* testen van de leverfunctie vóór transplantatie. In **hoofdstuk 9** bestudeerden we de impact van NMP op galwegpreservatie in zowel DCD (donation after cardiac death) als non-DCD (donatie zonder voorafgaande circulatiestilstand) rattenlevers. Levers werden 3 uren gepreserveerd met SCS of NMP, gevolgd door 2 uren *ex vivo* reperfusie. Vergeleken met de klassieke SCS, resulteerde NMP in superieure preservatie van galwegepithel morfologie en -functie. Dit gunstige effect was met name uitgesproken in de DCD donorlevers. Door het verminderen van galwegschaade kan NMP een grote impact hebben op het gebruik van DCD donorlevers en zodoende de uitkomsten na transplantatie verbeteren. Deze bevindingen zijn een belangrijke stimulans om een klinische studie naar NMP in humane DCD levertransplantatie op te zetten.

Succesvolle NMP is tot op heden alleen gerapporteerd in levers afkomstig van proefdieren (6-10). In **hoofdstuk 10** demonstrenen we in een unieke studie dat ook NMP van humane levers technisch mogelijk is. Vier humane levers (afgekeurd voor transplantatie) werden 6 uur lang succesvol *ex vivo* geperfuseerd. De geoxygeneerde, normotherme machineperfusie bestond uit druk- en temperatuurgereguleerde pulserende doorbloeding van de arterie hepatica en een continue doorbloeding van de vena porta. De biochemie van de perfusievloeistof reflecteerde minimale leverschade en een verbetering in leverfunctie tijdens de 6 uur durende perfusieperiode. De levers waren metabool actief; lactaatwaarden daalden tot een normaal (fysiologisch) niveau en



een continue galproductie werd waargenomen tijdens de perfusieperiode (gemiddeld  $8.16 \pm 0.65$  g/h na het eerste uur). Histologisch onderzoek voor en na 6 uur NMP liet goed-gepreserveerde levermorfologie zien, zonder tekenen van extra hepatocellulaire ischemie, galwegschaade of sinusoidale schade. Deze studie was de allereerste studie waarin werd aangetoond dat NMP van humane levers technisch haalbaar is.

Één van de grote voordelen van NMP is de mogelijkheid tot het *ex vivo* testen van suboptimale donorlevers die, gebaseerd op de huidige klinische criteria, niet in aanmerking komen voor transplantatie (in verband met een te groot risico op vroeg transplantaatfalen). Om machineperfusie klinisch te kunnen gebruiken voor het selecteren van transplanteerbare organen, is het noodzakelijk dat er markers worden geïdentificeerd die tijdens machineperfusie adequaat de leverfunctie na transplantatie kunnen voorspellen. Wanneer NMP aan het einde van een periode van koude ischemie (SCS) wordt uitgevoerd, zou het idealiter mogelijk moeten zijn om de leverkwaliteit te onderzoeken en te voorspellen binnen 1-3 uur perfusietijd. Op deze manier zal er voldoende tijd overblijven voor het selecteren en voorbereiden van een ontvanger. In **hoofdstuk 11** hebben we 12 afgekeurde levers geëvalueerd voor transplantaatfunctie na 6 uur NMP. Zes levers vertoonden excellente leverfunctie en de andere zes levers lieten duidelijke tekenen van schade en disfunctie zien. Galproductie na 2,5 uur NMP werd in deze studie geïdentificeerd als de enige 100% discriminerende voorspeller van transplantaatfunctie na 6 uur NMP. Concluderend kan gezegd worden dat normotherme machineperfusie van 'extended criteria donor' (ECD) levers de mogelijkheid biedt om donorlevers te testen vóór transplantatie. Dit creëert nieuwe kansen voor donororgaan selectie, therapeutische interventies en preconditionering. Naast het verbeteren van donororgaan kwaliteit en functie kan dit leiden tot een uitbreiding van het aantal voor transplantatie beschikbare donororganen.

## Deel D: Addendum

'Donation after cardiac death' (DCD) en andere 'extended criteria donor' (ECD) donororganen worden steeds vaker gebruikt voor transplantatie, resulterend in een verhoogd risico op galwegcomplicaties. Ten tijde van het donoraanbod worden donorgelateerde risico's zoals ziekteoverdracht en transplantaatfalen afgewogen tegen het (overlijdens)risico van de patiënt indien hij/zij op de wachtlijst blijft staan. De rol van de patiënt in het beslissingsproces, het tijdstip waarop en de mate waarin informatie over donorspecifieke risico's zou moeten worden gegeven, wordt besproken in de medische literatuur. Echter de mening van de patiënten zelf is niet eerder gedocumenteerd. **Hoofdstuk 12** beschrijft een eerste onderzoek naar de mening van leverpatiënten met betrekking tot deze zaken. Veertig leverpatiënten op de wachtlijst voor transplantatie en 179 reeds getransplanteerde leverpatiënten namen deel aan een anonieme vragenlijststudie. De meerderheid van de deelnemers wenste geïnformeerd te worden over donorgelateerde risico's en daarnaast willen ze ook betrokken worden bij de besluitvorming ten tijde van het donoraanbod. Door het standaardiseren van de inhoud, de overdrachtswijze en

de hoeveelheid informatie die we onze patiënten geven op verschillende tijdstippen tijdens het transplantatie toekenningsproces, zouden we iedere patiënt op de wachtlijst dezelfde kansen en zorg kunnen bieden.

Het rattenleverperfusiesysteem dat we hebben gemaakt voor onze studie in hoofdstuk 9, beschrijven we in detail in **hoofdstuk 13**. Het is een druk- en temperatuurgereguleerd systeem dat geschikt is voor NMP van rattenlevers. Twee kunstmatige longen voorzien de perfusievloeistof van zuurstof, de arteriële doorbloeding van de lever is pulserend en de portale doorbloeding is continu. Dit rattenleverperfusiesysteem lijkt veel op het perfusiesysteem dat we gebruiken voor humane levers en was in staat om gezonde rattenlevers in ieder geval 5 uur lang in leven te houden.

In **hoofdstuk 14**, het huidige hoofdstuk, worden de resultaten van dit proefschrift samengevat en bediscussieerd, gevolgd door een paragraaf met toekomstperspectieven.

## CONCLUSIES EN TOEKOMSTPERSPECTIEF

De studies beschreven in dit proefschrift hebben geresulteerd in het beter begrijpen van de onderliggende etiologieën van galwegschade en het daaropvolgende ontstaan van NAS na levertransplantatie. Daarnaast wordt het eerste bewijs geleverd dat machinepreservatie, vergeleken met klassieke SCS preservatie, superieure bescherming van de galwegen van donorlevers geeft.

### **De belangrijkste bevindingen en conclusies van dit proefschrift:**

- 1) Schade aan het galwegepitheel van de grote galwegen, gekenmerkt door loslating en verlies van galwegepitheelcellen en verminderde galwegepitheelfunctie, komt vrijwel universeel voor in alle donorlevers voor transplantatie. Echter, dit type schade is niet geassocieerd met het ontwikkelen van NAS na transplantatie. Deze onverwachte bevinding heeft onze kijk op de pathogenese van NAS compleet veranderd. Dat galwegschade universeel aanwezig is, maar slechts een deel van de donorlevers galwegstricturen ontwikkelt, geeft aan dat niet zozeer de hoeveelheid schade maar juist de afwezigheid van regeneratie bepalend is voor het ontwikkelen van NAS.
- 2) De peribiliaire klieren zijn holtes (nissen) met galwegepitheelvoorlopercellen (progenitorcellen) die in contact staan met het lumen van grotere galwegen. Deze klieren spelen een belangrijke rol in de regeneratie van het galwegepitheel na ernstige schade.
- 3) Naast de schade aan het galwegepitheel, wordt ook schade in de peribiliaire klieren en de peribiliaire vasculaire plexus gevonden in een aantal levers na SCS en voor transplantatie. Schade aan deze componenten van de galwegwand is sterk geassocieerd met het ontwikkelen van NAS vroeg na transplantatie. Dit ondersteunt onze hypothese dat een onvermogen tot

regeneratie van het galwegepitheel de belangrijkste voorspeller is voor het ontwikkelen van NAS.

- 4) Vergeleken met de klassieke preservatiemethode SCS biedt machineperfusie een betere bescherming aan de galwegen van donorlevers. Schade aan de peribiliaire vasculaire plexus kan worden voorkomen door preservatie met hypotherme machineperfusie (HMP), zoals aangetoond in een model van NHB donorlevers afkomstig van varkens. Galwegeepitheelverlies en disfunctie kan worden voorkomen door normotherme machineperfusie (NMP), zoals gedemonstreerd in een rattenmodel van DCD donatie.
- 5) NMP van humane levers is technisch haalbaar en deze nieuwe techniek biedt de mogelijkheid om galwegen beter te beschermen tussen uitname en transplantatie. Daarnaast kan NMP worden gebruikt om geschikte donorlevers voor transplantatie te selecteren. Galproductie tijdens NMP lijkt een goede voorspellende parameter te zijn voor het *ex vivo* testen van ECD donor levers voor transplantatie.
- 6) Naast de galwegschaade die ontstaat tijdens de koude preservatieperiode, kan immunogemedieerde schade optreden na transplantatie, dit is een belangrijke oorzaak van NAS dat later (>2 jaar) na transplantatie ontstaat.
- 7) Ten slotte zouden we de manier waarop we patiënten betrekken bij het besluit om een ECD donorlever al dan niet te accepteren, moeten herzien. Patiënten willen graag betrokken worden bij dit ingewikkelde proces en we zouden protocollen moeten ontwikkelen om hen beter te informeren.

Hoewel er in dit proefschrift antwoorden zijn gegeven op een aantal belangrijke klinische vraagstellingen, zijn hieruit nieuwe vragen en uitdagingen ontstaan. In deze laatste paragraaf van dit proefschrift wijd ik graag een aantal woorden aan de vragen die zijn ontstaan of nog steeds onbeantwoord zijn, alsmede suggesties voor onderzoek in de (nabije) toekomst.

Met betrekking tot de etiologie van NAS hebben we gedemonstreerd dat late NAS veel vaker optreedt in ontvangers met CCR5- $\Delta$ 32 (hoofdstuk 4). Dit kan worden verklaard door een immunologische disbalans die veroorzaakt wordt door een tekort aan functioneel CCR5 in deze patiënten. CCR5 deficiëntie is zowel in mensen als in proefdiermodellen geassocieerd met significant grotere hoeveelheden CCR5 ligand CCL5 in weefsel waarin een ontstekingsproces gaande is. Doordat het CCL5 zich kan binden aan zowel CCR5 als een alternatieve receptor, CCR1, worden er bij CCR5 deficiëntie mogelijk meer T-cellen aangetrokken (11-14). Daarnaast is de CCR5- $\Delta$ 32 mutatie geassocieerd met verminderde influx van regulatoire T-cellen naar de plek van beschadiging (15-17). Regulatoire T-cellen spelen een immunomodulerende rol door het verminderen van ontsteking en het onderdrukken van potentieel schadelijke lymfocyten. De sterke associatie tussen CCR5- $\Delta$ 32 en late NAS zoals beschreven in de studie in hoofdstuk 4 kan dus mogelijk worden verklaard door een verhoogde immunorespons ten opzichte van het galwegepitheel van de donorlever en/of door een tekort aan regulatoire T-cellen op de

plek van beschadiging. Echter, de huidige klinische observatiestudie stelt ons niet in staat om uit te kunnen zoeken waarom CCR5-Δ32 tot het ontwikkelen van NAS leidt. Een beter begrip van de onderliggende mechanismen zou moeten worden verkregen in een dierexperimentele studie. Het bestuderen van galwegschaade en proliferatie na galwegligatie in CCR5 knock-out muizen zou hieraan kunnen bijdragen. De influx van immuuncellen in de lever als reactie op de galwegschaade veroorzaakt door galwegligatie kan worden gekwantificeerd door flowcytometrie en immunohistochemie. Het verschil in immuunrespons tussen CCR5 wildtype en CCR5 knock-out muizen kan leiden tot een beter begrip van de onderliggende pathofysiologie van (late) NAS en ons daarmee dichterbij een potentiële therapeutische strategie brengen voor dit subtype van NAS.

Met betrekking tot het voorkomen van NAS kunnen we stellen dat de huidige methode van eenmalig koud spoelen en koud bewaren van levers op ijs (SCS) onvoldoende bescherming van de galwegen biedt. Machineperfusie van donorlevers is een aantrekkelijk alternatief voor SCS, met potentie om galwegschaade te voorkomen. De technische vooruitgangen op dit gebied, in combinatie met het almaar groeiende donortekort, bieden ons nieuwe onderzoeksmogelijkheden en klinische uitdagingen. Na een periode van meer dan 40 jaar waarin koude preservatie op ijs (SCS) van donororganen de gouden standaard is geweest, zien we nu een mogelijke verandering in de klinische transplantatiepraktijk door de introductie van machineperfusie. Hoewel een aantal studies in dit proefschrift zowel de technische mogelijkheden als het beschermende effect van machineperfusie op de galwegen hebben gedemonstreerd, blijven verschillende vragen onbeantwoord.

Om deze nieuwe vragen te kunnen beantwoorden, zullen toekomstige studies zich moeten richten op de volgende aspecten:

- 1) **Wat is de optimale temperatuur** voor galwegpreservatie tijdens machineperfusie? Het is nog onduidelijk of 37°C de optimale temperatuur is, of dat perfusie op een lagere temperatuur (bijvoorbeeld tussen 4-10 °C of op kamertemperatuur) net zo effectief, maar goedkoper en wellicht veiliger is.
- 2) Zolang de chirurgische techniek en de protocollen van een multi-orgaan donatieprocedure niet verandert, worden alle organen in het donorlichaam doorspoeld met een koude preservatievloeistof, voordat de organen worden uitgenomen. Als organen na deze koude flush op een apparaat worden aangesloten voor normotherme machineperfusie, **wat is dan de beste strategie om de temperatuur te verhogen?** Het is nog onbekend of dit langzaam en/of stapsgewijs moet gebeuren en zo ja, hoe langzaam.
- 3) **Wanneer en voor hoe lang kunnen we machineperfusie het beste gebruiken?** Moet de standaard koude ischemie (SCS) geheel worden vervangen door machineperfusie, of is het voldoende om SCS te combineren met een periode van machineperfusie? In het tweede geval zou machineperfusie moeten plaatsvinden voor SCS (direct na uitname van

de donororganen in het donorziekenhuis) of aan het einde van de SCS bij aankomst in het transplantatiecentrum?

- 4) **Zijn we in staat de kwaliteit te verbeteren** van de donorlevers en de galwegen door het gebruik van machineperfusie voor transplantatie? Zijn we in staat om levers te preconditioneren door het stimuleren van natuurlijke verdedigingsmechanismen of het stimuleren van endogene reparatieprocessen? Anderzijds kan machineperfusie ons wellicht in staat stellen om de kwaliteit van een donorlever te verbeteren door het verminderen van een bestaande pathologische conditie, zoals steatose (leververvetting).
- 5) Een andere belangrijke vraag die behandeld moet worden is: **Wat is de beste soort perfusievloeistof?**
- 6) Ten slotte, toekomstig onderzoek zou zich moeten richten op het identificeren van specifieke biomarkers of het ontwikkelen van moleculaire imaging tools ter **beoordeling van de levensvatbaarheid van de galwegen** voor transplantatie.

#### **Ad 1 - De optimale temperatuur**

Tijdens machineperfusie kunnen levers worden geperfuseerd met een geoxygeneerde of niet-geoxygeneerde perfusievloeistof op verschillende temperaturen (2-4,18,19). Een relatief simpele en veilige optie is hypotherme machineperfusie (HMP; 0-4°C), waarbij het voordeel ten opzichte van SCS wordt behaald uit het verwijderen van afvalproducten tijdens het perfuseren. De eerste klinische studie naar machineperfusie van humane levers werd uitgevoerd door Guarrera *et al.*, gebruik makende van HMP zonder zuurstof (1). Hoewel in deze studie een vermindering in vertraagde transplantaatfunctie werd gedemonstreerd, zijn langetermijn voordelen niet beschreven. Recente studies in proefdiermodellen hebben de voordelige effecten van oxygenatie aangetoond tijdens HMP, resulterend in verbeterde bescherming van mitochondriële functie, minder hepatocellulaire schade en een verbeterd functioneel herstel na reperfusie (19,20). Daarnaast demonstrenen wij zelf in hoofdstuk 8 van dit proefschrift dat geoxygeneerde HMP van varkenslevers resulteert in verbeterde preservatie van de peribiliaire vasculaire plexus van de galwegen. Echter, het is onbekend of peribiliaire klieren beter bewaard blijven tijdens geoxygeneerde HMP, en of dit in combinatie met verbeterde preservatie van de peribiliaire vasculaire plexus ook resulteert in een vermindering van galwegstricturen na transplantatie van humane levers. Het antwoord op deze vraag zal moeten komen van een gerandomiseerde klinische studie. In een dergelijke studie kan SCS worden vergeleken met geoxygeneerde HMP, waarbij DCD donorlevers, gezien de hoge incidentie van NAS in deze levers, de meest geschikte onderzoeksgroep zullen zijn.

#### **Ad 2 – De beste strategie om de temperatuur te verhogen**

Een alternatief voor het kiezen van één temperatuur is het combineren van verschillende temperaturen in een protocol dat zowel het transport, het testen en het preconditioneren van

de lever omvat. In een recente studie door Minor *et al.* zorgde 90 minuten gecontroleerde geoxygeneerde opwarming tot 20°C door machineperfusie voor een significante reductie in verlies van leverenzymen en verbeterde galproductie, vergeleken met 90 minuten SCS of subnormotherme machineperfusie (21). Toekomstig onderzoek is nodig om te onderzoeken wat in dit geval het beste klinische protocol is.

### **Ad 3 – Tijdstip en duur van machineperfusie**

Machineperfusie kan de klassieke koude preservatie (SCS) geheel vervangen of in combinatie met SCS worden ingezet. De strategie om SCS geheel buiten spel te zetten wordt momenteel gevolgd door de onderzoeksgroep van Dr. Friend in Oxford, UK, gebruikmakende van NMP. Deze methode is potentieel het meest succesvol, maar het vereist uitzonderlijke organisatorische planning en het draagt een relatief hoog mislukingsrisico. Indien een lever tijdens NMP op 37°C per ongeluk ontkoppeld van het perfusieapparaat, dan resulteert dit onmiddellijk in warme ischemie wat een groot risico is voor het donororgaan. Een veiliger, maar mogelijk nog steeds effectief, alternatief is een korte periode van geoxygeneerde hypotherme machineperfusie (HMP) voor of na het transport waarin de klassieke SCS wordt gebruikt. De laatste optie wordt actief onderzocht door de groep van Dr. Dutkowski in Zurich, Zwitserland (19,22) en een Japanse groep presenteerde recent veelbelovende preliminaire resultaten van een korte periode geoxygeneerde NMP voorafgaande aan SCS in een rattenmodel van DCD levertransplantatie (23). Welke optie het meest effectief is en veilig genoeg voor klinische toepassing, zal worden onderzocht in klinische studies in de komende jaren.

### **Ad 4 – Kwaliteitsverbetering donorlevers**

In tegenstelling tot HMP, is NMP potentieel in staat om de normale fysiologie en metabole activiteit van de lever te herstellen. Dit creëert een unieke kans om zowel orgaankwaliteit als galwegintegriteit te verbeteren door activering van endogene of exogene reparatiemechanismen. Potentieel interessante onderwerpen die verder onderzocht dienen te worden zijn bijvoorbeeld het toevoegen van mesenchymale stamcellen (24) of groeifactoren (25) aan de perfusievloeistof. Met name humorale factoren die de proliferatie van galwegepitheelcellen kunnen stimuleren, zoals 'vascular endothelial growth factor', 'glucagon-like peptide-1' en 'insulin-like growth factor-1' zijn interessante toevoegingen tijdens NMP (25). Daarnaast is het de moeite waard om de potentieel beschermende effecten van *ex vivo* stimulatie van bicarbonaatexcretie door galwegepitheelcellen te bestuderen, aangezien dit is beschreven als een belangrijk endogeen beschermingsmechanisme van het galwegepitheel tegen galzout-gemedieerde toxiciteit en celdood (26). Tenslotte zou NMP gebruikt kunnen worden om galwegpreservatie en functie te verbeteren door het toevoegen van de beschermende, ontstekingsremmende en fibroseremmende hydrofiele galzouten of afgeleiden hiervan, zoals tauroursodeoxycholic acid, of 6alpha-ethyl-chenodeoxycholic acid (27-29).

**Ad 5 – De beste perfusievloeistof**

In onze eigen NMP experimenten (hoofdstuk 9-11) gebruiken we een perfusievloeistof die zoveel mogelijk op 'normaal' bloed lijkt, omdat we de fysiologische omgeving van de lever willen nabootsen. De belangrijkste componenten van deze perfusievloeistof zijn rode bloedcellen (RBC), 'fresh frozen plasma' (FFP) en albumine. Het grootste verschil met 'normaal' bloed is de afwezigheid van potentieel schadelijke leukocyten en thrombocyten, en de toevoeging van antibiotica. Omdat bloedproducten schaars zijn en afhankelijk zijn van donatie, is het verstandig om kunstmatige zuurstofdrager en plasmavervangers te evalueren als mogelijk alternatieve componenten van de perfusievloeistof. Daarnaast zal kunstmatige zuurstofdrager noodzakelijk zijn indien een machineperfusie protocol met verschillende temperaturen wordt gebruikt, RBC's verliezen namelijk hun flexibiliteit en zuurstofbindende capaciteit bij lagere temperaturen.

**Ad 6 – Beoordeling levensvatbaarheid galwegen *ex vivo***

Hoewel we lieten zien dat de levensvatbaarheid van de levercellen tijdens machineperfusie testbaar is (hoofdstuk 10 en 11), we hebben de levensvatbaarheid van de galwegen nog niet kunnen aantonen, afgezien van de biopten die we hebben genomen van de ductus choledochus van donorlevers in hoofdstuk 7. In onze NMP experimenten hebben we biliaire secretie van bicarbonaat gebruikt als biomarker van de galwegepithelfunctie. Galwegepithelcellen dragen significant bij aan het volume en de flow van de gal door actieve secretie van bicarbonaat. Tijdens de NMP van humane levers zagen we herstel van de bicarbonaatsecretie tijdens machineperfusie. De hoeveelheid bicarbonaatsecretie in de gal is echter het resultaat van alle galwegepithelcellen in de intra- en extrahepatische galwegen en reflecteert daardoor niet persé de functie van het galwegepithel in de grotere galwegen, welke het meest gevoelig zijn voor het ontwikkelen van stricturen na transplantatie. Om deze reden is het van belang om betere biomarkers van galwegepithelschade en –functie te identificeren. De onderzoeksgroep van Dr. Van der Laan in Rotterdam heeft recent miRNA's geïdentificeerd als een veelbelovende nieuwe biomarker voor hepatocellulaire schade (30). Of het meten van galwegs specifieke miRNA's in de gal gebruikt kan worden om de levensvatbaarheid van het galwegepithel tijdens NMP te voorspellen, zal moeten worden uitgewezen. Een alternatief is het ontwikkelen van moleculaire beeldvormingstechnieken met near-infrarood fluorescentie waarmee het galwegepithel non-invasief kan worden beoordeeld. Als dergelijke beeldvormingstechnieken gecombineerd worden met cholangioscopie, dan zou dit een intraoperatief hulpmiddel kunnen zijn om chirurgen het galwegepithel te laten beoordelen, voorafgaande aan de transplantatie (31).

Samengevat, de studies in dit proefschrift hebben significant bijgedragen aan een beter begrip van de onderliggende oorzaken van galwegschaade tijdens en na levertransplantatie. Machineperfusie blijkt een uitvoerbaar en veelbelovende alternatief te zijn voor de klassieke koude preservatie van donorlevers voor transplantatie. Er is aangetoond dat machineperfusie



de galwegen beter beschermd dan de klassieke koude preservatie. De verwachting is dat deze nieuwe techniek de dagelijkse praktijk van levertransplantatie zal veranderen. Ik hoop en verwacht dat machineperfusie van donorlevers niet alleen de hoeveelheid galwegcomplicaties na levertransplantatie zal verminderen, maar ook een toename in het aantal getransplanteerde levers teweeg zal brengen, waardoor leverpatiënten een grotere kans krijgen op deze levensreddende therapie.

## REFERENTIES

- (1) Guarrera JV, Henry SD, Samstein B, Odeh-Ramadan R, Kinkhabwala M, Goldstein MJ, et al. Hypothermic machine preservation in human liver transplantation: the first clinical series. *Am J Transplant* 2010;10:372-381.
- (2) Op den Dries S, Karimian N, Sutton ME, Westerkamp AC, Nijsten MW, Gouw AS, et al. Ex vivo normothermic machine perfusion and viability testing of discarded human donor livers. *Am J Transplant* 2013;13:1327-1335.
- (3) Bae C, Henry SD, Guarrera JV. Is extracorporeal hypothermic machine perfusion of the liver better than the 'good old icebox'? *Curr Opin Organ Transplant* 2012;17:137-142.
- (4) Dutkowski P, de Rougemont O, Clavien PA. Machine perfusion for 'marginal' liver grafts. *Am J Transplant* 2008;8:917-924.
- (5) Schlegel A, Rougemont O, Graf R, Clavien PA, Dutkowski P. Protective mechanisms of end-ischemic cold machine perfusion in DCD liver grafts. *J Hepatol* 2013;58:278-286.
- (6) Vogel T, Brockmann JG, Friend PJ. Ex-vivo normothermic liver perfusion: an update. *Curr Opin Organ Transplant* 2010;15:167-172.
- (7) Brockmann J, Reddy S, Coussios C, Pigott D, Guirriero D, Hughes D, et al. Normothermic perfusion: a new paradigm for organ preservation. *Ann Surg* 2009;250:1-6.
- (8) St Peter SD, Imber CJ, Lopez I, Hughes D, Friend PJ. Extended preservation of non-heart-beating donor livers with normothermic machine perfusion. *Br J Surg* 2002;89:609-616.
- (9) Xu H, Berendsen T, Kim K, Soto-Gutierrez A, Bertheim F, Yarmush ML, et al. Excorporeal normothermic machine perfusion resuscitates pig DCD livers with extended warm ischemia. *J Surg Res* 2012;173:e83-88.
- (10) Schon MR, Kollmar O, Wolf S, Schrem H, Matthes M, Akkoc N, et al. Liver transplantation after organ preservation with normothermic extracorporeal perfusion. *Ann Surg* 2001;233:114-123.
- (11) Sharma S, Gurakar A, Jabbour N. Biliary strictures following liver transplantation: past, present and preventive strategies. *Liver Transpl* 2008;14:759-769.
- (12) Ajuebor MN, Wondimu Z, Hogaboam CM, Le T, Proudfoot AE, Swain MG. CCR5 deficiency drives enhanced natural killer cell trafficking to and activation within the liver in murine T cell-mediated hepatitis. *Am J Pathol* 2007;170:1975-1988.

- (13) Dawson TC, Beck MA, Kuziel WA, Henderson F, Maeda N. Contrasting effects of CCR5 and CCR2 deficiency in the pulmonary inflammatory response to influenza A virus. *Am J Pathol* 2000;156:1951-1959.
- (14) Carr DJ, Ash J, Lane TE, Kuziel WA. Abnormal immune response of CCR5-deficient mice to ocular infection with herpes simplex virus type 1. *J Gen Virol* 2006;87:489-499.
- (15) Dobaczewski M, Xia Y, Bujak M, Gonzalez-Quesada C, Frangogiannis NG. CCR5 signaling suppresses inflammation and reduces adverse remodeling of the infarcted heart, mediating recruitment of regulatory T cells. *Am J Pathol* 2010;176:2177-2187.
- (16) Nozaki T, Rosenblum JM, Schenk AD, Ishii D, Fairchild RL. CCR5 is required for regulation of alloreactive T-cell responses to single class II MHC-mismatched murine cardiac grafts. *Am J Transplant* 2009;9:2251-2261.
- (17) Wysocki CA, Jiang Q, Panoskaltsis-Mortari A, Taylor PA, McKinnon KP, Su L, et al. Critical role for CCR5 in the function of donor CD4+CD25+ regulatory T cells during acute graft-versus-host disease. *Blood* 2005;106:3300-3307.
- (18) Guarrera JV, Henry SD, Samstein B, Odeh-Ramadan R, Kinkhabwala M, Goldstein MJ, et al. Hypothermic machine preservation in human liver transplantation: the first clinical series. *Am J Transplant* 2010;10:372-381.
- (19) Schlegel A, Rougemont O, Graf R, Clavien PA, Dutkowski P. Protective mechanisms of end-ischemic cold machine perfusion in DCD liver grafts. *J Hepatol* 2013;58:278-286.
- (20) Luer B, Koetting M, Efferz P, Minor T. Role of oxygen during hypothermic machine perfusion preservation of the liver. *Transpl Int* 2010;23:944-950.
- (21) Minor T, Efferz P, Fox M, Wohlschlaeger J, Luer B. Controlled oxygenated rewarming of cold stored liver grafts by thermally graduated machine perfusion prior to reperfusion. *Am J Transplant* 2013;13:1450-1460.
- (22) Schlegel A, Graf R, Clavien PA, Dutkowski P. Hypothermic oxygenated perfusion (HOPE) protects from biliary injury in a rodent model of DCD liver transplantation. *J Hepatol*. 2013.
- (23) Hara Y, Akamatsu Y, Maida K, Kashiwadate T, Kobayashi Y, Ohuchi N, et al. A new liver graft preparation method for uncontrolled non-heart-beating donors, combining short oxygenated warm perfusion and prostaglandin E1. *J Surg Res* 2013.
- (24) Van Raemdonck D, Neyrinck A, Rega F, Devos T, Pirenne J. Machine perfusion in organ transplantation: a tool for ex-vivo graft conditioning with mesenchymal stem cells? *Curr Opin Organ Transplant* 2013;18:24-33.
- (25) Glaser SS, Onori P, Wise C, Yang F, Marzioni M, Alvaro D, et al. Recent advances in the regulation of cholangiocyte proliferation and function during extrahepatic cholestasis. *Dig Liver Dis* 2010;42:245-252.
- (26) Beuers U, Hohenester S, de Buy Wenniger LJ, Kremer AE, Jansen PL, Elferink RP. The biliary HCO<sub>3</sub><sup>-</sup> umbrella: a unifying hypothesis on pathogenetic and therapeutic aspects of fibrosing cholangiopathies. *Hepatology* 2010;52:1489-1496.

- (27) Falasca L, Tisone G, Palmieri G, Anselmo A, Di Paolo D, Baiocchi L, et al. Protective role of tauroursodeoxycholate during harvesting and cold storage of human liver: a pilot study in transplant recipients. *Transplantation* 2001;71:1268-1276.
- (28) Demetris AJ, Lunz JG,3rd, Specht S, Nozaki I. Biliary wound healing, ductular reactions, and IL-6/gp130 signaling in the development of liver disease. *World J Gastroenterol* 2006;12:3512-3522.
- (29) Marzioni M, Saccomanno S, Candelaresi C, Rychlicki C, Agostinelli L, Trozzi L, et al. Clinical implications of novel aspects of biliary pathophysiology. *Dig Liver Dis* 2010;42:238-244.
- (30) Farid WR, Pan Q, van der Meer AJ, de Ruiter PE, Ramakrishnaiah V, de Jonge J, et al. Hepatocyte-derived microRNAs as serum biomarkers of hepatic injury and rejection after liver transplantation. *Liver Transpl* 2012;18:290-297.
- (31) Moon JH, Terheggen G, Choi HJ, Neuhaus H. Peroral cholangioscopy: diagnostic and therapeutic applications. *Gastroenterology* 2013;144:276-282.

## List of publications

**Op den Dries S**, Sutton ME, Lisman T, Porte RJ. Protection of bile ducts in liver transplantation: Looking beyond ischemia. *Transplantation* 2011;92:373-9.

**Op den Dries S**, Buis CI, Adelmeijer J, Van der Jagt EJ, Haagsma EB, Lisman T, Porte RJ. Combination of primary sclerosing cholangitis and CCR5-Δ32 in recipients is strongly associated with development of nonanastomotic biliary strictures after liver transplantation. *Liver Int* 2011;31:1102-9.

Ten Hove WG, Korkmaz KS, **op den Dries S**, de Rooij BJF, van Hoek B, Porte RJ, van der Reijden JJ, Coenraad MJ, Dubbeld J, Hommes DW, Verspaget HW. Matrix metalloproteinase 2 genotype is associated with non-anastomotic biliary strictures after orthotopic liver transplantation. *Liver Int* 2011;31:1110-7.

Sutton ME, **op den Dries S**, Koster MH, Lisman T, Gouw ASH, Porte RJ. Regeneration of human extrahepatic biliary epithelium: the role of progenitor cells. *Liver Int* 2012;32:554-9.

**Op den Dries S**, Verdonk RC, Porte RJ. Biliary complications following liver transplantation. In: Clavien PA, Trotter JF, editors. *Medical Care of the Liver Transplant Patient*. Wiley-Blackwell;2012, p. 319-331.

**Op den Dries S**, Karimian N, Sutton ME, Westerkamp AC, Nijsten MWN, Gouw ASH, Wiersema-Buist J, Lisman T, Leuvenink HGD, Porte RJ. Ex-vivo Normothermic Machine Perfusion and Viability Testing of Discarded Human Donor Livers. *Am J Transplant* 2013;13:1327-35.

Karimian N, **op den Dries S**, Porte RJ. The origin of biliary strictures after liver transplantation: Is it the amount of epithelial injury or insufficient regeneration that counts? *J Hepatol* 2013;58:1065-7.

**Op den Dries S**, Sutton ME, Karimian N, de Boer MT, Wiersema-Buist J, Gouw ASH, Leuvenink HGD, Lisman T, Porte RJ. Hypothermic oxygenated machine perfusion prevents arteriolonecrosis of the peribiliary plexus in pig livers donated after cardiac death. *Submitted for publication*.

**Op den Dries S**, Karimian N, Sutton ME, Kuipers M, Wiersema-Buist J, Ottens PJ, Kuipers J, Giepmans BN, Lisman T, Porte RJ. Normothermic Machine Perfusion Reduces Bile Duct Injury and Improves Biliary Epithelial Function in Rat Donor Livers. *Submitted for publication*.

**Op den Dries S**, Westerkamp AC, Karimian N, Gouw ASH, Markmann JF, Lisman T, Yeh H, Uygun K, Martins P, Porte RJ. Injury of the peribiliary glands and vascular plexus before liver transplantation predicts formation of non-anastomotic biliary strictures. *Submitted for publication.*

**Op den Dries S**, Annema C, van den Berg AP, Ranchor AV, Porte RJ. Shared Decision Making in Transplantation: How Patients See Their Role in The Decision Process of Accepting a Donor Liver. *Submitted for publication.*

**Op den Dries S**, Sutton ME (co-first author), Karimian N, de Boer MT, Wiersema-Buist J, Gouw ASH, Leuvenink HGD, Lisman T, Porte RJ. Criteria for viability assessment of discarded human livers during ex-vivo normothermic machine perfusion. *Submitted for publication.*

## List of contributing authors

Aad P van den Berg, MD, PhD  
Department of Gastroenterology and Hepatology  
University Medical Center Groningen  
University of Groningen  
The Netherlands

Adelita V Ranchor, PhD, Professor of Health Psychology  
Health Psychology Section  
Department of Health Sciences  
University Medical Center Groningen  
University of Groningen  
The Netherlands

Andrie C Westerkamp, MD  
Surgical Research Laboratory  
Department of Surgery  
University Medical Center Groningen  
University of Groningen  
The Netherlands

Annette SH Gouw, MD, PhD, Professor of Pathology  
Department of Pathology and Medical Biology  
University Medical Center Groningen  
University of Groningen  
The Netherlands

Ben NG Giepmans, PhD  
Department of Cell Biology  
University Medical Center Groningen  
University of Groningen  
The Netherlands

Carlijn I Buis, MD, PhD  
Department of Surgery  
University Medical Center Groningen  
University of Groningen  
The Netherlands

Coby Annema  
Wenckebach Institute, School of Nursing & Health  
Graduate School for Health Research  
University Medical Center Groningen  
University of Groningen  
The Netherlands

Elizabeth B Haagsma, MD, PhD  
Department of Gastroenterology and Hepatology  
University Medical Center Groningen  
University of Groningen  
The Netherlands

Eric J van der Jagt, MD, PhD, Professor of Abdominal Radiology  
Department of Radiology  
University Medical Center Groningen  
University of Groningen  
The Netherlands

Gerrit H op den Dries  
Surgical Research Laboratory  
Department of Surgery  
University Medical Center Groningen  
University of Groningen  
The Netherlands

Heidi Yeh, MD, PhD  
Department of Surgery  
Massachusetts General Hospital  
Harvard Medical School  
Boston, MA, United States of America



Henri GD Leuvenink, PhD  
Surgical Research Laboratory  
Department of Surgery  
University Medical Center Groningen  
University of Groningen  
The Netherlands

James F Markmann, MD, PhD, Claude E Welch Professor of Surgery  
Chief of the Division of Transplant Surgery  
Department of Surgery  
Massachusetts General Hospital  
Harvard Medical School  
Boston, MA, United States of America

Janneke Wiersema-Buist  
Surgical Research Laboratory  
Department of Surgery  
University Medical Center Groningen  
University of Groningen  
The Netherlands

Jelle Adelmeijer  
Surgical Research Laboratory  
Department of Surgery  
University Medical Center Groningen  
University of Groningen  
The Netherlands

Jeroen Kuipers  
Department of Cell Biology  
University Medical Center Groningen  
University of Groningen  
The Netherlands

Korkut Uygun, PhD  
Center for Engineering in Medicine  
Massachusetts General Hospital  
Harvard Medical School  
Boston, MA, United States of America

Maarten WN Nijsten, MD, PhD  
Department of Critical Care  
University Medical Center Groningen  
University of Groningen  
The Netherlands

Marieke T de Boer, MD  
Department of Surgery  
University Medical Center Groningen  
University of Groningen  
The Netherlands

Michael E Sutton, MD  
Surgical Research Laboratory  
Department of Surgery  
University Medical Center Groningen  
University of Groningen  
The Netherlands

Michiel Kuipers  
Surgical Research Laboratory  
Department of Surgery  
University Medical Center Groningen  
University of Groningen  
The Netherlands

Mirjam H Koster  
Surgical Research Laboratory  
Department of Surgery  
University Medical Center Groningen  
University of Groningen  
The Netherlands

Negin Karimian, MD  
Surgical Research Laboratory  
Department of Surgery  
University Medical Center Groningen  
University of Groningen  
The Netherlands

Paulo Martins  
Department of Surgery  
Massachusetts General Hospital  
Harvard Medical School  
Boston, MA, United States of America

Petra J Ottens  
Surgical Research Laboratory  
Department of Surgery  
University Medical Center Groningen  
University of Groningen  
The Netherlands

Robert C Verdonk, MD, PhD  
Department of Gastroenterology and Hepatology  
University Medical Center Groningen  
University of Groningen  
The Netherlands

Robert J Porte, MD, PhD, Professor of Surgery  
Section of Hepatobiliary Surgery and Liver Transplantation  
Department of Surgery  
University Medical Center Groningen  
University of Groningen  
The Netherlands

Ton Lisman, PhD  
Surgical Research Laboratory  
Department of Surgery  
University Medical Center Groningen  
University of Groningen  
The Netherlands



## Acknowledgements

What began as an ambitious idea to humanize pig livers for transplantation into humans whilst on the Frisian island of Schiermonnikoog in 2007, and a subsequent attempt to humanize bile duct and liver tissue of mice, eventually morphed into a thesis on bile duct injury and machine perfusion. Although harvesting human livers from pigs might seem quite a distant ambition from the machine perfusion focus this thesis has attained, both ideas address the problems associated with the chronic worldwide donor shortage. The ambitious beginnings and twists and turns that followed illustrate that a PhD is not only about the published successes, but also the failed projects, which strengthen your motivation and determination to forge onward.

Although this thesis has my name alone printed on the front as sole author, it is a collection of numerous articles with many more contributing authors beyond myself. What's more, many others sit behind these authors in extensive contribution – from lab technicians to friends and family; from transplant coordinators to the local butcher; from transplant surgeons to those generous individuals that have donated their livers to research. A PhD is indeed a group effort, and there are many persons and organizations I would like to acknowledge and thank, for without their help this thesis would not be possible.

**Prof. dr. R.J. Porte**, beste Robert, ik kan me niet voorstellen dat er een betere promotor en begeleider bestaat dan jij! Je bent altijd 100% betrokken geweest bij alle projecten, ik mocht altijd langslopen of bellen en je mateloze enthousiasme liet me zelfs op de minder zonnige onderzoeksdagen lachen. Zonder jouw hulp en gedrevenheid was het machineperfusie onderzoek nooit zo snel van de grond gekomen. Ik bewonder je voor het behouden van je kalmte, humor en enthousiasme in een werkleven vol patiënten en promovendi. Je hebt een grote groep gezellige en enthousiaste jonge onderzoekers om je heen verzameld en ik ben er trots op dat ik daar onderdeel van mocht zijn.

**Prof. dr. J.A. Lisman**, beste Ton, ik ken niemand die zo goed is als jij, als het gaat om wetenschappelijk onderzoek. Jouw tips m.b.t. het schrijven van wetenschappelijke artikelen pas ik iedere keer weer toe. Je supersnelle revisies van manuscripten en heldere blik op onderzoeksprotocollen maken je tot de beste tweede promotor die ik me had kunnen wensen. Bedankt!

Mijn bijzondere dank gaat uit naar de leden van de beoordelingscommissie, **prof. dr. U. Beuers**, **prof. dr. E. Heineman** en **prof. dr. H.J. Verkade** voor het beoordelen van dit proefschrift. Beste Henk Jan, het waren de grappen en grollen van Robert en jou die mij er tijdens de JSM

onderzoekswEEK in 2007 van overtuigden dat wetenschappelijk onderzoek wel eens verrassend leuk kon zijn! Bijzonder dat je zowel aan het begin als aan het einde van mijn promotietijd een significante rol speelt.

In 2012 I was given the opportunity to extend my PhD time with six months of research at the Massachusetts General Hospital/Harvard Medical School in Boston, MA, USA. I would like to thank especially my direct supervisor **Dr. Paulo N. Martins** for his kind invitation and initiation of the collaboration between our research groups. Paulo, I am absolutely thrilled that you have, in return, accepted my invitation to take part in the corona at my PhD defense! To my supervisors **Prof. dr. James F. Markmann** and **Dr. Korkut Uygun**, although I felt that my time in Boston was as brief as it was busy, it was a real pleasure to work in your research groups, become a part of the 'MGH family' and play a role in establishing what I expect to be a very fruitful relationship between our UMCG research group and yours at MGH. Professor Markman, I am very honoured that you are planning to attend my PhD defense, I look forward to seeing you in Groningen!

Lieve **Negin Karimian, Michiel Kuipers, Michael Sutton, Pepijn Weeder** en **Andrie Westerkamp**. Met jullie heb ik letterlijk bloed, zweet en tranen gedeeld voor het onderzoek. Ons bloed gedoneerd aan de rattenlevers, zweeten tijdens de lange perfusie-sessies op OK en de tranen... gelukkig meestal van het lachen! Bedankt voor jullie gezelligheid en inzet! Pepijn, succes en veel plezier met je onderzoek in Boston en het voortzetten van de samenwerking tussen de onderzoeksgroepen van het UMCG en MGH! Dear Negin, despite the fact that when you arrived in January 2012 I dropped you through the ice when skating on the canal at my parents' house in Kollum, we still managed to become great friends! I can not wish for a better friend and colleague to continue our research, and I thank you immensely for the positive energy you've brought to the lab and into my life during the last two years of research – you keep smiling no matter what, even when you're in freezing cold water! I am honored to have you as a paronymph at my PhD defence.

Mede-promovendi/studenten in het Chirurgisch Onderzoekslaboratorium **Edris Alkozai, Marc Kirschbaum, Paria Mahboub, Golnar Karimian, Greg Hugenholtz, Anne Marieke Schut, Alix Matton, Rolando Rebolledo, Marleen van Oosten, Sanne Nieveld, Dane Hoeksma, Leon van Dullemen, Laura Burlage** en mijn (oud)kamergenoten/buren in het Triadegebouw **Welmoet Westendorp, Lucy Crane, Annelien Morks, Jeffrey Damman, Maximilia Hottenrott, Deborah van Dijk, Astrid Klooster, Geert van Rijt, Maarten Speijers, Valerie Wiersma, Marco Verkaik, Ilsalien Bakker** en **Freeha Arshad**. Met jullie het lab, de AIO-kamer en/of de gang delen was bijzonder aangenaam; van Duitse themafeestjes tot samen pipetteren tot vrijdagmiddagborrels met rondvliegende borrelnootjes, het is me een genot geweest! Zonder jullie zou het onderzoek een stuk ongezelliger zijn.

Onderzoekers en analisten van het Chirurgisch Onderzoekslaboratorium **Dr. Henri Leuvenink, Janneke Wiersema-Buist, Petra Ottens, Jacco Zwaagstra, Rozemarijn Kox, Douwe Samplonius, Susanne Veldhuis, Jelle Adelmeijer en Renée Gras**, ik heb jullie ondersteuning, geduld, hulp en uitleg altijd ontzettend gewaardeerd. Janneke, een bijzonder dank voor jou, jij hebt mij de afgelopen twee jaren ontzettend veel geholpen met kleuringen, PCR en overige laboratoriumanalyses, zonder jouw hulp had ik het nu allemaal nog niet kunnen afronden! Petra, bedankt voor de vele rattenhepatectomieën en je hulp met alles wat er voor de proefdieren geregeld moest worden. Henri, bedankt voor het delen van je expertise op het gebied van machineperfusie tijdens het ontwerpen en de bouw van het rattenleverperfusiesysteem.

Patholoog **Prof. dr. Annette S.H. Gouw**, bedankt voor het beoordelen de vele lever- en galwegcouples voor de verschillende studies in dit proefschrift en het mij leren scoren van de galweghistologie. Electronenmicroscopie-expert **Jeroen Kuipers**, ontzettend bedankt voor het aanleren van de benodigde technieken en je enthousiaste ondersteuning! Intensivist **Dr. Maarten W.N. Nijsten** en apotheker **Marina Maurer** wil ik graag bedanken voor het meedenken over de samenstelling van onze perfusievloeistoffen. **Coby Annema** wat fijn dat ik samen met jou het onderzoek in hoofdstuk 12 mocht uitvoeren, jouw ervaring en kennis op het gebied van vragenlijstonderzoek samen met de kritische blik van **Prof. dr. Adelita V. Ranchor** was onmisbaar en erg leerzaam. Mijn voorgangers **Dr. Carlijn I Buis** en **Dr. Harm Hoekstra**, jullie hebben aan de basis gestaan van het onderzoek in het eerste deel van mijn proefschrift. Dank hiervoor!

My colleagues and friends in Boston, **Bote Bruinsma, Hannah Harp, Tim Berendsen, Catheleyne Puts, Nalu Navarro-Alvarez, Adam Farmer, Maria-Louisa Izamis, Zurab Machaidze, James McDaid** and **Heidi Yeh** – thank you for welcoming me so warmly into your research groups and into your groups of friends! I regret not having had more time to spend with you, but I really did appreciate the fun and laughter we had. All the best with your time in Boston and beyond! Of my housemates at 3 Exeter Park in Cambridge I would like to thank 3 very special persons **Dr. Maureen Jackson, Dr. Ingegerd Elvers** and **Federico Fraternali**. Thank you so much for the friendship, the delicious Italian/vegan/nutritious dinners, laughter and support you gave me, especially in the stressful last three months of my PhD thesis. Although our time together was brief, I very much so valued it and I look forward to meeting you all again in the future!

Medewerkers van de Centrale Dienst Proefdieren (CDP), in het bijzonder **Michel Weij, Arie Nijmeijer, Ar Jansen, Natascha Broersma** en **Annemieke Smit-van Oosten**, alsook proefdierdeskundige **Catriene Thuring**. Bedankt voor jullie hulp, inzet en flexibiliteit tijdens



de proefdierexperimenten, met name het varkensperiment, welke organisatorisch een flinke uitdaging bleek te zijn.

De Liver Assist, het apparaat waarmee wij onze humane- en varkenslevers hebben geperfuseerd, werd op de markt gebracht door het bedrijf Organ Assist. Graag wil ik een aantal (oud)medewerkers van Organ Assist persoonlijk bedanken. **Pieter Hamming** bedankt voor je IT ondersteuning en het schrijven van het computerprogramma voor ons druk-gestuurde rattenleverperfusiesysteem. **Martin Kuizenga, Arjan van der Plaats** en **Ron Leuvenink** bedankt voor jullie technische ondersteuning en fysieke aanwezigheid bij de humane- en varkensexperimenten. Heel fijn dat jullie en **Melchior van Voorden** openstonden voor suggesties en dat we hierdoor de Liver Assist samen nog werkzamer hebben kunnen maken. Jullie hebben een fantastisch apparaat in handen en ik verwacht dat Organ Assist een belangrijk rol zal spelen in de transplantatiegeneeskunde van de nabije toekomst. Veel succes!

Mijn bijzondere dank gaat uit naar alle **Nederlandse transplantatiecoördinatoren**, in het bijzonder **Ernst Buiters, Cees Brugman, Sjirk Forma, Teun Bezema, Miranda Danhof-Dalmolen** en **Marjolein Leemkuil**, voor het identificeren van potentieel afgekeurde donorlevers en het verkrijgen van toestemming van de naasten van de donor. Zonder jullie was het humane machineperfusie onderzoek niet van de grond gekomen. Ernst, bedankt voor het uitstralen van je tomeloze enthousiasme voor dit onderzoek! Ik ben ontzettend dankbaar voor de vrijgevigheid van de **donoren en hun naasten** die toestemming gaven om hun lever voor onderzoek te gebruiken, zonder jullie hulp en gulheid was een belangrijk deel van het gedane onderzoek onmogelijk geweest.

Tijdens de 4 maanden waarin Robert Porte in Suriname was, hebben de Groninger levertransplantatiechirurgen en -fellows ons uit de brand geholpen met het voorbereiden van de humane levers op de machineperfusie: **Dr. Ger Sieders, Marieke de Boer, Paul Peeters, Ruben de Kleine** en **Sander Ijtsma**, hartelijk dank hiervoor. Moreover, **Marieke de Boer** and **Dr. Ewen Harrison**, thank you for helping out with several hepatectomies for our pig liver machine perfusion experiment. **Linda Albronda**, secretaresse HPB en levertransplantatie, bedankt voor je hulp bij de administratieve kant van de promotie. Alle **studenten van het levertteam** wil ik graag bedanken voor het verzamelen van de galwegbiopten voor hoofdstuk 7 van dit proefschrift. **Rolf Buining**, Sanquin Bloedbank, hartelijk bedankt voor het verlenen van toegang tot bloedproducten voor de perfusievloeistof van onze humane levers. Slagerij **Dik Hilbrants**, bedankt voor het beschikbaar stellen van stukjes lever en galweg voor wetenschappelijk onderzoek!

Graag bedank ik de (oud)medewerkers, het secretariaat en de oud-voorzitter van de Junior Scientific Masterclass **Dr. Joke van der Mark-van der Wouden, Barbara Slothouber, Dr. ing. Michiel Hooiveld, Jans van Aalst-Ubels** en **Prof. dr. J.C. Kluin-Nelemans** alsmede de **leden van de MD/PhD-beoordelingscommissie** voor het vertrouwen dat jullie mij in 2009 hebben gegeven door mijn aanvraag voor het MD/PhD-traject te honoreren. Fijn dat ik altijd langs mocht lopen met vragen of gewoon voor een kopje thee!

De afgelopen 3,5 jaar ben ik met enthousiasme lid geweest van **Rotaract Groningen** en ik wil graag alle (oud)leden bedanken voor vele mooie projecten die we hebben uitgevoerd en jullie interesse in mijn onderzoek.

Graag bedank ik mijn liefste vriendinnen **Corien Heslinga, Karianne Zwart, Wieke Dalenberg, Leony Reurich** en **Marijke Teeninga**, voor jullie steun, vrolijkheid en onvoorwaardelijke vriendschap, al meer dan 10 jaar! Lieve Wieke, jouw unieke gevoel voor humor gecombineerd met je optimisme en gedrevenheid is uniek, bedankt voor de vele fijne gesprekken, ik ben zo blij dat jij op 13 november mijn paranimf wilt zijn! Lieve **Ilse de Coo** en **Danielle van Deursen** bedankt voor de sportieve afleiding, de vele gezellige avonden en jullie steun. My dear Polish friends **Magda Wojtaszek, Magda Czepnik** and **Marta Samol**. Thank you for your understanding at all the dinners I missed and late nights out I would've otherwise celebrated with you, but for my PhD thesis. Thank you for being such dear friends. I have deep respect for you as PhD candidates in challenging fields of research and work environments, you are doing an amazing job!

Lieve **heit, mem** en **Jorrit Jan**, ik had me geen lievere ouders en broer kunnen wensen. Jullie hebben mij altijd ondersteund in iedere keuze die ik heb gemaakt en ik ben zo blij dat ik met mijn zorgen altijd bij jullie terecht kan. Niet alleen hebben jullie mij mentaal gesteund de afgelopen jaren, jullie hebben zelfs een paar keer in het lab en op de OK gestaan! Hoeveel promovendi kunnen dat van hun ouders zeggen... Heit, bedankt voor het maken van het orgaankamertje voor het rattenleverperfusiesysteem en de prachtige foto's voor het protocol. Mem, bedankt voor je OK-assistentie bij de varkenslever hepatectomieën. Bovenal, bedankt dat jullie er voor mij zijn.

My dearest **Hamish**, thank you for your everlasting support and your beautiful smile that never seems to disappear, you make me the happiest I could possibly be.



## Biography

Sanna op den Dries was born on the 29<sup>th</sup> of April 1986 in Dokkum, Dongeradeel, The Netherlands. Having moved to Kollum with her family at the age of 4, she attended Prins Bernhard primary school in Kollum and graduated from Lauwers College in Buitenpost in 2004. After participating in a one-year high school exchange program through the New Zealand Institute of International Understanding (NZIIU), she enrolled in medical school at the University of Groningen in 2005. During her medical studies, Sanna worked as a student manager with responsibility for 75 students at the International Housing Office for the University of Groningen, was a member (including 1 year as treasurer on the board) of the volunteer service club Rotaract Groningen, and she enjoyed student sport activities such as acrobatic rock 'n roll, rugby and running. In the second year of medical school she participated in the Junior Scientific Masterclass (JSM) research week at the Frisian island of Schiermonnikoog, where she developed an enthusiasm for medical research. After a part-time project in the research group of Prof. dr. Robert J. Porte and Prof. dr. Ton Lisman in 2007 on 'The role of local stem cells in regeneration of extrahepatic bile ducts' she continued with a six month full-time research internship in 2008 in the same group on 'Differentiation of human mesenchymal stem cells into cholangiocytes', which became the topic of her masters thesis. After an additional six months of full-time research on the etiology of bile duct strictures, Sanna published her first scientific paper and was accepted for the MD/PhD program in 2009, which is an honorary program allowing medical students to combine the masters phase of medical school with PhD research to obtain both MD and PhD degrees upon completion. A year of full-time research on bile duct strictures was followed by a year of medical rotations, and in 2011 she started her machine perfusion studies at the UMCG/University of Groningen. In 2013 Sanna extended her PhD program with six months of research in Boston at the Massachusetts General Hospital/Harvard Medical School in order to establish a collaboration between the research group in Groningen and those of Prof. dr. James F. Markmann and Dr. Kurkut Uygun in Boston, under direct supervision of Dr. Paulo N. Martins. After the defense of her PhD thesis in November 2013 and the completion of her medical studies early 2015, Sanna intends to pursue a career in a surgical related field.

